



HAL
open science

Scleroderma mushroom poisoning in France (2000–2022): clinical patterns and early signals of a possible emerging mycotoxic syndrome

Chloé Bruneau, Emilie Arnaud-Nguyen, Jeremy Lecot, Anne Landreau, Gaël Le
Roux

► To cite this version:

Chloé Bruneau, Emilie Arnaud-Nguyen, Jeremy Lecot, Anne Landreau, Gaël Le Roux. Scleroderma mushroom poisoning in France (2000–2022): clinical patterns and early signals of a possible emerging mycotoxic syndrome. *Mycological Progress*, 2026, 25 (1), pp.6. <10.1007/s11557-025-02116-w>. <hal-05493456>

HAL Id: hal-05493456

<https://hal.science/hal-05493456v1>

Submitted on 4 Feb 2026

HAL is a multi-disciplinary open access archive for the deposit and dissemination of scientific research documents, whether they are published or not. The documents may come from teaching and research institutions in France or abroad, or from public or private research centers.

L'archive ouverte pluridisciplinaire **HAL**, est destinée au dépôt et à la diffusion de documents scientifiques de niveau recherche, publiés ou non, émanant des établissements d'enseignement et de recherche français ou étrangers, des laboratoires publics ou privés.



Distributed under a Creative Commons CC BY 4.0 - Attribution - International License



Scleroderma mushroom poisoning in France (2000–2022): clinical patterns and early signals of a possible emerging mycotoxic syndrome

Chloé Bruneau¹ · Emilie Arnaud¹ · Jérémy Lecot¹ · Anne Landreau^{2,3} · Gaël Le Roux^{1,4} · French PCC Research Group

Received: 31 October 2025 / Revised: 11 December 2025 / Accepted: 15 December 2025
© The Author(s) 2026

Abstract

Mushroom poisoning caused by species of the genus *Scleroderma* (“earthballs”) is generally considered benign and limited to mild gastrointestinal symptoms. However, recent clinical observations suggest a wider spectrum of toxicity. This retrospective study analyzed 134 *Scleroderma*-related cases reported to French Poison Control Centers between 2000 and 2022, representing the largest national series to date. Most exposures were accidental, often due to confusion with edible puffballs or truffles. While the majority of patients remained asymptomatic or experienced only minor gastrointestinal effects, nine cases (7%) were of moderate or severe intensity. In addition to vomiting and abdominal pain, several patients presented neurological symptoms such as vertigo, transient consciousness disorders, or myoclonia, as well as cardiovascular abnormalities including hypotension, bradycardia, or tachyarrhythmia. Similar cases have been described in Germany and Japan, with no co-ingestion of other toxic species. Although the responsible compounds remain unidentified, the combination of digestive, neurological, and cardiovascular manifestations, together with geographically dispersed occurrence, meets several defining features of emerging mycotoxic syndromes. These findings suggest that *Scleroderma* poisoning may represent a new toxidromic entity deserving further toxicological and biochemical characterization.

Keywords *Scleroderma* · Mushroom poisoning · Emerging mycotoxic syndrome

Introduction

Mushrooms represent a vast and diverse group of fungi, with thousands of species distributed worldwide. While many are edible, others contain toxins capable of causing a wide range of clinical syndromes, from mild gastrointestinal upset to severe, sometimes fatal, systemic poisoning (White

et al. 2019). In Europe, the most well-known and frequently reported mushroom poisoning syndromes include those caused by cyclopeptide-containing species (e.g., *Amanita phalloides* and related taxa) (Lecot et al. 2023), the gastrointestinal syndrome, and the pantherine syndrome associated with *Amanita muscaria* and *Amanita pantherina* (Satora et al. 2006). In contrast, other forms of mycetism are less common, remain poorly characterized, and are often under-reported (Landreau 2018; Bruneau et al. 2025).

Among these lesser-known poisonings are those caused by species of the genus *Scleroderma* (Pers., *Sclerodermataceae*, *Boletales*) (Phosri et al. 2009), commonly known in English as “onion earthballs.” These gasteroid fungi are generally considered of no culinary value and, in most cases, are associated only with mild gastrointestinal symptoms such as vomiting and diarrhea, or in popular belief, with no symptoms at all. *Scleroderma* basidiospores can cause allergic respiratory reactions, such as rhinitis or conjunctivitis, with skin reactivity observed in about 18% of exposed allergic individuals (Sprenger et al. 1988). However, sporadic cases of more severe toxicity have been reported in Germany, following accidental confusion with *Rhizopogon*, and in Japan,

A list of authors and their affiliations appears at the end of the paper.

Section editor: Ji-Kai Liu.

✉ Gaël Le Roux
galeroux@chu-angers.fr

¹ Grand Ouest Poison Control Center, University Hospital of Angers, 4 Rue Larrey, F-49933 Angers, France

² Faculty of Health, University of Angers, F-49000 Angers, France

³ University of Angers, University of Brest, IRF, and SFR ICAT, 49000 Angers, France

⁴ Inserm, EHESP, and Irset (Institut de Recherche en Santé, Environnement et Travail)–UMR_S1085, University of Angers, CHU Angers, University of Rennes, Angers, France

with cardiovascular and neurological manifestations inconsistent with any currently recognized mycotoxic syndrome (Haber et al. 2016; Sato et al. 2020). Ingestion of *Scleroderma* species is almost always accidental, most commonly resulting from shape confusion with edible puffballs (*Lycoperdon* spp.) or, less frequently, with truffles (Pérez-Moreno and Ferrera-Cerrato 1995; Li et al. 2020). Sitta et al. (2021) consider all European species of the genus *Scleroderma* to be consistently gastrointestinally toxic.

The genus *Scleroderma* is cosmopolitan, occurring in both temperate and tropical regions, and is well adapted to a wide variety of habitats. Most species form ectomycorrhizal associations with a broad range of host plants, including both native and exotic forest trees, although some can adopt a saprotrophic lifestyle. The fruiting bodies are typically small (2.5 to 10 cm) to medium in size, low to the ground, and globose or irregularly spherical in shape, often attached to a rudimentary stipe that may be partly buried in the substrate. The thick, leathery exoperidium is sometimes smooth but often warty and at maturity dries and cracks irregularly to reveal the internal gleba. The name *Scleroderma* derives from the Greek words *skleros* (hard) and *derma* (skin), referring to the fungus's thick, tough outer layer that distinguishes it from “puffballs” and related genera (Eyssartier et al. 2024). The spores are brown, globose, and ornamented with warts or reticulations, and the fruiting bodies typically emit a rubber-like odor when cut. Unlike puffballs, *Scleroderma* species lack a true hymenium. Their basidiospores are produced within peridioles and are released as a powdery mass through the cracks in the peridium. Spore ornamentation—spiny, sub-reticulate, or reticulate—is an important morphological feature for identification and is now complemented by molecular approaches, particularly sequencing of the nuclear ribosomal internal transcribed spacer (nrITS) region (Guzmán 1970; Jeffries 1999). Currently, there are 12 species of the genus *Scleroderma* identified and described in France (Société mycologique de France 2025) for 152 legitimate taxa classified as species in the world (Robert et al. n.d.).

The present study aims to provide a detailed description of *Scleroderma*-related mushroom poisonings in France, based on a retrospective review of cases reported to French Poison Control Centers (PCCs). By compiling the largest national series to date, this study seeks to improve the understanding of *Scleroderma* intoxications, guide clinical management, and contribute to the broader knowledge of mycetism beyond the well-documented classical syndromes.

Material and methods

A retrospective observational study was carried out on all cases of intoxication following ingestion of *Scleroderma* recorded between 2000 and 2022. Data were extracted from

the French Poison Center Information System (SICAP), fed by cases reported to the various French poison centers during the urgent toxicological response. This national database has been approved by the Commission Nationale Informatique et Liberté (CNIL, no. 202–131). A favorable opinion from the local ethics committee was obtained for this study (no. 2023–197).

Case selection and analyzed data

The study included all poisoning cases reported in France between 2000 and 2022 involving exposure to at least one *Scleroderma* species. Species identification was performed by mycology experts (Bourgeois et al. 2017). When species-level identification was not possible, the genus *Scleroderma* was inferred from morphological features described by the patient, namely, a round, spherical, or ovoid shape; absence of an external hymenophore (gills, pores, or spines); and the presence of a colored internal hymenium (gleba).

In one case (case 1), a fruiting body was available and allowed both macroscopic and microscopic identification (Sarasini 2005). Molecular confirmation of the specimen was subsequently performed by the ALVALAB laboratory (<http://www.alvalab.es>), following the protocol previously described (Murray and Thompson 1980; Mullis and Faloon 1987). The DNA sequence obtained by PCR amplification was compared with public reference data using BLAST (Altschul et al. 1990).

The data analyzed included socio-demographic characteristics (age, sex, region, date of poisoning), suspected species, any reported confusion with toxic or edible mushrooms, clinical and laboratory findings, severity of poisoning, clinical outcome, causality assessment, and patient management (place and time to treatment, treatments administered, and length of hospital stay).

Poisoning severity was graded according to the Poisoning Severity Score (PSS): PSS0 (no symptoms), PSS1 (minor), PSS2 (moderate), PSS3 (severe), and PSS4 (fatal) (Persson et al. 1998). Causality (the likelihood that the clinical and laboratory findings were attributable to *Scleroderma* ingestion) was assessed according to the toxicovigilance causality method and classified into five levels: not applicable (no clinical or laboratory signs), not excluded, possible, probable, or very probable (Sinno-Tellier et al. 2025).

Exclusion criteria were as follows: null or not excluded causality, exposure by a route other than ingestion, and poisonings occurring outside mainland France.

Results

Between January 1, 2000, and December 31, 2022, 134 cases of exposure related to the ingestion of *Scleroderma* mushrooms were recorded by French Poison Control

Centers (PCC), corresponding to an average of 34 ± 7.5 cases per year. Both sexes were affected, with a predominance of males (sex ratio = 1.6). Exposed individuals ranged from infants to the elderly (mean age 31.9 years; range 0.87–88 years; median 34 years; standard deviation 27.4), with adults aged 41–64 years representing the most affected group (26% of cases, $n = 35$).

The geographical distribution of cases was uneven across the country (Fig. 1). The three most affected regions were Brittany (18%, $n = 24$), Pays de la Loire (16%, $n = 21$), and Nouvelle-Aquitaine (15%, $n = 20$).

No clear trend emerged from the annual distribution of *Scleroderma* exposures (Fig. 2), which ranged from a minimum of 1 case in 2001 to a maximum of 19 in 2017. Exposures occurred from May to November, with September being the most affected month (29% of cases, $n = 39$).

All reported exposures were accidental, with the majority involving ingestion of a single mushroom species ($n = 114$; 85.1%). In the remaining 20 cases, co-ingestion involved no more than two species. Among accidental cases, 43% ($n = 57$) were due to confusion with another mushroom, most frequently puffballs (*Lycoperdon* spp., 60%) or truffles (25%). A further 39% ($n = 52$) resulted from a lack of risk perception, 10% ($n = 14$) occurred in an unspecified dietary context, and 8% ($n = 11$) involved intentional consumption of a *Scleroderma*.

Precise species identification was achieved in only 31% of cases ($n = 42$). The most frequently identified species was

Scleroderma citrinum ($n = 15$; 11%), followed by *S. bovista* ($n = 14$; 10%) and *S. verrucosum* ($n = 12$; 9%). Most cases ($n = 99$; 73%) were attributed to *Scleroderma* spp. without species-level identification.

The vast majority of patients experienced no symptoms (PSS0) or only mild symptoms (PSS1) ($n = 125$; 93%). Seven cases were of moderate severity (PSS2), and two were severe (PSS3). All cases evolved favorably, with no fatalities or long-term sequelae. Moderate and severe cases ($n = 9$; 7%) were all mono-exposures to *Scleroderma* spp. ($n = 4$), *S. bovista* ($n = 4$), or *S. verrucosum* ($n = 2$). The distribution of cases by species and severity is shown in Table 1.

Overall, 40% of patients ($n = 55$) remained asymptomatic. Among symptomatic cases, the mean time to onset was 70 min ($n = 74$; range 0–240 min; median 60 min; SD 54). Gastrointestinal symptoms were most frequent (97.5%, $n = 77$), predominantly vomiting (65%, $n = 50$), nausea (44%, $n = 34$), and abdominal pain (32.5%, $n = 25$). Neurological symptoms were reported in 24% ($n = 19$), most commonly vertigo (53%, $n = 10$) and altered consciousness (47%, $n = 9$), followed by seizures or myoclonus (11%, $n = 2$). Isolated reports included headache, confusion, hallucinations, and balance disorders.

Cardiac manifestations occurred in 14% of cases ($n = 11$), with hypotension being the most frequent (73%, $n = 8$), followed by arrhythmias (36%, $n = 4$), tachycardia (18%, $n = 2$), and bradycardia (18%, $n = 2$). Other reported signs included hyperhidrosis ($n = 13$), pallor ($n = 4$),

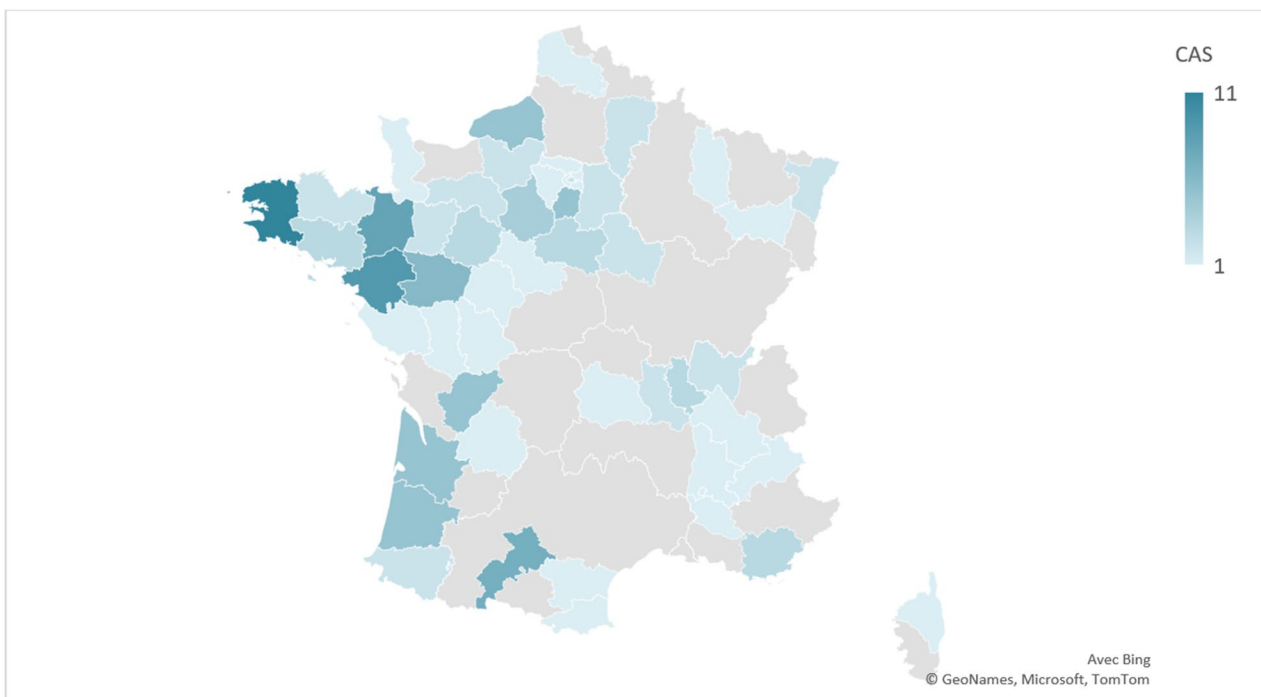


Fig. 1 Geographical distribution of *Scleroderma* poisoning cases between 2000 and 2022 in mainland France ($N = 134$)

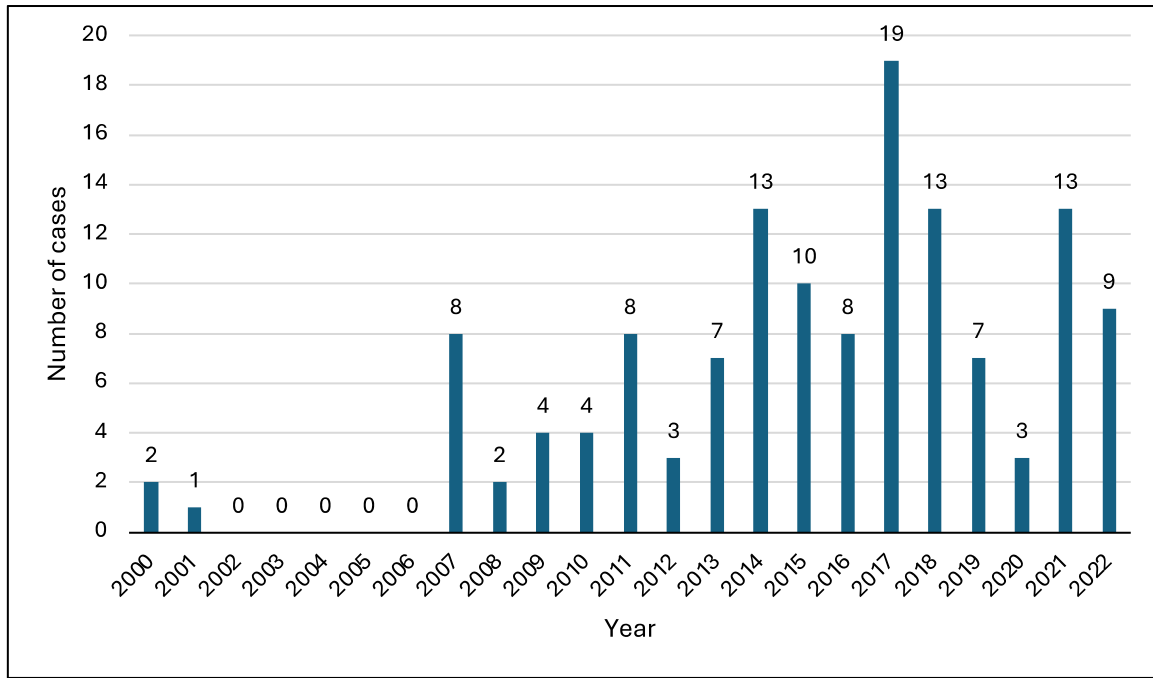


Fig. 2 Number of cases by year ($N=134$)

Table 1 Distribution of cases according to species of mushroom consumed and severity (PSS) ($N=134$)

Mushroom species consumed	Severity			
	PSS 0	PSS 1	PSS 2	PSS 3
<i>Scleroderma</i> spp.	35	40	3	
<i>Scleroderma areolatum</i>	1	1		
<i>Scleroderma bovista</i>	5	4	3	1
<i>Scleroderma citrinum</i>	5	9		
<i>Scleroderma verrucosum</i>	2	3	1	1
<i>S. citrinum</i> and <i>S. verrucosum</i>		1		
<i>S. verrucosum</i> and <i>Scleroderma</i> spp.	3	1		
<i>S. bovista</i> and <i>Collybia</i> spp.	1			
<i>Scleroderma</i> spp. and <i>Agaricus</i> spp.		1		
<i>Scleroderma</i> spp. and boletes		4		
<i>Scleroderma</i> spp. and porcini		2		
<i>Scleroderma</i> spp. and <i>Collybia fusipes</i>	1			
<i>Scleroderma</i> spp. and <i>Russula</i> spp.	2	3		
<i>Scleroderma</i> spp. and an unknown agaricoid mushroom		1		

asthenia ($n=3$), dry mouth ($n=2$), visual disturbances ($n=2$), hypothermia ($n=1$), mydriasis ($n=1$), and exogenous mucosal discoloration ($n=1$).

Biological abnormalities were rare: only one case of transient renal impairment was documented among the

three parameters assessed (renal function, electrolyte balance, and hepatic function).

Among symptomatic patients ($n=79$), management was most often at home (49%, $n=39$) or in hospital (43%, $n=34$), with only 2.5% ($n=2$) consulting a general practitioner. Time to hospital admission was under 3 h in 38% of cases ($n=13$) and between 3 and 6 h in 21% ($n=7$); in 41% ($n=14$), this information was unavailable. Most hospital stays were under 24 h ($n=26$; 76%), and 9% ($n=3$) lasted between 24 and 48 h.

Severe cases (PSS3)

Case 1: A 63-year-old woman with a history of hypertension and uterine cancer (treated with telmisartan and hydrochlorothiazide) collected what she believed to be puffballs (*Lycoperdon* spp.) from her garden, later identified as *Scleroderma bovista* (Fig. 3A), based on macroscopic and microscopic observations (Fig. 3B) and on molecular data. At 12:30 p.m., she consumed a large quantity after cooking. Symptoms began 1 h later with *vertigo*, visual hallucinations, and vomiting. On arrival of the emergency medical service (EMS) at 4 h post-ingestion, she presented with shock (Glasgow Coma Scale 14), severe hypotension (70/40 mmHg), and persistent vomiting. She was transferred to hospital, where initial management included rapid vascular filling with 500 mL of crystalloids, intramuscular adrenaline (0.5 mg), and oxygen therapy. Clinical improvement was rapid, with hemodynamic stabilization. By 22 h post-ingestion, she was discharged




Fig. 3 **A** *Scleroderma bovista* (specimen collected and consumed by the patient). **B** Spore print of the submitted specimen, showing dark brown, globose, and reticulate spores with an average size of $10.1 \times 9.1 \mu\text{m}$. **C** *Scleroderma verrucosum* (photograph by Rémy Péan, MycoDB)

with normal laboratory tests, preserved renal function, and complete resolution of symptoms. Her husband, who shared the same meal, experienced only mild gastrointestinal symptoms.

Case 2: A 68-year-old man consumed at noon a meal containing mushrooms assumed to be puffballs (*Lycoperdon* spp.), later identified as *Scleroderma verrucosum* (Fig. 3C). Symptoms appeared within 20 min, including diarrhea, nausea, and rapid onset of shock. EMS attended at 3 h post-ingestion and confirmed hemodynamic shock with marked hypotension (systolic blood pressure 70 mmHg). On arrival at the emergency department, hypotension persisted despite initial fluid resuscitation. Management included dopamine infusion, continued fluid therapy, and oxygen supplementation. Complete resolution occurred within 24 h, and the patient was discharged the next day after normalization of hemodynamic parameters.

Moderate cases (PSS2)

All moderate cases involved male patients aged between 13 and 78 years. Four cases were due to accidental ingestion by confusion with edible puffballs (*Lycoperdon* spp.). Identified species included *Scleroderma verrucosum* ($n=1$) and *S. bovista* ($n=3$); in three additional cases, the species was not specified (*Scleroderma* spp.). All incidents occurred during a meal in which the mushrooms were cooked, except for one case in which the patient, due to a lack of risk awareness, consumed the mushroom raw. Moderate-intensity poisonings are summarized in Table 2.

Discussion

In this retrospective study covering the period 2000–2022, 134 cases of *Scleroderma* mushroom poisoning were recorded in mainland France. At the population level, such incidents are uncommon and primarily affect young

children and adults (particularly those over 40 years of age) with a slight male predominance (sex ratio, 0.6).

The annual distribution showed no clear trend, although a relative increase cannot be ruled out. The absence of reference data on overall annual fungal exposures limits the ability to confirm any epidemiological trend. The high proportion of cases linked to a lack of risk perception is directly related to the large representation of children under 4 years in the study; in these cases, the mushrooms were consumed raw and generally in small quantities. Intentional consumption with prior knowledge was rare. Most cases resulted from misidentification with other edible mushrooms, particularly puffballs (*Lycoperdon* spp.) and truffles. This highlights the difficulty of accurate identification, their slightly distinctive macroscopic characters even for experienced foragers, and the danger of consuming wild mushrooms that have not been validated by an expert or qualified mycologist. In this series, genus-level identification of *Scleroderma* was often possible based on patient descriptions (globose form, absence of external hymenophore, colored internal gleba), although species-level determination usually required macro- and microscopic examinations. Four species were formally identified: *S. citrinum*, *S. bovista*, *S. verrucosum*, and *S. areolatum*.

Moderate and severe cases involved exclusively mono-exposures to *Scleroderma* spp., *S. bovista*, or *S. verrucosum*, supporting a plausible causal link and ruling out the involvement of another mushroom species. The most common clinical pattern resembled a classical gastrointestinal syndrome, with isolated digestive symptoms (vomiting, nausea, abdominal pain) appearing soon after ingestion. These findings are consistent with existing literature, which reports digestive symptoms as the most frequent presentation of *Scleroderma* poisoning worldwide, regardless of species.

A notable feature of this study is the documentation of atypical presentations, particularly neurological and cardiovascular symptoms. Although relatively infrequent, such manifestations may be clinically significant. This mirrors cases reported in Germany and Japan. The German case

Table 2 Summary of cases of medium-severity scleroderma intoxication

Case	Case 1	Case 2	Case 3	Case 4	Case 5	Case 6	Case 7
Sex, age	M, 53 yrs	M, 13 yrs	M, 60 yrs	M, 78 yrs	M, 76 yrs	M, 16 yrs	M, 65 yrs
Medical history	None	None	Cardiac disease, gout	None	Cardiac disease	Other	Cardiac disease
Circumstances	Unknown	Unknown	Mistaken identity	Mistaken identity	Mistaken identity	Lack of risk perception	Mistaken identity
Species sought/species consumed	<i>S. bovista</i>	<i>S. bovista</i> /puffball	<i>Scleroderma</i> spp./puffball	<i>Scleroderma</i> spp./puffball	<i>Scleroderma</i> spp.	<i>S. verrucosum</i> /puffball	<i>S. bovista</i>
Symptoms							
Time to onset	30 min	20 min	120 min	30 min	180 min	150 min	120 min
Gastrointestinal	Nausea, abdominal pain	Vomiting, nausea, abdominal pain	Nausea	Vomiting	—	Vomiting, abdominal pain	Vomiting
Cardiac	Hypotension (81/48 mmHg)	Hypotension (80/40 mmHg)	Arrhythmia with bradycardia (53 bpm)	—	Hypotension (self-measurement 70/-mmHg)	Hypotension	Hypotension (73/47 mmHg), arrhythmia with tachycardia (130 bpm), fibrillation
Neurological	Altered consciousness, vertigo	Vertigo	Altered consciousness, myoclonus	Confusion	Vertigo	—	Altered consciousness (loss of consciousness, then GCS 8–11), myoclonus
Other	—	—	Hyperhidrosis	Pallor	—	—	Hypothermia (35 °C), pallor, mydriasis
Biological parameters	—	—	—	—	—	—	Functional renal impairment (creatinine 116 µmol/L)
Management—delay/duration	Hospitalized, NR—<24 h	Hospitalized, NR—24–48 h	Hospitalized, 3 h—24–48 h	Hospitalized, 2 h—24–48 h	—	Hospitalized, NR—<24 h	Hospitalized, 2 h—<24 h
Treatment	Fluid resuscitation	Fluid resuscitation	Symptomatic (antiemetic and analgesic)	Fluid resuscitation	—	—	Fluid resuscitation, symptomatic (oxygen, clonazepam)

involved *Scleroderma cepa* and presented with gastrointestinal, neurological, and visual disturbances (including hallucinations and transient achromatopsia) (Haber et al. 2016), while the Japanese case involving *S. albidum* showed bradycardia, hypotension, and neurological symptoms (8). Tegez (15) reported the death of a pot-bellied pig 5 h after ingesting a *S. citrinum* fruiting body. The animal vomited and collapsed within minutes of ingestion and remained weak and recumbent until death. *Scleroderma* species have also been implicated in several dog poisonings in North America, with affected animals showing typical gastrointestinal signs (vomiting, diarrhea, hypersalivation), sometimes accompanied by weakness or tachycardia, even after ingesting small amounts (Beug 2017). In some cases, hypotension could be partially explained by fluid loss due to vomiting, but a direct toxic effect on vascular regulation cannot be excluded.

These atypical features resemble those observed in this study, particularly in the two severe cases. Although these poisonings resulted from mono-exposures, the possibility of contamination by another mushroom or colonization by microorganisms (pathogenic bacteria, molds) cannot be excluded (Nieminen and Mustonen 2020). Consumption circumstances (raw or cooked mushroom, age of the consumer, and unpleasant taste and odor possibly limiting the ingested amount) could also influence severity.

Mycosynthesis analyses have identified several compounds in different *Scleroderma* species (Fig. 4), but none fully explains the symptoms observed. Consistent with its placement within the *Boletales* (Velíšek and Cejpek 2011),

S. citrinum produces polyphenolic pigments derived from pulvinic acid such as sclerocitrin, norbadione A, and xerocomic acid (Gill and Steglich 1987; Zhou and Liu 2010), which have been investigated for their potential antioxidant (Habrant et al. 2009) and radioprotective (Le Roux et al. 2011) properties.

Pulvinic acid derivatives are widespread in edible boletes, and recent work has shown that several purified pigments, including xerocomic acid and methyl variegatate from *Phlebopus portentosus* and *P. spongiosus*, exhibit only weak to moderate cytotoxicity in vitro at micromolar concentrations (Chuankid et al. 2020). This widespread occurrence in edible mushrooms strongly suggests that pulvinic acids are unlikely to represent the toxic principle responsible for the gastrointestinal or atypical neurological and cardiovascular effects observed in *Scleroderma* poisoning. Their contribution, if any, would more plausibly relate to nonspecific mucosal irritation rather than systemic toxicity. Xerocomic acid has also been identified as a potential cytochrome P450 inhibitor (Huang et al. 2009), but no clinically relevant effects have been demonstrated in vivo.

S. bovista contains primarily ergostane- and lanostane-type steroids, as well as a ceramide derivative (Kovacs et al. 2018). *S. polyrhizum* contains sterols and fatty acids (Gonzalez et al. 1983). Previous phytochemical screenings of *Scleroderma verrucosum* performed using colorimetric assays have suggested the presence of broad classes of metabolites such as “alkaloids,” “flavonoids,” or “tannins.” However, these results rely on nonspecific qualitative tests that are

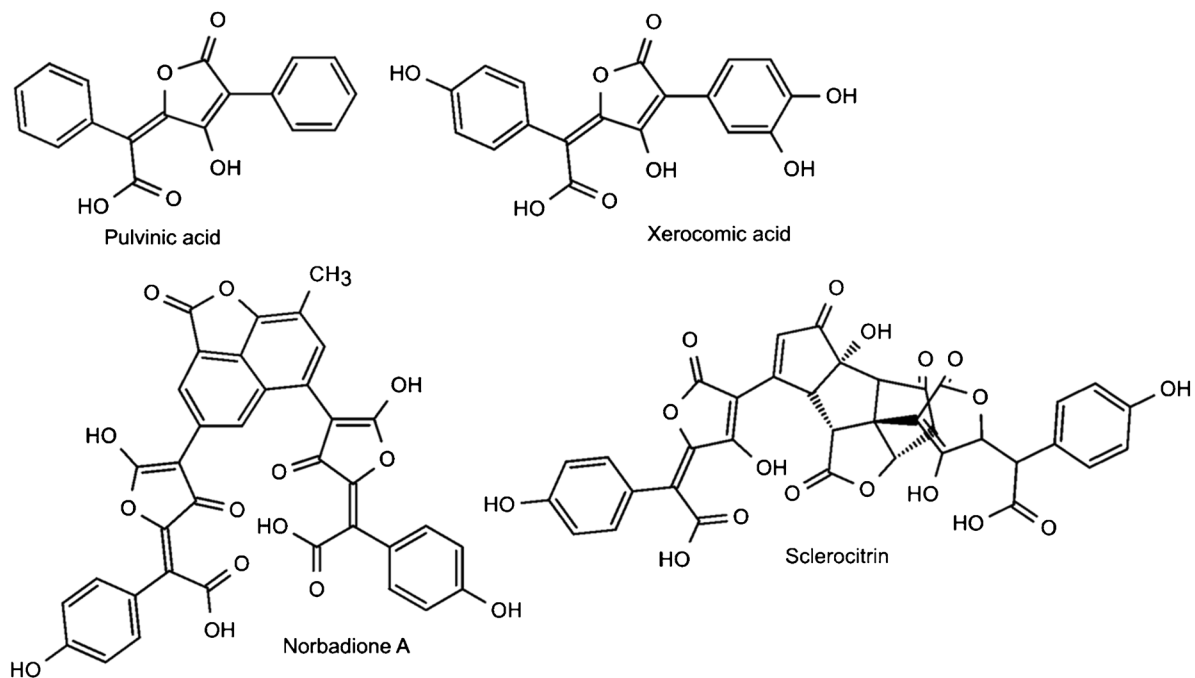


Fig. 4 Pulvinic acid derivatives reported from *Scleroderma citrinum*

known to lack chemical specificity. Furthermore, the ability of *Basidiomycota* to biosynthesize flavonoids remains a matter of debate, as such compounds have only been reported in a few isolated cases (Pukalski and Latowski 2022). We therefore do not consider these findings reliable and restrict the chemical profile of *Scleroderma* species to structurally validated fungal metabolites (e.g., pulvinic-acid derivatives, sterols, fatty acids) reported from well-characterized analyses, while *S. verrucosum* has a broad range of secondary metabolites, including alkaloids and triterpenes (Menezes Filho et al. 2022). No muscarinic alkaloids or other classical cholinergic toxins have been isolated from *Scleroderma* to date. Thus, the muscarinic-like symptoms reported in the Japanese case remain a clinical observation without chemical confirmation. Possible explanations include the presence of as-yet-uncharacterized compounds.

Limits and bias

This retrospective study is subject to the inherent limitations of analyses based on data collected a posteriori from Poison Control Center (PCC) records. Such a design precludes direct control over the quality and completeness of the information and does not account for cases in which no PCC was contacted. Selection bias may also have influenced the final sample size, particularly due to incomplete or inconsistently recorded data in the PCC database at the time of the calls.

Although the study includes 134 cases, moderate-to-severe poisonings ($n = 9$) were relatively uncommon, limiting the statistical power for analyzing these specific clinical presentations. As a result, generalization regarding atypical manifestations of *Scleroderma* poisoning should be approached with caution. Furthermore, several clinical and laboratory variables were absent or incompletely documented. Missing data included laboratory parameter results, time from ingestion to care, alcohol co-consumption, ingested quantity, and preparation method, among others, all of which may have limited the scope of certain analyses.

Despite these limitations, this study provides the most extensive national overview to date of *Scleroderma*-related poisonings in France. It highlights areas for improvement in data collection and clinical documentation and underscores the need for prospective studies to clarify the toxic potential of specific *Scleroderma* species.

Taken together, these findings support the hypothesis that *Scleroderma* intoxication could represent an emerging mycotoxic syndrome.

Beyond the classical benign gastrointestinal picture, several moderate and severe cases revealed consistent neurological and cardiovascular involvement occurring after a short latency and in the absence of co-ingested toxic species.

The “*Scleroderma* toxidrome” fulfills the defining criteria of emerging mycotoxic syndromes: an unexpected clinical expression inconsistent with its previous toxicological classification, simultaneous yet geographically dispersed reports (France, Germany, Japan), and persistent diagnostic uncertainty in the absence of an identified toxin (Saviuc and Danel 2006; Bruneau et al. 2025). Altogether, these observations argue for the recognition of *Scleroderma* poisoning as a potential eighth mycotoxic syndrome, bridging gastrointestinal, neurological, and cardiovascular involvement.

Acknowledgements The authors warmly thank Rémi Péan, from the Société d’Études Scientifiques de l’Anjou, for his valuable assistance to Anne Landreau in the identification of *Scleroderma bovista*.

French PCC Research Group Nathalie Paret^e, Cécile Chevallier^e, Anthony Facile^e, Aurore Czerwiec^e, Ramy Azzouz^f, Anne Garat^f, Patrick Nisse^f, Philippe Chauveau^a, Géraldine Meyer^a, Morgane Cellier^a, Nicolas Delcourt^g, Florent Battefort^g, Alix-Marie Pouget^g, Camille Paradis^h, Audrey Nardon^h, Magali Labadie^h, Romain Torrensⁱ, Julien Reynoardⁱ, Nicolas Simonⁱ, Céline Moulut^j, Marion Evrard^j, Weniko Care^k, Hervé Laborde-Casterot^k, Jérôme Langrand^k

^a‘Grand Ouest’ Poison Control Center, University Hospital of Angers, Angers, France

^eLyon Poison Control Center, Hospices Civils de Lyon (HCL), Lyon, France

^fLille Poison Control Center, University Hospital of Lille, Lille, France

^g‘Occitanie’ Poison Control Center, University Hospital of Toulouse, Toulouse, France

^hBordeaux Poison Control Center, University Hospital of Bordeaux, Bordeaux, France

ⁱMarseille Poison Control Center, AP-HM, Marseille, France

^j‘Est’ Poison Control Center, University Hospital of Nancy, Nancy, France

^kParis Poison Control Center, Toxicology Federation (FeTox), Hôpital Fernand Widal, AP-HP, Paris Cité University, Paris, France

Author contribution Chloe Bruneau: conceptualization, methodology, writing—original draft, supervision. Emilie Arnaud: investigation, data curation, formal analysis, writing—original draft. Jeremy Lecot: visualization, writing—review and editing. French PCC Research Group: participating investigators for data collection. Anne Landreau: conceptualization, supervision, writing—review and editing. Gaël Le Roux: writing—original draft, supervision.

Funding Open access funding provided by Université d’Angers. The authors declare that no funds, grants, or other support was received during the preparation of this manuscript.

Data availability Data available on request.

Declarations

Ethics approval A favorable opinion from the local ethics committee was obtained for this study (no. 2023–197).

Consent to participate Not applicable.

Consent for publication Not applicable.

Competing interests The authors declare no competing interests.

Open Access This article is licensed under a Creative Commons Attribution 4.0 International License, which permits use, sharing, adaptation, distribution and reproduction in any medium or format, as long as you give appropriate credit to the original author(s) and the source, provide a link to the Creative Commons licence, and indicate if changes were made. The images or other third party material in this article are included in the article's Creative Commons licence, unless indicated otherwise in a credit line to the material. If material is not included in the article's Creative Commons licence and your intended use is not permitted by statutory regulation or exceeds the permitted use, you will need to obtain permission directly from the copyright holder. To view a copy of this licence, visit <http://creativecommons.org/licenses/by/4.0/>.

References

- Altschul SF, Gish W, Miller W et al (1990) Basic local alignment search tool. *J Mol Biol* 215:403–410. [https://doi.org/10.1016/S0022-2836\(05\)80360-2](https://doi.org/10.1016/S0022-2836(05)80360-2)
- Beug MW (2017) Mushroom poisoning in North America. *Mycophile - Newsl North Am Mycol Assoc* 57:10–16
- Bourgeois N, Bruneau C, Courtois A et al (2017) La Mycoliste : un outil d'aide à l'identification des champignons impliqués dans les intoxications humaines en France. Bilan de fonctionnement 2014–2015. *Toxicologie Analytique Et Clinique* 29:S32–S33. <https://doi.org/10.1016/j.toxac.2017.03.037>
- Bruneau C, Poilane M, Lecot J et al (2025) Emerging mycotoxic syndromes in France: epidemiological trends and public health implications (2015–2022). *Toxicon*. <https://doi.org/10.1016/j.toxicon.2025.108623>
- Chaukid B, Schrey H, Thongbai B et al (2020) Secondary metabolites of *Phlebotopus* species from Northern Thailand. *Mycol Progress* 19:1525–1536. <https://doi.org/10.1007/s11557-020-01643-y>
- Eyssartier G, Roux P, Buyck B (2024) Le guide des champignons: France et Europe, 5e édition revue et augmentée. Belin, Paris
- Gill M, Steglich W (1987) Pigments of Fungi (Macromycetes). In: Fortschritte der Chemie organischer Naturstoffe / Progress in the Chemistry of Organic Natural Products. Fortschritte der Chemie organischer Naturstoffe / Progress in the Chemistry of Organic Natural Products, vol 51. Springer, Vienna. https://doi.org/10.1007/978-3-7091-6971-1_1
- Gonzalez AG, Barrera JB, Toldo Marante FJ (1983) The steroids and fatty acids of the basidiomycete *Scleroderma polyrhizum*. *Phytochemistry* 22:1049–1050. [https://doi.org/10.1016/0031-9422\(83\)85062-6](https://doi.org/10.1016/0031-9422(83)85062-6)
- Guzmán G (1970) Monografía Del Género *Scleroderma* Pers. Emend. Fr. (*Fungi-Basidiomycetes*). Darwiniana, vol. 16. JSTOR, pp 233–407. <http://www.jstor.org/stable/23213879>. Accessed 6 Jan 2026
- Haber B, Schrett V, Pfab R, Eyer F (2016) Reversible neurotoxicity, gastrointestinal and visual disturbances after consumption of the onion earthball, *Scleroderma cepa* Pers: a case report. *Clin Toxicol* 54:344–351. <https://doi.org/10.3109/15563650.2016.1165952>
- Habrant D, Poigny S, Ségur-Derai M et al (2009) Evaluation of antioxidant properties of monoaromatic derivatives of pulvinic acids. *J Med Chem* 52:2454–2464. <https://doi.org/10.1021/jm801500h>
- Huang Y-T, Onose J, Abe N, Yoshikawa K (2009) *In vitro* inhibitory effects of pulvinic acid derivatives isolated from Chinese edible mushrooms, *Boletus calopus* and *Suillus bovinus*, on cytochrome P450 activity. *Biosci Biotechnol Biochem* 73:855–860. <https://doi.org/10.1271/bbb.80759>
- Jeffries P (1999) *Scleroderma*. In: Cairney JWG, Chambers SM (eds) *Ectomycorrhizal Fungi Key Genera in Profile*. Springer, Berlin, Heidelberg. https://doi.org/10.1007/978-3-662-06827-4_7
- Kovacs B, Béni Z, Dékány M et al (2018) Isolation and structure determination of antiproliferative secondary metabolites from the potato earthball mushroom, *Scleroderma bovista* (*Agaricomycetes*). *Int J Med Mushrooms* 20:411–418. <https://doi.org/10.1615/IntJMedMushrooms.2018026043>
- Landreau A (2018) Intoxication par les champignons : état des lieux des nouveaux syndromes. *Toxicol Anal Clin* 30:158. <https://doi.org/10.1016/j.toxac.2018.07.079>
- Le Roux A, Meunier S, Le Gall T et al (2011) Synthesis and radioprotective properties of pulvinic acid derivatives. *ChemMedChem* 6:561–569. <https://doi.org/10.1002/cmdc.201000391>
- Lecot J, Cellier M, Courtois A et al (2023) Cyclopeptide mushroom poisoning: a retrospective series of 204 patients. *Basic Clin Pharmacol Toxicol* 132:533–542. <https://doi.org/10.1111/bcpt.13858>
- Li H, Zhang H, Zhang Y et al (2020) Mushroom poisoning outbreaks - China, 2019. *China CDC Wkly* 2:19–24
- Menezes Filho ACPD, Ventura MVA, Alves I et al (2022) Phytochemical prospection, total flavonoids and total phenolic and antioxidant activity of the mushroom extract *Scleroderma verrucosum* (Bull.) Pers. *Braz J Sci* 1:1–7. <https://doi.org/10.14295/bjs.v1i1.2>
- Mullis KB, Faloona FA (1987) Specific synthesis of DNA *in vitro* via a polymerase-catalyzed chain reaction. In: *Methods in enzymology*. Elsevier, pp 335–350. [https://doi.org/10.1016/0076-6879\(87\)55023-6](https://doi.org/10.1016/0076-6879(87)55023-6)
- Murray MG, Thompson WF (1980) Rapid isolation of high molecular weight plant DNA. *Nucleic Acids Res* 8:4321–4326. <https://doi.org/10.1093/nar/8.19.4321>
- Nieminen P, Mustonen A-M (2020) Toxic potential of traditionally consumed mushroom species—a controversial continuum with many unanswered questions. *Toxins* 12:639. <https://doi.org/10.3390/toxins12100639>
- Pérez-Moreno J, Ferrera-Cerrato R (1995) A review of mushroom poisoning in Mexico. *Food Addit Contam* 12:355–360. <https://doi.org/10.1080/02652039509374315>
- Persson HE, Sjöberg GK, Haines JA, De Garbino JP (1998) Poisoning severity score. Grading of acute poisoning. *J Toxicol Clin Toxicol* 36:205–213. <https://doi.org/10.3109/15563659809028940>
- Phosri C, Martín MP, Watling R et al (2009) Molecular phylogeny and re-assessment of some *Scleroderma* spp. (*Gasteromycetes*). *An Jardín Botánico Madr* 66:83–91. <https://doi.org/10.3989/ajbm.2199>
- Pukalski J, Latowski D (2022) Secrets of flavonoid synthesis in mushroom cells. *Cells* 11:3052. <https://doi.org/10.3390/cells11193052>
- Robert V, Stegehuis G, Stalpers J (2005) The MycoBank engine and related databases. <https://www.MycoBank.org/>
- Sarasini M (2005) *Gasteromiceti epigei*. Associazione Micologica Bresadola, Vicenza
- Sato Y, Tomonari H, Kaneko Y, Yo K (2020) Mushroom poisoning with *Scleroderma albidum*: a case report with review of the literature. *Acute Med Surg* 7:e460. <https://doi.org/10.1002/ams2.460>
- Satora L, Pach D, Ciszowski K, Winnik L (2006) Panther cap *Amanita pantherina* poisoning case report and review. *Toxicon* 47:605–607. <https://doi.org/10.1016/j.toxicon.2006.01.008>
- Saviuc P, Danel V (2006) New syndromes in mushroom poisoning. *Toxicol Rev* 25:199–209. <https://doi.org/10.2165/00139709-200625030-00004>
- Sinno-Tellier S, Délepine D, Vodovar D et al (2025) Evaluation of the reproducibility and validity of the use of the causality

- assessment method for poisonings designed and applied by the French poison control centres. *Clin Toxicol* 63:570–578. <https://doi.org/10.1080/15563650.2025.2515239>
- Sitta N, Davoli P, Floriani M, Suriano E (2021) *Scleroderma*. In: Guida ragionata alla commestibilità dei funghi, 1st edn. Centro Studi Micologici dell'AMB, Moncalieri, pp 134–135
- Société mycologique de France (2025) MycoDB. <https://mycobd.fr>. Accessed 20 Aug 2025
- Sprenger JD, Altman LC, O'Neil CE et al (1988) Prevalence of basidiospore allergy in the Pacific Northwest. *J Allergy Clin Immunol* 82:1076–1080. [https://doi.org/10.1016/0091-6749\(88\)90146-7](https://doi.org/10.1016/0091-6749(88)90146-7)
- Velíšek J, Cejpek K (2011) Pigments of higher fungi - a review. *Czech J Food Sci* 29:87–102. <https://doi.org/10.17221/524/2010-CJFS>
- White J, Weinstein SA, De Haro L et al (2019) Mushroom poisoning: a proposed new clinical classification. *Toxicon* 157:53–65. <https://doi.org/10.1016/j.toxicon.2018.11.007>
- Zhou Z-Y, Liu J-K (2010) Pigments of fungi (macromycetes). *Nat Prod Rep* 27:1531. <https://doi.org/10.1039/c004593d>

Publisher's Note Springer Nature remains neutral with regard to jurisdictional claims in published maps and institutional affiliations.