



**HAL**  
open science

## Evaluation of image quality parameters in lung using MR elastography technique

Philippe Pouletaut, Fabrice Charleux, Sabine F Bensamoun

► **To cite this version:**

Philippe Pouletaut, Fabrice Charleux, Sabine F Bensamoun. Evaluation of image quality parameters in lung using MR elastography technique. *Multidisciplinary Biomechanics Journal*, 2025, 50th congress of the..., <10.46298/mbj.16134>. <hal-05143113v2>

**HAL Id: hal-05143113**

**<https://hal.science/hal-05143113v2>**

Submitted on 23 Oct 2025

HAL is a multi-disciplinary open access archive for the deposit and dissemination of scientific research documents, whether they are published or not. The documents may come from teaching and research institutions in France or abroad, or from public or private research centers.

L'archive ouverte pluridisciplinaire HAL, est destinée au dépôt et à la diffusion de documents scientifiques de niveau recherche, publiés ou non, émanant des établissements d'enseignement et de recherche français ou étrangers, des laboratoires publics ou privés.



Distributed under a Creative Commons CC BY 4.0 - Attribution - International License

# Evaluation of image quality parameters in lung using MR elastography technique

Philippe Pouletaut<sup>a</sup>, Fabrice Charleux<sup>b</sup>,  
Sabine F. Bensamoun<sup>a\*</sup>

<sup>a</sup> Université de technologie de Compiègne, CNRS, BMBI, UMR7338, Compiègne, France

<sup>b</sup> ACRIM-Polyclinique Saint Côme, Radiology department, Compiègne, France

\* Corresponding author: [sabine.bensamoun@utc.fr](mailto:sabine.bensamoun@utc.fr)

Received date: 04/04/2025

Accepted date: 27/06/2025

Publication date: 27/10/2025

**Keywords:** image quality assessment, magnetic resonance elastography, signal-to-noise ratio, lung stiffness

© 2025 The Authors

Licence CC-BY 4.0

Published by Société de Biomécanique

## 1. Introduction

In clinical practice, lung tissue examination is typically performed using computed tomography (CT), which provides morphological and structural information. Recent studies have shown that even when lung tissue appears structurally normal, without visible infiltrated fibrotic tissue that may induce bronchitis symptoms or signs of emphysema, its stiffness may still be altered (Chakouch et al. 2023).

This stiffness can be quantified using a non-invasive imaging technique called magnetic resonance elastography (MRE). Once the MRE protocol was deemed sufficiently repeatable and reproducible, it was then applied to the monitoring of the lung stiffness in long COVID patients (Bensamoun et al. 2025a) as well as the diagnosis of lung disease caused by tobacco use (Bensamoun et al. 2025b).

While these recent MRE studies have demonstrated that this technique can provide a new imaging biomarker, further development of the MRE lung protocol is necessary. A key aspect of this development is ensuring image quality, which requires evaluating (1) the signal-to-noise ratio (SNR) in MRE magnitude images and (2) the signal quality in stiffness images.

## 2. Methods

### 2.1 Recruitment of smoking patients

A cohort of thirty-four smokers referred for a lung CT test was recruited (#A01496-33) at the radiology

department (ACRIM) of the Saint Côme Polyclinic (Compiègne). CT scans were analyzed by a senior radiologist, focusing particularly on structural properties such as bronchial thickness, opacities, etc.

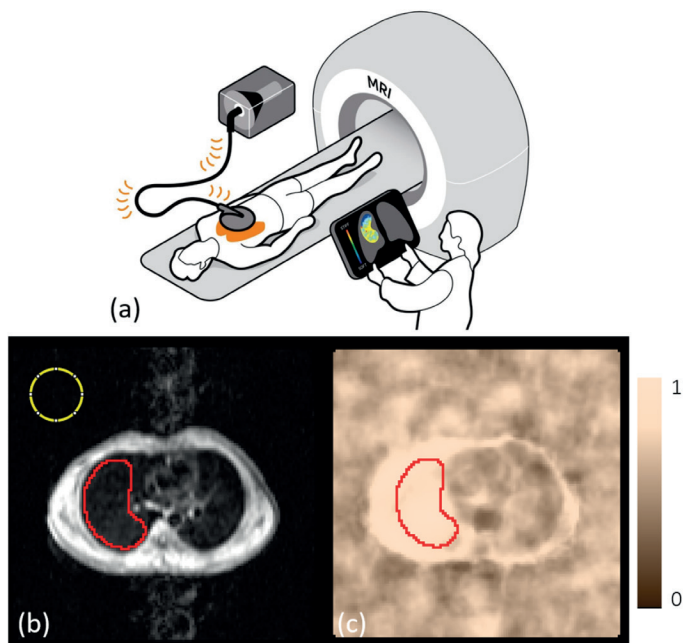
### 2.2 CT, MRI, and MRE image acquisitions

From the CT images, the slice level where the intermediate trunk exhibited a clover-shaped appearance was identified for subsequent MRE assessment in the same lung region. Next, lung density measurement from MRI, acquired using a fast gradient-echo sequence, was calibrated with a Gadolinium-doped water phantom placed on the sternum. MRE test (Fig. 1a) was made using a 1.5 T MRI over a 22 s acquisition. A driver was positioned on the right lung, to avoid heart artefacts, and inducing mechanical shear waves at 50 Hz. A spin-echo echo-planar sequence with motion-encoding gradient was applied to capture shear wave displacement and assess lung stiffness. Data were recorded from 4 axial slices, evenly spaced 15 mm apart, and labeled “Slice 1 to 4” from the upper to the lower level of the patient. Lung stiffness maps were generated from phase and magnitude images using multimodel direct inversion (Silva et al. 2015) and were subsequently corrected for lung density (Bensamoun et al. 2025a).

### 2.3 Magnitude and phase images analysis

The quality of the MRE magnitude images (Fig. 1b) was assessed by computing the signal-to-noise ratio (SNR).

The mean signal intensity ( $m$ ) was measured in the right lung (RL) contoured by a red profile, while the noise, corresponding to the standard deviation ( $\sigma$ ) of the signal intensity, was calculated in the background (BG) delineated by with a yellow circle (Fig. 1b), and integrated in:  $SNR = 0.655 \cdot \frac{m_{RL}}{\sigma_{BG}}$  where the factor 0.655 corrects the standard equation to account for the Rician rather than Gaussian distribution of the background signal (Yu et al. 2019). The quality of the phase image was assessed using stiffness confidence images (Fig. 1c) generated with MRE-Lab software (Mayo Clinic, USA). The red contour was duplicated from the magnitude image, and the mean stiffness confidence (SC) level and the stiffness area with a confidence level higher than 0.95 (AHC) were then calculated.



**Figure 1.** Set-up (a), outlines of the lung (red contour) and background (yellow circle) regions in MR magnitude (b) and stiffness confidence maps (c).

### 2.3 Statistical analysis

The values of SNR, SC and AHC were expressed in mean and standard deviation, and compared between the four slices using two-sample Wilcoxon-Mann-Whitney test.

### 3. Results and discussion

Table 1 shows that the SNR data are not statistically different between slices, with a value of around 4. This result indicates that the magnitude images have

sufficient signal amplitude (4 times higher than the noise) regardless of the selected slice among the four.

However, the stiffness confidence (SC) level and the area of high confidence (AHC) are statistically different ( $P < 0.001$ ) when comparing the value on slice 1 or 2 with those on slice 3 or 4.

**Table 1.** Comparison of image quality parameters in the right lung region of 34 smokers (mean  $\pm$  SD)

	SNR	SC	AHC
Slice 1	4.16 $\pm$ 1.07	0.72 $\pm$ 0.10	1.9 $\pm$ 7.0
Slice 2	3.95 $\pm$ 0.89	0.69 $\pm$ 0.10	1.3 $\pm$ 6.8
Slice 3	4.13 $\pm$ 1.04	0.87 $\pm$ 0.09	23.1 $\pm$ 25.2
Slice 4	4.25 $\pm$ 1.14	0.85 $\pm$ 0.09	19.5 $\pm$ 23.2
All 4 slices	4.18 $\pm$ 0.95	0.79 $\pm$ 0.07	11.8 $\pm$ 0.1

SNR: signal-to-noise ratio; SC: stiffness confidence; AHC: area (%) of high confidence level ( $> 0.95$ ).

The measurement obtained for SC and AHC parameters revealed that lung stiffness is more accurately estimated on slices 3 and 4, which correspond to the lower regions of the right lung. In contrast, the phase difference measured by MRE in the upper slices may be less reliable due to the reflections of the mechanical wave on the ribs of the thoracic cage. As a result, lung stiffness values are likely more impacted by phase difference measurement in the upper lung slices.

### 4. Conclusions

This study has demonstrated the good quality of the images produced by the MRE lung tests. Furthermore, the analysis has provided valuable insights for reducing scan time. Specifically, lung stiffness could be reliably assessed using only the two lower slices, instead of the current four, thereby improving the confidence level in stiffness measurements while streamlining the procedure. In perspective, the MRE protocol could be improved by generating shear waves in right and left lungs.

### Conflict of Interest Statement

None.

### Contributor Roles

PP: Software, Methodology, Writing original draft; SFB: Methodology, Writing original draft; Supervision,

Funding acquisition, Validation, Writing-review & editing; FC: Validation, Writing-review & editing.

## Funding

This project was co-funded by the European Union through the European Regional Development Fund (FEDER/ERDF) within the framework of the Contrat de Plan Etat-Région (CPER) tecsante 2021–2027 for the Hauts-de-France region.

## References

- Bensamoun, S. F., McGee, K. P., Chakouch, M., Pouletaut, P., & Charleux, F. (2025a). Monitoring of lung stiffness for long-COVID patients using magnetic resonance elastography (MRE). *Magnetic Resonance Imaging*, *115*, 110269. <https://doi.org/10.1016/j.mri.2024.110269>
- Bensamoun, S.F., McGee, K., Chakouch, M., Pouletaut, P., & Charleux, F. (2025b). Quantification of Lung Stiffness Using Magnetic Resonance Elastography (MRE): Clinical Validation for Smokers. *IEEE Transactions on Biomedical Engineering*, *72*(9), 2851–2858. <https://doi.org/10.1109/TBME.2025.3553375>
- Chakouch, M. K., Pouletaut, P., Charleux, F., Bensamoun, S. F. (2023). How magnetic resonance elastography (MRE) could provide biomechanical properties to complete computed tomography (CT) scan lung diagnostic? 48th Congress of the Society of Biomechanics. *Computer Methods in Biomechanics and Biomedical Engineering*, *26* (sup1), S128. <https://doi.org/10.1080/10255842.2023.2246304>
- Silva, A. M., Grimm, R. C., Glaser, K. J., Fu, Y., Wu, T., Ehman, R. L., & Silva, A. C. (2015). Magnetic resonance elastography: evaluation of new inversion algorithm and quantitative analysis method. *Abdominal imaging*, *40*, 810–817. <https://doi.org/10.1007/s00261-015-0372-5>
- Yu, S., Dai, G., Wang, Z., Li, L., Wei, X., & Xie, Y. (2018). A consistency evaluation of signal-to-noise ratio in the quality assessment of human brain magnetic resonance images. *BMC Medical Imaging*, *18*, 1–9. <https://doi.org/10.1186/s12880-018-0256-6>