



HAL
open science

Outcome and recurrence patterns of low-risk gonadal germ cell tumors in children and adolescents

Tiphaine Courtel, Sylvie Chabaud, Daniel Orbach, H el ene Sudour-Bonnange, Cecile Verit e, Angelique Rome, Cecile Dumesnil, Brice Fresneau, Estelle Thebaud, Marleen Renard, et al.

► To cite this version:

Tiphaine Courtel, Sylvie Chabaud, Daniel Orbach, H el ene Sudour-Bonnange, Cecile Verit e, et al.. Outcome and recurrence patterns of low-risk gonadal germ cell tumors in children and adolescents. *Pediatric Hematology Oncology Journal*, 2025, 10 (1), pp.51 - 56. <10.1016/j.phoj.2025.02.002>. <hal-05075029>

HAL Id: hal-05075029

<https://hal.science/hal-05075029v1>

Submitted on 20 May 2025

HAL is a multi-disciplinary open access archive for the deposit and dissemination of scientific research documents, whether they are published or not. The documents may come from teaching and research institutions in France or abroad, or from public or private research centers.

L'archive ouverte pluridisciplinaire **HAL**, est destin e au d ep ot et  a la diffusion de documents scientifiques de niveau recherche, publi es ou non,  emanant des  tablissements d'enseignement et de recherche fran ais ou  trangers, des laboratoires publics ou priv es.

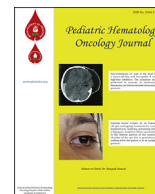

Distributed under a Creative Commons CC BY-NC-ND 4.0 - Attribution - Non-commercial use - No Derivative Works - International License



Contents lists available at ScienceDirect

Pediatric Hematology Oncology Journal

journal homepage: www.journals.elsevier.com/pediatric-hematology-oncology-journal

Outcome and recurrence patterns of low-risk gonadal germ cell tumors in children and adolescents



Tiphaine Courtel ^{a,m,*}, Sylvie Chabaud ^b, Daniel Orbach ^c, H el ene Sudour-Bonnange ^d, Cecile Verit e ^e, Angelique Rome ^f, Cecile Dumesnil ^g, Brice Fresneau ^h, Estelle Thebaud ⁱ, Marleen Renard ^j, Aissatou Barry ^b, Frederic Hameury ^k, Frederique Dijoud ^l, Cecile Faure Conter ^a

^a Institut d'Hemato-oncologie P ediatrique, Department of Pediatric Oncology, Lyon, France

^b Statistical unit, Clinical Research department, Centre L eon B erard, Lyon, France

^c SIREDO Oncology Center (Care, Innovation and Research for Children, Adolescents and young Adults with Cancer) Institut Curie, PSL University, Paris, France

^d Pediatric and Adolescents Oncology Unit, Anti-Cancer Center Oscar Lambret, Lille, France

^e Pediatric Hematology-Oncology Unit, Pellegrin Hospital, CHU Bordeaux, Bordeaux, France

^f Department of Pediatric Oncology of Timone Children's Hospital, Marseille, France

^g Department of Pediatric Oncology, University Hospital Center of Rouen, Rouen, France

^h Gustave Roussy, Universit e Paris-Saclay, Department of Children and Adolescent Oncology, Paris-Saclay University, Paris-Sud University, CESP, INSERM, Villejuif, France

ⁱ Department of Pediatric Oncology, University Hospital Center of Nantes, Nantes, France

^j Department of Paediatric Hemato-oncology, University Hospital, Leuven, Belgium

^k H opital Femme M ere Enfant, Department of Pediatric Surgery, Lyon, France

^l Institut Multisite de Pathologie, CHU de Lyon, France

^m Unit e d'Onco-H emato-Immunologie p ediatrique, CHU Angers, Angers, France

ARTICLE INFO

Article history:

Received 4 December 2024

Received in revised form

17 February 2025

Accepted 24 February 2025

Available online 25 February 2025

Keywords:

Germ cell tumors

Chemotherapy

Risk factors

Stage I

Children

Gonadal

ABSTRACT

Pediatric low-risk gonadal germ cell tumors (LR-GCTs) are typically managed with close surveillance following surgery alone. However, the patterns of relapse and prognostic factors for relapse remain insufficiently understood. We reviewed 72 patients under 19 years old diagnosed with low-risk ovarian (OGCT) or testicular (TGCT) GCT between May 27, 2014, and December 31, 2022, from the TGM13-observatory (EudraCT 2013-004039-60). Among 30 OGCT (median age 13 years), 15 were dysgerminomas and 15 were non-dysgerminomatous OGCT (NDOGCT), with 10 patients having incomplete abdominal staging. Eleven relapses were observed, nine of which were locoregional. The three-year progression-free survival (PFS) was 73 % (95 % CI: 44–89) for dysgerminomas and 53 % (95 % CI: 26–74) for NDOGCT ($p = 0.22$). Among the 42 testicular tumors (median age 3 years), all but one were NSGCTs. Ten relapses occurred, resulting in one death. The three-year PFS for testicular GCTs was 76 % (95 % CI: 59–86). Relapse patterns differed by age: in toddlers, relapses predominantly occurred in the lungs, while in adolescents, relapses were primarily in the para-aortic lymph nodes. The median time to relapse was six months. No significant prognostic factors for relapse were identified, including older age (>11 years), incomplete staging for OGCT, and the presence of lymphovascular invasion or embryonal carcinoma for TGCT. Survival after relapse remains excellent, and further research with a larger sample of children is needed to better identify risk factors for relapse in pediatric LR-GCTs.

  2025 Pediatric Hematology Oncology Chapter of Indian Academy of Pediatrics. Published by Elsevier B.V. This is an open access article under the CC BY-NC-ND license (<http://creativecommons.org/licenses/by-nc-nd/4.0/>).

* Corresponding author. Unit e d'Onco-H emato-Immunologie p ediatrique, Centre Hospitalier Universitaire Angers, Angers, France.

E-mail address: tiphaine.courtel@chu-angers.fr (T. Courtel).

Abbreviations

AFP	Alpha-fetoprotein
BEP	Bleomycin, Etoposide, Platinum
CI	Confidence interval
CT	Computed tomography
EC	Embryonal carcinoma
EFS	Event-free survival
FIGO	International Federation of Gynecology and Obstetrics
GCT	Germ cell tumors
IT	Immature teratoma
LR	Low risk
LR-GCT	Low-risk germ cell tumor
LVI	Lymphovascular invasion
MD	Missing data
MT	Mature teratoma
NSGCT	Non-seminomatous germ cell tumor
NDOGCT	Non-dysgerminomatous ovarian germ cell tumor
OGCT	Ovarian germ cell tumor
OS	Overall survival
PFS	Progression-free survival
TGCT	Testicular germ cell tumor
TNM	Tumor, node, metastasis
YST	Yolk sac tumor

1. Introduction

Low-risk germ cell tumors (LR-GCTs) are confined to the gonads, with no evidence of metastasis based on clinical, radiological, and biochemical evaluations, and are fully resected during initial surgery. These tumors are classified as TNM pS1 for testicular GCTs [1] and FIGO IA1 for ovarian GCTs [2]. In the TGM 2013 protocol [3], they are designated as *Extension A*, which forms the basis of this study. Among adult testicular GCTs, stage I is the most common at diagnosis, accounting for 50–70 % of cases [4]. In pediatric GCTs across all sites, stage I represents about 25 % of cases [5]. In ovarian GCTs, adult studies show relapse rates of 36 % for FIGO (International Federation of Gynecology and Obstetrics) stage IA non-dysgerminomatous GCTs (NDGCTs) and 22 % for dysgerminomas [6], with incomplete staging being the primary risk factor for recurrence [7]. For apparent stage I testicular GCTs managed with surgery alone, relapse rates are 27 % for NSGCTs [8] and 17 % for seminomas [9]. Prognostic factors linked to relapse in adults include lymphovascular invasion (LVI) and the presence of embryonal carcinoma components [10,11]. While adjuvant chemotherapy reduces relapse risk, it does not improve overall survival and introduces potential acute and long-term toxicities [9,12–14]. Consequently, one or two cycles of chemotherapy are considered for patients at high risk of relapse, alongside active surveillance. However, the biology of GCTs differs greatly between pediatric and adult populations [15]. This study aimed to assess relapse risk in children with stage I gonadal GCTs, evaluate relapse patterns, and identify pediatric-specific risk factors.

2. Materials and methods

2.1. Population and treatment

This multicenter study used prospective data from the TGM13 Observatory, which included 29 centers from the French Society of Pediatric Oncology (SFCE) and seven centers in Belgium. It involved patients aged 0–18 years diagnosed with gonadal LR-GCTs between May 27, 2014, and December 31, 2022. Inclusion criteria were: (i) tumor localized to gonadal sites; (ii) histological diagnosis of seminomatous or non-seminomatous GCTs, excluding pure mature teratomas; and (iii) post-surgical stage classified as TNM pS1 [1] for testicular tumors or FIGO IA [2] for ovarian tumors. Patients were managed according to the TGM2013 protocol (EudraCT 2013-

004039-60) [3], which recommended surgery followed by close monitoring. In case of relapse, chemotherapy was administered, with or without additional surgery [3]. Surgical adherence to the protocol was assessed through pathology and surgical report reviews. For ovarian tumors, surgical adequacy required complete intra-abdominal exploration to ensure full FIGO staging, including: (i) inspection of the peritoneal cavity; (ii) documentation of the contralateral ovary; (iii) peritoneal cytology analysis; and (iv) en bloc tumor resection. If any element of the exploration was incomplete, the tumor was classified as stage IX for the purpose of this study. For testicular tumors, adequacy was defined as clamping the spermatic cord at the inguinal ring followed by radical orchidectomy, typically via an inguinal approach, but a scrotal approach was acceptable if the tumor size prevented inguinal access.

2.2. Regulatory aspects

The TGM13 Observatory was approved by the Southeast IV Protection of People Committee (No. CPP 13/065) on October 23, 2013. Participation required documented consent from patients, their parents, or legal representatives, ensuring ethical compliance and respect for autonomy.

2.3. Statistical analyses

Survival outcomes were analyzed using the Kaplan–Meier method. Progression-free survival (PFS) was the time from diagnosis to relapse, death, or last patient contact. Overall survival (OS) was the time from diagnosis to death the date or last follow-up for living patients. PFS was further analyzed based on tumor type, surgical approach for ovarian tumors, presence of LVI and embryonal carcinoma in testicular tumors, and age (younger or older than 11 years). Subgroup comparisons of PFS were done using the Log-Rank test. All analyses were performed using SAS® software, version 9.4 (Cary, NC, USA).

3. Results

A total of 72 patients with low-risk gonadal GCTs were identified (Table 1). Of these, 30 had ovarian GCTs. Fifteen of these were dysgerminomas, including five associated with gonadal dysgenesis. The other 15 were NDGCTs, with 14 containing at least a yolk sac tumor (YST) component, and one classified as an immature teratoma. All NDGCTs had elevated alpha-fetoprotein (AFP) levels, with six cases below 1000 ng/ml, four between 1000 and 10,000 ng/ml, and five above 10,000 ng/ml. Eight ovarian GCTs, including six dysgerminomas and two NDGCTs, showed increased HCG levels, all under 5000 IU/L. Elevated LDH was noted in eight cases, including three dysgerminomas, with levels more than 10 times the normal limit. The median age at surgery for ovarian GCTs was 13 years, ranging from 6 to 17 years, with seven patients under 11 years. Incomplete surgical exploration, classified as Stage IX, occurred in 10 patients. This was due to missing peritoneal cytology in three cases, lack of peritoneal exploration in four, and failure to examine the contralateral ovary in three. One patient underwent tumor morcellation with an endobag. All five patients with gonadal dysgenesis had prophylactic contralateral gonadectomy.

In the testicular GCT group, 42 patients were identified, including one with a pure seminoma. Of the 41 NSGCTs, 36 contained at least a YST component, and 15 had embryonal carcinoma components (Table 1). Lymphovascular invasion (LVI) was present in 13 patients (31 %), with data missing for one case. The median age at surgery for testicular GCTs was three years ranging from 0 to 18 years. The age distribution showed two peaks: 23 patients were

Table 1
Characteristics of patients with ovarian and testicular LR-GCT.

		OVARY n = 30	TESTIS n = 42	TOTAL
Age years	Median age (range), years	13 (6–17)	2.8 (0–18)	
	<11 years	8	24	32
	≥11 years	22	18	40
Surgical adequacy	Yes	20	42	62
	No	10	–	–
Histology	NSGCT/NDGCT	3	22	25
	•Pure Yolk sac tumor	–	–	–
	•Pure Embryonal carcinoma	–	3	3
	•Mixed NSGCT	12	16	28
	Of which containing EC	1	12	13
	Seminoma/dysgerminoma	15	1	16
	LVI			
	•Yes	NA	13	13
•No	NA	28	28	
•MD	NA	1	1	

Abbreviations: EC: embryonal carcinoma; LVI: lymphovascular invasion; MD: missing data; NA: not applicable; NDGCT: Non dysgerminomatous germ cell tumor; NSGCT: Non seminomatous germ cell tumor.

under four years, 18 were over 13 years, and one was eight years old. All testicular surgery followed protocol guidelines.

After a median follow-up of 47 months (range 15–109), 11 relapses occurred among the 30 patients with ovarian GCT, including four out of 15 dysgerminomas and seven out of 15 NDGCTs (Table 2). The median time to relapse was 5.8 months (range 2–15). Relapse patterns included three cases with lymph node involvement, three with peritoneal recurrence, four with multiple-site relapses, and one isolated biological relapse with elevated tumor markers but no detectable clinical masses (Table 2). Tumor marker elevation was seen in seven of the 11 relapsed cases. The 3-year PFS for ovarian GCTs was 63 % (95 % CI: 44–78) (Fig. 1). All relapsed patients achieved complete remission after three or four courses of chemotherapy.

Among the 42 patients with testicular GCT, 10 progressed, including one with seminoma and nine with NSGCT (Table 3). The median time to relapse was 5.6 months (range 2–26), with the seminoma relapse occurring last. Relapse patterns varied by age and histology. In children under three, all relapses involved YST histology, with four in the lungs and one in the kidney, all linked to elevated AFP levels. In adolescents over 16, relapses occurred only in lymph nodes and included cases of embryonal carcinoma, mixed NSGCT, and seminoma, with two relapses showing no tumor marker elevation. The three-year PFS for testicular GCTs was 76 %

(95 % CI: 59–86) (Fig. 1). One patient relapsed with lymph node involvement and died suddenly before completing chemotherapy, while others achieved complete remission after three or four courses of chemotherapy.

An analysis of relapse risk factors is shown in Table 4. Age (11 years and above vs less than) had no significant impact on outcome for ovarian or testicular tumors (p = 0.41 and p = 0.53, respectively). In testicular tumors, LVI and EC did not affect PFS (p = 0.12 and p = 0.58). For ovarian tumors, PFS was similar between NDGCT and dysgerminoma histotypes (3-year PFS rates of 53 % and 73 %, respectively; p = 0.22). Completeness of surgical staging also had no significant effect on outcome (p = 0.55).

4. Discussion

This series confirms the excellent overall survival rate for patients with LR-GCTs. Recurrence patterns varied by tumor site, histology, and patient age. Ovarian non-dysgerminomatous tumors had a notably higher recurrence rate (7 out of 15 cases), which is consistent with other pediatric GCT studies. In ovarian GCT, recurrence risk after surgery alone is significant. For example, a pediatric series from the Children’s Oncology Group of 25 NDOGCTs reported a 4-year PFS of 52 %, which is similar to our 3-year PFS of 53 % [16]. Similarly, a French adult study showed a 5-year event-free survival

Table 2
Characteristics of patients with ovarian LR-GCT who experienced a relapse.

Patient number	Age (years)	Histology	Site of relapse	Tumor markers at relapse	Delay of relapse (months)	Status and post diagnosis follow up
Patient #1	6	Dysgerminoma	Lymph node (retroperitoneum)	normal	10	CR 95 months
Patient #2	7	Dysgerminoma	Lymph node (retroperitoneum)	normal	6	CR 84 months
Patient #3	11	ND-GCT (YST-IT)	Peritoneum	elevated	3	CR 36 months
Patient #4	11	ND-GCT (YST-IT)	Peritoneum	elevated	3	CR 66 months
Patient #5	12	Dysgerminoma	None (Biological only)	elevated	6	CR 98 months
Patient #6	12	ND-GCT (YST)	Lymph node (abdomen) + lung	elevated	3	CR 74 months
Patient #7	13	ND-GCT (YST-MT)	Lymph node (abdomen) + Peritoneum	elevated	3	CR 64 months
Patient #8	13	ND-GCT (IT-MT)	Peritoneum	normal	16	CR 36 months
Patient #9	14	ND-GCT (YST-MT)	Lymph node (abdomen) + peritoneum + contralateral ovary	elevated	2	CR 95 months
Patient #10	16	Dysgerminoma	Lymph node (retroperitoneum)	normal	11	CR 55 months
Patient #11	17	ND-GCT (YST)	Peritoneum + Uterus	elevated	11	CR 33 months

Abbreviations: CR: complete remission; IT: immature teratoma; LR-GCT: Low risk germ cell tumor; MT: mature teratoma; ND-GCT: Non dysgerminomatous germ cell tumor; YST: yolk sac tumor.

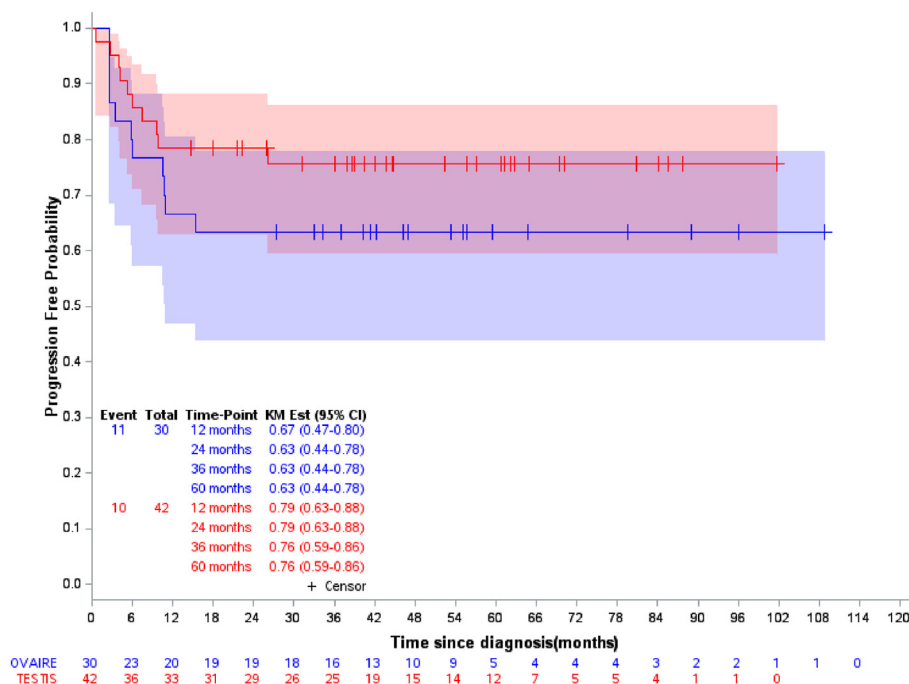


Fig. 1. Progression-free survival (PFS) for ovarian and testicular low-risk germ cell tumors.

Abbreviations: CI: Confidence interval; PFS: Progression free survival; LR-GCT: low risk germ cell tumors.

Table 3

Characteristics of patients with testicular LR-GCT who experienced a relapse.

Patient number	Age (years)	Histology	Site of relapse	Tumor markers at relapse	Delay of relapse (months)	Status and post diagnosis follow up
Patient #12	1	NS-GCT (YST)	Lung	elevated	5	CR 37 months
Patient #13	1	NS-GCT (YST)	Lung	elevated	10	CR 16 month
Patient #14	1	NS-GCT (YST)	kidney	elevated	6	CR 49 months
Patient #15	2	NS-GCT (YST)	Lung	elevated	7	CR 11 months
Patient #16	3	NS-GCT (YST-MT)	Lung	elevated	10	CR 85 months
Patient #17	16	Seminoma	Lymph node (retroperitoneum)	normal	26	CR 62 months
Patient #18	17	NS-GCT (EC-YST-MT)	Lymph node (retroperitoneum)	elevated	4	CR 32 months
Patient #19	17	NS-GCT (EC)	Lymph node (retroperitoneum)	normal	4	CR 82 months
Patient #20	17	NS-GCT (EC-YST-MT)	Lymph node (retroperitoneum)	elevated	3	CR 38 months
Patient #21	18	NS-GCT (EC)	Lymph node (retroperitoneum)	elevated	2	Death, 4 months

Abbreviations: CR: complete remission; EC: embryonal carcinoma; LR-GCT: Low risk germ cell tumor; MT: mature teratoma; NS-GCT: Non seminomatous germ cell tumor; YST: yolk sac tumor.

Table 4

Analysis of risk factors affecting PFS.

	Risk factors		Number of patients	3-y PFS (CI 95 %)	Log rank test p-value
Ovary	Histology	Dysgerminoma	15	73 (44–89)	p = 0.22
		NDGCT	15	53 (26–74)	
	Surgical adequacy	No (Stage IX)	10	70 (33–89)	p = 0.55
		Yes (FIGO IA)	20	60 (36–78)	
	Age	<11 years	8	75 (31–93)	p = 0.41
≥11 years		22	59 (36–76)		
Testis	Lymphovascular invasion	Yes	13	62 (31–82)	p = 0.12
		No	28	82 (62–92)	
	Embryonal carcinoma	Yes	15	73 (44–89)	p = 0.58
		No	27	77 (56–89)	
	Age	<11 years	24	79 (57–91)	p = 0.53
≥11 years		18	71 (44–87)		

Abbreviations: CI: Confidence interval; NDGCT: Non dysgerminomatous germ cell tumor; PFS: Progression free survival.

of 54.6 % for surgery-only patients, compared to 94.4 % for those receiving adjuvant chemotherapy [17]. However, survival rates remain excellent when chemotherapy is given only at relapse, with survival rates between 95 % and 98.5 % [16,18,19]. As a result, some adult and pediatric groups have abandoned routine chemotherapy for stage I ovarian tumors, relying on careful monitoring of tumor markers [18,20,21]. This strategy allows chemotherapy to be reserved for relapses [7,17], avoiding unnecessary exposure for others. The AGCT 1531 protocol (EudraCT number: 2018-004141-17) [22], is currently evaluating whether complete surgical resection followed by surveillance can maintain a 2-year overall survival rate of at least 95.7 % in pediatric, adolescent, and adult patients with LR-OGCT.

Incomplete staging was observed in 33 % of cases in our study (10 out of 30), a marked improvement compared to 2008 French pediatric study where 53 % of cases had incomplete staging [23]. A more recent adult study (MITO-9) found incomplete peritoneal staging in 34.7 % of cases, indicating better adherence to staging protocols over time [7]. Although incomplete staging has been linked to relapse risk in some studies, this was not observed in our series, but the sample size was small.

For testicular LR-GCT, our three-year PFS of 76 % is similar to the COG 4-year EFS of 74 % and 100 % 4-year OS in 80 testicular GCT cases treated with surgery alone [24]. Relapses in that study were characterized by elevated AFP, with retroperitoneal lymphadenopathy and pulmonary metastases. Risk factors for relapse included age over 10, mixed histology, and LVI. In contrast, a German pediatric series [18] showed a lower relapse rate of 11.3 %. Relapses were more common in the 15–18 year age group. Larger adult studies report that abdominal relapses are the most common, with pulmonary relapses less frequent [13,25]. Tumor marker elevation in adults is inconsistent, with LVI and embryonal carcinoma increasing relapse risk, which was not seen in our study [13,26].

The current series highlights age-related differences in relapse patterns. In young children, relapses were mostly hematogenous, with lung metastases and consistently elevated AFP levels. In adolescents, relapses were more commonly in retroperitoneal lymph nodes, with more varied tumor marker elevations [27]. These findings suggest that surveillance strategies should be age-specific, and for young children with testicular YSTs, regular AFP monitoring may be more valuable than abdominal computed tomography (CT) scans. In contrast, surveillance for adolescents with TGCT could follow the adult approach, relying more on abdominal and thoracic CT scans to track lymphatic spread.

In the literature, patients over 11 years old with stage II to IV germ cell tumors have a higher risk of recurrence [28]. In our series, age did not significantly affect prognosis, but this could be due to the small sample size. The AGCT1531 protocol [22] may help clarify this further.

Although this series offers some valuable insights, the small sample size limits a more detailed analysis of relapse risk factors. Nonetheless, the relapse rates observed align with those in previous studies on ovarian [16] and testicular [24] GCTs, supporting these findings.

5. Conclusions

Recurrence of LR-GCTs occurs in approximately a quarter of testicular and a third of ovarian cases, mostly within the first year of follow-up. In young children with testicular YSTs, relapses tend to spread to the lungs, unlike the lymphatic recurrences seen in older patients. Due to these differences, it is essential to discuss each case in a multidisciplinary tumor board and ensure patients and their families understand the need for careful follow-up. While our data

support some findings from previous multi-institutional pediatric studies, further research is needed to identify key risk factors for recurrence and refine surveillance and treatment strategies in this group of patients with an otherwise excellent outcome.

Patient's/Guardian's consent

Documented consent from patients, their parents, and/or their legal representatives.

Ethical clearance

The TGM13 Observatory was approved by the Southeast IV Protection of People Committee (No. CPP 13/065) on October 23, 2013, providing ethical clearance in accordance of the Declaration of Helsinki.

Funding

This research did not receive any specific grant from funding agencies in the public, commercial or not-for-profit sectors.

Declaration of competing interest

The authors declare that they have no conflicts of interest related to this article.

Acknowledgments

The authors would like to thank the “Enfants, Cancers, Santé” association for their support.

References

- [1] TNM Classification of Malignant Tumours, 8th edition <https://www.uicc.org/resources/tnm-classification-malignant-tumours-8th-edition>.
- [2] Prat J. FIGO Committee on Gynecologic Oncology. Staging classification for cancer of the ovary, fallopian tube, and peritoneum. *Int J Gynaecol Obstet Off Organ Int Fed Gynaecol Obstet* 2014;124(1):1–5. <https://doi.org/10.1016/j.ijgo.2013.10.001>.
- [3] Faure-Contier C, Orbach D, Sudour-Bonnange H, et al. Extracranial germ cell tumours in children and adolescents: results from the French TGM13 protocol. *Pediatr Blood Cancer* 2023;70(3):e30117. <https://doi.org/10.1002/pbc.30117>.
- [4] Cheng L, Albers P, Berney DM, et al. Testicular cancer. *Nat Rev Dis Primers* 2018;4(1):29. <https://doi.org/10.1038/s41572-018-0029-0>.
- [5] Fresneau B, Orbach D, Faure-Contier C, et al. Is alpha-fetoprotein decline a prognostic factor of childhood non-seminomatous germ cell tumours? Results of the French TGM95 study. *Eur J Cancer Oxf Engl* 1990;95:11–9. <https://doi.org/10.1016/j.ejca.2018.02.029>. 2018.
- [6] Patterson DM, Murugaesu N, Holden L, Seckl MJ, Rustin GJS. A review of the close surveillance policy for stage I female germ cell tumors of the ovary and other sites. *Int J Gynecol Cancer Off J Int Gynecol Cancer Soc* 2008;18(1):43–50. <https://doi.org/10.1111/j.1525-1438.2007.00969.x>.
- [7] Mangili G, Sigismondi C, Lorusso D, et al. The role of staging and adjuvant chemotherapy in stage I malignant ovarian germ cell tumors (MOGTs): the MITO-9 study. *Ann Oncol Off J Eur Soc Med Oncol* 2017;28(2):333–8. <https://doi.org/10.1093/annonc/mdw563>.
- [8] Alexandre J, Fizazi K, Mahé C, et al. Stage I non-seminomatous germ-cell tumours of the testis: identification of a subgroup of patients with a very low risk of relapse. *Eur J Cancer Oxf Engl* 1990;37(5):576–82. [https://doi.org/10.1016/s0959-8049\(00\)00442-1](https://doi.org/10.1016/s0959-8049(00)00442-1). 2001.
- [9] Daugaard G, Petersen PM, Rørth M. Surveillance in stage I testicular cancer. *APMIS Acta Pathol Microbiol Immunol Scand* 2003;111(1):76–83. <https://doi.org/10.1034/j.1600-0463.2003.11101111.x>; discussion 83–85.
- [10] Hoskin P, Dilly S, Easton D, Horwich A, Hendry W, Peckham MJ. Prognostic factors in stage I non-seminomatous germ-cell testicular tumors managed by orchiectomy and surveillance: implications for adjuvant chemotherapy 2016;4(7):1031–6. <https://doi.org/10.1200/JCO.1986.4.7.1031>.
- [11] Blok JM, Pluim I, Daugaard G, et al. Lymphovascular invasion and presence of embryonal carcinoma as risk factors for occult metastatic disease in clinical stage I nonseminomatous germ cell tumour: a systematic review and meta-analysis. *BJU Int* 2020;125(3):355–68. <https://doi.org/10.1111/bju.14967>.
- [12] Kollmannsberger C, Moore C, Chi KN, et al. Non-risk-adapted surveillance for patients with stage I nonseminomatous testicular germ-cell tumors:

- diminishing treatment-related morbidity while maintaining efficacy. *Ann Oncol Off J Eur Soc Med Oncol* 2010;21(6):1296–301. <https://doi.org/10.1093/annonc/mdp473>.
- [13] Daugaard G, Gundgaard MG, Mortensen MS, et al. Surveillance for stage I nonseminoma testicular cancer: outcomes and long-term follow-up in a population-based cohort. *J Clin Oncol Off J Am Soc Clin Oncol* 2014;32(34):3817–23. <https://doi.org/10.1200/JCO.2013.53.5831>.
- [14] Colls BM, Harvey VJ, Skelton L, et al. Late results of surveillance of clinical stage I nonseminoma germ cell testicular tumours: 17 years' experience in a national study in New Zealand. *BJU Int* 1999;83(1):76–82. <https://doi.org/10.1046/j.1464-410x.1999.00869.x>.
- [15] Oosterhuis JW, Looijenga LHJ. Human germ cell tumours from a developmental perspective. *Nat Rev Cancer* 2019;19(9):522–37. <https://doi.org/10.1038/s41568-019-0178-9>.
- [16] Billmire DF, Cullen JW, Rescorla FJ, et al. Surveillance after initial surgery for pediatric and adolescent girls with stage I ovarian germ cell tumors: report from the Children's Oncology Group. *J Clin Oncol Off J Am Soc Clin Oncol* 2014;32(5):465–70. <https://doi.org/10.1200/JCO.2013.51.1006>.
- [17] Derquin F, Floquet A, Hardy-Bessard AC, et al. Need for risk-adapted therapy for malignant ovarian germ cell tumors: a large multicenter analysis of germ cell tumors' patients from French TMRG network. *Gynecol Oncol* 2020;158(3):666–72. <https://doi.org/10.1016/j.ygyno.2020.06.491>.
- [18] Calaminus G, Schneider DT, von Schweinitz D, et al. Age-dependent presentation and clinical course of 1465 patients aged 0 to less than 18 Years with ovarian or testicular germ cell tumors; data of the MAKEI 96 protocol revisited in the light of prenatal germ cell biology. *Cancers* 2020;12(3):611. <https://doi.org/10.3390/cancers12030611>.
- [19] Dark GG, Bower M, Newlands ES, Paradinas F, Rustin GJ. Surveillance policy for stage I ovarian germ cell tumors. *J Clin Oncol Off J Am Soc Clin Oncol* 1997;15(2):620–4. <https://doi.org/10.1200/JCO.1997.15.2.620>.
- [20] Fresneau B, Orbach D, Faure-Contier C, et al. Sex-cord stromal tumors in children and teenagers: results of the TGM-95 study. *Pediatr Blood Cancer* 2015;62(12):2114–9. <https://doi.org/10.1002/pbc.25614>.
- [21] Lopes LF, Macedo CRPD, Aguiar SDS, et al. Lowered cisplatin dose and No bleomycin in the treatment of pediatric germ cell tumors: results of the GCT-99 protocol from the Brazilian germ cell pediatric Oncology cooperative group. *J Clin Oncol Off J Am Soc Clin Oncol* 2016;34(6):603–10. <https://doi.org/10.1200/JCO.2014.59.1420>.
- [22] Fonseca A, Frazier AL, Shaikh F. Germ cell tumors in adolescents and young adults. *J Oncol Pract* 2019;15(8):433–41. <https://doi.org/10.1200/JOP.19.00190>.
- [23] Palenzuela G, Martin E, Meunier A, et al. Comprehensive staging allows for excellent outcome in patients with localized malignant germ cell tumor of the ovary. *Ann Surg* 2008;248(5):836–41. <https://doi.org/10.1097/SLA.0b013e31818447cd>.
- [24] Rescorla FJ, Ross JH, Billmire DF, et al. Surveillance after initial surgery for Stage I pediatric and adolescent boys with malignant testicular germ cell tumors: report from the Children's Oncology Group. *J Pediatr Surg* 2015;50(6):1000–3. <https://doi.org/10.1016/j.jpedsurg.2015.03.026>.
- [25] Hamilton RJ, Nayan M, Anson-Cartwright L, et al. Treatment of relapse of clinical stage I nonseminomatous germ cell tumors on surveillance. *J Clin Oncol Off J Am Soc Clin Oncol* 2019;37(22):1919–26. <https://doi.org/10.1200/JCO.18.01250>.
- [26] Kollmannsberger C, Tandstad T, Bedard PL, et al. Patterns of relapse in patients with clinical stage I testicular cancer managed with active surveillance. *J Clin Oncol Off J Am Soc Clin Oncol* 2015;33(1):51–7. <https://doi.org/10.1200/JCO.2014.56.2116>.
- [27] Foster RS, Hermans B, Bihrlé R, Donohue JP. Clinical stage I pure yolk sac tumor of the testis in adults has different clinical behavior than juvenile yolk sac tumor. *J Urol* 2000;164(6):1943–4.
- [28] Frazier AL, Hale JP, Rodríguez-Galindo C, et al. Revised risk classification for pediatric extracranial germ cell tumors based on 25 years of clinical trial data from the United Kingdom and United States. *J Clin Oncol Off J Am Soc Clin Oncol* 2015;33(2):195–201. <https://doi.org/10.1200/JCO.2014.58.3369>.