



HAL
open science

Understanding the Origin of Superficial Bone Changes in Qafzeh 9 Skull (Middle Paleolithic, Southwestern Asia): Contribution of Three-Dimensional Imaging

Dany Coutinho-Nogueira, H el ene Coqueugniot, Anne-marie Tillier

► To cite this version:

Dany Coutinho-Nogueira, H el ene Coqueugniot, Anne-marie Tillier. Understanding the Origin of Superficial Bone Changes in Qafzeh 9 Skull (Middle Paleolithic, Southwestern Asia): Contribution of Three-Dimensional Imaging. *American Journal of Biological Anthropology*, 2025, 186 (4), pp.e70051. <10.1002/ajpa.70051>. <hal-05049145>

HAL Id: hal-05049145

<https://hal.science/hal-05049145v1>

Submitted on 7 May 2025

HAL is a multi-disciplinary open access archive for the deposit and dissemination of scientific research documents, whether they are published or not. The documents may come from teaching and research institutions in France or abroad, or from public or private research centers.

L'archive ouverte pluridisciplinaire **HAL**, est destin ee au d ep ot et  a la diffusion de documents scientifiques de niveau recherche, publi es ou non,  emanant des  tablissements d'enseignement et de recherche fran ais ou  trangers, des laboratoires publics ou priv es.



HAL Authorization

1 **Understanding the origin of superficial bone changes in Qafzeh 9 skull (Middle Paleolithic,**
2 **Southwestern Asia). Contribution of three-dimensional imaging.**

3 Dany Coutinho-Nogueira¹, H  l  ne Coqueugniot², and Anne-marie Tillier³

4 1 - University of Coimbra, CIAS - Research Centre for Anthropology and Health, Department
5 of Life Science, Coimbra, Portugal

6 2 - UMR 6034 Arch  osciences-Bordeaux (CNRS, Universit   Bordeaux-Montaigne, EPHE-PSL,
7 Universit   de Bordeaux), Pessac, France

8 3 – Honorary Research Director at CNRS (French National Centre for Scientific Research)

9

10 Short title: Superficial bone changes in Qafzeh 9 skull

11 Corresponding author: Dany Coutinho Nogueira, dany.coutinhonogueira@gmail.com

12 **Research highlights:**

- 13 - The application of advanced 3D imaging techniques, such as micro-CT, allows
14 detailed observations of bone alterations to address their etiology (e.g., normal
15 anatomy, taphonomy, ontogeny, etc.)
16 - This study reveals the presence of anatomical variants in Qafzeh 9, an early
17 anatomically modern human, enhancing our understanding of biological diversity
18 and intra-site variability at Qafzeh
19 - Micro-CT scans of Qafzeh 9 reveal a fusion of the frontal bone tables, with associated
20 bone flattening and diplo   modifications, which are linked to growth patterns
21 consistently found in non-adult individuals from recent modern samples
22

23 **Abstract**

24 **Objectives:** Deciphering the origins of bone alterations is crucial in paleoanthropology for
25 understanding biological variation and distinguishing between taphonomy, normal anatomy,
26 growth-related changes, and pathological conditions.

1 **Materials and Methods:** Qafzeh 9, an early anatomically modern human from Lower
2 Galilee, exhibits three alterations on its frontal bone: a circular lacuna, two parallel grooves,
3 and a flattening near the superior temporal line. Micro-CT images and 3D reconstructions
4 complement macroscopic observations to determine the etiologies of these features.

5 **Results:** Our analysis reveals that one of them, the flattening near the superior temporal
6 line, is associated with changes in the diploë.

7 **Discussion:** Data from four recent modern human samples show that this feature is present
8 in all non-adult individuals and suggests that the flattening and thinning of the diploë may
9 be related to growth patterns and dental changes. Our results bring new insights for the
10 development of methodologies for age estimation based on frontal bone. This study also
11 enhances our understanding of intra-site variability at Qafzeh and provides a better
12 understanding of the biological diversity and growth patterns among early anatomically
13 modern humans.

14 **Keywords:** Early Anatomically Modern Humans; frontal bone; anatomical variant;
15 ontogeny; taphonomy

16

17

18 **Introduction**

19 Understanding the origins of superficial bone changes is essential for characterizing
20 both individual and population-level biological variations when studying fossil hominins. It
21 also plays a key role in distinguishing cultural or intentional modifications from potential
22 pathological conditions. The use of medical imaging allows us to go beyond macroscopic
23 observations by visualizing internal structures to interpret bone alterations and distinguish
24 those of antemortem origin (e.g. ontogenetic, pathological, traumatic) from those resulting
25 from taphonomic conditions.

26 Qafzeh, a key archaeological site in the Southern Levant, has yielded an exceptional
27 collection of early anatomically modern human fossils associated with Middle Paleolithic

1 material culture. This site offers evidence of symbolic behavior and diverse burial practices,
2 making it a central focus in research on the cultural and biological evolution of early *Homo*
3 *sapiens* (Vandermeersch 1981, Tillier 1999, Hovers et al. 2003, Bar Yosef Mayer et al. 2009).

4 Among the recovered individuals, Qafzeh 9 presents several superficial alterations
5 on the cranial vault. The right lateral side of the frontal bone exhibits three superficial
6 modifications: a circular bone lacuna and two rectilinear, discontinuous, parallel grooves on
7 either side of the lacuna. Additionally, there is a flat area between the most lateral groove
8 and the upper temporal line (Figure 1). Due to taphonomic alterations on the left side of the
9 frontal, it is unclear whether these modifications were symmetrical. Nonetheless, this
10 particular concentration of structures and alterations of the bone raises questions regarding
11 their origin.

12 The aims of this study were to investigate the etiology of these alterations using
13 advanced imaging techniques, exploring possibilities such as growth-related changes,
14 pathologies, or normal anatomical variants. This study also aims to improve our
15 understanding of individual variability at Qafzeh and provide broader insights into the
16 biology of early anatomically modern humans.

17

18 **Material and methods**

19 1. Archaeological context

20 The Qafzeh cave, located 2.5 km from the town of Nazareth in Lower Galilee, holds
21 significant importance in the study of ancient Near Eastern settlement due to the
22 abundance of human remains it has yielded from the Mousterian layers (Vandermeersch
23 1981, Tillier 1999, 2014). The human sample unearthed (n=28, Tillier 2014), dated to 92 ± 5
24 ka BP through radiometric methods (Schwarcz et al 1988, Valladas et al. 1988), along with
25 human fossils from Skhūl on Mount Carmel, are among the earliest evidence of a modern
26 human presence in the Levant, Eurasia, and Africa. Additionally, the analysis of material
27 cultural from Qafzeh concerning the use of ochre and presence of marine shells suggests a
28 level of symbolism broadly associated with modern human behavior (Hovers et al 2003, Bar
29 Yosef Mayer et al. 2009).

1 In addition to archaeological evidence of modern human behavior, the Qafzeh site is
2 notable for the discovery of the earliest burials in the region. Compared to other Eurasian
3 sites, the number of burials at Qafzeh is striking, with a variety of mortuary deposits
4 identified, including both single and multiple burials, as well as remains of both sub-adult
5 and adult individuals. In one instance, animal remains were also found associated with a
6 burial (Vandermeersch 1969, 1970, Vandermeersch and Bar Yosef 2017, Tillier 2009). Yet,
7 particular fossilization conditions caused the occasional post-mortem alterations of the
8 human bones. The process of brecciation, more or less intense depending on location, has
9 intensively affected layer XVII from which a large proportion of the human remains
10 originate.

11

12 2. Qafzeh 9

13 The case reported here documents the superficial bone alterations observed in one
14 individual from the first and only evidence of a double primary burial associated with the
15 Middle Paleolithic traditions in Southwestern Asia (Vandermeersch 1969, Tillier 1995, 2009).
16 Qafzeh 9 was buried with a younger individual (Qafzeh 10, circa 6 years old at death). The
17 double burial prompts consideration of the circumstances surrounding their deaths, which
18 may or may not have occurred simultaneously. A reassessment of the biological profile of
19 Qafzeh 9 suggests that this individual died before achieving full skeletal and dental maturity
20 and supports a male sex classification (Coutinho Nogueira et al. 2021). Skeletal analysis did
21 not reveal evidence of lethal pathologies but identified benign bone pathologies and carious
22 lesions (Tillier et al. 2004; Coutinho Nogueira et al. 2019; Tillier 2021).

23

24 Comparative sample

25 The comparative sample is composed of five fossil individuals from the Levant, including
26 three children from the Qafzeh and Skhūl archeological sites (Qafzeh 10, 11 and Skhūl I) and
27 two adults (Qafzeh 25 and Skhūl V) for which CT-scans were available at Tel Aviv University
28 or Nespos. In addition, two osteological collections curated by the Department of
29 Anthropology at the National Museum of Natural History in Washington, DC and by the
30 American Museum of Natural History in New York, were employed. A sample of 58

1 individuals scanned by Lynn Copes (2012) at the Anthropology Department at the National
2 Museum of Natural History, Washington, DC with a Siemens Somatom spiral scanner (70 μ A,
3 110 kV, slice width 1.0 mm, reconstruction 0.5 mm). These individuals were recovered from
4 archaeological sites in Melanesia, New Zealand, and Greenland. For some, age and sex has
5 been previously estimated by Copes (2012). The comparative sample was completed with
6 10 individuals, aged between 2 and 10 years, from the anatomical reference collection of
7 the *Département d'Anatomie Normale de la faculté de médecine de Strasbourg*
8 (Coqueugniot & Hublin 2012) and 114 individuals, aged between 18 and 27, from the New
9 Mexico Decedent Image Database (Table 2). Finally, the 21st Century Identified Skeletal
10 Collection and the Non-Identified Collection of the Capucho Cemetery (University of
11 Coimbra) (Ferreira et al. 2021; José et al. 2021) was used for visual comparisons.

123. Methods

13 Understanding the morphological changes observed in human skeletal remains and
14 interpreting their underlying processes is essential for studies on past human populations. It
15 is crucial to gather relevant arguments for a diagnosis of bone modifications (Table 1), to
16 separate environmental factors from cultural ones, and to distinguish between deliberate
17 interventions (e.g. artificial cranial deformation, intentional injury) and true pathological
18 conditions. In this respect, medical imaging allows us to go beyond macroscopic observation
19 by visualizing inaccessible internal structures to interpret bone modifications and lesions,
20 even if the exact circumstances surrounding an injury or feature may remain unknown in
21 prehistoric human communities (e.g. Spoor et al. 2003, Gunz et al. 2010; Coqueugniot et al.
22 2014, Coqueugniot and Dutour 2023). In this study, a 3D approach is used to understand the
23 nature of the bone changes exhibited by the Qafzeh 9 skull. A micro-CT scan was obtained
24 for the cranium (isometric voxel of 200 μ m). The observation of the CT slices and the 3D
25 reconstruction were done using TIVMI software® (Dutailly et al., 2009). We also studied the
26 variation in density (through grayscale levels on micro-CT images) of the frontal bone at the
27 site of flattening and in a region without alterations and far from sutures.

28 **Results**

29 Frontal grooves

1 The most lateral groove is longer and consists of four sections aligned in the same
2 direction, while the smaller, more medial groove comprises two sections. Macroscopic
3 observations reveal a U-shaped cross-section with blunt edges, a detail confirmed by our
4 observations using micro-CT imaging. This also revealed the presence of multiple canals
5 within the bone, with three being particularly visible in areas lacking surface grooves. Osteo-
6 condensation is evident around the canals and beneath the grooves (Figure 2A and B).
7 Furthermore, 3D reconstructions of the canals and grooves demonstrate continuity
8 between these structures (Figure 3)

9 Frontal superficial lacuna

10 The superficial lacuna has irregular and non-blunted edges, with an overall irregular
11 surface. Its location and shape do not correspond to any known anatomical variation
12 (Hauser and de Stefano, 1989). Observation of the micro-CT sections does not reveal any
13 clear bone remodeling under the lacuna (Figure 4). No canals or blood vessels are visible,
14 which seems to exclude any periosteal reaction or cortical changes and thus, they are
15 unrelated to a pathological process or ante-mortem damage.

16 Flattening of the frontal bone

17 Qafzeh 9 shows a flattening near the superior temporal line which is present on each
18 side of the frontal bone. The micro-CT slices reveal a fusion of the tables and local
19 disappearance of the diploë on the lateral part of the frontal bone which extends to the
20 parietal bones. This fusion follows the superior temporal line (Figure 5). The analysis of the
21 density variation of the frontal bone revealed different profiles, with the absence of a low-
22 density zone at the site of the bone flattening and the absence of diploë (Figure 6A and B).

23 **Discussion**

24 Frontal grooves

25 The presence of canals under the grooves and their relationships excludes a post-
26 mortem origin as these structures appear organized and structured. In view of the location,
27 shape, and presence of several canals that may correspond to blood vessels and nerves, the
28 most likely hypothesis is that this is the supraorbital pedicle (also referred to as frontal

1 grooves or *sulci frontalis*), which may be bifid and correspond to vascular and nervous
2 grooves (Hauser & De Stefano 1989). The absence of grooves or canals in the lower part of
3 the bone near the orbit may be explained by post mortem damage in the region, which also
4 affects the left side of the frontal bone.

5 Qafzeh 9 appears to be the only individual within the Qafzeh hominin sample to display
6 the *sulci frontalis*. This anatomical variant is not observed in any of the adults of the sample
7 (Qafzeh 3, 6, and 25). However, like Qafzeh 9, they exhibit the *incisura supraorbitalis*,
8 another anatomical variant associated with the same vascular and nervous ramifications as
9 the *sulci frontalis* (Vandermeersch 1981). The *incisura supraorbitalis* is also present in
10 Qafzeh 11, while two younger children, Qafzeh 10 and Qafzeh 15, lack this feature (Tillier
11 1999). Unfortunately, this anatomical region is not preserved in the adults Qafzeh 5 and 7 or
12 in the hydrocephalic child Qafzeh 12 (Tillier et al. 2001), making this assessment impossible
13 for these individuals. Moreover, the presence of frontal bone grooves has not been
14 reported on any other Levantine Middle Paleolithic hominins due to post-mortem
15 alterations caused by soil pressure, as shown in Amud I, Tabun C1 15 and Skhül IV (McCown
16 & Keith, 1939; Suzuki 1970).

17 Among extant populations, the presence of frontal grooves on the external surface of
18 the skull is thought to mark the passage of branches of the supraorbital nerve and is usually
19 viewed as having no medical importance (Hauser & De Stefano 1989, Figure 7A-D). These
20 anatomical variations are sometimes misinterpreted in medical and forensic contexts as
21 fractures (Schunk & Murayama 1960; Mann & Hunt 2019). Vascular impressions were also
22 misinterpreted as trauma in archaeological cases (e.g., Willman et al., 2024). With regard to
23 the fossil record, the presence of frontal bone grooves has led to various interpretations:
24 traces of defleshing, for instance, on the Bodo skull (White 1986), and cut-marks on the
25 Neanderthal child, Engis 2, from Belgium. Yet, later studies revealed that such traces were
26 related to preparation for casting purposes (Russell & Le Mort 1986; White & Toth 1989).

27 Hauser and De Stefano (1989) highlight the presence of *sulci frontalis* even in fetuses
28 and hypothesize that this variation has a significant genetic component. On its own, this
29 anatomical variant provides limited information about Qafzeh 9. However, when considered
30 alongside other features such as overall cranial morphology, mandibular morphology or

1 dental occlusal variants (i.e., malposition of incisor) (Coutinho Nogueira 2019, Tillier 2021) it
2 appears that Qafzeh 9 differs from other individuals at the site, with the exception of Qafzeh
3 10.

4 Frontal superficial lacuna

5 Since there is no visible remodeling under the lesion and it does not correspond to any
6 known anatomical variant, the most parsimonious hypothesis is therefore to suggest that
7 this damage corresponds to a lytic lesion of taphonomic origin.

8 Flattening and thinning of the diploë/tabular fusion

9 The analysis of the comparative sample allows us to point out the systematic
10 presence of this characteristic in non-adult individuals. The bone thinning and the fusion of
11 the tables are present in children from the Strasbourg Medical School collection (10
12 individuals, 2-10 years old). They are also found in the 6 non-adults and 5 very young adults
13 individuals in the CT-scan collection made available by Lynn Copes (Copes 2012).

14 The analysis of the New Mexico Decedent database shows that young adults can
15 present the tabular fusion at least until 27 years old but with lower frequencies in older
16 individuals (min 11,11% at 26 years old; max 80% at 19 years old, Figure 8). All the older
17 individuals of this sample (between 26 and 27 years) presenting a tabular fusion also
18 present dental pathologies including several caries and/or antemortem teeth loss. Thus, age
19 may not be the only factor influencing the presence or absence of tabular fusion.

20 Concerning Qafzeh 9, dental maturation and bone ossification stages suggest that
21 the individual died between 18 and 21 years (Coutinho et al. 2021). Misalignment of the
22 anterior upper dentition has implied some joint disability as shown by the presence of an
23 osteochondritis dissecans on the right mandibular condyle (Coutinho et al. 2019). Within the
24 Qafzeh sample, cranial table fusion can also be observed on the CT- scans of the Qafzeh 10
25 child skull (around 6 years old, Tillier, 1999) and Qafzeh 11 (12-13 years old, Figure 9, Tillier,
26 *ibidem*). The Skhūl I child (ca. 3 years old) from Mount Carmel exhibits the same trait. Yet,
27 two adults, Qafzeh 25 and Skhūl V, do not show any modification of the frontal tables on the
28 CT-scans.

1 Given its location at the region of insertion for the temporal muscle and the
2 observed bone thinning in individuals with dental issues, this feature may be associated with
3 masticatory function. One hypothesis is that the fusion of the internal and external tables
4 could strengthen the muscle insertion area during dental or cranial development. However,
5 this hypothesis requires testing on a larger reference collection with known age and sex.

6 **Conclusion**

7 Our study shows that the meticulous analysis of CT images can reveal valuable
8 information about the normal and developmental variation in both past and contemporary
9 populations.

10 The analysis of several superficial changes on the Qafzeh 9 skull allowed us to
11 address their etiology but also to highlight new characteristics hitherto unknown for the
12 fossil. The lacuna was most certainly caused by post-mortem alterations. The frontal
13 grooves described on Qafzeh 9 are not observed on any other individual from the site,
14 supporting inter-individual variation already highlighted in previous studies
15 (Vandermeersch, 1981; Tillier, 1999; Coutinho-Nogueira, 2019). The identification of bone
16 thinning and fusion of the tables in the frontal bone supports previous assertions that
17 Qafzeh 9 did not reach complete skeletal maturity. This paves the way for developing new
18 methodological approaches to better understand changes in tabular bone.

19

20 **Acknowledgements**

21 The authors would like to thank Israel Hershkovitz, curator of the anthropological collection
22 of the Sackler School of Medicine, for access to the original fossil and the medical images, to
23 Julia Abramov for the reception and logistics support at the Tel Aviv University. First author
24 was financially supported by a research and travel grant from Irene Levi Sala Care
25 Archaeological Foundation. We are deeply indebted to Bernard Vandermeersch, who
26 directed the French mission of Qafzeh that provided a record rich in anthropological finds,
27 and for his support of our study. The authors thank the anonymous reviewers, the editor
28 and associate editor for their comments and suggestions, they also thanks John C. Willman

1 for the English editing. Finally, they are grateful to the Peabody Museum, Lynn Copes, Jean-
2 Jacques Hublin, Jean-Luc Kahn and Maria Teresa Ferreira for access to the modern reference
3 collections. There is no permit number. We extend our sincere gratitude to the entire
4 NMDID project team and its Principal Investigator, Dr. Edgar, for the establishment of this
5 database. We also acknowledge the Free Access to the Decedent Database, funded by the
6 National Institute of Justice under grant number 2016-DN-BX-0144.

7 The first author benefits from the support provided by CIAS which is funded by National
8 Funds through the FCT - Foundation for Science and Technology, I.P., within the scope of the
9 project UIDB/00283/2020 (<https://doi.org/10.54499/UIDB/00283/2020>)

10

11 **Author contributions**

12 Concept/design: DCN, AmT, HC; acquisition of data: DCN, AmT, HC; data
13 analysis/interpretation: DCN, AmT, HC; drafting of the manuscript: DCN, AmT

14 **Conflict of Interest**

15 The authors declare no conflict of interest

16 **Data Availability Statement**

17 The data is available upon request to the curators of the archaeological collections

18 **References**

19 Bar-Yosef, D. E., Vandermeersch, B., & Bar-Yosef, O. (2009). Shells and ochre in Middle
20 Paleolithic Qafzeh Cave, Israel: Indications for modern behavior. *Journal of Human*
21 *Evolution*, 56, 307–314.

22 Copes, L. E. (2012). *Comparative and experimental investigations of cranial robusticity in*
23 *Mid-Pleistocene hominins*. Ph.D. Dissertation, Anthropology, Arizona State University.

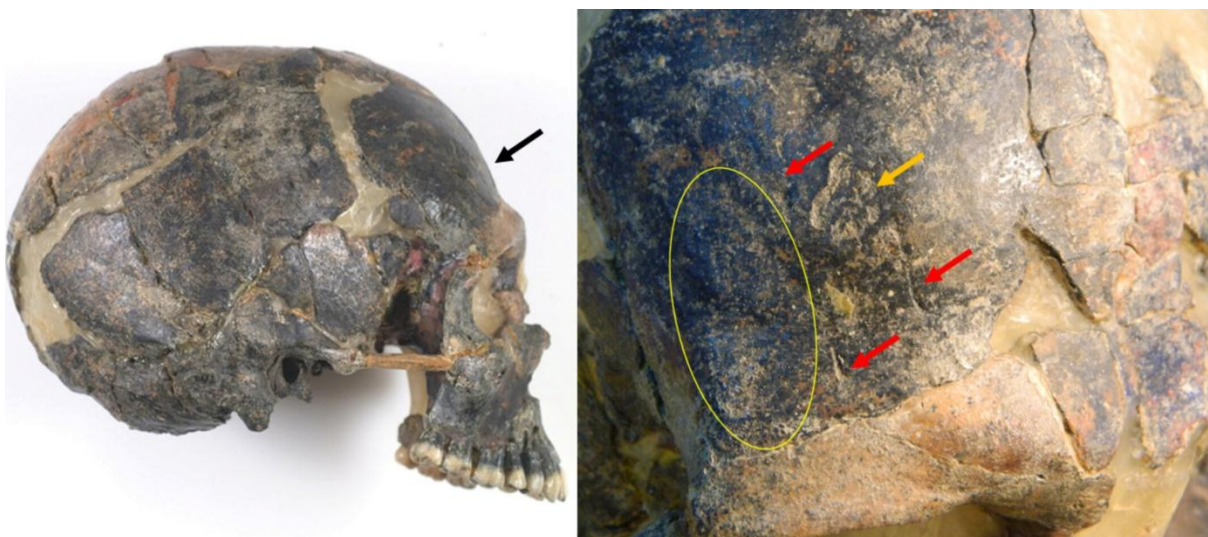
24 Coqueugniot, H., & Hublin, J. J. (2012). Age-related changes of digital endocranial volume
25 during human ontogeny: Results from an osteological reference collection. *American Journal*
26 *of Physical Anthropology*, 147, 312-318.

- 1 Coqueugniot, H., Dutour, O., Arensburg, B., Duday, H., Vandermeersch, B., & Tillier, A. M.
2 (2014). Earliest cranio-encephalic trauma from the Levantine Middle Palaeolithic: 3D
3 reappraisal of the Qafzeh 11 skull, consequences of pediatric brain damage on individual
4 condition and social care. *PLoS ONE*, 9.
- 5 Coqueugniot, H., & Dutour, O. (2023). Apport de l'imagerie tridimensionnelle à l'étude des
6 maladies des populations du passé. In H. Coqueugniot, O. Dutour, J. Jaubert, & P. Paillet
7 (Eds.), *Les sciences archéologiques à l'ère du virtuel* (pp. 42-55). Paris: CTHS éditions.
- 8 Coutinho-Nogueira, D. (2019). *Paléomagerie appliquée aux Homo sapiens de Qafzeh*
9 *(Paléolithique moyen, Levant sud). Variabilité normale et pathologique*. Ph.D. Thesis,
10 Université PSL, Ecole Pratique des Hautes Etudes.
- 11 Coutinho-Nogueira, D., Dutour, O., Coqueugniot, H., & Tillier, A. M. (2019). Qafzeh 9
12 mandible (ca 90-100 kyrs BP, Israel) revisited: μ -CT and 3D reveal new pathological
13 conditions. *International Journal of Paleopathology*, 26, 104–110.
14 <https://doi.org/10.1016/j.ijpp.2019.06.002>
- 15 Coutinho-Nogueira, D., Coqueugniot, H., & Tillier, A. M. (2021). Qafzeh 9 Early Modern
16 Human from Southwest Asia: Age at death and sex estimation re-assessed. *Homo:*
17 *Internationale Zeitschrift für die vergleichende Forschung am Menschen*, 72(4), 293–305.
18 <https://doi.org/10.1127/homo/2021/1513>
- 19 Dutailly, B., Coqueugniot, H., Desbarats, P., Gueorguieva, S., & Synave, R. (2009). 3D surface
20 reconstruction using HMH algorithm. In *Proceedings of the 16th IEEE International*
21 *Conference on Image Processing* (pp. 2505-2508).
- 22 Edgar, H.J.H., Daneshvari, Berry S., Moes, E., Adolphi, N.L., Bridges, P., & Nolte, K.B. (2020).
23 New Mexico Decedent Image Database. Office of the Medical Investigator, University of
24 New Mexico. doi.org/10.25827/5s8c-n515.
- 25 Ferreira, M. T., Coelho, C., Makhoul, C., Navega, D., Gonçalves, D., Cunha, E., & Curate, F.
26 (2021). New data about the 21st Century Identified Skeletal Collection (University of
27 Coimbra, Portugal). *International journal of legal medicine*, 135(3), 1087–1094.
28 <https://doi.org/10.1007/s00414-020-02399-6>
- 29 Gunz, P., Neubauer, S., Maureille, B., & Hublin, J. J. (2010). Brain development after birth
30 differs between Neanderthals and modern humans. *Current Biology*, 20(21), R922.
31 <https://doi.org/10.1016/j.cub.2010.10.018>
- 32 Hauser, G., & De Stefano, G. F. (1989). *Epigenetic variants of the human skull*. Stuttgart:
33 Schweizerbart'sche Verlagsbuchhandlung.
- 34 Hovers, E., Ilani, S., Bar-Yosef, O., & Vandermeersch, B. (2003). An early case of color
35 symbolism: Ochre use by modern humans in Qafzeh Cave. *Current Anthropology*, 44(4), 491-
36 522.

- 1 José, A., Tomé, L., Coelho, C., Cunha, E., Umbelino, C., & Ferreira, M. T. (2021). The
2 unidentified skeletal collection of Capuchos cemetery (Santarém) housed at the University
3 of Coimbra. *Antropologia Portuguesa*, 38, 79–98. https://doi.org/10.14195/2182-7982_38_5
- 4 Mann, R. W., & Hunt, D. R. (2019). Non-metric traits and anatomical variants that can mimic
5 trauma in the human skeleton. *Forensic Science International*, 301, 202–224.
- 6 McCown, T. D., & Keith, A. (1939). *The Stone Age of Mount Carmel* (Vol. II). Oxford:
7 Clarendon University Press.
- 8 Russell, M. D., & Le Mort, F. (1986). Cutmarks on the Engis 2 calvaria? *American Journal of*
9 *Physical Anthropology*, 69(3), 317–323. <https://doi.org/10.1002/ajpa.1330690304>
- 10 Schwarcz, H., Grün, R., Vandermeersch, B., Bar-Yosef, O., Valladas, H., & Tchernov, E. (1988).
11 ESR dates for the hominid burial site of Qafzeh in Israel. *Journal of Human Evolution*, 17(8),
12 733-738.
- 13 Schunk, H., & Maruyama, Y. (1960). Two vascular grooves of the external table of the skull
14 which simulate fractures. *Acta Radiologica*, 54(3), 186-194. DOI:
15 10.3109/00016926009172539
- 16 Spoor, F., Hublin, J. J., Braun, M., & Zonneveld, F. (2003). The bony labyrinth of
17 Neanderthals. *Journal of Human Evolution*, 44, 141–165.
- 18 Suzuki, H. (1970). The skull of the Amud man. In H. Suzuki & F. Takai (Eds.), *The Amud Man*
19 *and His Cave Site* (pp. 123-206). Tokyo: The University of Tokyo Press.
- 20 Tillier, A. M. (1995). Paléanthropologie et pratiques funéraires au Levant méditerranéen
21 durant le Paléolithique moyen: le cas des sujets non adultes. *Paléorient*, 21(2), 63-76.
- 22 Tillier, A. M. (1999). *Les enfants moustériens de Qafzeh. Interprétation phylogénétique et*
23 *paléoauxologique*. Paris: Cahiers de Paléanthropologie, CNRS Editions.
- 24 Tillier, A. M. (2009). *L'homme et la mort : L'émergence du geste funéraire durant la*
25 *Préhistoire*. Paris: CNRS Éditions.
- 26 Tillier, A. M. (2021). Aspects of health status in Pre-Sedentism Populations of Southwestern
27 Asia. Evidence from Qafzeh Site, Lower Galilee. *Paléorient*, 47(1), 31-44.
- 28 Tillier, A. M., Arensburg, B., Duday, H., & Vandermeersch, B. (2001). Brief communication:
29 An early case of hydrocephalus, the Middle Paleolithic Qafzeh 12 child (Israel). *American*
30 *Journal of Physical Anthropology*, 114, 166-170.
- 31 Tillier, A. M., Arensburg, B., Duday, H., & Vandermeersch, B. (2004). Dental pathology,
32 stressful events and disease in Levantine early anatomically modern humans: Evidence from
33 Qafzeh. In N. Goren-Inbar & J. D. Speth (Eds.), *Human Paleoecology in the Levantine Corridor*
34 (pp. 135-148).

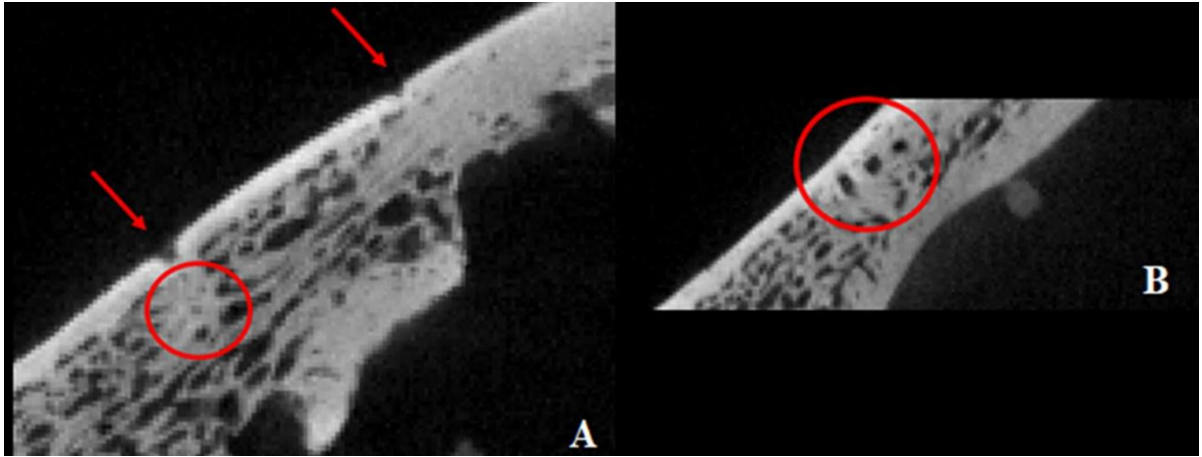
- 1 Valladas, H., Reyss, J. L., Joron, J. L., Valladas, G., Bar-Yosef, O., & Vandermeersch, B. (1988).
 2 Thermoluminescence dates for the Mousterian Proto-Cro-Magnons from Qafzeh Cave
 3 (Israel). *Nature*, 331, 614-616.
- 4 Vandermeersch, B. (1969). Les nouveaux squelettes moustériens découverts à Qafzeh et
 5 leur signification. *Comptes Rendus l'Académie des Sciences de Paris*, 268(D), 2562-2565.
- 6 Vandermeersch, B. (1970). Une sépulture moustérienne avec offrandes découverte dans la
 7 grotte de Qafzeh. *Comptes Rendus l'Académie des Sciences de Paris*, 270(D), 298–301.
- 8 Vandermeersch, B. (1981). *Les hommes fossiles de Qafzeh*. Cahiers de Paléanthropologie,
 9 CNRS Editions, Paris.
- 10 Vandermeersch, B., & Bar-Yosef, O. (2017). Qafzeh Cave and Terrace. In Y. Enzel & O. Bar-
 11 Yosef (Eds.), *Quaternary of the Levant: Environments, Climate Change, and Humans* (pp.
 12 251-253). Cambridge: Cambridge University Press.
- 13 Willman, J. C., Coutinho-Nogueira, D., & Silva, A. M. (2024). Reassessing trauma in a Late
 14 Neolithic cranium from Megalitho da Capella (Figueira da Foz, Portugal). *Anthropologischer*
 15 *Anzeiger; Bericht Uber die Biologisch-anthropologische Literatur*, 81(3), 341-349. DOI:
 16 10.1127/anthranz/2024/1771.

17



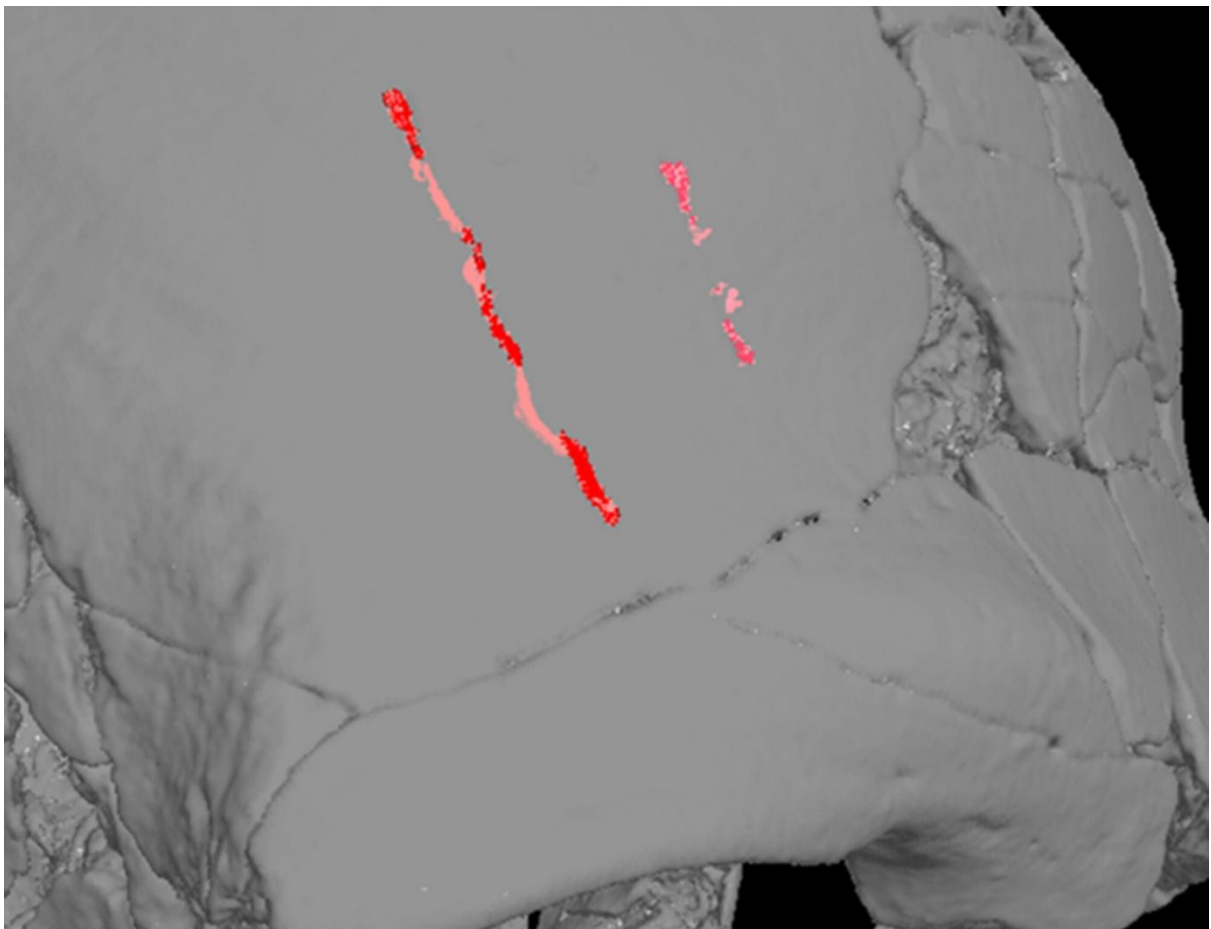
18
 19 Figure 1: *Norma lateralis* (or right lateral view) of the Qafzeh 9 skull, showing the right side
 20 of the frontal bone with notable bone changes above the orbital region. Red arrows
 21 highlight the grooves, the orange arrow points to the lacuna, and the yellow circle indicate
 22 the flat area

23



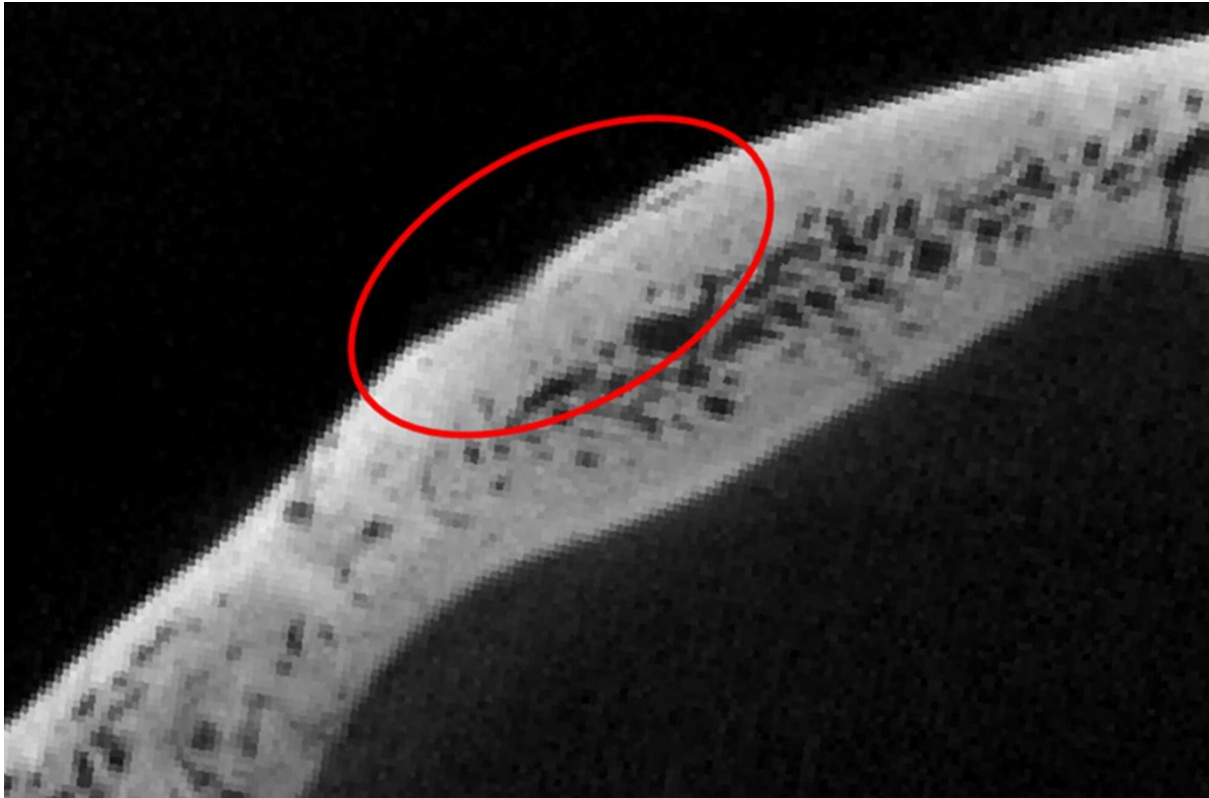
1

2 Figure 2: Micro-CT slices of the Qafzeh 9 frontal bone showing the surface grooves (red
3 arrows), and the underlying structures (A: osteo-condensation; B: vascular and/or nervous
4 canals; red circles)



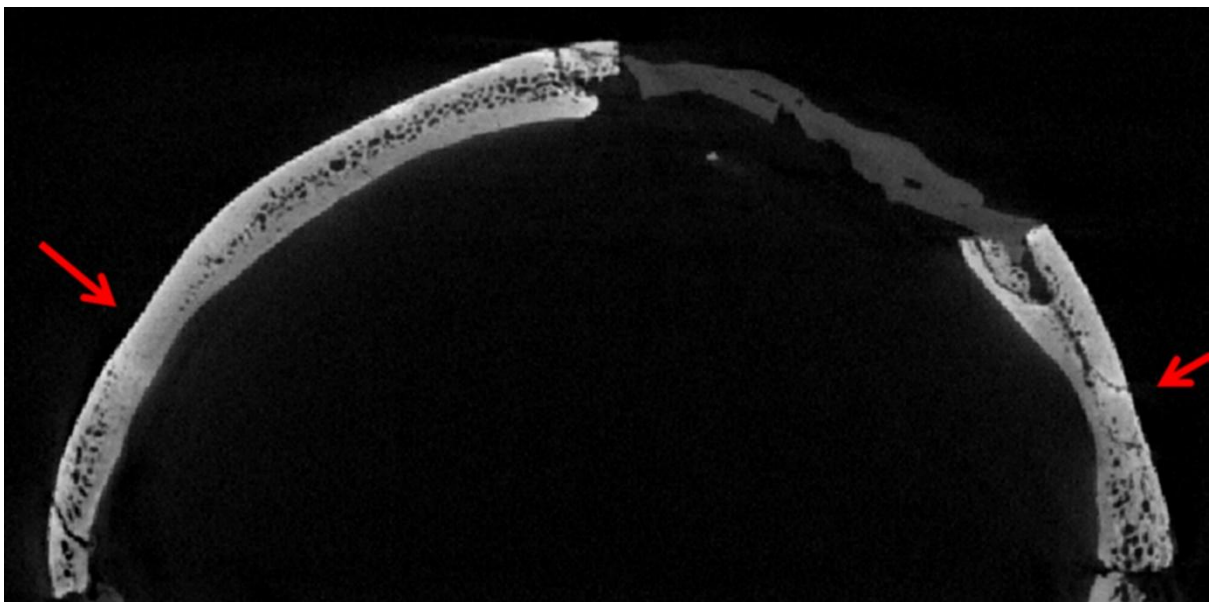
5

6 Figure 3: Virtual reconstruction of the grooves and canals. The grooves on the surface are
7 shown in dark red, the canals inside the bones are shown in light red.



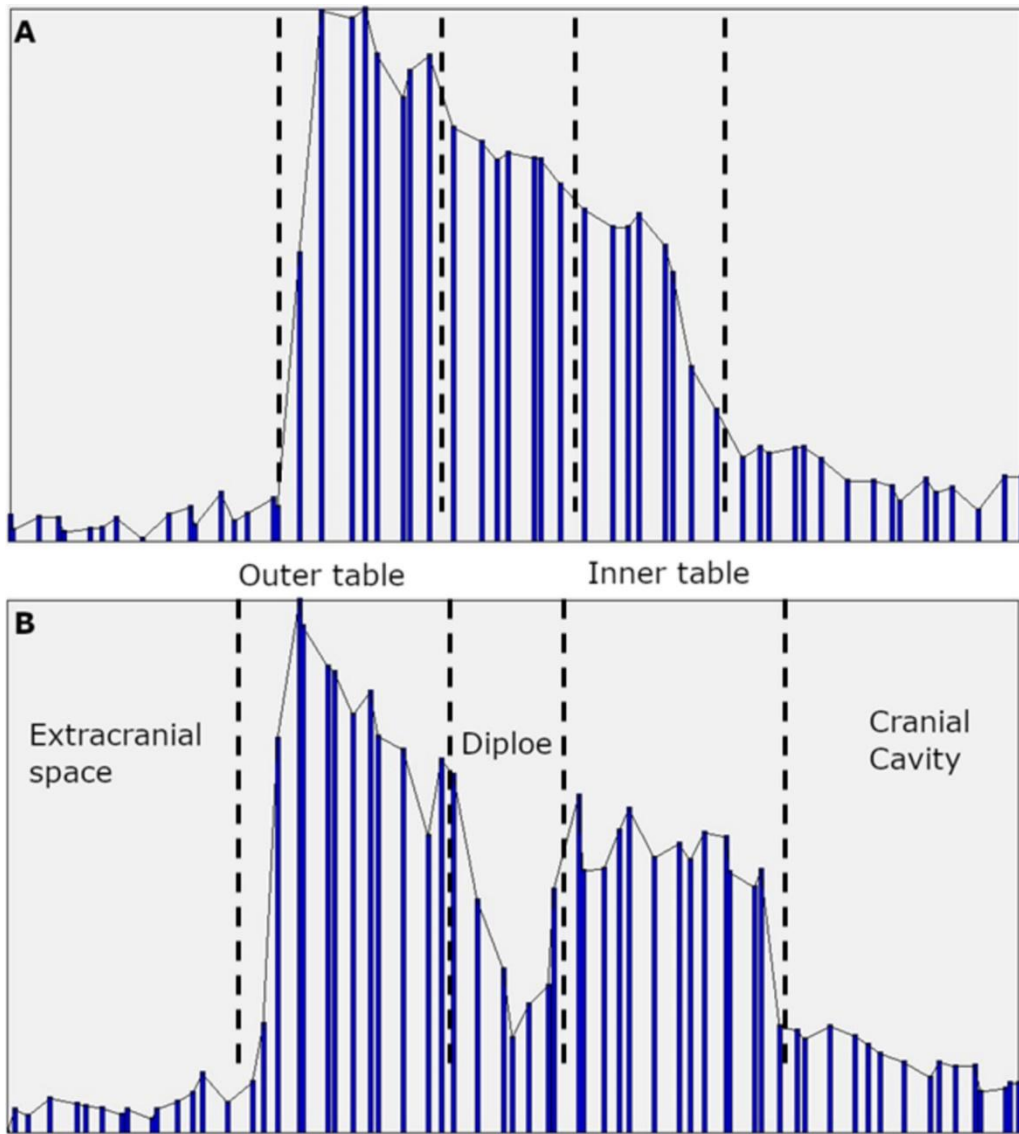
1

2 Figure 4: Micro-CT slice of the Qafzeh 9 frontal bone showing the lacuna and the underlying
3 structures.

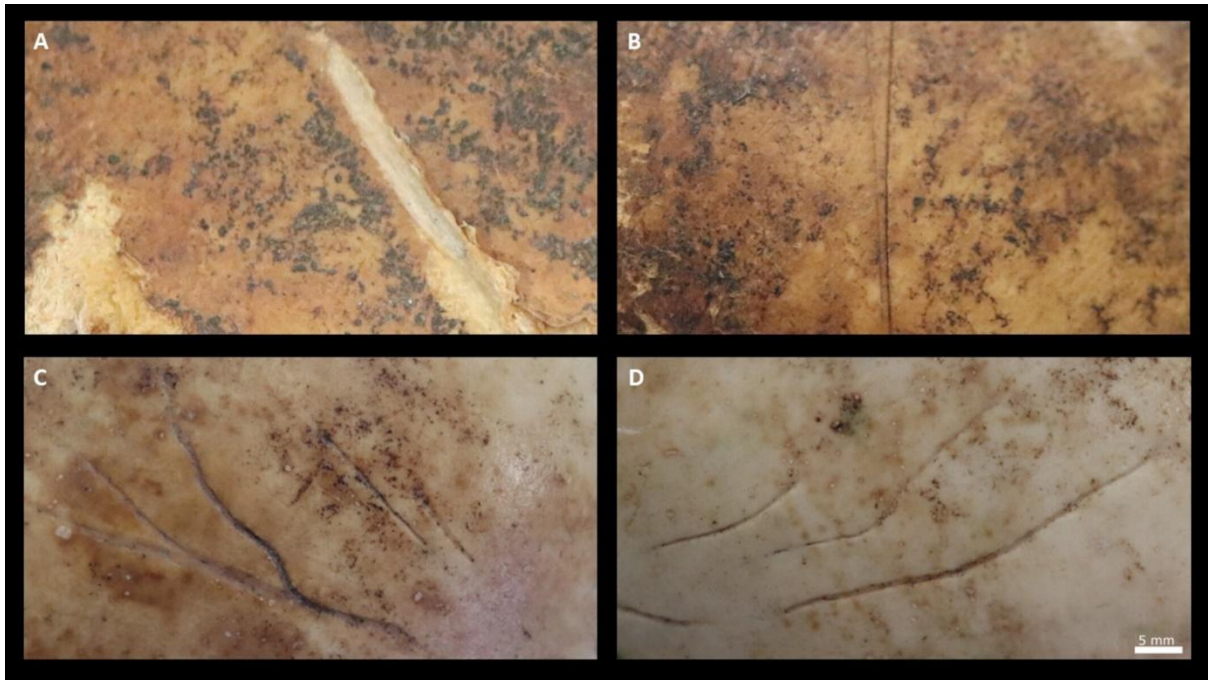


4

5 Figure 5: Micro-CT slice of the Qafzeh 9 frontal bone showing the flattening and the absence
6 or thinning of the diploë (coronal view).

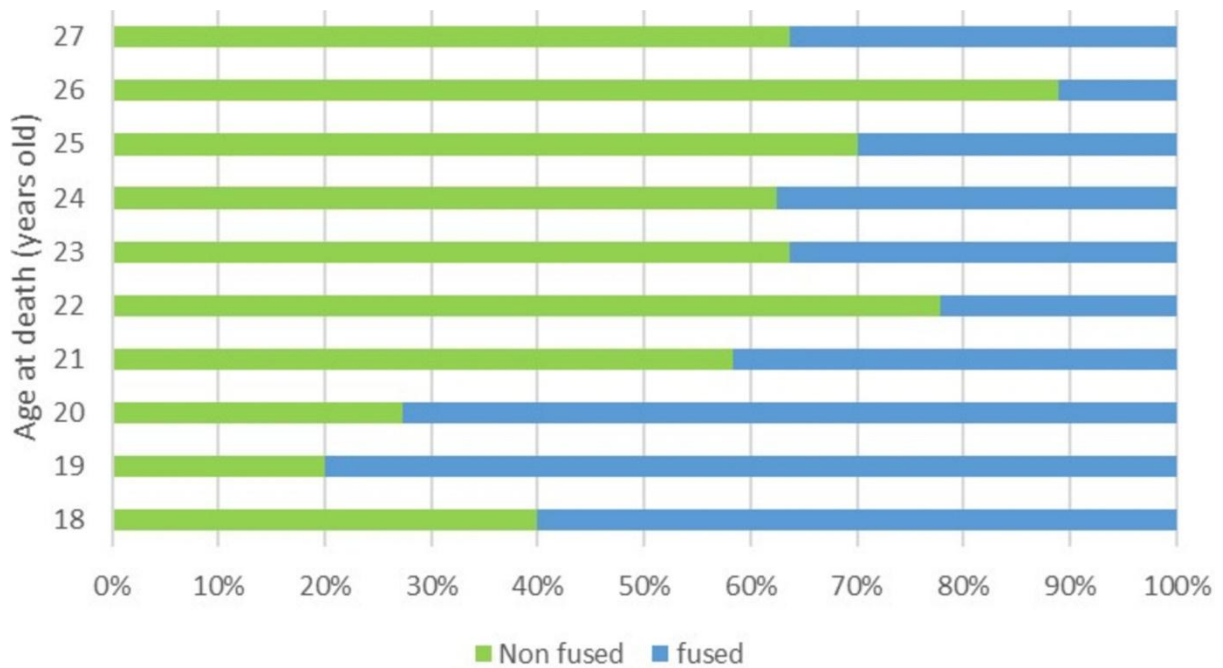


1
 2 Figure 6: Histogram of the bone density variation of the frontal bone in the region of the
 3 flattening (A) and in a region without bone changes (B). The Y axis represent the grey levels
 4 (density)



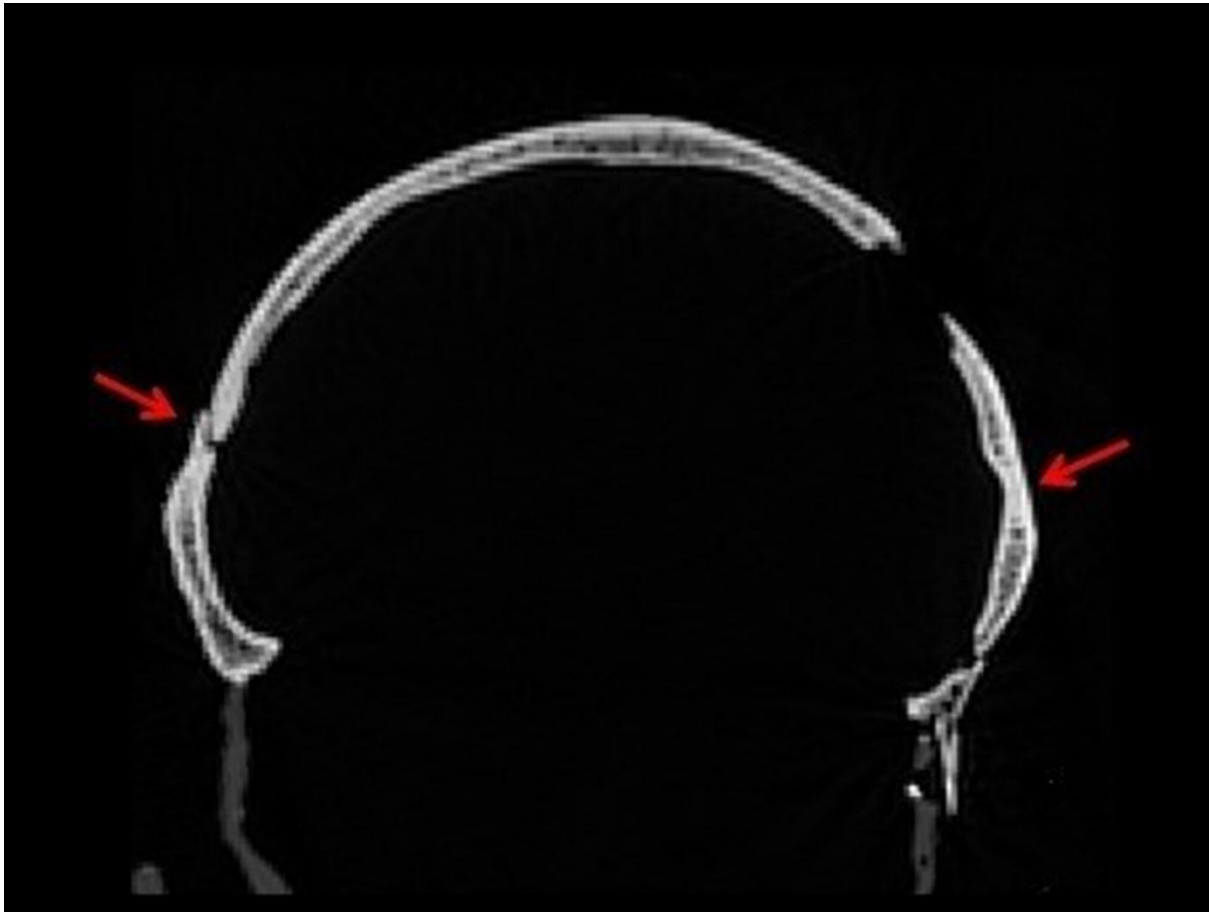
1

2 Figure 7: Different cranial changes on skulls from the 21st Century Identified Skeletal
 3 Collection and from the Non-Identified Collection of the Capucho Cemetery (University of
 4 Coimbra, Portugal), A: cut-mark due to exhumation by gravediggers; B: peri-mortem cut-
 5 mark made to remove the scalp during the autopsy; C and D are frontal grooves, left and
 6 right side of the frontal bone of the same individual



7

- 1 Figure 8: Graph showing the percentages by age at death of presence or absence of cranial
- 2 table fusion in the New Mexico sample



- 3
- 4 Figure 9: CT scan slices showing the bilateral thinning of the diploë in the frontal bone of
- 5 Qafzeh 11 (12-13 years old at death; coronal view)

6

1

2 **TABLE 1.** Comparative sample used for the analysis of CT scans, including information on
 3 age, geographic origin, and time period.

Sample	Region	Number of individuals	Period	Age at death
Qafzeh-Skhūl (archaeology)	Southwestern Asia	5	Late Pleistocene	3 non-adults 2 adults (age group estimated)
Department of Anthropology at the National Museum of Natural History and American Museum of Natural History (archaeology)	Northern America	6	Holocene	11 young adults
	Australia-New Zealand	5		47 adults (age group estimated)
	Malay Archipelago	47		
Département d'Anatomie Normale de la faculté de médecine de Strasbourg (anatomical collection)	Western Europe	10	Holocene	2–10 years old (real age)
New Mexico Decedent Image Database (CT-scan database)	Northern America	114	Holocene	18–27 years old (real age)

4

5

1 **TABLE 2.** Examples of environmental, taphonomic alterations (post-mortem) and normal,
 2 pathological and cultural modifications (ante-mortem).

Post-mortem alterations	Ante-mortem modifications
<ul style="list-style-type: none"> • Fractures • Distortion caused by soil pressure • Missing parts • Encrustation • Faunal alterations • Weathering 	<ul style="list-style-type: none"> • Anatomical variations (e.g., wormian bones, accessory foramina, retromolar space) • Ontogenic/developmental characteristics (e.g., normal periosteal porosities, sutural fusion) • Individual variation (e.g., asymmetry, tooth malposition and rotation) • Cultural or activity related bone modifications (e.g., artificial cranial deformation, enthesal changes, toothpick marks) • Pathologies and senescence (e.g., fractures, vertebral osteoarthritis, periodontal disease)

3