



HAL
open science

Evaluation of a method to quantify posture and scapula position using biplanar radiography

Sandrine Bousigues, Laurent Gajny, Wafa Skalli, Xavier Ohl, Patrice Tétreault,
Nicola Hagemeister

► **To cite this version:**

Sandrine Bousigues, Laurent Gajny, Wafa Skalli, Xavier Ohl, Patrice Tétreault, et al.. Evaluation of a method to quantify posture and scapula position using biplanar radiography. *Medical Engineering & Physics*, 2024, 127, pp.104167. <10.1016/j.medengphy.2024.104167>. <hal-04990267>

HAL Id: hal-04990267

<https://hal.science/hal-04990267v1>

Submitted on 13 Mar 2025

HAL is a multi-disciplinary open access archive for the deposit and dissemination of scientific research documents, whether they are published or not. The documents may come from teaching and research institutions in France or abroad, or from public or private research centers.

L'archive ouverte pluridisciplinaire **HAL**, est destinée au dépôt et à la diffusion de documents scientifiques de niveau recherche, publiés ou non, émanant des établissements d'enseignement et de recherche français ou étrangers, des laboratoires publics ou privés.



HAL Authorization

Evaluation of a method to quantify posture and scapula position using biplanar radiography

S. Bousigues (1), L. Gajny (1), W. Skalli (1), X. Ohi (3), P. Tétreault (4), N. Hagemeister (2)

1. Institut de Biomécanique Humaine Georges Charpak ; Arts et Métiers, Sciences et Technologies; Université Sorbonne Paris Nord.

2. Laboratoire d'Innovation Ouverte en technologie de la Santé ; Ecole de Technologie Supérieure, Montréal, Canada

3. Hôpital Maison Blanche, CHU de Reims, France

4. Centre Hospitalier de l'Université de Montréal, Canada

Abstract

Background: Recent studies have stated the relevance of having new parameters to quantify the position and orientation of the scapula with patients standing upright. Although biplanar radiography can provide 3D reconstructions of the scapula and the spine, it is not yet possible to acquire these images with patients in the same position.

Methods: Two pairs of images were acquired, one for the 3D reconstruction of the spine and ribcage and one for the 3D reconstruction of the scapula. Following 3D reconstructions, scapular alignment was performed in two stages, a coarse alignment based on manual annotations of landmarks on the clavicle and pelvis, and an adjusted alignment. Clinical parameters were computed: protraction, internal rotation, tilt and upward rotation. Reproducibility was assessed on an in vivo dataset of upright biplanar radiographs. Accuracy was assessed using supine cadaveric CT-scans and digitally reconstructed radiographs.

Findings: The mean error was less than 2° for all clinical parameters, and the 95% confidence interval for reproducibility ranged from 2.5° to 5.3°.

Interpretation: The confidence intervals were lower than the variability measured between participants for the clinical parameters assessed, which indicates that this method has the potential to detect different patterns in pathological populations.

Keywords

Biplanar radiography, Registration, patient-specific modelling, reproducibility study, scapula

1. Introduction

The interactions between the shoulder girdle and the spine are increasingly focused on in clinical research. For example, Moroder et al., [1] show that patient posture affects simulated mobility after reverse shoulder arthroplasty. However, their study was performed retrospectively on 100 patients (200 shoulders) using supine CT scans. Meanwhile, Matsumura et al. [2] reported that the position and orientation of the scapula changes significantly between supine and standing CT-scans, supporting the need for new methods to quantify posture.

To our knowledge, none of the tools currently available allow for the simultaneous quantification of both parameters, namely spinal alignment and the position and orientation of the scapula in the functional (i.e., upright) position. Biplanar radiography systems are used to reconstruct the spine, analyze sagittal balance and different spinal curvatures [3], [4]. 3D spine reconstruction requires sagittal and frontal radiographs and is based on validated methods [5], [6]. To achieve complete imaging of the scapulothoracic complex, it is possible to create a 3D reconstruction of the ribcage [7], [8] which can then be assessed with a mean line-to-line error distance of 3.6 mm compared to a reference.

However, modeling the shoulder from frontal and sagittal radiographs is challenging. These images are not suitable for scapula reconstruction due to the bony overlap of both shoulders and the spine on the lateral radiograph. Nonetheless, 3D reconstruction of the scapula is possible, provided that the images are taken with an axial rotation of approximately 40° from the frontal plane [9], [10], [11]. The reported morphological error when using this method was less than 2 mm and the orientation and position error less than 2 mm and 5.6° (95% confidence interval for inter-rater reliability).

Moroder et al., described clinical parameters to assess the spine and the shoulder such as the thoracic kyphosis, the scapular protraction, internal rotation, upward rotation and tilt [13]. To quantify these parameters, it is necessary to have reconstructions of both the spine and the scapula within the same reference frame. Therefore, to compute these parameters using low-dose biplanar radiography, an extra step is needed for the rigid registration of the 3D reconstruction of the scapula with the images used for the 3D spine reconstruction. The reliability of this registration process has yet to be evaluated for biplanar radiography. Studies have shown that a 3D reconstruction from a CT-scan is possible with biplane fluoroscopy [12] but the present study focuses only on biplanar radiography with the goal of improving fluidity.

The aim of this study was to propose and evaluate a method for scapula registration on sagittal and frontal images to assess two clinical parameters simultaneously: those for the spine and those described by Moroder et al. for the shoulder [13].

2. Methods

2.1. In vivo and in vitro databases

Fourteen patients were included in the reproducibility study after approval by the local ethics committees (CER CHUM: 22.036 (2023-10589)) and written informed consent, six men and eight women with a mean age of 60 years (between 42 and 83). All patients with an appointment at the clinic for shoulder problems were eligible. Patients with known osteoarthritis or major bony deformation of the scapula or the humerus were excluded. The other exclusion criteria were: patients unable to stand upright or to enter the EOS cabin which is exiguous. Pregnant women and patients who already had a shoulder prosthesis were also excluded.

Two pairs of radiographs were taken in a standing position using a biplanar radiography system (EOS system). During the acquisition of the first pair of images, the patients were asked to stand in the cabin with arms at their sides, and an axial rotation of about 40° with respect to the frontal plane. This pair of radiographs will be referred to as Rx40. The second pair of radiographs was taken immediately after the first one in a free-standing position [3] for a true antero-posterior view, with the hands on the cheekbones (henceforth referred to as Rx0). Six right and eight left shoulders were imaged.

Six supine CT scans of Post-Mortem Human Subjects (PMHS) from previous studies were used for the accuracy study. Scapulae, acetabula, and T1 vertebrae were manually segmented and reconstructed on the CT-scan images using the MITK-GEM software [14]. In addition, two pairs of biplanar Digitally

Reconstructed Radiographs (DRR) were generated for each CT-scan to reproduce the calibrated biplanar radiographs [15] in the Rx0 and Rx40 positions. This process reproduced the vertical X-ray scanning method of the EOS system.

2.2. 3D reconstruction

Prior to the image registration, a qualified operator performed all the 3D reconstructions. Reconstructions of the spine [6] and the rib cage [7], [8] were completed from images taken in the free-standing position [3]. The scapula was reconstructed on the Rx40 images according to the method described by Bousigues et al., as shown in figure 1. From these 3D reconstructions, the Trigonum Spinae (TS), the Inferior Angle of the scapula (IA) [16], the Glenoid Centre (defined as the centroid of the least-square circle of the inferior glenoid rim, projected onto the glenoid surface) and the barycentre of the T1 vertebral body were extracted. Other parameters are described in section 2.5 (protraction, internal rotation, upward rotation and tilt of the scapula) and were calculated on the adjusted alignment. The scapular glenoid-oriented coordinate system described by Kolz was computed [12].

2.3. Coarse alignment

To perform the initial coarse alignment, both pairs of radiographs were annotated as follows: identifying the centre of the acetabula (using a best-fit circle on the radiographs and identifying the centre of the circle) and the centre point between the two ends of the clavicle (also with a best-fit circle on the radiographs) using in-house software and MATLAB 2020a. Triangulation was used for 3D reconstructions of the landmarks (with the EOS calibration settings) and used to coarsely register the scapula within the images to reconstruct the spine and ribcage.

2.4. Adjusted alignment

The subject-specific scapula contours for each 3D scapula model were then projected onto the scapula contours visible on the Rx0 radiographs. The initial coarse alignment of the scapula was manually modified by an operator until the scapula contours matched the radiographic contours in the most visible areas. In the frontal view, the lateral border, the glenoid, the coracoid process, the acromion and the medial borders were used because the scapula is clear and visible. On the lateral view, the lateral border and the scapular spine were the most visible and were used to adjust the 3D scapula model. To determine if there were any collisions between the scapula and the ribcage, we used the Gilbert Johnson Keerthi algorithm [17]. If a collision was detected, the user was prompted to check where the collision occurred and correct it.

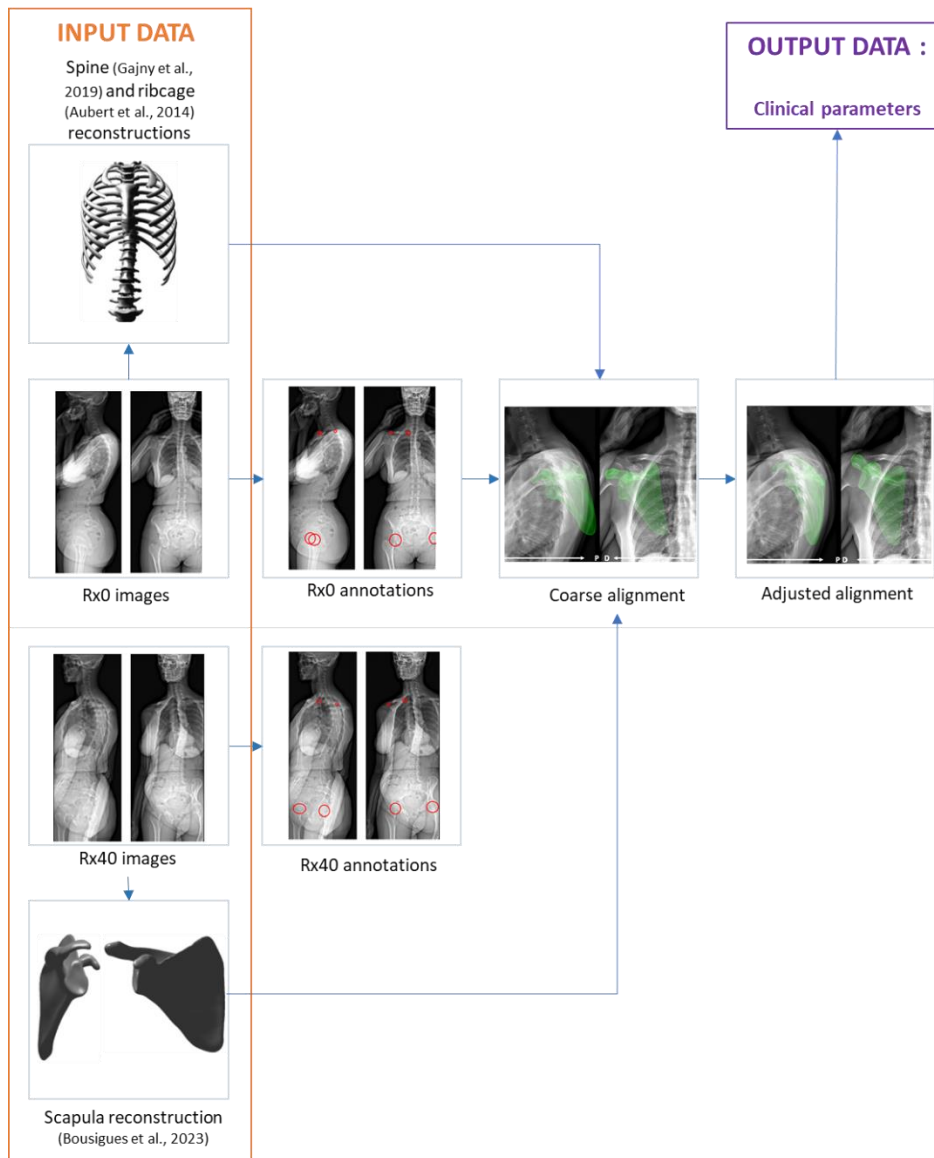


Figure 1: Flowchart for the methods (the input data are the Rx0 and Rx40 images and the 3D reconstructions performed on the images, then with annotations on both sets of images, the coarse alignment is done then the adjusted alignment is done to compute the clinical parameters).

2.5. Clinical parameter computation

The anato-gravital frame as defined in Roscop et al. [18] was used in our study. The origin (O) was the centre of the segment connecting the centre of the acetabula, the Z-axis was defined according to the plumb line and oriented upward and the Y-axis was defined based on a projection on the horizontal plane of the centre of the segment joining the centres of the acetabula. The X-axis was defined as a cross product of the Y-axis and the Z-axis.

The clinical parameters described by Moroder et al. [13] were then calculated, with some adaptations. More specifically, we used the anato-gravital frame axis instead of the sagittal and longitudinal vertebral axis, and the T1 vertebral upper endplate normal.

Protraction was defined as the angle between the X-axis of the anato-gravital frame and the line defined by the centre of T1 and the projection of the Glenoid Centre (GC) on a horizontal plane including T1 (figure 2).

Internal rotation was defined as the angle between the Y-axis of the anatomo-gravital frame and the line defined by the GC and the Trigonum Spinae (TS), projected onto a horizontal plane (figure 2).

The tilt was defined as the angle between the Z-axis of the anatomo-gravital frame and the line defined by TS and the Inferior Angle (IA) of the scapula projected on the sagittal plane (figure 2).

Upward rotation was defined as the angle between the Z-axis of the anatomo-gravital frame and the line defined by TS and the Inferior Angle (IA) of the scapula projected in the frontal plane (figure 2).

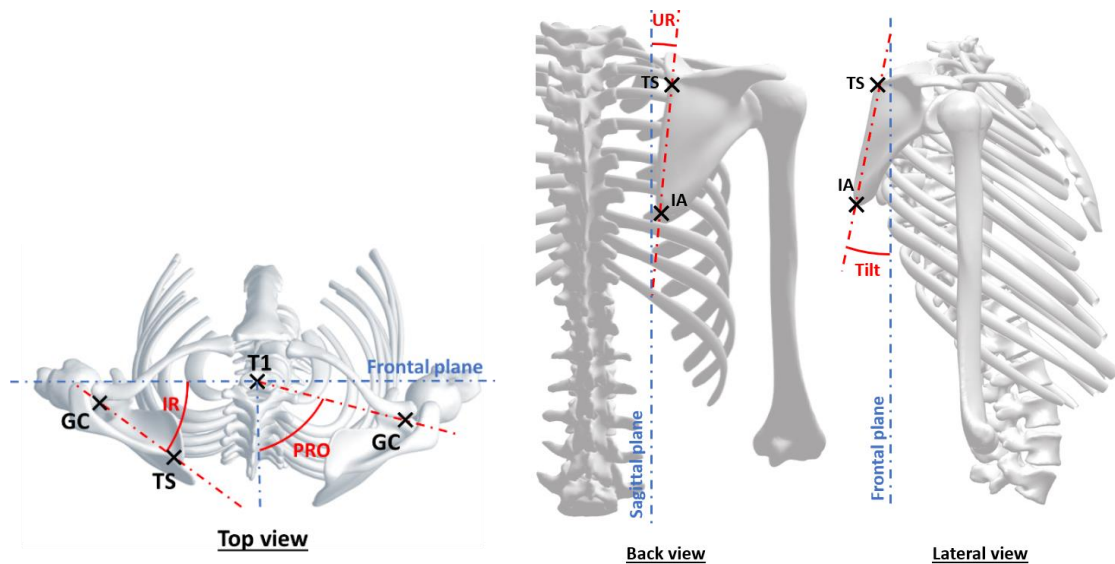


Figure 2 : Illustration of the protraction (PRO) the internal rotation angles (IR), the upward rotation (UR) and the tilt angles

2.6. Evaluation

Reproducibility

A reproducibility study was performed on the biplanar radiographs of the 14 subjects. A qualified operator performed the 3D reconstructions of the spine, the ribcage and the scapula beforehand. Then, two operators (biomedical engineers) completed the alignment process for all scapulae 3 times. The operators waited a minimum of two days before processing the same data set. In addition, the data were randomized between each set, with a change in subject identification numbers. The reliability of each clinical parameters was computed as twice the standard deviation for repeatability and reproducibility as defined in the ISO 5725-2 standards.

Accuracy

To assess the accuracy of the method, the DRR from the supine PMHS CT-scans were used as a reference. The clinical parameters were calculated on the CT-scan reconstructions. The T1 vertebrae, the scapulae and the pelvis were manually segmented and 3D reconstructed from the CT-scans using the MITK-GEM software [14]. The landmarks described in section 2.2 were identified on the 3D reconstructions. This allowed the calculation of the clinical parameters in the same way as with the EOS system. These will be referred to as the "Reference" clinical parameters (fig. 3).

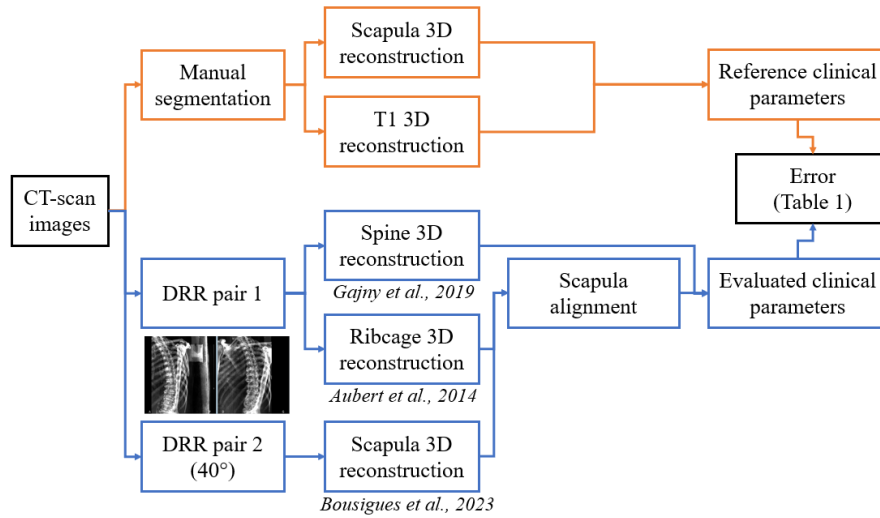


Figure 3: Flowchart for the accuracy evaluation

The method for coarse alignment and adjusted alignment was then applied on the PMHS DRR. Although the DRR generated from the PHMS were always taken with the body in the same position, a modification was made to reproduce the effect of scapular motion between the acquisition of Rx0 and Rx40 that is seen in living participants. Indeed, the patient moves in the EOS booth between the acquisition of the two pairs of images, requiring the adjusted alignment after the coarse alignment. Therefore, after a preliminary evaluation to reflect changes in the position of the scapula (in translation and in rotation) between the two pairs of DRR, random rotation angles and translations were applied to the scapula to reproduce the conditions when acquiring images with living participants. This was done in the following way.

First, the glenoid-oriented coordinate system for the scapula, as defined by Kolz et al. and Lawrence et al. [12], [19], was calculated. Second, random rotation angles ($\theta_x, \theta_y, \theta_z$) as well as random translation values (T_x, T_y, T_z) in the global coordinate system were generated based on normal distributions with standard deviations of 10° and 10 mm, and mean values of 20° for θ_x , and of 0° for θ_y and θ_z , and 0 mm for all the translations. Translations were applied to the scapula in the global coordinate system. Rotation angles were applied to the scapula around the axis of the glenoid-oriented coordinate system. These random rotations and translations were intended to mimic the coarse alignment step, where the scapula is never exactly aligned with the contours of the radiograph. Then, the clinical parameters were calculated and compared to the reference clinical parameters. The difference in degrees between the calculated and the reference clinical parameters was noted.

3. Results

Reproducibility (in-vivo)

The 95% confidence interval for reproducibility calculated on the biplanar radiographs (done in the upright position) was less than 3° for protraction, and less than 5.5° for the other clinical parameters (table 1 and figure 4). The protraction and the upward rotation were the clinical parameters with the lowest variability in the in vivo population with less than 10° standard deviation. The internal rotation and the tilt had a higher variability with a standard deviation of 12.5° and 10.6° , respectively (table 1).

Table 1 : Reproducibility results

Clinical parameters	Mean (SD)	Reproducibility (95% confidence interval)	Repeatability (95% confidence interval)
Protraction [°]	83.1 (7.4)	2.5	2.0
Internal rotation [°]	49.0 (12.5)	4.9	3.8
Tilt [°]	-3.3 (10.6)	5.3	4.2
Upward rotation [°]	11.9 (8.4)	3.4	2.8

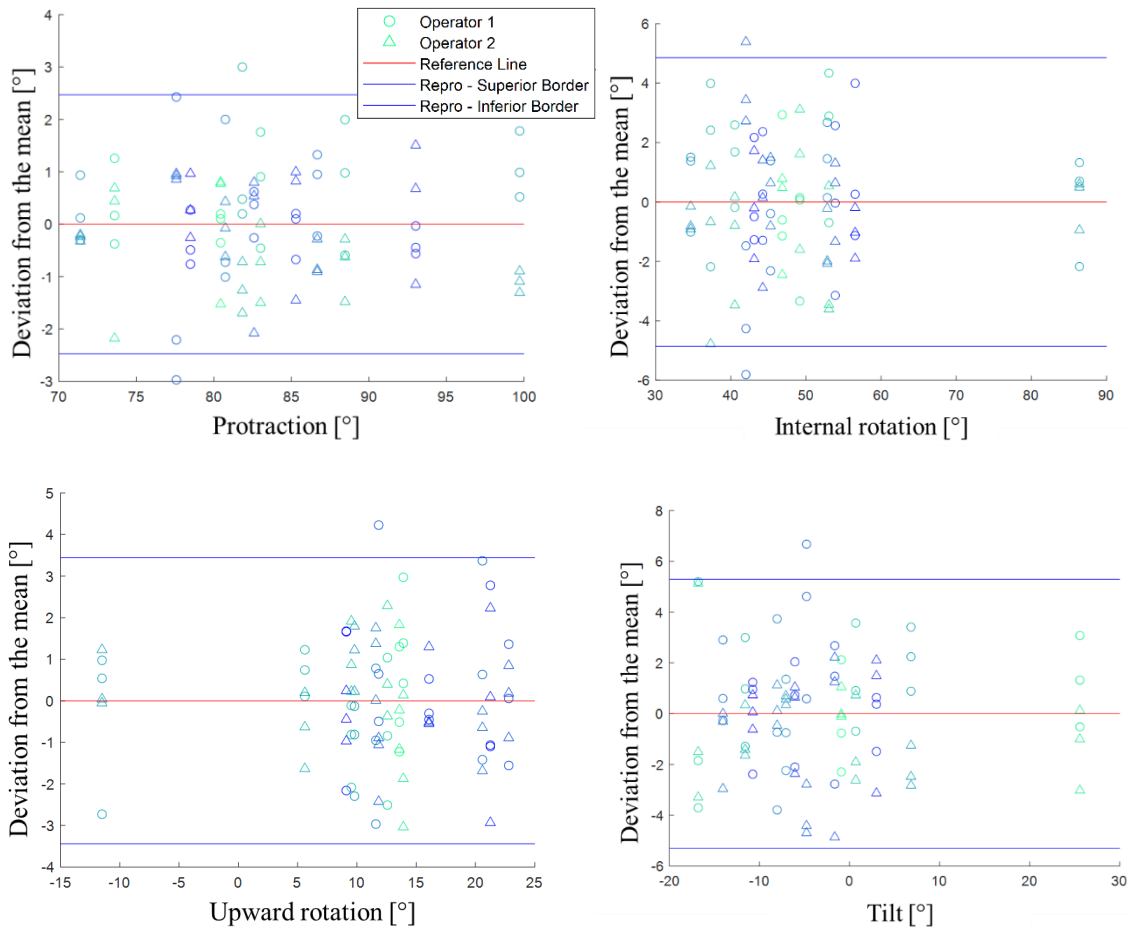


Figure 4: Bland-Altman plots for the reproducibility study

Accuracy (PMHS)

The mean error calculated on the PMHS CT-scans (taken in a supine position) between the reference and the reconstruction with alignment process (using the proposed method on the DRR) was less than 2° and the standard deviation was less than 2.5° for all the clinical parameters (table 2). The Maximum Absolute Error (MAE) reached 5.1° for the internal rotation and the upward rotation, and was less than 4° for the protraction and the tilt (table 2).

Table 2: Accuracy results

Clinical parameters	Mean error (SD)	Maximum absolute error
Protraction [°]	-1.8 (1.2)	3.7
Internal rotation [°]	-1.1 (2.3)	5.1
Tilt [°]	0.4 (1.9)	3.2
Upward rotation [°]	-1.0 (2.4)	5.1

4. Discussion

The aim of this study was to propose and evaluate a method for the registration of the scapula in the free-standing images used for the 3D reconstruction of the spine and the ribcage. This method involved two steps (coarse alignment and adjusted alignment), and was evaluated on two data sets: an in vivo database of biplanar radiographs collected from patients and PMHS CT-scans with DRR. Reproducibility had a 95% confidence interval of less than 5.5° for all the clinical parameters. The scapula registration method took approximately 5 minutes for an expert user, and included the two phases (coarse alignment, and adjusted alignment). This makes this method suitable for clinical research and to assess the possible associations between the spine and shoulder clinical parameters. Mean errors were less than 2° and standard deviations were less than 2.5° when assessing accuracy.

The shoulder parameters were adapted from Moroder et al. [13]. These clinical parameters were calculated in relation to the anatomic-gravitational frame axis, instead of the sagittal vertebral axis used to calculate the protraction and the internal rotation, while the sagittal longitudinal axis was used to measure the upward rotation, and the perpendicular line to the upper baseplate of the T1 vertebra was used to measure the tilt. These modifications were meant to provide more robust calculations than in the original study [13]. Indeed, as the upper endplate of T1 is a small surface with a visibility that may be altered on the lateral view, it may not be a reliable measure for clinical parameter computation. Moreover the sagittal vertebral axis as defined by Moroder et al. [13] uses the spinous process of the vertebrae, which is not always adjusted in the 3D reconstruction of the spine because it is not used to compute spinal parameters. To create the patient's frontal plane, we used the annotation of the acetabula and the best-fit circle process to strengthen reproducibility. The ISB thorax coordinate system [20] was not chosen because the anatomical landmarks it requires are not visible on the radiographs. It could be used in future studies but it would require radiopaque markers to be placed on the anatomical structures of interest beforehand. As this study aimed to present a method to study the interactions between the scapula and the spino-pelvic alignment, it was not evaluated here.

Regarding the results, the maximum error in the accuracy study was 5.1° for the internal rotation and the upward rotation. The mean values (and standard deviation) observed in the reproducibility study were 83.1° (7.4°) for the protraction, 49.0° (12.5°) for the internal rotation, 13.6° (5.0°) for the upward rotation, and -3.3° (10.6°) for the tilt. With regard to variations in these clinical parameters in the population, the method presented seems to be sufficiently accurate to detect differences in these angles, although we must remain cautious regarding the interpretation of the upward rotation and the tilt. The method described requires manual adjustments, therefore, the risk of operator bias was assessed with the reproducibility study. The whole process (with all 3D reconstructions, and the alignment) takes approximately 30 minutes per subjects for an expert operator.

The main limitation of this study is the patient position in the EOS booth for the 3D reconstruction of the spine. Pan et al., address the reproducibility of different positions for sagittal spine assessment [21], but they did not use radiographs. The biplanar radiography system is limited by the issues that arise from the bony overlap. Therefore, to avoid the superimposition of the arms and the spine, it is necessary to propose a standardized position without the arms over the spine in the sagittal image which in turn has an impact on positioning for the scapular pose. Moreover, the acquisition system itself limits the possible arm motion in the EOS booth.

Conclusion

This study presents an innovative method to accurately characterize both shoulder and spine posture. This information could provide new insights on how spinal alignment disorders may affect shoulder posture. Patient position for the acquisition of this data should be considered when interpreting the results from the proposed method, and still needs to be optimized for routine clinical use. However, it could already play a role in research to assess the possible associations between spinal parameters and shoulder position and orientation (on asymptomatic volunteers and on volunteers with some controlled pathologies). The variations recorded in the studied population would indicate that this method is sufficiently accurate to assess different types of postures, pathological differences, and the effect of surgery and/or physical therapy. This method could be combined with an analysis of the thoracic cage [22] and associated with spinopelvic alignment analyses in order to better understand the shoulder's contribution to overall alignment.

Acknowledgment

The authors wish to thank the ParisTech BiomecAM chair program on subject-specific musculoskeletal modelling with the financial support of COVEA as well as the ETS Marcelle Gauvreau chair program. We also thank all the volunteers who agreed to participate in this study, Sawsane Aloui who participated to the reproducibility study and Kathleen Beaumont for English editing.

Conflict of interest

None to declare.

Ethical approval

CER CHUM: 22.036 (2023-10589)

References

- [1] P. Moroder *et al.*, « Patient Posture Affects Simulated ROM in Reverse Total Shoulder Arthroplasty: A Modeling Study Using Preoperative Planning Software », *Clin. Orthop.*, vol. 480, n° 3, p. 619-631, mars 2022, doi: 10.1097/CORR.0000000000002003.
- [2] N. Matsumura *et al.*, « Three-dimensional alignment changes of the shoulder girdle between the supine and standing positions », *J. Orthop. Surg.*, vol. 15, n° 1, p. 411, déc. 2020, doi: 10.1186/s13018-020-01934-w.
- [3] J.-S. Steffen *et al.*, « 3D postural balance with regard to gravity line: an evaluation in the transversal plane on 93 patients and 23 asymptomatic volunteers », *Eur. Spine J.*, vol. 19, n° 5, p. 760-767, mai 2010, doi: 10.1007/s00586-009-1249-5.
- [4] C. Amabile, J.-C. Le Huec, et W. Skalli, « Invariance of head-pelvis alignment and compensatory mechanisms for asymptomatic adults older than 49 years », *Eur. Spine J.*, vol. 27, n° 2, p. 458-466, févr. 2018, doi: 10.1007/s00586-016-4830-8.

- [5] L. Humbert, J. A. De Guise, B. Aubert, B. Godbout, et W. Skalli, « 3D reconstruction of the spine from biplanar X-rays using parametric models based on transversal and longitudinal inferences », *Med. Eng. Phys.*, vol. 31, n° 6, Art. n° 6, juill. 2009, doi: 10.1016/j.medengphy.2009.01.003.
- [6] L. Gajny, S. Ebrahimi, C. Vergari, E. Angelini, et W. Skalli, « Quasi-automatic 3D reconstruction of the full spine from low-dose biplanar X-rays based on statistical inferences and image analysis », *Eur. Spine J.*, vol. 28, n° 4, Art. n° 4, avr. 2019, doi: 10.1007/s00586-018-5807-6.
- [7] B. Aubert, C. Vergari, B. Ilharreborde, A. Courvoisier, et W. Skalli, « 3D reconstruction of rib cage geometry from biplanar radiographs using a statistical parametric model approach », *Comput. Methods Biomech. Biomed. Eng. Imaging Vis.*, vol. 4, n° 5, Art. n° 5, 2014, doi: 10.1080/21681163.2014.913990.
- [8] C. Vergari, B. Aubert, P. Lallemand-Dudek, T.-X. Haen, et W. Skalli, « A novel method of anatomical landmark selection for rib cage 3D reconstruction from biplanar radiography », *Comput. Methods Biomech. Biomed. Eng. Imaging Vis.*, vol. 8, n° 1, p. 15-23, janv. 2020, doi: 10.1080/21681163.2018.1537860.
- [9] P. Y. Lagacé *et al.*, « 3D reconstruction of the scapula from biplanar radiographs », D. R. Haynor et S. Ourselin, Éd., San Diego, California, USA, févr. 2012, p. 83143L. doi: 10.1117/12.911527.
- [10] A.-M. Cauchon, P. Tétreault, C. Bascans, W. Skalli, et N. Hagemester, « Morphologic and radiologic parameters correlating to shoulder function at diagnosis for patients with rotator cuff tear », *J. Shoulder Elbow Surg.*, vol. 29, n° 11, p. 2272-2281, nov. 2020, doi: 10.1016/j.jse.2020.03.027.
- [11] S. Bousigues *et al.*, « 3D reconstruction of the scapula from biplanar X-rays for pose estimation and morphological analysis », *Med. Eng. Phys.*, vol. 120, p. 104043, oct. 2023, doi: 10.1016/j.medengphy.2023.104043.
- [12] C. W. Kolz *et al.*, « Reliable interpretation of scapular kinematics depends on coordinate system definition », *Gait Posture*, vol. 81, p. 183-190, sept. 2020, doi: 10.1016/j.gaitpost.2020.07.020.
- [13] P. Moroder, D. Akgün, F. Plachel, A. D. J. Baur, et P. Siegert, « The influence of posture and scapulothoracic orientation on the choice of humeral component retrotorsion in reverse total shoulder arthroplasty », *J. Shoulder Elbow Surg.*, vol. 29, n° 10, p. 1992-2001, oct. 2020, doi: 10.1016/j.jse.2020.01.089.
- [14] Y. Pauchard *et al.*, « Interactive graph-cut segmentation for fast creation of finite element models from clinical ct data for hip fracture prediction », *Comput. Methods Biomech. Biomed. Engin.*, vol. 19, n° 16, p. 1693-1703, déc. 2016, doi: 10.1080/10255842.2016.1181173.
- [15] P. W. de Bruin, B. L. Kaptein, B. C. Stoel, J. H. C. Reiber, P. M. Rozing, et E. R. Valstar, « Image-based RSA: Roentgen stereophotogrammetric analysis based on 2D–3D image registration », *J. Biomech.*, vol. 41, n° 1, Art. n° 1, janv. 2008, doi: 10.1016/j.jbiomech.2007.07.002.
- [16] X. Ohl, C. Stanchina, F. Billuart, et W. Skalli, « Shoulder bony landmarks location using the EOS® low-dose stereoradiography system: a reproducibility study », *Surg. Radiol. Anat.*, vol. 32, n° 2, Art. n° 2, févr. 2010, doi: 10.1007/s00276-009-0566-z.
- [17] E. G. Gilbert, D. W. Johnson, et S. S. Keerthi, « A fast procedure for computing the distance between complex objects in three-dimensional space », *IEEE J. Robot. Autom.*, 1988.
- [18] C. Roscop, P. Mathio, L. Gajny, P. Kouyoumdjian, W. Skalli, et O. Gille, « Analysis of apex and transitional vertebra of the spine according to pelvic incidence using orientation and position parameters », *Eur. Spine J.*, vol. 30, n° 9, p. 2514-2519, sept. 2021, doi: 10.1007/s00586-021-06908-y.
- [19] R. L. Lawrence, K. Roseni, et M. J. Bey, « Correspondence between scapular anatomical coordinate systems and the 3D axis of motion: A new perspective on an old challenge », *J. Biomech.*, vol. 145, p. 111385, déc. 2022, doi: 10.1016/j.jbiomech.2022.111385.
- [20] G. Wu *et al.*, « ISB recommendation on definitions of joint coordinate systems of various joints for the reporting of human joint motion—Part II: shoulder, elbow, wrist and hand », *J. Biomech.*, vol. 38, n° 5, Art. n° 5, mai 2005, doi: 10.1016/j.jbiomech.2004.05.042.

- [21] F. Pan, T. Zander, S. Reitmaier, M. Bashkuev, et H. Schmidt, « How reproducible do we stand and sit? Indications for a reliable sagittal spinal assessment », *Clin. Biomech.*, vol. 70, p. 123-130, déc. 2019, doi: 10.1016/j.clinbiomech.2019.08.011.
- [22] M. Khalifé *et al.*, « The rib cage: a new element in the spinopelvic chain », *Eur. Spine J.*, vol. 31, n° 6, Art. n° 6, juin 2022, doi: 10.1007/s00586-022-07216-9.