



HAL
open science

The Da Vinci Robot, a promising yet underused minimally invasive tool for spine surgery: A scoping review of its current role and limits

Anis Choucha, Francesco Travaglini, Matteo de Simone, Morgane Evin, Kaissar Farah, Stéphane Fuentes

► To cite this version:

Anis Choucha, Francesco Travaglini, Matteo de Simone, Morgane Evin, Kaissar Farah, et al.. The Da Vinci Robot, a promising yet underused minimally invasive tool for spine surgery: A scoping review of its current role and limits. *Neurochirurgie*, 2024, 71 (3), pp.101624. 10.1016/j.neuchi.2024.101624 . hal-04955654

HAL Id: hal-04955654

<https://hal.science/hal-04955654v1>


Submitted on 19 Feb 2025

HAL is a multi-disciplinary open access archive for the deposit and dissemination of scientific research documents, whether they are published or not. The documents may come from teaching and research institutions in France or abroad, or from public or private research centers.

L'archive ouverte pluridisciplinaire **HAL**, est destinée au dépôt et à la diffusion de documents scientifiques de niveau recherche, publiés ou non, émanant des établissements d'enseignement et de recherche français ou étrangers, des laboratoires publics ou privés.



Distributed under a Creative Commons Attribution 4.0 International License



Review Article

The Da Vinci Robot, a promising yet underused minimally invasive tool for spine surgery: A scoping review of its current role and limits

Anis Choucha^{a,b,*}, Francesco Travaglini^c, Matteo De Simone^d, Morgane Evin^b, Kaissar Farah^a, Stéphane Fuentes^a

^a Aix Marseille Univ, APM, UH Timone, Department of Neurosurgery, Marseille, France

^b Laboratory of Biomechanics and Application, UMRT24, Gustave Eiffel University, Aix Marseille University, Marseille, France

^c Dipartimento di Medicina Traslazionale e per la Romagna, Università degli studi di Ferrara, Ferrara, Italy

^d Department of Medicine, Surgery and Dentistry "Scuola Medica Salernitana", University of Salerno, Via S. Allende, 84081 Baronissi, Italy



ARTICLE INFO

Keywords:

Da Vinci

Robot

Scoping review

Spine surgery

Emerging technology

ABSTRACT

Background: The Da Vinci robot® (DVR), released in the early 2000s, provided a set of innovation aiming at pushing minimally invasive surgery forward. Its stereoscopic magnified visualization camera, motions that exceed the natural range of the human hand, or tremor reduction enhanced the surgeon's skills and added value in many surgical fields.

Objective: To map the current use of the DVR in spine surgery, identify gaps, address its limits and future perspectives.

Methods: We conducted a scoping review upon PRISMA guidelines through Pubmed from inception to July 2024, including english-written articles describing clinical use of the DVR on procedures related to spinal conditions. We collected a broad range of data, from journals publishing those articles, to the study design, the purpose of the study, the sample size or conclusions. We then provided a narrative review on the scope of indications and results of those studies.

Results: Seventeen studies including a total of forty-nine patients were included. Those included procedures in the craniocervical junction for 4 patients, thoracic spine for 5 cases, 29 patients involved the lumbar and lumbosacral segment, and 11 on the sacral region. Pathologies included degenerative diseases with 25 cases (14 ALIF and 11 OLIF), tumors as paraspinal schwannomas and odontoid lesions, but also basilar invagination of the odontoid process, Tarlov cyst, and sacral fracture.

Conclusion: The DVR presents as a valuable tool for minimally invasive surgery in selected cases. Further studies including cost effectiveness, leaning curve, and control trial are needed.

1. Introduction

Robotic surgery represents a pioneering field that promote minimally invasive surgery by competing to overcome human limitations in sight, touch, and precision. Various robotic systems have been designed to improve surgical outcomes and try to do so in different ways. For instance, the MazorX (Medtronic), Excelsius GPS (Globus Medical), and Brainlab Cirq (Brainlab), can aid in pedicle screw fixation by locking a predefined trajectory in navigated surgeries [1]. Hence these systems can help through guiding a surgical gesture.

The Da Vinci Robot (DVR) (© [2024] Intuitive Surgical Operations,

Inc. Sunnyvale, CA, USA), released in the early 2000s, is the most widespread system across multiple surgical disciplines [2]. The DVR stands out as it aims at enhancing the surgeon's capabilities through several innovations. These include endoscopic stereoscopic magnified visualization, which provides a three-dimensional view of the surgical field, and robotic arms that offer a range of motion beyond the limitations of the human hand. Additionally, the system significantly reduces tremors, allowing for more precise and controlled surgical movements [2].

The Da Vinci System consists of a surgeon's console, usually located in the same room as the patient, and a patient-side cart with three to four

* Corresponding author at: secretariat du service du Pr DUFOUR, Hôpital de la Timone, bâtiment adulte, 5eme étage, 264, rue Saint Pierre, 13385 Marseille, France.

E-mail address: anis.c13@gmail.com (A. Choucha).

<https://doi.org/10.1016/j.neuchi.2024.101624>

Received 20 August 2024; Received in revised form 15 December 2024; Accepted 17 December 2024

Available online 18 December 2024

0028-3770/© 2024 The Authors.

Published by Elsevier Masson SAS. This is an open access article under the CC BY license (<http://creativecommons.org/licenses/by/4.0/>).

interactive robotic arms (cf Fig. 1). These arms can hold and manipulate various surgical instruments, including scalpels, scissors, bovies, and graspers, while the final arm controls a 3D camera. The surgeon operates these arms from the console (Fig. 1). Hence this system entirely rely on a human operator and is classified as a level 0 in autonomy according to Yang's level of robots' autonomy [3].

The Da Vinci Robot has been proven effective in a range of procedures, particularly in general, urologic, gynecologic, thoracic, and transoral surgery, as it first got FDA approval for those interventions [2]. Safety and efficacy of this robot have been extensively documented in procedures such as prostatectomies, hysterectomies, or hemicolectomy [4]. These successes have established the Da Vinci Robot as a benchmark for robotic-assisted surgery.

Despite its widespread use in various surgical fields, the application of the Da Vinci Robot in spinal surgery has been relatively limited. Pending a FDA approval in spine surgery, the DVR has been used for complex cases intersecting other disciplines as thoracic or general surgery. In March 2024, Intuitive Surgical announced 510(k) FDA approval for their new Da Vinci 5 model, which incorporates a set of new innovations [2]. This development is expected to spur new publications and research, further exploring the capabilities and applications of this advanced system. Hence, we aimed to map the scope of all reported clinical uses of the Da Vinci Robot in spinal surgery, identifying gaps, limitations, perspectives, and successes. By analyzing the existing literature, we seek to provide a comprehensive overview of the current state of robotic-assisted spinal surgery and suggest directions for future research and development.

2. Material and method

2.1. Study design

A scoping review was conducted according to the Preferred Reporting Items for Systematic Reviews and Meta-Analyses for Scoping review (PRISMA ScR) guideline on MEDLINE/Pubmed from inception to July 2024. By doing so, we intended to map the current use of the Da Vinci robotic system® (DVR) in spinal surgery.

Eligibility criteria were established according to the « population – concept – context » framework defined by the Johanna Briggs Institute (JBI) for scoping reviews. We included english-written articles depicting the use of the Da Vinci Robotic System® (DVR), for part or whole surgical intervention related to spinal condition in human patients. Hence,

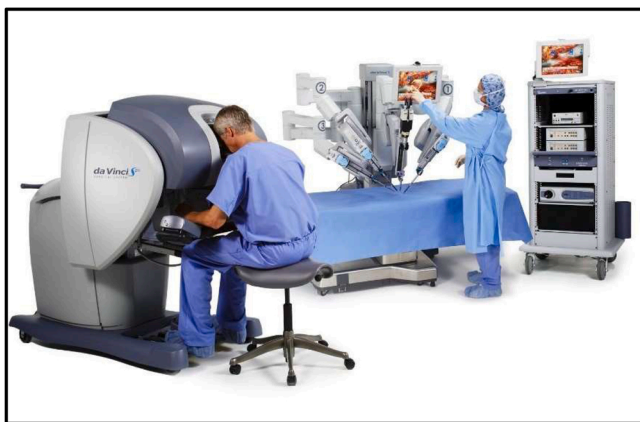

Fig. 1. Da vinci robot © [2024] Intuitive Surgical Operations, Inc. This figure illustrates the main components of the Da Vinci surgical robot system. On the left is the surgeon's console, where the surgeon controls the robot's movements with precision. In the center, the robotic arms are positioned over the surgical field, equipped with specialized instruments that replicate the surgeon's hand motions with enhanced dexterity. On the right, the video column displays a view of the operative site.

we included original articles, case reports or case series, and technical note. We excluded all studies not written in english language; not related to spinal conditions; not related to the DVR; and animal or cadaveric proof-of-concept studies. Letters and reviews were excluded.

This review was registered in the Open Science Framework (<https://doi.org/10.17605/OSF.IO/FU7HT>). IRB or Ethic approval was not required for this study. A preliminary search based on PubMed, Cochrane Library, JBI Evidence Synthesis, and Google Scholar revealed no previous scoping reviews on the use of Da Vinci robotic system on spine surgery. This study did not receive any funding or financial support. The authors have no personal, financial, or institutional interest related to this article.

2.2. Search strategy

A search strategy was determined upon JBI recommendations. First, we predefined medical subject headings (MeSH) as follow : “da vinci”; “robot”; “minimally invasive”; “spine”; “spinal conditions”; “case reports”; “case series”; “technical note”. From these MeSH, search term were established to proceed on PubMed: (“da vinci”[Title] AND (“spine”[MeSH Terms] OR “spine”[All Fields] OR “spines”[All Fields] OR “spine s”[All Fields]) + “DA”[All Fields] AND “VINCI”[All Fields] AND “SPINE”[All Fields]). After duplicates and retracted articles were removed, titles and abstracts were assessed to sort out articles in compliance with our eligibility criteria. Finally, 17 articles were included, the detailed flow chart is available in Fig. 2.

2.3. Data collection

The data Item list included general informations (authors, year of publication, Journal of publication, Journal Citation Indicator (JCI), title, type of article, number of cases), informations related to the pathology (spine segment, nosology, disease) surgical approach and conclusion of the study. Introduced by Clarivate, the Journal Citation Indicator is a normalized metric that allows for easy comparison of journals across different research fields.

3. Results

3.1. Studies selection

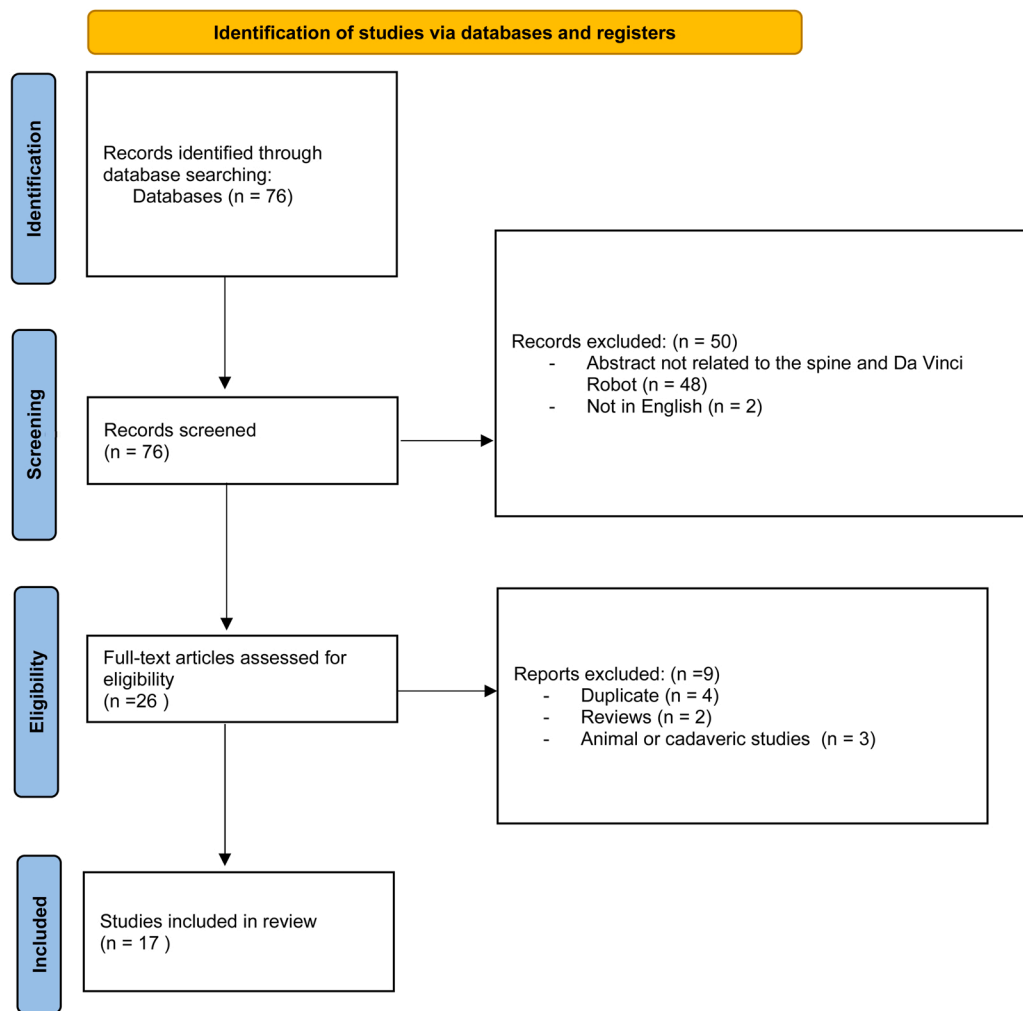
The initial research yielded a total of 76 articles (cf Fig. 1). TWO articles were excluded because not in English language. After a first round of title and abstract screening, 48 articles were excluded because not directly related to the topic. Four articles were identified as duplicates and subsequently removed. A second round full-text article assessment revealed two reviews and three articles depicting pre-clinical cadavers studies or animal models that did not involve human patients, and hence were subsequently excluded. Finally, a total of 17 articles were included for review and analysis (cf Table 1).

3.2. Study design and population

Of the 17 articles selected, 11 (65%) are case reports, 4 (24%) are case series, and 2 (12%) are technical notes (Fig. 3B). A total of 49 patients were presented in total (cf Table 1). Only two articles (12%) included a series of 10 or more patients. A further article (6%) presented a case series comprising nine patients. Eight articles (47%), including case reports and technical notes, presented a single patient treated by DVR system. Five articles (29%) presented two cases in which the treatment was applied. The first article was published in 2010, and the most recent was published in 2024.

The mean JCI (journal citation indicator) of the scientific journals in which the articles were published, according to Clarivate, was 0.85 (0.28–1.56) at the last measurement in 2023 (cf Table 1).

Six of the 17 journals (35%) are classified as pertaining to clinical



From: Page MJ, McKenzie JE, Bossuyt PM, Boutron I, Hoffmann TC, Mulrow CD, et al. The PRISMA 2020 statement: an updated guideline for reporting systematic reviews. *BMJ* 2021;372:n71. doi: 10.1136/bmj.n71

Fig. 2. Flow-Chart PRISMA-Sc guideline compliant.

neurology and surgery (Table 2 & Fig. 3A), three (18%) are dedicated to general surgery, three (18%) to orthopedics, three (18%) to otolaryngology, one (6%) to demography, and one (6%) to general and internal medicine (cf Table 2 & Fig. 3A).

3.3. Pathology

A total of 4 patients (8% of the 49 patients included) from three studies (18%) were related to the craniocervical junction (CCJ) pathology, with no studies specifically referencing the subaxial cervical spine. Five cases (10%) from three studies (18%) presented pathologies of the thoracic segment, twenty-nine patients (60%) from 8 studies (47%) referred to the lumbar segment or lumbosacral junction, and eleven patients (22%) from three studies (18%) to sacral pathology (Fig. 3 E & 3 F).

In particular, the DVR was used in seven studies (41%), including 18 patients (37%) for tumor management such as complex spinal schwannomas, or head and neck tumors involving C2. A total of 25 patients (51%) from 5 studies (29%) underwent surgery for degenerative spinal pathology. These included fifteen patients operated for an anterior lumbar interbody fusion, and 10 for an oblique lumbar interbody fusion. One case report (6%) reported a patient (2%) related to a pelvic fracture with sacral nerve injury. One case series (6%) of two patients (4%)

involved surgical treatment of an infectious spondylodiscitis for debridement. Finally, one case report (6%) of a patient (2%) reported the use of DVR for a basilar invagination of the C2 odontoid process, and one case (2.1%) involved a symptomatic Tarlov cyst [5].

Ten studies (59%) focused on an anterior approach, four (24%) used a lateral approach, and the remaining two (12%) studies described a transoral approach.

3.3.1. Degenerative lumbar spine surgery

Overall, six studies involving a total of 25 patients were identified, reporting initial experiences with ALIF (15/25), OLIF (6/25), or corpectomy (4/25) using the DVR (Table 3). In all studies, a multidisciplinary team was involved, including either a urological surgeon (5/6) or a vascular and general surgeon. For ALIF, most patients were treated for a single level (11/15), and four cases described a double-level procedures. The predominantly treated level was L4/L5. The average operative time for ALIF procedures, based on 10 cases, was 219 min. Blood loss data, available for six cases, indicated a mean blood loss of 48.33 mL. For OLIF, the average operative time, calculated from six cases, was 222.5 min, including both single-level and two-level surgeries. The mean operative time for corpectomy procedures, based on four cases, was 390 min. A minimum of three access ports was used in all studies (ranging from three to six ports). There was significant variation

Table 1
Detailed list of articles published.

Author	Year	Journal	Journam Topics	JCI (2023)	Title	Kind of study	N. of case	Pathology	Spine segment	Approach	Conclusion
Oh et al.	2014	J Spinal Disord Tech.	Clinical Neurology, Orthopedics	0.64	Robotic resection of huge presacral tumors: case series and comparison with an open resection.	case series	9	tumoral	sacral	Anterior	Presacral tumor, especially those growing anterior, can be successfully removed with the daVinci Robotic System, and this approach can become the standard for manipulation of this kind of tumor
Pacchiarotti et al	2017	Neurosurg Focus.	Clinical Neurology, Surgery	1.24	Robotic paravertebral schwannoma resection at extreme locations of the thoracic cavity.	case report	2	tumoral	thoracic	Lateral	Robot-assisted thoracoscopic resection is an effective therapy for certain paravertebral schwannomas in both the high superior and low inferior posterior mediastinum with excellent perioperative outcomes.
Lee et al.	2013	J Neurol Surg A Cent Eur Neurosurg	Demography	0.48	Minimally invasive, robot-assisted, anterior lumbar interbody fusion: a technical note.	technical note	2	degenerative	lumbo-sacral	Anterior	Use of the robotic assistance in the performance of ALIF is possible without significant operative complications. This technique may provide added benefit over conventional laparoscopic approaches to the spine.
Yang et al.	2011	J Korean Med Sci.	Medicine, General & Internal Surgery	0.98	Robot-assisted resection of paraspinal Schwannoma.	case report	1	tumoral	lumbar	Anterior	
Lee et al.	2013	J Robot Surg.	Surgery	1.00	Technique and surgical outcomes of robot-assisted anterior lumbar interbody fusion.	case series	11	degenerative	lumbo-sacral	Anterior	This study shows the feasibility of R-ALIF at L5-S1, L4-L5, and L4-L5 and L5-S1. the initial results are promising and allow us to hypothesize that the robot could be a tool that provides an effective and safe method of assisting with ALIF in the future.
Molteni et al.	2017	Eur Arch Otorhinolaryngol.	Otorhinolaryngology	1.23	Transoral robotic-assisted surgery for the approach to anterior cervical spine lesion.	case series	2	tumoral	CCJ	anterior (transoral)	A preliminary study of feasibility of TORS-assisted approach for anterior cervical spine and cranio-cervical junction pathologies is described. An anatomical study and the first two cases confirmed that this approach might have some advantages compared to the traditional one.
Perez-Cruet et al.	2012	Neurosurgery	Clinical Neurology, Surgery	1.56	Use of the da Vinci minimally invasive robotic system for resection of a complicated paraspinal schwannoma with thoracic extension: case report	case report	2	tumoral	thoracic	lateral	
Albayar et al.	2022	Int J Surg Case Rep	Surgery	0.28	Robot-assisted ventral sacral Tarlov cystectomy; A case report.	case report	1	Tarlov Cyst	sacral	Anterior	Robot-assisted resection of the intra-pelvic TCs may be considered as a minimally invasive, safe, and effective option to achieve resection and resolution of symptoms on short-term follow-up.
Rapoport et al.	2021	Oper Neurosurg (Hagerstown).	Clinical Neurology, Surgery	0.73	Robotic Resection of a Nerve Sheath Tumor Via a Retroperitoneal Approach.	case report	1	tumoral	lumbar	lateral	In selected patients with nerve sheath tumors requiring surgical resection, robotic resection represents a minimally invasive alternative to traditional open surgical approaches and may obviate the need for instrumented spinal fusion. Such cases should be managed in an interdisciplinary fashion, taking into account both the operative approach and the neuroanatomy of the lesion.

(continued on next page)

Table 1 (continued)

Author	Year	Journal	Journam Topics	JCI (2023)	Title	Kind of study	N. of case	Pathology	Spine segment	Approach	Conclusion
Yuk et al.	2023	World Neurosurg	Clinical Neurology, Surgery	0.68	Da Vinci Meets Globus Excelsius GPS: A Totally Robotic Minimally Invasive Anterior and Posterior Lumbar Fusion.	case report	1	degenerative/ spondylolistesis	lumbo-sacral	Anterior	All-robotic placement of both ALIF and posterior lumbar pedicle fixation may be safe, feasible, and efficacious.
Peng et al.	2019	J Orthop Surg Res.	Orthopedics	1.16	Using the Starr Frame and Da Vinci surgery system for pelvic fracture and sacral nerve injury.	case report	1	neurolysis	sacral	Anterior	The Da Vinci surgery system has great advantages for minimally invasive neurolysis of the sacral nerve and electrocoagulation for hemostasis in the pre-sacral space. We believe that the Da Vinci surgery system and computer and robot-assisted surgery will become more beneficial for orthopedic surgeons in the near future.
Beutler	2013	Spine (Phila Pa 1976)	Clinical Neurology, Orthopedics	1.14	The da Vinci robotic surgical assisted anterior lumbar interbody fusion: technical development and case report.	technical note	1	degenerative	lumbo-sacral	Anterior	Robotic assisted ALIF offers significant potential advantages compared with both standard open and laparoscopic techniques. Visualization and tissue dissection are greatly enhanced as relative to standard laparoscopic techniques. The use of the da Vinci robot has been demonstrated to decrease postoperative morbidity in general surgical, gynecologic, and urologic applications. Maintenance of pneumoperitoneum throughout the ALIF procedure is also expected to decrease patient morbidity compared with an open approach.
Loniewski et al.	2024	World Neurosurg	Clinical Neurology, Surgery	0.68	Da Vinci Robotic Assistance for Anterolateral Lumbar Arthrodesis: Results of a French Multicentric Study.	case series	10	Degenerative	lumbar and lumbo-sacral	Oblique	The use of the DVR in lumbar surgery allows a safe minimally performed.
Ye et al.	2022	Front Surg	Surgery	0.72	Da Vinci robot-assisted laparoscopic retroperitoneal debridement for lumbar septic spondylodiscitis: A two-case report.	case report	2	infection	lumbar	lateral	This paper shows that the lumbar operation via the retroperitoneal anterior approach is feasible, safe, and flexible. Given the development of manufacturing technology and the decrease in the cost related to this kind of operation in the near future, the author is optimistic about the application of robots in spine surgery.
Finley et al.	2014	J Neurol Surg A Cent Eur Neurosurg	Clinical Neurology, Surgery	0.32	Thorascopic resection of an apical paraspinal schwannoma using the da Vinci surgical system.	case report	1	tumoral	thoracic	Anterior	This article illustrates the technique of thorascopic resection with the da Vinci surgical system of an apical paraspinal schwannoma. This procedure obviates the need for an open thoracotomy and introduces the accuracy of the robotic system.
Lee et al.	2010	ORL J Otorhinolaryngol Relat Spec	Otorhinolaryngology	0.74	Da Vinci Robot-assisted transoral odontoidectomy for basilar invagination.	case report	1	basilar invagination	CCJ	anterior (transoral)	A fully robotic surgery will require the development of new tools for the da Vinci robotic arms. The unique advantages of robotic surgery will prompt otolaryngologists and neurosurgeons to further refine and perfect its use and

(continued on next page)

Table 1 (continued)

Author	Year	Journal	Journals Topics	JCI (2023)	Title	Kind of study	N. of case	Pathology	Spine segment	Approach	Conclusion
McCann et al.	2019	Laryngoscope	Otorhinolaryngology	0.89	Novel approach using transoral robotic surgery for resection of cervical spine chordoma	Case report	1	tumoral	CCJ	anterior	application to the difficult problems of skull base surgery To obtain en bloc resection of the lesion while both overcoming limitations due to access and without introducing morbidity from traditional anterior approaches, we elected using transoral robotic surgery for resection. Due to complete resection, the patient remains disease-free and was spared adjuvant radiation.

in the robot’s positioning, including from behind the patient between their legs to the left side. In all cases reported, patients experienced significant improvement in symptoms in the immediate postoperative period, and no major complications were reported.

Lee et al. [6] reported two ALIF cases at the L5-S1 level, performed via a retroperitoneal approach. Surgical durations ranged from 144 to 192 min, with minimal blood loss (50 mL). Outcomes showed significant pain reduction and successful bone fusion. Similarly, Lee et al. [7] presented data on 11 patients undergoing ALIF, with single-level surgeries averaging 180 min and multi-level surgeries approximately 270 min. No major complications were noted, confirming the procedure’s safety. Yuk et al. [8] and Beutler et al. [9] described initial experiences with ALIF using transperitoneal approaches. Mean surgical times were 75 min and 135 min, respectively, with blood loss under 30 mL. Both studies reported no complications, demonstrating clinical improvements and successful patient recovery. Loniewski et al. [10] highlighted the use of oblique lumbar interbody fusion (OLIF) and corpectomy in patients with complex medical histories. Single-level OLIF surgeries averaged 159 min, while two-level procedures required approximately 286 min. Corpectomy procedures averaged 390 min, achieving bony fusion within one year with no complications.

The authors highlighted potential benefits of using the DVR in this context, such as lower risks of retrograde ejaculation, facilitated lymph node dissection, and reduced blood loss through this minimally invasive approach. Additionally, the visualization of the disc space and surrounding structures was considered superior to current open and laparoscopic techniques. No specific drawbacks were identified by the authors (Table 4).

3.3.2. Transoral spine surgery

Lee et al. [11] reported the first institutional case of a transoral approach for basilar invagination (Table 3). The procedure, lasting 240 min, involved pharyngeal dissection, odontoidectomy, and closure. Postoperative outcomes included rapid extubation and dietary normalization within one week. Molteni et al. [12] reported two cases involving C1-C2 benign bone tumors, with surgical durations ranging from 145–330 min. Both patients demonstrated progressive clinical improvement postoperatively. However, McCann et al. [13] documented complications in a case of odontoid chordoma, including wound dehiscence and anterior hardware contamination, which necessitated prolonged antibiotic therapy and a staged recovery. All cases represented initial experiences at their respective centers. In all four cases, the surgical team included a neurosurgeon and an ENT specialist.

The authors highlighted several benefits of using the DVR in transoral spine surgery. These included the small oral opening required for the procedure (4 cm) and the precise initial pharyngeal dissection facilitated by the robot, enabling safe identification of the eustachian tubes. Additionally, closure was made easier, both for the dura (in cases of intradural surgery or iatrogenic durotomy) and for the posterior pharyngeal mucosa, potentially reducing the rate of wound dehiscence. The assistance of an ENT specialist at the console with a 3D magnified camera while the spine surgeon worked on the bone was also emphasized. However, the authors noted a significant limitation: the lack of specialized surgical instruments for bone dissection, requiring parts of the surgery to be performed without direct robotic assistance (Table 4).

3.3.3. Thoracic tumoral surgery

Three studies, including four patients, reported the use of the DVR for access and resection of paravertebral benign tumors (Table 3). Typical patients presented with tumors that appeared benign on pre-operative imaging, demonstrated growth on subsequent imaging, were asymptomatic, and were located near critical anatomical structures. In these scenarios, a complete tumoral removal was aimed with preservation of the functional outcome. An exception was noted in a case reported by Perez Cruzet, where a patient presented with a paravertebral schwannoma refractory to radiation therapy, confirmed by biopsy and

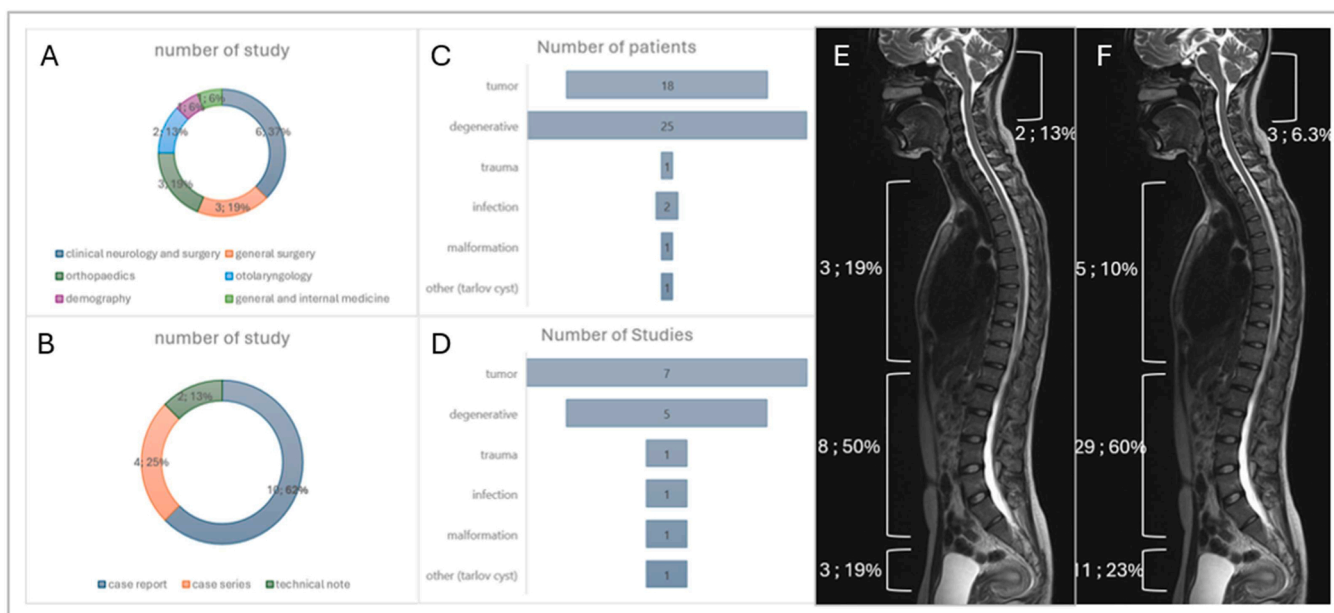


Fig. 3. Data collection from studies related to the use of the Da Vinci Robot in spine surgery. A: Categories of journal that published those articles (number; percentage); B: Type of studies published (number ; percentage); C: Number of patients by pathology treated (number); D: Number of studies by pathology treated (number); E: Repartition of studies according to the treated area of the spine (number ; percentage); F: Repartition of patients according to the treated area of the spine (number ; percentage).

Table 2
Types of articles included and journals.

	Number (percentage) – mean (min – max)
Type of article	
Case report	10 (62.5%)
Case Series	4 (25%)
Technical Note	2 (12.5%)
Journal's category	
Neurosurgery	6 (37.5%)
General Surgery	3 (18.8%)
Orthopedics	3 (18.8%)
Otolaryngology	2 (12.5%)
Demography	1 (6.3%)
Internal Medicine	1 (6.3%)
JCI (2023)	0.85 (0.28–1.56)

associated with evolving pain. The use of the DVR in this case was specifically motivated by the increased surgical risk posed by prior radiation therapy.

Operative duration was available for two patients [14], with each surgery lasting approximately 105 min. Blood loss was minimal, under 100 mL for most cases, except for the patient who had undergone prior radiation therapy, where blood loss was approximately 250 mL. In one case, a two-step surgical approach was performed: first, a posterior tubular decompression to remove the intracanal portion of the tumor, followed by posterior fusion, and then an anterior transthoracic approach for complete resection.

Patient positioning varied between supine and lateral decubitus. Equipment commonly used included somatosensory and motor-evoked potential monitoring, neuromonitoring probes for free-running and triggered electromyography, and double-lumen endotracheal tubes.

All procedures achieved excellent outcomes, with patients remaining neurologically intact and demonstrating clinical improvement. Patients were discharged between postoperative days 1 and 3.

3.3.4. Lumbo-sacral tumoral spine surgery

The DVR has been utilized to facilitate minimally invasive approaches for lumbo sacral tumors (Table 3). The reported cases include a

variety of neurogenic lesions, such as schwannomas, other benign paraspinal tumors, and a symptomatic sacral Tarlov cyst. These tumors were often deeply seated and surrounded by critical neurovascular structures.

Surgical approaches varied, with transperitoneal access being the most frequently used, as illustrated by Yang et al. [15], who described a left L4 paraspinous schwannoma near the aortic bifurcation, treated in 2 h and 40 min. Similarly, Oh [16] et al. employed transperitoneal access in their series of nine patients with presacral neurogenic lesions, including seven schwannomas, a transitional meningioma, and a malignant neurofibroma. The mean surgical duration in this study was 4 h and 12 min, with blood loss ranging from 200 to 1500 mL. Notable complications included wound infections in two cases, neuropathic pain in one, numbness in one, and intestinal obstruction in another.

Alternatively, retroperitoneal approaches were also employed, as in Rapoport et al.'s [17] case of a right L1 paraspinous schwannoma. This surgery lasted 1 h and 32 min, with minimal blood loss (50 mL), and the patient was discharged on postoperative day 2 without complications. Another case was reported by Albayar et al. [5], who used an anterior pelvic approach for a symptomatic sacral Tarlov cyst, leveraging intraoperative nerve monitoring and ureteral stenting to ensure safety.

Authors highlighted several advantages of the DVR in these indications, including minimally invasive exposure of the ventral sacral roots through a small surgical window, improved visualization, enhanced maneuverability, and superior suturing capability. Additionally, the robot allowed for precise and efficient electrocoagulation for hemostasis in the presacral space, contributing to reduced surgical times and favorable outcomes (Table 4).

3.3.5. Other

The use of DVR has also been described in other complex spinal surgeries, for example in cases of spondylodiscitis and pelvic fractures. Ye et al. [18] reported two cases of spondylodiscitis at L1-L2 and L4-L5. Both patients, were treated by orthopedic and urologic surgeons through an anterior approach to reach the spine with DVR assistance. Patients required one week of hospitalization and a three-month antibiotic regimen. While this series is small, it underscores the DVR's potential for managing infections in the lumbar spine, where precise access and

Table 3
 Informations related to patients included in this review.

Study	Specific Clinical Context justifying the use of DVR	Pathology and approach	Number of level operated (number of patients) or lesion	Mean Duration (surgical time)	Experience of the center	Surgical team	Blood Loss	Frame, or specific equipment	Outcome
Lee et al.	None (no past medical history)	ALIF retroperitoneal	1 (2/2) (L5-S1)	2h48 (192 min and 144 min)	First cases of the institution	Neurosurgeon, urologic surgeon	50 mL	.trendelenburg position .C-arm fluoroscope .12 mm 0° endoscope .Three portals	improved overall pain and adequate bone fusion in both cases
Lee et al.	No specific clinical setting	ALIF retroperitoneal	2 (4/11) 1 (7/11)	Overall : 3h40 For one level : L5-S1 (5 patients) : mean 3h07 (from 2h25 to 4h02) .L4-L5 (2 patients) : mean 3h40 (143 min – 297 min) For Two levels : L4-L5 and L5-S1 (4 patients) : 4h35 (227 min – 327 min)	Initial experience	Neurosurgeon, urologic surgeon	65 mL	.modified lithotomy position .skytron 6000 frame .C-arm fluoroscope . four to six portals	No major visceral/vascular injuries, postoperative ileus, or neurologic problems reported
Yuk et al.	None (no past medical history)	ALIF transperitoneal	1 (L5-S1)	1h15	Initial experience	Neurosurgeon Vascular surgeon, Urologic surgeon	20 mL	.Da vinci positioned between legs .Trendelenburg position .Jackson Frame .C-arm fluoroscope .12 mm 30° endoscope .Four portal .Da Vinci positioned between patient's left arm and head	Clinical improvement, no major complications
Beutler et al.	—	ALIF transperitoneal	1 (L5-S1)	2h15	Initial experience	Spine Surgeon General Surgeon	25 mL	.Trendelenburg .JacksonFrame .C-arm fluoroscope .4 portals (2 cameras) .lateral positioning	Patient discharged at day 1 postoperative
Loniewski et al., ^{ref}	Obese patients or patients with past medical history of multiple abdominal surgeries	OLIF Transperitoneal or Corporectomy	1 (3/10 single level OLIF) 2 (3/10 two level OLIF) 1 (4/10 single level corporectomy)	Overall : 5h07 For OLIF : one level (3 patients) : mean 2h39 .two levels (3 patients) : mean 4h46	Multicenter initial experience	Neurosurgeon, Vascular surgeon, urologic surgeon	—	.C-Arm fluoroscope . Da vinci positioned posterior to the patient	No complication reported, bony fusion achieved at one year postoperative

(continued on next page)

Table 3 (continued)

Study	Specific Clinical Context justifying the use of DVR	Pathology and approach	Number of level operated (number of patients) or lesion	Mean Duration (surgical time)	Experience of the center	Surgical team	Blood Loss	Frame, or specific equipment	Outcome
Transoral spine surgery Lee et al., ^{ref}	None (no specific problem related to the patient justifying the use of Da Vinci)	Basilar invagination Transoral	1	For corporectomy : one level (4 patients) : 6 h30 4h00 (total) : .15 min docking the Da Vinci .1h pharyngeal dissection .1h30 Odontoidectomy .1h closure	First case institutional case	Neurosurgeon, ENT	—	.Da Vinci positioned at the top of the table .C-Arm Fluoroscope .12 mm 0° and 30° endoscope	Extubation at 24 h, normal diet at 1 week Post op CT satisfaisant
Molteni et al.	No specific reason related to the patient	Benign bone tumors involving C1-C2	2 (atlantoaxial junction)	.5h30 for patient 1 (partial odontoidectomy and anterior arch of C1 removal), .2h25 for patient 2 (biopsy of atlanto-epistropheal joint then suture and closure)	Initial experience	Neurosurgeon, ENT	—	.C-arm fluoroscope .Nasogastric tube .30° endoscope .Davis Meier mouth gag .V-loc suture device	.liquid based diet for 3–4 days .pathologist : bone-cartilage fragments with inflammatory infiltrate .progressive improvement in strength and gastrointestinal symptoms.
McCann et al.	Small incidental lesion in a young healthy male	Odontoid chordoma	1	—	Initial experience in that setting	—	—	—	.wound dehiscence and oral flora contamination of anterior hardware. .discharged at postoperative day 30 .10-week course of antibiotics .tracheostomy decannulation at week 14 .9 months postoperative : no deficit, did not undergo radiation, patient is back to work
Thoracic tumoral spine surgery Finley et al., ^{ref}	Incidental left apical paraspinal 2.5cm × 2.5cm lesion – enlarging during follow-up and positive on PET imaging	paravertebral schwannoma (T1 level) through video assisted-Thoracoscopic approach (VATS)	1	—	First institutional case	Neurosurgeon and thoracic surgeon	—	.double-lumen endotracheal tube	. Total removal of the lesion

(continued on next page)

Table 3 (continued)

Study	Specific Clinical Context justifying the use of DVR	Pathology and approach	Number of level operated (number of patients) or lesion	Mean Duration (surgical time)	Experience of the center	Surgical team	Blood Loss	Frame, or specific equipment	Outcome
Pacchiarotti et al	Patient 1 : incidental lesion at the superior posterior sulcus (close to the aortic arch) – Authors states that standard VATS limitation carried “high risk of conversion to open thoracotomy” Patient 2 : incidental lesion enlarging during follow-up spanning from T9 to T11	paravertebral schwannoma – transthoracic anterior approach (VATS)	1 (2/2 patients)	Patient 1: 1h45 (15 min for docking of the robot and 75 min of robotic operating time) Patient 2 : 1h53 (13 min for robot docking and 90 min of robot operating time)	—	Neurosurgeon and thoracic surgeon	20 mL and 80 mL	.supine with gel roll under the shoulder – Table turned at 45° angle .Kelly clamp .three portal .neuromonitoring probe for free-running and triggered electromyography .lateral decubitus .endobronchial balloon	.motor function preserved Both patients : .Chest tube removed within few hours postoperative .discharged at postoperative day 1 .Uneventful postoperative course .total removal Both patient :. Gross total removal
Perez-Cruet et al.	Patient 1 : Failure of radiation therapy for a paravertebral schwannoma (proved on biopsy) with new onset right side shoulder pain Patient 2 : T3–4 foraminal mass that extended into the thoracic cavity (Figure 5A). N Neurologic intact	Upper thoracic paravertebral schwannomas (T2T3 and T3T4) expanding both on the thoracic cavity and in the spinal canal First : posterior tubular approach with laminectomy facetectomy and fusion. Then : anterior or lateral DVR-assisted thoracoscopy	1	—	Initial expérience	—	250 mL and 55 mL	.Jackson Frame .tubular retractor and for lamnectomy and facetectomy then posterior fusion (first part of the surgery) .Then supine (patient 1) and lateral position (patient 2) for robot-assister VATS .Somatosensory and motor evoked potential .double-lumen endotracheal tube	. Neurologically intact .Chest tube removed at postoperative day 2 (patient 1) and day 1 (patient 2) .Patient discharged at day 3 (patient 1) and day 2 (patient 2) .Normal activity within weeks
Lumbo sacral tumoral spine surgery Yang et al., ref	Patient with past medical history of L4L5 discectomy (right approach) – Left, fast growing, incidental left L4 mass, close to the aorta	L4L5 paraspinal schwannoma – Transperitoneal approach	1	Total time 2h40 (setup time : 30 min)	First institutional case	—	100 mL	.Right semilateral position	.Started diet 6 h after surgery

(continued on next page)

Table 3 (continued)

Study	Specific Clinical Context justifying the use of DVR	Pathology and approach	Number of level operated (number of patients) or lesion	Mean Duration (surgical time)	Experience of the center	Surgical team	Blood Loss	Frame, or specific equipment	Outcome
	bifurcation – Exam : Numbness left posterior thigh							.Four portals	.Discharged 48 h after surgery .neurological exam intact .2 patients with wound infection
Oh et al.	Symptomatic Presacral neurogenic lesions	Nine patients (7 schwannoma, one transitional meningioma, one malignant neurofibroma) – Transperitoneal approach	1	Mean 4h12 (from 2h to 5h50)	Initial institutional experience	—	655 mL (200 mL to 1500 mL)	—	.1 patient with neuropathic pain .1 patient with numbness .1 patient with intestinal obstruction .discharged at postoperative day 2
Albayar et al.	Symptomatic sacral Tarlov Cyst	Right S3 Tarlov Cyst – Anterior pelvic approach	1	—	First case	Neurosurgeon and General Surgeon	50 mL	.Supine position .5 mm 30° camera .Four portals .Nerve monitoring .Bilateral ureteral stenting	.discharged at postoperative day 2 .No complication
Rapoport et al.	healthy 48-yr-old man who presented with right flank pain and paresthesia, and was found to have a 6 × 4 × 2 cm mass arising from the right L1 root.	L1 paraspinal schwannoma – Retroperitoneal approach	1	Total surgical time : 1h 32 (including 44 min Console time)	—	Neurosurgeon and Urologist	50 mL	.intraoperative neuromonitoring	Discharged home at day 2 post surgery
Other Ye et al.	Patients with history of lumbar pain without any precipitating cause, aggravated after activity.	L1-L2 (patient 1) and L4-L5 (patient 2) Spondylodiscitis	1 (2/2 patients)	—	—	Orthopedic and Urologic surgeons	—	—	1 week hospitalization and 3 months antibiotics therapy
Peng et al.	Pelvic fracture	Type C3 pelvic fracture (Denis II sacral fracture on the right side, sacroiliac joint dislocation on the left side, and bilateral pubic rami and ischial ramus fractures. Fracture fragment compression was present in the S1 sacral foramen	—	2 h for pelvic fixation 3 h sacral nerve release	First institutional case	Orthopedics	250 mL	.Starr Frame .percutaneous transsacral–transiliac screw .C arm .TINAVI	.discharged at day 7 postoperative .numbness and neuropathic pain in the foot – No motor dysfunction

Table 4
Benefits and drawbacks outlined by authors.

Spine segment or pathology	General benefit of using the Da Vinci	Inconvenients
CCJ - Anterior approach	Requires only 4 cm oral opening Careful initial pharyngeal dissection, with safe identification of eustachian tubes Facilitated watertight closure of dura compared to microscopic and endoscopic surgery (useful for intradural surgery or inadvertent durotomy for extradural surgery) Facilitated closure of the posterior pharyngeal mucosa, potentially lowering wound dehiscence rate Guidance from the ENT stayed at the console (with the 3D camera) while the neurosurgeon is performing odontoidectomy	Lack of instruments for bone dissection
Thoracic	Potentially safer dissection of nerves through stable arms and instrumentation with 6 degrees of freedom	Suction is not available through the surgical system and must be placed by an assistant through either a separate port or through one of the ports used by the robotic arms
Lumbar - tumoral	Delicate dissection from the aorta and originating nerves for deep seated paravertbral lesions Sufficient exposure with small incisions Minimal retraction is needed to reach retroperitoneal lesions Definitive identification of the true tumor capsule is more straightforward Lowering risks of retrograde ejaculation Ease dissection of lymph nodes Blood loss is minimal	
Lumbar/Sacral - Degenerative	The visualization inside the disc space and surrounding structures was considered better than current open and laparoscopic techniques Easy electrocoagulation for hemostasis in the pre-sacral space	
Sacral - tumoral	Short surgery time Minimally invasive exposure of the ventral sacral roots in a small window with improved visualization, maneuverability, and suturing capability.	

debridement may be crucial for recovery.

Peng et al. [19] investigated the use of DVR for pelvic fractures, specifically in a complex Type C3 fracture with involvement of the sacral foramen. The procedure involved two separate operations: pelvic fixation (lasting 2 h) and sacral nerve release (lasting 3 h). The surgical team utilized a C-arm fluoroscopy, Starr Frame, and TINAVI for navigation. The patient experienced a blood loss of 250 mL and was discharged on postoperative day 7. While the patient developed numbness and neuropathic pain in the foot, there was no motor dysfunction, indicating a successful nerve release.

These studies highlight the versatility of DVR in managing various spine and pelvic conditions, demonstrating benefits such as enhanced precision, reduced blood loss, and favorable recovery outcomes (Table 4).

4. Discussion

Since the FDA approved the Da Vinci Robotic System (Intuitive Surgical Inc. Sunnyvale, CA, USA) Si® model in 2009 and the Xi® model in 2014, their applications in various surgical fields have expanded significantly [4]. These systems have been successful in procedures like prostatectomies, cardiac valve repairs, and lung transplants [2]. Through several advanced features, including a 3-dimensional endoscopic view, motions that exceed the natural range of the human hand, or tremor reduction, the DVR aims at overcoming human limitations, hence competing to enhance surgical performance in minimally invasive surgery.

Spine surgery is increasingly embracing this technology, thanks to the efforts of pioneering surgeons [20]. Following promising cadaver pilot studies, clinical research focusing on spinal conditions has emerged to advance minimally invasive techniques. The DVR system aims to reduce approach-related morbidity, shorten hospital stays, and provide quicker postoperative recovery. Although the current body of early studies is relatively small, it is expected to be followed by larger, higher-quality research, including randomized trials. Even more considering the recent 510(k) FDA approval of the new Da Vinci 5® model in March 2024 [2]. This latest model boasts significant advancements, such as improved accuracy and precision, haptic force-sensing technology that allows surgeons to feel subtle tissue forces, and new equipment like an electrosurgical unit. Furthermore, this model facilitates data collection to support the training of AI tools.

During the 2000s, the FDA approved the use of the Da Vinci Robot (DVR) in various surgical fields, including general, urologic, gynecologic, thoracic, and transoral procedures [1]. Consequently, spinal conditions intersecting these specialties became early candidates for DVR application. According to our review, Lee et al. were the first to report using the DVR in spinal surgery [11]. They successfully employed the system to address a basilar invagination of the odontoid process through a transoral odontoidectomy. They justified the use of the DVR in odontoidectomy by the “superb visualization” provided through stereoscopic visualization and magnification of the surgical field, assisting the approach in a narrow and deep working channel, particularly in patients with restricted mouth opening. They further emphasize that DVR is efficient to deal with iatrogenic durotomy. Following this success, another team reported a DVR-assisted transoral approach to effectively remove C2 benign tumors in two cases [12].

In the scope of clinical settings where DVR showed promising results, accessing lumbar discs through anterior and oblique approach for challenging cases represented the majority of included patients [6–10, 15,17,18]. Selected patients were obese patients, patients with a history of multiple abdominal surgeries, and patients with spondylodiscitis requiring retroperitoneal debridement [18]. Authors justified the used of DVR in such scenario thanks to its enhanced vision, as it includes a flexible camera controlled by the surgeon with adjustable angles. Additionally, the DVR reduces tremors and allows for precise movements without fatigue, facilitating the dissection of the psoas muscle and potentially lowering the risk of vascular, nervous, urological, or visceral damage. Loniewski et al. [10] published a series involving 10 patients who successfully underwent multi-level oblique lumbar interbody fusion (OLIF), with the DVR assisting in the approach. This adds to the findings of Lee et al. [7], who documented 11 patients undergoing anterior lumbar interbody fusion (ALIF) procedures. Both studies demonstrated that for these challenging patient groups, the DVR seems to offer safer surgery with reduced blood loss, shorter hospital stays, and improved recovery. Lee et al. also suggested that DVR-assisted ALIF at L5-S1 level could carry less risks of retrograde ejaculation [6]. These data have to be confirmed by larger cohort studies and eventually controlled trial. Notably, Yuk et al. [8]. performed a fully robot assisted ALIF, with transperitoneal DVR-assisted fusion, followed by posterior pedicle screw fixation assisted by Excelsius GPS robot.

The Da Vinci Robot (DVR) demonstrates promising results in the surgical treatment of peripheral nerve tumors, particularly

schwannomas, which can grow significantly due to their indolent and benign nature [14–17,21,22]. These tumors, often extravertebral or dumbbell-shaped, pose substantial surgical challenges, especially when located in the thoracic spine, causing spinal compression, intradural extension, and extension into the thoracic cavity with associated cerebrospinal fluid (CSF) leaks. The most challenging locations for safe resection include the extreme superior and inferior sulci of the thoracic cavity, where confined anatomical spaces severely limit visualization and identification of adjacent structures, such as subclavian vessels, the brachial plexus, azygos vein, esophagus, descending aorta, thoracic duct, intercostal vessels, and diaphragm. The DVR's advanced capabilities, including seven-degree arm movement, interchangeable camera ports, and bipolar electrocautery, allow for precise dissection of tumors from these critical structures, even in very confined spaces. This technology also facilitates tight dural closure, preventing pseudomeningocele and postoperative CSF leaks. Additionally, the DVR is effective in resecting paravertebral well-encapsulated masses originating from the prevertebral sympathetic plexus and abutting the abdominal aorta and left psoas muscle at the L4-L5 level, enhancing the safety and efficacy of these complex procedures.

However, the DVR faces several limitations hindering it from being extensively used in spine surgery to this day. One key limitation is that the DVR has not yet received FDA approval specifically for spinal surgery, leading to its cautious and selective use, mainly to facilitate surgical approaches in complex cases. Moreover, outcomes reports are still pending from a limited number of centers, limiting available data in the literature. The high cost of the DVR, which can reach up to 2 million euros, is another significant barrier, explaining why many centers do not have access to this technology. What is more, the maintenance costs reach \$150 000 per year and further expenses related to DVR supplies, staff, and non-DVR supplies adds to the overall cost. A study on the cost of ownership of the DVR across 16 centers in the USA, (involving 6000 patients), reported that the weighted average fixed cost per case was \$984, and the weighted average variable cost per case was \$8025 (from \$3325 for cholecystectomy to \$16,986 for rectal resection) [23]. Additionally, the learning curve for mastering the DVR is steep; while studies suggest proficiency is achieved after 30 hysterectomies [24], 27 hemicolectomies [25], and 20 prostatectomies [26], there is a lack of similar data for spinal surgery. Long-term outcomes and quality-of-life data for these minimally invasive techniques are also lacking, making meaningful comparisons with open approaches and cost-effectiveness analyses challenging. Furthermore, most of these procedures require a multidisciplinary team, demanding significant human resources in addition to the material resources, further complicating the widespread adoption of the DVR in spinal surgery.

5. Conclusion

The collective findings of the articles indicate that DVR system represents a secure and viable tool for minimally invasive spine surgery. Complex cases such as obese patients with past medical history of abdominal surgery makes good candidate for DVR assisted lumbar interbody fusion. Selected cases also include patients with benign asymptomatic paraspinal tumors growing on follow-up imaging. The use of DVR will certainly become more prevalent in the future, and as surgeons, we should train and familiarize ourselves with rapidly evolving technology and techniques. Nevertheless, some limits need to be addressed, as the absence of FDA approval and the necessity for the development of additional requisite tools.

CRedit authorship contribution statement

Substantial contributions to the conception or design of the work; or the acquisition, analysis, or interpretation of data for the work: AC, FT, SF.

Drafting the work or reviewing it critically for important intellectual

content: AC, FT.

Final approval of the version to be published: SF, ME, KF.

Informed consent and patient details

The authors declare that the work described does not involve patients or volunteers.

Human and animal rights

The authors declare that the work described has not involved experimentation on humans or animals.

Submission statement

This manuscript is original and has not been submitted elsewhere in part or in whole.

Funding

There is no disclosure of funding.

Declaration of competing interest

The authors certify that there is no conflict of interest with any financial organization regarding the material discussed in the manuscript.

References

- [1] MacLean L, Hersh AM, Bhimreddy M, et al. Comparison of accuracy, revision, and perioperative outcomes in robot-assisted spine surgeries: systematic review and meta-analysis. *J Neurosurg: Spine* 2024;1–13. <https://doi.org/10.3171/2024.4.SPINE23917>. Published online July 1.
- [2] Asadizeidabadi A, Hosseini S, Vetshev F, Osmin S, Hosseini S. Comparison of da Vinci 5 with previous versions of da Vinci and Sina: a review. *Laparosc Endosc Robot Surg* 2024;7(2):60–5. <https://doi.org/10.1016/j.lers.2024.04.006>.
- [3] Yang GZ, Cambias J, Cleary K, et al. Medical robotics—regulatory, ethical, and legal considerations for increasing levels of autonomy. *Sci Robot* 2017;2(4):eaam8638. <https://doi.org/10.1126/scirobotics.aam8638>.
- [4] Fiacchini G, Vianini M, Dallan I, Bruschini L. Is the Da Vinci Xi system a real improvement for oncologic transoral robotic surgery? A systematic review of the literature. *J Robotic Surg* 2021;15(1):1–12. <https://doi.org/10.1007/s11701-020-01132-0>.
- [5] Albayar A, Shao JM, Soriano IS, Welch WC. Robot-assisted ventral sacral Tarlov cystectomy; A case report. *Int J Surg Case Rep* 2022;90:106732. <https://doi.org/10.1016/j.ijscr.2021.106732>.
- [6] Lee J, Bhowmick D, Eun D, Welch W. Minimally invasive, robot-assisted, anterior lumbar interbody fusion: a technical note. *J Neurol Surg A Cent Eur Neurosurg* 2013;74(04):258–61. <https://doi.org/10.1055/s-0032-1330121>.
- [7] Lee Z, Lee JYK, Welch WC, Eun D. Technique and surgical outcomes of robot-assisted anterior lumbar interbody fusion. *J Robotic Surg* 2013;7(2):177–85. <https://doi.org/10.1007/s11701-012-0365-0>.
- [8] Yuk FJ, Carr MT, Schupper AJ, et al. Da Vinci Meets Globus Excelsius GPS: a totally robotic minimally invasive anterior and posterior lumbar fusion. *World Neurosurg* 2023;180:29–35. <https://doi.org/10.1016/j.wneu.2023.09.028>.
- [9] Beutler WJ, Poppelman WC, DiMarco LA. The da Vinci robotic surgical assisted anterior lumbar interbody fusion: technical development and case report. *Spine* 2013;38(4):356–63. <https://doi.org/10.1097/BRS.0b013e31826b3d72>.
- [10] Loniewski S, Farah K, Mansouri N, et al. Da Vinci robotic assistance for anterolateral lumbar arthrodesis: results of a French Multicentric Study. *World Neurosurg* 2024;181:e685–93. <https://doi.org/10.1016/j.wneu.2023.10.114>.
- [11] Lee JYK, Lega B, Bhowmick D, et al. Da Vinci Robot-assisted transoral odontoidectomy for basilar invagination. *ORL* 2010;72(2):91–5. <https://doi.org/10.1159/000278256>.
- [12] Molteni G, Greco MG, Presutti L. Transoral robotic-assisted surgery for the approach to anterior cervical spine lesions. *Eur Arch Otorhinolaryngol* 2017;274(11):4011–6. <https://doi.org/10.1007/s00405-017-4731-4>.
- [13] McCann AC, Berger C, Mahmoud AF, Kuan EC, Malhotra NR, O'Malley BW. Novel approach using transoral robotic surgery for resection of cervical spine chordoma. *Laryngoscope* 2019;129(6):1395–9. <https://doi.org/10.1002/lary.27489>.
- [14] Pacchiarotti G, Wang MY, Kolcun JPG, et al. Robotic paravertebral schwannoma resection at extreme locations of the thoracic cavity. *Neurosurg Focus* 2017;42(5):E17. <https://doi.org/10.3171/2017.2.FOCUS16551>.
- [15] Yang MS, Kim KN, Yoon DH, Pennant W, Ha Y. Robot-assisted resection of Paraspinal Schwannoma. *J Korean Med Sci* 2011;26(1):150. <https://doi.org/10.3346/jkms.2011.26.1.150>.

- [16] Oh JK, Yang MS, Yoon DH, et al. Robotic resection of huge presacral tumors: case series and comparison with an open resection. *J Spinal Disorders Techn* 2014;27(4):E151–4. <https://doi.org/10.1097/BSD.0b013e318299c5fd>.
- [17] Rapoport BI, Sze C, Chen X, et al. Robotic resection of a nerve sheath tumor via a retroperitoneal approach. *Operative Surg* 2021;20(2):E85–90. <https://doi.org/10.1093/ons/opaa329>.
- [18] Ye J, Liu H, Hu X, Li J, Gao L, Tang Y. Da Vinci robot-assisted laparoscopic retroperitoneal debridement for lumbar septic spondylodiscitis: a two-case report. *Front Surg* 2022;9:930536. <https://doi.org/10.3389/fsurg.2022.930536>.
- [19] Peng Y, Zhang W, Zhang G, et al. Using the Starr Frame and Da Vinci surgery system for pelvic fracture and sacral nerve injury. *J Orthop Surg Res* 2019;14(1):29. <https://doi.org/10.1186/s13018-018-1040-6>.
- [20] Loniewski S, Farah K, Malikov S, Fuentes S. Da Vinci robotic-assisted anterolateral lumbar arthrodesis: operative technique. *Acta Neurochir* 2023;165(9):2711–6. <https://doi.org/10.1007/s00701-023-05676-6>.
- [21] Perez-Cruet MJ, Welsh RJ, Hussain NS, Begun EM, Lin J, Park P. Use of the da Vinci Minimally Invasive Robotic System for Resection of a Complicated Paraspinal Schwannoma With Thoracic Extension: case report. *Operat Neurosurg* 2012;71:onsE209–oneE214. <https://doi.org/10.1227/NEU.0b013e31826112d8>.
- [22] Finley D, Sherman J, Avila E, Bilsky M. Thorascopic resection of an apical Paraspinal Schwannoma using the da Vinci surgical system. *J Neurol Surg A Cent Eur Neurosurg* 2013;75(01):058–63. <https://doi.org/10.1055/s-0033-1345687>.
- [23] Feldstein J, Schwander B, Roberts M, Coussons H. Cost of ownership assessment for a da Vinci robot based on US real-world data. *Robot Comput Surg* 2019;15(5):e2023. <https://doi.org/10.1002/rcs.2023>.
- [24] Oh S, Bae N, Cho HW, Park YJ, Kim YJ, Shin JH. Learning curves and perioperative outcomes of single-incision robotic sacrocolpopexy on two different da Vinci® surgical systems. *J Robotic Surg* 2023;17(4):1457–62. <https://doi.org/10.1007/s11701-023-01541-x>.
- [25] Huang P, Li S, Li P, Jia B. The learning curve of Da Vinci Robot-Assisted Hemicolectomy for colon cancer: a retrospective study of 76 cases at a single center. *Front Surg* 2022;9:897103. <https://doi.org/10.3389/fsurg.2022.897103>.
- [26] Yu C, Xu L, Ye L, et al. Single-port robot-assisted perineal radical prostatectomy with the da Vinci Xi system: initial experience and learning curve using the cumulative sum method. *World J Surg Onc* 2023;21(1):46. <https://doi.org/10.1186/s12957-023-02927-9>.