



HAL
open science

Radiation Therapy in a Perineal Squamous Cell Carcinoma in a Patient With Fanconi Anemia: A Case Report and Review of Literature

Tanguy Perennec, Stéphane Supiot, Marc-André Mahe, Juliette Podevin, Emmanuel Rio, Caroline Abadie

► **To cite this version:**

Tanguy Perennec, Stéphane Supiot, Marc-André Mahe, Juliette Podevin, Emmanuel Rio, et al.. Radiation Therapy in a Perineal Squamous Cell Carcinoma in a Patient With Fanconi Anemia: A Case Report and Review of Literature. *Advances in Radiation Oncology*, 2021, 6 (1), pp.100546. 10.1016/j.adro.2020.08.003 . hal-04950987

HAL Id: hal-04950987

<https://hal.science/hal-04950987v1>

Submitted on 17 Feb 2025

HAL is a multi-disciplinary open access archive for the deposit and dissemination of scientific research documents, whether they are published or not. The documents may come from teaching and research institutions in France or abroad, or from public or private research centers.

L'archive ouverte pluridisciplinaire **HAL**, est destinée au dépôt et à la diffusion de documents scientifiques de niveau recherche, publiés ou non, émanant des établissements d'enseignement et de recherche français ou étrangers, des laboratoires publics ou privés.



Distributed under a Creative Commons Attribution - NonCommercial - NoDerivatives 4.0 International License

Teaching Case

Radiation Therapy in a Perineal Squamous Cell Carcinoma in a Patient With Fanconi Anemia: A Case Report and Review of Literature



Tanguy Perennec, MD,^a Stéphane Supiot, MD, PhD,^{a,b,*} Marc-André Mahe, MD, PhD,^a Juliette Podevin, MD,^c Emmanuel Rio, MD,^a and Caroline Abadie, MD^{c,d}

^aDepartment of Radiation Oncology, Institut de Cancérologie de l'Ouest René Gauducheau, Nantes- Saint Herblain, France; ^bCentre de Recherche en Cancérologie Immunologie Nantes Angers (CRCINA), Institut National de Santé et de la Recherche Médicale (INSERM) UMR U1232, Centre National de la Recherche Scientifique (CNRS) ERL 6001, Université de Nantes, 44007 Nantes, France; ^cDepartment of visceral surgery, Centre Hospitalier Universitaire, Nantes-Saint Herblain, France; and ^dDepartment of Genetics Institut de Cancérologie de l'Ouest René Gauducheau, Nantes-Saint Herblain, France

Received 24 March 2020; revised 8 June 2020; accepted 3 August 2020

Introduction

Fanconi anemia (FA) is a rare genetic syndrome characterized by congenital malformations, progressive bone marrow failure, and predisposition to malignancy.¹ Life expectancy for patients with FA used to be very poor, with death typically supervening between 20 and 30 years of age, but bone marrow transplantation has transformed the prognosis: most patients with FA now live for more than 30 years after transplantation.² The condition is caused by a defect in 1 of the proteins of the FA pathway, which in the healthy individual governs homologous recombination repair and translesion bypass in response to DNA covalent linkage induced by cross-linking agents.³ The defective proteins prevent DNA damage from being correctly repaired, which leads to increased chromosomal instability and the predisposition to malignant disease (mostly squamous cell carcinomas [SCCs] and acute myeloid leukemia). Every cell in the body of a

patient with FA is thus also exquisitely sensitive to radiation therapy, and to chemotherapies such as mitomycin C and cisplatin, which induce covalent linkages, so severe toxicity must be anticipated should these therapies be deployed.

Although the theoretical risks of radiation therapy and chemotherapy in patients with FA are well understood, data informing the risk-benefit analysis of such treatments are sparse. A PubMed search on radiation therapy in patients with FA with SCC yielded only 11 results, mostly single case reports, with a wide range of therapeutic plans and outcomes.

We report our experience with neo-adjuvant radiation therapy in a patient with FA presenting with an extensive perineal recurrence of an SCC of the vagina.

Case Presentation

A 25-year-old woman presented to the gynecology department with intense pain, dysuria, and a foul-smelling anal discharge with mucus and blood in December 2016. Examination revealed a mass in the anal canal.

She was known to have FA, diagnosed with molecular testing (heterozygotic mutation IVS11_IVS14del and IVS07-05T>C). At the age of 19 she had been treated for

Sources of support: This work had no specific funding.

Disclosures: none.

All data generated and analyzed during this study are included in this published article.

* Corresponding author: Stéphane Supiot, MD, PhD; E-mail: stephane.supiot@ico.unicancer.fr

<https://doi.org/10.1016/j.adro.2020.08.003>

2452-1094/© 2020 The Author(s). Published by Elsevier Inc. on behalf of American Society for Radiation Oncology. This is an open access article under the CC BY-NC-ND license (<http://creativecommons.org/licenses/by-nc-nd/4.0/>).

myelodysplasia with an allogenic bone marrow transplant, in combination with fludarabine and cyclophosphamide chemotherapy and total body irradiation (2 Gy), with no acute or late toxicity. No analysis of chimerism was performed.

In 2008, the patient was diagnosed with recurrent vulvar, anal, and cervical intraepithelial neoplasias, at least 1 of which tested human papillomavirus positive. In April 2015, she developed a 3-cm vaginal SCC, which was treated by radical colpohysterectomy and bilateral adnexectomy. Then she represented 2 times in the 2 following years, with a relapse of 9 mm in the vulva and then 20 mm in the perineal region, both treated by surgery with healthy margins. The depth of infiltration could not be determined in each SCC except for the second time, when it was 5 mm. In situ lesions were always numerous and in contact with the excision limits.

The newly presented tumor in the anal canal was confirmed as a relapse of the SCC by biopsy. It was 4 cm in maximum diameter and was associated with numerous recurrent vulvar, anal, and cervical intraepithelial neoplasia lesions, and a 2-cm left internal inguinal fixed adenopathy. The tumor was therefore classified T4N2, stage IIIB.

After discussion at a multidisciplinary case conference, it was decided, in view of the general condition and youth of the patient, to attempt a curative treatment with neoadjuvant radiation therapy before a total pelvic exenteration. The radiation therapy was delivered to the perineal and vulvar regions, anal canal, lower rectum, and bilateral inguinal nodes to a total dose of 45 Gy, given in 30 sessions (1.5 Gy per day), 5 times a week (see Appendix E1). The treatment was delivered with tomotherapy, using 6 MV photons with intensity modulated radiation therapy. A grade I radio-dermatitis was initially observed in the perineal region after 18 Gy, mostly in the supra pubic region. Then, grade I radio-dermatitis expanded gradually to the inguinal areas and became grade II in the inguinal area and in the gluteal cleft after 24 Gy with exuding painful limited lesions. Grade III was reached after 31.5 Gy with confluent lesions from the inguinal area to the

anus. Skin toxicity was managed first by cleaning with saline and application of cream containing hyaluronic acid (Effidia). Then, when the lesions became exuding, eosin and silicone absorbent dressing (Mepilex Transfer) were applied. Pain treatment required fentanyl and oxycodone (Fig 1).

Two weeks after radiation therapy, a severe non-regenerative normocytic anemia at 6.4 g/dL was diagnosed, probably induced by radiation therapy. The anemia, in addition to cachexia, necessitated a 2-month postponement of surgery. The patient then underwent the total pelvic exenteration with terminal colostomy and urinary diversion. Excision was complete on the operative specimen, except for an area in contact with the left ischiopubic ramus, which was not considered sufficient grounds for reoperation and was kept under observation.

One month later, the patient presented with severe pelvic pain, scar disunion, and a swollen and erythematous suprapubic area. A biopsy confirmed a relapse of the SCC. In view of the patient's poor general condition (cachexia and asthenia with drowsiness), the patient received best supportive care in the palliative unit, where she died within a month.

Discussion

Our literature review found that all reported patients with FA treated for SCC with radio-chemotherapy had to discontinue treatment due to leucopenia or total aplasia,⁴⁻⁷ hemorrhagic complication,⁸ and, in 1 case, a pneumonia in which the white blood cell count was unspecified.⁹ The only exceptions were 2 patients treated with radio-chemotherapy with cetuximab¹⁰ and gemcitabine⁴ and 2 patients treated by radiation therapy and very low dose chemotherapy (less than 25% of the normal dose).^{11,12}

Conversely, radiation therapy without chemotherapy has been reported to yield oncological success with acceptable adverse effect (\leq grade 2)^{13,14} but also severe hematologic adverse events, with oncological success¹⁵ or death.^{16,17}

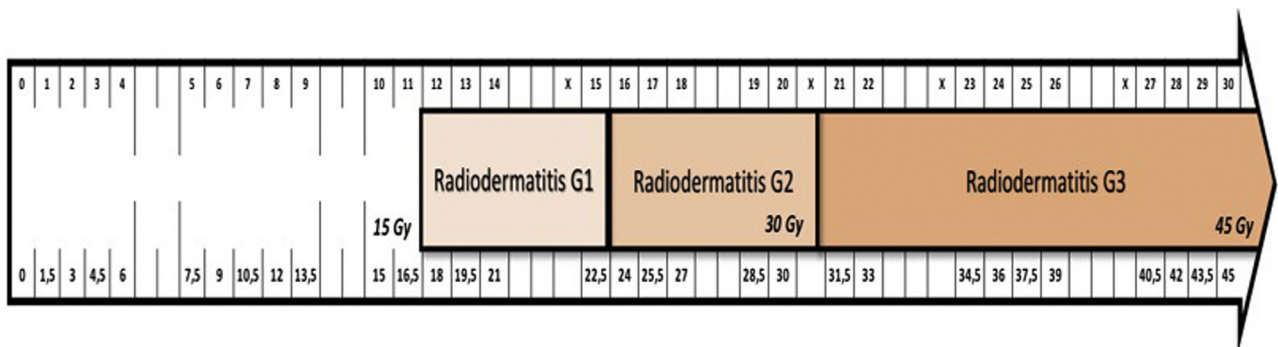


Figure 1 Timeline of radiation therapy toxicity depicting the number of fractions delivered (upper line) and the cumulated dose (lower line). X in the timeline represents each postpone-ment of radiation therapy.

In Table 1, we summarize all reports of radiation therapy treatment of SCC of the anus, genital tract, vulva, cervix, vagina, or urinary tract in patients with FA. No cases of stem cell transplantation are reported. Of the 8 cases reported, only 2 treatments can be considered successful (patient alive and relapse-free more than 8 months after treatment). Four patients died during the treatment or immediately afterward, including 3 from sepsis secondary to leukopenia.

In the light of this review, we considered that chemotherapy should be avoided because of the excessive risk of serious complications related to myelosuppression. Radiation therapy also presents significant risks and a regular monitoring of blood counts should be performed and any cytopenia treated early. The case reports in which radiation therapy was completed with acceptable side effects suggest that extended courses at lower daily doses to reach the same total dose should be considered, even if the biological equivalent dose is slightly lower (in the present case 1.50 instead of 1.80 Gy per fraction, for a total dose of 45 Gy).²³ Nevertheless, reports documenting

the tolerability of radiation therapy in patients with FA are extremely rare. Furthermore, information on whether or not patients have been transplanted should be carefully reported, including data on chimerism after hematopoietic transplant, as chimerism may be associated with fewer hematological adverse events.

According to National Comprehensive Cancer Network guidelines, our patient should have undergone radio-chemotherapy when she presented with her anal tumor,²⁴ but in the present case, we had to consider the important theoretical risk of using chemotherapy and radiation therapy and decided to only treat by radiation therapy. Radiation therapy could have also been offered at her diagnosis of recurrent vaginal SCC. At the time, this option had not been discussed by the medical team. Perhaps earlier radiation therapy should have been discussed given the significant probability of relapse, but that would require radiation therapy anyway. On the other hand, radiation therapy, in the light of our review, is associated a high risk of death from leukopenia and thrombocytopenia. Finally, therapeutic decision making remains very difficult: use radiation

Table 1 Reported treatment modalities and outcomes in FA perineal SCC treated with radiation therapy

Ref.	Site	Treatment modality	Outcome
(⁴)	Anus	Postoperative irradiation 55.8 Gy in 31 fractions	Moderate skin reaction but an inoperable SCC of the tongue was diagnosed 4 mo later. She died in 7 mo.
(⁵)	Vulva	54 Gy given in 30 fractions associated with cisplatin	Treatment stopped after 21 Gy due to leukopenia and pelvic abscess, treated by surgery. The patient died 2 d postoperatively as a result of septic shock.
(¹⁴)	Vulva	Surgery and radiation therapy of 45 Gy plus 15 Gy to the inguinal nodes	Treatment completed with moderate skin reaction. Free of relapse at 1 y.
(¹⁸)	Vulva + inguinal metastasis	45 Gy, given in 25 fractions	Treatment stopped after 9 Gy owing to cardiopulmonary arrest caused by a seizure.
(¹⁹)	Left retromolar trigone + vulva + cervix	64.8 Gy, given in 27 fractions. Surgery and brachytherapy of 35 Gy, 7 fractions	Treatment completed with oral mucositis grade 3 and leukopenia grade 4. The patient died of septicemia.
(²⁰)	Vulva	Not reported	Thrombocytopenia grade 3
(²¹)	Vagina	Brachytherapy of 48 Gy in 6 fractions of 5 Gy — 15 day interval — then 2 fractions of 5 Gy followed by 2 fractions of 4 Gy	Treatment completed with moderate rectal pain, moderate vaginal bleeding, anemia grade 2. Then: pulmonary fungal infection, pancytopenia, rectal pain and bleeding, vaginal bacterial and fungal infection, leg and arm phlebitis, perineal abscess and sepsis. The patient died 12 wk after the initial diagnosis.
(²²)	Anus	Not reported	Complete response without recurrence at 8 mo of follow-up

Abbreviations: FA = Fanconi anemia; SCC = squamous cell carcinoma.

therapy early, with a curative intent but with a high hematological risk, or wait until disease is locally advanced and treat with palliative intent. In all cases, patients should undergo serial blood counts and have a transfusion if needed, given that hematological complications are the most frequent and serious complications in patients with FA.

Supplementary Materials

Supplementary material for this article can be found at <https://doi.org/10.1016/j.adro.2020.08.003>.

References

1. Mehta PA, Tolar J. Fanconi anemia. In: Adam MP, Ardinger HH, Pagon RA, et al., eds. *GeneReviews*®. Seattle: University of Washington, Seattle; 1993.
2. Sanders JE, Woolfrey AE, Carpenter PA, et al. Late effects among pediatric patients followed for nearly 4 decades after transplantation for severe aplastic anemia. *Blood*. 2011;118:1421-1428.
3. Wang W. Emergence of a DNA-damage response network consisting of Fanconi anaemia and BRCA proteins. *Nat Rev Genet*. 2007;8:735-748.
4. Bremer M, Schindler D, Groß M, Dörk T, Morlot S, Karstens JH. Fanconi's anemia and clinical radiosensitivity: Report on two adult patients with locally advanced solid tumors treated by radiotherapy. *Strahlenther Onkol*. 2003;179:748-753.
5. Carvalho JP, Dias MLN, Carvalho FM, Del Pilar Estevez Diz M, Petito JW. Squamous cell vulvar carcinoma associated with Fanconi's anemia: A case report. *Int J Gynecol Cancer*. 2002;12:220.
6. Hosoya Y, Lefor A, Hirashima Y, et al. Successful treatment of esophageal squamous cell carcinoma in a patient with Fanconi anemia. *Jpn J Clin Oncol*. 2010;40:805-810.
7. Beehuat Tan I, Cutcutache I, Jiang Zang Z, et al. Fanconi's anemia in adulthood: Chemoradiation-induced bone marrow failure and a novel FANCA mutation identified by targeted deep sequencing. *J Clin Oncol*. 2011;29:e591-e594.
8. Spanier G, Pohl F, Giese T, Meier JK, Koelbl O, Reichert TE. Fatal course of tonsillar squamous cell carcinoma associated with Fanconi anaemia: A mini review. *J Cranio-Maxillofac Surg*. 2012;40:510-515.
9. Bradford CR, Hoffman HT, Wolf GT, Carey TE, Baker SR, McClatchey KD. Squamous carcinoma of the head and neck in organ transplant recipients: Possible role of oncogenic viruses. *Laryngoscope*. 1990;100:190-194.
10. Wong WM, Parvathaneni U, Jewell PD, et al. Squamous cell carcinoma of the oral tongue in a patient with Fanconi anemia treated with radiotherapy and concurrent cetuximab: A case report and review of the literature. *Head Neck*. 2013;35:E292-E298.
11. Tipples K, Raouf S. Treatment of oesophageal squamous cell carcinoma in a patient with Fanconi anaemia. *Clin Oncol*. 2008;20:383-384.
12. Dudek AZ, Chereddy S, Nguyen S, Wagner JE, Maddaus M. Neoadjuvant chemotherapy with reduced-dose carboplatin and gemcitabine for non-small cell lung cancer in a patient with fanconi anemia. *J Thorac Oncol*. 2008;3:447-450.
13. Nolan M, Courtney R, Sexton P, Barry T, McCann PJ. Aggressive recurrence of oral squamous cell carcinoma in a patient with Fanconi's anemia (FA). *Ir Med J*. 2017;110:533.
14. Mousavi A, Abbasi F, Abadi AGN, Hashemi FA. Vulvar squamous cell carcinoma associated with Fanconi's anemia. *Int J Hematol*. 2010;91:498-500.
15. Budrukkar A, Shahid T, Murthy V, et al. Squamous cell carcinoma of base of tongue in a patient with Fanconi's anemia treated with radiation therapy: Case report and review of literature. *Head Neck*. 2010;32:1422-1427.
16. Horta H de L e, Guimarães FF, Rocha LOS, Guimarães RES, Valadares ER. Squamous cell carcinoma of the hypopharynx in a young woman with Fanconi's anemia. *Braz J Otorhinolaryngol*. 2006;72:845-848.
17. Öksüzöğlü B, Yalçın Ş. Squamous cell carcinoma of the tongue in a patient with Fanconi's anemia: A case report and review of the literature. *Ann Hematol*. 2002;81:294-298.
18. Harper JL, Jenrette JM, Goddu SM, Lal A, Smith T. Vulvar cancer in a patient with Fanconi's anemia, treated with 3D conformal radiotherapy. *Am J Hematol*. 2004;76:148-151.
19. Han T-J, Lee C-H, Yoo C-W, et al. Synchronous multifocal HPV-related neoplasm involving both the genital tract and the head-and-neck area: A case report of Fanconi anemia. *Radiother Oncol*. 2009;92:138-141.
20. Natesan D, Susko M, Havrilesky L, Chino J. Definitive chemoradiotherapy for vulvar cancer. *Int J Gynecol Cancer*. 2016;26:1699.
21. Dias AR, de Andrade Silva MC, Carvalho FM, et al. Fanconi anemia and vaginal squamous cell carcinoma. *Rare Tumors*. 2012;4:11-12.
22. Barbeiro S, Atalaia-Martins C, Marcos P, Gonçalves C, Cotrim I, Vasconcelos H. A case series of anal carcinoma misdiagnosed as idiopathic chronic anal fissure. *PJG*. 2017;24:227-231.
23. Schethenbach K, Wagenmann M, Freund M, Schipper J, Hanenberg H. Squamous cell carcinomas of the head and neck in fanconi anemia: Risk, prevention, therapy, and the need for guidelines. *Klin Padiatr*. 2012;224:132-138.
24. Benson AB, Venook AP, Al-Hawary MM, et al. Anal carcinoma, Version 2.2018, NCCN Clinical Practice Guidelines in Oncology. *J Natl Compr Canc Netw*. 2018;16:852-871.