



**HAL**  
open science

## Delayed-type hypersensitivity gastrointestinal symptoms induced by food oral immunotherapy and efficiently treated by dupilumab: A case report

Camille Braun, Kathryn Samaan, François Graham, Louis Paradis, Anne Des Roches, Philippe Bégin

### ► To cite this version:

Camille Braun, Kathryn Samaan, François Graham, Louis Paradis, Anne Des Roches, et al.. Delayed-type hypersensitivity gastrointestinal symptoms induced by food oral immunotherapy and efficiently treated by dupilumab: A case report. *Pediatric Allergy and Immunology*, 2023, 34 (3), 10.1111/pai.13935 . hal-04946511

**HAL Id: hal-04946511**

**<https://hal.science/hal-04946511v1>**

Submitted on 17 Feb 2025

**HAL** is a multi-disciplinary open access archive for the deposit and dissemination of scientific research documents, whether they are published or not. The documents may come from teaching and research institutions in France or abroad, or from public or private research centers.

L'archive ouverte pluridisciplinaire **HAL**, est destinée au dépôt et à la diffusion de documents scientifiques de niveau recherche, publiés ou non, émanant des établissements d'enseignement et de recherche français ou étrangers, des laboratoires publics ou privés.



Distributed under a Creative Commons Attribution - NonCommercial - NoDerivatives 4.0 International License

# Delayed-type hypersensitivity gastrointestinal symptoms induced by food oral immunotherapy and efficiently treated by dupilumab: A case report

To the Editor,

Food oral immunotherapy (FOIT) is newly indicated as an option for the management of food allergies (FAs), including in patients with severe disease and/or those with multiple food allergens.<sup>1</sup> Mild-to-moderate adverse events with food dosing are frequent and often include gastrointestinal (GI) symptoms (abdominal pain, nausea, and emesis).<sup>1</sup> Patients presenting with immediate GI symptoms usually respond well to premedication with H1 or H2 antagonists or mast cell stabilizers.<sup>2</sup> For delayed GI symptoms, the distinction between immunoglobulin E (IgE)-mediated late-phase and cell-mediated reactions is often not self-evident and management can be challenging.<sup>3</sup> We report here the case of a patient presenting with two distinct FOIT-induced GI symptomatology that were successfully managed in turn with omalizumab and dupilumab, thus suggesting different underlying mechanisms. Omalizumab is a monoclonal antibody that binds serum IgE and prevents it from arming its receptor on mast cells, thereby decreasing immediate reactivity to the allergen. Dupilumab, on the contrary, binds the IL13/IL4 receptor, which is central to the type 2 inflammatory response. [Figure 1](#) summarizes the sequence of events.

The patient initiated a multiple FOIT at 5 years old, 2 months after starting omalizumab, indicated at the time for his uncontrolled severe asthma, although off-label given his age. The patient also presented atopic dermatitis (AD), which was controlled with mild-to-moderate potency topical steroids. He had been diagnosed with multiple IgE-mediated FAs (peanut, sesame, soybean, tomato, mustard, hazelnut, sunflower, strawberry, kiwi, and multiple legumes) as well as house dust mites, dog and cat allergies by skin testing, specific IgE and a concordant history of reactions, including oral food challenges. Two episodes of severe anaphylaxis (generalized urticaria, facial angioedema, bronchospasm, and hypoxia) to mustard and one to tomato were objectivated at the ER despite low specific IgE against these foods (sIgE = 0.24 and 0.33 kU/L, respectively). His asthma was quickly controlled after omalizumab initiation, and it was decided to start a multiple FOIT with peanut (sIgE = 288 kU/L), sesame (sIgE = 2.19 kU/L), hazelnut (sIgE = 24.5 kU/L), mustard, and soybean (sIgE = 13.3 kU/L). A target maintenance dose of 1250 mg

of total food proteins (250 mg of proteins per food) was reached after an uneventful rush escalation.

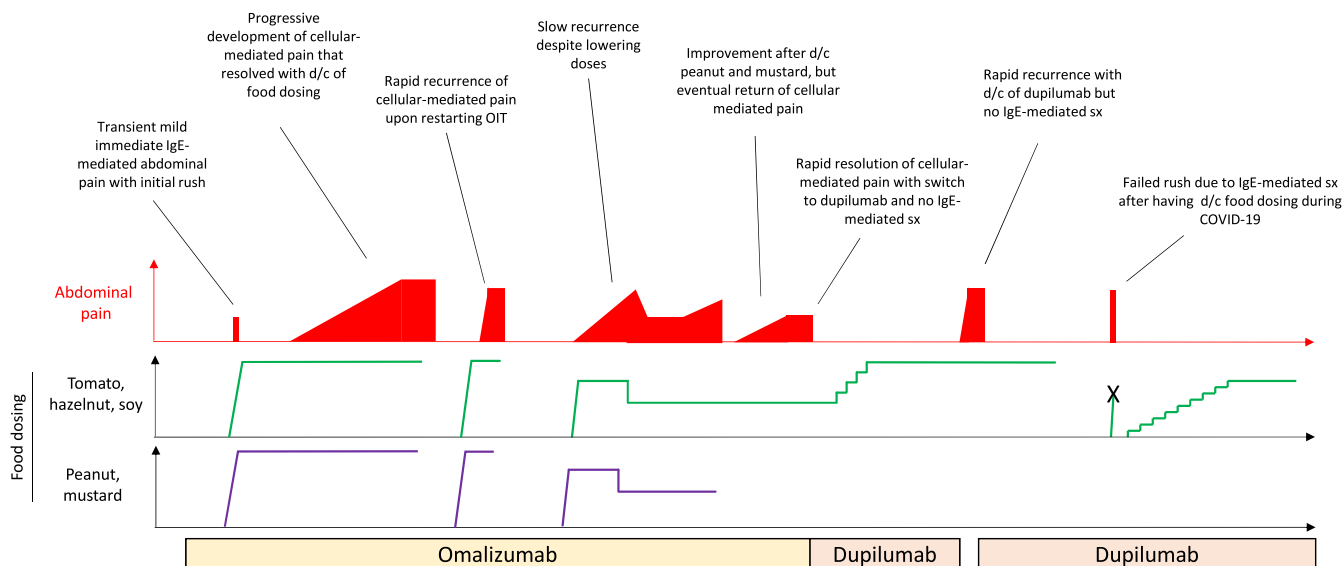
In the first few weeks of daily home ingestion, the patient reported immediate lip pruritus and mild abdominal pain after taking the dose, which were successfully controlled with H1 and H2 antihistamine pretreatment. About 2 months after FOIT initiation, the patient developed chronic moderate abdominal pain and reflux for which the timing appeared unrelated to daily dose ingestion. H1 and H2 antihistamine, montelukast and disodium cromoglycate failed to prevent these symptoms. The patient also presented random episodes of vomiting and loose stools. Trials of ingested topical corticosteroids and oral corticosteroids were also ineffective. Endoscopy was declined by parents who felt it was too invasive.

The patient temporarily discontinued the FOIT, which led to a complete regression of the symptoms. These quickly reappeared when food dosing was resumed, along with AD exacerbation. Decreasing the FOIT maintenance dose by half provided only a temporary improvement in symptoms. Atopy patch tests<sup>4</sup> with the different flours/powders at a 30% concentration in Vaseline revealed mild 2+ positive reactions to soybean and hazelnut and strong 3+ positive for peanut and sesame ([Figure 2](#)). Atopy patch test for mustard caused caustic irritation and was thus uninterpretable. Daily ingestion of peanut, sesame, and mustard was stopped, and FOIT was continued for soybean and hazelnut only, quickly reaching 125 mg of protein per food. However, after a few weeks, daily doses had to be further decreased due to a recurrence of dose-independent GI symptoms and eczema.

Based on the suspicion that the patient's symptoms were the result of a food-induced delayed-type hypersensitivity reaction (Gell & Coombs IVb), biologic therapy was switched from omalizumab to dupilumab, a monoclonal antibody targeting type 2 inflammation by blocking the IL-4/13 receptor. Four days after the first injection, the atopy patch tests became negative, except for peanut, which improved but remained at 3+ ([Figure 2](#)). Delayed GI symptoms and AD completely abated following dupilumab initiation despite restarting FOIT with hazelnut, sesame, mustard, soybean, and this time, tomato. Six months later, dupilumab was discontinued due to technical

This is an open access article under the terms of the [Creative Commons Attribution-NonCommercial-NoDerivs](#) License, which permits use and distribution in any medium, provided the original work is properly cited, the use is non-commercial and no modifications or adaptations are made.

© 2023 The Authors. *Pediatric Allergy and Immunology* published by European Academy of Allergy and Clinical Immunology and John Wiley & Sons Ltd.



**FIGURE 1** Chronology of the successive events that occurred in the present case. The red graph illustrates the chronology and the intensity of the abdominal pain. The colored curves illustrate the progression of the daily OIT dosing with the various foods. d/c = discontinuation; hz = hazelnut; IgE = immunoglobulin E; OIT = oral immunotherapy; pn = peanut; sx = symptoms.

issues related to coverage. Delayed OIT symptoms reappeared in about a month and resolved again when dupilumab was reinstated.

One year later, the patient stopped food dosing entirely due to the COVID-19 pandemic, without stopping dupilumab. When FOIT was resumed 6 months later, contrarily to the initial food escalation on omalizumab, the patient presented immediate dose-related reactions (urticaria, mouth pruritus, and emesis within 15 min of food ingestion) after low amounts of the food allergen, requiring a more traditional up-dosing schedule to be employed. There was however no recurrence of the dose-independent GI symptoms or AD.

This case provides a unique insight into the underlying mechanisms of abdominal pain in OIT, which is one of the most frequent adverse events reported with this treatment.<sup>1</sup> Recognizing the existence of distinct endotypes of abdominal pain in FOIT could be useful to guide optimal management. Here, the recourse to two different biologics during OIT, as well as a sequence of challenge and dechallenge with dupilumab and food dosing, allowed to specifically tease out the contribution of IgE-mediated and type 2 inflammatory pathways in the patient's abdominal pain patterns.

Omalizumab has been used extensively to increase tolerance threshold in omalizumab-enabled OIT protocols, allowing for faster and safer desensitization. Omalizumab prevents not only the immediate degranulation of mast cells responsible for immediate local symptoms but also the late-phase production of lipid mediators, which may contribute to delayed abdominal reactions. The notion of an IgE-mediated component to delayed abdominal pain is supported by its frequent occurrence in the months following discontinuation of omalizumab.<sup>5,6</sup>

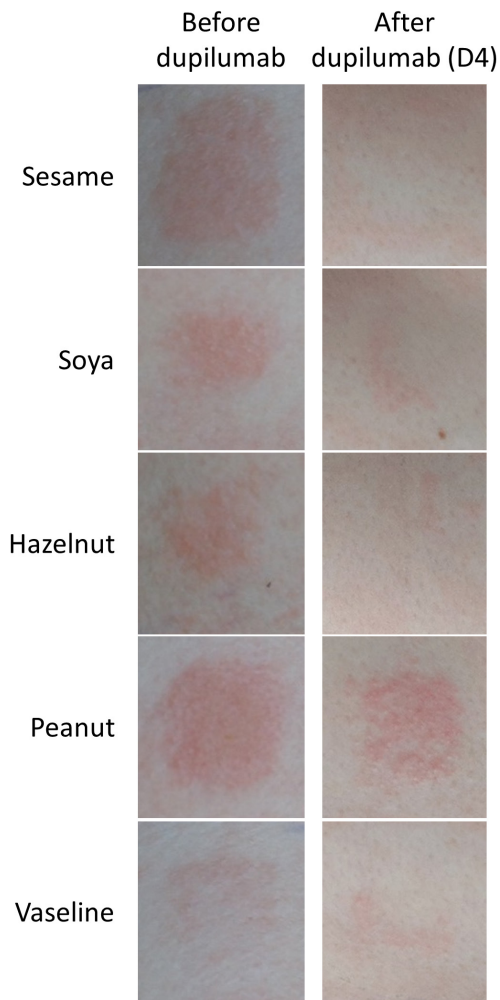
Outside the specific context of omalizumab-enabled OIT, IgE-mediated late-phase reaction pain can be difficult to distinguish from type 2 cell-mediated symptoms, as both are expected to improve with topical and oral corticosteroids and to be associated with

blood and tissue eosinophilia. In this specific case, however, the positive atopy patch tests and the response to dupilumab dechallenge and rechallenge specifically pointed toward a type 2 cell-mediated etiology. Another potentially relevant feature was the timing of the symptoms, which were not delayed but rather mostly unrelated to the time of food dosing.

A remarkable finding was that the abdominal pain did not improve with a decrease in OIT dose, which is usually the case with the classical presentations of Eosinophilic Esophagitis Like Oral Immunotherapy Related Syndrome<sup>7</sup> or Oral Immunotherapy-Induced Gastrointestinal Symptoms and Eosinophilic Responses.<sup>8,9</sup> Improvement with lower doses and slower subsequent increase may indicate an IgE-mediated mechanism that is amenable to desensitization. The extent of GI involvement may also be helpful to distinguish between endotypes. Echeverria-Zusaire and colleagues had previously reported that the presence of lower GI symptoms was associated with a failure to continue food dosing despite medication and dose adjustments.<sup>10</sup> The extent to which these different features are truly driven by a difference in endotype or by individual disease severity is unclear.

Just as omalizumab did not prevent type 2 inflammatory symptoms, dupilumab did not offer protection against IgE-mediated symptoms when OIT was resumed after its prolonged discontinuation. Taken as a whole, this case provides a clear demonstration of the complementary, nonredundant actions of these two biologics in FOIT.

In conclusion, the use of two biologics in this case, with challenge-dechallenge-rechallenge sequences demonstrated the co-existence of distinct endotypes of FOIT-induced abdominal pain. The recognition of these endotypes may help further personalize patient care in FOIT, with the development of individualized management algorithm based on clinical features and targeted investigations such as



**FIGURE 2** Patch tests performed before dupilumab treatment (left) and 4 days after the first injection of dupilumab (right).

APT. Dupilumab may be an effective option for patients presenting with a type 2 inflammatory FOIT-related abdominal pain endotype persisting despite dose adjustments.

#### CONFLICT OF INTEREST STATEMENT

None.

Camille Braun<sup>1,2,3</sup>  
 Kathryn Samaan<sup>1</sup>  
 François Graham<sup>1,4</sup>  
 Louis Paradis<sup>1</sup>  
 Anne Des Roches<sup>1</sup>  
 Philippe Bégin<sup>1,4</sup>

<sup>1</sup>Section of Allergy and Clinical Immunology, Department of Pediatrics, Centre Hospitalier Universitaire Sainte-Justine, Montreal, Quebec, Canada

<sup>2</sup>Department of Pediatrics, Pneumology, Allergy, Cystic Fibrosis, Hôpital Femme Mère Enfant, Hospices Civils de Lyon, Bron, France

<sup>3</sup>Centre International de Recherche en Infectiologie, INSERM U1111, CNRS UMR 5308, Université Lyon 1, ENS de Lyon, Lyon, France

<sup>4</sup>Section of Allergy and Clinical Immunology, Department of Medicine, Centre Hospitalier de l'Université de Montréal, Montreal, Quebec, Canada

#### Correspondence

Camille Braun, Service de Pédiatrie, pneumologie, allergologie, mucoviscidose, Hôpital Femme Mère Enfant, 59 Boulevard Pinel, 69677 Bron Cedex, France.  
 Email: [camille.braun.med@ssss.gouv.qc.ca](mailto:camille.braun.med@ssss.gouv.qc.ca)

Editor: CARMEN RIGGIONI

#### REFERENCES

- Bégin P, Chan ES, Kim H, et al. CSACI guidelines for the ethical, evidence-based and patient-oriented clinical practice of oral immunotherapy in IgE-mediated food allergy. *Allergy Asthma Clin Immunol*. 2020;16:20.
- Patriarca G, Nucera E, Roncallo C, et al. Oral desensitizing treatment in food allergy: clinical and immunological results. *Aliment Pharmacol Ther*. 2003;17:459-465.
- Chu DK, Freitag T, Marrin A, et al. Peanut Oral immunotherapy with or without H1 and H2 antihistamine premedication for Peanut allergy (PISCES): a placebo-controlled randomized clinical trial. *J Allergy Clin Immunol Pract*. 2022;10:2386-2394.
- Luo Y, Zhang G-Q, Li Z-Y. The diagnostic value of APT for food allergy in children: a systematic review and meta-analysis. *Pediatr Allergy Immunol*. 2019;30:451-461.
- Burk CM, Dellon ES, Steele PH, et al. Eosinophilic esophagitis during peanut oral immunotherapy with omalizumab. *J Allergy Clin Immunol Pract*. 2017;5:498-501.
- Azzano P, Paquin M, Langlois A, et al. Determinants of omalizumab dose-related efficacy in oral immunotherapy: evidence from a cohort of 181 patients. *J Allergy Clin Immunol*. 2021;147:233-243.
- Wasserman, R. L., Sugerma R. W., Kamili Q. U. A., Pence D. M., Hague A. R., Herbert M. Eosinophilic esophagitis like Oral immunotherapy related syndrome (ELORS). *J Allergy Clin Immunol* 141, AB258 (2018), AB258.
- Goldberg MR, Nachshon L, Levy MB, Elizur A, Katz Y. Risk factors and treatment outcomes for oral immunotherapy-induced gastrointestinal symptoms and eosinophilic responses (OITIGER). *J Allergy Clin Immunol Pract*. 2020;8:125-131.
- Chua GT, Chan ES, Invik R, et al. How we manage gastrointestinal symptoms during Oral immunotherapy through a shared decision-making process - a practical guide for the community practitioner. *J Allergy Clin Immunol Pract*. 2022. doi:10.1016/j.jaip.2022.11.015
- Echeverría-Zudaire LÁ, Fernández-Fernández S, Rayo-Fernández A, Muñoz-Archidona C, Checa-Rodríguez R. Primary eosinophilic gastrointestinal disorders in children who have received food oral immunotherapy. *Allergol Immunopathol*. 2016;44:531-536.