



HAL
open science

COVID-19 vaccination may cause FDG uptake beyond axillary area

Vincent Fleury, Bruno Maucherat, Daniela Rusu, Frédéric Dumont, Caroline Rousseau

► **To cite this version:**

Vincent Fleury, Bruno Maucherat, Daniela Rusu, Frédéric Dumont, Caroline Rousseau. COVID-19 vaccination may cause FDG uptake beyond axillary area. *European Journal of Hybrid Imaging*, 2021, 5 (1), pp.11. 10.1186/s41824-021-00105-2. hal-04937646

HAL Id: hal-04937646

<https://hal.science/hal-04937646v1>

Submitted on 10 Feb 2025

HAL is a multi-disciplinary open access archive for the deposit and dissemination of scientific research documents, whether they are published or not. The documents may come from teaching and research institutions in France or abroad, or from public or private research centers.

L'archive ouverte pluridisciplinaire **HAL**, est destinée au dépôt et à la diffusion de documents scientifiques de niveau recherche, publiés ou non, émanant des établissements d'enseignement et de recherche français ou étrangers, des laboratoires publics ou privés.



Distributed under a Creative Commons Attribution 4.0 International License

CASE REPORT

Open Access

COVID-19 vaccination may cause FDG uptake beyond axillary area



Vincent Fleury^{1*}, Bruno Maucherat¹, Daniela Rusu¹, Frédéric Dumont² and Caroline Rousseau^{1,3,4}

* Correspondence: vfleury245@gmail.com

¹Department of Nuclear Medicine, ICO Gauducheau Cancer Center, Boulevard Monod, 44805 Saint-Herblain Cedex, France
Full list of author information is available at the end of the article

Abstract

Background: The vaccination immune response may induce false-positive ¹⁸F-FDG PET/CT uptake.

Case presentation: An extended supraclavicular lymph nodal activation after coronavirus disease 2019 (COVID-19) vaccination revealed on ¹⁸F-FDG PET/CT mimics a Virchow nodule in a patient with medical history of well-differentiated appendicular adenocarcinoma.

Conclusion: This case highlights a nodal activation beyond axillary area and the importance of documenting vaccination history at the time of scanning to avoid false-positive results.

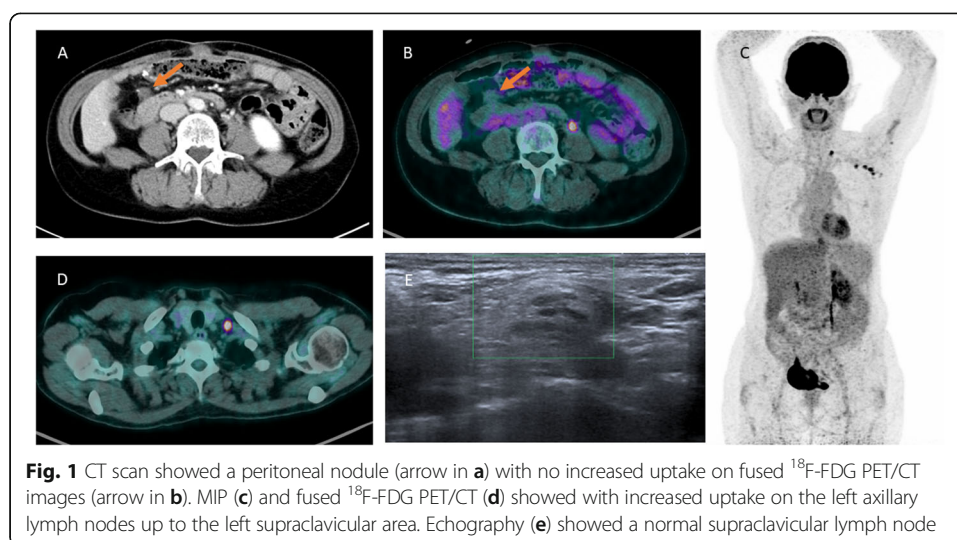
Keywords: FDG PET/CT, COVID-19, Vaccine

Background

Development of vaccines to prevent COVID-19 is a hope to prevent transmission or reduce the severity of infection. However, vaccination could be a potential source of false-positive results in ¹⁸F-FDG PET/CT (Katal et al. 2021).

Case presentation

We present the case of a 64-year-old female with well-differentiated appendicular adenocarcinoma associated with peritoneal carcinosis initially treated by surgery and chemotherapy benefited from a ¹⁸F-FDG PET/CT to investigate a peritoneal nodule (Fig. 1). This peritoneal nodule (arrow) visualized on the axial (a) view of CT image showed no increased FDG uptake on the axial (b) PET/CT fused image. The MIP (c) and axial (D) PET/CT fused images detected an intense hypermetabolism on the left axillary lymph nodes up to the left supraclavicular area. The patient revealed she had received the first of dose Pfizer BNT162b2mRNA vaccine against COVID-19 on the left shoulder intramuscular 4 days before FDG examination. In order to exclude a Virchow nodule due to her digestive cancer history, we performed a cervical echography with supraclavicular node cytological biopsy sample. Echography (E) showed a 14-mm-long axis normal lymph node with its central hilum. Cytological analysis revealed activated lymphoid cells without tumor cells.



Discussion

Several previous reports have demonstrated axillary lymph nodal activation on ^{18}F -FDG PET/CT following influenza and COVID-19 vaccination (Burger et al. 2011; Shirone et al. 2012; Eifer et al. 2021; Nawwar et al. 2021). This case revealed an atypical extended supraclavicular activation. In the context of the COVID-19 pandemic and large vaccination programs, questionnaires including date and location of the vaccination can help to avoid false-positive lymph node interpretation with the risk of a therapeutic choice impact offered to the patient. In patients with solid tumor like breast cancer or melanoma, the vaccination should be performed in the contralateral arm to limit misinterpretations. Otherwise, it would be advisable to respect a time interval to define between the vaccination and ^{18}F -FDG PET/CT scan.

Conclusion

Nuclear physicians should be careful when cancers staging and re-staging. This is especially important for patients with breast cancer having been vaccinated on the homolateral upper limb, digestive cancer patients vaccinated on the left side, or with lung or head and neck carcinoma.

Acknowledgements

Not applicable

Authors' contributions

Conception and design: VF; BM; DR; FD; CR. Acquisition of data, analysis and interpretation of data: VF; BM; DR; FD; CR. Drafting the article and final approval of the revised manuscript: VF; BM; DR; FD; CR. All authors read and approved the final manuscript.

Funding

No funding

Availability of data and materials

Not applicable

Declarations

Ethics approval and consent to participate

As the FDG-PET/CT was part of a routinely performed clinical examination, no ethics approval was needed.

Consent for publication

For this case report, the patient has consented to the submission.

Competing interests

The authors declare that they have no conflicts of interest or competing interests.

Author details

¹Department of Nuclear Medicine, ICO Gauducheau Cancer Center, Boulevard Monod, 44805 Saint-Herblain Cedex, France. ²Department of Surgical Oncology, ICO Gauducheau Cancer Center, Saint-Herblain, France. ³CNRS, Inserm, CRCI NA, Nantes, France. ⁴Nantes University, Nantes, France.

Received: 11 April 2021 Accepted: 10 May 2021

Published online: 01 June 2021

References

- Burger IA, Husmann L, Hany TF, Schmid DT, Schaefer NG (2011) Incidence and intensity of F-18 FDG uptake after vaccination with H1N1 vaccine. *Clin Nucl Med*. 36(10):848–853. <https://doi.org/10.1097/RLU.0b013e3182177322>
- Eifer M, Eshet Y (2021) Imaging of COVID-19 vaccination at FDG PET/CT. *Radiology*. 28:210030
- Katal S, Pouraryan A, Gholamrezanezhad A (2021) COVID-19 vaccine is here: practical considerations for clinical imaging applications. *Clin Imaging*. 76:38–41. <https://doi.org/10.1016/j.clinimag.2021.01.023>
- Nawwar AA, Searle J, Hagan I, Lyburn ID (2021) COVID-19 vaccination induced axillary nodal uptake on [18F]FDG PET/CT. *Eur J Nucl Med Mol Imaging*. 26:1–2
- Shirone N, Shinkai T, Yamane T, Uto F, Yoshimura H, Tamai H, Imai T, Inoue M, Kitano S, Kichikawa K, Hasegawa M (2012 Apr) Axillary lymph node accumulation on FDG-PET/CT after influenza vaccination. *Ann Nucl Med*. 26(3):248–252. <https://doi.org/10.1007/s12149-011-0568-x>

Publisher's Note

Springer Nature remains neutral with regard to jurisdictional claims in published maps and institutional affiliations.

Submit your manuscript to a SpringerOpen[®] journal and benefit from:

- ▶ Convenient online submission
- ▶ Rigorous peer review
- ▶ Open access: articles freely available online
- ▶ High visibility within the field
- ▶ Retaining the copyright to your article

Submit your next manuscript at ▶ [springeropen.com](https://www.springeropen.com)
