



HAL
open science

Neoplastic plasma cells with concomitant azurophilic crystalline inclusions and Snapper-Schneid bodies

Radu Chiriac, Luc-marie Gerland, Lucile Baseggio

► To cite this version:

Radu Chiriac, Luc-marie Gerland, Lucile Baseggio. Neoplastic plasma cells with concomitant azurophilic crystalline inclusions and Snapper-Schneid bodies. *eJHaem*, 2024, 5 (5), pp.1076-1077. 10.1002/jha2.1004 . hal-04911072

HAL Id: hal-04911072

<https://hal.science/hal-04911072v1>

Submitted on 24 Jan 2025

HAL is a multi-disciplinary open access archive for the deposit and dissemination of scientific research documents, whether they are published or not. The documents may come from teaching and research institutions in France or abroad, or from public or private research centers.

L'archive ouverte pluridisciplinaire **HAL**, est destinée au dépôt et à la diffusion de documents scientifiques de niveau recherche, publiés ou non, émanant des établissements d'enseignement et de recherche français ou étrangers, des laboratoires publics ou privés.



Distributed under a Creative Commons Attribution 4.0 International License

Neoplastic plasma cells with concomitant azurophilic crystalline inclusions and Snapper-Schneid bodies

Radu Chiriac  | Luc-Marie Gerland | Lucile Baseggio 

Laboratoire d'hématologie biologique, Hospices Civils de Lyon, Pierre-Benite, France

Correspondence

Radu Chiriac, Laboratoire d'hématologie biologique, Hospices Civils de Lyon, 69495 Pierre Benite Cedex, France.

Email: radu.chiriac@chu-lyon.fr

KEYWORDS

cytology, flow cytometry, multiple myeloma, plasma cell

A 66-year-old woman was being monitored for severe osteoporosis. Laboratory studies showed a 6 g/dL M spike and immunoglobulin M kappa paraprotein. Also, CRAB criteria were met.

The bone marrow (BM) aspirate revealed the presence of 30% atypical plasma cells (PC), which contained numerous large cytoplasmic azurophilic granules that appeared as dots resembling intracellular

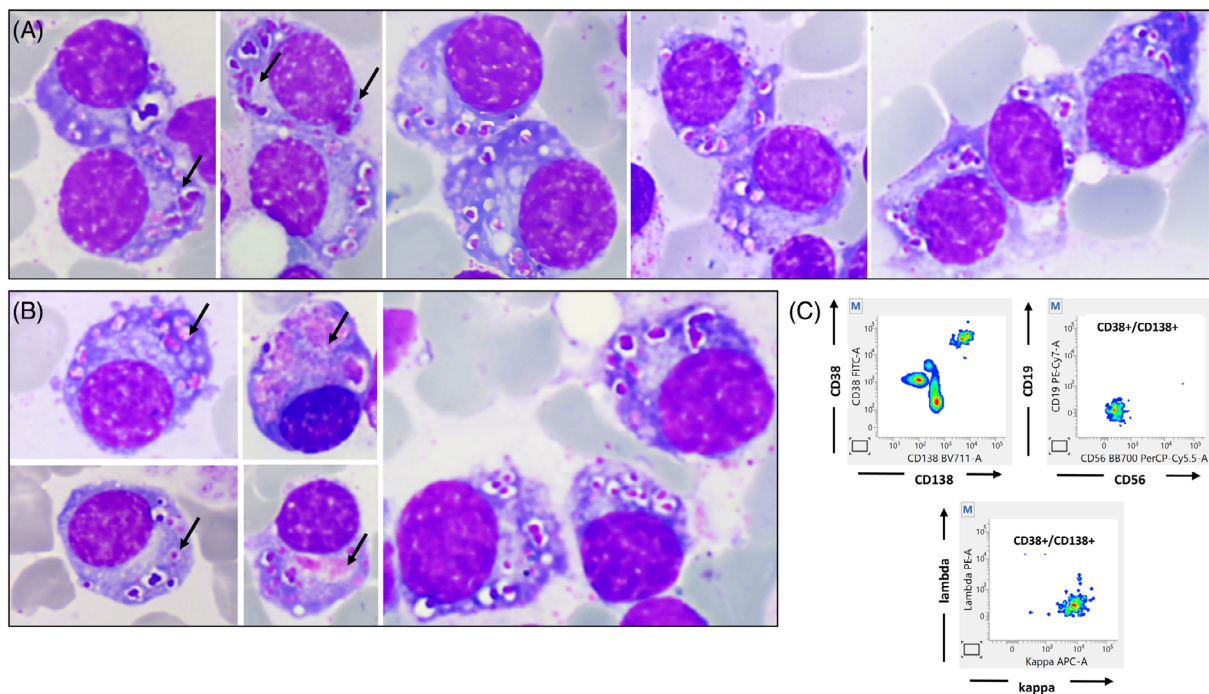


FIGURE 1 Panels A and B (x100 objective): Plasma cells with numerous large cytoplasmic granules and a few Snapper-Schneid bodies (arrows). Panel C: Aberrant flow cytometry profile of plasma cells—CD38+/CD138+, loss of CD45, CD19, and CD56, expressing kappa immunoglobulin light chain.

This is an open access article under the terms of the [Creative Commons Attribution](https://creativecommons.org/licenses/by/4.0/) License, which permits use, distribution and reproduction in any medium, provided the original work is properly cited.

© 2024 The Author(s). eJHaem published by British Society for Haematology and John Wiley & Sons Ltd.

microorganisms. Concurrently, these cells were reminiscent of the “storage-type” histiocytes reported in lysosomal storage diseases (Figure 1, Panels A and B; May-Grunwald Giemsa stain [MGG], x100 objective). However, a subset of PC displayed coarse azurophilic granules, morphologically consistent with Snapper-Schneid bodies (Figure 1, Panels A and B [arrows]; MGG stain, x100 objective). Flow cytometry of the BM aspirate revealed a monotypic CD38+/CD138+ PC population with an aberrant profile characterized by the loss of CD45 and CD19. These PC were also CD56-, CD200+, CD20+, CD117+, and CD27- (Figure 1, Panel C), and expressed kappa immunoglobulin light chain, consistent with the observed paraprotein.

Various types of cytoplasmic inclusions have been documented in plasma cell neoplasms, including Russell bodies, crystals, and Auer rod-like inclusions, while azurophilic granules and Snapper-Schneid bodies remain uncommon. This myeloma case is particularly noteworthy as it demonstrates the presence of both azurophilic granules and Snapper-Schneid bodies in an untreated patient with a rare paraprotein: immunoglobulin M kappa. Previous case reports have documented this phenomenon in pretreated patients, including those involving diamidine treatment [1].

The presence of PC with atypical granules and an aberrant immunophenotype underscores diagnostic complexity, requiring thorough morphological and immunological examination. Careful distinction of these features from those of microbial infections or lysosomal storage diseases is essential to ensure appropriate clinical management.

AUTHOR CONTRIBUTIONS

Radu Chiriac wrote the manuscript; Lucile Baseggio and Luc-Marie Gerland conducted the cytological and flow cytometric studies. All authors contributed to the final manuscript.

CONFLICT OF INTEREST STATEMENT

The authors declare no conflict of interest.

FUNDING INFORMATION

The authors received no specific funding for this work.

DATA AVAILABILITY STATEMENT

Data sharing is not applicable to this article as no new data were created or analyzed in this study.

ETHICS STATEMENT

This manuscript respects the ethical policy of Hospices Civils de Lyon for the treatment of human research participants.

PATIENT CONSENT STATEMENT

No patient-identifying data were used. The authors did not obtain written informed consent from the patient but the patient did not object to his data being used for research purposes (as required by the ethics policy of Hospices Civils de Lyon).

CLINICAL TRIAL REGISTRATION

The authors have confirmed clinical trial registration is not needed for this submission.

ORCID

Radu Chiriac  <https://orcid.org/0009-0001-7550-0638>

Lucile Baseggio  <https://orcid.org/0000-0001-7543-6480>

REFERENCE

1. Snapper I, Schneid B. On the influence of stilbamidine upon myeloma cells. *Blood*. 1946;1(6):534–36.

How to cite this article: Chiriac R, Gerland L-M, Baseggio L. Neoplastic plasma cells with concomitant azurophilic crystalline inclusions and Snapper-Schneid bodies. *eJHaem*. 2024;5:1076–77. <https://doi.org/10.1002/jha2.1004>