



**HAL**  
open science

## Acute abdominal aortic occlusion associated with transient paraplegia

Florent Porez, Antoine Gaudin, Dominique Fabre, Alessandro Costanzo,  
Lucas Le Guillou, Stéphan Haulon

► **To cite this version:**

Florent Porez, Antoine Gaudin, Dominique Fabre, Alessandro Costanzo, Lucas Le Guillou, et al.. Acute abdominal aortic occlusion associated with transient paraplegia. *Journal of Vascular Surgery Cases and Innovative Techniques*, 2024, 10 (6), pp.101637. 10.1016/j.jvscit.2024.101637. hal-04910332

**HAL Id: hal-04910332**

**<https://hal.science/hal-04910332v1>**

Submitted on 24 Jan 2025

**HAL** is a multi-disciplinary open access archive for the deposit and dissemination of scientific research documents, whether they are published or not. The documents may come from teaching and research institutions in France or abroad, or from public or private research centers.

L'archive ouverte pluridisciplinaire **HAL**, est destinée au dépôt et à la diffusion de documents scientifiques de niveau recherche, publiés ou non, émanant des établissements d'enseignement et de recherche français ou étrangers, des laboratoires publics ou privés.



Distributed under a Creative Commons Attribution - NonCommercial - NoDerivatives 4.0 International License

# Acute abdominal aortic occlusion associated with transient paraplegia

Florent Porez, MD, Antoine Gaudin, MD, Dominique Fabre, MD, PhD, Alessandro Costanzo, MD, Lucas Le Guillou, MD, and Stéphan Haulon, MD, PhD, *Le Plessis-Robinson, France*

## ABSTRACT

We describe a rare case of acute occlusion of the abdominal aorta presenting as a rapidly evolving flaccid paraplegia owing to spinal cord ischemia and our management protocol that allowed complete recovery of the patient. A 70-year-old man who was referred to our department with painless lower limb loss of sensory and motor function. Endovascular recanalization was performed using a covered stent. The patient was discharged 4 days after the procedure with full recovery of neurological symptoms. Rapid aortic endovascular revascularization to restore flow to the pelvis and lower limbs, associated with spinal cord ischemia protocols, is critical for full recovery. (*J Vasc Surg Cases Innov Tech* 2024;10:101637.)

Acute occlusion of the abdominal aorta (AOAA) is a rare vascular emergency with high morbidity and mortality rates.<sup>1</sup> The typical presentation includes bilateral lower limb ischemia with pulselessness, paresthesia, pallor, and intense pain. AOAA associated with flaccid paraplegia owing to spinal cord ischemia (SCI) is extremely rare and poorly documented.<sup>2-6</sup> We report a case of a 70-year-old man who developed rapidly evolving flaccid paraplegia while running owing to acute occlusion of the infrarenal aorta. Initially assessed by the neurosurgery team via computed tomography (CT) scan for potential neurological etiologies, the patient was found to have aortic thrombosis and was transferred immediately to our department. Patient data, including imaging and clinical history, were reviewed from our electronic database. The patient provided written consent for publishing the case, including images.

## RESULTS

A 70-year-old man was admitted with complete loss of sensory and motor function in the lower limbs. Clinical examination showed complete flaccid paraplegia without pain, and absent femoral artery pulses on both sides. The CT scan revealed a short occlusion of the infrarenal abdominal aorta, just below the inferior mesenteric artery, with a patent aortic bifurcation and patent external and internal iliac arteries. Endovascular

recanalization was performed after 3D CT scan reconstruction for procedural planning (Fig 1, A).

**Procedure.** Under local anesthesia, the right femoral artery was punctured under ultrasound guidance, and a 6F sheath was inserted. Preclosing with a Prostyle device (Abbott, Chicago, IL) was performed. A Terumo Glidewire was advanced through the occlusion under fusion guidance. Angiography confirmed a short occlusion of the abdominal aorta. After placement of a stiff wire (Lunderquist, Cook Medical, Bloomington, IN), we inserted a 12F sheath, which was advanced through the occlusion. A covered stent graft BeGraft Aortic 16 × 58 mm (Bentley, Hechingen, Germany) was advanced protected inside the sheath. The left femoral artery was also punctured to insert a 6F sheath and inflate an angioplasty balloon at the origin of the left common iliac artery to avoid embolization while inflating the aortic stent. A control angiogram showed patency of the stent graft, with no residual stenosis and patent iliac arteries. Femoral access was closed with the ProStyle device on the right side, and with a Femoseal (Terumo, Tokyo, Japan) device on the left side. The total ischemia time from the onset of symptoms to the treatment of the occlusion was approximately 3 hours. The patient was then transferred to the intensive care unit for close monitoring of our SCI protocol.<sup>7</sup>

**Clinical outcome and follow-up.** The patient showed an immediate decrease in symptoms after the procedure, with progressive recovery of his lower limbs motor and sensitive function. He was discharged 4 days after the procedure after full recovery of his neurological symptoms. His follow-up was uneventful, and a CT scan performed 3 months after the procedure confirmed the patency of the abdominal aorta (Fig 1, B), without any clinical sequelae.

## DISCUSSION

Acute aortic occlusion presenting as flaccid paraplegia. AOAA is usually concomitant with peripheral arterial disease and is associated with high morbidity and mortality rates.<sup>2</sup> AOAA is rarely associated with SCI,

---

From the Department of Vascular Surgery, Aortic Center, Hôpital Marie Lannelongue, Groupe Hospitalier Paris Saint Joseph, INSERM UMR\_S 999, Université Paris Saclay.

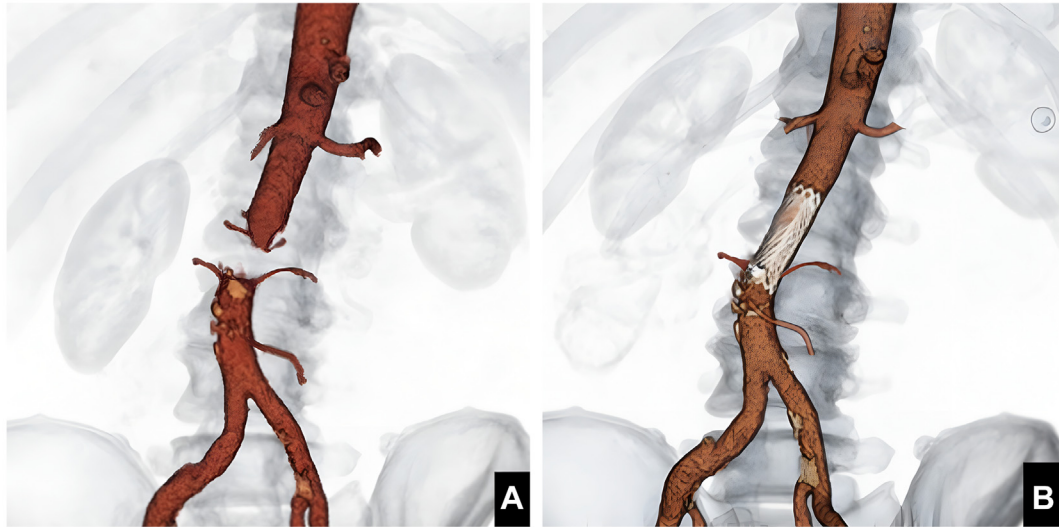
Correspondence: Stéphan Haulon, MD, PhD, Department of Vascular Surgery, Aortic Center, Hôpital Marie Lannelongue, Groupe Hospitalier Paris Saint Joseph, INSERM UMR\_S 999, Université Paris-Saclay, 133 Avenue de la Résistance, Le Plessis Robinson 92350, France (e-mail: [s.haulon@ghpsj.fr](mailto:s.haulon@ghpsj.fr)).

The editors and reviewers of this article have no relevant financial relationships to disclose per the Journal policy that requires reviewers to decline review of any manuscript for which they may have a conflict of interest.

2468-4287

© 2024 The Author(s). Published by Elsevier Inc. on behalf of Society for Vascular Surgery. This is an open access article under the CC BY-NC-ND license (<http://creativecommons.org/licenses/by-nc-nd/4.0/>).

<https://doi.org/10.1016/j.jvscit.2024.101637>



**Fig 1. (A)** Preoperative three-dimensional (3D) volume rendering reconstruction computed tomography (CT) scan. **(B)** Postoperative 3D volume rendering reconstruction CT scan.

which complicates the clinical presentation by introducing central neurological symptoms.

In AOAA without SCI, neurological deficits are caused by bilateral limb ischemia and result from inadequate blood flow to the muscles and nerves of the lower limbs. Pain is the most prominent symptom, associated with progressive sensory deficit, gradually progressing to a loss of motor function and, ultimately, tissue necrosis.

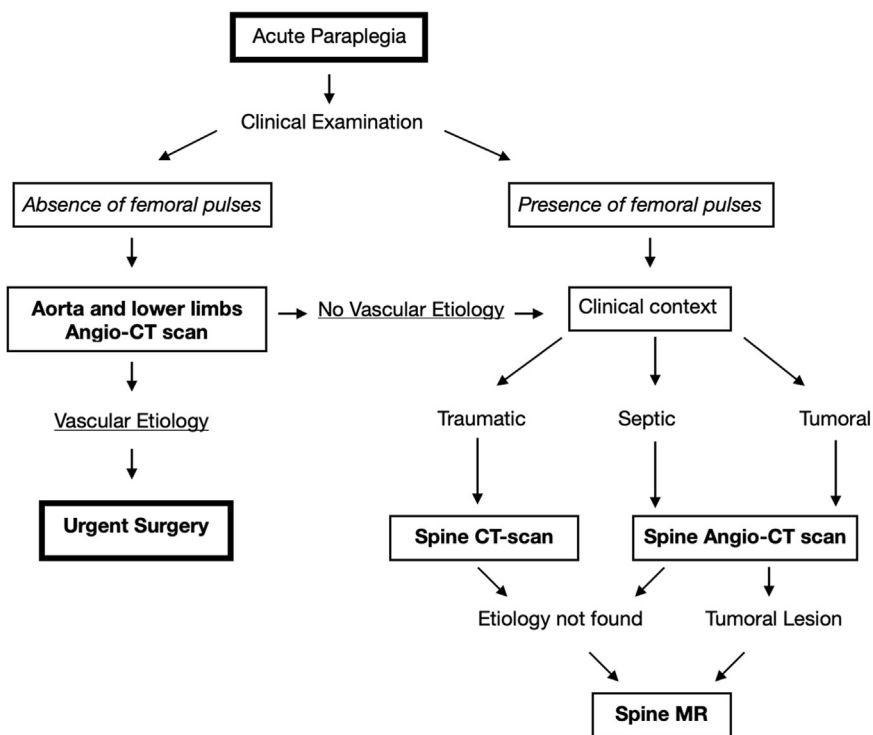
In AOAA with SCI, neurological deficit is the prominent and sudden symptom, caused by loss of function of the motor neurons and of the sensory pathway in the spinal cord. Patients describe a loss of voluntary movement and muscle tone and, more important, an absence of pain despite the associated lower limb ischemia. The painless flaccid paraplegia is responsible for the delayed diagnosis of AOAA. We provide a brief algorithm to distinguish aortic occlusion from other causes of SCI in Fig 2.

**SCI pathophysiology.** Concerning our patient, we hypothesized that the SCI was caused by the association of the occlusion of aortic collaterals (iliolumbar arteries) feeding the anterior spinal artery and, mostly, by low flow in the bilateral acute hypogastric arteries owing to the aortic thrombosis. According to Ohira et al,<sup>8</sup> spinal cord perfusion relies on a complex network of collateral arteries, primarily from branches emerging from the internal iliac arteries, forming an anastomotic continuum supporting the anterior and posterior spinal arteries. Preserving hypogastric artery perfusion is crucial to prevent SCI, as highlighted by Iliopoulos et al<sup>9</sup> in patients with bilateral acute hypogastric artery thrombosis resulting in SCI.

**Surgical treatment vs endovascular revascularization.** Endovascular recanalization was chosen over open surgery owing to its rapidity and minimally invasive nature,

avoiding general anesthesia and aortic clamping, resulting in less morbidity and faster restoration of blood flow to the pelvis and lower limbs. Limited data suggest that outcomes from endovascular procedures are generally better compared with those from open surgery in cases of AOAA with SCI, especially when they are performed promptly after symptom onset. Triantafyllopoulos et al<sup>3</sup> reported a case of a 56-year-old man with flaccid paraplegia and lower limb ischemia treated by embolectomy, he did not survive a revascularization syndrome. Bolduc et al<sup>4</sup> described two patients with AOAA and painless paraplegia owing to SCI; both were treated with open aortic reconstruction, resulting in one death and one case of permanent paraplegia. Meagher et al<sup>2</sup> reported poor outcomes in seven of eight patients with AOAA and SCI, mainly owing to delayed diagnosis, with a mean delay from presentation of symptoms to diagnosis of >24 hours. Five patients died, two survived, one had permanent paraplegia, and one underwent lower limb amputation. The only patient who had a complete recovery had the shortest diagnostic delay (2 hours and 15 minutes).

In contrast, Azzarone et al<sup>5</sup> and Leiderman et al<sup>6</sup> reported also reported successful outcomes following endovascular treatment. Thromboaspiration or mechanical thrombectomy was not considered owing to the extensive nature of the thrombus and the risk of embolization; a covered stent provided immediate restoration of blood flow and minimized the embolic risk. Analysis of the CT scan on a three-dimensional workstation is performed to select the shortest stent graft to avoid extensive coverage of aortic collaterals such as the iliolumbar arteries or the inferior mesenteric artery. An SCI prevention protocol monitored in intensive care unit must be started as soon as possible, including maintaining a (I)



**Fig 2.** Brief algorithm aiming to distinguish aortic occlusion vs other causes of spinal paraparesis. *CT*, computed tomography.

mean arterial pressure of  $\geq 90$  mm Hg, (2) a hemoglobin level of  $\geq 10.0$  g/dL, and (3)  $SpO_2$  of  $\geq 95$ , eventually associated with cerebrospinal fluid drainage and anti-inflammatory medications. This protocol is not beneficial in patients with AOAA without SCI, where the neurological symptoms are caused by lower limbs ischemia.

## CONCLUSIONS

Flaccid paraplegia without associated lower limb pain may be the only early symptom of acute abdominal aortic occlusion, a condition with high morbidity and mortality rates. Vascular examination should be conducted promptly to avoid delayed diagnosis and immediate referral to a vascular surgery unit. Our case demonstrates that rapid endovascular aortic revascularization, mostly to restore flow to the pelvis and lower limbs, associated with a SCI prevention protocol, is critical to achieve a full recovery.

## DISCLOSURES

S.H. is a consultant and has IP with Cook Medical, GE Healthcare, and Bentley.

## REFERENCES

- Hines GL, Liu HH. Acute aortic occlusion and its sequelae: metabolic, pathologic etiology, and management. *Cardiol Rev*. 2021;29:57–61.
- Meagher AP, Lord RS, Graham AR, Hill DA. Acute aortic occlusion presenting with lower limb paralysis. *J Cardiovasc Surg*. 1991;32:643–647.
- Triantafyllopoulos GK, Athanassacopoulos M, Maltezos C, Pneumaticos SC. Acute infrarenal aortic thrombosis presenting with flaccid paraplegia. *Spine*. 2011;36:E1042–E1045.
- Bolduc ME, Clayson S, Madras PN. Acute aortic thrombosis presenting as painless paraplegia. *J Cardiovasc Surg*. 1989;30:506–508.
- Azzarone M, De Troia A, Iazzolino L, Nabulsi B, Tecchio T. Hybrid treatment of acute abdominal aortic thrombosis presenting with paraplegia. *Ann Vasc Surg*. 2016;33:228.e5–228.e8.
- Leiderman DBD, Wolosker N, Vieira de Melo Oliveira M, et al. Paraplegia of lower limbs caused by a segmental thrombosis of the descending thoracic aorta reversed with endovascular treatment—A case report and literature review. *Ann Vasc Surg*. 2018;50:300.e5.
- Locatelli F, Nana P, Le Houérou T, et al. Spinal cord ischemia rates and prophylactic spinal drainage in patients treated with fenestrated/branched endovascular repair for thoracoabdominal aneurysms. *J Vasc Surg*. 2023;78:883–891.
- Ohira S, Lansman SL, Spielvogel D. Collateral network concept in 2023. *Ann Cardiothorac Surg*. 2023;12:450–462.
- Iliopoulos JI, Howanitz PE, Pierce GE, Kueshkerian SM, Thomas JH, Hermreck AS. The critical hypogastric circulation. *Am J Surg*. 1987;154:671–675.

Submitted Jun 20, 2024; accepted Aug 30, 2024.