



HAL
open science

Multiple congenital anomalies in two fetuses with glutathione-synthetase deficit (GSS)

Jeanne Jury, Jean-françois Benoist, Madeleine Joubert, Chloé Quelin, Thomas Besnard, Solène Conrad, Claudine Le Vaillant, Stéphane Bézieau, Bertrand Isidor, Tania Attié-bitach, et al.

► To cite this version:

Jeanne Jury, Jean-françois Benoist, Madeleine Joubert, Chloé Quelin, Thomas Besnard, et al.. Multiple congenital anomalies in two fetuses with glutathione-synthetase deficit (GSS). *Clinical Genetics*, 2024, 106 (6), pp.776 - 781. 10.1111/cge.14613 . hal-04907793

HAL Id: hal-04907793

<https://hal.science/hal-04907793v1>

Submitted on 23 Jan 2025

HAL is a multi-disciplinary open access archive for the deposit and dissemination of scientific research documents, whether they are published or not. The documents may come from teaching and research institutions in France or abroad, or from public or private research centers.


L'archive ouverte pluridisciplinaire **HAL**, est destinée au dépôt et à la diffusion de documents scientifiques de niveau recherche, publiés ou non, émanant des établissements d'enseignement et de recherche français ou étrangers, des laboratoires publics ou privés.



Distributed under a Creative Commons Attribution - NonCommercial - NoDerivatives 4.0 International License

SHORT REPORT

Multiple congenital anomalies in two fetuses with glutathione-synthetase deficit (GSS)

Jeanne Jury¹ | Jean-François Benoist^{2,3}  | Madeleine Joubert⁴ | Chloé Quelin⁵ |
 Thomas Besnard^{1,6} | Solène Conrad¹ | Claudine Le Vaillant⁷ |
 Stéphane Bézieau^{1,6} | Bertrand Isidor^{1,6} | Tania Attié-Bitach^{8,9,10} |
 Benjamin Cogné^{1,6,10} | Marie Vincent^{1,6}

¹Service de Génétique médicale, Nantes Université, CHU de Nantes, Nantes, France

²Laboratoire de Biochimie Métabolique, Hôpital Necker-Enfants-Malades, AHPH, Paris, France

³CEA, INRAE, DMTS, SPI, MetaboHUB-IDF, Université Paris-Saclay, Gif-sur-Yvette, France

⁴Unité de Fœtopathologie et Génétique, CHU de Nantes, Nantes, France

⁵Service de Génétique Clinique, CLAD Ouest, CHU Rennes, Hôpital Sud, Rennes, France

⁶l'institut du thorax, Nantes Université, CHU de Nantes, CNRS, INSERM, Nantes, France

⁷Service de Gynécologie et Obstétrique, CHU Nantes, Nantes, France

⁸Imagine Institute, INSERM UMR1163, Paris, France

⁹Service de Médecine Génomique des Maladies Rares, Hôpital Necker-Enfants Malades, Assistance Publique-Hôpitaux de Paris, Faculté de Médecine, Université de Paris Cité, Paris, France

¹⁰Laboratoire SeqOIA (PFMG 2025), Paris, France

Correspondence

Marie Vincent, Service de génétique médicale, CHU de Nantes, 1 Place Alexis Ricordeau, 44093 Nantes, France.

Email: marie.vincent@chu-nantes.fr

Abstract

Glutathione synthetase deficiency is a rare inborn metabolic disease usually caused by biallelic variants in *GSS*. Clinical severity varies from isolated hemolytic anemia, sometimes associated with chronic metabolic acidosis and 5-oxoprolinuria, to severe neurological phenotypes with neonatal lethality. Here we report on two fetal siblings from two pregnancies with glutathione synthetase deficiency exhibiting similar multiple congenital anomalies associating phocomelia, cleft palate, intra-uterine growth retardation, genito-urinary malformations, and congenital heart defect. Genome sequencing showed that both fetuses were compound heterozygous for two *GSS* variants: the previously reported pathogenic missense substitution NM_000178.4 c.800G>A p.(Arg267Gln), and a 2.4 kb intragenic deletion NC_000020.11:g.34944530_34946833del. RNA-seq on brain tissue revealed the out-of-frame deletion of the exon 3 and an almost monoallelic expression of the missense variant (88%), suggesting degradation of the deletion-harboring allele by nonsense-mediated mRNA decay. 5-oxoprolin (pyroglutamic acid) levels in amniotic fluid were elevated, suggesting an alteration of the gamma-glutamyl cycle, and corroborating the pathogenicity of the two *GSS* variants. Only one case of glutathione synthetase deficiency with limb malformations has previously been reported, in a newborn homozygous for the c.800G>A variant. Thus, our data allow us to discuss a potential phenotypic extension of glutathione synthetase deficiency, with a possible involvement of the c.800G>A variant.

KEYWORDS

fetal, glutathione synthetase deficiency, GS, GSS, multiple congenital anomalies, RNA-seq

1 | INTRODUCTION

GSS encodes the glutathione synthetase enzyme, allowing the formation of glutathione through the gamma-glutamyl cycle. Glutathione is

a ubiquitous tripeptide, consisting of glutamate, cysteine, and glycine, with antioxidant properties, involved in numerous fundamental metabolic pathways. Glutathione synthesis occurs in the gamma-glutamyl cycle. Biallelic variants in *GSS* are known to cause glutathione

This is an open access article under the terms of the [Creative Commons Attribution-NonCommercial-NoDerivs](https://creativecommons.org/licenses/by-nc-nd/4.0/) License, which permits use and distribution in any medium, provided the original work is properly cited, the use is non-commercial and no modifications or adaptations are made.

© 2024 The Author(s). *Clinical Genetics* published by John Wiley & Sons Ltd.

synthetase deficiency (GSD; OMIM #266130, OMIM #231900), an inborn metabolic disease of variable severity, characterized by hemolytic anemia. This can be isolated in the mildest cases, usually without clinical repercussions. In moderate cases, hemolytic anemia is associated with urinary excretion of 5-oxoproline and with chronic metabolic acidosis, which begins shortly after birth.

Among the most severe cases, metabolic acidosis can result in early death from respiratory failure if left untreated or severe infections. Other cases can also develop progressive neurologic involvement, such as seizures, ataxia, global developmental delay and intellectual disability.¹

We present two fetal siblings from two pregnancies with GSD and severe multiple congenital anomalies. They both presented with intra-uterine growth retardation (IUGR), unilateral or bilateral phocomelia, suspicion of congenital heart defect (CHD), cleft palate, and genito-urinary anomalies in one case, with dysplastic kidneys, unicornuate uterus and tubal agenesis.

2 | MATERIALS AND METHODS

2.1 | Clinical data

Both cases were fetuses from two distinct pregnancies of the same couple, referred to Nantes hospital, in a context of recurrent multiple congenital anomalies. Written consent was obtained from the parents for medical termination of pregnancy, fetal autopsy, molecular genetic analysis, and publication of the clinical and molecular findings. Data were provided by individual physician coauthors in accordance with local research and ethics requirements.

2.2 | Molecular data

Genome sequencing (GS) was performed in quatuor (two fetuses and both parents). Parental DNA was extracted from blood samples, while fetal DNA was obtained from fetal tissue. (Figure 1A) Sequence data were aligned to the reference genome GRCh38.92 using BWA-MEM (0.7.15). Mean depth was 46.1X and genomic coverage $\geq 15X$ was 96.6%. Single nucleotide variations and delins < 50 pb were detected by GATK (4.1.7.0) and annotated using SnpEff (4.3t) and SnpSift (4.3t). Copy number variants were detected using CNVnator (v0.4.1) and annotation was performed using AnnotSV (v2.5.1).

RNA was extracted from a frozen fetal brain sample with the Nucleospin RNA plus kit (Macherey-Nagel). cDNA was synthesized using the SureSelect cDNA module (Agilent Technologies). RNA-seq library was prepared on the MAGNIS NGS Prep System (Agilent Technologies) using the SureSelect XT-HS1 protocol (human all exon v8). Libraries were sequenced on NextSeq550 (Illumina) generating 25 million 2×75 bp reads. Fastq files were aligned on the human genome GRCh38 (Ensembl transcript 106) with STAR (v.2.7.11a).

2.3 | Biochemical data

The levels of pyroglutamic acid in the preserved frozen amniotic fluid of fetus 1 were measured by gas chromatography–mass spectrometry (GC–MS), and compared with three control samples from fetuses of the same gestation age with normal levels of pyroglutamic acid (15, 28, and 20 μM). The quality of amniotic fluid preservation was assessed by amino-acid chromatography analysis, which was unremarkable.

3 | RESULTS

3.1 | Clinical data

The unrelated French parents of the fetuses are both healthy with no remarkable family history (Figure 1A). At the time of each pregnancy, the mother was respectively 27 and 29 years old and the father was respectively 26 and 28 years old. There were no reported toxic exposures and there was no maternal diabetes during either pregnancy.

3.1.1 | Fetus 1

Fetus 1 presented with a nuchal translucency of 3 mm on the first trimester ultrasound (US). Follow-up at 17 weeks of gestation (WG) revealed oligoamnios, pyelic dilatation with dysplastic kidneys, intra uterine growth retardation (IUGR), short rachis, atrio-ventricular canal defect, and omphalocele. Only one of the lower limbs was assessed well and had a short femur. The other lower limb was not seen. The couple requested medical termination of pregnancy (TOP) at 18 WG due to the severity and complexity of the affection. Karyotype analysis on amniotic fluid revealed a maternally inherited balanced Robertsonian translocation 45,XX, der(13;14)(q10;q10).

Fetus 1 underwent fetal examination at 18 WG (Figure 1B). All biometric measurements showed IUGR with small occipitofrontal circumference (OFC), around 15–16 WG. Macroscopic examination revealed a small omphalocele, overlapping of skull bones with turricephaly, and slight dysmorphic facial features including hypertelorism, low-set ears, short nose with anteverted nostrils, and thin lips. She presented with a large cleft palate associated with retrognathism and glossoptosis, suggesting Pierre Robin sequence. Lower limb anomalies were characterized as right lower phocomelia and a short incurved left femur. Both upper limbs were amyotrophic with armpit pterygia, suggesting fetal akinesia without malformations. Hands and feet displayed no anomalies. X-Rays showed a bone age of around 16 WG, confirmed unilateral right phocomelia and a short curved V-shaped left femur without other skeletal anomalies.

Microscopic examination revealed pulmonary hypoplasia, bilateral hypoplastic dysplastic kidneys with glomerular and tubular microcysts, a left unicornuate uterus with right tubal agenesis.

3.1.2 | Fetus 2

Fetus 2 presented at 12 WG with increased nuchal translucency of 10 mm, with generalized lymphedema, probable atrioventricular canal defect, cephalic pole anomaly suggestive of holoprosencephaly,

abnormal angulation of the spine, bilateral lower limb phocomelia, bilateral upper limb malformations suggestive of radial ray anomaly, and fetal akinesia. Karyotype analysis at 12 WG on chorionic villi showed free and homogeneous trisomy 21. The couple thus requested medical TOP at 14 WG.

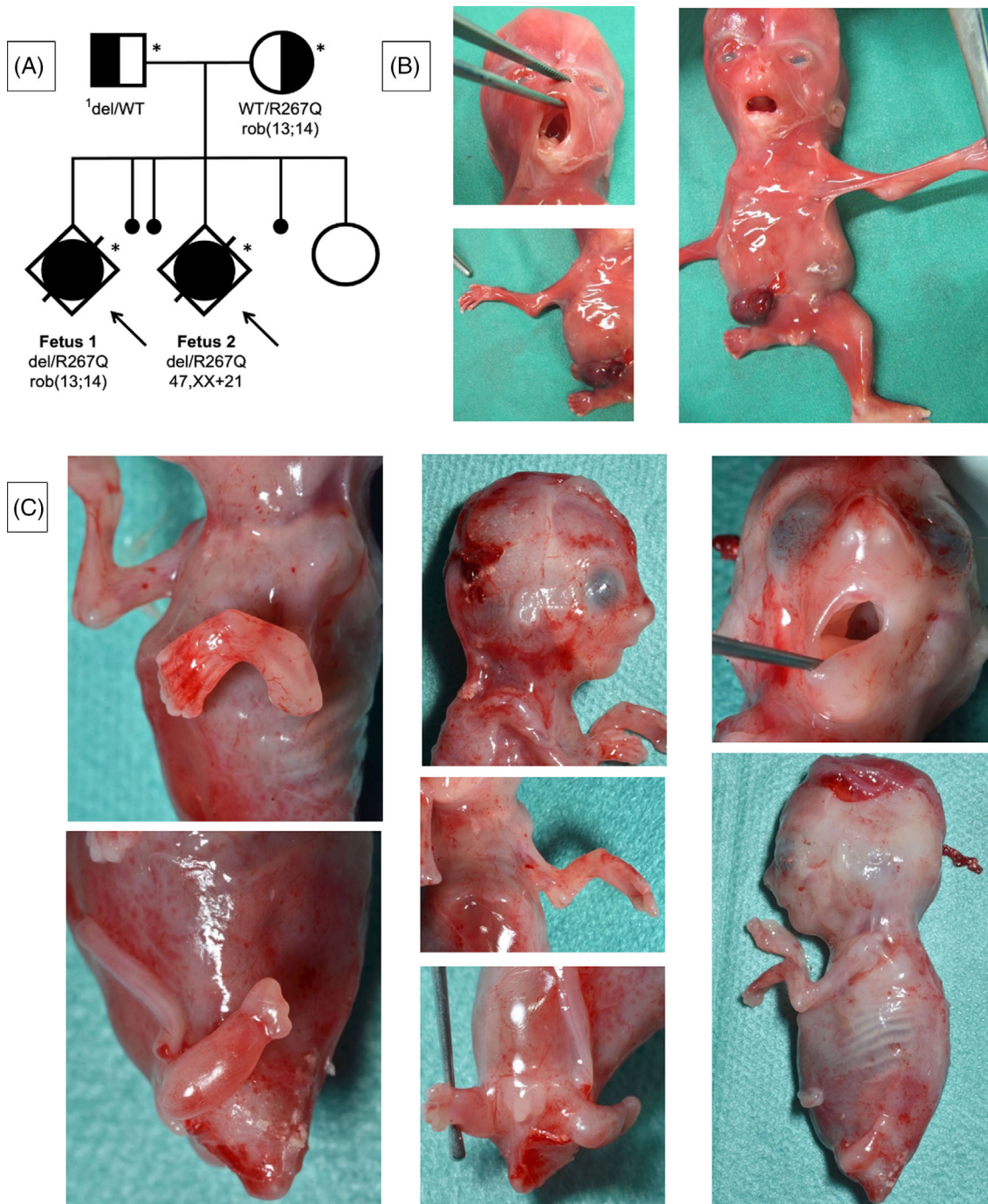


FIGURE 1 Clinical data. (A) Pedigree and molecular findings. ¹del = del(20)(q11.22)NC_000020.11:g.34944530_34946833. (B) Fetus 1 (18 WG). Large cleft palate, glossoptosis and micrognathia, suggesting Pierre Robin sequence. Slight dysmorphic facial characteristics: Hypertelorism, low-set ears, short nose with anteverted nostrils, and thin lips. Bilateral arm pterygium. Omphalocele. Right lower limb phocomelia with normal foot. Short left femur. (C) Fetus 2 (14 WG). Large cleft palate and micrognathia. Protruding eyes. Bilateral radial ray defect with normal hands. Bilateral lower limb phocomelia with oligosyndactyly.

Fetus 2 underwent fetal examination at 14 WG (Figure 1C). All biometric measurements showed IUGR with small OFC (around 12 WG). Macroscopic examination confirmed bilateral lower phocomelia with oligodactyly (4 right toes and 3 left toes) and complete syndactyly. Both elbows were stiff with pterygia. The left upper limb exhibited forearm shortening characterized on x-rays by a single forearm bone associated with a short first metacarpal. She presented with a large cleft palate with retrognathia. External genitalia were female, with no visible abnormality at this stage. Microscopic examination showed a hypotrophic heart which was impossible to dissect, like all other organs.

The couple also had three early miscarriages and a full-term pregnancy giving birth to a girl with unilateral renal agenesis and no other congenital anomalies nor developmental delay.

3.2 | Genetic analysis

CMA analysis on DNA extracted from fetal tissue was unremarkable in the two fetuses, except for the known trisomy 21 in fetus 2.

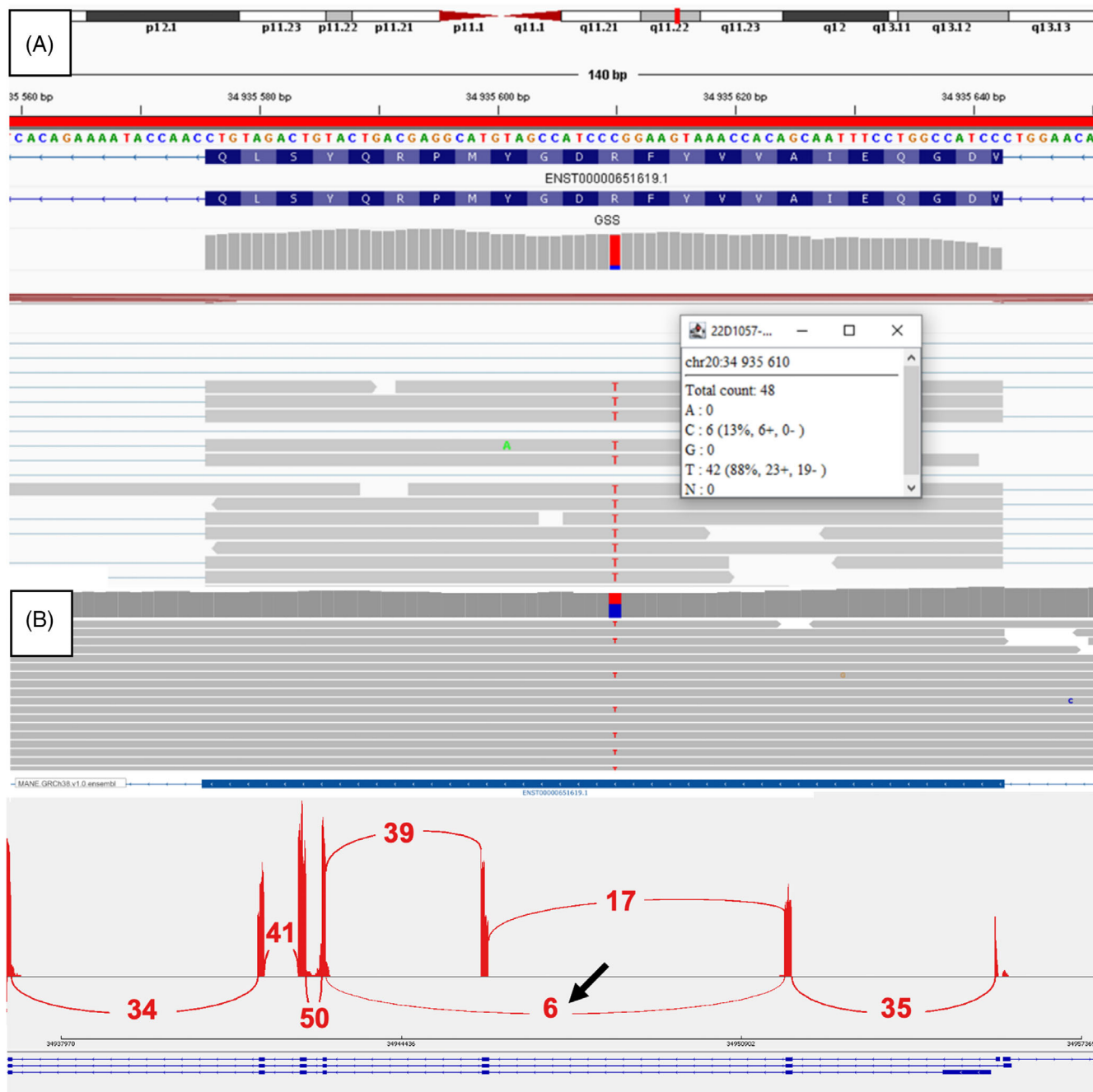


FIGURE 2 Molecular data. (A) RNA-seq BAM data showing 88% expression of the missense variant. (B) Sashimi plot showing RNA-seq results from brain tissue, black arrow showing exon 3 deletion.

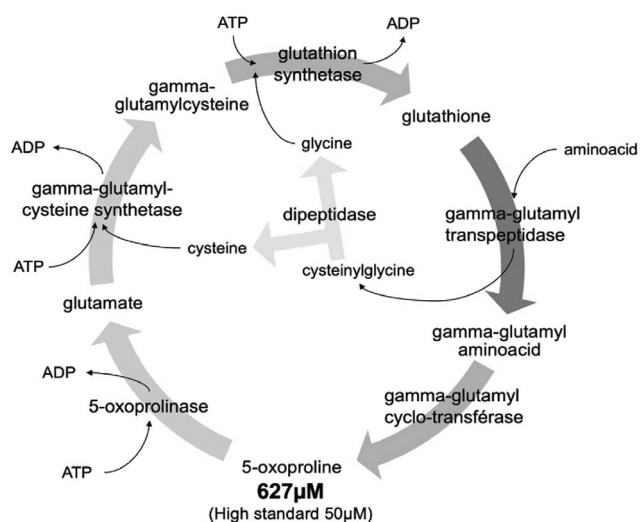


FIGURE 3 Gamma-glutamyl cycle representation showing elevated 5-oxoproline levels.

Genome sequencing analysis in quatuor revealed in both fetuses a maternally inherited missense variant NM_000178.4(GSS):c.800G>A p.(Arg267Gln), previously described as pathogenic, as well as a paternally inherited intragenic deletion of 2.4 kb, seq[GRCh38] del(20)(q11.22) NC_000020.11:g.34944530_34946833 leading to the deletion of the exon 3, paternally inherited (Figure 1A). No other variants in genes responsible for multiple congenital anomalies, and in particular limb anomalies, could be found.

RNA sequencing (RNA-seq) on brain tissue showed the out-of-frame deletion of the exon 3 and an almost monoallelic expression of the missense variant (88%), suggesting degradation of the deletion-harboring allele by nonsense-mediated mRNA decay (NMD) (Figure 2).

3.3 | Biochemical analysis

Pyroglutamic acid (or 5-oxoproline) levels in amniotic fluid of fetus 1 were 627 μ M for a high standard of 50 μ M, indicating a disruption of the gamma-glutamyl cycle, and compatible with a downstream enzyme deficiency (Figure 3). This analysis was not carried out in fetus 2, due to lack of amniotic fluid sample, nor in the heterozygous parents, in whom levels are generally normal.¹ Total glutathione was not determined, because it could have been artificially lowered due to the age of the amniotic fluid.

4 | DISCUSSION

Here we report two fetal cases of GSD presenting with a complex association of multiple congenital anomalies.

Exhaustive genetic analyses (karyotype, CMA, and GS) did not show any obvious cause for the polymalformative syndrome. The

balanced translocation in fetus 1 is inherited and therefore does not contribute to the phenotype. Trisomy 21 in fetus 2 may have contributed to the lymphedema and CHD, but does not explain the overall severe phenotype. Indeed, trisomy 21 is known to be associated with short limb length but has no reported cases of phocomelia despite its high prevalence.

To our knowledge, this is the first description of fetal cases of GSD. Nonetheless, GSS is essential for embryonic development, as demonstrated by the lethality observed as early as embryonic day 7.5 in homozygous knockout mice.²

A review of the literature found a case of severe GSD in a newborn who was small for gestational age (birth weight, height, and OFC of 10th percentile), and who presented with respiratory distress, hypotonia, hemolytic anemia, severe metabolic acidosis and who died at day 14 of clinically suspected sepsis.³ He also had a unilateral femoral agenesis. Interestingly, this newborn was homozygous for the same missense variant c.800G>A p.(Arg267Gln). ES in trio revealed no known etiology for femoral agenesis.³

Another report mentioned the c.800G>A variant, with two siblings, compound heterozygous for c.800G>A and c.491G>A variants, who presented with a severe form with neurologic damage and brain MRI abnormalities, and who died at 2 months.⁴ The c.491G>A variant has been reported at a homozygous state in several cases of moderate GSD, whereas the associated phenotype can be severe in compound heterozygous patients with nonsense or frameshift variants, which may suggest a particularly deleterious aspect of the c.800G>A variant.^{5,6}

Correlation between GSS enzymatic activity and clinical phenotype has been investigated in one patient with a moderate phenotype of GSD including hemolytic anemia, and 9% residual GSS activity in fibroblasts.⁷ He was compound heterozygous for c.847C>T p.(Arg283Cys) and c.799C>T p.(Arg267Trp) variants; the second variant affects the same codon of our patients, in the reported case, it led to no detectable GSS enzymatic activity on cell lines.¹ Moreover, the codon 267 is part of the substrate binding site with gamma-glutamylcysteine and seems to play an important functional role in the enzymatic catalysis, with significant alterations of the GSS kinetic properties when this residue is altered.⁸

In our case, RNA-seq showed almost monoallelic expression of the missense variant, probably secondary to degradation of the allele with the intragenic deletion by NMD. It is a complementary analysis of interest which has shown benefits in terms of molecular diagnosis in the context of neurodevelopmental disorders, particularly for structural variants.⁹

In addition, biochemical studies proved useful in providing further evidence of the involvement of GSS in our cases. This illustrates the benefit of measuring biochemical parameters for rare variants in genes for which such a parameter is known and available.

Even though other cases of congenital malformations have not been formally correlated in GSD or other gamma-glutamyl cycle disorders, there are now at least 3 cases from 2 families of limb anomalies in patients with GSD involving the c.800G>A variant.¹⁰ However, the reported homozygous case for the c.800G>A variant presented with a

unilateral femoral agenesis, which is less severe than one could expect since our cases with 88% of RNA copies harboring the c.800G>A variant had bilateral phocomelia. Nevertheless, our data suggest a phenotypic extension of GSD and lead us to suspect a potential involvement of c.800G>A variant regarding malformations, especially limb anomalies, with a hypothetical neomorph phenomenon, which would require more evidence as a mechanism for the disorder. Nonetheless, variable expressivity may explain that the other compound heterozygous case with c.800G>A and a truncating variant did not exhibit any limb anomalies even though he had a severe form of GSD.⁴

This case also highlights the importance of high-throughput sequencing in nonspecific fetal multiple congenital anomalies and its complementarity with RNA-seq and with biochemical assays, to help confirm molecular results.

ACKNOWLEDGMENTS

The authors thank the family.

CONFLICT OF INTEREST STATEMENT

The authors declare no conflicts of interest.

PEER REVIEW

The peer review history for this article is available at <https://www.webofscience.com/api/gateway/wos/peer-review/10.1111/cge.14613>.

DATA AVAILABILITY STATEMENT

The data that support the findings of this study are available from the corresponding author upon reasonable request.

ORCID

Jean-François Benoist  <https://orcid.org/0000-0002-5389-8585>

REFERENCES

1. Shi Z-Z, Habib GM, Rhead WJ, et al. Mutations in the glutathione synthetase gene cause 5-oxoprolinuria. *Nat Genet.* 1996;14:361-365.
2. Winkler A, Njålsson R, Carlsson K, et al. Glutathione is essential for early embryogenesis—analysis of a glutathione synthetase knockout mouse. *Biochem Biophys Res Commun.* 2011;412:121-126.
3. Guney Varal I, Dogan P, Gorukmez O, Dorum S, Akdag A. Glutathione synthetase deficiency: a novel mutation with femur agenesis. *Fetal Pediatr Pathol.* 2020;39:38-44.
4. Qiuping Y, Zhaoyuan T, Qiuping Yang ZQ. 谷胱甘肽合成酶缺乏症并文献复习. *中华妇幼临床医学杂志(电子版).* 2021;17(425):425-430.
5. Li X, Ding Y, Liu Y, et al. Five Chinese patients with 5-oxoprolinuria due to glutathione synthetase and 5-oxoprolinase deficiencies. *Brain Dev.* 2015;37:952-959.
6. Wu X, Jiao J, Xia Y, et al. Case report: a Chinese patient with glutathione synthetase deficiency and a novel glutathione synthase mutation. *Front Pediatr.* 2023;11:1212405.
7. Njålsson R, Ristoff E, Carlsson K, Winkler A, Larsson A, Norgren S. Genotype, enzyme activity, glutathione level, and clinical phenotype in patients with glutathione synthetase deficiency. *Hum Genet.* 2005;116:384-389.
8. Njålsson R, Carlsson K, Olin B, et al. Kinetic properties of missense mutations in patients with glutathione synthetase deficiency. *Biochem J.* 2000;349:275-279.
9. Riquin K, Isidor B, Mercier S, et al. Integrating RNA-Seq into genome sequencing workflow enhances the analysis of structural variants causing neurodevelopmental disorders. *J Med Genet.* 2023;61:47-56.
10. Polekhina G, Board PG, Gali RR, Rossjohn J, Parker MW. Molecular basis of glutathione synthetase deficiency and a rare gene permutation event. *EMBO J.* 1999;18:3204-3213.

How to cite this article: Jury J, Benoist J-F, Joubert M, et al. Multiple congenital anomalies in two fetuses with glutathione-synthetase deficit (GSS). *Clinical Genetics.* 2024; 106(6):776-781. doi:10.1111/cge.14613