



HAL
open science

Uterine haemangiosarcoma of a spayed female dog

Inès Khemri, Catherine Layssol-Lamour, Mallaurie Penent, Rafael Bernardes,
Hanna Mila

► **To cite this version:**

Inès Khemri, Catherine Layssol-Lamour, Mallaurie Penent, Rafael Bernardes, Hanna Mila. Uterine haemangiosarcoma of a spayed female dog. European Veterinary Society for small animal reproduction (EVSSAR), Jun 2024, Barcelone, Spain. hal-04888590

HAL Id: hal-04888590

<https://hal.science/hal-04888590v1>

Submitted on 15 Jan 2025

HAL is a multi-disciplinary open access archive for the deposit and dissemination of scientific research documents, whether they are published or not. The documents may come from teaching and research institutions in France or abroad, or from public or private research centers.

L'archive ouverte pluridisciplinaire **HAL**, est destinée au dépôt et à la diffusion de documents scientifiques de niveau recherche, publiés ou non, émanant des établissements d'enseignement et de recherche français ou étrangers, des laboratoires publics ou privés.

Uterine haemangiosarcoma of a spayed female dog



Inès Khemri¹, Catherine Layssol-Lamour², Mallaurie Penent², Rafael Bernardes² and Hanna Mila¹
¹NeoCare, ENVt, Université de Toulouse, France; ²Ecole Nationale Vétérinaire de Toulouse, Toulouse, France.

Introduction. Canine haemangiosarcoma (HSA) is a common malignant tumor of endothelial cells of blood vessels. Although angiosarcomas can arise in any region of the body (most frequently in the liver, heart, spleen, and skin) it is rarely observed in the genital tract in animals or humans. Only a few cases of haemangiosarcoma were reported in the dog, with tumors localized in the vulva and vagina.

Case presentation.

A 6-year-old spayed border collie female dog spayed at 1 year of age was presented for vulvar hemorrhagic discharge that had been occurring for two weeks.

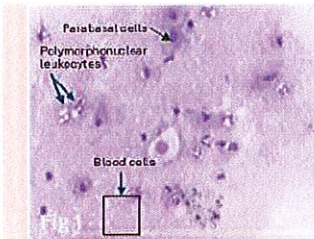
Physical examination.

It revealed a palpable and painful abdominal mass in the caudal region of the right abdomen. A digital vaginal examination showed no abnormalities.

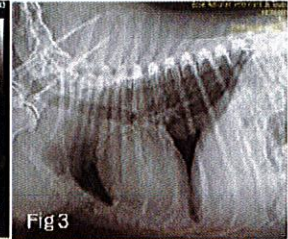
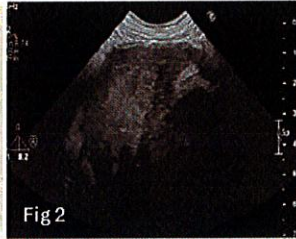
Differential diagnosis.

- Reproductive tract disorders: ovarian remnant syndrome, vaginitis, vaginal or vestibular mass, vascular ectasia
- Urinary tract disease
- Coagulopathy
- Foreign body

Complementary exams.



VARIABLE	RESULTS	AVERAGE
White blood cells (x10 ³ /μL)	19,80	3,88-14,57
Segmented neutrophils (x10 ³ /μL)	17,42	2,1-11,2
Lymphocytes (x10 ³ /μL)	0,93	0,78-3,39
Monocytes (x10 ³ /μL)	1,26	0-1,2
Eosinophils (x10 ³ /μL)	0,15	0-1,2
Basophils (x10 ³ /μL)	0,01	0-0,13
Hematocrit (%)	31,5	37,5-60,3
Hemoglobin (g/dL)	10,4	14,1-20,1
Platelets (x10 ³ /μL)	355	127-395



Vaginal cytology

- Parabasal cells
- Blood cells
- Polymorphonuclear leukocytes
- No bacteria

Hemogram and biochemistry

- Mild normocytic regenerative anemia
- Neutrophilic leukocytosis
- Lymphopenia
- PT/APTT were within normal limits

Abdominal ultrasonography

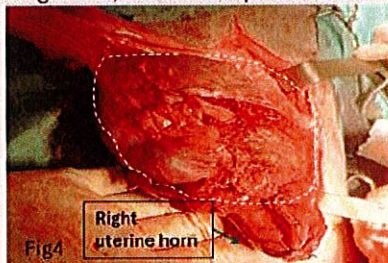
- Large heterogeneous, cavitory mass was seen at the tip of the right uterine horn.
- A discrete peritoneal effusion was also detected

Thoracic radiography

- Absence of distant metastasis

Management and follow-up.

Surgical excision of the uterus and histopathological examination were performed (Fig 4). Histopathological analysis revealed a hemangiosarcoma of the uterus, which was confirmed using immunohistochemical endothelial markers CD31 (Fig5). By the 2-month follow-up, the dog showed anorexia and lethargy with a hemorrhagic vulvar discharge. Thus, the owners opted for euthanasia.



Histopathological examination.

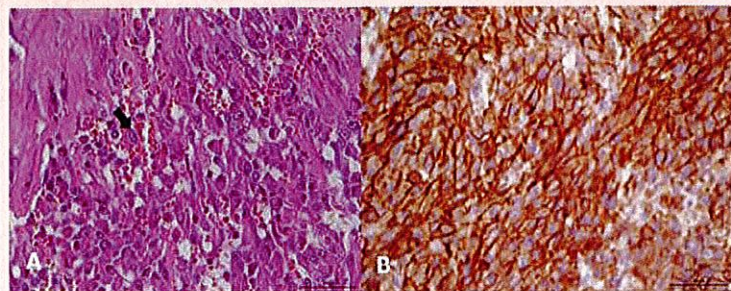


Fig5 A: The neoplasm is composed of pleomorphic spindle cells that form numerous irregular blood-filled vascular channels. Neoplastic cells have oval to irregular nuclei with finely stippled chromatin and one or more prominent nucleoli (arrows). **B:** Immunohistochemical expression of endothelial marker CD31. Tumor cells are strongly positive for CD31.

Discussion and conclusion.

HSAs are malignant tumors of vascular endothelial cells. In the current case, the histomorphological findings such as marked anisocytosis, anisonucleosis and irregular vascular canals surrounded by polymorphic neoplastic cells confirmed the tumor as HSA. No breed predisposition was specified in the literature [1]. Some studies suggest that neutering may be associated with an increased risk of splenic and cardiac haemangiosarcoma in the dog [1]. Spayed female dogs have 5 times more risk of HSA than intact females [2], studies suggested, cells that become sensitive to estrogen as a result of multiple cycles may undergo neoplastic transformation with the disappearance of the protective effect of estrogen after sterilization. Thus, the diagnosis of uterine haemangiosarcoma should be included in the differential list of causes for vaginal bleeding including in spayed female dogs [3]. Etiological factors predisposing to haemangiosarcoma are thus poorly understood and require further investigation.

[1] Clendaniel DC, Sivacolurthu RK, Sorenmo KU, Denovon TA, Turner A, Arcozzi T, et al. Association between macroscopic appearance of liver lesions and liver histology in dogs with splenic hemangiosarcoma: 79 cases (2004–2009). *J Am Anim Hosp Assoc* 2014; 50: e9–s10.
[2] Ware WA, Hooper DL. Cardiac tumors in dogs: 1982–1995. *J Vet Intern Med* 1999; 13: 95–103.
[3] Torres da Silva G, Hart BL, Forver TB, Oberbauer AM, McV Messam LL, Willits N, et al. Neutering dogs: Effects on joint disorders and cancers in golden retrievers. *PLoS One* 2013; 8: e55937.

