



**HAL**  
open science

# A constriction geometry analysis of place contrasts in Malayalam nasals

Alexei Kochetov, Pierre Badin

► **To cite this version:**

Alexei Kochetov, Pierre Badin. A constriction geometry analysis of place contrasts in Malayalam nasals. ISSP 2024 - 13th International Seminar on Speech Production, Cécile Fougeron; Pascal Perrier, May 2024, Autrans, France. hal-04882225

**HAL Id: hal-04882225**

**<https://hal.science/hal-04882225v1>**

Submitted on 13 Jan 2025

**HAL** is a multi-disciplinary open access archive for the deposit and dissemination of scientific research documents, whether they are published or not. The documents may come from teaching and research institutions in France or abroad, or from public or private research centers.

L'archive ouverte pluridisciplinaire **HAL**, est destinée au dépôt et à la diffusion de documents scientifiques de niveau recherche, publiés ou non, émanant des établissements d'enseignement et de recherche français ou étrangers, des laboratoires publics ou privés.



Distributed under a Creative Commons Attribution 4.0 International License

# A constriction geometry analysis of place contrasts in Malayalam nasals

Alexei Kochetov<sup>1,2</sup>, Pierre Badin<sup>2</sup>

<sup>1</sup>*Dept. of Linguistics, Univ. of Toronto, Toronto, Canada*

<sup>2</sup>*Univ. Grenoble Alpes, CNRS, Grenoble INP, GIPSA-lab, Grenoble, France*

al.kochetov@utoronto.ca, Pierre.Badin@gipsa-lab.grenoble-inp.fr

## Abstract

*This study examines the constriction geometry of a typologically rare 6-way place contrast in Malayalam nasals. This is done using static MRI data obtained from two speakers. The measures of tongue constriction angle (higher for more posterior places) and tongue constriction length (higher for laminals and dorsals) were found to provide a relatively good characterization of the contrast. Altogether, all pairs of consonants were statistically distinguished by a combination of these variables except for the dental vs. alveolar contrast (and two other pairs for one of the speakers). The nasal consonants were realized as apico-laminal dental /ɲ/, apical alveolar /n/, laminal alveolar or alveopalatal /ɲ/, subapical palatal (retroflex) /ɲ/, fronted velar /ŋ/ and (plain) velar /ŋ/. This is largely consistent with previous phonetic descriptions of the sounds and earlier palatographic data available for coronals. Finally, the results for dental and retroflex nasals are compared to similar consonants in Kannada (another Dravidian language), pointing to potential language-particular differences in the realization of the contrast.*

**Keywords:** *speech production, place contrasts, nasals, MRI, Malayalam*

## 1. Introduction

Malayalam (Dravidian) exhibits a typologically unusual 6-way place of articulation contrast in lingual nasal consonants (Kumari 1972; Asher & Kumari 1997; Namboodiripad & Garellek 2017). As illustrated in Table 1, the contrast involves a series of nasals that are traditionally described as dental, alveolar, retroflex, (alveolo)palatal, and two velars – palatalized and plain. How exactly this complex set of contrasts is distinguished by speakers, however, is unclear.

**Table 1:** *Place contrasts in Malayalam lingual nasals.*

Place	Word	Gloss
dental	paɲ:i	<i>pig</i>
alveolar	kan:i	<i>a month</i>
retroflex	kaɲ:i	<i>link</i>
(alveolo)palatal	kaɲ:i	<i>gruel</i>
palatalized velar	mat:anɲ:a	<i>pumpkin</i>
(plain) velar	taɲ:i	<i>held fast</i>

The only previous articulatory investigation of a subset of these consonants, the coronals /ɲ, n, ɲ, ɲ/, was conducted by Dart & Nihalani (1999). Based on static palatograms and linguograms obtained from nine speakers, the authors concluded that the four consonants could be classified into three rather than four places of articulation: denti-alveolar /ɲ/, alveolar /n/ and /ɲ/, and postalveolar for /ɲ/. Of note is their finding of a more anterior than expected production of /ɲ/, traditionally described as

(alveolo)palatal (e.g., Kumari 1972; Asher & Kumari 1997). The authors also observed that the consonants were differentiated by four constriction shapes: apical for /n/, apico-laminal for /ɲ/, apico-sublaminal for /ɲ/, and laminal for /ɲ/. In other words, the four-way contrast in Malayalam coronals was distinguished by a combination of the constriction location (/ɲ/ > /n/, /ɲ/ > /ɲ/) and the spatial extent of the constriction (being minimal for apicals and maximal for (sub)laminals).

In this study we examine the constriction geometry of Malayalam nasals using static MRI data from two speakers. In doing this, we are expanding on the tongue tip constriction angle method proposed by Proctor, Bundgaard-Nielsen, Best, Goldstein, Kroos, & Harvey (2010), designed to model a 4-way coronal contrast in Wubuy, an Australian Aboriginal language. In that study, the contrast between laminal dental, apical alveolar, apical retroflex, and laminal alveopalatal was defined as a series of spatial tongue tip/body targets as angles along a polar grid line of the vocal tract, from the upper teeth to the pharynx, spanning a range of 140°.

We recently adapted this approach to capture the dental-retroflex contrast in Kannada (Dravidian), using static MRI recorded from two speakers (Kochetov, Savariaux, Lamalle, Noël, & Badin 2024). The results showed that – among stops, nasals, and laterals – the contrast was clearly distinguished by smaller angles (more posterior constrictions) for retroflexes compared to dentals. For example, the dental nasal /ɲ/ in the /a\_a/ context was produced by the two speakers with a constriction at 156° or 157°, while the angle for the retroflex /ɲ/ was 130° or 126°, respectively. In addition, there were constriction length differences, with higher values for laminals and subapicals compared to apicals (with the types varying by both place and manner).

Unlike Kannada, which has only two coronal and one velar nasal, the set of relevant consonants in Malayalam is considerably larger. It thus remains to be seen whether the tongue constriction angle method is applicable to the complex set of contrasts in Malayalam nasals.

## 2. Methods

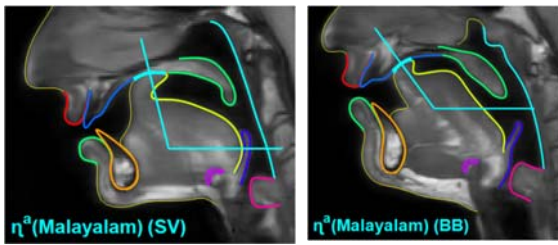
### 2.1. Speakers, procedure, and materials

Single slice mid-sagittal MRI static images were recorded for two native speakers of Malayalam (SV, female; BB, male; both from Thiruvananthapuram, Kerala, India) with a Philips Achieva 3.0T dStream scanner using a 20-channel head-neck coil in Turbo Spin Echo mode. The speakers were asked to produce the nasals /ɲ, n, ɲ, ɲ, ɲ/ in five symmetric V\_V contexts: /a\_a/, /i\_i/, /u\_u/, /e\_e/, and /o\_o/ (e.g., [aɲa], [iɲi], [uɲu], [eɲe], [oɲo]). They did it three times in a row, first producing the VCV word twice naturally and then repeating it again and sustaining the articulation of the consonant for about 6.5 seconds. The MRI recordings were taken during the sustained articulation phase. This resulted in a total of 60 images of target consonants (6 consonants x 5 vowel contexts x

1 repetition x 2 speakers). The data were collected as part of a larger corpus of Malayalam sounds.

## 2.2. Segmentation and tongue constriction geometric characteristics

Semi-automatic segmentation of the main speech articulators from the MRI images was performed according to Labrunie, Badin, Voit, Joseph, Frahm, Lamalle, Vilain, & Boë (2018). The contours were aligned with the hard palate and two variables were calculated (as in Kochetov *et al.* 2023): Tongue Constriction Location (TCL) and Length (TClength). An acoustic Low Frequency Impedance approximation (LFI) was computed for each VT tube as its length divided by the square of its cross-sectional distance. The center of the constriction was considered as the location upstream and downstream of which the cumulated LFIs are equal; TCL was expressed as the angle of this point in reference to the VT center. TClength was estimated as the length of a uniform tube with the same cumulated LFI as the tubes close to the constriction center having a cross-dimensional distance below a given threshold. The results of this procedure are illustrated in Figure 1, where the constriction limits are outlined by thicker cyan lines on the inner and outer walls, and the center of the constriction is marked by the radial line.



**Figure 1:** *Articulator contours superimposed on a midsagittal image of /ŋ/ in /aŋa/ by speakers SV and BB with the angle representing the constriction location measure.*

## 2.3. Statistical analysis

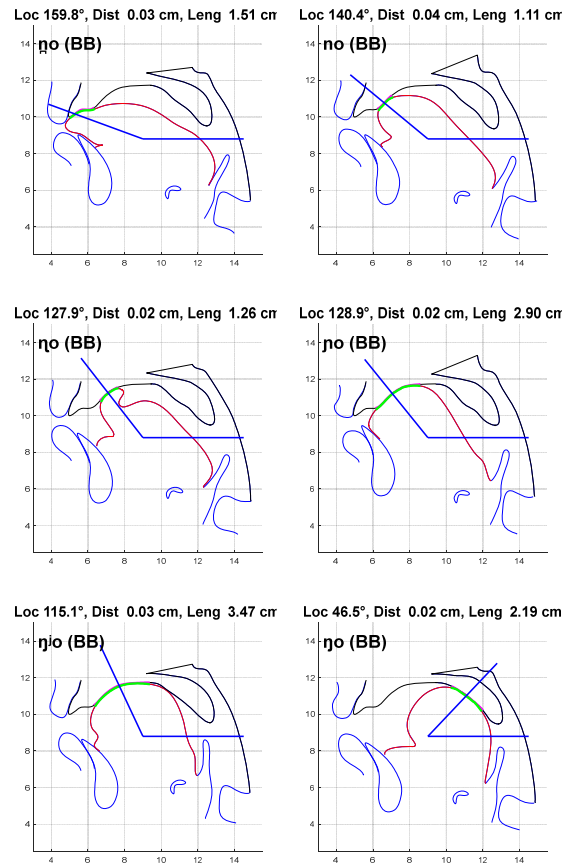
Although our dataset is relatively small, we chose to provide an exploratory statistical analysis of the data. This was done Linear Mixed Effects Regression (LMER) models with tongue constriction parameters TCL and TClength, separately for each speaker. Place (with 6 levels) was a fixed effect, while Vowel (with 5 levels) was a random effect (with random intercepts). The analysis was implemented with the *lme4* package (Bates *et al.* 2015) using *R* (Team, 2014). In each case, likelihood ratio tests were used to compare a full model to a nested model excluding the factor of interest, employing the *Anova()* function of *lmerTest* package (Kuznetsova *et al.* 2017). Pairwise comparisons and post-hoc tests (with a Bonferroni correction for multiple comparisons) were performed using the *phia* package (De Rosario-Martinez 2015).

## 3. Results

### 3.1. Overview

Figure 2 illustrates the tongue constriction location angle (in blue) and constriction length (in green) for all nasal consonants produced by speaker BB in the context /o\_o/. It can be seen that the angle progressively decreases from the dental place (159.8°) to the velar place (46.5°); the constriction length is relatively small for the anterior consonants produced with the tongue tip,

blade, or the underside (e.g., 1.11 cm for /n/), and is much larger for the posterior consonants produced with the tongue front/body or dorsum (e.g., 3.47 cm for /ŋ/). The realization of the first three consonants by the speaker can be described as an apico-laminal dental (or denti-alveolar), apical alveolar, and a subapical palatal retroflex, respectively. The last consonant in the figure is a fairly posterior velar or uvular; /ŋ/ and /ŋi/ are fairly similar, differing in the relative frontness of the constriction and the involvement of the tongue dorsum. They can be classified as laminal alveopalatal and lamino-dorsal palatal. Similar realizations in the /o\_o/ context were exhibited by speaker SV, with the exception of /ŋ/, which was produced at a more anterior location (thus being a laminal alveolar). In addition, this speaker's retroflex showed a more retracted constriction (at the dome of the palate; cf. Figure 1).



**Figure 2:** *Constriction location plots for nasal consonants in the /o/ context by speaker BB. Loc: TCL; Dist: Constriction diameter (not used in the study); Leng: TClength.*

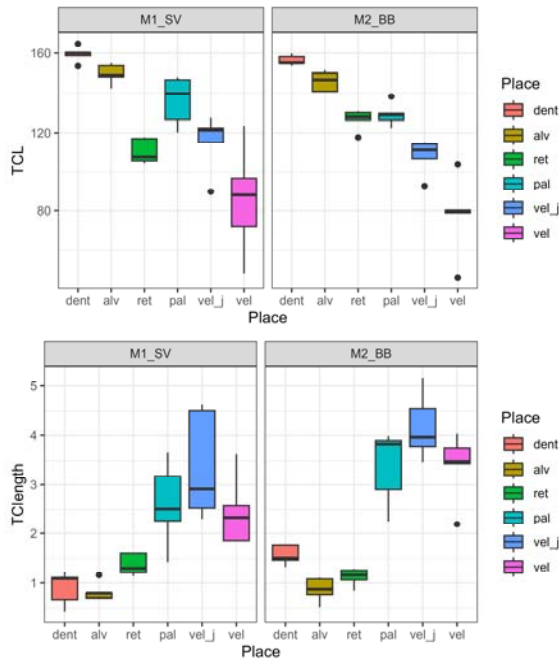
### 3.2. LMER results

Results of LMER models and posthoc tests performed separately by variable and speaker are summarized in Table 2 and are further illustrated in Figure 3. We can see that for speaker SV, TCL angle distinguished dental and alveolar nasals (higher angle) from the retroflex and the two velars; the latter two also differed from each other. The alveopalatal nasal, however, did not significantly differ in TCL from the other nasals, apart from the plain velar. This can be attributed to the fairly extensive linguopalatal contact for /ŋ/, spanning the alveolar and postalveolar regions. Overall, eight out of 15

pairwise comparisons were significant. For speaker BB, significant TCL differences involved 12 out of 15 pairwise comparisons: all consonants were differentiated from each other apart from the pairs /ɳ/-n/, /n/-ŋ/, and /ŋ/-ɲ/. The results for TClength were similar for both speakers: values were significantly higher for the alveopalatal and two velars compared to the dental, alveolar, and retroflex (with the exception of /ŋ/-ŋ/ for SV). In other words, the length results reflected differences between laminals and dorsals on the one hand and apicals (and apico-laminals) and sub-apicals on the other.

**Table 2:** Results of LMER model comparisons for Tongue Tip Constriction Location (TTCL) and Constriction Length (TClength) and pairwise posthoc comparisons by speaker (DF = 5).

	Variable	F	Pr(>F)	Posthoc differences (p<.05)
SV	TCL	18.24	<.001	ɳ, n > ŋ, ɲ <sup>i</sup> , ɲ; ɲ <sup>i</sup> > ɲ; ɳ > ɲ
	TClength	12.77	<.001	ɳ, ɲ <sup>i</sup> , ɲ > ɳ, n; ɳ, ɲ <sup>i</sup> > ɲ
BB	TCL	41.25	<.001	ɳ, n > ŋ, ɲ <sup>i</sup> , ɲ; ɳ > ɳ; ɳ > ɲ <sup>i</sup> , ɲ; ɳ > ɲ <sup>i</sup> , ɲ
	TClength	40.38	<.001	ɳ, ɲ <sup>i</sup> , ɲ > ɳ, n, ɳ



**Figure 3:** Boxplots for Tongue Constriction Location (top) and Tongue Constriction Length (bottom) by place (dental, alveolar, retroflex, palatal, palatalized velar, and velar) for both speakers.

Taken together, all nasals were distinguished by the combination of two measures for speaker BB, with the exception of the dental-alveolar pair (14 out of 15 pairwise comparisons). For speaker SV, the measures distinguished all consonants except for the dental-alveolar, alveopalatal-palatalized velar, and retroflex-velar pairs (/ɳ/-n/, /ɳ/-ŋ<sup>i</sup>/, and

/ŋ/-ŋ<sup>i</sup>/; 12 out of 15 comparisons). Thus the only contrast that was not distinguished by TCL and TClength measures across the speakers was the dental-alveolar contrast. It should be noted that TCL values for both speakers were on average higher for /ɳ/ than /n/ (Figure 3; see also Figure 2). Similarly, TCL values for /ɳ/ produced by SV were higher than /ŋ<sup>i</sup>/, as well as higher for /ŋ/ than /ŋ<sup>i</sup>/.

The lack of significance in these cases can be due to the relatively small number of analyzed tokens, the overall proximity of dental and alveolar locations, and – for SV – overall greater contextual variability of the data (as evident in larger confidence intervals for most consonants; Figure 3). We assume that the between-speaker differences observed here reflect different individual strategies; however, we cannot exclude the possibility of gender-specific differences.

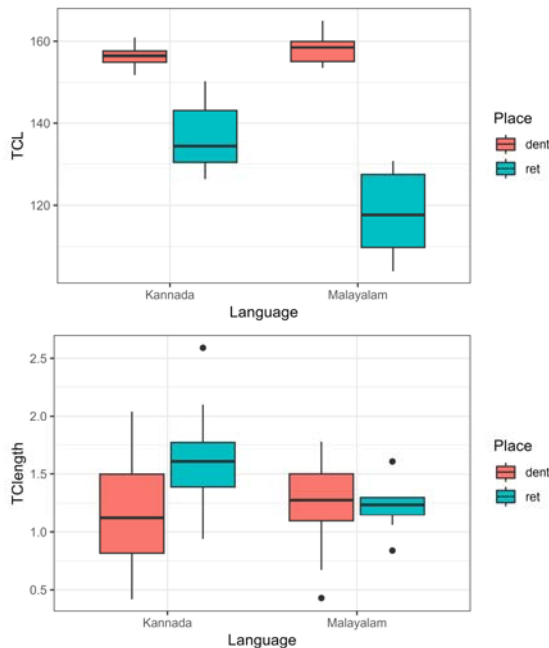
#### 4. Discussion and conclusion

The goal of this study was to explore the highly complex set of place contrasts in Malayalam by adapting the tongue constriction angle method previously used for coronals in Wubuy (Proctor *et al.* 2010) and Kannada (Kochetov *et al.* 2024). This was done by analyzing static MRI data obtained from two speakers of the language. The results showed that measures of TCL angle and TClength can potentially distinguish all Malayalam nasal contrasts except for the two anterior coronals – the dental /ɳ/ and the alveolar /n/. As mentioned above, the lack of significant differences here (which is in contrast to Proctor *et al.* 2010’s findings for Wubuy) is likely due to the relative proximity of TCL values for the two consonants, compounded by the small number of items. Two other consonant pairs produced by SV were not clearly differentiated by the measures – /ɳ/-ŋ<sup>i</sup>/ and /ŋ/-ŋ<sup>i</sup>/.

This suggests that – for a fuller analysis of Malayalam place contrasts – the constriction geometry measures need to be complemented by articulatory modeling parameters, such as tongue tip fronting, tongue body, and tongue dorsum PCA components. These measures, together with TCL and TClength, were used in our analysis of the dental-retroflex contrast in Kannada (Kochetov *et al.* 2024; following the method proposed by Badin, Bailly, Revéret, Baciú, Segebarth, & Savariaux 2002). Tongue tip fronting in particular differentiated dentals from retroflexes, and may therefore be useful in capturing the greater tip protrusion for the Malayalam /ɳ/ (relative to both /n/ and /ŋ/). Similarly, the tongue body and dorsum components should contribute to differentiating between retroflex, alveopalatal, and palatalized and plain velar places. We are currently exploring this approach to Malayalam nasals.

As was found for Wubuy (Proctor *et al.* 2010), coronals in Malayalam are characterized by a combination of place (constriction location) and constriction shape (apical, laminal, subapical). Our two speakers showed overall similar realizations of the consonants, with the exception of /ɳ/, which was produced as laminal alveolar by SV (in contrast to laminal alveopalatal by BB). Recall that this was also the description of this consonant by Dart & Nihalani (1999) based on palatographic data. The more posterior realization of this consonant by speaker BB, however, points to a larger variability in the production of this consonant than previously observed. Further, our results for the other coronals are consistent with Dart & Nihalani’s (1999) conclusions about the articulation of /ɳ/ (apico-laminal dental), /n/ (apical alveolar), and /ŋ/ (subapical postalveolar or palatal). Both speakers produced the retroflex /ŋ/ with a considerable curling of the tongue tip (especially for SV) and a large sublingual cavity. This is similar to what has been observed for the Malayalam lateral in the MRI study by Narayanan, Byrd, & Kaun (1999).

As TCL and TClength measurements used here were also employed for Kannada dental and retroflex consonants in Kochetov *et al.* (2024; as noted above), it is worth comparing those measurements (for nasals) to the current results. It can be seen in Figure 4 (top) that the dental /ɲ/ was produced as fairly front in both languages (two speakers were pooled in each group). The closure for the retroflex /ŋ/, on the other hand, was considerably more posterior in Malayalam than in Kannada. Further, while the Kannada speakers showed some TClength differences (more linguopalatal contact for the retroflex), the two consonants were relatively similar for the Malayalam speakers. Interestingly, the more retracted articulation of Malayalam retroflexes can be plausibly attributed to its more crowded coronal inventory. This is difficult to ascertain, however, given the small sample sizes of both studies. Future work should explore the potential differences in the production of similar contrasts across Dravidian languages.



**Figure 4:** Boxplots for TCL (top) and TClength (bottom) for dental and retroflex nasals in Kannada (from Kochetov *et al.* 2024) and Malayalam (current study) (two speakers pooled for each language).

It is important to note that while the constriction geometry method was originally developed for coronal contrasts, it is clearly applicable to more posterior lingual sounds, such as velars. Interestingly, the palatalized velar in our Malayalam data was more similar in its constriction location to coronals (and especially to /ɲ/) than to its plain velar counterpart. This shows that the consonant is better characterized as a fronted velar ([ɲ]) or a dorsal palatal, rather than a velar with a secondary palatal articulation. It should however be kept in mind that our understanding of these consonants is based on static images of sustained articulations. As palatalized consonants typically involve asynchronous coordination of primary and secondary gestures (Kochetov 2006; Shaw, Oh, Durvasula, & Kochetov 2021), dynamic MRI is needed to further investigate this question.

To conclude, our investigation of articulatory properties of a complex set of Malayalam nasals has revealed that the contrasts can be relatively successfully characterized by a

combination of two variables – the Tongue Constriction Location angle and Tongue Constriction Length. Further work, however, is needed to provide a fuller characterization of this complex contrast, as well as to investigate possible speaker-/gender-specific strategies and language-particular differences in the realization of similar contrasts.

## 5. Acknowledgements

The authors would like to thank the two speakers and Christophe Savariaux and Laurent Lamalle for providing extensive support for the data collection and analysis. The data were collected at the IRMaGe MRI facility in Grenoble. The research was partly funded by an Insight Grant from Social Sciences and Humanities Research Council of Canada (#435-2015-2013) to Alexei Kochetov. The MRI facilities centre IRMaGe in Grenoble, France, was partly funded by the grant ‘Infrastructure d’avenir en Biologie Santé - ANR-11-INBS-0006’ from the French *Agence Nationale de la Recherche*.

## 6. References

- Badin, P., Bailly, G., Revéret, L., Baciú, M., Segebarth, C., & Savariaux, C. (2002). Three-dimensional linear articulatory modeling of tongue, lips and face, based on MRI and video images. *Journal of Phonetics* 30(3), 533–553.
- Bates, Douglas, Martin Mächler, Ben Bolker & Steve Walker. 2015. Fitting linear mixed-effects models using {lme4}. *Journal of Statistical Software*, 67(1), 1–48.
- Dart, S.N., & Nihalani, P. (1999). The articulation of Malayalam coronal stops and nasals. *Journal of the International Phonetic Association*, 29, 129–142.
- De Rosario-Martinez, H. 2015. Package ‘phia’. Retrieved from <https://github.com/heliosdrml/phia>.
- Kochetov, A. (2006). Syllable position effects and gestural organization: Articulatory evidence from Russian. In L. Goldstein, D. Whalen, & C. Best (Eds.), *Laboratory Phonology 8* (pp. 565–588). Berlin, New York: De Gruyter Mouton.
- Kochetov, A., Savariaux, C., Lamalle, L., Noël, C., & Badin, P. (2023). An MRI-based articulatory analysis of the Kannada dental-retroflex contrast. *Journal of the International Phonetic Association*, 1–37.
- Kumari, S.B. (1972). *Malayalam phonetic reader*. Mysore, India: Central Institute of Indian Languages.
- Kuznetsova, A., Brockhoff, P.B. & Christensen, R.H.B. (2017). lmerTest package: Tests in linear mixed effects models. *Journal of Statistical Software*, 82, 1–26.
- Labrunie, M., Badin, P., Voit, D., Joseph, A.A., Frahm, J., Lamalle, L., Vilain, C., & Boë, L.-J. (2018). Automatic segmentation of speech articulators from real-time midsagittal MRI based on supervised learning. *Speech Communication*, 99, 27–46.
- Namboodiripad, S., & Garellek, M. (2017). Malayalam (Namboodiri Dialect). *Journal of International Phonetic Association*, 47, 109–118.
- Narayanan, Shrikanth S., Dani Byrd & Abigail Kaun. 1999. Geometry, kinematics, and acoustics of Tamil liquid consonants. *The Journal of the Acoustical Society of America* 106(4), 1993–2007.
- Proctor, M., Bundgaard-Nielsen, R.L., Best, C.T., Goldstein, L., Kroos, C., & Harvey, M. (2010). Articulatory modelling of coronal stop contrasts in Wubuy. In *SST 2010, 13th Australasian Speech Science and Technology*, pp. 90–93. Melbourne, Australia.
- Shaw, J. A., Oh, S., Durvasula, K., & Kochetov, A. (2021). Articulatory coordination distinguishes complex segments from segment sequences. *Phonology*, 38(3), 437–477.
- Team, R.D.C. (2014). R: A language and environment for statistical computing. R Foundation for Statistical Computing, <http://www.R-project.org>.