



HAL
open science

Interstitial 11q deletion in a patient with Sprengel's deformity: a case report and review of the literature

Dhekra Ismail, Lilia Kraoua, Sylvie Jaillard, Hela Bellil, Mohamed Zairi, Faouzi Maazoul, Ridha Mrad, Mohamed Nabil Nessib, Mediha Trabelsi

► **To cite this version:**

Dhekra Ismail, Lilia Kraoua, Sylvie Jaillard, Hela Bellil, Mohamed Zairi, et al.. Interstitial 11q deletion in a patient with Sprengel's deformity: a case report and review of the literature. *Molecular Cytogenetics*, 2024, 17 (1), pp.30. <10.1186/s13039-024-00695-z>. <hal-04882094>

HAL Id: hal-04882094

<https://hal.science/hal-04882094v1>

Submitted on 13 Jan 2025

HAL is a multi-disciplinary open access archive for the deposit and dissemination of scientific research documents, whether they are published or not. The documents may come from teaching and research institutions in France or abroad, or from public or private research centers.

L'archive ouverte pluridisciplinaire **HAL**, est destinée au dépôt et à la diffusion de documents scientifiques de niveau recherche, publiés ou non, émanant des établissements d'enseignement et de recherche français ou étrangers, des laboratoires publics ou privés.



Distributed under a Creative Commons CC BY-NC-ND 4.0 - Attribution - Non-commercial use - No Derivative Works - International License

CASE REPORT

Open Access



Interstitial 11q deletion in a patient with Sprengel's deformity: a case report and review of the literature

Dhekra Ismail^{1,2*}, Lilia Kraoua^{1,2}, Sylvie Jaillard³, Hela Bellil^{1,2}, Mohamed Zairi⁴, Faouzi Maazoul^{1,2}, Ridha Mrad^{1,2}, Mohamed Nabil Nessib⁴ and Mediha Trabelsi^{1,2}

Abstract

Background Interstitial chromosome 11 long arm deletions (11q13-q23) represent a rare cytogenetic abnormality characterized by non-specific clinical features including intellectual disability and several malformations without a clear genotype-phenotype correlation. We describe the first case of interstitial 11q deletion identified in a boy with Sprengel's deformity and provide a review of the literature.

Case presentation We report a 9-year-old boy with congenital scapular deformity, iris and chorioretinal coloboma, normal intelligence, and a history of mild motor development delay. The karyotype showed a *de novo* large 11q deletion. Fluorescence *in situ* hybridization (FISH) confirmed that the deletion is interstitial, and array comparative genomic hybridization (aCGH) revealed a loss of 25.8 Mb encompassing the 11q14.1-q22.3 region.

Conclusions The present case and the literature review of 61 previously published cases highlight the clinical heterogeneity and the lack of genotype-phenotype correlation in interstitial 11q deletions. Sprengel's deformity found in our patient might be a new finding in 11q deletions or, more probably, a fortuitous association.

Keywords 11q deletion, Sprengel's deformity, aCGH, coloboma, genotype-phenotype correlation

Background

Interstitial chromosome 11 long arm deletions (11q13-q23) represent a rare cytogenetic abnormality compared to 11q terminal deletions (11q23.3-q25), also known as Jacobsen syndrome. To date, 61 cases have been published [1–47]. In about half of the cases, the deletion was

characterized by array Comparative Genomic Hybridization (aCGH). Interstitial 11q deletions are quite heterogeneous in size, ranging from 743 kb [34] to 40.2 Mb [25], with breakpoints located between 11q13.2 and 11q23.3. Clinically, these deletions are associated with non-specific features such as developmental delay, intellectual disability, post-natal growth retardation, dysmorphic features, and in some cases, several malformations involving heart, brain, palate, eyes, bones, and kidneys. Most of the deletions described in the literature are *de novo*. In 10 cases, the deletion was inherited from one parent [5, 24, 28, 29, 46, 47]. No particular genotype-phenotype correlation has been made so far.

Herein, we report a case of a patient with an interstitial 11q deletion diagnosed with Sprengel's deformity

*Correspondence:

Dhekra Ismail
ism.dhekra@gmail.com

¹Department of Genetics, Charles Nicolle Hospital, Tunis, Tunisia

²LR99ES10 Human Genetics Laboratory, Faculty of Medicine of Tunis, University of Tunis El Manar, Tunis, Tunisia

³Department of Cytogenetics and Cell Biology, CHU Rennes, Rennes, France

⁴Department of Pediatric Orthopedic Surgery, Bechir Hamza Children's Hospital, Tunis, Tunisia



© The Author(s) 2024. **Open Access** This article is licensed under a Creative Commons Attribution-NonCommercial-NoDerivatives 4.0 International License, which permits any non-commercial use, sharing, distribution and reproduction in any medium or format, as long as you give appropriate credit to the original author(s) and the source, provide a link to the Creative Commons licence, and indicate if you modified the licensed material. You do not have permission under this licence to share adapted material derived from this article or parts of it. The images or other third party material in this article are included in the article's Creative Commons licence, unless indicated otherwise in a credit line to the material. If material is not included in the article's Creative Commons licence and your intended use is not permitted by statutory regulation or exceeds the permitted use, you will need to obtain permission directly from the copyright holder. To view a copy of this licence, visit <http://creativecommons.org/licenses/by-nc-nd/4.0/>.

(MIM%184400). Although it is a rare malformation, it is the most common congenital shoulder defect. It has been observed in association with a variety of conditions including Klippel-Feil syndrome, scoliosis, rib anomalies, and spinal dysraphism [48, 49]. It has also been described in 3q29 microdeletion [50] but it is still widely considered sporadic due to its unknown etiology and undetermined causal genes [48, 49].

In this report, we describe the first case of interstitial 11q deletion in a patient with Sprengel's deformity. Further, we provide an in-depth review of the literature and discuss the genotype-phenotype correlation.

Case presentation

The proband is a 9-year-old boy who was referred to our department of genetics at the age of six years because of Sprengel's deformity and facial dysmorphism. He is the fourth child of a 38-year-old mother and a 41-year-old father, both healthy and unrelated. His family history was negative for genetic diseases except for a three-year older brother who had autistic behavior.

The child was delivered vaginally following a healthy full-term pregnancy and weighed 4000 g at birth. The neonatal period was uneventful. Early personal history revealed a mild motor development delay: he was able to sit without support at the age of nine months and walked alone at the age of 19 months. However, he had no speech delay or intellectual disability. The patient has been followed up in ophthalmology since the age of nine months for coloboma and myopia, and in pediatric orthopedics since the age of four years because of congenital elevation of the scapula (Sprengel's deformity). He enrolled in primary school at the age of six with apparently normal learning performances except for a slow writing (Fig. 1).

The first examination at the age of six years showed a weight of 23 kg (+1.2 SD), a height of 111 cm (-1 SD), and a head circumference of 52 cm (average). The patient had mild facial dysmorphism including hypertelorism, upslanting palpebral fissures, bilateral epicanthus, bilateral inferior iris coloboma (Fig. 2-A), mild ptosis of the right eye, marked philtrum, abnormal teeth position, and posteriorly rotated low-set ears with thick lobes. He also had a short neck, a mild pectus excavatum (Fig. 2-B), an abnormally elevated left scapula (Fig. 2-C), a supernumerary palmar crease with fetal pads on both hands and clinodactyly of the 4th left toe, and the two 5th toes.

X-ray showed an elevated left scapula. Ultrasound of the left shoulder identified a bony deformity in the posterior-superior part of the left shoulder. No solid or cystic mass was detected. Chest computed tomography (CT) revealed a bilateral supernumerary cervical rib arising from C7, a small millimetric left subclavicular ossicle, a bifid aspect of the anterior arches of the 3rd right rib, and the 3rd and 5th left ribs. No omo-vertebral bone was identified. Specialized ophthalmological examination showed strong myopia with bilateral chorioretinal and iris coloboma. Both abdominal ultrasound and echocardiogram revealed no abnormalities and the complete blood count was normal.

Methods

Clinical evaluation

The patient had been under the care of an ophthalmologist since the age of nine months and a pediatric orthopedist since the age of four years. Later, at age six, he was referred to the genetics department for evaluation by a clinical geneticist.

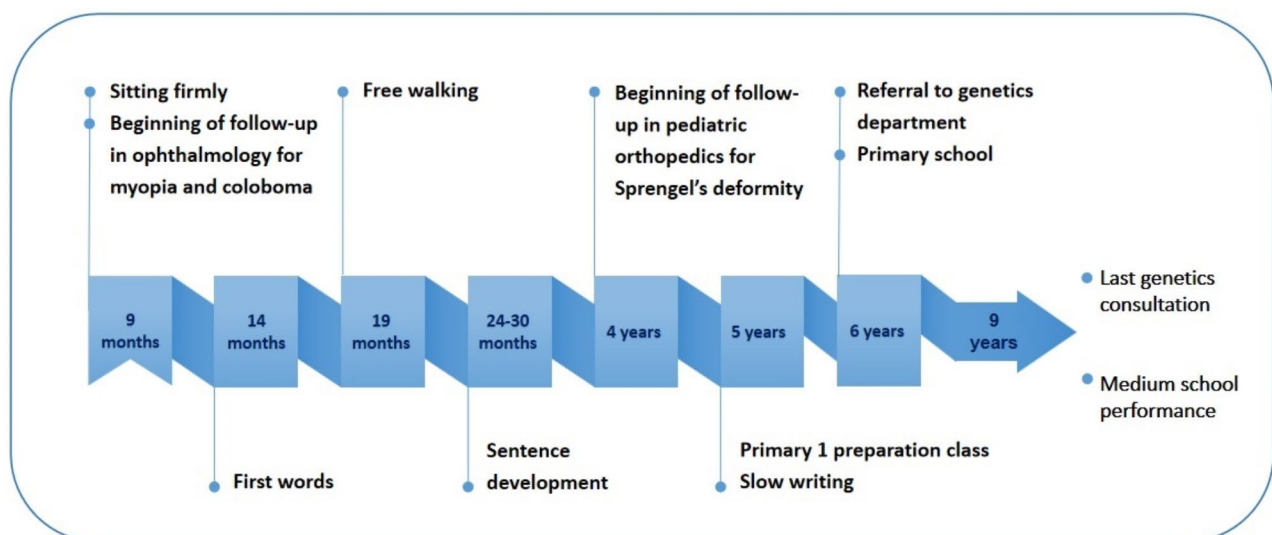


Fig. 1 Timeline of the patient's clinical milestones

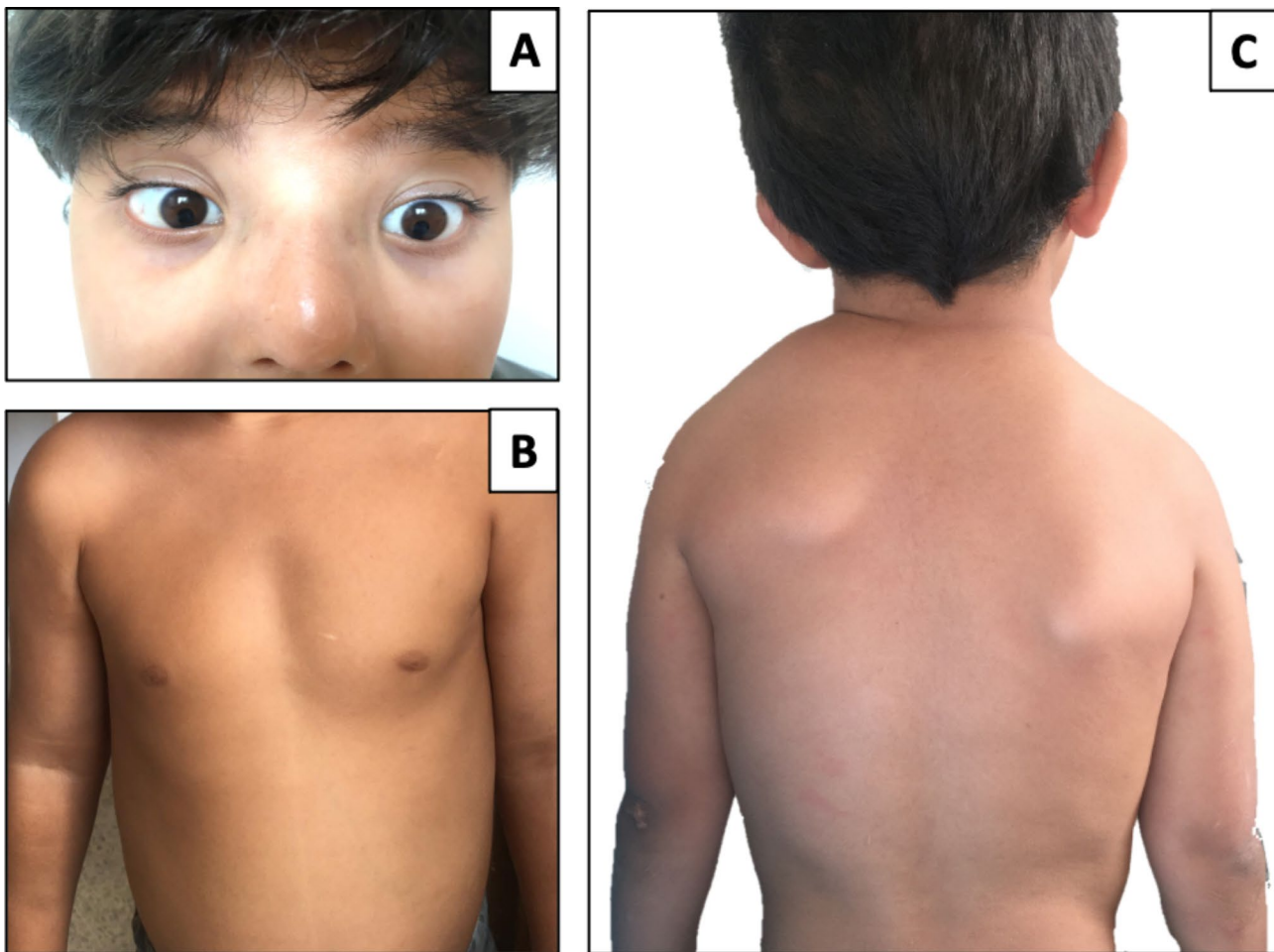


Fig. 2 Photographs of the proband at the age of six years. (A) Bilateral iris coloboma. (B) Pectus excavatum. (C) Sprengel's deformity

Conventional cytogenetic analysis

Standard R-band karyotyping with a 400-band resolution was performed on cultured peripheral lymphocytes in the patient and his parents, according to the Dutrillaux and Lejeune protocol [51].

Molecular cytogenetic analysis

Multiple fluorescence in situ hybridization (FISH) assays were performed on metaphase spreads using commercial chromosome 11-specific fluorescently labeled probes (Kreatech): centromeric probe (SE 11), whole chromosome painting probe (wcp11), short arm subtelomeric probe (ST 11pter, D11S1363), long arm subtelomeric probe (ST 11qter, D11S4437), 11q22.3 region-specific probe (ON ATM (11q22) / GLI (12q13)), and 11q23.3 region-specific probe (ON MLL (11q23) / SE 11). The slides were initially pretreated. Probes and target DNA were then co-denatured at 75 °C for 5 min and hybridized for 10 to 48 h at 37 °C. Following hybridization, the slides were washed with saline-sodium citrate (SSC) solution and counterstained using 4',6-diamidino-2-phenylindole

dihydrochloride (DAPI). The signals were examined using an epifluorescence Zeiss Axio® Imager M1 microscope.

An aCGH (Agilent® Technologies, Santa Clara, CA) was performed on oligonucleotide-based Sure Print G3 Human CGH 4×180 K microarray platform, with an overall median probe spacing of 13 kb, according to the protocol provided by the manufacturer. In brief, normal male control DNA (reference DNA) and patient's DNA were differentially labeled with Cy3 (cyanine 3-deoxyuridine triphosphate) and Cy5 (cyanine 5-deoxyuridine triphosphate), respectively, using Agilent SureTag Complete DNA Labeling Kit (Agilent Technologies). Labeled DNA was then cleaned with purification columns (Agilent Technologies) and hybridized on array at 67 °C for 24 h. Microarrays were washed using Agilent Oligo aCGH Wash Buffers and scanning was performed using Agilent Microarray Scanner. Data were analyzed with CytoGenomics Software (Agilent®) configured to human genome assembly GRCh37/hg19. The following databases were used to assess the clinical significance of genomic aberrations: the University of California Santa Cruz (UCSC) Genome Browser, the Database of Chromosomal

Imbalance and Phenotype in Humans Using Ensemble Resources (DECIPHER), Online Mendelian Inheritance in Man (OMIM) database, and PubMed. The clinical features of our patient were correlated with the Copy Number Variation (CNV) region and the involved genes, as well as with other cases published in the literature and databases.

Results

Karyotype showed a large deletion in the long arm of chromosome 11 (Fig. 3-B). FISH analyses revealed two complete wcp11 signals with no signal of translocated chromosome 11 material (Fig. 3-C). Subtelomeric 11p and 11q probes showed signals in place proving that the deletion was interstitial (Fig. 3-D). Locus-specific FISH showed two MLL signals in place at 11q23.3 (Fig. 3-E) and one signal at 11q22.3 confirming the deletion of ATM locus (Fig. 3-F). We concluded that the distal breakpoint was located between 11q22.3 and 11q23.3. Both parents showed normal karyotypes; therefore, the deletion was considered de novo.

Molecular characterization by aCGH confirmed the 11q interstitial deletion with breakpoints mapping at 11q14.1 (83,835,113) and 11q22.3 (109,702,695). The size of the deletion was 25.8 Mb. This region contains 234 RefSeq genes, 113 protein-coding genes, and 94 OMIM-listed genes including 31 disease-associated genes of which 10 are monoallelic genes. The karyotype was interpreted as: 46,XY,del(11)(q14.1q22.3).ish

del(11)(D11S1363+,D11Z1+,ATM-,MLL+, D11S4437+). arr[GRCh37] 11q14.1q22.3(83835113_109702695)x1 dn (Fig. 4).

Discussion

We describe a 9-year-old boy with minor abnormalities including Sprengel's deformity, mild motor development delay, and normal intelligence, in whom we identified a 25.8 Mb de novo interstitial 11q deletion encompassing the 11q14.1-q22.3 region which includes 31 disease-associated genes.

Most deletions reported in the literature in the long arm of chromosome 11 are terminal (11q23.3-q25) and have been associated with Jacobsen syndrome, a well-characterized genetic disorder (MIM #147791). However, interstitial 11q deletions (11q13-q23) are rarer and very heterogeneous in size and phenotype [44]. So far, a total of 61 published cases (52 pure 11q deletions and 9 associated with other genetic abnormalities) have been described in the literature (see Additional file 1). The majority of the interstitial deletions characterized by aCGH (29 cases) were between 3 and 13 Mb, with extremes going from 743 kb [34] to 40.2 Mb [25]. In the majority of cases, the proximal breakpoint was located at 11q14 (33 cases) and the distal breakpoint at 11q22 (22 cases). Our patient shares these common breakpoints. The phenotype remains highly heterogeneous and poorly delineated. It includes poor growth, developmental delay, hypotonia, intellectual disability, seizures,

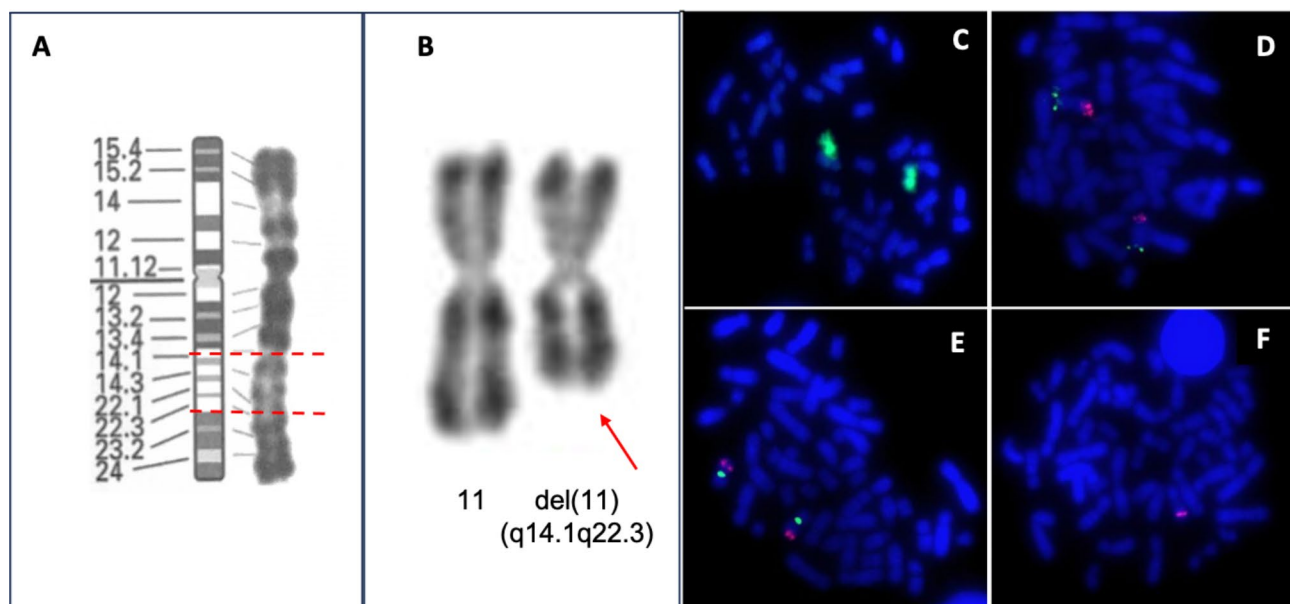


Fig. 3 Partial R-banding karyotype of the proband and FISH images. **(A)** Chromosome 11 ideogram in R band showing the deleted region between dashed lines. **(B)** R-banding karyotype showing partial deletion of the long arm of one chromosome 11 (arrow). **(C)** FISH using wcp11 probe (green) showed no insertion or translocation. **(D)** FISH using ST 11pter (green) and ST 11qter (red) probes showed normal hybridization. **(E)** FISH using ON MLL (11q23) (red) / SE 11 (green) probe showed no MLL deletion. **(F)** FISH using ON ATM (11q22) (red) / GLI (12q13) (green) probe showed the absence of ATM signal on the deleted chromosome 11 (GLI signal is not shown)

Table 1 Clinical findings in our patient and previously reported patients with pure 11q interstitial deletion

Clinical features	Number of patients in the literature*	Percentage	Present case
Neurodevelopment			
Intellectual disability	19/49	39%	-
Developmental delay	22/49	45%	Mild
Speech delay	11/49	22%	-
Hypotonia	11/49	22%	-
Seizures	8/49	16%	-
Strabismus	9/49	18%	-
Growth			
Intrauterine growth retardation	4/50	8%	-
Postnatal growth retardation	18/49	37%	-
Malformations			
Trigonocephaly	6/49	12%	-
Dolichocephaly	3/49	6%	-
Microcephaly	5/50	10%	-
Brain anomalies (hydrocephalus, hypoplastic/absent corpus callosum, cortical atrophy, white matter abnormalities)	3/50	6%	Unexplored
Kidney/urinary tract anomalies (left renal malrotation, horseshoe kidney, bilateral duplication of ureters, vesicoureteral reflux)	6/50	12%	-
Heart anomalies (mitral valve prolapse, tricuspid insufficiency, pulmonary stenosis, double outlet right ventricle, ventricular septal defect, atrial septal defect, right atrial and ventricular enlargement, patent ductus arteriosus)	11/50	22%	-
Cleft lip/palate	11/50	22%	-
Skeletal anomalies**	16/49	33%	-
Retinal dysgenesis/exudative vitreoretinopathy	5/49	10%	-
Iris/chorioretinal coloboma	4/50	8%	+
Myopia	3/49	6%	+
Dysmorphic features			
Hypertelorism	12/49	24%	+
Epi/telecanthus	9/49	18%	+
High-arched palate	16/49	33%	-
Ear anomalies	18/49	37%	+
Micro/retrognathia	15/49	31%	-
Ptosis	12/49	24%	+

*Frequencies were calculated using our review of the literature (see Additional file 1). We counted patients with only pure 11q deletions (without associated genetic anomalies). We also excluded patients with unavailable information [37, 47].**Skeletal anomalies are detailed in the [discussion](#) section

and their dysfunction may disrupt embryonic development, leading to spinal dysraphism and shoulder defects [50]. Further, some authors suggested autosomal dominant transmission of Sprengel's deformity through familial case studies [58, 59]. However, the condition has not been clearly linked to any specific gene and its exact etiology remains unknown [48]. Several skeletal abnormalities have been reported in association with 11q deletions. These include overlapping toes [5, 39, 41], broad thumbs and halluces [5, 21], adducted thumbs [19], triphalangeal thumb [8], arachnodactyly [27], tapering fingers [30, 39], hypoplastic first rib [33], rib agenesis [19], syndactyly [27, 41, 46], brachydactyly [37, 41, 46], camptodactyly [30], clinodactyly [30, 35, 37], club foot [29, 33] and scoliosis [30, 33, 40]. Another skeletal phenotype has been identified in one patient with an interstitial 11q deletion

(11q21-q22.2) described by Ikegawa et al. in 1998, presenting with severe pseudoachondroplasia (PSACH) characterized by short-limb dwarfism, normal face, and normal intellect. However, the authors could not prove the causal link between the deleted region and PSACH and suggested that the association may just be fortuitous [18]. The only disease-causing gene involved in a skeletal phenotype in the 11q14.1-q22.3 region is the *MMP13* gene (MIM*600108). Missense mutations in this gene were associated with autosomal dominant spondyloepimetaphyseal dysplasias (SEMDs) and metaphyseal anadysplasia (MIM#602111), a group of skeletal disorders characterized by poor growth and defective modeling of the spine and long bones. However, the phenotype does not include Sprengel's deformity or rib abnormalities.

Our patient presented with rib abnormalities and clinodactyly which have already been described in the literature with 11q deletion [19]. However, scapular abnormalities have never been reported previously in association with this deletion. Based on the Mouse Genome Informatics database (MGI), no genes within the mouse genomic region equivalent to the deleted region in our case were associated with Sprengel's deformity in mice. Thus, Sprengel's deformity found in our patient might be due to an unknown gene in the 11q region or maybe a fortuitous association. More genetic studies in other patients with Sprengel's deformity would address the question.

In addition to the skeletal anomalies, our patient was diagnosed with iris and chorioretinal coloboma. This feature has already been reported in 11q interstitial deletions in at least four patients [15, 25, 30, 41]. It has been linked to the *YAPI* gene (MIM*606608) located at 11q22.1 and known to be responsible for coloboma, ocular, with or without hearing impairment, cleft lip/palate, and/or impaired intellectual development [60].

Global developmental delay and intellectual disability have been associated with 11q interstitial deletions with variable severity [13, 27]. The OMIM morbid genes known to be associated with an intellectual disability in the 11q region are the *EED* gene (MIM*605984) at 11q14.2, where heterozygous missense mutations are responsible for Cohen-Gibson syndrome (MIM#617561) including overgrowth, intellectual disability, and developmental delay [61], and the *GRIA4* gene at 11q22.3, where heterozygous missense mutations are associated with neurodevelopmental disorder with or without seizures, and gait abnormalities. None of these features was found in our patient except for a mild developmental delay.

Further major abnormalities found in patients with 11q interstitial deletions such as growth retardation, microcephaly, cleft lip/palate, heart defects, kidney malformations, retinal dysgenesis, and exudative vitreoretinopathy [36] were absent in our patient.

Among the less frequent manifestations reported in constitutional 11q deletions, neuroblastoma has been reported in five patients [25, 26, 35, 39, 62]. These patients had deletions within the 11q22.3-q23.3 region. Indeed, the neuroblastoma locus is presumed to be at 11q22-q23 but the causative genes are not identified yet [39]. Since this putative locus is not included in the present deletion, we believe our patient's probability of developing neuroblastoma is low. Despite the large deletion size (25.8 Mb), the proband had a mild phenotype. This outstanding contrast supports the absence of genotype-phenotype correlation reported in the literature [36, 44].

Conclusion

The present case as well as our review of the literature highlight the clinical heterogeneity and the lack of genotype-phenotype correlation in interstitial 11q deletions. Sprengel's deformity found in our patient might be a new finding in 11q deletion or more probably a fortuitous association since it is a common congenital shoulder defect. Further genetic studies in other patients with Sprengel's deformity would verify this hypothesis.

Abbreviations

aCGH	Array Comparative Genomic Hybridization
ATM	Ataxia-Telangiectasia Mutated
CT	Computed tomography
DNA	Deoxyribonucleic acid
FISH	Fluorescent in situ hybridization
GRCh37	Genome Reference Consortium Human version 37
hg19	19th human genome assembly
MLL	Mixed-lineage leukemia
ON	Oncology
PSACH	Pseudoachondroplasia
SD	Standard deviation
SE 11	Satellite enumeration 11
SEMDs	Autosomal dominant spondyloepimetaphyseal dysplasias
SSC	Saline-sodium citrate
ST 11pter	Subtelomeric 11p arm
ST 11qter	Subtelomeric 11q arm
wcp11	Whole chromosome painting 11

Supplementary Information

The online version contains supplementary material available at <https://doi.org/10.1186/s13039-024-00695-z>.

Additional file 1: Interstitial 11q deletions - Review of the literature. Clinical and cytogenetic details of cases with interstitial 11q deletions reported in the literature.

Acknowledgements

We sincerely thank the patient and his family for their participation.

Author contributions

Clinical evaluation: MZ, FM and MNN; Genetic analysis and data interpretation: LK, SJ and HB; Writing—original draft preparation: DI; Writing—review and editing: LK; Supervision: MT and RM; All authors have read and agreed to the published version of the manuscript.

Funding

No funding was received for this work.

Data availability

All data generated or analyzed during this study are included in this published article and its supplementary information file.

Declarations

Ethics approval and consent to participate

Written informed consent was obtained from the parents of the proband for the genetic studies.

Consent for publication

Written informed consent was obtained from the parents of the proband for photographs publication.

Competing interests

The authors declare no competing interests.

Received: 8 August 2024 / Accepted: 23 October 2024

Published online: 03 December 2024

References

- Taillemite JL, Baheux-Morlier G, Roux C. <ArticleTitle Language="En">Délétion Interstitielle Du bras long d'un chromosome 11. *Ann Genet.* 1975;18:61–3.
- Sørensen K, Nielsen J, Holm V, Haahr J. Fragile site long arm chromosome 16. *Hum Genet.* 1979;48:131–4.
- McPherson E, Meissner L. 11q-syndrome: review and report of two cases. *Birth Defects Orig Artic Ser.* 1982;18:295–300.
- Taki H, Kusuda S, Ohsasa Y, Hase Y, Tsuruhara T, Yoshimura A. A case-report of partial deletion of long arm to chromosome 11 del(11)(q21q23). *Jpn J Hum Genet.* 1983;28:179–80.
- Rudd NL, Teshima IE. The association of a lymphoreticular malignancy with an 11q deletion: A coincidence or a cancer susceptibility? *Hum Genet.* 1983;63:323–6.
- Bateman JB, Maumenee IH, Sparkes RS. Peters' Anomaly Associated With Partial Deletion of the Long Arm of Chromosome 11. *Am J Ophthalmol.* 1984;97:11–5.
- de Pater JMK, de France HF, Bijlsma JB. Interstitial deletion of the long arm of chromosome 11. *J Med Genet.* 1985;22:224–6.
- Carnevale A, Blanco B, Grether P, Castillejos AR. Interstitial deletion of the long arm of chromosome 11. *Ann Genet.* 1987;30:56–8.
- Okamura T, Sagehashi N, Tsukagoshi T. 11q-syndrome with cleft palate. A case report. *J Jpn PSR.* 1988;8:353–8.
- Guć-Sčekić M, Pilić-Radivojević G, Mrdjenović G, Djurić M. Interstitial deletion of 11q. *J Med Genet.* 1989;26:205–6.
- Wakazono A, Masuno M, Yamaguchi S, Tsubouchi K, Kondo N, Orii T. Interstitial deletion of the long arm of chromosome 11: Report of a case and review of the literature. *Jpn J Hum Genet.* 1992;37:229–34.
- Hori T, Masuno M, Wakazono A, Takahashi E, Katakura R, Orii T. Interstitial deletion of the long arm of chromosome 11 determined by fluorescence in situ hybridization. *Jpn J Hum Genet.* 1993;38:219–24.
- Stratton RF, Lazarus H, Ritchie KJL, Bell E. Deletion (11)(q14.1q21). *Am J Med Genet.* 1994;49:294–8.
- Hertz JM, Tommerup N, Sørensen FB, Henriques UV, Nielsen A, Therkelsen AJ. Partial deletion 11q: report of a case with a large terminal deletion 11q21-qter without loss of telomeric sequences, and review of the literature. *Clin Genet.* 1995;47:231–5.
- Ono J, Hasegawa T, Sugama S, Sagehashi N, Hase Y, Oku K, et al. Partial deletion of the long arm of chromosome 11: ten Japanese children. *Clin Genet.* 1996;50:474–8.
- Joyce CA, Zorich B, Pike SJ, Barber JC, Dennis NR. Williams-Beuren syndrome: phenotypic variability and deletions of chromosomes 7, 11, and 22 in a series of 52 patients. *J Med Genet.* 1996;33:986–92.
- De Pater JM, Ippel PF, Bijlsma JB, Van Nieuwenhuizen O. Interstitial deletion 11q. Case report and review of the literature. *Genet Couns.* 1997;8:335–9.
- Ikegawa S, Ohashi H, Hosoda F, Fukushima Y, Ohki M, Nakamura Y. Pseudoachondroplasia with de novo deletion [del(11)(q21q22.2)]. *Am J Med Genet.* 1998;77:356–9.
- de Lonlay-Debeney P, de Blois MC, Bonnet D, Amiel J, Abadie V, Picq M, et al. Ebstain anomaly associated with rearrangements of chromosomal region 11q. *Am J Med Genet.* 1998;80:157–9.
- Horelli-Kuitunen N, Gahmberg N, Eeva M, Palotie A, Järvelä I. Interstitial deletion of bands 11q21→22.3 in a three-year-old girl defined using fluorescence in situ hybridization on metaphase chromosomes. *Am J Med Genet.* 1999;86:416–9.
- Meyer MF, Gerresheim F, Pfeiffer A, Epplen JT, Schatz H. Association of polycystic ovary syndrome with an interstitial deletion of the long arm of chromosome 11 [del(11)(q21q23.1)]. *Exp Clin Endocrinol Diabetes.* 2000;108:519–23.
- Syrrou M, Fryns JP. Interstitial deletion of chromosome 11 (q22.3-q23.2) in a boy with mild developmental delay. *J Med Genet.* 2001;38:621–4.
- Coupy I, Taine L, Goizet C, Soriano C, Mortemousque B, Arveiler B, et al. Leucodystrophy and oculocutaneous albinism in a child with an 11q14 deletion. *J Med Genet.* 2001;38:35–8.
- Li L, Moore P, Ngo C, Petrovic V, White SM, Northrop E, et al. Identification of a haplosufficient 3.6-Mb region in human chromosome 11q14.3→q21. *Cytogene Genome Res.* 2002;97:158–62.
- Mosse Y, Greshock J, King A, Khazi D, Weber BL, Maris JM. Identification and high-resolution mapping of a constitutional 11q deletion in an infant with multifocal neuroblastoma. *Lancet Oncol.* 2003;4:769–71.
- Satgé D, Moore SW, Stiller CA, Niggli FK, Pritchard-Jones K, Bown N, et al. Abnormal constitutional karyotypes in patients with neuroblastoma: a report of four new cases and review of 47 others in the literature. *Cancer Genet Cytogenet.* 2003;147:89–98.
- Li P, Zhang HZ, Huff S, Nimmakayalu M, Qumsiyeh M, Yu J, et al. Karyotype–phenotype insights from 11q14.1–q23.2 interstitial deletions: FZD4 haploinsufficiency and exudative vitreoretinopathy in a patient with a complex chromosome rearrangement. *Am J Med Genet Part A.* 2006;140A:2721–9.
- Goumy C, Gouas L, Tchirkov A, Roucaute T, Giollant M, Veronèse L, et al. Familial deletion 11q14.3–q22.1 without apparent phenotypic consequences: A haplosufficient 8.5 Mb region. *Am J Med Genet Part A.* 2008;146A:2668–72.
- Sparkes RL, Shetty S, Chernos JE, Mefford HC, Micheil Innes A. Interstitial deletion of 11q in a mother and fetus: implications of directly transmitted chromosomal imbalances for prenatal genetic counseling. *Prenat Diagn.* 2009;29:283–6.
- Melis D, Genesio R, Cozzolino M, Del Giudice E, Mormile A, Imperati F, et al. An emerging phenotype of proximal 11q deletions. *Eur J Med Genet.* 2010;53:340–3.
- Wincent J, Schoumans J, Anderlid BM. De novo deletion of chromosome 11q13.4–q14.3 in a boy with microcephaly, ptosis and developmental delay. *Eur J Med Genet.* 2010;53:50–3.
- Kariminejad A, Kariminejad R, Tzschach A, Najafi H, Ahmed A, Ullmann R, et al. 11q14.1–11q22.1 deletion in a 1-year-old male with minor dysmorphic features. *Am J Med Genet Part A.* 2010;152A:2651–5.
- Sachdeva R, Sears JE, Rychwalski PJ. A novel case of bilateral high myopia, cataract, and total retinal detachment associated with interstitial 11q deletion. *Ophthalmic Genet.* 2010;31:84–8.
- Krgovic D, Marcun Varda N, Zagorac A, Kokalj-Vokac N. Submicroscopic interstitial deletion of chromosome 11q22.3 in a girl with mild mental retardation and facial dysmorphism: Case report. *Mol Cytogenet.* 2011;4:17.
- Passariello A, De Brasi D, Defferrari R, Genesio R, Tufano M, Mazzocco K, et al. Constitutional 11q14–q22 chromosome deletion syndrome in a child with neuroblastoma MYCN single copy. *Eur J Med Genet.* 2013;56:626–34.
- Nacinovich R, Villa N, Redaelli S, Broggi F, Bomba M, Stoppa P, et al. Interstitial 11q deletion: genomic characterization and neuropsychiatric follow up from early infancy to adolescence and literature review. *BMC Res Notes.* 2014;7:248.
- Yelavarthi K, Cabral H, Wilson GN, Rohena L, Risheg H, Penton A, et al. Partial monosomy of 11q22.2q22.3 including the SDHD gene in individuals with developmental delay. *Am J Med Genet Part A.* 2015;167:695–700.
- Papoulidis I, Paspaliaris V, Siomou E, Orru S, Murru R, Sifakis S, et al. Interstitial deletion at 11q14.2–11q22.1 may cause severe learning difficulties, mental retardation and mild heart defects in 13-year old male. *Mol Cytogenet.* 2015;8:71.
- Shiohama T, Fujii K, Hino M, Shimizu K, Ohashi H, Kambe M, et al. Coexistence of neuroblastoma and ganglioneuroma in a girl with a hemizygous deletion of chromosome 11q14.1–23.3. *Am J Med Genet Part A.* 2016;170:492–7.
- Cetin Z, Clark O, Yakut S, Nur B, Mihci E, Karauzum S. A molecularly characterized interstitial deletion encompassing the 11q14.1–q23.3 region in a case with multiple congenital abnormalities. *Genet Couns.* 2016;27:51–66.
- Tucker T, Steinraths M, Oh T, Nelson TN, Van Allen MI, Brown L, et al. Incidental finding of paternal UPD15 in a child with a deletion of 11q21–q22.3, presenting with developmental delay, coloboma and characteristic dysmorphic features. *Clin Dysmorphol.* 2016;25:77–81.
- Li LL, Zhang HG, Shao XG, Gao JC, Zhang HY, Liu RZ. De novo interstitial deletion in the long arm of chromosome 11: a case report. *Genet Mol Res.* 2016;15.
- Kim YS, Kim GH, Byeon JH, Eun SH, Eun BL. Chromosome 11q13 deletion syndrome. *Korean J Pediatr.* 2016;59:510–3.
- Lallar M, Srivastava P, Phadke SR. A large interstitial 11q deletion with isolated mild intellectual disability: review of the literature for genotype–phenotype correlation. *Clin Dysmorphol.* 2018;27:142–4.
- Zachaki S, Kouvidi E, Mitrakos A, Lazaros L, Pantou A, Mavrou A, et al. A novel paracentric inversion [inv(20)(q13.1q13.3)] accompanied by an 11q14.3–q21 microdeletion in a pediatric patient with an intellectual disability. *Balk J Med Genet.* 2018;21:63–7.
- Kirk B, Kharbanda M, Bateman MS, Hunt D, Taylor EJ, Collins AL, et al. Directly Transmitted 12.3-Mb Deletion with a Consistent Phenotype in the Variable 11q21q22.3 Region. *Cytogenet Genome Res.* 2020;160:185–92.

47. Zhao L, Luo H, Luo G, Qiu X, Liao Y. [Prenatal diagnosis and genetic analysis of a 46,XN,del(11)(q14q22) fetus]. *Chin J Med Genet.* 2020;37:879–82.
48. Harvey EJ, Bernstein M, Desy NM, Saran N, Ouellet JA. Sprengel Deformity: Pathogenesis and Management. *J Am Acad Orthop Surg.* 2012;20:177–86.
49. van Aalst J, Vles JSH, Cuppen I, Sival DA, Niks EH, Van Rhijn LW, et al. Sprengel's deformity and spinal dysraphism: connecting the shoulder and the spine. *Childs Nerv Syst.* 2013;29:1051–8.
50. Guo S, Fan XF, Jin JY, Fan LL, Zeng L, Zhou ZB, et al. A novel proximal 3q29 chromosome microdeletion in a Chinese patient with Chiari malformation type II and Sprengel's deformity. *Mol Cytogenet.* 2018;11:8.
51. Dutrillaux B, Lejeune J. [A new technic of analysis of the human karyotype]. *C R Acad Hebd Seances Acad Sci D.* 1971;272:2638–40.
52. Eulenberg. High degree of scapular dislocation. *Arch Klin Chir.* 1863;4:304–11.
53. Sprengel O. [Congenital upward displacement of the scapula]. *Arch Klin Chir* 1891;42:545.
54. Landau JP, Hoenecke HR. Genetic and biomechanical determinants of glenoid version: Implications for glenoid implant placement in shoulder arthroplasty. *J Shoulder Elb Surg.* 2009;18:661–7.
55. Matsuoka T, Ahlberg PE, Kassaris N, Iannarelli P, Dennehy U, Richardson WD, et al. Neural crest origins of the neck and shoulder. *Nature.* 2005;436:347–55.
56. Rancourt DE, Tsuzuki T, Capecchi MR. Genetic interaction between *hoxb-5* and *hoxb-6* is revealed by nonallelic noncomplementation. *Genes Dev.* 1995;9:108–22.
57. Dhir R, Chin K, Lambert S. The congenital undescended scapula syndrome: Sprengel and the cleithrum: a case series and hypothesis. *J Shoulder Elb Surg.* 2018;27:252–9.
58. Wilson MG, Mikity VG, Shinno NW. Dominant inheritance of Sprengel's deformity. *J Pediatr.* 1971;79:818–21.
59. Kaissi AA, Chehida FB, Gharbi H, Ghachem MB, Hendaoui L, Hennekam RCM. Familial vertebral segmentation defects, Sprengel anomaly, and omovertebral bone with variable expressivity. *Am J Med Genet Part A.* 2005;138A:374–8.
60. Williamson KA, Rainger J, Floyd JAB, Ansari M, Meynert A, Aldridge KV, et al. Heterozygous loss-of-function mutations in *YAP1* cause both isolated and syndromic optic fissure closure defects. *Am J Hum Genet.* 2014;94:295–302.
61. Sequerra Amram Cohen A, Gibson WT. EED-Related Overgrowth. 2019. In: Adam MP, Feldman J, Mirzaa GM, Pagon RA, Wallace SE, Amemiya A, editors. *GeneReviews*®. Seattle (WA): University of Washington, Seattle; 1993–2024.
62. Koiffmann CP, Gonzalez CH, Vianna-Morgante AM, Kim CA, Odone-Filho V, Wajntal A. Neuroblastoma in a boy with MCA/MR syndrome, deletion 11q, and duplication 12q. *Am J Med Genet.* 1995;58:46–9.

Publisher's note

Springer Nature remains neutral with regard to jurisdictional claims in published maps and institutional affiliations.