



HAL
open science

Recent Advances in Cone-beam CT in Oral Medicine

Delphine Maret, Jean-Noel Vergnes, Ove Peters, Christine Peters, Karim Nasr, Paul Monsarrat

► **To cite this version:**

Delphine Maret, Jean-Noel Vergnes, Ove Peters, Christine Peters, Karim Nasr, et al.. Recent Advances in Cone-beam CT in Oral Medicine. *Current Medical Imaging Reviews*, 2020, 16 (5), pp.553-564. 10.2174/1573405615666190114152003 . hal-04853364

HAL Id: hal-04853364

<https://hal.science/hal-04853364v1>

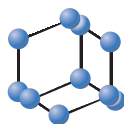
Submitted on 20 Feb 2025

HAL is a multi-disciplinary open access archive for the deposit and dissemination of scientific research documents, whether they are published or not. The documents may come from teaching and research institutions in France or abroad, or from public or private research centers.

L'archive ouverte pluridisciplinaire **HAL**, est destinée au dépôt et à la diffusion de documents scientifiques de niveau recherche, publiés ou non, émanant des établissements d'enseignement et de recherche français ou étrangers, des laboratoires publics ou privés.



Distributed under a Creative Commons Attribution 4.0 International License



Recent Advances in Cone-beam CT in Oral Medicine

Delphine Maret^{1,2,*}, Jean-Noel Vergnes^{3,4}, Ove A. Peters^{5,6}, Christine Peters⁵, Karim Nasr¹ and Paul Monsarrat^{1,7}

¹Oral Rehabilitation Department, Dental Faculty, Paul Sabatier University, Toulouse University Hospital (CHU de Toulouse), Toulouse, France; ²AMIS Laboratory - Laboratoire Anthropologie Moléculaire et Imagerie de Synthèse, Université de Toulouse, UMR 5288 CNRS, UPS, Toulouse, France; ³Epidemiology and Public Health Department, Dental Faculty, Paul Sabatier University, Toulouse University Hospital (CHU de Toulouse), Toulouse, France; ⁴Division of Oral Health and Society, Faculty of Dentistry, McGill University, Montreal, Quebec, Canada; ⁵Department of Endodontics, Arthur A. Dugoni School of Dentistry, University of the Pacific, San Francisco, California, USA; ⁶School of Dentistry, University of Queensland, Brisbane, Queensland, Australia; ⁷STROMALab, Université de Toulouse, CNRS ERL 5311, EFS, ENVT, Inserm U1031, UPS, Toulouse, France

Abstract: Background: The cone-beam computed tomography (CBCT) technology has continuously evolved since its appearance in oral medicine in the early 2000s.

Objectives: To present recent advances in CBCT in oral medicine: i) selection of recent and consensual evidence-based sources, ii) structured summary of the information based on an iterative framework and iii) compliance with ethical, public health and patient-centered concerns.

Main Findings: We will focus on technological advances, such as sensors and reconstruction algorithms used to improve the constant quality of the image and dosimetry. CBCT examination is now performed in almost all disciplines of oral medicine: currently, the main clinical disciplines that use CBCT acquisitions are endodontics and oral surgery, with clearly defined indications. Periodontology and ear, nose and throat medicine are more recent fields of application. For a given application and indication, the smallest possible field of view must be used. One of the major challenges in contemporary healthcare is ensuring that technological developments do not take precedence over admitted standards of care. The entire volume should be reviewed in full, with a systematic approach. All findings are noted in the patient's record and explained to the patient, including incidental findings. This presupposes the person reviewing the images is sufficiently trained to interpret such images, inform the patient and organize the clinical pathway, with referrals to other medical or oral medicine specialties as needed.

Conclusion: A close collaboration between dentists, medical physicists, radiologists, radiographers and engineers is critical for all aspects of CBCT technology.

Keywords: Cone-beam computed tomography, radiology, oral medicine, stomatognathic diseases, incidental findings, patient-centered care.

1. INTRODUCTION

Cone-beam computed tomography (CBCT) is a technology that is especially useful in dental and maxillofacial radiology as it enables volume data to be acquired rapidly [1, 2]. Since its first introduction in Europe in 1998 [3] and in the U.S. in 2001, CBCT has come to occupy an increasingly important place in the diagnosis and in the planning of treatments [4]. In the USA, it is estimated that about 80% of dental specialists (endodontic practitioners, orthodontists or oral surgeons) have access to a CBCT machine [5, 6]. Although dental specialists perform more CBCT examinations than general dental practitioners [7], the latter is also a growing user group, since most dental schools have adopted CBCT courses in their curriculum [8]. In this context of

rapidly evolving CBCT uses, the aim of this review was to present recent advances related to CBCT in oral medicine. The guiding principles for this review were the selection of recent and consensual evidence-based sources, a structured summary of the information based on an iterative framework and the compliance with ethical, public health and patient-centered concerns. Consequently, this review will be divided into three parts, i) presenting the technological challenges in CBCT including recent advances, ii) the clinical use of CBCT from the practitioner's perspective according to the latest recommendations, iii) and the consideration of CBCT based on patient-centered care principles.

2. TECHNOLOGICAL CHALLENGES IN CBCT

2.1. Basic Principles of CBCT

The apparatus consists of a continuous or pulsating X-ray generator emitting a divergent pyramidal or cone-shaped

ARTICLE HISTORY


Received: September 24, 2018
Revised: December 09, 2018
Accepted: December 19, 2018

DOI:
10.2174/1573405615666190114152003



This is an Open Access article published under CC BY 4.0
<https://creativecommons.org/licenses/by/4.0/legalcode>

*Address correspondence to this author at the Dental Faculty, Paul Sabatier University, University Hospital (CHU de Toulouse), 3 chemin des Maraichers 31062, Toulouse, France; Tel: +33 5 62 17 29 29; Fax: +33 5 61 25 47 19; E-mail: delphine_maret@yahoo.fr



beam that crosses the object to be explored, directed towards through the middle of the region of interest. The attenuated beam is then analysed by a digital area detector. The X-ray tube and the flat-panel detector are aligned and joined together in an imaging gantry which turns around the patient in a single, partial or complete rotation scan (180° to 360°), thereby acquiring digital data as data volume.

The patient may be in a standing, sitting or supine position, depending on the equipment used and the clinical needs. The standing position is the most commonly used. The sitting position may be preferred, a compromise to reduce both kinetic artefacts and the physical footprint [9]. At the end of the rotation, the acquired digital data are processed with volume reconstruction algorithms.

The acquisition constants depend on the patient's characteristics, clinical needs and desired spatial resolution, among others [10], with variable field of view (FOV) from 4×4 cm for a single jaw to around 30×30 cm for full craniofacial imaging. Tube voltage ranges from 40 to 120 kV (with typical values between 60 and 90 kV), tube current from 1 to 32 mA and exposure and scanning time from approximately 1 to 40 seconds [10, 11]. The size and shape of the detector, the beam projection geometry and the ability to collimate the beam determine the size and shape of the FOV [10]. The time required for volume acquisition (acquisition of the raw data) also depends on the CBCT device, according to the number of projection images or the rate to which they are acquired, i.e. frame rate [10].

2.2. Characteristics of the CBCT Image

Spatial resolution (sharpness) is the capacity to capture the finest details in an image, i.e. the minimum distance needed to make distinction between two objects [12]. The voxel is the unit of volume [2, 13] and the spatial resolution is related to the voxel size (without being restricted). In CBCT, the voxels are in general cubic (isotropic) and the cross sections should have the same spatial resolution whatever their orientation, which allows post-reconstruction of curvilinear sections (e.g. panoramic, temporomandibular joint exam), and reliable measurements [11]. The so-called nominal spatial resolution is the resolution that results directly from the physical properties of the radiology machine and that can be inferred theoretically from voxel size and focal spot [11]. The machines with a small field of view currently have the highest spatial resolutions and smaller voxel sizes are expected to provide images that represent fine structures more accurately than larger voxel sizes would [2, 14, 15]. Nevertheless, several other parameters may counteract a theoretical high spatial resolution, with the often-neglected patient motion (a heartbeat results in $80 \mu\text{m}$ amplitude at the head). This phenomenon is amplified by scanning time, increasing the risk of unwanted patient movement [16].

Density or contrast resolution corresponds to the capacity to distinguish two structures of different densities, with different mean voxel value between the two regions [17]. The main implicated factors [17] are the exposure values, the dynamic range of the detector (detectable range of exposure values), the bit depth (the number of shades of grey that the system can consider). The low-contrast resolution of CBCT,

linked to various physical and technical factors, can lead to difficulties in soft tissue evaluation [14].

The spatial resolution is also affected by the partial volume effect, which has repercussions on the image quality [12, 17]. The smaller the object is, the more difficult it is to distinguish from the background, particularly if the contrast is weak. When the size of a structure is smaller than the voxel size, the voxel displays an average value between the structure and the surrounding tissues. The anatomical structure may "disappear" (e.g. within ethmoid bone) and transitions between the regions may appear blurred and gradual instead sharp and abrupt [12, 19]. Complementarily, cross contamination concerns the quantitative impact of volume partial effect and designates the fact that two regions of different intensities contaminate each other mutually [12, 18, 19]. Consequently, CBCT devices having a high spatial resolution are less affected by volume partial effect phenomena as the voxel sizes are smaller [12] but these devices are more subject to noise [12, 20].

2.3. Advances in Image Detection

Innovations in detector materials and technology have increased the speed and efficiency of CBCT. Nowadays, few machines use charge-coupled devices with an image intensifier detector. The majority of detectors are now flat-panel detectors (FPDs) [21]. Amorphous silicon (a-Si)-based FPDs, also known as TFT technology, are known to be more resistant to radiation damage. However, they are plagued by instability over time such as so-called ghosting or image lag [22]. Complementary metal oxide semiconductor (CMOS)-based FPDs have many advantages over TFTs, such as lower cost, smaller pixel pitch, less electronic noise, higher readout rate, and less image lag. Consequently, their spatial resolution is higher, as although the maximum wafer size and radiation hardness as not as good relative to TFT [17, 23]. Like TFT, CMOS-based FPDs are completed by overlaying the CMOS pixel array with a scintillation layer. Thallium-doped cesium iodine-based scintillators (CsI:Tl) have been used typically. Improvements are continuously being made to increase the sensitivity while improving spatial resolution and decreasing the signal-to-noise ratio [23], even if this technology may be getting close to its limits [24].

An alternative and very promising approach is to use a photon-counting detector with spectral capacities. This is a direct imaging method with a sensitive material that converts incident x-ray photons to electron flow, detected by a CMOS array [25]. Reduced scatter makes this approach more efficient, improves resolution, and provides a more favorable signal-to-noise ratio. As a result, lower levels of ionizing radiation may be used [24]. These energy-resolved photon-counting detectors open the way for multi-spectral imaging (also called "color" x-ray imaging). This, in turn, allows the sensor to differentiate between energy levels, and to obtain information about a material's composition. The advantages of such technology include low-dose imaging capacities, minimization of metal artifacts, separate reconstruction of soft and hard tissues, more efficient segmentation algorithms for tooth and bone features, and improved pathology detection [26].

2.4. Advances in Volume Reconstruction

Stored as 2D projection frames, the native raw data first undergo several pre-processing steps (*e.g.* offset and gain corrections), then are processed to create a volumetric dataset by reconstruction. Almost all CBCT machines involve filtered back-projection (FBP) with the Feldkamp-Davis-Kress (FDK) algorithm, known for its simplicity and fast reconstruction times [17]. This reconstruction method is nevertheless highly sensitive to artefacts, noise and scatter [27], particularly when the exposure rate and the number of x-ray projections are decreased. To obtain smaller voxel sizes, and thereby improved spatial resolution, higher radiation doses may be required which goes counter to the concept of radiation minimization. Hence, intensive research is now being performed into alternative methodologies such as iterative or hybrid iterative/analytical reconstruction algorithms [25]. Various forms of *a priori* information are incorporated (*e.g.* modelling of scatter radiation, beam hardening) to obtain new methods for low-dose CBCT imaging with sufficient contrast-to-noise ratio [28, 29]. Whereas FBP methods typically require only one back projection operation, each iteration generally requires at least one forward and one back projection [30]. Application of iterative algorithms to high-resolution CBCT imaging involves a computational burden that can be challenged using graphical processing units *i.e.* GPUs [31].

2.5. Advances in Image Quality

Despite constant improvements in image quality, each CBCT acquisition and reconstruction introduces noise and artefacts specific to its operating mode, which can be responsible for obscuring or mimicking pathology [32]. Artefacts arise from unit-related, object-related or patient-related factors; they usually appear as stripe-like and ring-like patterns (black-and-white), double contours, and blurring in the reconstructed images [33].

The overall system noise is constantly reduced by improving the quality of the sensors and signal transmission system. Patient motion and metal-related artefacts are the two most problematic ones. Metal artefacts appear because of X-ray beam hardening and the back-projection reconstruction method [17, 27], which are responsible for areas of hypodense perturbations, black or white radial streaks centered

on metal structures, and the presence of a black border near dense structures (*e.g.* implant, endodontic post, inlay/metal core). Metal artefact reduction algorithms (Fig. 1) and image data processing methods have been developed to improve image quality [34]. Motion artefacts appear as lack of sharpness and counteract the theoretical high spatial resolution [9]. Motion compensation algorithms have been developed [35] to supplement mechanical means (*e.g.* head restraints, bite support). In the future, precise information about patient movement during acquisition (*e.g.* by tracking marker movements) could be added to the reconstruction process [36].

2.6. Challenges in Optimization of Exposure in CBCT

While the dose and the subsequent risks arising from dentomaxillofacial imaging are small at the individual level, the radiation dose accumulates over a patient's lifetime. Clinicians ordering dental CBCT should be mindful that each image adds incrementally to the lifetime attributable risk of radiation-induced cancer. In a recent meta-analysis of published data [37], adult effective doses ranged from 5-652 μSv for small FOVs, 9-560 μSv for medium FOVs and 46 to 1073 μSv for large FOVs. The range of doses may vary on using low-dose and high-definition protocols provided by the manufacturers [37]. Children are more sensitive to radiation, particularly in the thyroid gland, gonads and breast tissue, with higher cancer risk at a younger age [37, 38]. A 2010 New York Times article triggered a worldwide discussion on the safety of CBCT scans for orthodontic and other dental purposes [39]. Dental organizations such as the American Association of Endodontists and the American Academy of Oral and Maxillofacial Radiography published initial CBCT position statements in 2011 that have since been revised. Compared with traditional medical multi-slice computed tomography (MSCT), CBCT uses much lower radiation doses. Although new ultra-low dose MSCT protocols with iterative reconstruction are being explored for the craniofacial area [40], the same improvements are expected from head-and-neck CBCT with extreme low-dose protocols [29].

The "as low as reasonably achievable" (ALARA) radiation dosage principle requires healthcare providers to weigh the potential benefit of diagnostic information against the expense and risk of the imaging procedure. Recently,

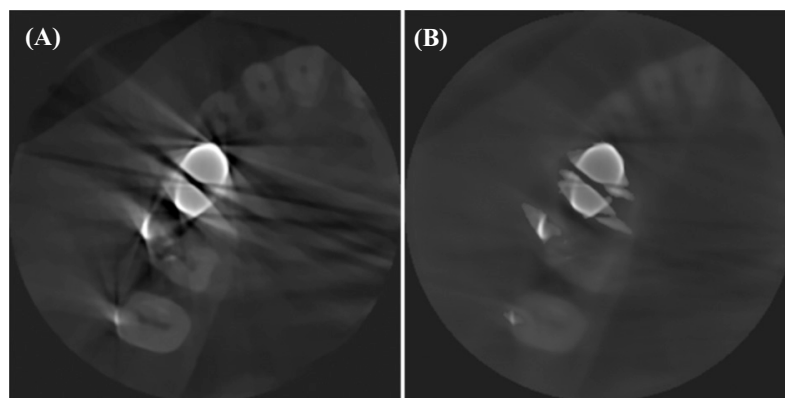


Fig. (1). Example of metallic artefact reduction algorithm; without (A) and with (B) algorithm. Courtesy of Carestream Dental (Marne La Vallee, France).

ALARA became the ALADA principle “as low as diagnostically acceptable” [41] or ALARP “as low as reasonably practicable”. Radiation dose and image quality are inextricably linked; exposure parameters should be carefully chosen based on the specific diagnostic question (*e.g.* root fractures, periapical bone loss, temporomandibular joint), patient size and age, and CBCT machine [42]. The radiation dose to patients can be reduced without causing a significant impact on image quality and therefore diagnostic accuracy. Future developments in dose optimization strategies will help to define case-by-case guidelines [41, 43]. For example, while a proper diagnosis of periapical pathosis requires higher exposure parameters compared to implant planning, up to 45% dose reduction can be achieved using 180 degrees rotation instead of 360 degrees, without compromising diagnostic information [44]. An optimized exposure protocol based on head circumference could further reduce the radiation dose per individual by 7% to 50% [43]. For low-dose protocols, reducing the mA instead of the kVp results in a smaller image quality degradation [45].

3. CLINICAL USE OF CBCT IN ORAL MEDICINE: A FULL SPECTRUM OF POTENTIAL APPLICATIONS

3.1. Justification of CBCT Imaging Examinations

A CBCT exam should be prescribed only when the diagnostic yield will benefit patient care, enhance patient safety, or significantly improve clinical outcomes. To limit the radiation dose, the smallest FOV appropriate to image the specific anatomical area of interest should be used [46, 47]. CBCT is used in many clinical situations when soft tissue discrimination is not the reason for the exam [48]. Several anatomical structures can be viewed depending on the FOV size (Table 1).

Table 1. List of bone structures and regions of the head and neck that can be imaged using CBCT (depending on field of view size).

Naso-oropharyngeal airway and paranasal sinuses
Sinus frontal, maxillary, sphenoid, ethmoid
Inferior, middle, superior meatus
Cavum, pharyngeal tonsils, Rosenmuller dimple
Palatine tonsils
Glosso-epiglottic furrow
Face skeleton
Piriform aperture, nasal bone and vomer
Maxilla, palatine and zygomatic bones
Mandible, foramen mandibular and mental
Lacrimal bone
Concha – inferior nasal
Hyoid bone

Temporomandibular joint
Mandibular condyle
Temporal fossa and articular tubercula
Cervical vertebrae region
Atlas with arches (anterior and posterior)
Axis with dens (odontoid process)
Cervical vertebrae
Outer, middle and internal ear
Auditory meatus (external)
Malleus, Stapes, Incus, Semicircular canals, Cochlea
Auditory meatus (internal)
Temporal bone – mastoid process
Skull base and calvarial
<i>Frontal bone</i>
<i>Sphenoid bone (body and both wings)</i>
Fossa – hypophyseal
Canal – optic
Clivus
Fissure – inferior and superior orbital
Foramen rotundum, ovale, lacerum, spinosus
Canal – carotid
<i>Ethmoid bone</i>
Concha – middle and superior nasal
<i>Temporal bone</i>
Petrous part
Styloid process
Shell
<i>Occipital bone, condyle, protuberance (external)</i>
Foramen – jugular, magnum, stylomastoid
<i>Parietal bone</i>
Suture – coronal, sagittal, lambdoid
Focal calcifications
Lymph node, tonsils
Sinuses
Vessels (<i>e.g.</i> facial vessels, internal carotid)
Gland (salivary, pineal, hypophysis)
Ligaments (mainly stylohyoid, stylomandibular)
<i>Falx cerebri</i>

3.2. Applications in Endodontics

CBCT is becoming the standard of care for many imaging tasks in endodontics. For contradictory and nonspecific clinical signs and symptoms, CBCT may be the imaging modality of choice. Previously undetected, painless radiolucencies become visible on 3D CBCT images in endodontics (Fig. 2A-H). Even small FOV scans, routinely used in endodontic imaging, yield unexpected, incidental findings [49]. Numerous authors have found 20-40% more radiolucencies on CBCT images in comparison to traditional periapical radiographs [50-52]. Research on the actual condition, *i.e.* whether the observed areas truly represents inflammation, or may in some cases represent cystic or scar tissue, remains limited [53]. A number of radiolucencies or radiopacities can mimic endodontic lesions [54]. To date, histologic examination of biopsied tissue remains the gold standard to distinguish between cysts and apical granulomas. The correlation between CBCT gray values and histopathology is not clear [55]. Treating clinically pain-free teeth might not always lead to a positive end-result for the affected patient and could lead to more invasive treatment or overtreatment [56].

In trauma cases, the severity of facial or dental trauma determines the need for CBCT imaging [57]. CBCT scans reveal alveolar, root fractures and are helpful in repositioning bone and teeth (Fig. 2I-M). Complicated fractures that include the pulp space can influence restorability and crown-to-root ratio [58]. To avoid unnecessary loss of tooth structure, small FOV CBCT should be considered for intra-appointment identification and localization of missed or calcified canals, for apical treatment in immature teeth, and in dental developmental anomalies (Fig. 3A-K).

When planning retreatment of symptomatic or diseased endodontically treated teeth, negative prognostic factors might change the treatment plan towards extraction, *e.g.* vertical root fractures, resorptions or perforations. Analysis can confirm the number of radiolucencies, the roots involved, the exact distances between root canals, the total of missed or filled canals, and the location of intracanal obstructions [59]. On periapical radiographs, the diameter of radiolucencies is less than registered in CBCT images [60]. In addition, axial and coronal images determine the type of cortical bone plate defect created by the lesion [61]. Success rates of RCT determined by CBCT

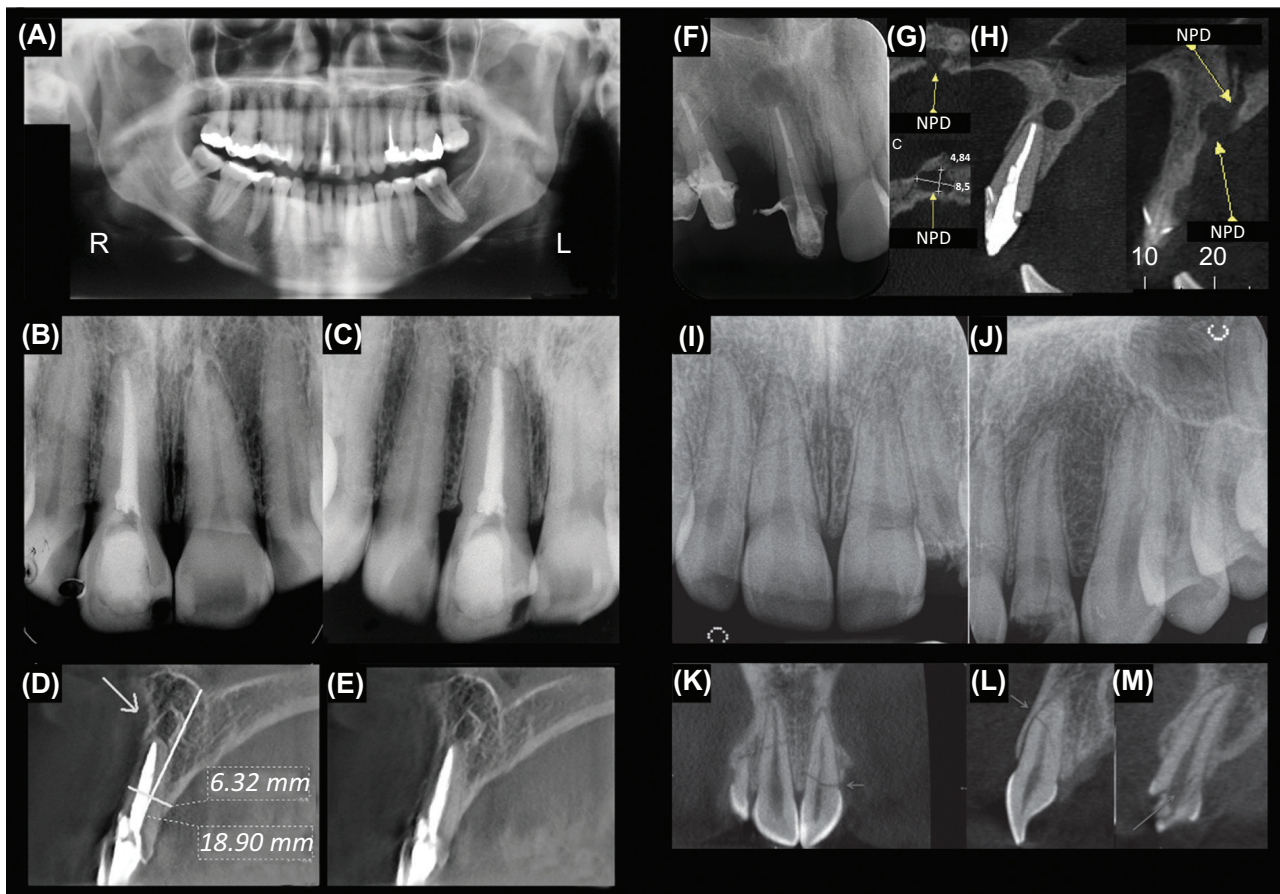


Fig. (2). The panoramic radiograph (A) and two horizontally shifted periapical (PA) radiographs (B, C) show a healthy periapex in an upper right incisor. In a sagittal CBCT view of the same tooth (D, E), a periapical radiolucency is visible. (F, G, H) CBCT images of the anterior maxilla show that the apical radiolucency projected over the right maxillary incisor in a PA image is in fact the anterior palatine foramen. (I, J) Periapical radiographs of the left and right upper anterior maxilla after trauma. The images did not show the extent of all fractures present. (K, L, M) Coronal and sagittal CBCT images confirm horizontal root fractures in both upper central anterior teeth and a crown-to-root fracture in left lateral upper incisor.

A-E modified from Estrela *et al.* Journal of Endodontics 2008; 34: 273-279, reprinted with permission. F-H modified from Faitaroni *et al.* Journal of Endodontics 2011; 37: 403-410, reprinted with permission. I-M modified from Cohenca & Silverman, Dental Traumatology 2017; 33: 321-328, reprinted with permission.

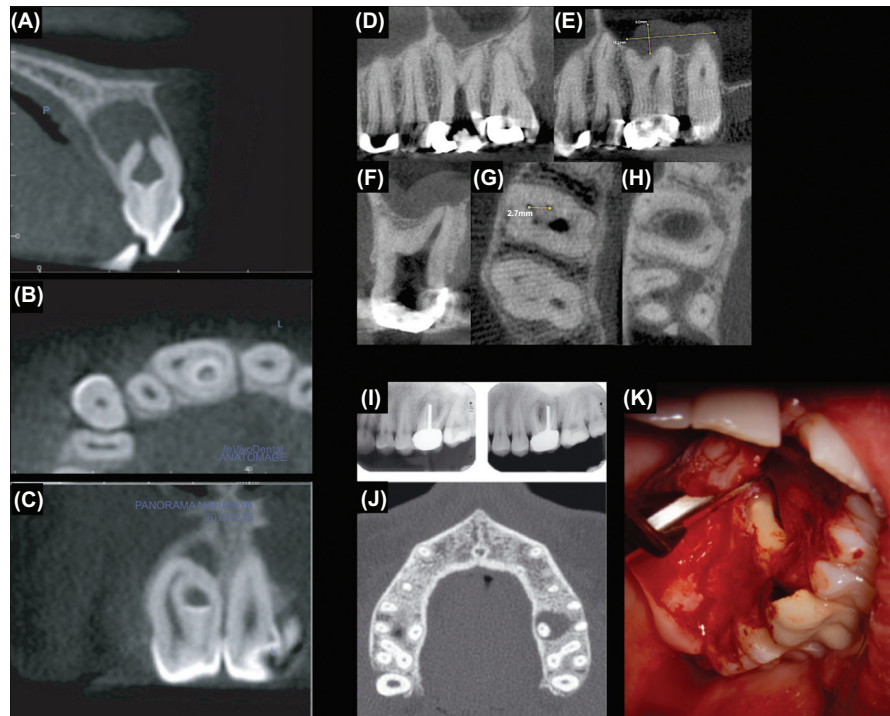


Fig. (3). (A, B, C) An Oehlers type 3 dens-in-dente with a vital main canal and an apical lesion due to an infected invagination. A 3D plastic model of the tooth was constructed using CBCT data to plan the access cavity. CBCT sections (D-H) of a taurodontic maxillary right first molar. Intraoperative CBCT was used to determine canal locations, the extent of the pulp chamber and furcation depth. (I, J, K) Periapical radiographs of a previously treated left upper molar scheduled for retreatment. An axial CBCT view illustrated that only the palatal root was involved. (K) Instead of non-surgical retreatment, the pathosis was addressed surgically with a palatal flap. A-C modified from Kfir *et al.* *International Endodontics Journal* 2013; 46: 275-288, reprinted with permission. D-H modified from Ball *et al.* *Journal of Endodontics* 2013; 39: 548-557, reprinted with permission. I-K modified from Huumonen *et al.* *International Endodontic Journal* 2006; 39: 827-833, reprinted with permission.

appear to be 10-40% lower than that diagnosed with periapical radiographs [50, 59, 62].

On CBCT, streaking and beam hardening artifacts from metal implants and radio-opaque root fillings increase the difficulty of diagnosing lesions and root fractures and can lead to misinterpretation of remaining root dentin thickness [63]. To circumvent misdiagnosis, a map reading strategy focuses on axial slices of a volume [64].

CBCT measurements can avoid iatrogenic mishaps, help to keep endodontic surgical access as small as practical (Fig. 3K), and identify the size and location of lesions and vulnerable anatomical structures such as the maxillary sinus, mental foramen and mandibular canal [59, 65, 66]. CBCT interpretation for healing of periapical lesions after endodontic microsurgery is more precise than follow-up by periapical films [67]. Apical surgery procedures may cause or worsen cracks or root fractures and the crown-to-root ratio of a tooth may become compromised after surgery [68]. Surgical outcomes with persistent lesions on CBCT scans should be performed carefully, as no action other than monitoring may be required [53].

3.3. Applications in Oral and Maxillofacial Surgery and Implantology

CBCT is now part of the standard educational process for residents and it is replacing panoramic imaging in private

offices for both diagnosis and surgical treatment planning [6]. CBCT is usually indicated for pathology, orthodontic and orthognathic surgery [69], trauma, reconstructive surgery planning as well as dental applications (*e.g.* impacted teeth or dental implant). CBCT may be indicated for infections, salivary gland pathology, facial pain or TMJ [6].

CBCT imaging for patients requiring dental implants is potentially useful for i) The diagnosis and assessment of treatment outcomes, ii) Implant treatment planning, and iii) Anatomic characterization [70]. The use of postoperative CBCT should be restricted to specific complications, such as postoperative infections related to the maxillary sinus or damage of neurovascular structures [71]. Visualization and assessment of the internal structure of soft tissues and lesions are limited or impossible. The correlation with Hounsfield Units for bone density quantification is still challenging [10, 48] even though the results with correction algorithms are promising [72].

3.4. Applications for Temporomandibular Joint Disorders

The Research Diagnostic Criteria for Temporomandibular Disorders (RDC/TMD) has recommended CT as the modality of choice for evaluation of TMJ bone changes [73]. Bony surfaces can be explored in all dimensions to identify pathological changes such as cortical erosion, subchondral sclerosis, flattening, osteophytes and subchondral cysts [74].

Paired with CBCT, MRI is the gold standard for imaging the intra-articular soft tissue components of the TMJ [73]. The volume fusion of MRI and CBCT acquisitions by registration may bring a significant clinical value [75].

3.5. Applications in Periodontology

Although current evidence-based guidelines are scarce, CBCT may be useful for the diagnosis of periodontal disease and treatment planning [1, 76]. According to Scarfe *et al.*, limited FOV, high-resolution protocols with CBCT are indicated for an accurate view of the morphology and topography of localized defects, such as furcation involvement and intrabony vertical and buccal/lingual defects, and to assess the effects of regenerative therapy. This can contribute to the clinical decision and improve clinical efficiency [1]. However, unreliable Hounsfield values derived from CBCT acquisitions [72] and the sensitivity to metal artefacts may limit their use in periodontology.

3.6. Applications in Orthodontics

CBCT is an efficient tool for the diagnosis and treatment planning of many complex clinical orthodontics situations, e.g. in facial growth, tooth eruption disturbances or impacted teeth, cleft-lip, cleft palate and skeletal discrepancies, and in orthognathic or craniofacial surgery [77, 78]. Volumetric 3D cephalometric analyses and integration of surface photographs (2D or 3D) with CBCT open the way for advanced analysis, treatment planning and predictive computer-assisted simulations, and better evaluation of soft tissue changes after superimposition of pre- and post-treatment exams [78].

3.7. Applications in ENT Medicine

CBCT examinations can replace MDCT in some otolaryngology tasks. CBCT be used to explore qualitatively and quantitatively the upper pharyngeal airway, the presence and severity of obstructive sleep apnea [79, 80]. For example, it can help to identify risk factors and/or to predict treatment outcomes (e.g. discovery of restrictions of the aeropharyngeal sector, adenotonsillar hypertrophy, deviated nasal septum, turbinate hypertrophy). The aerodynamic characteristics of the airflow within the oropharynx can also be modelled [81].

High-resolution CBCT exams make it possible to precisely assess the fine structures of the inner and middle ear, and cranial base. For example, the size and shape of the cochlea or the post-operative position of an intra-cochlear electrode array may be explored, the ossicular chain, otospongiosis sites, most malformations and dysplasia, traumatic lesions or chronic otitis [82]. Since the radiation level is lower than in conventional CT, CBCT is ideal for repeat examinations, postoperative follow-up and pediatric exploration [82].

3.8. CBCT within a CAD/CAM Line

CBCT images can be directly used for computer-aided design/computer-aided manufacturing (CAD/CAM) restorations with clinically acceptable marginal adaptation [83]. More commonly, DICOM images are combined in CAD/

CAM software packages with acquisitions made with intra- or extra-oral impression scanners that provide high-accuracy for the digitization of oral surfaces [84]. Initially restricted to implant planning, implant surgical guides and immediate provisional prosthesis [85, 86], and now coupled with digital 3D printing, CAD/CAM software packages can be applied to many areas: occlusal splints with correlation of mandibular movement [87], mandibular advancement splints for treatment of obstructive sleep apnea [88], orthograde or retrograde endodontic-guided treatments [89, 90], custom bone grafts [91], orthognathic surgical transfer splints [92], or root analogue custom dental implants [93].

3.9. CBCT as a Measuring Tool

In CBCT, the voxels are cubic (isotropic) and metrically accurate which provides reliable measurements. This could apply to dental arches, teeth or parts of a tooth, such as the root canal, which are important in many dental disciplines, including orthodontics, implantology, and endodontics. A segmentation process can provide a variety of information to clinicians and researchers [94]. In endodontics, segmentation can make the root canal anatomy easier to understand [95] and help with a surgical approach to cysts [96]. In orthodontics, tooth segmentation is helpful for viewing the positions of roots, not only the crowns [97]. It also makes it possible to compute the intra-osseous tooth volume and to better predict the behavior of the resistance center of the teeth [98]. In implantology, knowledge of the segmented bone volume or segmented sinus volume makes it possible to predict the exact volume of biological material needed for pre-implant reconstruction [99]. The segmented volume can also be used to mimic the transgingival root volume, leading to a customized prosthetic abutment [100]. In forensic odontology, the tooth volume can be used to estimate an individual's age [101]. Automatic segmentation with CBCT can be used in the field of clinical dentistry for reliable measurements if some manual refinements are applied [102].

4. CBCT IN ORAL MEDICINE BASED ON PATIENT-CENTERED CARE PRINCIPLES

One of the major challenges regarding contemporary healthcare is ensuring that technological development do not take precedence over admitted standards of care. In oral medicine (as in medicine), patient (or person) centered care (PCC) is a core pillar of dental education and practice. Thus, recent advances in CBCT should be contextualized within broader frames of reference. In particular, the growing use of CBCT investigations in dentistry raises important ethical and public health concerns, which can be addressed according to PCC principles [103]. Depending on whether we consider the individual or the collective level, two ground rules fulfill the PCC requirements: recognizing the patient as a person and incorporating CBCT technology in an integrated dental organization (Fig. 4A-D).

4.1. Recognizing the Patient as a Person

Recognizing the patient as a person implies active listening, making patients an active participant for both the diagnosis and intervention steps of meetings [104]. Often, special efforts are required to ensure that patients understand the

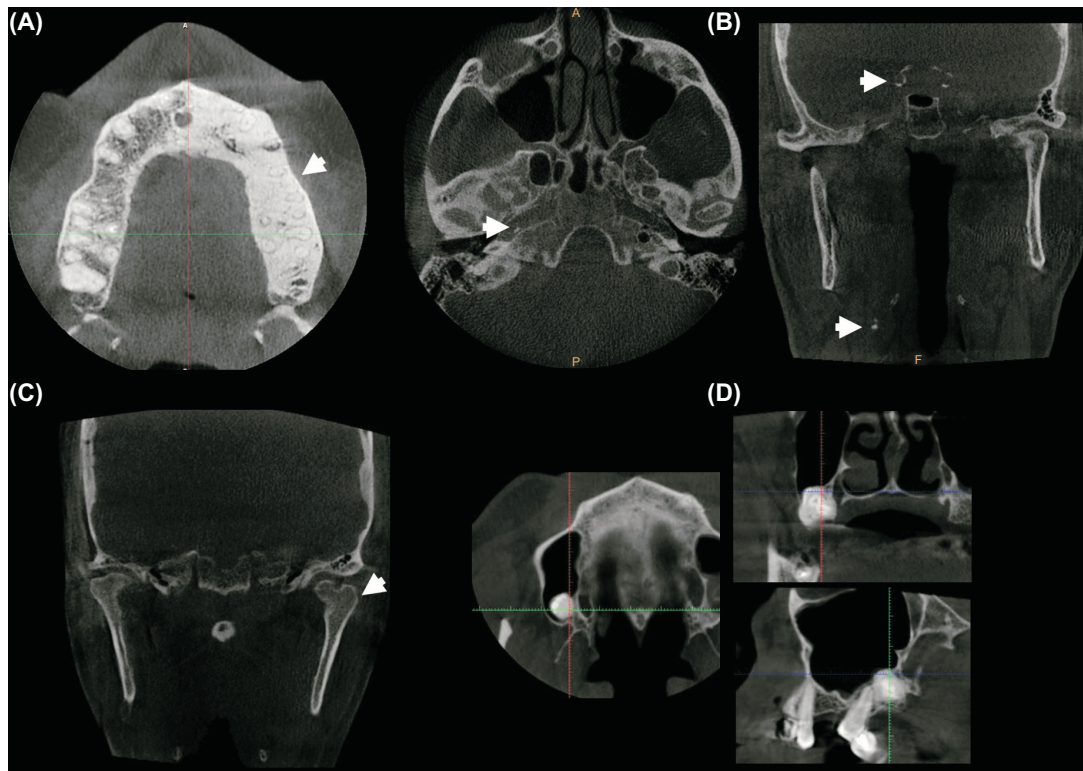


Fig. (4). (A) Fibrous dysplasia (white arrow) discovered incidentally in a 58-year-old healthy man. No intervention was required, and a follow-up had been set up. (B) Carotid artery calcifications (white arrows) discovered incidentally all along the path of the internal carotid artery of a 60-year-old man (at the carotid bifurcation, inside the petrous part, in the supra-cavernous section). The patient was referred to his general practitioner. (C) Bifid condyle discovered incidentally (white arrow). No clinical manifestations in the temporomandibular joint. (D) Compound odontoma discovered incidentally in a 35-year-old woman. No clinical manifestations.

implications of specialized investigations for which informed consent is required [104].

In particular, the possibility of incidental findings should be discussed with the patient prior to the radiologic procedure [105]. Studies have reported a high prevalence of incidental findings, defined by Scarfe *et al.* as an “occult entity discovered unexpectedly on an imaging examination performed for an unrelated reason” [106]. With the improvement in CBCT resolution and the FOV enlargement, the likelihood of such incidental findings increases and will continue to increase in the future. An appropriately trained general dentist, a specialized oral-maxillofacial radiologist (*i.e.* OMFR) or a medical radiologist should review CBCT examinations. For non-dentoalveolar issues, small FOV (*e.g.* temporal bone) and all craniofacial CBCT images, a radiological report should be prepared by an OMFR or a medical radiologist [107]. Depending on the location and the urgency of referrals, several medical specialties may be involved, *e.g.* orthodontists, dentists, internists, endocrinologists, vascular physician, neurologists, otolaryngologists, family physicians or oral surgeons. As an example, carotid artery calcifications detected during a CBCT exam may be a marker of increased cardiovascular risk for the patient and may require referral to a general practitioner or a specialist [106, 108]. The discovery of abnormal findings in the *sella turcica* may require referral to an endocrinologist for putative pituitary adenoma [109].

Patients should be clearly informed that the entire volume will be reviewed in full using a systematic approach [108], and that all findings will be recorded in the patient’s record and explained to the patient [105]. A patient’s refusal to undergo the radiologic examination must also be respected, and alternative pathways for the diagnosis and/or treatment should then be discussed with him or her, relating to the risk-benefit balance.

4.2. Incorporating CBCT Technology into an Integrated Dental Organization

Integrated health systems have been promoted as a means to improve access, quality and continuity of services in a more efficient way, especially for people with complex needs [110]. When it comes to CBCT use within the dental workforce, a balance between two contradictory trends should be found.

On one hand, there are numerous situations where CBCT benefits patient care, enhances patient safety and significantly improves clinical outcomes [46]. Given the ongoing development of this technology and the rapid commercialization of CBCT devices, dentists should at least be able to recognize clinical situations where CBCT can meet a patient’s needs.

On the other hand, CBCT is not a panacea and should not be used in every case. From a public health perspective, there is no need for all the dentists to have a CBCT device in

their practices. Instead, clinical pathways between different specialists may be actively organized.

CONCLUSION

Virtually all disciplines of oral medicine can benefit from CBCT as a second or even first-line examination. Its main limitations are the additional radiation dose in relation, and in addition to 2D, a considerable risk of artefacts (especially linked to patient movement and presence of metal objects), and the significant learning curve for reading these acquisitions, given the risk of incidental findings in volumes. In the near future, expected technological progress in terms of sensors and reconstruction algorithms will lead to the development of ultra-low dose protocols (doses approaching or reaching 2D doses) while providing high resolution and good image quality.

CONSENT FOR PUBLICATION

Not applicable.

CONFLICT OF INTEREST

The authors declare no conflict of interest, financial or otherwise.

FUNDING

None.

ACKNOWLEDGEMENTS

The authors thank Jean-Marc Ingèse and Vincent Loustauneau (Carestream Dental, Marne La Vallee, France) and Susan Becker for their help in proofreading, Drs Elisabeth Coudrais, Pierre Monsarrat, Damien Ostrowski for some CBCT exams.

REFERENCES

- Scarfe WC, Azevedo B, Pinheiro LR, Priaminiarti M, Sales MAO. The emerging role of maxillofacial radiology in the diagnosis and management of patients with complex periodontitis. *Periodontol* 2000 2017; 74(1): 116-39. <http://dx.doi.org/10.1111/prd.12193> PMID: 28429477
- Scarfe WC, Farman AG, Sukovic P. Clinical applications of cone-beam computed tomography in dental practice. *J Can Dent Assoc* 2006; 72(1): 75-80. PMID: 16480609
- Mozzo P, Procacci C, Tacconi A, Martini PT, Andreis IA. A new volumetric CT machine for dental imaging based on the cone-beam technique: preliminary results. *Eur Radiol* 1998; 8(9): 1558-64. <http://dx.doi.org/10.1007/s003300050586> PMID: 9866761
- Hatcher DC. Operational principles for cone-beam computed tomography. *J Am Dent Assoc* 2010; 141(141): 3S-6S. <http://dx.doi.org/10.14219/jada.archive.2010.0359> PMID: 20884933
- Setzer FC, Hinckley N, Kohli MR, Karabucak B. A survey of cone-beam computed tomographic use among endodontic practitioners in the United States. *J Endod* 2017; 43(5): 699-704. <http://dx.doi.org/10.1016/j.joen.2016.12.021> PMID: 28292601
- Carter JB, Stone JD, Clark RS, Mercer JE. Applications of cone-beam computed tomography in oral and maxillofacial surgery: an overview of published indications and clinical usage in United States academic centers and oral and maxillofacial surgery practices. *J Oral Maxillofac Surg* 2016; 74(4): 668-79. <http://dx.doi.org/10.1016/j.joms.2015.10.018> PMID: 26611374
- Hol C, Hellén-Halme K, Torgersen G, Nilsson M, Møystad A. How do dentists use CBCT in dental clinics? A Norwegian nationwide survey. *Acta Odontol Scand* 2015; 73(3): 195-201. <http://dx.doi.org/10.3109/00016357.2014.979866> PMID: 25415368
- Parashar V, Whites E, Monsour P, Chaudhry J, Geist JR. Cone beam computed tomography in dental education: a survey of US, UK, and Australian dental schools. *J Dent Educ* 2012; 76(11): 1443-7. PMID: 23144479
- Hanzelka T, Dusek J, Ocsek F, *et al.* Movement of the patient and the cone beam computed tomography scanner: objectives and possible solutions. *Oral Surg Oral Med Oral Pathol Oral Radiol* 2013; 116(6): 769-73. <http://dx.doi.org/10.1016/j.o000.2013.08.010> PMID: 24237728
- Scarfe WC, Li Z, Aboelmaaty W, Scott SA, Farman AG. Maxillofacial cone beam computed tomography: essence, elements and steps to interpretation. *Aust Dent J* 2012; 57(Suppl. 1): 46-60. <http://dx.doi.org/10.1111/j.1834-7819.2011.01657.x> PMID: 22376097
- Kiljunen T, Kaasalainen T, Suomalainen A, Kortensniemi M. Dental cone beam CT: a review. *Phys Med* 2015; 31(8): 844-60. <http://dx.doi.org/10.1016/j.ejmp.2015.09.004> PMID: 26481816
- Molen AD. Considerations in the use of cone-beam computed tomography for buccal bone measurements. *Am J Orthod Dentofacial Orthop* 2010; 137(4): S130-5. <http://dx.doi.org/10.1016/j.ajodo.2010.01.015> PMID: 20381753
- Macleod I, Heath N. Cone-Beam Computed Tomography (CBCT) in dental practice. *Dent Update* 2008; 35(9): 590-2. <http://dx.doi.org/10.12968/denu.2008.35.9.590> PMID: 19065875
- Adibi S, Zhang W, Servos T, O'Neill PN. Cone beam computed tomography in dentistry: what dental educators and learners should know. *J Dent Educ* 2012; 76(11): 1437-42. PMID: 23144478
- Razavi T, Palmer RM, Davies J, Wilson R, Palmer PJ. Accuracy of measuring the cortical bone thickness adjacent to dental implants using cone beam computed tomography. *Clin Oral Implants Res* 2010; 21(7): 718-25. <http://dx.doi.org/10.1111/j.1600-0501.2009.01905.x> PMID: 20636726
- Brüllmann D, Schulze RKW. Spatial resolution in CBCT machines for dental/maxillofacial applications-what do we know today? *Dentomaxillofac Radiol* 2015; 44(1): 20140204. <http://dx.doi.org/10.1259/dmfr.20140204> PMID: 25168812
- Pauwels R, Araki K, Siewerdsen JH, Thongvigitmanee SS. Technical aspects of dental CBCT: state of the art. *Dentomaxillofac Radiol* 2015; 44(1): 20140224. <http://dx.doi.org/10.1259/dmfr.20140224> PMID: 25263643
- Chakeres DW. Clinical significance of partial volume averaging of the temporal bone. *AJNR Am J Neuroradiol* 1984; 5(3): 297-302. PMID: 6426283
- Scarfe WC, Farman AG. What is cone-beam CT and how does it work? *Dent Clin North Am* 2008; 52: 707-30. <http://dx.doi.org/10.1016/j.cden.2008.05.005>
- Kwong JC, Palomo JM, Landers MA, Figueroa A, Hans MG. Image quality produced by different cone-beam computed tomography settings. *Am J Orthod Dentofacial Orthop* 2008; 133(2): 317-27. <http://dx.doi.org/10.1016/j.ajodo.2007.02.053> PMID: 18249300
- Nemtoi A, Czink C, Haba D, Gahleitner A. Cone beam CT: a current overview of devices. *Dentomaxillofac Radiol* 2013; 42(8): 20120443. <http://dx.doi.org/10.1259/dmfr.20120443> PMID: 23818529
- Kim DW, Han JC, Yun S, Kim HK. Aging of imaging properties of a CMOS flat-panel detector for dental cone-beam computed tomography. *J Instrum* 2017; 12: P01005. <http://dx.doi.org/10.1088/1748-0221/12/01/P01005>
- Cha BK, Jeon S, Seo C-W. X-ray performance of a wafer-scale CMOS flat panel imager for applications in medical imaging and nondestructive testing. *Nucl Instrum Methods Phys Res Sect A* 2016; 831: 404-9. <http://dx.doi.org/10.1016/j.nima.2016.04.117>
- Inglesse J, Bothorel S, Loustauneau V, Rankin-Parobek D. Dental imaging with photon-counting detector, 2017. Available from: <https://www.google.com/patents/US9743893>

- [25] Panetta D. Advances in X-ray detectors for clinical and preclinical computed tomography. *Nucl Instrum Methods Phys Res Sect A* 2016; 809: 2-12.
<http://dx.doi.org/10.1016/j.nima.2015.10.034>
- [26] Inglese J, Schildkraut J. Volume image reconstruction using data from multiple energy spectra, 2016. Available from: <http://www.google.com/patents/US9269168>
- [27] Schulze R, Heil U, Gross D, et al. Artefacts in CBCT: a review. *Dentomaxillofac Radiol* 2011; 40(5): 265-73.
<http://dx.doi.org/10.1259/dmfr/30642039> PMID: 21697151
- [28] Liu W, Rong J, Gao P, Liao Q, Lu H. Algorithm for x-ray beam hardening and scatter correction in low-dose cone-beam CT: phantom studies. In: *International Society for Optics and Photonics; San Diego, California, United States; SPIE*; 2016; pp. 978332.
- [29] Park JC, Zhang H, Chen Y, et al. Priori mask guided image reconstruction (p-MGIR) for ultra-low dose cone-beam computed tomography. *Phys Med Biol* 2015; 60(21): 8505-24.
<http://dx.doi.org/10.1088/0031-9155/60/21/8505> PMID: 26485492
- [30] Cao Q, Zbijewski W, Sisniega A, Yorkston J, Siewerdsen JH, Stayman JW. Multiresolution iterative reconstruction in high-resolution extremity cone-beam CT. *Phys Med Biol* 2016; 61(20): 7263-81.
<http://dx.doi.org/10.1088/0031-9155/61/20/7263> PMID: 27694701
- [31] Du Y, Yu G, Xiang X, Wang X. GPU accelerated voxel-driven forward projection for iterative reconstruction of cone-beam CT. *Biomed Eng Online* 2017; 16(1): 2.
<http://dx.doi.org/10.1186/s12938-016-0293-8> PMID: 28086901
- [32] Boas FE, Fleischmann D. CT artifacts: causes and reduction techniques. *Imaging Med* 2012; 4: 229-40.
<http://dx.doi.org/10.2217/iim.12.13>
- [33] Spin-Neto R, Wenzel A. Patient movement and motion artefacts in cone beam computed tomography of the dentomaxillofacial region: a systematic literature review. *Oral Surg Oral Med Oral Pathol Oral Radiol* 2016; 121(4): 425-33.
<http://dx.doi.org/10.1016/j.ooolo.2015.11.019> PMID: 26972541
- [34] Queiroz PM, Rovaris K, Gaêta-Araujo H, et al. Influence of artifact reduction tools in micro-computed tomography images for endodontic research. *J Endod* 2017; 43(12): 2108-11.
<http://dx.doi.org/10.1016/j.joen.2017.07.024> PMID: 29033091
- [35] Gu J, Bae W, Ye JC. Translational motion correction algorithm for truncated cone-beam CT using opposite projections. *J X-Ray Sci Technol* 2017; 2017: 1-18.
<http://dx.doi.org/10.3233/XST-16231>
- [36] Spin-Neto R, Matzen LH, Schropp L, Sørensen TS, Gottfredsen E, Wenzel A. Accuracy of video observation and a three-dimensional head tracking system for detecting and quantifying robot-simulated head movements in cone beam computed tomography. *Oral Surg Oral Med Oral Pathol Oral Radiol* 2017; 123(6): 721-8.
<http://dx.doi.org/10.1016/j.ooolo.2017.02.010> PMID: 28412232
- [37] Ludlow JB, Timothy R, Walker C, et al. Effective dose of dental CBCT-a meta-analysis of published data and additional data for nine CBCT units. *Dentomaxillofac Radiol* 2015; 44(1): 20140197.
<http://dx.doi.org/10.1259/dmfr.20140197> PMID: 25224586
- [38] Choi E, Ford NL. Measuring absorbed dose for i-CAT CBCT examinations in child, adolescent and adult phantoms. *Dentomaxillofac Radiol* 2015; 44(6): 20150018.
<http://dx.doi.org/10.1259/dmfr.20150018> PMID: 25785822
- [39] Bogdanich W, McGinty J. Radiation worries for children in dentists' chairs, 2010. Available from: <http://www.nytimes.com/2010/11/23/us/23scan.html>
- [40] Widmann G, Al-Shawaf R, Schullian P, Al-Sadhan R, Hörmann R, Al-Ekrish AA. Effect of ultra-low doses, ASIR and MBIR on density and noise levels of MDCT images of dental implant sites. *Eur Radiol* 2017; 27(5): 2225-34.
<http://dx.doi.org/10.1007/s00330-016-4588-8> PMID: 27655306
- [41] Goulston R, Davies J, Horner K, Murphy F. Dose optimization by altering the operating potential and tube current exposure time product in dental cone beam CT: a systematic review. *Dentomaxillofac Radiol* 2016; 45(3): 20150254.
<http://dx.doi.org/10.1259/dmfr.20150254> PMID: 26732433
- [42] Ludlow JB, Walker C. Assessment of phantom dosimetry and image quality of i-CAT FLX cone-beam computed tomography. *Am J Orthod Dentofacial Orthop* 2013; 144(6): 802-17.
<http://dx.doi.org/10.1016/j.ajodo.2013.07.013> PMID: 24286904
- [43] Pauwels R, Jacobs R, Bogaerts R, Bosmans H, Panmekiate S. Determination of size-specific exposure settings in dental cone-beam CT. *Eur Radiol* 2017; 27(1): 279-85.
<http://dx.doi.org/10.1007/s00330-016-4353-z> PMID: 27108296
- [44] Pauwels R, Zhang G, Theodorakou C, et al. SEDENTEXCT Project consortium. Effective radiation dose and eye lens dose in dental cone beam CT: effect of field of view and angle of rotation. *Br J Radiol* 2014; 87(1042): 20130654.
<http://dx.doi.org/10.1259/bjr.20130654> PMID: 25189417
- [45] Pauwels R, Silkosessak O, Jacobs R, Bogaerts R, Bosmans H, Panmekiate S. A pragmatic approach to determine the optimal kVp in cone beam CT: balancing contrast-to-noise ratio and radiation dose. *Dentomaxillofac Radiol* 2014; 43(5): 20140059.
- [46] American Dental Association Council on Scientific Affairs. The use of cone-beam computed tomography in dentistry: an advisory statement from the American Dental Association Council on Scientific Affairs. *J Am Dent Assoc* 2012; 143(8): 899-902.
<http://dx.doi.org/10.14219/jada.archive.2012.0295> PMID: 22855905
- [47] European Commission. Guidelines on CBCT for dental and maxillofacial radiology | SEDENTEXCT, 2012. Available from: <http://www.sedentext.eu/content/guidelines-cbct-dental-and-maxillofacial-radiology>
- [48] Kamburoğlu K. Use of dentomaxillofacial cone beam computed tomography in dentistry. *World J Radiol* 2015; 7(6): 128-30.
<http://dx.doi.org/10.4329/wjr.v7.i6.128> PMID: 26120381
- [49] Oser DG, Henson BR, Shiang EY, Finkelman MD, Amato RB. Incidental findings in small field of view cone-beam computed tomography scans. *J Endod* 2017; 43(6): 901-4.
<http://dx.doi.org/10.1016/j.joen.2017.01.033> PMID: 28359665
- [50] Lofthag-Hansen S, Huuonen S, Gröndahl K, Gröndahl H-G. Limited cone-beam CT and intraoral radiography for the diagnosis of periapical pathology. *Oral Surg Oral Med Oral Pathol Oral Radiol Endod* 2007; 103(1): 114-9.
<http://dx.doi.org/10.1016/j.tripleo.2006.01.001> PMID: 17178504
- [51] de Paula-Silva FWG, Wu M-K, Leonardo MR, da Silva LAB, Wesselink PR. Accuracy of periapical radiography and cone-beam computed tomography scans in diagnosing apical periodontitis using histopathological findings as a gold standard. *J Endod* 2009; 35(7): 1009-12.
<http://dx.doi.org/10.1016/j.joen.2009.04.006> PMID: 19567324
- [52] Estrela C, Bueno MR, Leles CR, Azevedo B, Azevedo JR. Accuracy of cone beam computed tomography and panoramic and periapical radiography for detection of apical periodontitis. *J Endod* 2008; 34(3): 273-9.
<http://dx.doi.org/10.1016/j.joen.2007.11.023> PMID: 18291274
- [53] Kruse C, Spin-Neto R, Reibel J, Wenzel A, Kirkevang L-L. Diagnostic validity of periapical radiography and CBCT for assessing periapical lesions that persist after endodontic surgery. *Dentomaxillofac Radiol* 2017; 46(7): 20170210.
<http://dx.doi.org/10.1259/dmfr.20170210> PMID: 28707526
- [54] Sirotheau CPF, Paiva FF, Souza de JA, et al. Nonendodontic lesions misdiagnosed as apical periodontitis lesions: series of case reports and review of literature. *J Endod* 2014; 40(1): 16-27.
<http://dx.doi.org/10.1016/j.joen.2013.08.021> PMID: 24331985
- [55] Guo J, Simon JH, Sedghizadeh P, Soliman ON, Chapman T, Enciso R. Evaluation of the reliability and accuracy of using cone-beam computed tomography for diagnosing periapical cysts from granulomas. *J Endod* 2013; 39(12): 1485-90.
<http://dx.doi.org/10.1016/j.joen.2013.08.019> PMID: 24238434
- [56] Mota de Almeida FJ, Huuonen S, Molander A, Öhman A, Kvist T. Computed tomography (CT) in the selection of treatment for root-filled maxillary molars with apical periodontitis. *Dentomaxillofac Radiol* 2016; 45(5): 20150391.
<http://dx.doi.org/10.1259/dmfr.20150391> PMID: 26985980
- [57] Andersson L, Andreasen JO, Day P, et al. International association of dental traumatology. International Association of Dental traumatology guidelines for the management of traumatic dental injuries: 2. Avulsion of permanent teeth. *Dent Traumatol* 2012; 28(2): 88-96.
<http://dx.doi.org/10.1111/j.1600-9657.2012.01125.x> PMID: 22409417
- [58] Cohenca N, Silberman A. Contemporary imaging for the diagnosis and treatment of traumatic dental injuries: A review. *Dent Traumatol* 2017; 33(5): 321-8.
<http://dx.doi.org/10.1111/edt.12339> PMID: 28317333

- [59] Huuomonen S, Kvist T, Gröndahl K, Molander A. Diagnostic value of computed tomography in re-treatment of root fillings in maxillary molars. *Int Endod J* 2006; 39(10): 827-33. <http://dx.doi.org/10.1111/j.1365-2591.2006.01157.x> PMID: 16948669
- [60] Tsai P, Torabinejad M, Rice D, Azevedo B. Accuracy of cone-beam computed tomography and periapical radiography in detecting small periapical lesions. *J Endod* 2012; 38(7): 965-70. <http://dx.doi.org/10.1016/j.joen.2012.03.001> PMID: 22703662
- [61] Yoshioka T, Kikuchi I, Adorno CG, Suda H. Periapical bone defects of root filled teeth with persistent lesions evaluated by cone-beam computed tomography. *Int Endod J* 2011; 44(3): 245-52. <http://dx.doi.org/10.1111/j.1365-2591.2010.01814.x> PMID: 21166825
- [62] Estrela C, Alencar AH, Kitten GT, Vencio EF, Gava E. Mesenchymal stem cells in the dental tissues: perspectives for tissue regeneration. *Braz Dent J* 2011; 22(2): 91-8. <http://dx.doi.org/10.1590/S0103-64402011000200001> PMID: 21537580
- [63] Decurcio DA, Bueno MR, de Alencar AHG, Porto OCL, Azevedo BC, Estrela C. Effect of root canal filling materials on dimensions of cone-beam computed tomography images. *J Appl Oral Sci* 2012; 20(2): 260-7. <http://dx.doi.org/10.1590/S1678-77572012000200023> PMID: 22666847
- [64] Bueno MR, Estrela C, De Figueiredo JAP, Azevedo BC. Map-reading strategy to diagnose root perforations near metallic intracanal posts by using cone beam computed tomography. *J Endod* 2011; 37(1): 85-90. <http://dx.doi.org/10.1016/j.joen.2010.08.006> PMID: 21146084
- [65] Bornstein MM, Lauber R, Sendi P, von Arx T. Comparison of periapical radiography and limited cone-beam computed tomography in mandibular molars for analysis of anatomical landmarks before apical surgery. *J Endod* 2011; 37(2): 151-7. <http://dx.doi.org/10.1016/j.joen.2010.11.014> PMID: 21238794
- [66] Dawood A, Brown J, Sauret-Jackson V, Purkayastha S. Optimization of cone beam CT exposure for pre-surgical evaluation of the implant site. *Dentomaxillofac Radiol* 2012; 41(1): 70-4. <http://dx.doi.org/10.1259/dmfr/16421849> PMID: 22184628
- [67] Schloss T, Sonntag D, Kohli MR, Setzer FC. A comparison of 2- and 3-dimensional healing assessment after endodontic surgery using cone-beam computed tomographic volumes or periapical radiographs. *J Endod* 2017; 43(7): 1072-9. <http://dx.doi.org/10.1016/j.joen.2017.02.007> PMID: 28527841
- [68] von Arx T, Jensen SS, Bornstein MM. Changes of root length and root-to-crown ratio after apical surgery: an analysis by using cone-beam computed tomography. *J Endod* 2015; 41(9): 1424-9. <http://dx.doi.org/10.1016/j.joen.2015.04.001> PMID: 25958177
- [69] Cevidanes LHS, Boen V, Paniagua B, Styner M, Nguyen T. Orthodontic and orthognathic surgery planning using CBCT. John Wiley & Sons, Ltd. 2016. <http://dx.doi.org/10.1002/9781119004370.ch8>
- [70] Rios HF, Borgnakke WS, Benavides E. The use of cone-beam computed tomography in management of patients requiring dental implants: an American academy of periodontology best evidence review. *J Periodontol* 2017; 88(10): 946-59. <http://dx.doi.org/10.1902/jop.2017.160548> PMID: 28967330
- [71] Bornstein MM, Horner K, Jacobs R. Use of cone beam computed tomography in implant dentistry: current concepts, indications and limitations for clinical practice and research. *Periodontol* 2000 2017; 73(1): 51-72. <http://dx.doi.org/10.1111/prd.12161> PMID: 28000270
- [72] Magill D, Beckmann N, Felice MA, Yoo T, Luo M, Mupparapu M. Investigation of dental cone-beam CT pixel data and a modified method for conversion to Hounsfield unit (HU). *Dento Maxillo Facial Radiol* 2017; 2017: 20170321.
- [73] Talaat W, Al Bayatti S, Al Kawas S. CBCT analysis of bony changes associated with temporomandibular disorders. *Cranio* 2016; 34(2): 88-94. <http://dx.doi.org/10.1179/2151090315Y.0000000002> PMID: 25672907
- [74] Ma R-H, Yin S, Li G. The detection accuracy of cone beam CT for osseous defects of the temporomandibular joint: a systematic review and meta-analysis. *Sci Rep* 2016; 6: 34714. <http://dx.doi.org/10.1038/srep34714> PMID: 27708375
- [75] Al-Saleh MAQ, Alsufyani NA, Saltaji H, Jaremko JL, Major PW. MRI and CBCT image registration of temporomandibular joint: a systematic review. *J Otolaryngol Head Neck Surg* 2016; 45(1): 30. <http://dx.doi.org/10.1186/s40463-016-0144-4> PMID: 27164975
- [76] Kim DM, Bassir SH. When is cone-beam computed tomography imaging appropriate for diagnostic inquiry in the management of inflammatory periodontitis? An American academy of periodontology best evidence review. *J Periodontol* 2017; 88(10): 978-98. <http://dx.doi.org/10.1902/jop.2017.160505> PMID: 28967334
- [77] Kapila SD, Nervina JM. CBCT in orthodontics: assessment of treatment outcomes and indications for its use. *Dentomaxillofac Radiol* 2015; 44(1): 20140282. <http://dx.doi.org/10.1259/dmfr.20140282> PMID: 25358833
- [78] Scarfe WC, Azevedo B, Toghiani S, Farman AG. Cone beam computed tomographic imaging in orthodontics. *Aust Dent J* 2017; 62(Suppl. 1): 33-50. <http://dx.doi.org/10.1111/adj.12479> PMID: 28297089
- [79] Momany SM, AlJamal G, Shugaa-Addin B, Khader YS. Cone beam computed tomography analysis of upper airway measurements in patients with obstructive sleep Apnea. *Am J Med Sci* 2016; 352(4): 376-84. <http://dx.doi.org/10.1016/j.amjms.2016.07.014> PMID: 27776719
- [80] Zimmerman JN, Lee J, Pliska BT. Reliability of upper pharyngeal airway assessment using dental CBCT: a systematic review. *Eur J Orthod* 2017; 39(5): 489-96. <http://dx.doi.org/10.1093/ejo/cjw079> PMID: 27999121
- [81] Chen H, Li Y, Reiber JH, et al. Analyses of aerodynamic characteristics of the oropharynx applying CBCT: obstructive sleep apnea patients versus control subjects. *Dentomaxillofac Radiol* 2017; 2017: 0238. <http://dx.doi.org/10.1259/dmfr.20170238> PMID: 29076751
- [82] Hodez C, Griffaton-Taillandier C, Bensimon I. Cone-beam imaging: applications in ENT. *Eur Ann Otorhinolaryngol Head Neck Dis* 2011; 128(2): 65-78. <http://dx.doi.org/10.1016/j.anorl.2010.10.008> PMID: 21459066
- [83] Şeker E, Özcelik TB, Rath N, Yılmaz B. Evaluation of marginal fit of CAD/CAM restorations fabricated through cone beam computerized tomography and laboratory scanner data. *J Prosthet Dent* 2016; 115(1): 47-51. <http://dx.doi.org/10.1016/j.prosdent.2015.08.006> PMID: 26518986
- [84] Ting-Shu S, Jian S. Intraoral digital impression technique: a review. *J Prosthodont* 2015; 24(4): 313-21. <http://dx.doi.org/10.1111/jopr.12218> PMID: 25220390
- [85] Flügge T, Derksen W, Te Poel J, Hassan B, Nelson K, Wismeijer D. Registration of cone beam computed tomography data and intraoral surface scans - A prerequisite for guided implant surgery with CAD/CAM drilling guides. *Clin Oral Implants Res* 2017; 28(9): 1113-8. <http://dx.doi.org/10.1111/clr.12925> PMID: 27440381
- [86] Inbarajan A, Banu F, Tv P, Kumar A, Seenivasan M. Pre-surgical provisional prosthesis for immediate non-occlusal-loaded flapless implant. *Cureus* 2017; 9(6): e1345. <http://dx.doi.org/10.7759/cureus.1345> PMID: 28713661
- [87] Aslanidou K, Kau CH, Vlachos C, Saleh TA. The fabrication of a customized occlusal splint based on the merging of dynamic jaw tracking records, cone beam computed tomography, and CAD-CAM digital impression. *J Orthod Sci* 2017; 6(3): 104-9. http://dx.doi.org/10.4103/jos.JOS_61_16 PMID: 28717635
- [88] Alsufyani NA, Al-Saleh MAQ, Major PW. CBCT assessment of upper airway changes and treatment outcomes of obstructive sleep apnoea: a systematic review. *Sleep Breath* 2013; 17(3): 911-23. <http://dx.doi.org/10.1007/s11325-012-0799-7> PMID: 23344828
- [89] van der Meer WJ, Vissink A, Ng YL, Gulabivala K III. 3D Computer aided treatment planning in endodontics. *J Dent* 2016; 45: 67-72. <http://dx.doi.org/10.1016/j.jdent.2015.11.007> PMID: 26627596
- [90] Patel S, Aldowaisan A, Dawood A. A novel method for soft tissue retraction during periapical surgery using 3D technology: a case report. *Int Endod J* 2017; 50(8): 813-22. <http://dx.doi.org/10.1111/iej.12701> PMID: 27632716
- [91] Mirković S, Budak I, Puskar T, et al. Application of modern computer-aided technologies in the production of individual bone graft: a case report. *Vojnosanit Pregl* 2015; 72(12): 1126-31. <http://dx.doi.org/10.2298/VSP140915117M> PMID: 26898039

- [92] Zinser M, Zoeller J. Computer-Designed splints for surgical transfer of 3D Orthognathic planning. *Facial Plast Surg* 2015; 31(5): 474-90.
<http://dx.doi.org/10.1055/s-0035-1565010> PMID: 26579863
- [93] Evans ZP, Renne WG, Bacro TR, Mennito AS, Ludlow ME, Lechlopol MK. Anatomic customization of root-analog dental implants with cone-beam CT and CAD/CAM fabrication: a cadaver based pilot evaluation. *J Oral Implantol* 2017; 2017: 1-9.
<http://dx.doi.org/10.1563/aaid-joi-D-17-00090> PMID: 29064779
- [94] Naumovich SS, Naumovich SA, Goncharenko VG. Three-dimensional reconstruction of teeth and jaws based on segmentation of CT images using watershed transformation. *Dentomaxillofac Radiol* 2015; 44(4): 20140313.
<http://dx.doi.org/10.1259/dmfr.20140313> PMID: 25564886
- [95] Michetti J, Maret D, Mallet J-P, Diemer F. Validation of cone beam computed tomography as a tool to explore root canal anatomy. *J Endod* 2010; 36(7): 1187-90.
<http://dx.doi.org/10.1186/1746-160X-9-14> PMID: 20630296
- [96] Stoetzer M, Nickel F, Rana M, *et al.* Advances in assessing the volume of odontogenic cysts and tumors in the mandible: a retrospective clinical trial. *Head Face Med* 2013; 9: 14.
<http://dx.doi.org/10.1186/1746-160X-9-14> PMID: 23601144
- [97] Lee RJ, Weissheimer A, Pham J, *et al.* Three-dimensional monitoring of root movement during orthodontic treatment. *Am J Orthod Dentofacial Orthop* 2015; 147(1): 132-42.
<http://dx.doi.org/10.1016/j.ajodo.2014.10.010> PMID: 25533080
- [98] Jiang F, Kula K, Chen J. Estimating the location of the center of resistance of canines. *Angle Orthod* 2016; 86(3): 365-71.
<http://dx.doi.org/10.2319/051215-322.1> PMID: 26401827
- [99] Stimmelmayer M, Denk K, Erdelt K, *et al.* Accuracy and reproducibility of four cone beam computed tomography devices using 3D implant-planning software. *Int J Comput Dent* 2017; 20(1): 21-34. PMID: 28294203
- [100] Joda T, Ferrari M, Braegger U. A digital approach for one-step formation of the supra-implant emergence profile with an individualized CAD/CAM healing abutment. *J Prosthodont Res* 2016; 60(3): 220-3.
<http://dx.doi.org/10.1016/j.jpor.2016.01.005> PMID: 26868927
- [101] Marroquin TY, Karkhanis S, Kvaal SI, Vasudavan S, Kruger E, Tennant M. Age estimation in adults by dental imaging assessment systematic review. *Forensic Sci Int* 2017; 275: 203-11.
<http://dx.doi.org/10.1016/j.forsciint.2017.03.007> PMID: 28410514
- [102] Galibourg A, Dumoncel J, Telmon N, Calvet A, Michetti J, Maret D. Assessment of automatic segmentation of teeth using a watershed-based method. *Dentomaxillofac Radiol* 2017; 14(1): 20170220.
<http://dx.doi.org/10.1259/dmfr.20170220> PMID: 28937285
- [103] Apelian N, Vergnes JN, Hovey R, Bedos C. How can we provide person-centred dental care? *Br Dent J* 2017; 223(6): 419-24.
<http://dx.doi.org/10.1038/sj.bdj.2017.806> PMID: 28937118
- [104] Makanjee CR, Bergh A-M, Hoffmann WA. Healthcare provider and patient perspectives on diagnostic imaging investigations. *Afr J Prim Health Care Fam Med* 2015; 7(1): 7.
<http://dx.doi.org/10.4102/phcfm.v7i1.801> PMID: 26245604
- [105] O'Sullivan JW, Muntinga T, Grigg S, Ioannidis JPA. Prevalence and outcomes of incidental imaging findings: umbrella review. *BMJ* 2018; 361: k2387.
<http://dx.doi.org/10.1136/bmj.k2387> PMID: 29914908
- [106] Scarfe WC. Incidental findings on cone beam computed tomographic images: a Pandora's box? *Oral Surg Oral Med Oral Pathol Oral Radiol* 2014; 117(5): 537-40.
<http://dx.doi.org/10.1016/j.oooo.2014.01.002> PMID: 24508511
- [107] Horner K, Islam M, Flygare L, Tsiklakis K, Whaites E. Basic principles for use of dental cone beam computed tomography: consensus guidelines of the European Academy of Dental and Maxillofacial Radiology. *Dentomaxillofac Radiol* 2009; 38(4): 187-95.
<http://dx.doi.org/10.1259/dmfr/74941012> PMID: 19372107
- [108] Edwards R, Altalibi M, Flores-Mir C. The frequency and nature of incidental findings in cone-beam computed tomographic scans of the head and neck region: a systematic review. *J Am Dent Assoc* 2013; 144(2): 161-70.
<http://dx.doi.org/10.14219/jada.archive.2013.0095> PMID: 23372132
- [109] Maret D, Telmon N, Treil J, Caron P, Nabet C. Pituitary adenoma as an incidental finding in dental radiology: a case report. *Ann Intern Med* 2014; 160(4): 290-1.
<http://dx.doi.org/10.7326/L14-5004-4> PMID: 24727848
- [110] Valentijn PP, Schepman SM, Opheij W, Bruijnzeels MA. Understanding integrated care: a comprehensive conceptual framework based on the integrative functions of primary care. *Int J Integr Care* 2013; 2013: 13e010.
<http://dx.doi.org/10.5334/ijic.886> PMID: 23687482