



HAL
open science

Olfactory neuroblastoma in children and adolescents: The EXPeRT recommendations for diagnosis and management

Daniela Di Carlo, Giulia Fichera, Benoit Dumont, Enrico Pozzo, Beate Timmermann, Romain Luscan, Antoine Moya-Plana, Anna Synakiewicz, Ewa Bien, Nino Jorge dos Reis Farinha, et al.

► To cite this version:

Daniela Di Carlo, Giulia Fichera, Benoit Dumont, Enrico Pozzo, Beate Timmermann, et al.. Olfactory neuroblastoma in children and adolescents: The EXPeRT recommendations for diagnosis and management. *EJC Paediatric Oncology*, 2024, 3, 10.1016/j.ejped.2023.100136 . hal-04846196

HAL Id: hal-04846196

<https://hal.science/hal-04846196v1>

Submitted on 31 Jan 2025

HAL is a multi-disciplinary open access archive for the deposit and dissemination of scientific research documents, whether they are published or not. The documents may come from teaching and research institutions in France or abroad, or from public or private research centers.

L'archive ouverte pluridisciplinaire **HAL**, est destinée au dépôt et à la diffusion de documents scientifiques de niveau recherche, publiés ou non, émanant des établissements d'enseignement et de recherche français ou étrangers, des laboratoires publics ou privés.



Distributed under a Creative Commons Attribution - NonCommercial - NoDerivatives 4.0
International License



Olfactory neuroblastoma in children and adolescents: The EXPeRT recommendations for diagnosis and management

Daniela Di Carlo^{a,b,*}, Giulia Fichera^{c,2}, Benoit Dumont^{d,3}, Enrico Pozzo^{e,f,g,4}, Beate Timmermann^h, Romain Luscan^{i,j,5}, Antoine Moya-Plana^k, Anna Synakiewicz^{l,6}, Ewa Bien^{m,7}, Nino Jorge dos Reis Farinhaⁿ, Malgorzata Krawczyk^{m,8}, Rita Alaggio^o, Apostolos Pourtsidis^{p,9}, Brice Fresneau^{q,r,10}, Yves Reguerre^s, Tal Ben-Ami^t, Calogero Virgone^{u,11}, Jelena Roganovic^v, Jan Godzinski^{w,x}, Ines B Brecht^{y,12}, Dominik Schneider^z, Andrea Ferrari^{aa,13}, Barbara Hero^{ab}, Daniel Orbach^{ac,14}, Gianni Bisogno^{a,b}

^a Department of Women's and Children's Health, University of Padova, Italy

^b Pediatric Hematology-Oncology Division, University Hospital of Padova, Italy

^c Pediatric Radiology Unit, University Hospital of Padova, Padua, Italy

^d Pediatric Oncology and Hematology Department, Léon Bérard Cancer Center, Lyon, France

^e Department of Radiotherapy, Istituto Oncologico Veneto IOV-IRCCS, Padua, Italy

^f Pediatric Radiotherapy Unit, Istituto Oncologico Veneto IOV-IRCCS, Padua, Italy

^g Department of Medicine-DIMED, University of Padua, Padua, Italy

^h Department of particle therapy, University Hospital Essen, West German Proton Therapy Centre Essen (WPE), West German Cancer Center (WITZ), German Cancer Consortium (DKTK), Essen, Germany

ⁱ Department of Paediatric Otolaryngology, AP-HP, Hôpital Necker-Enfants Malades, F-75015 Paris, France

^j Université Paris Cité, Faculté de Médecine, F-75006 Paris, France

^k Head & Neck and Skull Base Surgery Department, Gustave Roussy and Paris Saclay University, Villejuif F-94805, France

^l Department of Pediatrics, Hematology and Oncology, Medical University of Gdansk, Poland,

^m Department of Pediatrics, Hematology and Oncology, Medical University of Gdansk, Gdansk, Poland

ⁿ Pediatric Oncology Unit, Centro Hospitalar Universitário São João, Porto, Portugal

^o Pathology Unit, Department of Laboratories, Bambino Gesù Children's Hospital, IRCCS, Rome, Italy

^p Pediatric and Adolescent Oncology Clinic, Children's Hospital MITERA, Athens, Greece

^q Gustave Roussy, Paris-Saclay University, Department of Children and Adolescents Oncology, Villejuif F-94805, France

^r Paris-Saclay University, Paris-Sud University, Epidemiology of Radiation, CESP, INSERM, Villejuif, France

^s Paediatric Oncology and Haematology Unit, CHU Saint Denis de La Réunion, France

^t Paediatric Haematology Unit, Kaplan Medical Centre, Rehovot, Israel

^u Paediatric Surgery, Department of Women's and Children's Health, University of Padua, Padua, Italy

^v Division of Hematology and Oncology, Department of Pediatrics, Clinical Hospital Centre Rijeka, Istarska 43, HR 51000, Rijeka, Croatia

^w Department of Paediatric Surgery, Marciniak Hospital, Wrocław, Poland

^x Department of Paediatric Traumatology and Emergency Medicine, Medical University Wrocław, Poland

^y Paediatric Haematology and Oncology, Children's Hospital, Eberhard-Karls-Universität, Tübingen, Germany

^z Clinic of Paediatrics, Dortmund Municipal Hospital, Dortmund, Germany

^{aa} Paediatric Oncology Unit, Fondazione IRCCS Istituto Nazionale dei Tumori, Milan, Italy

^{ab} Pediatric Oncology and Hematology, Children's Hospital, University Hospital Cologne, and Medical Faculty, University of Cologne, Germany

* Corresponding author.

E-mail addresses: danieladicarlo25@gmail.com (D. Di Carlo), gfighera90@gmail.com (G. Fichera), benoit.dumont@ihope.fr (B. Dumont), romain.luscan@aphp.fr (R. Luscan), anna.synakiewicz@gumed.edu.pl (A. Synakiewicz), ewa.bien@gumed.edu.pl (E. Bien), Nuno.reis.farinha@gmail.com (N.J. dos Reis Farinha), malgorzata.krawczyk@gumed.edu.pl (M. Krawczyk), yves.reguerre@chu-reunion.fr (Y. Reguerre), tal.ben.ami1@gmail.com (T. Ben-Ami), calogero.virgone@unipd.it (C. Virgone), jelena.roganovic1@ri.t-com.hr (J. Roganovic), jgodzin@wp.pl (J. Godzinski), ines.Brecht@med.uni-tuebingen.de (I.B. Brecht), Dominik.Schneider@klinikumdo.de (D. Schneider), Andrea.Ferrari@istitutotumouri.mi.it (A. Ferrari), daniel.orbach@curie.fr (D. Orbach).

<https://doi.org/10.1016/j.ejcped.2023.100136>

Received 31 May 2023; Received in revised form 15 November 2023; Accepted 12 December 2023

Available online 17 December 2023

2772-610X/© 2023 The Authors. Published by Elsevier Ltd. This is an open access article under the CC BY-NC-ND license (<http://creativecommons.org/licenses/by-nc-nd/4.0/>).

ARTICLE INFO

Keywords:

Esthesioneuroblastoma
 Olfactory neuroblastoma
 Nasal cavity
 Nasal neoplasms
 Rare disease

ABSTRACT

Olfactory neuroblastoma (ON) is a rare tumor commonly presenting between 50 and 60 years of age. In pediatric age this tumor is even rarer, with an estimated incidence of 0.1 per 100,000 children up to 15 years. It arises from the olfactory neuroepithelium of the nasal cavity, and it can be locally aggressive, spreading to the orbital cavity, skull base, intracranial cavity. In rarer cases it can also give distant metastasis, more frequently to regional lymph nodes and less commonly to distant sites like liver, lungs and bones. Prognosis varies depending on the stage at presentation (including dural invasion, regional nodal involvement, and distant metastasis), the histological grade, and aspects related to the treatment, such as the possibility to achieve clear margins with surgery and the multimodal approach. Chemotherapy, surgery and radiotherapy have been used to treat these patients and the different approaches have been reported in the literature. Given the rarity of the disease no shared guidelines exist for the management of this entity in children, but some suggestions can be given to optimize the ON management.

This study presents the internationally recognized recommendations for the diagnosis and treatment of ON in children and adolescents, established by the European Cooperative Study Group for Pediatric Rare Tumors (EXPeRT) group within the EU-funded project Pediatric Rare Tumors Network - European Registry (PARTNER).

1. Introduction

Olfactory neuroblastoma (ON), also known as esthesioneuroblastoma, is a rare neuroectodermal tumor, originating from the olfactory neuroepithelium of the nasal cavity. It accounts for 1–5% of intranasal tumors with an estimated incidence of 0.4 per million population in adults [1–3]. No gender predisposition has been reported. The distribution of age is unimodal with the majority of patients diagnosed in the fifth to sixth decades of life and less than 10% of cases occurring in patients younger than 20 years [4,5]. In children, ON represents the most frequent malignancy of the nasal cavity, but it is extremely rare with an estimated incidence of 0.1 per 100,000 children up to 15 years. ON can spread from the nasal cavity into the paranasal sinuses, the orbits and – through the lamina cribiformis – into the cranial cavity. Lymphatic dissemination occurs in up to 25% of patients, mainly to regional cervical lymph nodes [6–9]. Distant metastases occur in less than 10% of patients and may involve lungs, central nervous system, bone, liver, and bone marrow [10–12]. Given the rarity of these tumors, no standardized recommendations for the diagnosis and therapeutic management are available in children. The European Cooperative Study Group for Pediatric Rare Tumors (EXPeRT) started its activity in 2008 as a collaboration between national cooperative groups dedicated to very rare tumors (VRT) in children. From the beginning, it was recognized that in pediatric VRT randomized or even observational prospective clinical trials were very difficult to perform due to the low number of affected patients. With this limitation, EXPeRT worked to establish recommendations for a series of VRT occurring in pediatric age [13]. This document is part of this effort.

2. Methodology

According to the Consensus Conference Standard Operating Procedure methodology, the levels of evidence can be classified from levels of evidence I to V and grades of recommendation A to E (Table 1) [14]. For ON no level I, II, III evidence exists. These recommendations have been developed from retrospective series (level IV), case reports (level V), and personal expertise (level V).

3. Initial assessment

3.1. Clinical presentation

Clinical manifestations may persist for months prior to ON diagnosis and include headaches, sinusitis-like symptoms, unilateral nasal obstruction, recurrent epistaxis, and – less common – a visible intranasal mass or anosmia and explain why these patients are often first seen by Ear Nose and Throat (ENT) specialists [8,12]. Tumors extending beyond the nasal cavity may present with visual dysfunction or exophthalmos. Occasionally, hormone excess syndromes like inappropriate antidiuretic hormone secretion or Cushing syndrome have been reported [15].

Table 1

Levels of evidence and grades of recommendation (adapted from the Infectious Disease Society of America-United States Public Health Service Grading System) (Orbach 2021).

Levels of evidence	
I	Evidence from at least 1 large randomized, controlled trial of good methodological quality (low potential for bias) or meta-analyses of well-conducted randomized trials without heterogeneity
II	Small randomized trials or large randomized trials with a suspicion of bias (lower methodological quality) or meta-analyses of such trials or of trials with demonstrated heterogeneity
III	Prospective cohort studies
IV	Retrospective cohort studies or case-control studies
V	Studies without control group, case reports, expert opinions
Grades of recommendations	
A	Strong evidence for efficacy with a substantial clinical benefit, strongly recommended
B	Strong or moderate evidence for efficacy but with a limited clinical benefit, generally recommended
C	Insufficient evidence for efficacy or benefit does not outweigh the risk or the disadvantages (adverse events, costs, ...), optional
D	Moderate evidence against efficacy or for adverse outcome, generally not recommended
E	Strong evidence against efficacy or for adverse outcome, never recommended

¹ ORCID 0000 0003 0573 8576

² ORCID: 0000-0003-2977-5304

³ ORCID: 0000-0001-8331-3480

⁴ ORCID: 0000-0002-3362-3509

⁵ ORCID: 0000-0003-1219-727X

⁶ ORCID: 0000-0001-6418-0360

⁷ ORCID 0000-0002-2091-2686

⁸ ORCID 0000-0001-7093-8975

⁹ ORCID: 0000-0003-4031-6619

¹⁰ ORCID: 0000-0001-7603-7828

¹¹ Orcid: 0000-0002-3651-9416

¹² Orcid: 0000-0001-7973-3300

¹³ Orcid: 0000-0000-4724-0517

¹⁴ Orcid: 0000-0002-2529-139X

3.2. Imaging assessment

The primary tumor and its locoregional extension (including the neck) should be evaluated by cranial magnetic resonance imaging (MRI), to identify loco-regional invasion (orbital, meningeal, intracerebral extension, soft tissue involvement) and computed tomography (CT) with contrast enhancement, for assessing bone erosion, particularly at the cribriform plate, orbit, and air sinuses [16,17] [Level IV; Grade A].

¹⁸F-Fluorodeoxyglucose Positron Emission Tomography combined to whole-body (low-dose) CT scan (¹⁸F-FDG PET/CT) are also indicated in diagnostic workup to assess the metabolic activity of primary tumor and to detect regional extension, especially neck lymph nodes involvement [18] [Level IV; Grade B]. When nodal staging is doubtful, nodal biopsy should be recommended [Level IV; Grade A]. The value of ¹⁸F-FDG PET combined to MRI is not defined yet [Level V; Grade C].

Distant metastasis can occur at skeletal bone, followed by lungs and liver [19]. Initial staging should include chest CT scan to detect pulmonary metastases [Level IV; Grade B] and abdominal ultrasound for hepatic metastases [Level IV; Grade B]. ¹⁸F-FDG PET/CT was so far not routinely performed for staging evaluation but it could be of help in detecting bone lesions [Level IV; Grade B]. MetaIodoBenzylGuanidine (MIBG) scintigraphy has been reported to give positive results in one single patient with ON, therefore it is not routinely recommended [20] [Level V; Grade C].

[⁶⁸Ga]-DOTATATE PET combined with whole-body imaging (CT or MR) shows to play a role in clinical practice allowing diagnosis, staging, and treatment-response monitoring, but it is not routinely recommended [Level V; Grade C]. Some case reports described the improved resolution and decreased radiation dose exposure in case of somatostatin receptor (SSTR)-targeted PET imaging, exploiting the (SSTR) expression of ON [21] [Level V; Grade C].

MRI and CT scan should also be performed to evaluate response to chemotherapy and to plan local treatment every 2 cycles. Imaging evaluation should include all primary involved sites [Level V; Grade B].

3.3. Diagnosis

Histopathological evaluation is mandatory after biopsy or upfront resection, to confirm the clinical suspicion and allow the histological stratification of ON (Level IV; Grade A). A revision of the histological slides by a pathologist with proven experience in pediatric tumors and especially in head and neck tumors is highly recommended [Level IV; Grade A]. Biopsy should be performed preferentially with a transnasal technique [Level IV; Grade A].

3.4. Histopathology

The four-tiered Hyams system recognizes well (I, II) and least differentiated (III, IV) ON, based on architecture, pleomorphism, neurofibrillary matrix, rosettes, mitoses, necrosis, and calcifications [22]. This grading system should be used to grade ON at initial diagnosis [Level IV; Grade A].

Immunohistochemically ON express neuroendocrine markers; S100-protein, pan cytokeratins (focal staining in 1/3 of cases), in contrast with strong and diffuse positivity in neuroendocrine carcinoma or non-intestinal adenocarcinoma carcinomas of sinonasal tract [23]. Immunohistochemical staining for calretinin has been reported to be helpful to differentiate from other small round blue cells tumor and should be included in the panel [Level IV; Grade B]. Ki-67 proliferation index varies according to tumor grade [23].

3.5. Molecular pathology

ON is genetically heterogeneous. In a recent study 68% of ON harbored at least one somatic mutation, including TP53 (17%), PIK3CA, NF1, CDKN2A, and CDKN2C [24]. FGFR3 and CCND1 copy number

alterations are also reported [25]. Methylation profiling has demonstrated that classic ON form a distinct group, while other ON with variable immunophenotype, especially strong cytokeratin expression, or selected molecular alterations (such as IDH2 mutations) clustered with sinonasal adenocarcinoma, squamous cell carcinoma, and undifferentiated carcinoma, highlighting the blurred border with these entities [24]. Moreover, any characteristic fusion transcript has not been described, helping in the differential diagnosis with other entities.

3.6. Staging system

Modified Kadish staging is widely used to define the local tumor extension including four different groups based on the anatomical extension of the tumor: stage A, B, C, D [26,27] (Table 2). Authors suggest adopting the modified Kadish staging system in pediatric setting [Level IV; Grade B]. Dulguerov's staging system is more used in adult setting, it is based on the TNM classification of pretreatment imaging (CT and MR) findings and it is more specific in the description of the involvement of cribriform plaque, and intracranial but extradural tumors [19,22] (Table 3).

4. Treatment details

4.1. General considerations

Given the rarity of ON, the discussion by a Multidisciplinary Team (MDT) is highly recommended early in the process, and before any invasive procedure [Level V; Grade A].

The MDT has the aim to represent the different skills needed for the best diagnosis and treatment possible and should include radiologist, pathologist, pediatric oncologists, ENT surgeons, neurosurgeon, plastic surgeon, radiation oncologists, all with pediatric expertise.

After the MDT discussion the diagnosis must be confirmed with a biopsy [Level V; Grade A]. After histological confirmation of ON and complete staging results available, the MDT must discuss the most adapted treatment strategy, considering that multimodal treatment has been associated to better prognosis in advanced disease and that the following prognostic factors that have been associated to a worse outcome [11] [Level V; Grade A]:

- High histopathological grade [22]
- High Kadish stage [12]
- Dural infiltration [28]
- Metastases to the cervical lymph nodes or distant sites [4]
- Positive surgical margin status [29]

In children, ON usually presents with an advanced stage requiring a multimodal approach, including chemotherapy, surgery and radiotherapy [9] (Fig. 1).

Table 2
Modified Kadish staging system and distribution of the stages in a pediatric cohort [9].

Stage	Extension	Stage distribution in children
A	tumor confined to the nasal cavity	2.1%
B	tumor involving the nasal cavity and extending into the paranasal sinuses	28.7%
C	tumor extending beyond the nasal cavity and paranasal sinuses (includes involvement of orbit, base of skull, intracranial cavity, cribriform lamina)	60.6%
D	Involvement of cervical lymph nodes or distant sites.	8.5%

Table 3
Dugluerov modified TNM staging system.

Stage	Extension
T1	Tumor located in the nasal cavity, paranasal sinuses
T2	Involvement of sphenoid with extension to/erosion of the cribriform lamina
T3	Extension to orbital cavity, anterior cranial fossa without dural invasion
T4	Tumor involving brain

4.2. Chemotherapy

ON in pediatric patients is considered a chemosensitive tumor with a reported overall response rate between 65% and 70% [6,8,12,30]. In some cases, complete remission (CR) after chemotherapy has also been reported [8,30]. Different regimens have been used in different settings, as neoadjuvant and/or adjuvant therapy. Commonly used regimens have been cisplatin/etoposide or carboplatin/etoposide (neuroblastoma-based regimen), vincristine/doxorubicin/cyclophosphamide or vincristine/ifosfamide/actinomycin (sarcoma-based regimen). Data are limited to perform a comparison between the different regimens and thus there is no consensus on which type of chemotherapy should be used. The number of cycles is also controversial. In literature, the duration of chemotherapy ranged from 4 to 15 cycles [11]. Venkatramani et al. reported a very good partial response after four cycles, moreover events seem to occur early in the course of disease, suggesting that local treatment should not be delayed [6,12]. In advanced stages (Kadish C and D) polychemotherapy should be used in the neoadjuvant setting to maximize the reduction of tumor volume and enable surgical resection [Level V; Grade B]. Anyway, surgery should not be delayed, to avoid early local progression during chemotherapy [Level V; Grade B]. Platinum-based regimens or alkylating agents may be considered as the

first option [Level V; Grade C]. Adjuvant chemotherapy should also be considered for these patients, for at least two additional cycles with platinum-based regimens or alkylating agents according to the previous response [Level V; Grade C] (Fig. 1).

Metabolic therapy can be mentioned as a future perspective for ON treatment, given the positivity of SSTR [28] [Level V; Grade C].

4.3. Surgery

Surgery plays a key role in the multidisciplinary management of ON. Only Kadish stage A tumors, especially when presenting with low-grade histology (Hyams grade I-II), may be treated by resection only and therefore must be carefully selected [5] [Level V; Grade B] (Fig. 1).

The choice of the approach is based on a careful study of the imaging, with the aim to obtain an R0 resection. Historically, the surgical approach consisted of an external anterior craniofacial resection. The development of transnasal endoscopic surgery (TES) as an alternative to open procedures (OP) has been a major advancement, also for children [31,32]. There are no prospective studies comparing the results of TES vs OP, however, some data highlight that survival outcomes of TES are similar to those of OP [33] (Level IV, Grade B). The indications for TES have been defined by the Consensus Statement on Endoscopic Skull Base Surgery (ICAR:ESBS) which indicates that Kadish A and B ON should be resected endoscopically [34] (Level IV, Grade A). Kadish C tumors are amenable to TES when negative margins can be obtained. Otherwise, it is mandatory to combine TES with an OP. In adults, there are five critical extents which lead to consider a tumor unresectable: involvement of the orbital apex, cavernous sinus or optical chiasm, encasement of the internal carotid artery, massive brain invasion with perilesional edema and major vessels involvement (i.e. anterior cerebral artery) (ESMO-ERN Clinical Practice Guidelines for Sinonasal Epithelial

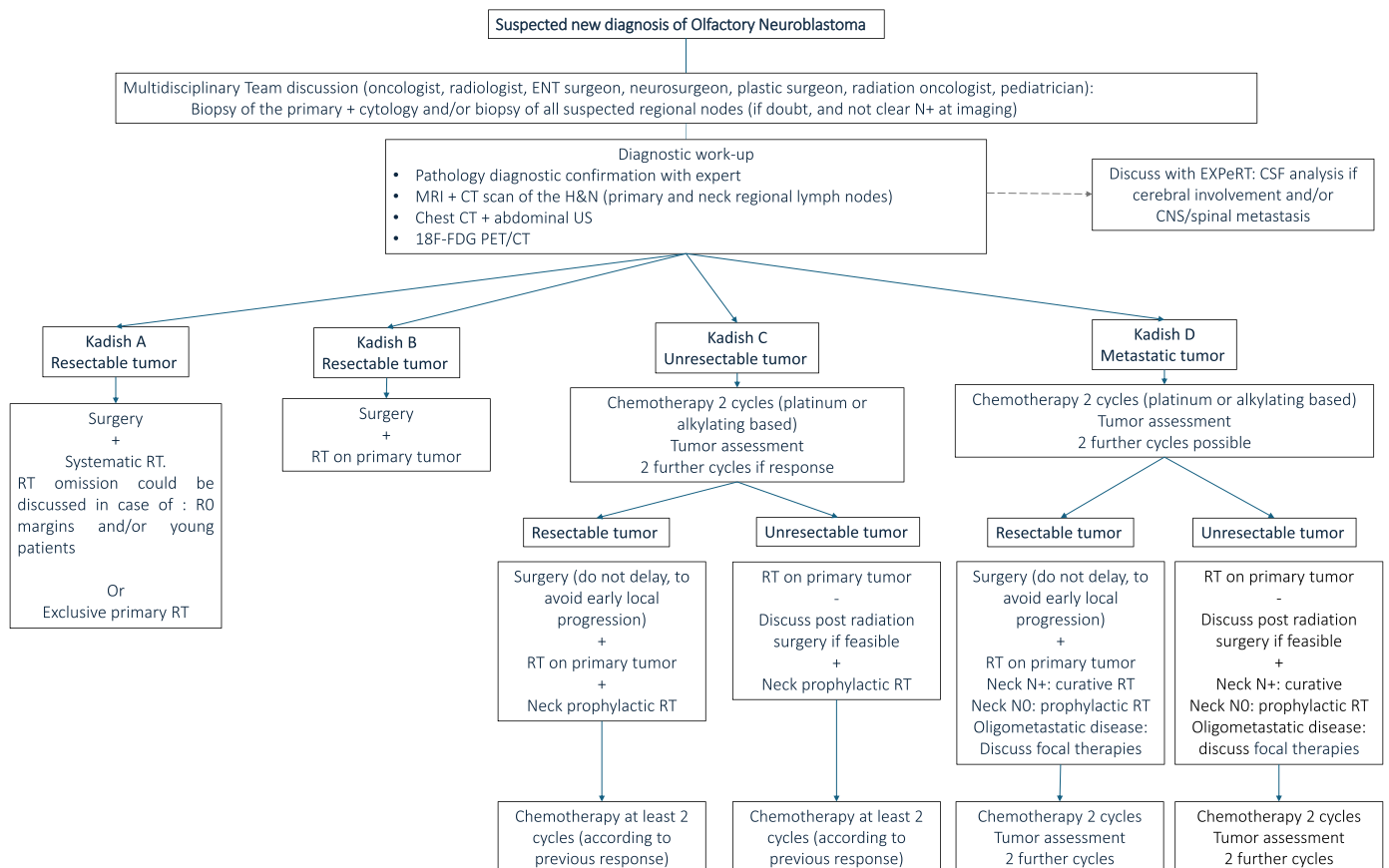


Fig. 1. Overall strategy proposal by the European Cooperative Study Group for Pediatric Rare Tumors (EXPeRT) groups for pediatric patients with thymoma according to Kadish-Morita staging system.

Malignancy, in press 2023). However, in the pediatric/adolescent age the presence of other patterns of extension, which would require a resection associated with major functional and/or esthetic sequelae, can reasonably lead the multidisciplinary team to favor a primary non-surgical treatment (Level V, Grade C).

In patients with positive cervical nodes amenable to resection, lymph neck dissection could be indicated (in addition to neck radiotherapy) [19] (Level V, Grade B). Prophylactic nodal dissection of neck area does not seem justified in relation to the low rate of occult metastasis at diagnosis in the pediatric/adolescent age group (Level V, Grade B).

4.4. Radiotherapy

Radiotherapy (RT) is a cornerstone in the treatment of ON. Retrospective studies in the pediatric populations have described a dose range between 45.0 and 70.2 Gy (Table 4) using photon-based conformal

therapy. However, promising results have come from the use of proton therapy with overall good outcomes in pediatric ON patients [7] [Level IV; Grade C].

Based on the Kadish stage at diagnosis, RT indications can be summarized as follows:

- In stage A, a local approach with surgery should be used. Exclusive primary RT has been discussed, but, because of the late toxicity, cannot be recommended routinely (Level IV; Grade D). If surgery is used and the margins are clear (R0), RT omission could be discussed; if surgical margins are positive or if there is residual disease, adjuvant RT needs to be done [Level IV; Grade B].
- In stage B, surgery followed by adjuvant RT is recommended [Level IV; Grade B].
- In stage C, neoadjuvant treatment with chemotherapy followed by RT or surgery if the tumor is unresectable or resectable, respectively.

Table 4
RT in ON from published pediatric cohorts.

Retrospective study reference	Overall number of patients	Number of RT patients (%)	Median dose delivered (Gy) (range)	Kadish grade of RT patients (total patients)	Median age of RT patients by Kadish	Median dose (Gy) delivered by Kadish grade	Type of RT delivered	Outcome and median FU
Dumont et al., <i>Pediatr Blood Cancer</i> , 2020	18	11 (61%)	56.3 Gy (range: 54–60 Gy)	A = 1[1] B = 3[3] C = 6[10] D = 1[4]	A = 13 yrs B = 13yrs C = 10.5 yrs (range: 7-14 yrs) D = 16 yrs	A = 56 Gy B = 54 Gy (range: 54 Gy-56 Gy) C = 56 Gy (range: 54 Gy-60 Gy) + 48 Gy prophylactic neck (1/6) D = 58 Gy primary site + 58 Gy curative neck	EBRT Photons	A = 100% alive, FU 74 months B = 100% alive, median FU 86 months (range: 55-185 months) C = 66% alive, median FU 73 months (range: 13-250 months) D = 0% alive, FU 24 months
Venkatramani et al., <i>Pediatr Blood Cancer</i> 2016	24	21 (87.5%)	56 Gy (range: 45–68.4 Gy)	B = 6[8] C = 15[16]	B = 14 yrs (range: 5-19 yrs) C = 14 yrs (range: 6-20 yrs)	B = 55.8 Gy (range: 50–60 Gy) C = 59.4 Gy (range: 45–68.4 Gy)	EBRT Photons	B = 66% alive, median FU 57.5mo (range: 27-92 months) C = 80% alive, median FU 35 months (range: 6-263 months)
Lucas et al., <i>Pediatr Blood Cancer</i> 2015	8	8 (100%)	59.4 Gy _{RBE} (range: 54–70.2)	B = 3[3] C = 1[1] D = 4[4]	B = 9 yrs (range: 4-11 yrs) C = 4 yrs D = 15 yrs (range: 6-21 yrs)	B = 59.4 Gy (range: 54–59.4 Gy) C = 59.4 Gy D = 59.4 Gy (range: 54–70.2 Gy)	EBRT Protons	B = 66.7% alive, median FU 9.6 months (range: 0.63-112.8 months) C = 100% alive, FU 33.6 months D = 100% alive, median FU 46.2 months (range: 3.6-91.2 months)
Kababri et al., <i>J Pediatr Hematol Oncol</i> 2014	11	10 (91%)	55 Gy (range: 50–65 Gy)	B = 4[5] C = 6[6]	B = 14.5 yrs (range: 10-18 yrs) C = 13.5 yrs (range: 4-16 yrs);	B = 55 Gy (range: 54–65 Gy); C = 57 Gy (range: 50–60 Gy)	EBRT Photons	B = 100% alive, median FU 102 months (range: 47-121 months) C = 83.3% alive, median FU 105 mo (range: 9-197 months)
Bisogno et al., <i>BMC Cancer</i> 2012	9	8 (89%)	53 Gy (range: 47–60 Gy)	B = 3[3] C = 4[6]	B = 11 yrs (range: 10-16 yrs) C = 11 yrs (range: 2-18 yrs)	B = 50 Gy (range: 48–60 Gy); C = 56.5 Gy (range: 47–60 Gy);	EBRT Photons	B = 100% alive, median FU 156 months (range: 133-168) C = 100% alive, median FU 224 months (range: 138–276)
Eich et al., <i>Strahlenther Onkol</i> 2005	19	15 (79%)	50 Gy (range: 32–60 Gy)				EBRT Photons	
Kumar et al., <i>JPHO</i> 2002	5	4 (80%)	50 Gy (range: 45–55 Gy)				EBRT Photons	

Abbreviations: EBRT, external beam radiotherapy; FU, follow-up; Gy, gray; yrs, years.

In addition, prophylactic irradiation to the cervical nodes (level I,II, III, retropharyngeal) is warranted [Level IV; Grade B].

- In stage D chemotherapy first is mainly used, with RT to local and metastatic sites either with ablative or palliative intent to be discussed in a multidisciplinary setting [Level IV; Grade C].

The dose of the adjuvant RT after surgery is 54 Gy if R0, 60 Gy if R1, or 66–70 Gy if R2 [5]. Conversely, for neck irradiation in N+ patients the suggested dose ranges between 66–70 Gy. For prophylactic irradiation of the neck the suggested dose is 50 Gy (Perez & Brady). For distant metastases, palliative dose of 5×4 Gy or 10×3 Gy can be used.

4.5. Targeted therapy

Considering the multimodal approach in the first line treatment of ON, targeted therapies might be considered for recurrent or chemotherapy-resistant ON, after MTD discussion [Level V; Grade A].

However, only a few studies focused on the molecular aspects of ON, usually performed in adults. Only cases reports describing the use of targeted therapy in adults with recurrent ON are available in the literature and can be summarized as follows:

- durable response to pazopanib in an adult patient with multiple recurrent and heavily pretreated advanced ON [35].
- CR after cetuximab and sunitinib in a patient with ON relapse and somatic alterations in the EGFR, FGFR2, KDR and RET genes [36].
- SD for 15 months in a patient with recurrent ON treated with Sunitinib [37].
- Partial response to bevacizumab after 2 months of treatment, followed by SD for almost 2 years [38].

A clinical trial to assess the effectiveness of bintrafusp alfa (NCT05012098) is currently open for adult patients with recurrent or metastatic ON.

5. Recurrent disease

The 5-year EFS in pediatric cohorts ranges from 44.4% to 91% [6,8,11,12,30]. In the cohort described by Dumont five patients out of 18 had an early progression. For three of them, progression of the tumor occurred early, before the local therapy [12]. Data on the treatment of recurrent and progressive pediatric ON are very scarce. In the French study all patients with relapse or progression of the disease died despite further lines of treatment [12]. In the Italian pediatric cohort, 4 patients out of 7 who relapsed died (3 due to further PD, 1 due to the treatment complications) [8]. Similarly, in the German pediatric cohort, 4 out of 7 relapsing patients died [11]. All authors have underlined worse outcomes in patients with high Kadish stage (C and D) and high-grade of the tumor (Hyams III and IV). Based on the data from small retrospective pediatric studies, treatment of relapse of ON is very challenging, molecular profiling should be performed early and therapeutic strategy should always be discussed within the MDT [Level V; Grade A].

6. Recommendations for follow up

Due to the possibility of relapse, a surveillance for at least 5 years is strongly advised. In literature, there is no standardized follow-up schedule available, but the following protocol has been suggested [19] [Level V; Grade B]:

- contrast-enhanced MR of primary tumor site (including the neck) performed 2 to 4 months after the end of therapy.
- MRI every three months in the first year
- MRI every six-month in the second year
- MRI yearly until five years after completing treatment

In addition, a chest X-ray to detect lung metastasis should be performed every year. Imaging studies should include every tumor site (primary tumor \pm metastatic sites), and additional evaluation should be proposed according to clinical symptoms [Level V; Grade C].

7. Sequelae of the treatment

Post-surgical acute adverse effects include cerebrospinal fluid (CSF) leakage (less common after endoscopic nasal approach, sinusitis, meningitis, and anosmia [8,12].

After radiotherapy acute AEs include dermatitis, mucositis, rhinitis, tissue necrosis, dysphagia [7]. Late AEs due to RT highly depend on the age of the patient at irradiation and include facial scoliosis, endocrine disorders, cataracts, retinopathy, optic neuritis, keratitis or second tumors [6].

Standard chemotherapy based on cisplatin, etoposide, doxorubicin or ifosfamide can cause acute complications such nausea, weight loss, vomiting, febrile neutropenia, mucositis, and chronic disturbances like hearing defects, cardiac and renal complications [7].

8. Conclusion

In conclusion, ON is a very rare tumor in pediatric age and given its rarity shared guidelines do not exist. In children, it often presents with local advanced stage and MTD discussion to plan a multimodal approach should be considered as the best strategy to treat these patients. In addition, relapse can occur early, justifying the inclusion of molecular diagnosis in the diagnostic approach.

Moreover, functional sequelae related to surgery and radiotherapy are common and should be actively followed-up for a correct management.

Funding

This research did not receive any specific grant from funding agencies in the public, commercial, or not-for-profit sectors.

Declaration of Competing Interest

The authors declare that they have no known competing financial interests or personal relationships that could have appeared to influence the work reported in this paper.

Acknowledgments

The authors wish to thank all the families and cooperating centers, as well as those who supported national activities on very rare tumors in pediatric age.

References

- [1] G. Broich, A. Pagliari, F. Ottaviani, Esthesioneuroblastoma: a general review of the cases published since the discovery of the tumour in 1924, *Anticancer Res.* 17 (4A) (1997) 2683–2706.
- [2] A. Ferlito, A. Rinaldo, P.H. Rhys-Evans, Contemporary clinical commentary: esthesioneuroblastoma: an update on management of the neck, *Laryngoscope* 113 (11) (2003) 1935–1938 (Nov).
- [3] L.D.R. Thompson, Olfactory neuroblastoma, *Head. Neck Pathol.* 3 (3) (2009) 252–259 (Sep).
- [4] D. Jethanamest, L.G. Morris, A.G. Sikora, D.I. Kutler, Esthesioneuroblastoma: a population-based analysis of survival and prognostic factors, *Arch. Otolaryngol. Neck Surg.* 133 (3) (2007) 276. Mar 1.
- [5] Z. zhen Yin, L. Gao, J. wei Luo, J. lin Yi, X. dong Huang, Y. Qu, et al., Long-term outcomes of patients with esthesioneuroblastomas: A cohort from a single institution, *Oral. Oncol.* 53 (2016) 48–53 (Feb).
- [6] R. Venkatramani, H. Pan, W.L. Furman, J.M. Marron, J. Haduong, P. Friedrich-Medina, et al., Multimodality treatment of pediatric esthesioneuroblastoma: esthesioneuroblastoma, *Pedia Blood Cancer* 63 (3) (2016) 465–470 (Mar).
- [7] J.T. Lucas, M.M. Ladra, S.M. MacDonald, P.M. Busse, A.M. Friedmann, D.H. Ebb, et al., Proton therapy for pediatric and adolescent esthesioneuroblastoma: proton

- radiotherapy for esthesioneuroblastoma, *Pedia Blood Cancer* 62 (9) (2015) 1523–1528 (Sep).
- [8] G. Bisogno, P. Soloni, M. Conte, M. Podda, A. Ferrari, A. Garaventa, et al., Esthesioneuroblastoma in pediatric and adolescent age. A report from the TREP project in cooperation with the Italian neuroblastoma and soft tissue sarcoma committees, *BMC Cancer* 12 (1) (2012) 117 (Dec).
- [9] C. Safi, D. Spielman, M. Otten, J.N. Bruce, N. Feldstein, J.B. Overvest, et al., Treatment strategies and outcomes of pediatric esthesioneuroblastoma: a systematic review, *Front Oncol.* 10 (2020) 1247. Jul 24.
- [10] P.J. Bradley, N.S. Jones, I. Robertson, Diagnosis and management of esthesioneuroblastoma, *Curr. Opin. Otolaryngol. Head. Neck Surg.* 11 (2) (2003) 112–118 (Apr).
- [11] H.T. Eich, B. Hero, S. Staar, O. Micke, H. Seegenschmied, A. Mattke, et al., Multimodality therapy including radiotherapy and chemotherapy improves event-free survival in stage C Esthesioneuroblastoma, *Strahl. Onkol.* 179 (4) (2003) 233–240 (Apr).
- [12] B. Dumont, B. Fresneau, L. Claude, A. Defachelles, V. Couloigner, S. Puget, et al., Pattern of loco-regional relapses and treatment in pediatric esthesioneuroblastoma: The French very rare tumors group (*Fracture*) contribution, *Pedia Blood Cancer [Internet]* 67 (4) (2020) (Available from), (<https://onlinelibrary.wiley.com/doi/10.1002/pbc.28154>).
- [13] A. Ferrari, D.T. Schneider, G. Bisogno, Y. Reguerre, J. Godzinski, E. Bien, et al., Facing the challenges of very rare tumors of pediatric age: the European cooperative study group for pediatric rare tumors (EXPERT) background, goals, and achievements, *Pedia Blood Cancer* 68 (Suppl 4) (2021), e28993 (Jun).
- [14] D. Orbach, A. Ferrari, D.T. Schneider, Y. Reguerre, J. Godzinski, E. Bien, et al., The European paediatric rare tumours network - European registry (PARTNER) project for very rare tumors in children, *Pedia Blood Cancer* 68 (Suppl 4) (2021), e29072 (Jun).
- [15] W.M. Gillette, D.C. Hubbard, J.N. Waters, A.S. Johnson, Esthesioneuroblastoma presenting with orbital signs and ectopic adrenocorticotrophic hormone syndrome, *Proc. Bayl. Univ. Med. Cent.* 35 (2) (2022) 245–247.
- [16] B. Fiani, S.A. Quadri, A. Cathel, M. Farooqui, A. Ramachandran, I. Siddiqi, et al., Esthesioneuroblastoma: a comprehensive review of diagnosis, management, and current treatment options, *World Neurosurg.* 126 (2019) 194–211 (Jun).
- [17] R. Kumar, Esthesioneuroblastoma: multimodal management and review of literature, *World J. Clin. Cases* 3 (9) (2015) 774–778. Sep 16.
- [18] S.M. Broski, C.H. Hunt, G.B. Johnson, R.M. Subramaniam, P.J. Peller, The added value of 18F-FDG PET/CT for evaluation of patients with esthesioneuroblastoma, *J. Nucl. Med. Publ. Soc. Nucl. Med* 53 (8) (2012) 1200–1206 (Aug).
- [19] A.B. Dublin, M. Bobinski, Imaging characteristics of olfactory neuroblastoma (esthesioneuroblastoma), *J. Neurol. Surg. Part B Skull Base* 77 (1) (2016) 1–5 (Feb).
- [20] K.J. Kairemo, A.P. Jekunen, M.S. Kestilä, H.A. Ramsay, Imaging of olfactory neuroblastoma—an analysis of 17 cases. *Auris Nasus Larynx* 25 (2) (1998) 173–179 (May).
- [21] M. Roytman, A.B. Tassler, A. Kacker, T.H. Schwartz, G.A. Dobri, S.B. Strauss, et al., 68Ga]-DOTATATE PET/CT and PET/MRI in the diagnosis and management of esthesioneuroblastoma: illustrative cases, *J. Neurosurg. Case Lessons* 1 (2) (2021), CASE2058. Jan 11.
- [22] P. Dulguerov, A.S. Allal, T.C. Calcaterra, Esthesioneuroblastoma: a meta-analysis and review, *Lancet Oncol.* 2 (11) (2001) 683–690 (Nov).
- [23] S.E. Mills, Neuroectodermal neoplasms of the head and neck with emphasis on neuroendocrine carcinomas, *Mod. Pathol. J. U S Can. Acad. Pathol. Inc.* 15 (3) (2002) 264–278 (Mar).
- [24] M. Classe, H. Yao, R. Mouawad, C.J. Creighton, A. Burgess, F. Allanic, et al., Integrated multi-omic analysis of esthesioneuroblastomas identifies two subgroups linked to cell ontogeny, *Cell Rep.* 25 (3) (2018) 811–821, e5.
- [25] G.L. Gallia, M. Zhang, Y. Ning, M.C. Haffner, D. Batista, Z.A. Binder, et al., Genomic analysis identifies frequent deletions of Dystrophin in olfactory neuroblastoma, *Nat. Commun.* 9 (1) (2018), 5410. Dec 21.
- [26] S. Kadish, M. Goodman, C.C. Wang, Olfactory neuroblastoma. A clinical analysis of 17 cases, *Cancer* 37 (3) (1976) 1571–1576 (Mar).
- [27] A. Morita, M.J. Ebersold, K.D. Olsen, R.L. Foote, J.E. Lewis, L.M. Quast, Esthesioneuroblastoma: prognosis and management, *Neurosurgery* 32 (5) (1993) 706–714, discussion 714–715.
- [28] M. Lechner, Y. Takahashi, M. Turri-Zanoni, J. Liu, N. Counsell, M. Hermsen, et al., Clinical outcomes, Kadish-INSICA staging and therapeutic targeting of somatostatin receptor 2 in olfactory neuroblastoma, *Eur. J. Cancer* 162 (2022) 221–236 (Feb).
- [29] S.G. Patel, B. Singh, H.E. Stambuk, D. Carlson, P.G. Bridger, G. Cantu, et al., Craniofacial surgery for esthesioneuroblastoma: report of an international collaborative study, *J. Neurol. Surg. Part B Skull Base* 73 (3) (2012) 208–220 (Jun).
- [30] M.E. Kababri, N. Gaspar, C. Dufour, O. Oberlin, Esthesioneuroblastoma in children and adolescent: experience on 11 cases with literature review, *J. Pedia Hematol. Oncol.* 36 (2) (2014).
- [31] P. Nicolai, P. Battaglia, M. Bignami, A. Bolzoni Villaret, G. Delù, T. Khrais, et al., Endoscopic surgery for malignant tumors of the sinonasal tract and adjacent skull base: a 10-year experience, *Am. J. Rhinol.* 22 (3) (2008) 308–316.
- [32] A. AlQahtani, M. Turri-Zanoni, I. Dallan, P. Battaglia, P. Castelnuovo, Endoscopic endonasal resection of sinonasal and skull base malignancies in children: feasibility and outcomes, *Childs Nerv. Syst. ChNS J. Int Soc. Pedia Neurosurg.* 28 (11) (2012) 1905–1910 (Nov).
- [33] T.S. Fu, E. Monteiro, N. Muhanna, D.P. Goldstein, J.R. de Almeida, Comparison of outcomes for open versus endoscopic approaches for olfactory neuroblastoma: a systematic review and individual participant data meta-analysis, *Head Neck* 38 (Suppl 1) (2016) E2306–E2316 (Apr).
- [34] Wang Y., Li J., Tian Z., Zhu Y. Clinicopathologic features and molecular spectrum of spindle cell and sclerosing rhabdomyosarcomas in the head and neck region.:9.
- [35] M. Spengler, M. Wheelden, H.B. Mackley, J.J. Drabick, Durable major response with pazopanib in recurrent, heavily pretreated metastatic esthesioneuroblastoma harboring a fumarate hydratase mutation, *JCO Precis Oncol.* 5 (2021), PO.20.00486.
- [36] L. Wang, Y. Ding, L. Wei, D. Zhao, R. Wang, Y. Zhang, et al., Recurrent olfactory neuroblastoma treated with cetuximab and sunitinib: a case report, *Medicine* 95 (18) (2016), e3536 (May).
- [37] M. Preusser, M. Hutterer, M. Sohm, O. Koperek, K. Elandt, K. Dieckmann, et al., Disease stabilization of progressive olfactory neuroblastoma (esthesioneuroblastoma) under treatment with sunitinib mesylate, *J. Neurooncol* 97 (2) (2010) 305–308 (Apr).
- [38] E.M. Dunbar, P.K. Pumphrey, S. Bidari, Unexpectedly durable palliation of metastatic olfactory neuroblastoma using anti-angiogenic therapy with Bevacizumab, *Rare Tumors* 4 (2) (2012), e33. Apr 12.