



**HAL**  
open science

# Relationships between migraine and epilepsy: Pathophysiological mechanisms and clinical implications

G Demarquay, S Rheims

► **To cite this version:**

G Demarquay, S Rheims. Relationships between migraine and epilepsy: Pathophysiological mechanisms and clinical implications. *Revue Neurologique*, 2021, 177 (7), pp.791 - 800. 10.1016/j.neurol.2021.06.004 . hal-04832319

**HAL Id: hal-04832319**

**<https://hal.science/hal-04832319v1>**

Submitted on 11 Dec 2024

**HAL** is a multi-disciplinary open access archive for the deposit and dissemination of scientific research documents, whether they are published or not. The documents may come from teaching and research institutions in France or abroad, or from public or private research centers.

L'archive ouverte pluridisciplinaire **HAL**, est destinée au dépôt et à la diffusion de documents scientifiques de niveau recherche, publiés ou non, émanant des établissements d'enseignement et de recherche français ou étrangers, des laboratoires publics ou privés.



Available online at  
**ScienceDirect**  
[www.sciencedirect.com](http://www.sciencedirect.com)

Elsevier Masson France  
**EM|consulte**  
[www.em-consulte.com](http://www.em-consulte.com)



## International meeting of the French society of neurology 2021

# Relationships between migraine and epilepsy: Pathophysiological mechanisms and clinical implications

G. Demarquay<sup>a,b,\*</sup>, S. Rheims<sup>a,b</sup>

<sup>a</sup> Department of Functional Neurology and Epileptology, Hospices Civils de Lyon and Lyon 1 University, Lyon, France

<sup>b</sup> Lyon Neuroscience Research Center (CRNL), INSERM U1028, CNRS UMR5292 and Lyon 1 University, Lyon, France

### INFO ARTICLE

#### Article history:

Received 31 May 2021  
 Received in revised form  
 26 June 2021  
 Accepted 28 June 2021  
 Available online xxx

#### Keywords:

Epilepsy  
 Headache  
 Migraine  
 Ictal epileptic headache  
 Post-ictal headache  
 Migralepsy  
 excitability

### ABSTRACT

Migraine and epilepsy are distinct neurological diseases with specific clinical features and underlying pathophysiological mechanisms. However, numerous studies have highlighted the complex and multifaceted relationships between the two conditions. The relationships between headache and epilepsy manifest themselves in different ways. Firstly, the clinical diagnosis of these disorders may be challenging in view of possible overlapping. While post-ictal headache is a frequent condition, ictal epileptic headache is a rare but challenging diagnosis. Both situations raise the question of the pathophysiological mechanism of headache triggered by seizures. Migraine aura and epilepsy can also exhibit overlapping symptoms leading to their misdiagnosis, in particular in the case of visual aura. Secondly, migraine with aura and epilepsy can occur as a co-morbid condition, particularly in familial hemiplegic migraine (FHM). From a pathophysiological perspective, the identification of genetic mutations in FHM has brought significant advances in the understanding of dysfunctions of neuronal networks leading to hyperexcitability. The purpose of this review is to present clinical situations encompassing headache and epilepsy that can be challenging in neurological practice and to discuss the underlying pathophysiological mechanism of such interactions.

© 2021 Elsevier Masson SAS. All rights reserved.

Some surprise may be felt that migraine is given a place in the borderland of epilepsy, but the position is justified by many relations, and among them by the fact that the two maladies are sometimes mistaken, and more often their distinction is difficult Gowers 1907 [1]

## 1. Introduction

Migraine and epilepsy are distinct neurological diseases with specific clinical features and underlying pathophysiological

\* Corresponding author at: Department of Functional Neurology and Epileptology, Hospices Civils de Lyon and Lyon 1 University, Lyon, France.

E-mail address: [genevieve.demarquay@chu-lyon.fr](mailto:genevieve.demarquay@chu-lyon.fr) (G. Demarquay).

<https://doi.org/10.1016/j.neurol.2021.06.004>

0035-3787/© 2021 Elsevier Masson SAS. All rights reserved.

mechanisms. However, the frequent co-occurrence of both conditions in a single patient and possible clinical similarities have been pointed out by Gowers since the beginning of the 20th century [1]. Numerous studies have since highlighted the complex relationship between headache and epilepsy. A recent review and meta-analysis have shown that the pooled estimated prevalence of headache among patients with epilepsy was 48.4%, including primary headache such as migraine with or without aura (26%) and tension-type headache (26.2%), and secondary headache such as seizure-related headache (43.1%) [2]. There is an overall 52% increase in the prevalence of migraine among patients with epilepsy versus non-epileptic patients and an overall 79% increase in the prevalence of epilepsy among migraine patients versus non-migraineurs (see [3] for a systematic review and meta-analysis). In clinical practice, the relationships between headache and epilepsy can be encountered in different situations.

The relationships between headache and epilepsy manifest themselves in different ways. Firstly, the clinical diagnosis of these disorders may be challenging in view of possible overlapping. While post-ictal headache is a frequent condition, ictal epileptic headache is a rare but challenging diagnosis. Both situations raise the question of the pathophysiological mechanism of headache triggered by seizures. Migraine aura and epilepsy can also exhibit overlapping symptoms leading to their misdiagnosis, in particular in the case of visual aura. Secondly, migraine with aura and epilepsy can occur as a co-morbid condition, particularly in familial hemiplegic migraine (FHM). From a pathophysiological perspective, the identification of genetic mutations in FHM has brought significant advances in the understanding of dysfunctions of neuronal networks leading to hyperexcitability. Thirdly, the fact that some antiepileptics drugs are effective at preventing migraine attacks supports the hypothesis that migraine and epilepsy share several common pathogenetic mechanisms.

The purpose of this review is to present clinical situations encompassing headache and epilepsy that can be challenging in neurological practice. We will first present clinical features of seizure-related headache, as well as their lateralizing and localizing value and pathophysiological mechanisms. In the second part of this article, we will focus on the clinical and pathophysiological relationships between migraine with aura and epilepsy. In the last part, we will present the antiepileptic drugs that have a proven efficacy in the preventative treatment of migraine.

## 2. Seizure-related headache

### 2.1. Definitions and characteristics

#### 2.1.1. Ictal epileptic headache

2.1.1.1. *Definition and clinical features.* Headache can occur during an epileptic seizure and diagnostic criteria of ictal epileptic headache have been proposed both by the International Classification of Headache Disorders (ICHD) [4] and by the International League Against Epilepsy (ILAE) [5].

**Table 1 – ICHD-3 diagnostic criteria for ictal epileptic headache [4].**

- A. Any headache fulfilling criterion C
- B. The patient is having a partial epileptic seizure
- C. Evidence of causation demonstrated by both of the following
  1. Headache has developed simultaneously with onset of the partial seizure
  2. Either or both of the following
    - a. Headache is ipsilateral to the ictal discharge
    - b. Headache significantly improves or remits immediately after the partial seizure has terminated
- D. Not better accounted for by another ICHD-3 diagnosis

According to the ICHD, ictal epileptic headache is caused by and occurs during a focal epileptic seizure (Table 1) [4]. The pain can be described by patients with migraine features or tension-type headache-like features, though non-specific headaches are also reported [6,7]. Ictal epileptic headache can be diffuse or lateralized [6]. This symptom can represent the only manifestation of the seizure (see the paragraph below) or can be associated with other epileptic symptoms. The duration of ictal headache may vary from seconds or minutes to hours or days in patients with status epilepticus. The term “hemicrania epileptica” was previously used to characterize ictal epileptic headache ipsilateral to the seizure [8]. In the current classification, hemicrania epileptica is considered as a very rare variant of ictal epileptic headache [4].

According to the ILAE, ictal epileptic headache is classified as a “focal sensory seizure with cephalic sensation, characterized by a sensation in the head such as light-headedness or headache” [5]. The term of cephalic aura is also used to refer to “abnormal sensations of the brain” [9] that can be more or less painful, such as dizziness, lightheadedness, electrical shock-like feelings, head numbness, and pressure [10]. To our knowledge, no formal definition differentiates ictal epileptic headache with tension-type headache-like features and cephalic aura, even though this latter is frequently associated with frontal aura [9] [11,12]. Contrary to the definition of ictal epileptic headache (Table 1) [4], focal sensory seizure with cephalic sensation and cephalic aura usually refers to diffuse headache.

2.1.1.2. *Pure ictal epileptic headache: a diagnostic challenge.* - Rarely, headache represents the sole manifestation of the seizure; this condition is called “pure ictal epileptic headache”. Overall, 35 patients with pure epileptic headache have been reported so far [6]; [13,14] but this condition may be underestimated. Indeed, “pure ictal epileptic headache” has no specific clinical characteristics and can mimic migraine or tension-type headache [6,15]. Accordingly, diagnostic confirmation requires to observe the concomitant focal epileptic discharge on electroencephalograph (EEG) monitoring. The head pain usually lasts from a few seconds to a few minutes. In rare cases, pure ictal epileptic headache can last hours, corresponding to the only symptom of a nonconvulsive status epilepticus [16,17]. Headache can be bilateral, ipsilateral or contralateral to the epileptogenic zone (see [6] for review).

**Table 2 – ICHD-3 diagnostic criteria for post-ictal epileptic headache [4]).**

A. Any headache fulfilling criterion C
B. The patient has recently had a partial or generalized epileptic seizure
C. Evidence of causation demonstrated by both of the following: <ol style="list-style-type: none"> <li>1. Headache has developed within three hours after the epileptic seizure has terminated</li> <li>2. Headache has resolved within 72 h after the epileptic seizure has terminated</li> </ol>
D. Not better accounted for by another ICHD-3 diagnosis

### 2.1.2. Post-ictal epileptic headache

2.1.2.1. *Definition and clinical features.* Post-ictal headache refers to head pain caused by and occurring within three hours after an epileptic seizure [4] (Table 2). The rate of post-ictal headache ranges from 21.3% [18] to 46.3% [19]. According to a recent meta-analysis, the pooled estimated prevalence of post-ictal headache is 43.1% [2]. In a recent longitudinal study, post-epileptic headache occurred after all seizures in 46.4% of patients, frequently in 37.1% and rarely in 7.6% [19] while another study showed that headache occurred in more than 50% of seizures in the majority of patients [20].

Headache can present with migraine features or tension-type headache-like features. Post-ictal headaches with migraine features are reported by 34 to 48% of adult patients while tension headache-like symptoms are described by 35% of patients (see for review [21]). Pain intensity is usually moderate-to-severe with a pain score rated between 6.1 and 6.3 on visual analogic scale (VAS) [21]. A recent meta-analysis found a mean weighted frequency of post-ictal headache and post-ictal migraine of 33% and 16% respectively [22]. Post-ictal headache is more frequently reported after generalized seizures than focal seizures [19,21,23,24]. Post-ictal headaches are also common in children, lasting minutes to hours and more likely to occur after generalized seizures [25]. In patients with focal epilepsy, post-ictal headache occurs more frequently in occipital lobe epilepsy than in frontal lobe epilepsy [24].

2.1.2.2. *A frequent but untreated headache.* As discussed below, post-ictal headache might be helpful for better localizing the seizure onset zone. However, post-ictal headache should foremost be recognized in order to propose an appropriate treatment. While post-ictal headache is a frequent symptom, this painful condition remains frequently underestimated and, most importantly, undertreated [20]. Usually, neurologists and patients focus their attention on seizures and not on post-ictal symptoms. A study revealed that only 30% of attacks were treated with analgesic medications [20], even for postictal headache of four hours or longer duration. Other studies reported an even lower rate of analgesic use. In Wang et al., none of the 469 patients with post-ictal headache used analgesics [26] whereas another study found that despite a mean post-ictal headache of 300 min and a mean VAS score of  $5.9 \pm 2.3$ , most of the patients did not treat head pain [27]. According to Förderreuther et al. [20], patients do not treat their post-ictal headache because they worry about taking more tablets and do not have a specific prescription.

In practice, clinicians should pay more attention to post-ictal epileptic headache. First, we should ask patients specifically about post-ictal symptoms, in particular patients with occipital lobe epilepsy or generalized epilepsy, and define the type and the duration of the headache. Secondly, an acute treatment should be considered in patients with disabling headache. Analgesics such as paracetamol or non-steroidal anti-inflammatory drugs (NSAIDs) can be effective but severe and long-duration headache with migraine-like features may require specific treatments. In patients with disabling post-ictal headache with migraine features non-responsive to analgesics, triptans can be effective at relieving acute pain [28,29].

### 2.1.3. Pre-ictal epileptic headache

The term “pre-ictal headache” is used to characterize headache starting before the onset of the seizure [27,30]. Some authors distinguish prodromal pre-ictal headache that occurs 24 h to 30 min before seizure onset and early pre-ictal headache that occurs within 30 min of seizure onset [7,31]. Pre-ictal epileptic headache is not included in the current International Classification of Headache Disorders. Moreover, distinguishing pre-ictal headache from headache that would correspond to initial subjective symptoms triggered by the epileptic discharge may be difficult.

## 2.2. What is the lateralizing and localizing value of seizure-related headache?

### 2.2.1. Lateralizing value

In patients with temporal lobe epilepsy, peri-ictal headaches (including pre-ictal, ictal and post-ictal headaches) may have a lateralization value when the pain is ipsilateral [7,32,33]. A first study conducted in 60 patients with temporal lobe epilepsy and 60 with extratemporal epilepsy found that peri-ictal headache was more likely to be ipsilateral to the seizure focus in patients with temporal lobe epilepsy (27/30 patients) than in patients with extratemporal epilepsy (2/17 patients) [33]. In another study conducted in 100 patients with mesial temporal lobe epilepsy with hippocampal sclerosis, 72 patients suffered from peri-ictal headache [32]. Among the 42 patients with unilateral headache—including interictal and peri-ictal headache—the pain was ipsilateral to the seizure in 31. More recently, an interview of 400 patients with drug-resistant focal epilepsy undergoing presurgical evaluation found a strong association between headache side and seizure focus lateralization for both peri-ictal and inter-ictal unilateral headache and both temporal and extra-temporal lobe epilepsy [7].

### 2.2.2. Localizing value

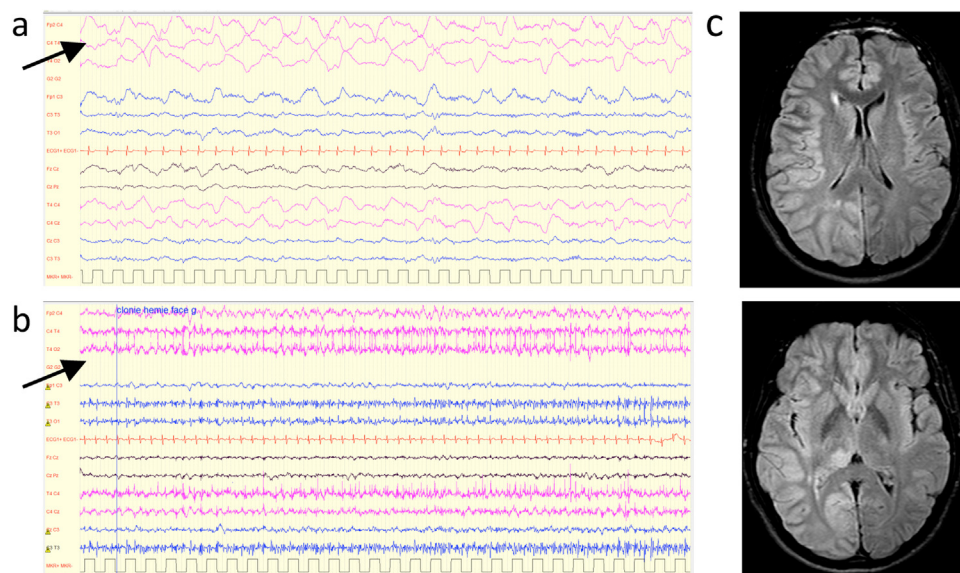
Fewer studies have evaluated the possible localizing value of seizure-related headache. Cephalic aura seems to be a common aura in frontal lobe epilepsy. For Palmmini and Gloor [11], cephalic aura was found in 24% of patients ( $n = 49$ ) with frontal epilepsy but only in 12% ( $n = 5$ ) with temporal epilepsy and in 3% ( $n = 1$ ) with parieto-occipital epilepsy. Cephalic aura was reported respectively in 35% ( $n = 9/26$ ) of patients with refractory frontal lobe epilepsy (35%) [34] and in 7.8% ( $n = 6/76$ ) of frontal aura [9]. In a stereoelectroencephalography (SEEG)

study performed in 11 patients with subjective signs and premotor epilepsy, three patients reported cephalic aura: “electrical sensation in the head, sometimes in the whole body, epigastric sensation” “cephalic sensation like a weight on the head, dizziness”, “indefinable sensation in the head” [35].

An important orientation element is the headache duration. Although occipital seizures can rarely be associated with headache of brief duration [36], the majority of patients with headaches related to parieto-occipital or occipital seizure present with long duration migraine-like headache associated with phono-photophobia and/or nausea, which can evolve to non-convulsive status epilepticus mimicking a migraine attack lasting hours or even days [16,37,38]. Similarly, post-ictal headache is frequently associated with occipital epilepsy [24] and is also common in idiopathic childhood occipital epilepsy of Gastaut [39]. In contrast, frontal or temporal lobe epilepsy are associated with brief headaches (Table 1) [6]. Headaches occurring during epileptic aura (i.e. subjective manifestations triggered by the epileptic discharge at the onset of a focal seizure) could also point to a seizure origin in the temporal or frontal regions. In a study including patients who underwent video-EEG monitoring, six out of 831 (0,7%) experienced headache as an aura [15]. Five of them suffered from temporal lobe seizures and one from central seizure. The headache was diffuse in one patient, bifrontal in one patient, ipsilateral to the focus in three patients and contralateral in one patient. In patients suffering from temporo-mesial epilepsy with hippocampal sclerosis, headache was reported in 3% of auras [40].

### 2.3. Pathophysiology of seizure-related headache

The pathophysiological mechanism of seizure-related headache is still a matter of debate and can vary depending to both the origin of the seizure and the nature of the headache. Long duration headaches with migraine-like features occurring during either status epilepticus (ictal headache) or after the seizure (post-ictal headache) may reflect the activation of the trigeminovascular system by the seizure. Mechanical and electrical studies conducted in the middle of the 20<sup>th</sup> century described dura mater, venous sinuses, meningeal and pial arteries as pain-sensitive intracranial structures [41,42]. These findings and further studies on neuropeptide-containing trigeminal nerves led to the description of the trigeminovascular system (see [43] for review). Alternatively, brief epileptic headache could reflect cortical symptoms elicited by the epileptic discharge. SEEG studies have shown that headache can be induced by stimulations. The earliest studies conducted by Penfield and colleagues mentioned that ipsilateral or contralateral headache to the stimulated side could exceptionally be evoked by cortical stimulations [44]. The authors stated that “these painful sensations are to be looked upon as evidences of referred pain from stimulation of the brain as an organ. This would seem to be contradictory to the statement (.) that the brain is insensitive” [44]. Further studies reported headache in patients with drug resistant epilepsy in response to stimulation of the insula [45] and rhinal cortex [46]. A recent study including more 16,000 cortical stimulations performed in 266 patients who underwent a SEEG showed that headache was evoked in 1.3% of cortical stimulations, mostly during the



**Fig. 1 – Occurrence of a focal status epilepticus in a severe hemiplegic migraine attack in a patient with ATP1A2 mutation. An 18-year-old man was brought to the emergency department for a severe migraine attack with left hemiplegia and drowsiness. EEG on admission (a) showed right delta activity. Six days after admission, he developed recurrent clonic seizures affecting the left side of the body. EEG (b) showed focal status epilepticus affecting the right hemisphere. MRI (c) performed during the status epilepticus showed an increased signal and swelling of the cortex and juxtacortical white matter in the right hemisphere. Genetic analysis confirmed the diagnosis of familial hemiplegic migraine (FHM2).**

temporo-frontal limbic stimulations [47]. Pain was more frequently described as bilateral (42.31%) than ipsilateral (16.83%) or contralateral. The pathophysiology of headache triggered by electrical stimulations is still unknown, but the hypothesis of a meningeal spread of the electrical stimulation is unlikely when the pain is bilateral or contralateral to the electrical stimulation. Triggered-headaches by SEEG stimulations and ictal headache may reflect either somatosensory pain caused by activation of the central network in pain or an autonomic response resulting from activation of the central autonomic network [47,48].

### 3. Epilepsy and migraine with aura

#### 3.1. Coexistence between epilepsy and hemiplegic migraine

The most obvious link between migraine and epilepsy conditions is observed in patients with FHM, a rare autosomal dominantly inherited subtype of migraine with aura. FHM is caused by mutations in three main genes *CACNA1A* (FHM1), *ATP1A2* (FHM2) and *SCN1A* (FHM3) which all encode ion transporters (see for review [49]). Mutations of the pre-synaptic protein *PRRT2* have also been identified in patients with hemiplegic migraine [50,51]. Attacks of hemiplegic migraine include both: reversible motor weakness ranging from mild paresis to complete hemiplegia and; reversible visual, sensory, and/or speech/language symptoms [4].

Contrary to migraine with non-hemiplegic aura, subjects with FHM mutations can also<sup>1</sup> present cerebellar ataxia and paroxysmal features including recurrent coma or epilepsy. Mutations in FHM gene have been identified both in FHM and in epilepsy. In affected families, patients can present both epilepsy and hemiplegic attacks, epilepsy without migraine attacks or hemiplegic attacks but no seizure [52]. Seizures can occur during hemiplegic migraine attacks (Fig. 1). Unlike non-hemiplegic migraine, severe FHM attacks can include variable degrees of impaired consciousness, confusion, elevated temperature and cerebral edema [49]. Focal seizures have been reported during such severe hemiplegic attacks in patients carrying *CACNA1A* and *ATP1A2* mutations, but not *SCN1A* (see for review [52,53]). Alternatively, seizures can occur independently from familial hemiplegic migraine attacks. Epilepsy can be focal or generalized without a clear correlation between mutation type (*CACNA1A*, *ATP1A2*, *SCN1A* and *PRRT2*) and the type of epilepsy. However, epilepsy seems to occur frequently before the onset of the hemiplegic attacks during childhood [53]. Moreover, the evolution of epilepsy has a good prognosis in the majority of patients [52]. This good evolution is particularly striking in FHM patients with *SCN1A* mutations and strongly contrasts with Dravet syndrome, a severe epileptic encephalopathy associated with other types of *SCN1A* mutations.

The genetics of migraine is detailed in another article by Anne Ducros of this themed issue dedicated to migraine.

<sup>1</sup> Attacks of hemiplegic migraine include both reversible motor weakness ranging from mild paresis to complete hemiplegia and reversible visual, sensory and/or speech language symptoms

Briefly, the gene *CACNA1A* codes for the  $\alpha 1$  subunit of the Cav2.1 P/Q type Ca<sup>2+</sup> channel. FHM1 is generally associated with missense gain-of-function mutations with increased Ca<sup>2+</sup> influx and enhanced glutamate release at cortical synapses [54]. *ATP1A2* encodes the  $\alpha 2$  subunit of the sodium-potassium ATPase pump mainly expressed in astrocytes. FHM2 mutations lead to impaired glial reuptake of potassium and glutamate from the synaptic cleft [54]. Both a gain of function of Cav2.1 and a loss of function of the  $\alpha 2$  Na<sup>+</sup>/K<sup>+</sup> pump could lead to increased glutamate release from excitatory synapses or decreased glutamate clearance by astrocytes and consequently increase the propensity to cortical spreading depression [53]. The *SCN1A* gene encodes the  $\alpha$ -subunit of voltage-gated sodium channel Nav1.1. Most of FHM3 mutations cause a gain of function in Nav1.1 leading to excessive excitability of glutamatergic neurons [53,55]. The genotype-phenotype correlations seem to depend on the functional effects of the *SCN1A* mutations rather than their positions in the canal proteins [55]. Overall, hemiplegic attacks and epilepsy can be generated by an alteration of the same neural network, but to our knowledge, the precise mechanisms that could generate epilepsy (mainly benign epilepsy in childhood) and spreading depression in migraine aura are not established [53].

#### 3.2. Differential diagnosis of migraine with visual aura and occipital epilepsy

##### 3.2.1. Clinical characteristics

Occipital epilepsy and migraine aura can present both positive and negative elementary visual symptoms (Table 3). The most common symptoms of migraine aura include flashes of bright light, phosphenes (small bright dots), foggy/blurred vision, zigzag lines, scotoma [56,57]. Most auras have more than one visual symptom [57]. The most characteristic symptom of migraine aura is fortification spectrum (or teichopsia). The most striking difference between occipital epilepsy and migraine aura relies on the duration of the visual symptoms: from seconds to minutes in epilepsy, from 5 to 60 min (mean duration 30 min) in migraine aura [56,57]. In a study comparing the clinical characteristics of migraine and epileptic visual auras, the mean duration of aura was 56 s in epilepsy and 20 min in migraine [58]. A cutoff duration of  $\geq 5$  min was discriminant to identify migraine patients (100% sensitivity, 92% specificity). One exception that can lead to an incorrect diagnosis is status epilepticus (see chapter below 3.2.2). Regarding the clinical description of the aura, a stereotypic lateralization and a horizontal drift of visual symptoms points to an epileptic origin [58]. In contrast, migraine aura can present with heterogenous clinical presentation within the same patient [59]. The majority of migraine aura (76%) has a gradual onset [60], while epilepsy is associated with a sudden onset of visual aura. Contrary to previous reports [61], colorful aura may be encountered in migraine aura [56,58]. Associated symptoms may also be helpful to distinguish the two entities, such as the occurrence of other epileptic symptoms or, on the contrary, migrainous somatosensory, aphasic and/or hemiplegic aura. Migraine-like headache with nausea/vomiting, photo-phonophobia points to a migraine origin but it is important to recall that

**Table 3 – Key differences for differentiating visual auras in migraine and epilepsy.**

	Migraine aura	Occipital lobe epilepsy
Duration	May vary from 5 to 60 min (mean 20–30 min)	Vary from seconds to minutes (typically < 5 min) except status epilepticus)
Onset of symptoms	Progressive	Sudden
Variability in the clinical presentation	Possible variability of visual symptoms and alternated side between attacks	Homogeneous presentation and frequent restriction of the visual sensation to one visual field
Accompanying symptoms	Somatosensory, aphasic and/or hemiplegic aura	Other epileptic symptoms
Headache	Frequent (migrainous or non-migrainous headache) but aura without headache can occur	Rare but migrainous or non-migrainous headache can occur especially after status epilepticus

occipital epilepsy is frequently followed by a post-ictal headache that can present with migraine-like features (see chapter I.1.2).

### 3.2.2. Migralepsy

Migralepsy or migraine-aura triggered seizure is a debatable concept that describes a condition in which an epileptic seizure is preceded by an attack of migraine with aura. This term was first used by Lennox and Lennox to characterize “ophthalmic migraine with perhaps nausea and vomiting followed by symptoms characteristic of epilepsy” [62]. However, visual migraine aura and occipital seizures may be mistaken one for the other, in particular in long-duration seizures (occipital status epilepticus) that can additionally be followed by a post-ictal headache. Occipital status epilepticus consisting of elementary visual hallucinations that evolve to a complex partial seizure or to secondary generalized seizure could mimic migralepsy. In a review of 50 potential migralepsy cases, most of the cases were questionable and suggestive of occipital lobe seizures [63]. To our knowledge, no convincing case with a concomitant EEG recording has been published.

## 4. Antiseizure drugs (ASD) in migraine

### 4.1. Which ASD are effective in migraine prophylaxis?

Among the available ASD, topiramate and sodium valproate (VPA) are the most studied and effective treatments for migraine prevention. However, both raise important issues in women of childbearing age, which must be balanced with their potential efficacy.

The effectiveness of VPA in the prevention of migraine was first suggested in an open-label study [64] and was confirmed in further placebo-controlled trials [65,66]. Other trials showed that divalproex sodium is also effective in migraine prevention [67,68]. Valproic acid is usually started at 250 mg/day with a slow titration to reach 500 to 1000 mg/day [69]. Common side effects include nausea, weight gain, somnolence, tremor, alopecia and increased liver function enzyme levels (liver function testing is recommended). As extensively shown, VPA significantly increases the risk of severe fetal malformations [70] as well as of cognitive deficits [71], mental retardation and autism [72] in children exposed in utero. Accordingly, VPA must not be prescribed for women with migraine of childbearing age.

Topiramate is an effective prophylactic medication for episodic migraine [73,74] and chronic migraine [75], even in the presence of medication overuse [76]. A meta-analysis showed that topiramate was superior to placebo in the overall mean reduction monthly number of headache day and was more effective than placebo at reducing migraine days by more than 50% [77]. Topiramate is usually started at 25 mg/day with a titration by 25 mg/week or slower to reach 100 mg/day (if necessary up to 200 mg per day). Common side effects include paresthesia, weight loss, cognitive effects (word-finding difficulties), depression, cognitive slowing, renal calculi, acute myopia with secondary angle closure glaucoma. Adverse events are more frequently reported by migraine patients than epileptic patients [78,79]. Topiramate is contraindicated in pregnant women and in those who wish to become pregnant, in patients with glaucoma, severe pulmonary disease, metformin use, hepatic disease, nephrolithiasis or renal failure. Topiramate must be used with caution in patients with depression. Topiramate has also been shown to increase the risk of severe malformations in fetuses exposed in utero, especially when used in association with other ASD [80]. Childbearing women must be clearly informed of this teratogenic risk.

Other ASD could be effective for the preventive treatment of migraine. Two meta-analyses concluded that levetiracetam was effective in patients with episodic migraine [77,81]. Levetiracetam showed efficacy in chronic migraine in one study, but was inferior to VPA [82]. Small-sized trials and a meta-analysis suggest that lamotrigine is effective in the prevention of migraine with aura [77,83] but there is not any proof of efficacy in migraine without aura. Furthermore, it should be noted that headache is a common side effect of lamotrigine [84].

In contrast, other ASD commonly used in the treatment of other painful disorders failed to prove efficacy in the prophylactic treatment of migraine. A multicenter, double-blind, placebo-controlled trial showed no difference between oxcarbazepine and placebo in the mean change in the number of migraine attacks [85]. Several trials demonstrated that gabapentin was not superior to placebo [77].

### 4.2. Mechanism of action of ASD in migraine

The mechanism of action underlying the preventive effect of ASD in migraine remains unknown. Preventive treatment may target peripheral-dural or central trigeminovascular mecha-

nisms involved in migraine pathophysiology. Animal studies showed that intravenous topiramate inhibits neuronal firing in the trigeminocervical complex and modulates trigemino-vascular transmission within the trigeminothalamic pathway [86–88]. More recently, VPA (as well as flunarizine, propranolol and amitriptyline) was shown to inhibit ongoing and acute nociceptive activation of central trigeminal neurons [89]. In this study, lamotrigine did not inhibit ongoing spontaneous trigeminocervical neuronal firing. Another study demonstrated that topiramate can inhibit the CGRP secretion from activated trigeminal neurons [90].

In humans, a placebo-controlled double-blind functional magnetic resonance imaging study performed in healthy subjects showed that topiramate decreases the activity in the thalamus and in other pain processing areas and increases functional coupling between the thalamus and several brain regions such as the bilateral precuneus, posterior cingulate cortex and secondary somatosensory cortex [91]. The authors suggested that topiramate modulates nociceptive trigeminal transmission in healthy subjects, attenuates the pain-related activity of parts of the thalamo-cortical network and enhances thalamic connectivity to the precuneus, posterior cingulate cortex and SII. In contrast, no significant effect of metoprolol on trigeminal pain processing was observed in a similar experimental protocol [92]. Alternatively, ASD may target mechanisms involved in cortical spreading depression. In animal models, topiramate and VPA (as well as propranolol, amitriptyline and methysergide) inhibit cortical spreading depression frequency [93]. Conversely, oxcarbazepine does not suppress cortical spreading depression [94]. Other studies have measured central excitability changes in migraine patients treated by ASD. The phosphene threshold measured by transcranial magnetic stimulation increases after 1-month treatment with VPA and is modestly correlated with the reduction of migraine headache in patients with migraine with aura, but not in patients without aura [95]. In patients without aura, the reduction of headache frequency was found to be inversely correlated with an increase of visual thresholds but did not correlate with motor thresholds [96]. In contrast, the measurement of cortical occipital excitability by transcranial magnetic stimulation using an objective technique of magnetic suppression of perceptual accuracy showed no significant correlation between mean change in headache frequency after topiramate treatment and mean change in inhibition from baseline to optimal dose [97]. Future research is needed for a better understanding of the mechanism of actions and efficacy of ASD in migraine.

## 5. Conclusion

An abundant literature has highlighted the complex and multifaceted relationships between migraine and epilepsy. The clinical diagnosis of these disorders may be challenging in view of possible overlapping. From a pathophysiological perspective, the identification of genetic mutations in rare forms of migraine and epilepsy has brought significant advances in the understanding of dysfunctions of neuronal networks leading to hyperexcitability. In addition, studies of ictal epileptic headache may help to better characterize the

underlying mechanisms of headache, in particular non-migrainous headache that are still poorly understood.

## Disclosure of interest

The author declares that he has no competing interest.

## REFERENCES

- [1] Gowers WR. The borderland of epilepsy: faints, vagal attacks, vertigo, migraine, sleep symptoms, and their treatment. vol. London: J. & A. Churchill, pp. 76-87. n.d.
- [2] Duko B, Ayalew M, Toma A. The epidemiology of headaches among patients with epilepsy: a systematic review and meta-analysis. *J Headache Pain* 2020;21:3. <http://doi.org/10.1186/s10194-020-1074-0>.
- [3] Keezer MR, Bauer PR, Ferrari MD, Sander JW. The comorbid relationship between migraine and epilepsy: a systematic review and meta-analysis. *Eur J Neurol* 2015;22:1038-47. <http://doi.org/10.1111/ene.12612>.
- [4] Headache Classification Committee of the International Headache Society (IHS). The International Classification of Headache Disorders, 3rd edition. *Cephalalgia* 2018;38:1-211. <http://doi.org/10.1177/0333102417738202>.
- [5] Fisher RS, Cross JH, D'Souza C, French JA, Haut SR, Higurashi N, et al. Instruction manual for the ILAE 2017 operational classification of seizure types. *Epilepsia* 2017;58:531-42. <http://doi.org/10.1111/epi.13671>.
- [6] Cianchetti C, Dainese F, Ledda MG, Avanzini G. Epileptic headache: a rare form of painful seizure. *Seizure* 2017;52:169-75. <http://doi.org/10.1016/j.seizure.2017.10.010>.
- [7] AlKhaja M, Alhowity I, Alotaibi F, Khoja A, Alsumaili M, Alsulami A, et al. Lateralization value of peri-ictal headache in drug-resistant focal epilepsy. *Epilepsy Behav* 2021;116:107712. <http://doi.org/10.1016/j.yebeh.2020.107712>.
- [8] Headache Classification Committee of the International Headache Society (IHS). The International Classification of Headache Disorders, 3rd edition (beta version). *Cephalalgia* 2013;33:629-808. <http://doi.org/10.1177/0333102413485658>.
- [9] Yin F, Ni D, Xu C, Yan X, Ma K, Zhang X, et al. Auras in intractable frontal lobe epilepsy: clinical characteristics, values, and limitations. *Epilepsy Behav* 2021;115:107724. <http://doi.org/10.1016/j.yebeh.2020.107724>.
- [10] Foldvary-Schaefer N, Unnwongse K. Localizing and lateralizing features of auras and seizures. *Epilepsy Behav* 2011;20:160-6. <http://doi.org/10.1016/j.yebeh.2010.08.034>.
- [11] Palmi A, Gloor P. The localizing value of auras in partial seizures: a prospective and retrospective study. *Neurology* 1992;42:801-8. <http://doi.org/10.1212/wnl.42.4.801>.
- [12] Kakisaka Y, Jehi L, Alkawadri R, Wang ZI, Enatsu R, Mosher JC, et al. Cephalic aura after frontal lobe resection. *J Clin Neurosci* 2014;21:1450-2. <http://doi.org/10.1016/j.jocn.2013.11.024>.
- [13] Taga A, Florindo I. Ictal headache: Insights from two cases. *Cephalalgia* 2018;38:1972-5. <http://doi.org/10.1177/0333102418758281>.
- [14] Viana PF, Hasegawa H, Jarosz J, Siddiqui A, Selway RP, Mullatti N. Short-lasting retroorbital pain attacks as a form of ictal epileptic headache: case report. *Cephalalgia* 2019;39:1195-9. <http://doi.org/10.1177/0333102419839792>.
- [15] Kim DW, Sunwoo J-S, Lee SK. Headache as an Aura of Epilepsy: Video-EEG Monitoring Study. *Headache* 2016;56:762-8. <http://doi.org/10.1111/head.12754>.



- [16] Belcastro V, Striano P, Pierguidi L, Calabresi P, Tambasco N. Ictal epileptic headache mimicking status migrainosus: EEG and DWI-MRI findings. *Headache* 2011;51:160–2. <http://doi.org/10.1111/j.1526-4610.2010.01709.x>.
- [17] Walker MC, Smith SJ, Sisodiya SM, Shorvon SD. Case of simple partial status epilepticus in occipital lobe epilepsy misdiagnosed as migraine: clinical, electrophysiological, and magnetic resonance imaging characteristics. *Epilepsia* 1995;36:1233–6. <http://doi.org/10.1111/j.1528-1157.1995.tb01067.x>.
- [18] Salma Z, Hanen HK, Salma S, Olfa H, Nouha F, Mariem D, et al. Headaches and their relationships to epileptic seizures. *Epilepsy Behav* 2019;90:233–7. <http://doi.org/10.1016/j.yebeh.2018.11.012>.
- [19] Caprara F, Letícia A, Rissardo JP, Leite MTB, Silveira JOF, Jauris PGM, et al. Characteristics of Post-Ictal Headaches in Patients with Epilepsy: a Longitudinal Study. *Seizure* 2020;81:244–9. <http://doi.org/10.1016/j.seizure.2020.08.001>.
- [20] Förderreuther S, Henkel A, Noachtar S, Straube A. Headache associated with epileptic seizures: epidemiology and clinical characteristics. *Headache* 2002;42:649–55. <http://doi.org/10.1046/j.1526-4610.2002.02154.x>.
- [21] Ekstein D, Schachter SC. Postictal headache. *Epilepsy Behav* 2010;19:151–5. <http://doi.org/10.1016/j.yebeh.2010.06.023>.
- [22] Subota A, Khan S, Josephson CB, Manji S, Lukmanji S, Roach P, et al. Signs and symptoms of the postictal period in epilepsy: A systematic review and meta-analysis. *Epilepsy Behav* 2019;94:243–51. <http://doi.org/10.1016/j.yebeh.2019.03.014>.
- [23] Schon F, Blau JN. Post-epileptic headache and migraine. *J Neurol Neurosurg Psychiatry* 1987;50:1148–52. <http://doi.org/10.1136/jnnp.50.9.1148>.
- [24] Ito M, Adachi N, Nakamura F, Koyama T, Okamura T, Kato M, et al. Multi-center study on post-ictal headache in patients with localization-related epilepsy. *Psychiatry Clin Neurosci* 2003;57:385–9. <http://doi.org/10.1046/j.1440-1819.2003.01136.x>.
- [25] Zawadzka M, Pilarska E, Konieczna S, Szmuda M, Matheisel A, Lemska A, et al. Peri-ictal headaches in the paediatric population - prospective study. *Cephalalgia* 2020. <http://doi.org/10.1177/0333102420977856> [333102420977856].
- [26] Wang X, Lang S, Zhang X, Zhu F, Wan M, Shi X, et al. Clinical factors associated with postictal headache in Chinese patients with partial epilepsy. *Seizure* 2014;23:191–5. <http://doi.org/10.1016/j.seizure.2013.11.011>.
- [27] Duchaczek B, Ghaeni L, Matzen J, Holtkamp M. Interictal and periictal headache in patients with epilepsy. *Eur J Neurol* 2013;20:1360–6. <http://doi.org/10.1111/ene.12049>.
- [28] Jacob J, Goadsby PJ, Duncan JS. Use of sumatriptan in post-ictal migraine headache. *Neurology* 1996;47:1104. <http://doi.org/10.1212/wnl.47.4.1104>.
- [29] Ogunyemi A, Adams D. Migraine-like symptoms triggered by occipital lobe seizures: response to sumatriptan. *Can J Neurol Sci* 1998;25:151–3. <http://doi.org/10.1017/s0317167100033771>.
- [30] Hofstra WA, Hageman G, de Weerd AW. Periictal and interictal headache including migraine in Dutch patients with epilepsy: a cross-sectional study. *Epilepsy Behav* 2015;44:155–8. <http://doi.org/10.1016/j.yebeh.2014.12.025>.
- [31] Yankovsky AE, Andermann F, Mercho S, Dubeau F, Bernasconi A. Preictal headache in partial epilepsy. *Neurology* 2005;65:1979–81. <http://doi.org/10.1212/01.wnl.0000188820.17776.cd>.
- [32] Nunes JC, Zakon DB, Claudino LS, Guarnieri R, Bastos A, Queiroz LP, et al. Hippocampal sclerosis and ipsilateral headache among mesial temporal lobe epilepsy patients. *Seizure* 2011;20:480–4. <http://doi.org/10.1016/j.seizure.2011.02.014>.
- [33] Bernasconi A, Andermann F, Bernasconi N, Reutens DC, Dubeau F. Lateralizing value of peri-ictal headache: A study of 100 patients with partial epilepsy. *Neurology* 2001;56:130–2. <http://doi.org/10.1212/wnl.56.1.130>.
- [34] Jobst BC, Siegel AM, Thadani VM, Roberts DW, Rhodes HC, Williamson PD. Intractable seizures of frontal lobe origin: clinical characteristics, localizing signs, and results of surgery. *Epilepsia* 2000;41:1139–52. <http://doi.org/10.1111/j.1528-1157.2000.tb00319.x>.
- [35] Beauvais K, Biraben A, Seigneuret E, Saikali S, Scarabin J-M. Subjective signs in premotor epilepsy: confirmation by stereo-electroencephalography. *Epileptic Disord* 2005;7:347–54.
- [36] Dainese F, Mai R, Francione S, Mainardi F, Zanchin G, Paladin F. Ictal headache: headache as first ictal symptom in focal epilepsy. *Epilepsy Behav* 2011;22:790–2. <http://doi.org/10.1016/j.yebeh.2011.10.007>.
- [37] Lindner A, Reiners K, Toyka KV. Meningeal hyperperfusion visualized by MRI in a patient with visual hallucinations and migraine. *Headache* 1996;36:53–7. <http://doi.org/10.1046/j.1526-4610.1996.3601053.x>.
- [38] Sethi M, Kowalczyk MA, Dalic LJ, Archer JS, Jackson GD. Abnormal neurovascular coupling during status epilepticus migrainosus in Sturge-Weber syndrome. *Neurology* 2017;88:209–11. <http://doi.org/10.1212/WNL.0000000000003492>.
- [39] Panayiotopoulos CP, Michael M, Sanders S, Valeta T, Koutroumanidis M. Benign childhood focal epilepsies: assessment of established and newly recognized syndromes. *Brain* 2008;131:2264–86. <http://doi.org/10.1093/brain/awn162>.
- [40] Dupont S, Samson Y, Nguyen-Michel V-H, Zavanone C, Clémenceau S, Miles R, et al. Are auras a reliable clinical indicator in medial temporal lobe epilepsy with hippocampal sclerosis? *Eur J Neurol* 2015;22:1310–6. <http://doi.org/10.1111/ene.12747>.
- [41] Graham J, Wolff H. Mechanism of migraine headache and action of ergotamine tartrate. *Arch Neurol Psychiatry* 1938;39:737–63.
- [42] Ray B, Wolf H. Experimental studies on headache: pain-sensitive structures of the head and their significance in headache. *Arch Surg* 1940;41:813–56.
- [43] Ashina M, Hansen JM, Do TP, Melo-Carrillo A, Burstein R, Moskowitz MA. Migraine and the trigeminovascular system-40 years and counting. *Lancet Neurol* 2019;18:795–804. [http://doi.org/10.1016/S1474-4422\(19\)30185-1](http://doi.org/10.1016/S1474-4422(19)30185-1).
- [44] Penfield WBE. Somatic motor and sensory representations in the cerebral cortex of man as studied by electrical stimulation. *Brain* 1937;60(4):389–443.
- [45] Afif A, Hoffmann D, Minotti L, Benabid AL, Kahane P. Middle short gyrus of the insula implicated in pain processing. *Pain* 2008;138:546–55. <http://doi.org/10.1016/j.pain.2008.02.004>.
- [46] Bartolomei F, Barbeau E, Gavaret M, Guye M, McGonigal A, Régis JET-AL>. Cortical stimulation study of the role of rhinal cortex in déjà vu and reminiscence of memories. *Neurology* 2004;63:858–64. <http://doi.org/10.1212/01.WNL.0000137037.56916.3F>.
- [47] Hotolean E, Mazzola L, Rheims S, Isnard J, Montavont A, Catenoix H, et al. Headaches provoked by cortical stimulation: Their localizing value in focal epileptic seizures. *Epilepsy Behav* 2021;122:108125. <http://doi.org/10.1016/j.yebeh.2021.108125>.
- [48] Parisi P, Belcastro V, Striano P. The Confirming Evidence for Ictal Epileptic Headache. *Headache* 2019;59:1832–3. <http://doi.org/10.1111/head.13678>.
- [49] Russell MB, Ducros A. Sporadic and familial hemiplegic migraine: pathophysiological mechanisms, clinical characteristics, diagnosis, and management. *Lancet*

- Neurol 2011;10:457–70. [http://doi.org/10.1016/S1474-4422\(11\)70048-5](http://doi.org/10.1016/S1474-4422(11)70048-5).
- [50] Riant F, Roze E, Barbance C, Méneret A, Guyant-Maréchal L, Lucas C, et al. PRRT2 mutations cause hemiplegic migraine. *Neurology* 2012;79:2122–4. <http://doi.org/10.1212/WNL.Ob013e3182752cb8>.
- [51] Suzuki-Muromoto S, Kosaki R, Kosaki K, Kubota M. Familial hemiplegic migraine with a PRRT2 mutation: phenotypic variations and carbamazepine efficacy. *Brain Dev* 2020;42:293–7. <http://doi.org/10.1016/j.braindev.2019.12.007>.
- [52] Haşirci Bayır BR, Tutkavul K, Eser M, Baykan B. Epilepsy in patients with familial hemiplegic migraine. *Seizure* 2021;88:87–94. <http://doi.org/10.1016/j.seizure.2021.03.028>.
- [53] Mantegazza M, Cestè S. Pathophysiological mechanisms of migraine and epilepsy: Similarities and differences. *Neurosci Lett* 2018;667:92–102. <http://doi.org/10.1016/j.neulet.2017.11.025>.
- [54] Di Stefano V, Rispoli MG, Pellegrino N, Graziosi A, Rotondo E, Napoli C, et al. Diagnostic and therapeutic aspects of hemiplegic migraine. *J Neurol Neurosurg Psychiatry* 2020;91:764–71. <http://doi.org/10.1136/jnnp-2020-322850>.
- [55] Prontera P, Sarchielli P, Caproni S, Bedetti C, Cupini LM, Calabresi P, et al. Epilepsy in hemiplegic migraine: Genetic mutations and clinical implications. *Cephalalgia* 2018;38:361–73. <http://doi.org/10.1177/0333102416686347>.
- [56] Queiroz LP, Friedman DI, Rapoport AM, Purdy RA. Characteristics of migraine visual aura in Southern Brazil and Northern USA. *Cephalalgia* 2011;31:1652–8. <http://doi.org/10.1177/0333102411430263>.
- [57] Viana M, Sances G, Linde M, Nappi G, Khaliq F, Goadsby PJ, et al. Prolonged migraine aura: new insights from a prospective diary-aided study. *J Headache Pain* 2018;19:77. <http://doi.org/10.1186/s10194-018-0910-y>.
- [58] Hartl E, Gonzalez-Victores JA, Rémi J, Schankin CJ, Noachtar S. Visual auras in epilepsy and migraine - an analysis of clinical characteristics. *Headache* 2017;57:908–16. <http://doi.org/10.1111/head.13113>.
- [59] Hansen JM, Baca SM, Vanvalkenburgh P, Charles A. Distinctive anatomical and physiological features of migraine aura revealed by 18 years of recording. *Brain* 2013;136:3589–95. <http://doi.org/10.1093/brain/awt309>.
- [60] Viana M, Sprenger T, Andelova M, Goadsby PJ. The typical duration of migraine aura: a systematic review. *Cephalalgia* 2013;33:483–90. <http://doi.org/10.1177/0333102413479834>.
- [61] Panayiotopoulos CP. Elementary visual hallucinations, blindness, and headache in idiopathic occipital epilepsy: differentiation from migraine. *J Neurol Neurosurg Psychiatry* 1999;66:536–40. <http://doi.org/10.1136/jnnp.66.4.536>.
- [62] Lennox WG, Lennox-Buchthal MA. *Epilepsy and related disorders/by William Gordon Lennox, with the collaboration of Margaret A. Lennox*. Boston: Little, Brown; 1960.
- [63] Sances G, Guaschino E, Perucca P, Allena M, Ghiotto N, Manni R. Migralepsy: a call for a revision of the definition. *Epilepsia* 2009;50:2487–96. <http://doi.org/10.1111/j.1528-1167.2009.02265.x>.
- [64] Sørensen KV. Valproate: a new drug in migraine prophylaxis. *Acta Neurol Scand* 1988;78:346–8. <http://doi.org/10.1111/j.1600-0404.1988.tb03667.x>.
- [65] Hering R, Kuritzky A. Sodium valproate in the prophylactic treatment of migraine: a double-blind study versus placebo. *Cephalalgia* 1992;12:81–4. <http://doi.org/10.1046/j.1468-2982.1992.1202081.x>.
- [66] Jensen R, Brinck T, Olesen J. Sodium valproate has a prophylactic effect in migraine without aura: a triple-blind, placebo-controlled crossover study. *Neurology* 1994;44:647–51. <http://doi.org/10.1212/wnl.44.4.647>.
- [67] Mathew NT, Saper JR, Silberstein SD, Rankin L, Markley HG, Solomon S, et al. Migraine prophylaxis with divalproex. *Arch Neurol* 1995;52:281–6. <http://doi.org/10.1001/archneur.1995.00540270077022>.
- [68] Klapper J. Divalproex sodium in migraine prophylaxis: a dose-controlled study. *Cephalalgia* 1997;17:103–8. <http://doi.org/10.1046/j.1468-2982.1997.1702103.x>.
- [69] Lanteri-Minet M, Valade D, Géraud G, Lucas C, Donnet A, Société française d'étude des migraines et des céphalées. [Guidelines for the diagnosis and management of migraine in adults and children]. *Rev Neurol (Paris)* 2013;169:14–29. <http://doi.org/10.1016/j.neurol.2012.07.022>.
- [70] Tomson T, Battino D, Bonizzoni E, Craig J, Lindhout D, Perucca E, et al. Comparative risk of major congenital malformations with eight different antiepileptic drugs: a prospective cohort study of the EURAP registry. *Lancet Neurol* 2018;17:530–8. [http://doi.org/10.1016/S1474-4422\(18\)30107-8](http://doi.org/10.1016/S1474-4422(18)30107-8).
- [71] Meador KJ, Baker GA, Browning N, Cohen MJ, Bromley RL, Clayton-Smith J, et al. Fetal antiepileptic drug exposure and cognitive outcomes at age 6 years (NEAD study): a prospective observational study. *Lancet Neurol* 2013;12:244–52. [http://doi.org/10.1016/S1474-4422\(12\)70323-X](http://doi.org/10.1016/S1474-4422(12)70323-X).
- [72] Christensen J, Grønborg TK, Sørensen MJ, Schendel D, Parner ET, Pedersen LH, et al. Prenatal valproate exposure and risk of autism spectrum disorders and childhood autism. *JAMA* 2013;309:1696–703. <http://doi.org/10.1001/jama.2013.2270>.
- [73] Brandes JL, Saper JR, Diamond M, Couch JR, Lewis DW, Schmitt J, et al. Topiramate for migraine prevention: a randomized controlled trial. *JAMA* 2004;291:965–73. <http://doi.org/10.1001/jama.291.8.965>.
- [74] Silberstein SD, Neto W, Schmitt J, Jacobs D, MIGR-001 Study Group. Topiramate in migraine prevention: results of a large controlled trial. *Arch Neurol* 2004;61:490–5. <http://doi.org/10.1001/archneur.61.4.490>.
- [75] Silberstein SD, Lipton RB, Dodick DW, Freitag FG, Ramadan N, Mathew N, et al. Efficacy and safety of topiramate for the treatment of chronic migraine: a randomized, double-blind, placebo-controlled trial. *Headache* 2007;47:170–80. <http://doi.org/10.1111/j.1526-4610.2006.00684.x>.
- [76] Diener H-C, Bussone G, Van Oene JC, Lahaye M, Schwalen S, Goadsby PJ, et al. Topiramate reduces headache days in chronic migraine: a randomized, double-blind, placebo-controlled study. *Cephalalgia* 2007;27:814–23. <http://doi.org/10.1111/j.1468-2982.2007.01326.x>.
- [77] Jackson JL, Cogbill E, Santana-Davila R, Eldredge C, Collier W, Gradall A, et al. A Comparative Effectiveness Meta-Analysis of Drugs for the Prophylaxis of Migraine Headache. *PLoS One* 2015;10:e0130733. <http://doi.org/10.1371/journal.pone.0130733>.
- [78] Luykx J, Mason M, Ferrari MD, Carpay J. Are migraineurs at increased risk of adverse drug responses? A meta-analytic comparison of topiramate-related adverse drug reactions in epilepsy and migraine. *Clin Pharmacol Ther* 2009;85:283–8. <http://doi.org/10.1038/clpt.2008.203>.
- [79] Romoli M, Costa C, Siliquini S, Corbelli I, Eusebi P, Bedetti C, et al. Antiepileptic drugs in migraine and epilepsy: who is at increased risk of adverse events? *Cephalalgia* 2018;38:274–82. <http://doi.org/10.1177/0333102416683925>.
- [80] Keni RR, Jose M, Sarma PS, Thomas SV, Kerala Registry of Epilepsy and Pregnancy Study Group. Teratogenicity of antiepileptic dual therapy: dose-dependent, drug-specific, or both? *Neurology* 2018;90:e790–6. <http://doi.org/10.1212/WNL.0000000000005031>.
- [81] Yen P-H, Kuan Y-C, Tam K-W, Chung C-C, Hong C-T, Huang Y-H. Efficacy of levetiracetam for migraine prophylaxis: a systematic review and meta-analysis. *J Formos Med Assoc* 2020. <http://doi.org/10.1016/j.jfma.2020.08.020>.

- [82] Kashipazha D, Ghadikolaei HS, Siavashi M. Levetiracetam in Compare to Sodium Valproate for Prophylaxis in Chronic Migraine Headache: A Randomized Double-Blind Clinical Trial. *Curr Clin Pharmacol* 2017;12:55–9. <http://doi.org/10.2174/1574884712666170329094419>.
- [83] Buch D, Chabriat H. Lamotrigine in the Prevention of Migraine With Aura: A Narrative Review. *Headache* 2019;59:1187–97. <http://doi.org/10.1111/head.13615>.
- [84] Biton V, Shneker BF, Naritoku D, Hammer AE, Vuong A, Caldwell PT, et al. Long-term tolerability and safety of lamotrigine extended-release: pooled analysis of three clinical trials. *Clin Drug Investig* 2013;33:359–64. <http://doi.org/10.1007/s40261-013-0070-4>.
- [85] Silberstein S, Saper J, Berenson F, Somogyi M, McCague K, D'Souza J. Oxcarbazepine in migraine headache: a double-blind, randomized, placebo-controlled study. *Neurology* 2008;70:548–55. <http://doi.org/10.1212/01.wnl.0000297551.27191.70>.
- [86] Storer RJ, Goadsby PJ. Topiramate inhibits trigeminovascular neurons in the cat. *Cephalalgia* 2004;24:1049–56. <http://doi.org/10.1111/j.1468-2982.2004.00767.x>.
- [87] Akerman S, Goadsby PJ. Topiramate inhibits trigeminovascular activation: an intravital microscopy study. *Br J Pharmacol* 2005;146:7–14. <http://doi.org/10.1038/sj.bjp.0706290>.
- [88] Andreou AP, Goadsby PJ. Topiramate in the treatment of migraine: a kainate (glutamate) receptor antagonist within the trigeminothalamic pathway. *Cephalalgia* 2011;31:1343–58. <http://doi.org/10.1177/0333102411418259>.
- [89] Akerman S, Romero-Reyes M. Targeting the central projection of the dural trigeminovascular system for migraine prophylaxis. *J Cereb Blood Flow Metab* 2019;39:704–17. <http://doi.org/10.1177/0271678X17729280>.
- [90] Durham PL, Niemann C, Cady R. Repression of stimulated calcitonin gene-related peptide secretion by topiramate. *Headache* 2006;46:1291–5. <http://doi.org/10.1111/j.1526-4610.2006.00538.x>.
- [91] Hebestreit JM, May A. Topiramate modulates trigeminal pain processing in thalamo-cortical networks in humans after single dose administration. *PLoS One* 2017;12:e0184406. <http://doi.org/10.1371/journal.pone.0184406>.
- [92] Hebestreit JM, May A. The enigma of site of action of migraine preventives: no effect of metoprolol on trigeminal pain processing in patients and healthy controls. *J Headache Pain* 2017;18:116. <http://doi.org/10.1186/s10194-017-0827-x>.
- [93] Ayata C, Jin H, Kudo C, Dalkara T, Moskowitz MA. Suppression of cortical spreading depression in migraine prophylaxis. *Ann Neurol* 2006;59:652–61. <http://doi.org/10.1002/ana.20778>.
- [94] Hoffmann U, Dilekőz E, Kudo C, Ayata C. Oxcarbazepine does not suppress cortical spreading depression. *Cephalalgia* 2011;31:537–42. <http://doi.org/10.1177/0333102410388433>.
- [95] Mulleners WM, Chronicle EP, Vredeveld JW, Koehler PJ. Visual cortex excitability in migraine before and after valproate prophylaxis: a pilot study using TMS. *Eur J Neurol* 2002;9:35–40. <http://doi.org/10.1046/j.1468-1331.2002.00334.x>.
- [96] Artemenko AR, Kurenkov AL, Filatova EG, Nikitin SS, Kaube H, Katsarava Z. Effects of topiramate on migraine frequency and cortical excitability in patients with frequent migraine. *Cephalalgia* 2008;28:203–8. <http://doi.org/10.1111/j.1468-2982.2007.01491.x>.
- [97] Aurora SK, Barrodale PM, Vermaas AR, Rudra CB. Topiramate modulates excitability of the occipital cortex when measured by transcranial magnetic stimulation. *Cephalalgia* 2010;30:648–54. <http://doi.org/10.1111/j.1468-2982.2009.01998.x>.