



HAL
open science

Functional connectivity and epileptogenicity of nodular heterotopias: A single-pulse stimulation study

Sébastien Boulogne, Francesca Pizzo, Benoit Chatard, Nicolas Roehri, Hélène Catenoux, Karine Ostrowsky-coste, Bernard Giusiano, Marc Guenot, Romain Carron, Fabrice Bartolomei, et al.

► To cite this version:

Sébastien Boulogne, Francesca Pizzo, Benoit Chatard, Nicolas Roehri, Hélène Catenoux, et al.. Functional connectivity and epileptogenicity of nodular heterotopias: A single-pulse stimulation study. *Epilepsia*, 2022, 63 (4), pp.961 - 973. 10.1111/epi.17168 . hal-04832307

HAL Id: hal-04832307

<https://hal.science/hal-04832307v1>

Submitted on 11 Dec 2024

HAL is a multi-disciplinary open access archive for the deposit and dissemination of scientific research documents, whether they are published or not. The documents may come from teaching and research institutions in France or abroad, or from public or private research centers.

L'archive ouverte pluridisciplinaire **HAL**, est destinée au dépôt et à la diffusion de documents scientifiques de niveau recherche, publiés ou non, émanant des établissements d'enseignement et de recherche français ou étrangers, des laboratoires publics ou privés.

FULL-LENGTH ORIGINAL RESEARCH

Functional connectivity and epileptogenicity of nodular heterotopias: A single-pulse stimulation study

Sébastien Boulogne^{1,2,3}  | Francesca Pizzo^{4,5}  | Benoit Chatard² | Nicolas Roehri⁴ |
Hélène Catenoix^{1,2} | Karine Ostrowsky-Coste^{2,6} | Bernard Giusiano^{4,5} |
Marc Guenet^{2,7} | Romain Carron⁸ | Fabrice Bartolomei^{4,5}  | Sylvain Rheims^{1,2,3} 

¹Department of Functional Neurology and Epileptology, Hospices Civils de Lyon and University of Lyon, Lyon, France

²Lyon's Neurosciences Research Center, INSERM U1028, CNRS 5292, Lyon, France

³Lyon 1 University, Villeurbanne, France

⁴Inserm, INS, Institut de Neurosciences des Systèmes, Aix Marseille University, Marseille, France

⁵Epileptology and Cerebral Rythmology Department, Assistance Publique – Hôpitaux de Marseille, Marseille, France

⁶Epileptology, Sleep Disorders and Functional Pediatric Neurology, Hospices Civils de Lyon and University of Lyon, Lyon, France

⁷Department of Functional Neurosurgery, Hospices Civils de Lyon and University of Lyon, Lyon, France

⁸Department of Functional Neurosurgery, Assistance Publique – Hôpitaux de Marseille, Marseille, France

Correspondence

Sébastien Boulogne, Department of Functional Neurology and Epileptology, Hospices Civils de Lyon, Lyon, France.
Email: sebastien.boulogne@chu-lyon.fr

Abstract

Objective: Nodular heterotopias (NHs) are malformations of cortical development associated with drug-resistant focal epilepsy with frequent poor surgical outcome. The epileptogenic network is complex and can involve the nodule, the overlying cortex, or both. Single-pulse electrical stimulation (SPES) during stereo-electroencephalography (SEEG) allows the investigation of functional connectivity between the stimulated and responsive cortices by eliciting cortico-cortical evoked potentials (CCEPs). We used SPES to analyze the NH connectome and its relation to the epileptogenic network organization.

Methods: We retrospectively studied 12 patients with NH who underwent 1 Hz or 0.2 Hz SPES of NH during SEEG. Outbound connectivity (regions where CCEPs were elicited by NH stimulation) and inbound connectivity (regions where stimulation elicited CCEPs in the NH) were searched. SEEG channels were then classified as “heterotopic” (located within the NH), “connected” (located in normotopic cortex and showing connectivity with the NH), and “unconnected.” We used the epileptogenicity index (EI) to quantify implication of channels in the seizure-onset zone and to classify seizures as heterotopic, normotopic, and normo-heterotopic.

Results: One hundred thirty-five outbound and 72 inbound connections were found. Three patients showed connectivity between hippocampus and NH, and seven patients showed strong internodular connectivity. A total of 39 seizures were analyzed: 23 normo-heterotopic, 12 normotopic, and 4 heterotopic. Logistic regression found that “connected” channels were significantly ($p = 8.4e-05$) more likely to be epileptogenic than “unconnected” channels (odds ratio 4.71, 95% confidence interval (CI) [2.17, 10.21]) and heterotopic channels were also significantly ($p = .024$) more epileptogenic than “unconnected” channels (odds ratio 3.29, 95% CI [1.17, 9.23]).

Significance: SPES reveals widespread connectivity between NH and normotopic regions. Those connected regions show higher epileptogenicity. SPES might be useful to assess NH epileptogenic network.

KEYWORDS

cortico-cortical evoked potentials, epilepsy, epileptogenicity, functional connectivity, nodular heterotopia

1 | INTRODUCTION

Nodular heterotopias (NHs) are malformations of cortical development resulting from abnormal radial neuronal migration, which can be located in the subcortical white matter or more frequently along the ventricular walls, either unilaterally or bilaterally.^{1,2} Patients with NHs typically have drug-resistant focal epilepsy and frequently need epilepsy surgery evaluation. However, seizure outcomes after resective surgery or less-invasive multitarget ablation, like stereo-electroencephalography (SEEG)-guided thermocoagulations or laser ablation, are conflicting.³⁻⁶ Recent data indicate that epileptogenic networks associated with NH are heterogenous and unique to each patient.³ Determining if the epileptogenic zone is restricted to the NH, involves both the NH and the “overlying cortex” or is localized outside the NH, is challenging, and usually requires invasive EEG recordings with depth electrodes.

Other epileptogenic lesions and cortical malformations, including focal cortical dysplasia or hippocampal sclerosis, can be associated with NH and sometimes take part in the epileptogenic network.^{7,8} Furthermore, alteration of cortical development also involves normotopic (i.e., normally located) and apparently normal cortical regions,^{9,10} resulting in complex and variable organization of the epileptogenic zones across patients. Intracranial EEG data are nonetheless in agreement on a higher involvement of the normotopic cortex compared to NH.^{3,11} In a recent study of 19 patients with NH recorded with SEEG, seizure onsets were mostly normotopic (48.5%) or normoheterotopic (45.5%), whereas only 6% were purely heterotopic.³ However, all of the normotopic regions were not equally involved, and differentiating epileptogenic from non-epileptogenic normotopic cortices is challenging. The commonly used anatomical classification between “local” (same lobes as the NH) and “distant” normotopic cortices is questionable, especially for patients with posterior periventricular multiple NH, which face the temporo-parieto-occipital junction, and for whom most cortical regions could be considered “local” while separated by several centimeters. Furthermore, some patients in this study³ showed higher epileptogenicity in distant, rather than in local normotopic cortices.

Relationships between NH and normotopic cortices are complex.⁶ Histology¹² and diffusion tractography magnetic resonance imaging (MRI) studies reveal^{13,14} structural connectivity tracts emerging from

Key Points

- Single-pulse electrical stimulation is a useful tool to assess the epileptogenic network in nodular heterotopias.
- Cortico-cortical evoked potentials showed that nodular heterotopias have widespread connectivity with the overlying cortex but also with distant cortical regions and other nodules.
- Cortical regions functionally connected to the nodules have higher epileptogenicity than unconnected ones.
- Whether or not these data may help to guide radiofrequency thermocoagulations or laser therapy in patients with nodular heterotopias will require specific studies.

NH and connecting with adjacent but also distant regions, ipsilaterally and contralaterally. Some of those connections might be functional: SEEG recordings^{3,4,15} and functional MRI (fMRI) studies^{13,16,17} have shown synchronous activities between NH and the overlying cortex during epileptic discharges or cognitive tasks. Quantitative MRI also showed cortical thickening preferentially in cortices overlying the HN, which co-localized with areas of abnormal function identified with resting-state fMRI.¹⁸ A few case reports used cortico-cortical evoked potentials (CCEPs) to study NH functional connectivity^{19,20} or to help localize small NH scattered in the white matter.²¹ Some noninvasive reports, using fMRI and magnetic transcranial stimulation with simultaneous scalp EEG, suggested that the existence of functional connectivity between NH and normotopic structures could predict the epileptogenicity of the network,^{17,22} but this hypothesis has not been formally evaluated using invasive EEG recordings.

To address this issue, we analyzed the SEEG data of patients with NH in whom single-pulse electrical stimulation (SPES) had been performed within the NH. Our objectives were: (1) to describe NH functional connectivity using CCEPs, and (2) to evaluate if the normotopic structures functionally connected with the NH would be more epileptogenic than unconnected structures. Consequently, we wanted to evaluate if CCEPs could be used as an epileptogenicity biomarker for normotopic cortex in patients with NH.

2 | METHODS

2.1 | Patient selection

We retrospectively reviewed the database of patients with drug-resistant focal epilepsy who underwent invasive recordings with SEEG for presurgical evaluation between January 2001 and October 2017 in two French tertiary epilepsy centers (Lyon and Marseille) to select those who fulfilled the following criteria: (1) had drug-resistant focal epilepsy and MRI evidence of NHs, (2) underwent SEEG, and (3) in whom 1 Hz and/or 0.2 Hz SPES of NH, performed for clinical purpose, were available.

Overall, 12 patients were eligible, including 11 who had previously been reported in Pizzo et al.³ (Table 1). For the other eight patients included in Pizzo et al.,³ only high-frequency (50 Hz) stimulations were performed and were therefore not eligible for the current study. All 12 patients had a comprehensive phase I surgical evaluation including surface EEG, neuropsychological testing, routine MRI, and [18F]-fluorodeoxyglucose positron emission tomography. The patients underwent SEEG exploration during long-term video-EEG monitoring, as part of normal clinical care. We collected and analyzed clinical and raw data of SEEG recordings. All patients were fully informed of the purpose and risks of the SEEG procedure and gave their written consent. The local ethics committee approved this study.

2.2 | SEEG recordings

SEEG was routinely performed according to Talairach's stereotactic method²³ or using a frameless stereotactic surgical robot. The brain regions to be investigated by depth electrodes were determined for each patient, based on individual presurgical data and most likely origin of seizure onset, independently from this study.

Electrodes were 0.8 mm in diameter and included 5–18 recording contacts, 2 mm in length, 1.5 mm apart (Dixi Medical in Lyon, ALCIS in Marseille). They were implanted stereotactically after a peroperative angiography.

We recorded EEG signals using a video-EEG monitoring system—Micromed (Lyon) or a Coherence-Natus (Marseille)—at a sampling rate of 256, 512, or 1024 Hz. The referential electrode was a contact located within the white matter or the skull, as far as possible from the suspected epileptogenic zones. Two hardware filters were present in the acquisition procedure: (1) a high-pass filter with cutoff frequency equal to 0.53 Hz (Lyon) and 0.16 Hz (Marseille), used to remove very slow variations that could contaminate the baseline and (2) an anti-aliasing low-pass

filter with a cutoff frequency at 97, 170, or 340 Hz accordingly to the sampling rates 250, 512, or 1024 Hz. For each patient, we used a bipolar montage between adjacent contacts of each electrode. Channels showing artifacts or localized in the white matter were excluded from the analysis.

2.3 | SEEG contact classification

The exact locations of each electrode and each recording contact were verified on a post-implantation MRI (Lyon and Marseille) or computerized tomography (CT) scan (Marseille) but with CT scan/MRI data fusion using the in-house software GARDEL (a Graphical user interface for Automatic Registration and Depth Electrodes Localization) following previously described procedures,^{24,25} available at: <https://meg.univ-amu.fr/wiki/GARDEL:presentation>. All patients had at least one pair of contacts within an NH. According to their location on MRI, the SEEG contacts were classified as “heterotopic” if located within or near the visible borders of the HN and “normotopic” if located in nonlesional cortex.

2.4 | Ictal recordings: Visual analysis, computation of the epileptogenicity index, and seizure classification

As described in the previous study,³ seizure data were collected and visually analyzed, with special attention to the seizure-onset patterns and to the structures involved at seizure onset. We computed the epileptogenicity index (EI) for all selected seizures by using our in-house plugin, implemented in the AnyWave software,^{26,27} available respectively at: <https://meg.univ-amu.fr/wiki/AnyWave:Plug-ins> and <https://meg.univ-amu.fr/wiki/AnyWave>. The EI is a method computed on SEEG signals that aims to quantify the epileptogenicity of brain structures.^{3,28} In summary, the EI is intended to quantify two important features of the transition from preictal to ictal activity on the SEEG signals: (1) the signal energy redistribution from lower frequency bands (theta, alpha) toward higher frequency bands (beta, gamma, high gamma, and ripple), and (2) the delay in appearance of these high-frequency components in a given structure with respect to the first structure involved in a “rapid discharge” mode of seizure onset. The EI is a normalized quantity ranging from 0 (no epileptogenicity) to 1 (maximal epileptogenicity). This quantity may be estimated using a two-stage procedure: (1) within a sliding window (5 s duration), the signal energy ratio (ER) is computed, between high (beta [12–24 Hz], gamma [24–127 Hz]) and low (theta [4–7.4 Hz]

TABLE 1 Clinical, MRI, and SEEG characteristics

Patient	Patient number in Pizzo et al. ³	Sex	Age (y)	Epilepsy onset (y)	Family history	MRI	Surgical treatment	Outcome (Engel class)
A	1	f	30	21	N	Bilateral PNH, posterior, >L	/	
B	2	f	15	10	N	Unilateral PNH, TO, L	Thermocoagulation NC + NH	I
C	6	m	44	20	N	Unilateral NH, F, R	/	
D	7	m	24	18	N	Bilateral bifocal, posterior R & F L	Temporo-occipital disconnection	I
E	11	f	42	33	N	Unilateral bifocal PNH, TPO, R	Thermocoagulation NC + NH	I
F	13	f	28	16	N	Bilateral PNH, TPO	Thermocoagulation NC + NH	III
G	14	f	29	20	N	Unilateral PNH, TO, L	Thermocoagulation NC + NH	IV
H	15	m	31	11	N	Bilateral PNH, TPO	Thermocoagulation NC + NH	IV
I	16	f	16	12	N	Bilateral PNH, TPO	Thermocoagulation NC and temporo-occipital cortectomy	IV
J	17	f	27	24	N	Bilateral PNH, TPO, >R	Thermocoagulation NC + NH	IV
IK rK	18	f	52	21	N	Bilateral PNH, TPO	Thermocoagulation NC + NH (only within left hemisphere)	IV
L		f	17	15	N	Unilateral PNH, PO, L	Thermocoagulation NH	I

Abbreviations: f, female; F, frontal; L, left; m, male; NC, normotopic cortex; NH, nodular heterotopia; O, occipital; P, parietal; PNH, periventricular NH; R, right; T, temporal.

and alpha [7.4–12 Hz]) frequency bands of the EEG obtained from the signal spectral density $C(w)$ (squared modulus of Fourier transform); (2) change-points in the $ER[n]$ quantity, which is sensitive to frequency changes in the signal, are detected. An optimal algorithm (“cumulative sum algorithm” or “CUSUM”) is used to automatically determine the time instant when ER increases, that is, when theta–alpha activity (predominant in background SEEG signals) changes into higher frequency activity (predominant during the rapid discharge). The seizure onset was set visually by the reviewer and then the plugin was launched on a time window around the onset. The involvement of each structure in the development of the seizure is thus detected, channel by channel, by using the CUSUM algorithm.

Some patients showed independent bilateral epileptogenic zones and seizure dynamics (patients A, F, G, H, and K). Because the objective of the study was to evaluate if the connectivity revealed by SPES could predict the epileptogenic network, we only considered the seizures originating from the hemisphere in which SPES were available. For one of the patients with bilateral epileptogenic zones (patient K), SPES was available for both hemispheres; thus, we separated the SEEG data between right (rK) and left (IK) hemispheres for EI and statistical analysis for this patient.

Seizures were classified as heterotopic, normotopic, or normo-heterotopic according to the EI value. An EI value of 0.3 was set as a threshold to define a channel as epileptogenic.³ When the EI was ≥ 0.3 in the heterotopic cortex only, the seizure was considered “heterotopic”; when the EI was ≥ 0.3 in normotopic cortex only, the seizure was considered “normotopic”; when the EI was ≥ 0.3 in both heterotopic and normotopic cortex, the seizure was defined “normo-heterotopic.”

2.5 | Electrical stimulation

Clinical SEEG investigation typically includes cortical direct electrical stimulations with 50 Hz and/or ≤ 1 Hz stimulations with the main objectives of: (1) assessing the epileptogenicity of the implanted brain regions by triggering ictal signs, epileptic discharges, or full-blown seizures, helping to better localize the epileptogenic zone; and (2) performing a functional mapping in order to delineate the relation between the epileptogenic zone and the eloquent cortices.²⁹

Low-frequency stimulation (≤ 1 Hz), called single-pulse electrical stimulation (or SPES),^{30–32} also allows the study of CCEPs. CCEPs correspond to highly consistent loco-regional or distant cortical early responses, appearing

before 100 ms with a fixed latency. CCEPs are considered physiological and measure the effective connectivity between the stimulated cortical region and other connected regions with a high temporal and spatial resolution.

Electrical stimulations were produced by a current-regulated neurostimulator. Square pulses of current were applied between two adjacent contacts (bipolar stimulation) with mono- or biphasic pulses. The used parameters are known to deliver current within 5 mm around the stimulated dipole and ensure a charge density below the maximal safety limit of $60 \mu\text{C}/\text{cm}^2/\text{phase}$, in order to avoid tissue damage.

SPES performed within the heterotopic nodule was an inclusion criterion for this study but SPES was also performed in normotopic regions in 6 of the 12 included patients.

Because of the retrospective design of the study, stimulation parameters for each stimulated site were heterogeneous between cortical regions and between individuals in terms of intensity, frequency, and duration. Five to 20 pulses were delivered for each stimulated dipole. All patients had 1 Hz SPES and three patients had additional 0.2 Hz SPES in order to look for delayed responses^{33,34} (data not shown). Both frequencies allow the analysis of the CCEPs time range [0–100 ms]. Intensities varied between 1 and 3 mA and pulse width between 1 and 2 ms.

2.6 | Cortico-cortical evoked potentials and functional connectivity assessment

Connectivity was determined using our in-house CCEP software. For each bipolar stimulation, we performed an automatic detection of the pulse artifact generated on the stimulated channel.

Cortico-cortical evoked potentials consist of an early bi- or polyphasic component (emerging 10–50 ms after the stimulation) generally followed by a slow wave (50–500 ms after the stimulation). The stimulation artifact was removed using a local interpolation of 5 ms around the artifact. The analysis focused on the first 100 ms to only describe the early responses. CCEPs were searched on all the recorded cortical regions using a bipolar montage of adjacent contacts. Noisy trials containing artifacts or epileptiform discharges were excluded. The trials of each stimulation block were then averaged. We used a Wilcoxon signed-rank test to compare EEG signal during the 1 s after stimulation to the 1 s before stimulation. CCEPs were considered significant based on the Wilcoxon test ($p \leq .05$) confirmed by visual analysis to ascertain that the waveforms corresponded to an expected CCEP morphology with an amplitude above twice the standard deviation of background activity. We measured the latency of the first wave and the peak-to-peak amplitude of the CCEP.

When a significant CCEP was observed, the stimulated and the responsive channels were considered connected. To assess the number of connections, we gathered adjacent channels within the same cortical region: one connection can represent the functional connectivity between one or more stimulated adjacent channel(s) and one or more responsive adjacent channel(s).

To evaluate the NH connectome (Figure 1), we determined its *outbound connectivity* (normotopic regions where CCEPs were elicited by heterotopic cortex stimulation) and its *inbound connectivity* (normotopic regions where stimulation elicited CCEPs in heterotopic cortex). Outbound connectivity was available for all patients, whereas inbound connectivity analysis was possible for only the 6 patients who had SPES performed in normotopic cortices. Then according to CCEP analysis, “normotopic” channels were subclassified as “*normotopic connected*” if they showed outbound and/or inbound connectivity with the heterotopic nodule or “*normotopic unconnected*” if no connectivity was found.

2.7 | Statistical analysis

We used R to perform a mixed-effect logistic regression of epileptogenicity (EI) versus connectivity (normotopic unconnected/normotopic connected/heterotopic). The variable to be explained is constituted by the EI values of each channel of each seizure of each patient. EI was dichotomized according to its “non-epileptogenic” value when $\text{EI} < 0.3$ and “epileptogenic” when $\text{EI} \geq 0.3$. As fixed effects, we entered the variable “connected” into the model; as random effects, patients and channels could have different intercepts.

2.8 | Data availability statement

The data that support the findings of this study are available from the corresponding author upon reasonable request.

3 | RESULTS

3.1 | Patients characteristics

Nine patients had periventricular NH: four were bilateral symmetrical, three were bilateral asymmetrical, and two were unilateral. The three other patients had subcortical NH: two bilateral and one unilateral. A total of 727 channels were recorded: 121 were “heterotopic” and 606 were “normotopic” (Table 1).

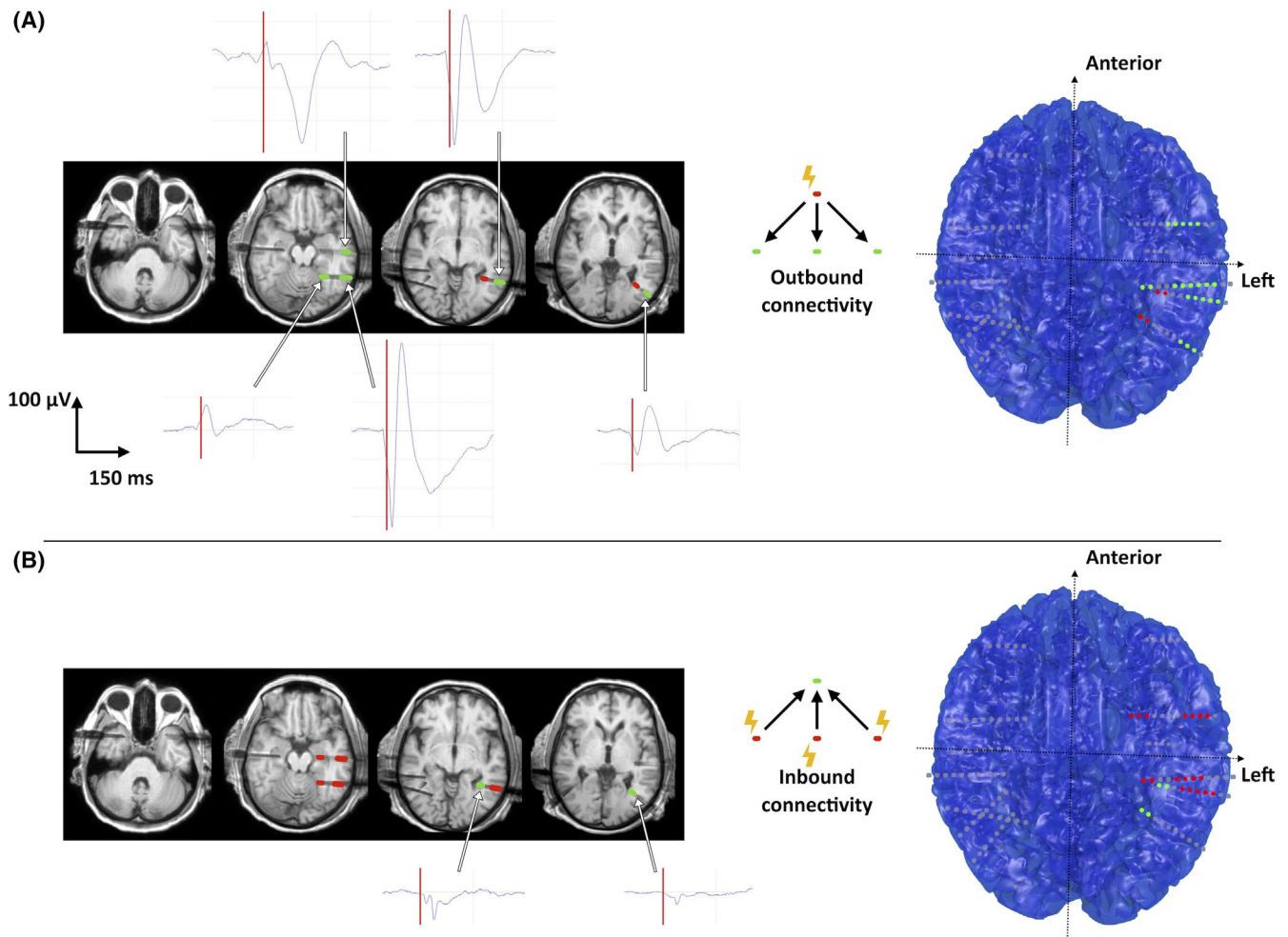


FIGURE 1 (A) Outbound and (B) inbound heterotopic nodule connectivity in patient IK. On the left, transversal T1-weighted magnetic resonance imaging (MRI) scans and on the right, a three-dimensional (3D) view of all the implanted electrodes and their contacts showing the location of the stimulated (red dots) and of the responding regions (green dots) with the corresponding cortico-cortical evoked potential (CCEP) waveform. The vertical red bar represents the stimulation time. The artefact has been removed by a $[-5\text{ s}, +5\text{ s}]$ interpolation. Two electrodes targeted the left posterior periventricular heterotopic nodules. Five outbound connections (A) were found homolaterally with lingual and lateral temporal cortices. Five inbound connections (B) were found homolaterally with the hippocampus, and lingual and lateral temporal cortices. The insula and the temporal pole did not show significant connectivity with the nodular heterotopias (NHs)

3.2 | Connectivity analysis

Outbound connectivity was studied for all patients. Two patients (C and D) showed no connection; their data were then withheld from further analysis. Among the remaining 10 patients, we found 135 outbound connections (4–36 per patient) revealing 92 connected normotopic regions (3–19 per patient). The latencies of outbound CCEPs were $[\text{mean} \pm \text{SD}] 36 \pm 15$ ms and amplitudes were 130 ± 96 mA. Three patients (E, F, rK) each showed one outbound connection with contralateral normotopic cortex, linking a posterior periventricular NH to contralateral temporal or parietal lateral cortices (Table 2).

Inbound connectivity was available for only the six patients who had SPES performed within normotopic

cortices. We found 72 inbound connections (7–30 per patient) revealing 38 connected regions; 33 of those (86%) were also outbound connected regions. The latencies of inbound CCEPs were $[\text{mean} \pm \text{SD}] 26 \pm 11$ ms and amplitudes were 75 ± 45 mA. CCEPs recorded within NH had the same morphology as normotopic CCEPs but with a significantly smaller amplitude ($p = 1.8e-05$).

All patients but one (patient G) had multiple electrodes implanted within NH. Seven (64%) of those patients showed internodular connectivity, with a total of 36 connections (1–16 per patients); 12 connections were reciprocal and 12 were unidirectional. The latencies of internodular CCEPs were $[\text{mean} \pm \text{SD}] 24 \pm 11$ ms and amplitudes were 101 ± 27 mA.

One reciprocal connection (patient J) and three inbound connections (patients rK, lK and L) were found

TABLE 2 Connectivity and seizure analysis

Patient	SPES frequency	Studied connectivity O: outbound I: Inbound	SEEG contacts (channels) in:						Inbound connected regions (number of connections)	Internodular connections	Heterotopic seizures	Normotopic seizures	Normo-heterotopic seizures
			Heterotopic cortex		Normotopic cortex		Normotopic unconnected cortex						
			Heterotopic cortex	Normotopic cortex	Heterotopic cortex	Normotopic cortex	Normotopic unconnected cortex	Normotopic unconnected cortex					
A	1 Hz	O	12 (9)	16 (11)	47 (36)	6 (9)	/	0				2	
B	1 Hz	O	11 (9)	19 (14)	40 (30)	5 (7)	/	1				5	
C	1 Hz	O	22 (17)	0	45 (28)	0	/	0	1			3	
D	1 Hz	O	18 (13)	0	71 (43)	0	/	0				4	
E	1 Hz	I/O	29 (24)	45 (35)	25 (19)	19 (28)	3 (7)	5	2				
F	1 Hz	O	10 (5)	12 (7)	59 (32)	4 (4)	/	0		1			
G	1 Hz	O	4 (3)	13 (9)	36 (25)	3 (4)	/	/	6				
H	1 & 0.2 Hz	I/O	19 (11)	26 (20)	28 (21)	7 (14)	5 (7)	1				2	
I	1 Hz	I/O	6 (3)	47 (36)	39 (29)	10 (13)	6 (6)	1		2		2	
J	1 & 0.2 Hz	I/O	15 (10)	50 (40)	12 (6)	12 (36)	12 (30)	6				3	
IK	1 & 0.2 Hz	I/O	6 (4)	30 (25)	14 (9)	5 (5)	4 (4)	1				2	
rK			11 (7)	24 (16)	4 (2)	7 (14)	4 (4)	5	2				
L	1 Hz	I/O	11 (6)	67 (54)	70 (59)	14 (47)	4 (14)	16					

between a posterior periventricular NH and the ipsilateral hippocampus, which was recorded in all patients.

We did not find connections between NH located in different hemispheres. However, patient E, who had two unilateral temporo-occipital NH separated by several centimeters, showed a unidirectional connection linking the anterior to the posterior nodule.

Among the 535 normotopic channels of the 10 patients in whom CCEPs were observed, 267 were considered connected with NH and 268 unconnected. An example of an NH functional connectome revealed by SPES is shown in Figure 1.

3.3 | Seizure-onset zone

Thirty-nine seizures were analyzed ([mean ± SD] 3 ± 1.47 per patient) using visual and computational analysis (Table 2). Interictal activity and seizure-onset patterns were similar to those described in Pizzo et al.³ Four seizures were heterotopic, 12 were normotopic, and 23 were normo-heterotopic. Ten patients had exclusively one type of seizures in their studied hemisphere: two had heterotopic seizures, two had normotopic seizures, five had normo-heterotopic seizures, and patient K had exclusively normotopic seizures in her left epileptogenic network and exclusively normo-heterotopic seizures in the contralateral network. The remaining two patients had both normotopic and heterotopic seizures.

3.4 | Relation between functional connectivity and epileptogenicity

Thirty-one seizures in the 10 patients for whom CCEPs were found, contributed to the analysis. EI was compared between the three categories of channels: “heterotopic,” “normotopic connected,” and “normotopic unconnected” (Figures 2 and 3). Mixed-effect logistic regression found that “connected” channels were significantly ($p = 8.4e-05$) more likely to be epileptogenic than “unconnected” ones with an odds ratio of 4.71, 95% confidence interval (CI) [2.17, 10.21] (Figure 4). Heterotopic channels were also significantly ($p = .024$) more epileptogenic than “unconnected” ones with an odds ratio of 3.29, 95% CI [1.17, 9.23].

3.5 | Epilepsy surgery

Nine patients had thermocoagulations at the end of the SEEG recording with a good persistent outcome (Engel I) in three patients: patient B with normo-heterotopic seizures had thermocoagulations within NH, connected,

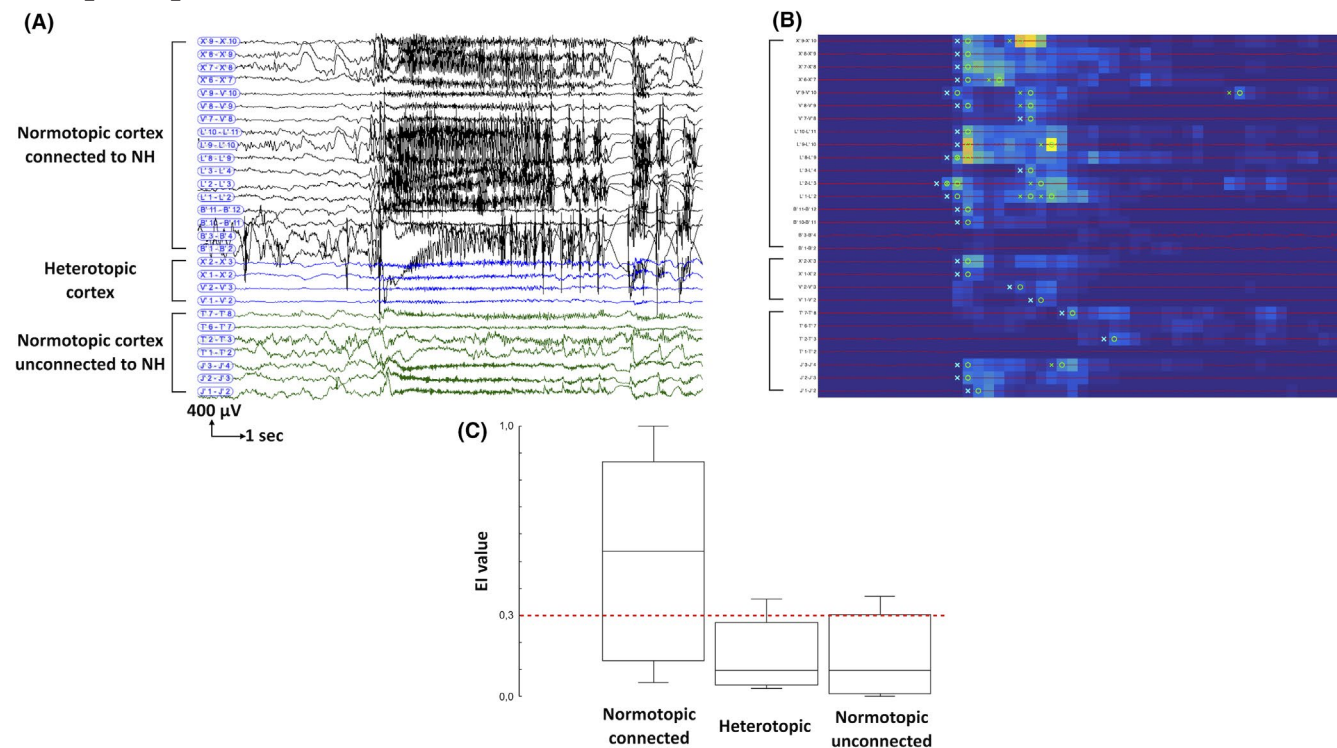


FIGURE 2 Normotopic seizure in patient IK. (A) Stereo-electroencephalography (SEEG) recording from heterotopic cortex, normotopic cortex connected to the nodular heterotopias (NHs), and normotopic cortex unconnected to the NH. (B) The epileptogenicity index (EI) map showed the increase in energy ratio (in blue to yellow scale) and the time of detection (circle, alarm time; cross, detection time 30) in each SEEG channel selected. The highest epileptogenicity is detected in the connected normotopic cortex. (C) Box plot of EI values obtained in each group of contacts in this seizure. The red dotted line marks the 0.3 value considered as a threshold to define a region as epileptogenic. Normotopic connected cortex showed a high degree of epileptogenicity

and unconnected normotopic cortex; patient E with heterotopic seizures had thermocoagulations within NH and connected normotopic cortex; patient L with heterotopic seizures had thermocoagulations exclusively within NH.

Two patients had surgery: patient D, in whom no CCEPs were found, had a temporo-occipital disconnection with a good outcome (Engel I), and patient I had thermocoagulations, later followed by a temporo-occipital cortectomy, that both had no effect (Engel IV).

4 | DISCUSSION

This is the first patient series ($n = 12$) in whom SPES were used to study NH functional connectivity. Our work supports the hypothesis that epileptogenicity associated with NH relies on a diffuse network involving heterotopic and normotopic structures but this is the first SEEG study to demonstrate a direct link between functional connectivity between normotopic cortices with NH and epileptogenicity. We showed a high internodular connectivity and widespread outbound and inbound connections between NH and normotopic cortex, including the hippocampus and the contralateral hemisphere. Connectivity and

epileptogenicity patterns were heterogenous across patients; nonetheless, regions connected to the HN showed a significantly higher epileptogenicity than unconnected regions.

4.1 | NH connectivity

Cortico-cortical evoked potential analysis showed that NH are highly connected: only two patients did not have CCEPs and nearly half of the recorded normotopic channels were connected to the NH. It should be noted that most NH faced multiple lobes; most normotopic channels were located within those lobes and had to be considered as “local” while not being in the cortex immediately overlying the HN. We did not diffusion tensor imaging (DTI) available to reconstruct and actually measure the length of the anatomical fibers linking the stimulating and the recording contacts. However, based on visual analysis we could assume that many local connections were long-distance and three patients also showed connections with the contralateral hemisphere. Tractography studies also found that most NH had numerous structural connectivity tracts, mainly toward the overlying cortex but also toward

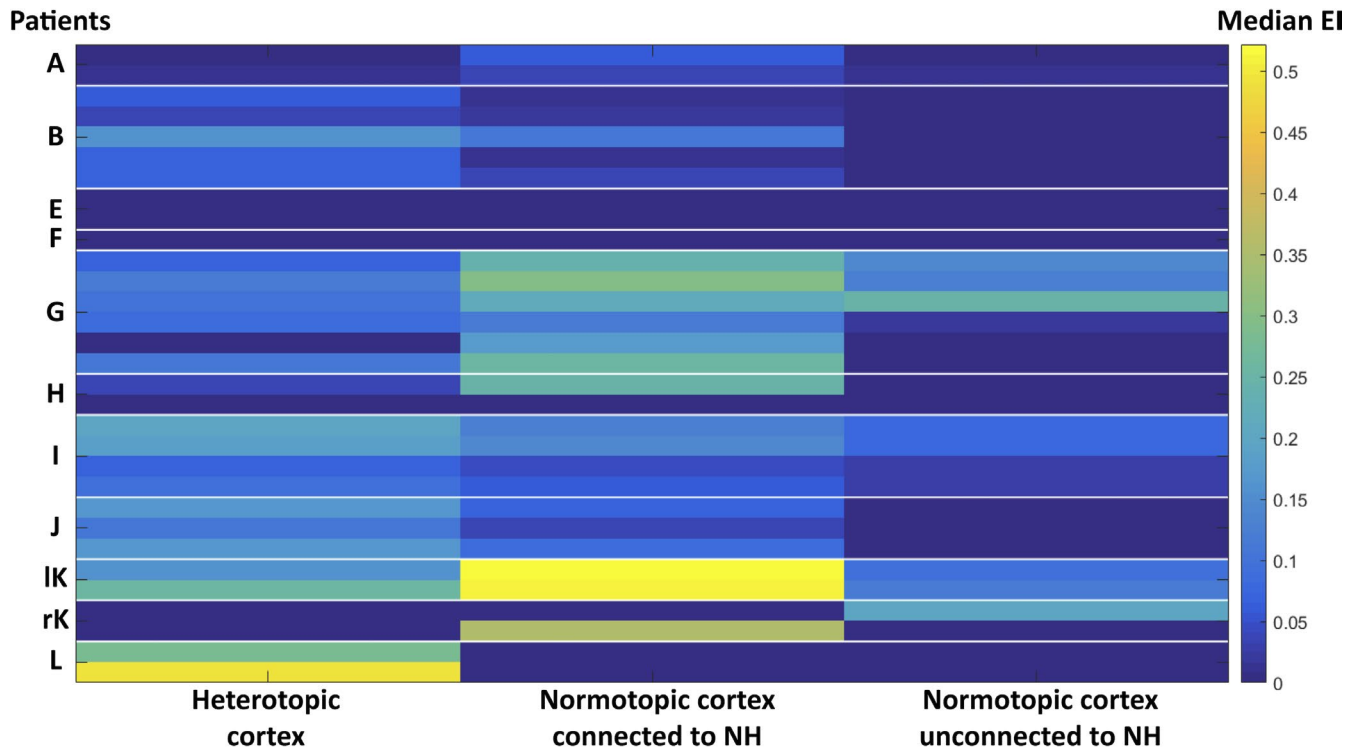
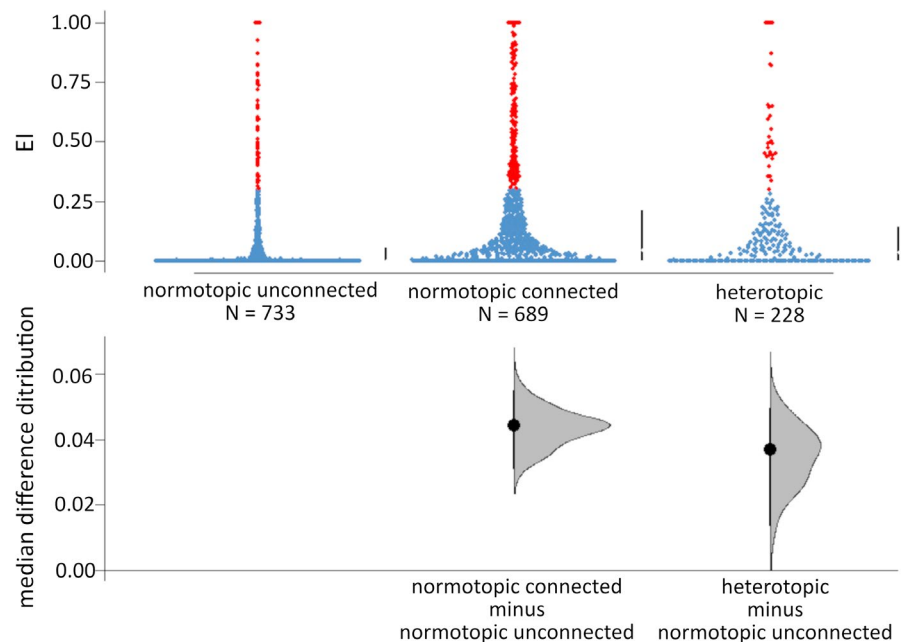


FIGURE 3 Epileptogenicity index trough seizures and patients. Median EI values (refer to color bar) for each groups of channels (“heterotopic cortex,” “normotopic cortex connected to the nodular heterotopias [NH],” and “normotopic cortex unconnected to the NH”) for each studied patient’s seizure (lines). There’s marked heterogeneity between seizures but note that the “normotopic unconnected” group is usually the less epileptogenic

FIGURE 4 Effect of connectivity on epileptogenicity index. Cumming estimation plot⁴⁸ showing connectivity effect on the median difference distributions of the EI (5000 bootstrap resamples) among the studied seizures. The channels considered epileptogenic ($EI \geq 0.3$) are represented in red. The median and 25th and 75th percentiles are displayed as gapped lines to the right of each group. The difference axis illustrates the median difference between groups: the median is indicated by the black circle, the 95% confidence interval by the vertical line, and the difference distribution by the filled curve



other homolateral and contralateral cortical regions, and to a lesser extent subcortical and cerebellar structures.¹³ Resting-state and task-related fMRI^{13,17,35} as well as intracranial EEG^{3,15,36} proved that many of those tracts were functional, demonstrating simultaneous activation within heterotopic and normotopic overlying regions. Genetic

and molecular understanding of NH physiopathology suggest that heterotopic neurons are functional but failed to migrate to the developing cortex.² Using this cortical development approach, Deleo et al.¹⁸ proposed an original definition of the overlying cortex using the Laplace equation to generate hypothetical curvilinear paths between

the outer ventricular zone and the cortical surface. One might hypothesize that the predominant NH connectivity with the immediately overlying cortex reflects the functional connectivity between heterotopic neurons and the gray matter location they were intended to join, and that long-distance NH connectivity is analogous to association fibers emerging from normotopic cortices.

Three patients had CCEPs between posterior NH and the hippocampus, which had also been observed in one patient by Valton et al.¹⁹ Experimental electrophysiologic studies also demonstrated functional coupling between heterotopic neurons and the hippocampus, using brain slices from an NH-induced rat model³⁷ and from a resected temporal lobe in a patient with drug-refractory epilepsy.³⁸ Furthermore, hippocampal abnormalities are frequently associated with cortical malformation, up to 70% of patients with NH in some studies,^{18,39} which raises the question of a dual pathology. A quantitative and functional MRI study found an increased complexity of the parahippocampal cortex correlated with hippocampal malrotation indices while those regions did not overlap with the HN overlying cortex.¹⁸ However, even when temporal lobe structures are involved in the seizures, temporal lobe resection is usually unsuccessful.⁴⁰ These data suggest that the NH connectivity network exceeds the immediately overlying cortex and might notably involve the hippocampus.

Two thirds of our patients showed internodular connectivity. Using fMRI, Khoo et al.⁸ found that 11 of 16 patients showed internodular connectivity and that 83% of the studied NH were connected with at least one other nodule, even when located in a different hemisphere; during intracranial EEG, the authors also showed that ictal activity spreads faster between fMRI-connected nodules.⁴¹ Furthermore, a good seizure outcome is more likely in patients when the ablation targets a unique nodule⁴² or all or several NH⁴ when seizure onsets involve the heterotopic cortices. We can highlight that patient L, who showed the most internodular connections (seven reciprocal and two unidirectional connections), had exclusive heterotopic seizures and became seizure-free after extensive NH radiofrequency thermocoagulation.

4.2 | NH epileptogenicity

To our knowledge, this is the first study to demonstrate that functional connectivity, assessed by CCEPs, between apparently normal cortical regions and NH is associated with significantly higher epileptogenicity. A few noninvasive reports also showed correlations between connectivity and epileptogenicity in patients with NH. An EEG-fMRI study in one patient with bilateral NH showed connectivity between NH and the overlying cortex within the epileptogenic

hemisphere but not in the contralateral non-epileptogenic side.¹⁷ Similarly, Shafi et al.²² found hyperexcitable cortical responses to transcranial magnetic stimulation within normotopic regions connected to the NH, which were not present in unconnected regions. However, interpretation of data at an individual patient level in our series remains difficult: patients without CCEPs (C and D) demonstrated normotopic and normo-heterotopic seizures, whereas some patients with heterotopic seizures (E and L) showed widespread CCEPs. It also remains unclear if CCEPs are different between epileptogenic and physiological networks, since the topology revealed by SPES within the epileptogenic zone seemed similar to that found in homologous nonepileptogenic regions.^{43,44} However, other studies indicated that the epileptogenic zone showed more numerous⁴⁵ and larger^{46,47} CCEPs than nonepileptogenic regions. This issue has been poorly addressed in epilepsies associated with cortical malformations for which the existence of aberrant connections is well documented.

4.3 | Treatment outcome

In the largest published HN study ($n = 20$) by Mirandola et al.,⁴ good outcome (Engel I) was achieved for 13 of 17 patients who benefited from thermocoagulation, including 4 patients with bilateral HN, and for 6 of 7 patients after surgery. In our study, good outcome (Engel I) was achieved in only 40% of the patients: three of nine after thermocoagulation only and one of two after surgery. Among those four patients, three had unilateral HN and one (patient E) had bilateral HN but a unilateral epileptogenic zone. Among the six patients with bad outcome (Engel III-IV), five had bilateral HN including four with bilateral independent epileptogenic zones. Patients with bilateral HN represent 58% of our study population but only 25% in Mirandola et al. with no mention of bilateral epileptogenic zones. The outcome discrepancies between the two studies might be explained by a difference in widespread epileptogenic zones. As reported in the present study, most patients included in the Mirandola's cohort underwent SEEG-guided thermocoagulations directed to both to heterotopias and to selected cortical regions. However, the total number of thermolesions at the individual patient level could not be compared and we could not exclude that differences in the management of the cortical thermocoagulations may have contributed to the outcome discrepancies between the two studies.

4.4 | Limitations of the study

Our study is retrospective, and the main limitation is the heterogeneity of SPES protocols and of the population.

Given that SPES was performed during routine clinical assessment, stimulation protocols were heterogeneous across patients and all recorded cortical sites were not systematically explored. This especially concerned the first patients (A–G), for whom systematic extensive SPES was not yet part of our daily practice and with fewer delivered stimulations: we may have underestimated their NH connectome. For the latest patients (H–L) however, we performed SPES in all of the recorded cortices. This could explain why we did not find outbound connections in patients C and D who had, respectively, only two and one heterotopic dipoles, each stimulated once with SPES, whereas some of the latest patients had up to seven stimulated heterotopic dipoles.

Low-frequency SPES at 0.2 Hz can also induce delayed responses, which appear at least 100 ms after the stimulation. Those responses are rare, inconsistent, and with variable latency and a spike or sharp-wave morphology. They are suggestive of an underlying epileptogenic cortex.^{29,33,34} Because 0.2 Hz SPES was available in only three patients, we did not include delayed response analysis in the study.

NH is a rare cause of epilepsy, making it difficult to study a homogenous population; we included patients with unilateral and bilateral, subcortical and periventricular, unique, and multiple NH. Such variety of MRI anomalies could explain the heterogeneity of CCEPs and seizure-onset patterns.

Finally, NHs are deep and small malformations, sometimes not exceeding a few millimeters. It is therefore challenging to perfectly implant the electrodes within the NH and it was not unusual not to be able to have more than one contact within the NH borders when they were very small. Bipolar electrical stimulation might have frequently involved the white matter surrounding the NH, which may question that the elicited CCEPs would not only reflect HN-outbound connectivity. However, this white matter is likely to be made of fiber tracts connected to the NH, and inbound connectivity analysis showed that 86% of the connections were reciprocal, which was reassuring concerning the risk of false-positive outbound connections.

5 | CONCLUSION

Our study demonstrated that normotopic cortex functionally connected to the NH has higher epileptogenicity than unconnected regions. Our study adds up to previous data showing that NH epileptogenic networks are large, heterogeneous across patients, and involve both heterotopic and neocortical regions. During invasive intracranial recordings, CCEP study could be an additional tool

to explore the epileptogenic network in patients with NH, particularly with a view to better targeted lesion therapy. However, whether these data may help to guide radiofrequency thermocoagulations or laser therapy in these patients will require specific studies.

ACKNOWLEDGMENTS

We thank Jeremy JAZAKALA, engineer in Lyon's Neurosciences Research Center, INSERM U1028, CNRS 5292, for implementing the CCEP software. We thank Russel VICTORIO for English editing.

CONFLICT OF INTEREST

None of the authors has any conflict of interest to disclose related to this work. We confirm that we have read the Journal's position on issues involved in ethical publication and affirm that this report is consistent with those guidelines.

AUTHORS CONTRIBUTIONS

SB, FP, FB, and SR contributed to the conception and design of the study; SB, FP, NR, HC, KOC, MG, RC, FB, and SR contributed to the acquisition and analysis of data; BG performed statistical analyses; SB, FP, BC, NR, BG, and SR contributed to the first draft and prepared the figures. All authors contributed to the final version of the manuscript.

ORCID

Sébastien Boulogne  <https://orcid.org/0000-0001-8681-7369>

Francesca Pizzo  <https://orcid.org/0000-0001-6345-1288>

Fabrice Bartolomei  <https://orcid.org/0000-0002-1678-0297>

Sylvain Rheims  <https://orcid.org/0000-0002-4663-8515>

REFERENCES

1. Battaglia G, Chiapparini L, Franceschetti S, Freri E, Tassi L, Bassanini S, et al. Periventricular nodular heterotopia: classification, epileptic history, and genesis of epileptic discharges. *Epilepsia*. 2006;47(1):86–97.
2. Battaglia G, Bassanini S, Granata T, Setola V, Giavazzi A, Pagliardini S. The genesis of epileptogenic cerebral heterotopia: clues from experimental models. *Epileptic Disord*. 2003;5(2):51–8.
3. Pizzo F, Roehri N, Catenox H, Medina S, McGonigal A, Giusiano B, et al. Epileptogenic networks in nodular heterotopia: a stereoelectroencephalography study. *Epilepsia*. 2017;58(12):2112–23. <https://doi.org/10.1111/epi.13919>
4. Mirandola L, Mai RF, Francione S, Pelliccia V, Gozzo F, Sartori I, et al. Stereo-EEG: diagnostic and therapeutic tool for periventricular nodular heterotopia epilepsies. *Epilepsia*. 2017;58(11):1962–71.
5. Thompson SA, Kalamangalam GP, Tandon N. Intracranial evaluation and laser ablation for epilepsy with periventricular nodular heterotopia. *Seizure*. 2016;41:211–6.
6. Khoo HM, Gotman J, Hall JA, Dubeau F. Treatment of epilepsy associated with periventricular nodular heterotopia. *Curr Neurol Neurosci Rep*. 2020;20(12):59.

7. Gonzalez G, Vedolin L, Barry B, Poduri A, Walsh C, Barkovich AJ. Location of periventricular nodular heterotopia is related to the malformation phenotype on MRI. *Am J Neuroradiol*. 2013;34(4):877–83.
8. Mandelstam SA, Leventer RJ, Sandow A, McGillivray G, van Kogelenberg M, Guerrini R, et al. Bilateral posterior periventricular nodular heterotopia: a recognizable cortical malformation with a spectrum of associated brain abnormalities. *Am J Neuroradiol*. 2013;34(2):432–8.
9. Represa A. Why malformations of cortical development cause epilepsy. *Front Neurosci*. 2019;13:250. <https://www.frontiersin.org/article/https://doi.org/10.3389/fnins.2019.00250/full>
10. Hong S-J, Bernhardt BC, Gill RS, Bernasconi N, Bernasconi A. The spectrum of structural and functional network alterations in malformations of cortical development. *Brain*. 2017;140(8):2133–43.
11. Tassi L. Electroclinical, MRI and neuropathological study of 10 patients with nodular heterotopia, with surgical outcomes. *Brain*. 2004;128(2):321–37. <http://dx.doi.org/10.1093/brain/awh357>
12. Hannan AJ, Servotte S, Katsnelson A, Sisodiya S, Blakemore C, Squier M, et al. Characterization of nodular neuronal heterotopia in children. *Brain*. 1999;122(Pt 2):219–38.
13. Christodoulou JA, Walker LM, Del Tufo SN, Katzir T, Gabrieli JDE, Whitfield-Gabrieli S, et al. Abnormal structural and functional brain connectivity in gray matter heterotopia: connectivity and epilepsy in heterotopia. *Epilepsia*. 2012;53(6):1024–32.
14. Farquharson S, Tournier J-D, Calamante F, Mandelstam S, Burgess R, Schneider ME, et al. Periventricular nodular heterotopia: detection of abnormal microanatomic fiber structures with whole-brain diffusion MR imaging tractography. *Radiology*. 2016;281(3):896–906.
15. Wagner J, Elger CE, Urbach H, Bien CG. Electric stimulation of periventricular heterotopia: Participation in higher cerebral functions. *Epilepsy Behav*. 2009;14(2):425–8.
16. Tyvaert L, Hawco C, Kobayashi E, LeVan P, Dubeau F, Gotman J. Different structures involved during ictal and interictal epileptic activity in malformations of cortical development: an EEG-fMRI study. *Brain*. 2008;131(8):2042–60.
17. Archer JS, Abbott DF, Masterton RAJ, Palmer SM, Jackson GD. Functional MRI interactions between dysplastic nodules and overlying cortex in periventricular nodular heterotopia. *Epilepsy Behav*. 2010;19(4):631–4.
18. Deleo F, Hong S-J, Fadaie F, Caldaïrou B, Krystal S, Bernasconi N, et al. Whole-brain multimodal MRI phenotyping of periventricular nodular heterotopia. *Neurology*. 2020;95(17):e2418–26.
19. Valton L, Guye M, McGonigal A, Marquis P, Wendling F, Régis J, et al. Functional interactions in brain networks underlying epileptic seizures in bilateral diffuse periventricular heterotopia. *Clin Neurophysiol*. 2008;119(1):212–23.
20. Cvetkovska E, Martins WA, Gonzalez-Martinez J, Taylor K, Li J, Grinenko O, et al. Heterotopia or overlaying cortex: what about in-between? *Epilepsy Behav Case Rep*. 2019;11:4–9.
21. Valentín A, Morris R, Honavar M, Bodi I, Teijeira-Azcona A, Lázaro M, et al. Single pulse electrical stimulation identifies epileptogenicity in a case with subcortical nodular heterotopia and MRI negative epilepsy. *Brain Stimul*. 2015;8(3):672–4.
22. Shafi MM, Vernet M, Klooster D, Chu CJ, Boric K, Barnard ME, et al. Physiological consequences of abnormal connectivity in a developmental epilepsy: cortical connectivity. *Ann Neurol*. 2015;77(3):487–503.
23. Guenet M, Isnard J, Ryvlin P, Fischer C, Ostrowsky K, Mauguïere F, et al. Neurophysiological monitoring for epilepsy surgery: the Talairach SEEG method. *StereoElectroEncephaloGraphy*. Indications, results, complications and therapeutic applications in a series of 100 consecutive cases. *Stereotact Funct Neurosurg*. 2001;77(1–4):29–32.
24. Bartolomei F, Barbeau E, Gavaret M, Guye M, McGonigal A, Régis J, et al. Cortical stimulation study of the role of rhinal cortex in déjà vu and reminiscence of memories. *Neurology*. 2004;63(5):858–64.
25. Medina Villalon S, Paz R, Roehri N, Lagarde S, Pizzo F, Colombet B, et al. EpiTools, A software suite for presurgical brain mapping in epilepsy: intracerebral EEG. *J Neurosci Methods*. 2018;303:7–15.
26. Colombet B, Woodman M, Badier JM, Bénar CG. AnyWave: a cross-platform and modular software for visualizing and processing electrophysiological signals. *J Neurosci Methods*. 2015;242:118–26.
27. Roehri N, Pizzo F, Lagarde S, Lambert I, Nica A, McGonigal A, et al. High-frequency oscillations are not better biomarkers of epileptogenic tissues than spikes: HFOs are not better than spikes. *Ann Neurol*. 2018;83(1):84–97.
28. Bartolomei F, Chauvel P, Wendling F. Epileptogenicity of brain structures in human temporal lobe epilepsy: a quantified study from intracerebral EEG. *Brain*. 2008;131(Pt 7):1818–30.
29. Boulogne S, Ryvlin P, Rheims S. Single and paired-pulse electrical stimulation during invasive EEG recordings. *Rev Neurol*. 2016;172(3):174–81.
30. Almashaihi T, Rheims S, Ostrowsky-Coste K, Montavont A, Jung J, De Bellescize J, et al. Intra-insular functional connectivity in human. *Hum Brain Mapp*. 2014;35(6):2779–88. <http://dx.doi.org/10.1002/hbm.22366>
31. Catenoux H, Magnin M, Guénot M, Isnard J, Mauguïere F, Ryvlin P. Hippocampal-orbitofrontal connectivity in human: an electrical stimulation study. *Clin Neurophysiol*. 2005;116(8):1779–84.
32. Trebaul L, Deman P, Tuyisenge V, Jedynek M, Hugues E, Rudrauf D, et al. Probabilistic functional tractography of the human cortex revisited. *NeuroImage*. 2018;181:414.
33. Valentín A, Anderson M, Alarcón G, Seoane JJG, Selway R, Binnie CD, et al. Responses to single pulse electrical stimulation identify epileptogenesis in the human brain in vivo. *Brain*. 2002;125(Pt 8):1709–18.
34. van't Klooster MA, Zijlmans M, Leijten FSS, Ferrier CH, van Putten MJAM, Huiskamp GJM. Time-frequency analysis of single pulse electrical stimulation to assist delineation of epileptogenic cortex. *Brain*. 2011;134(10):2855–66.
35. Pinard J, Feydy A, Carlier R, Perez N, Pierot L, Burnod Y. Functional MRI in double cortex: functionality of heterotopia. *Neurology*. 2000;54(7):1531–3.
36. Dubeau F, Tampieri D, Lee N, Andermann E, Carpenter S, Leblanc R, et al. Periventricular and subcortical nodular heterotopia A study of 33 patients. *Brain*. 1995;118(5):1273–87.
37. Chevassus-Au-Louis N, Congar P, Represa A, Ben-Ari Y, Gaiarsa J-L. Neuronal migration disorders: heterotopic neocortical neurons in CA1 provide a bridge between the hippocampus and the neocortex. *Proc Natl Acad Sci USA*. 1998;95(17):10263–8.

38. Kitaura H, Oishi M, Takei N, Fu Y-J, Hiraishi T, Fukuda M, et al. Periventricular nodular heterotopia functionally couples with the overlying hippocampus: optical Imaging of PVNH. *Epilepsia*. 2012;53(7):e127–31.
39. Kuchukhidze G, Koppelstaetter F, Unterberger I, Dobesberger J, Walser G, Zamarian L, et al. Hippocampal abnormalities in malformations of cortical development: MRI study. *Neurology*. 2010;74(20):1575–82.
40. Li LM, Dubeau F, Andermann F, Fish DR, Watson C, Cascino GD, et al. Periventricular nodular heterotopia and intractable temporal lobe epilepsy: poor outcome after temporal lobe resection. *Ann Neurol*. 1997;41(5):662–8.
41. Khoo HM, Ellenrieder N, Zazubovits N, Hall JA, Dubeau F, Gotman J. Internodular functional connectivity in heterotopia-related epilepsy. *Ann Clin Transl Neurol*. 2019;6(6):1010–23. <https://doi.org/10.1002/acn3.769>
42. Cossu M, Fuschillo D, Cardinale F, Castana L, Francione S, Nobili L, et al. Stereo-EEG-guided radio-frequency thermocoagulations of epileptogenic grey-matter nodular heterotopy. *J Neurol Neurosurg Psychiatry*. 2014;85(6):611–7.
43. Lacruz ME, García Seoane JJ, Valentin A, Selway R, Alarcón G. Frontal and temporal functional connections of the living human brain: connections of the human brain. *Eur J Neurosci*. 2007;26(5):1357–70.
44. Keller CJ, Honey CJ, Mégevand P, Entz L, Ulbert I, Mehta AD. Mapping human brain networks with cortico-cortical evoked potentials. *Philos Trans R Soc Lond, B, Biol Sci*. 2014;369(1653):20130528.
45. Yan Q, Gaspard N, Zaveri HP, Blumenfeld H, Hirsch LJ, Spencer DD, et al. The connectivity index: an effective metric for grading epileptogenicity. *J Neurosurg*. 2020;133(4):971–8. <http://dx.doi.org/10.3171/2019.4.jns195>
46. Enatsu R, Piao Z, O'Connor T, Horning K, Mosher J, Burgess R, et al. Cortical excitability varies upon ictal onset patterns in neocortical epilepsy: a cortico-cortical evoked potential study. *Clin Neurophysiol*. 2012;123(2):252–60.
47. Iwasaki M, Enatsu R, Matsumoto R, Novak E, Thankappen B, Piao Z, et al. Accentuated cortico-cortical evoked potentials in neocortical epilepsy in areas of ictal onset. *Epileptic Disord*. 2010;12(4):292–302.
48. Ho J, Tumkaya T, Aryal S, Choi H, Claridge-Chang A. Moving beyond P values: Everyday data analysis with estimation plots. 15.

How to cite this article: Boulogne S, Pizzo F, Chatard B, Roehri N, Catenoix H, Ostrowsky-Coste K, et al. Functional connectivity and epileptogenicity of nodular heterotopias: A single-pulse stimulation study. *Epilepsia*. 2022;00:1–13. <https://doi.org/10.1111/epi.17168>