



HAL
open science

Biochemical exploration of cholestasis: interpretation, traps and interferences

Nicolas Stojkoski, Maylis Bertrand, Khaled Messaoudi, Claude Bendavid, Redwan Al-Shami, Caroline Moreau

► **To cite this version:**

Nicolas Stojkoski, Maylis Bertrand, Khaled Messaoudi, Claude Bendavid, Redwan Al-Shami, et al.. Biochemical exploration of cholestasis: interpretation, traps and interferences. *Clinical Biochemistry*, 2025, 135, pp.110852. <10.1016/j.clinbiochem.2024.110852>. <hal-04827323>

HAL Id: hal-04827323

<https://hal.science/hal-04827323v1>

Submitted on 9 Dec 2024

HAL is a multi-disciplinary open access archive for the deposit and dissemination of scientific research documents, whether they are published or not. The documents may come from teaching and research institutions in France or abroad, or from public or private research centers.

L'archive ouverte pluridisciplinaire **HAL**, est destinée au dépôt et à la diffusion de documents scientifiques de niveau recherche, publiés ou non, émanant des établissements d'enseignement et de recherche français ou étrangers, des laboratoires publics ou privés.



Distributed under a Creative Commons CC BY 4.0 - Attribution - International License



Biochemical exploration of cholestasis: interpretation, traps and interferences

Nicolas Stojkoski^{a,1}, Maylis Bertrand^{a,1}, Khaled Messaoudi^a, Claude Bendavid^{a,b}, Redwan Al-Shami^c, Caroline Moreau^{a,d,*}

^a Biochemistry Laboratory, CHU Pontchaillou, Rennes, France

^b UnivRennes, NUMECAN, CHU Pontchaillou, Rennes, France

^c Hepatology, CHU Pontchaillou, Rennes, France

^d Univ Rennes, CHU Rennes, INSERM, EHESP, IRSET (Institut de Recherche en Santé, Environnement et Travail) UMR_S 1085, F-35000 Rennes, France

ARTICLE INFO

Keywords:

Cholestasis
Serum protein electrophoresis
Lipoproteins
LpX
Interferences

ABSTRACT

We described the case of a 33-year-old patient who presented to the emergency department with non-febrile jaundice associated with epigastric pain. He suffered from acute non-severe alcoholic hepatitis and cholestasis. Biochemical investigations highlighted a huge elevation of the alpha-1-globulins fraction with an unexpected peak in the alpha-1-globulins area in serum protein electrophoresis, a severe hypercholesterolemia without xanthelasmas nor cholesterolomas. Investigations revealed an abnormal lipoprotein, Lipoprotein X (LpX) that can be responsible for the hypercholesterolemia, but also interferes with biochemical tests like direct low-density lipoprotein cholesterol, albumin, and serum electrolytes assays. LpX is an abnormal lipoprotein, which can be present in patients with liver dysfunction, notably in cholestasis-related conditions where the metabolism of plasma lipoproteins is altered. Cholestasis prevents the normal formation of bile acids, leading to the formation of LpX, which is rich in phospholipids and unesterified cholesterol, but poor in esterified cholesterol, triglycerides and proteins. The accumulation of LpX can lead to severe hypercholesterolemia, but this remains uncommon and data regarding the pathophysiology and incidence of this disease is scarce. The laboratory investigation of patients with suspected LpX can be challenging, due to the lack of available methods for measurement of LpX. In conclusion, LpX-induced hyperlipidemia must be identified to prevent interference in results for a number of biochemical tests, and additionally to improve patient care.

1. Case description

A 33-year-old male of Polish origin, with a body mass index of 27.27 kg/m², presented to the emergency department with non-febrile jaundice, moderate-intensity epigastric pain, dark urine, and pruritus. The pain had begun seven days earlier and has recently intensified without vomiting nor fever. His medical history and his family history were without particularities nor treatment. The patient had not taken any medicines, herbal remedies, mushrooms, or toxic substances. However, he had increased his alcohol consumption over the last three months. On clinical examination, the clinician reported a patient who was afebrile, hemodynamically stable and neurologically normal. The patient had mucocutaneous jaundice, with a mild pruritus, but no cutaneous signs of hypercholesterolemia or hypertriglyceridemia. There were no

cutaneous signs of hepatocellular failure or ascites. There were no reports of oedema of the lower limbs. Cardiopulmonary auscultation was normal. Magnetic resonance cholangio-pancreatography and abdominal pelvic computed tomography revealed significant hepatic steatosis with hepatomegaly. The bile ducts were unobstructed; there was no lithiasis in the gallbladder, nor acute pancreatitis but there was intravesicular sludge.

Biological examination revealed cholestasis, icterus and hepatic cytolysis (Table 1). Wilson disease, autoimmune hepatitis, and viral hepatitis were excluded (Table 1). A serum protein capillary electrophoresis highlighted a particular profile [Fig. 1A] with an unexpected peak in the alpha-1-globulins fraction and a discrepancy with albumin measured by turbidimetry. Thus, acute non-severe alcoholic hepatitis was first suspected.

* Corresponding author at: CHU Pontchaillou, Laboratoire de Biochimie, 2 rue Henri le Guilloux, 35 000 Rennes cedex 9, France.

E-mail address: caroline.moreau@chu-rennes.fr (C. Moreau).

¹ Nicolas STOJKOSKI and Maylis BERTRAND equally contributed to this work.

Table 1
Laboratory results during and after diagnosis.

	Laboratory results at diagnosis	Laboratory results 44 days after diagnosis	Reference values
Sodium (Na ⁺) (mmol/L) (<i>indirect potentiometry</i>)	133		136–145
Potassium (K ⁺) (mmol/L)	3.9		3.4–4.5
Chloride (Cl ⁻) (mmol/L)	98		98–107
Copper (μmol/L)	15.71		12–50–24.00
Relative exchangeable copper (%)	4.90		<8.00
Albumin g/L (<i>turbidimetry</i>)	37.1	44.9	35–52
Gamma glutamyltransferase (IU/L)	8199	137	11–55
Alkaline phosphatase (IU/L)	376	73	N < 135
Total bilirubin (μmol/L)	117.9	14	N < 24
Conjugated bilirubin (μmol/L)	100	7	N < 5
ASAT (IU/L)	307	35	N < 35
ALAT (IU/L)	493	46	N < 45
Lipase (IU/L)	27		13–60
Alpha-1-antitrypsin (g/L)	1.89		0.90–1.20
Orosomuroid (g/L)	1.13		0.50–1.20 g/
Ferritin (μg/L)	4 825	477	N < 345
Cholesterol total (mmol/L)	20.40	5.70	3.75–6.20
Triglycerides (mmol/L)	5.59	1.15	0.60–1.70
HDL-cholesterol (mmol/L)	0.46	1.65	1.04–2.07
LDL-cholesterol (<i>Friedewald formula</i>) (mmol/l)	Not calculated	3.53	<4.9
Non HDL-cholesterol (mmol/L)	19.9		
Apolipoprotein A1 (g/L)	0.67		1.04–2.02
Apolipoprotein B (g/L)	3.79		0.66–1.33
<u>Wilson disease investigations</u>			
urinary copper (μmol/L)	0.7		<0.38
exchangeable plasma copper (μmol/L)	15.71		12–50–24.00
relative plasma exchangeable copper (%)	4.90		<8.00
<u>Viral hepatitis explorations</u>			
<i>Hepatitis C serology</i>			
anti-HCV antibodies	0.052 negative		positivity threshold ≥ 1
<i>Hepatitis B serology</i>			
HBsAg	0.4 negative		positivity threshold ≥ 1
Total antibody to hepatitis B core antigen	2.1 negative		positivity threshold ≤ 1
Anti-HBs antibody (UI/L)	988 positive		positivity threshold v10
<i>Hepatitis A serology</i>			
Anti-HVA IgM	0.26 negative		positivity threshold ≥ 1
<i>VZV serology</i>			
Anti-VZV IgG (mUI/mL)	992 positive		positivity threshold > 150
<i>Hepatitis E serology</i>			
Anti-HVE IgM	<0.10 negative		positivity threshold > 1
<i>HSV serology</i>			
Anti HSV IgG	>30 negative		positivity threshold ≥ 1.1

Table 1 (continued)

	Laboratory results at diagnosis	Laboratory results 44 days after diagnosis	Reference values
<i>Epstein Barr Virus serology</i>			
Anti-VCA IgM	0.444 negative		positivity threshold ≥ 1
Anti-VCA IgG	862 positive		positivity threshold ≥ 1
Anti-EBNA IgG	187 positive		positivity threshold ≥ 1
<i>Cytomegalovirus serology</i>			
Anti-CMV IgM (U/mL)	0.1 negative		positivity threshold ≥ 1
Anti-CMV IgG (U/mL)	<0.2 negative		positivity threshold ≥ 1
<u>Auto-immune hepatitis investigations</u>			
anti-smooth muscle antibody	negative		
anti-mitochondrial antibody	negative		
anti-LKM1 antibody	negative		
anti-LC1 antibody	negative		
anti-SLA antibody	negative		
anti gastric parietal cell antibody	negative		

For publication, the physician obtained patient's informed consent.

2. Case discussion

2.1. Biological explorations

The electrophoretic profile at diagnosis highlighted the presence of a double peak in the alpha-1-globulins fraction, composed of two quantitatively equivalent, completely symmetrical peaks. The proteins usually present in the alpha-1-globulin fraction were normal (alpha-1-antitrypsin and orosomuroid, [Table 1](#)). Knowing that low density lipoprotein (LDL)-type lipoproteins can migrate in this area, a lipid profile was ordered, highlighting a hypercholesterolemia with hypertriglyceridemia ([Fig. 2A](#), [Table 1](#)). Then, in order to distinguish LDL-cholesterol (containing apolipoprotein B [ApoB]) from non LDL-cholesterol, we measured the ApoB and apolipoprotein A1 (ApoA1): ApoB was increased (increased LDL-cholesterol, consequently) while ApoA1 was decreased (decreased high density lipoprotein [HDL]-cholesterol, consequently) ([Table 1](#)). We completed the investigations with lipoprotein electrophoresis using agarose gel, highlighting the presence of chylomicrons (sampling in fasting state), increased LDL-cholesterol, decreased HDL-cholesterol, and the presence of lipoprotein with a cathodic migration. In this context of cholestasis combined with a disturbed lipid profile, this lipoprotein could be lipoprotein X (LpX) and could explain this second peak [[1–3](#)]. So, one of the two peaks could be linked to LDL-cholesterol, the other one to LpX, since these two lipoproteins can migrate between the albumin and alpha-1 globulins fractions on serum protein capillary electrophoresis [[2](#)]. As previously reported, LpX falsely elevated cholesterolemia, especially LDL-cholesterol [[4,5](#)] and discriminating dyslipidemia due to the presence of LpX versus LDL-cholesterol is essential.

In our study, the identification of LpX was made by a lipoproteinogram (or lipidogram), that consists of an electrophoretic separation of the main classes of serum lipoproteins. Separation was done in agarose gel using the Sebia Hydragel Lipo + Lp(a)® kit and based on the charge and the molecular weight of the lipoproteins, in an SDS-agarose gel including density and pH gradients. After separation, the lipoproteins are visualized by staining with Sudan Black.

Other direct available methods for the detection of LpX include ultracentrifugation, and nuclear magnetic resonance spectroscopy (NMR). The identification of LpX by ultracentrifugation is difficult since LpX's density and size are similar to LDL and VLDL (very low density lipoprotein). So, the separation must be done by sequential ultracentrifugation of the 1.020–1.063 g/mL lipoprotein fraction, and subsequently analyzed by Fast Protein Liquid Chromatography.

A variety of methods based on ³¹P, ¹³C, and ¹H NMR spectroscopy have been described for detecting LP-X. Recently, a new method to detect and quantify LP-X via a modified version of the NMR LipoProfile® test analysis used for routine clinical measurement of VLDL, LDL, and HDL particles and their different-size subclasses was published [6].

Because of a discrepancy between the albumin dosage measured by turbidimetry (37.1 g/L) and the evaluation by electrophoresis (30.7 g/L) [7,8], congenital bisalbuminemia was excluded. The normal level of lipase was not in favor of an acquired bisalbuminemia. Serum albumin was also measured with a colorimetric method assay (bromocresol green) at 38.1 g/L, and given that the colorimetric assay slightly overestimates the albumin value compared with the turbidimetric assay, the colorimetric assay seems to confirm the turbidimetric assay. This discordance could be related to LpX composition including albumin [3]. Consequently, the albumin in the LpX could be measured by turbidimetry, but may have undergone abnormal migration on electrophoresis. This could contribute to the appearance of an abnormal peak corresponding to LpX.

2.2. LpX pathophysiology

During cholestasis, the metabolism of plasma lipoproteins is altered, and an anomalous lipoprotein (LpX) can appear, leading to hypercholesterolemia. LpX is present in the plasma of patients affected by extra- and intra-hepatic cholestasis, but also potentially in lecithin-cholesterol-acyl-transferase (LCAT) deficiency and after lipid infusion [9]. In cholestasis, the accumulation of toxic bile acids in the liver leads to various negative feedback controls [3]. For example, bile acids can bind to farnesinoid X receptors (FXR) in the liver, which reduces the expression of the cholesterol 7α-hydroxylase gene [3]. Since the formation of bile acids is an important excretion pathway for free cholesterol, this cholesterol also accumulates in the liver. The association of unesterified cholesterol with phospholipids and albumin in the bile

ducts forms a “biliary lipoprotein”. Because of cholestasis, this lipoprotein passes into the bloodstream and incorporates more albumin and a small amount of triglycerides, ApoC and esterified cholesterol to form “mature” LpX [3,10]. Finally, “mature” LpX is composed of approximately 66 % phospholipids, 22 % free cholesterol, and 6 % proteins, including albumin, ApoC and ApoE [10,11]. This is a low-density lipoprotein subfraction with a structure close to a lamellar vesicle with a diameter of 30 to 70 nm [4] and a density close to VLDL-cholesterol and LDL-cholesterol. As LpX does not contain ApoB, LpX is consequently unable to bind to hepatic ApoB receptors. Consequently, LpX provides a long half-life in general circulation and does not participate in the negative feedback control of endogenous cholesterol synthesis. Finally, LpX is cleared by the reticuloendothelial system and eliminated by the kidneys [3].

2.3. Clinical implications of LpX

LpX is a large lipoprotein, whose accumulation for long term can lead to skin xanthomas, hypercholesterolemia, thrombotic events, and hyperviscosity syndrome. However, cardiovascular and atherogenesis events are rare in LpX-induced hyperlipidemia and some authors emphasize the protective role of LpX: some studies even suggest that it is anti-atherogenic, reducing LDL-cholesterol oxidation [1]. However, LpX could also form deposits in renal glomeruli, which could be nephrotoxic [9]. Resolution of hypercholesterolemia can require treatment of the cause of the cholestasis, such as LDL-apheresis or plasma exchange [12]. The use of statins can be dangerous, as in cholestasis they may accumulate to toxic concentrations because of their deficient bile elimination [1].

For the present patient, hypercholesterolemia was not associated with subclinical atherosclerosis. During follow-up, the patient showed no signs of atheroma, lameness on exertion, stroke or chest pain. The observed dyslipidemia was characterized by high VLDL- and LDL-cholesterol levels and reduced HDL-cholesterol in the presence of LpX. The increased ApoB level raised the question of the real cardiovascular risk for this patient, and a full lipid exploration was carried out well after this acute episode, revealing no significant lipid abnormalities (Table 1) and excluding atherosclerosis risk.

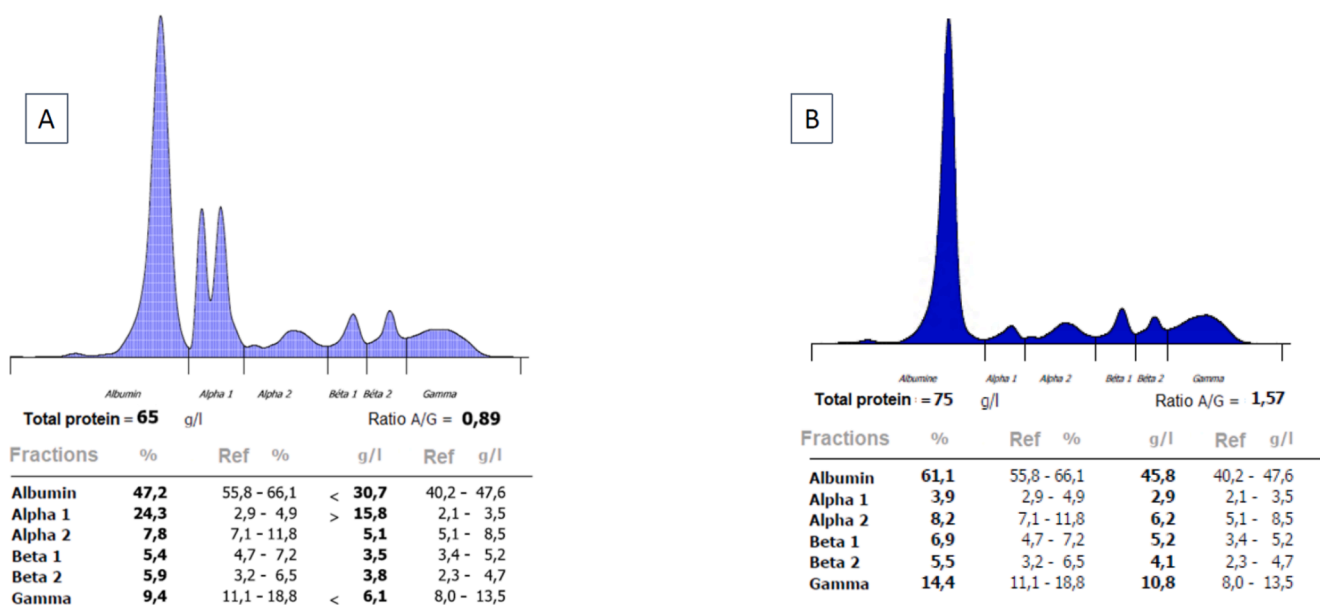


Fig. 1. Patient's serum proteins capillary electrophoresis (Capillary3 Tera®, Sebia). A. at diagnosis; The electrophoresis reveals hypogammaglobulinemia, hypoalbuminemia and double peak in the alpha-1-globulins area. B. 44-days after diagnosis. Normalized serum proteins capillary electrophoresis.

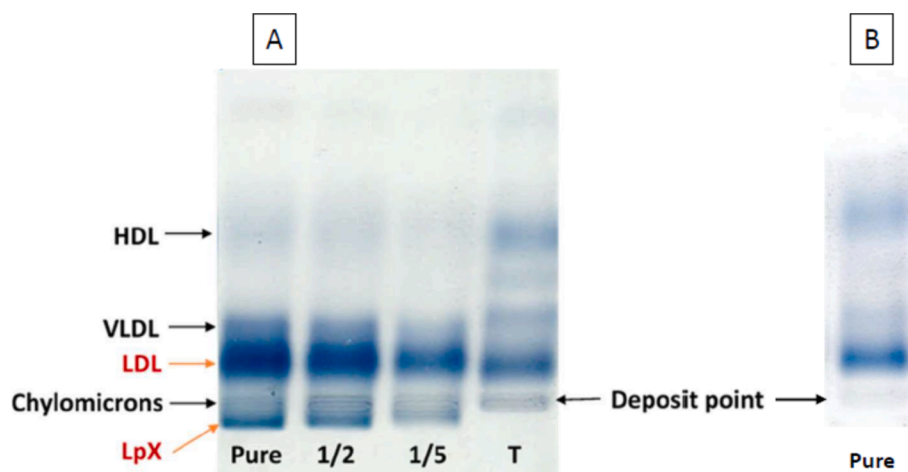


Fig. 2. A. at diagnosis: Lipoproteins electrophoresis with Sudan black staining. Pure = Non-diluted sample, dilution to the half (1/2), dilution to the fifth (1/5) and control (T). B. 44-days after diagnosis. Normalized serum lipoproteins electrophoresis.

2.4. Potential interferences due to LpX in biochemical tests

Laboratory investigation of LpX-induced hyperlipidemia is challenging because there is no available direct method for the measurement of LpX and because LpX causes numerous interferences in a number of biochemical tests.

As LpX is an additional lipoprotein in the blood, it is not included in the Friedewald formula, which can lead to a false increase in calculated LDL-cholesterol, because this equation assumes that all cholesterol is present in LDL-, HDL- or VLDL-cholesterol, but LpX is not taken into account [13]. The Sampson or Martin-Hopkins formulae do not include LpX into account either and could give a false LDL-cholesterol value [14,15]. The beta quantification method based on ultracentrifugation does not allow LDL-cholesterol to be differentiated from LpX because the two lipoproteins have the same density and would induce a false increase in LDL-cholesterol [2]. Moreover, this method is not routinely available. Alternatively, the Roche® LDL-cholesterol II generation test using a selective micellar solubilisation technique with a non-ionic detergent could solubilize only LDL-cholesterol and not LpX, thus eliminating the interference of LpX in the LDL-cholesterol assay [2].

High levels of LpX may also induce hyperviscosity syndrome and cause pseudohyponatremia, as well as pseudohypokalemia and pseudohypochloridemia if ionogram is measured by indirect potentiometry. Indirect potentiometry measures ionic activity in diluted plasma water and converts it into concentration in total plasma, according to a theoretical ratio of 93 % plasma water to 7 % lipid-protein phase. However, in the presence of elevated LpX, this lipid-protein phase is significantly underestimated [5,13,16]. In the present case, the patient presented hyponatremia. Unfortunately, direct potentiometric determination of electrolytes was not achieved because the presence of LpX was not detected at the time of testing.

2.5. Case follow-up

The patient was hospitalized for one week with simple monitoring of alcohol abstinence. Given the gradual improvement in the liver function tests and the absence of any signs of worsening, it was decided that the patient should be discharged with biological monitoring and addiction therapy to wean him from alcohol. No treatment for LpX was introduced, as none has been shown to be effective, apart from treating the underlying cause, *i.e.* cholestasis and alcoholism. At the follow-up appointment 44-days after hospitalization, the patient had correctly followed the alcohol withdrawal advice. He was no longer experiencing pain or jaundice. Biologically, transaminases, alkaline phosphatase, and conjugated bilirubin had returned to normal (Table 1). Only GGT

remained lightly elevated but had significantly decreased. The lipid profile was also in normal ranges. Serum electrophoresis had returned to normal, with no alpha-1-globulin peak and no albumin discrepancy [Fig. 1B]. Lipoprotein electrophoresis showed no visible LpX [Fig. 2B]. This confirmed the previous hypothesis of secondary dyslipidemia caused by LpX linked to liver dysfunction, especially cholestasis-related conditions. Hyperlipidemia resolved with adequate treatment of cholestatic disease.

3. Conclusion

During cholestasis, both the composition and metabolism of lipoproteins may be altered with, in rare cases, a hypercholesterolemia due to the presence of an anomalous lipoprotein called LpX. It is important to distinguish hypercholesterolemia due to LpX from those due to LDL-cholesterol, because the associated risks and treatments are different and because the presence of LpX may cause numerous interferences in biochemical tests. Nevertheless, the presence of hypercholesterolemia associated with cholestasis should suggest the presence of LpX, and LpX may coexist with a high LDL-cholesterol concentration in hypercholesterolemia with cholestasis. The simultaneous presence of LpX and increased LDL-cholesterol may explain the presence of a double peak in the alpha-1-globulin fraction as reported for the first time in our case, as well as a discordance in albumin on serum electrophoresis versus turbidimetric measurement. LpX may interfere with the calculation and direct measurement of LDL-cholesterol, but may also cause pseudohyponatremia and pseudohypokalemia. Ongoing dialogue between clinicians and biologists will enable us to understand discrepancies in biological results, or to identify interferences, in order to optimize patient care.

CRediT authorship contribution statement

Nicolas Stojkoski: Writing – review & editing, Writing – original draft, Validation, Investigation, Formal analysis, Conceptualization. **Maylis Bertrand:** Writing – review & editing, Writing – original draft, Validation, Investigation, Formal analysis, Conceptualization. **Khaled Messaoudi:** Writing – review & editing, Writing – original draft, Visualization, Validation, Methodology, Investigation, Formal analysis, Conceptualization. **Claude Bendavid:** Writing – review & editing, Writing – original draft, Visualization, Validation, Supervision, Methodology, Investigation, Formal analysis. **Redwan Al-Shami:** Writing – review & editing, Writing – original draft, Visualization, Validation, Resources, Methodology, Investigation, Conceptualization. **Caroline Moreau:** Writing – review & editing, Writing – original draft,

Visualization, Validation, Supervision, Methodology, Investigation, Formal analysis, Conceptualization.

Declaration of Competing Interest

The authors declare that they have no known competing financial interests or personal relationships that could have appeared to influence the work reported in this paper.

References

- [1] L.P.M. Huygen, J. Westerink, G.C. Mol, R.H.H. Bemelmans, When LDL cholesterol is not LDL cholesterol: LpX, a clinical lesson, *JACC Case Rep.* 4 (11) (2022) 690–693.
- [2] Y. Zhao, S. Wang, S. Liang, H. Zhang, Y. Zhang, R. Yu, et al., Clinical laboratory characteristics of patients with obstructive jaundice accompanied by dyslipidemia, *Clin. Biochem.* 94 (2021) 42–47.
- [3] R. Fellin, E. Manzato, Lipoprotein-X fifty years after its original discovery, *Nutr. Metab. Cardiovasc. Dis. NMCD* 29 (1) (2019) 4–8.
- [4] L. Kattah, A. Gómez, S. Gutiérrez, K. Puerto, E.D. Moreno-Pallares, A. Jaramillo, et al., Hypercholesterolemia due to Lipoprotein X: case report and thematic review, *Clin. Med. Insights Endocrinol. Diabetes* 12 (2019) 1179551419878687.
- [5] F. Azad, N.A. Mughaedh, A. Alloghbi, I. Tawhari, Hypercholesterolemia due to lipoprotein-X manifesting as pseudo hyponatremia in a patient with cholestasis, *Proc. Bayl. Univ. Med. Cent.* 36 (2) (2023) 222–223.
- [6] E. García, I. Shalaurova, S.P. Matyus, L.A. Freeman, E.B. Neufeld, M.L. Sampson, R. Zubiran, et al., A high-throughput NMR method for Lipoprotein-X quantification, *Molecules* 29 (3) (2024) 564.
- [7] M. Padelli, C. Leven, E. Le Reun, T. Labouret, N. Galakhoff, M. Labarre, et al., Is capillary zone electrophoresis a suitable method for estimating serum albumin: a comparison of four methods, *Clin. Chim. Acta Int. J. Clin. Chem.* 487 (2018) 250–255.
- [8] A. Rossary, F. Blondé-Cyober, J.P. Bastard, M.C. Beauvieux, P. Beyne, J. Drai, et al., Determination of serum albumin, analytical challenges: a French multicenter study, *Ann. Biol. Clin. (Paris)* 75 (3) (2017) 305–318.
- [9] A. Ossoli, E.B. Neufeld, S.G. Thacker, B. Vaisman, M. Pryor, L.A. Freeman, et al., Lipoprotein X causes renal disease in LCAT deficiency, *PLoS One* 11 (2) (2016) e0150083.
- [10] E. Manzato, R. Fellin, G. Baggio, S. Walch, W. Neubeck, D. Seidel, Formation of lipoprotein-X. Its relationship to bile compounds, *J. Clin. Invest.* 57 (5) (1976) 1248–1260.
- [11] D. Seidel, P. Alaupovic, R.H. Furman, A lipoprotein characterizing obstructive jaundice. I. Method for quantitative separation and identification of lipoproteins in jaundiced subjects, *J. Clin. Invest.* 48 (7) (1969) 1211–1223.
- [12] Y. Jung, H.A. Nelson, D.M.H. Lin, Use of therapeutic plasma exchange to remove lipoprotein X in a patient with vanishing bile duct syndrome presenting with cholestasis, pseudo hyponatremia, and hypercholesterolemia: a case report and review of literature, *J Clin Apheresis.* 39 (1) (2024) e22105.
- [13] M.A. Crook, Lipoprotein X: clinical implications, *Ann Clin Biochem.* 50 (Pt 2) (2013) 93–94.
- [14] G. Ertürk Zararsız, S. Bolat, A. Cephe, N. Kochan, S.İ. Yerlitaş, H.O. Doğan, et al., Validation of Friedewald, Martin-Hopkins and Sampson low-density lipoprotein cholesterol equations, *PLoS One* 17 (5) (2022) e0263860.
- [15] P.J. Briers, M.R. Langlois, Concordance of apolipoprotein B concentration with the Friedewald, Martin-Hopkins, and Sampson formulas for calculating LDL cholesterol, *Biochem. Medica* 32 (1) (2022) 010704.
- [16] M.S. Zelmat, Direct and indirect ion selective electrodes methods: the differences specified through a case of Waldenström's macroglobulinemia, *Ann. Biol. Clin. (Paris)* 73 (3) (2015) 345–352.