



HAL
open science

Right iliac deep vein thrombosis and pulmonary embolism associated with recreational nitrous oxide: a case report

Thomas Bizouard, C Caplette, Damien Duval, Dominique Savary, Delphine Douillet

► To cite this version:

Thomas Bizouard, C Caplette, Damien Duval, Dominique Savary, Delphine Douillet. Right iliac deep vein thrombosis and pulmonary embolism associated with recreational nitrous oxide: a case report. *International Journal of Emergency Medicine*, 2024, 17 (1), pp.169. 10.1186/s12245-024-00689-z . hal-04826996

HAL Id: hal-04826996

<https://hal.science/hal-04826996v1>

Submitted on 9 Dec 2024

HAL is a multi-disciplinary open access archive for the deposit and dissemination of scientific research documents, whether they are published or not. The documents may come from teaching and research institutions in France or abroad, or from public or private research centers.

L'archive ouverte pluridisciplinaire **HAL**, est destinée au dépôt et à la diffusion de documents scientifiques de niveau recherche, publiés ou non, émanant des établissements d'enseignement et de recherche français ou étrangers, des laboratoires publics ou privés.



Distributed under a Creative Commons Attribution - NonCommercial - NoDerivatives 4.0 International License

CASE REPORT

Open Access



Right iliac deep vein thrombosis and pulmonary embolism associated with recreational nitrous oxide: a case report

Thomas Bizouard^{1*}, Catherine Caplette¹, Damien Duval¹, Dominique Savary^{1,2} and Delphine Douillet^{1,2,3}

Abstract

Background The recreational use of nitrous oxide is becoming increasingly common among teenagers and young adults. Since 2018, the use of nitrous oxide has increased exponentially and has become a public health problem.

Case presentation A 23-year-old patient was referred to accident and emergency (A&E) by his general practitioner for deterioration in general condition, vomiting, diarrhea and febrile headache at 39 °C.

He reported that he had been partying for a month and consuming alcohol, cannabis and nitrous oxide. Three days before the consultation, he reported increased abdominal pain in the right iliac fossa. His homocysteine concentration was 51.9 µmol/L, and his plasma methyl malonate concentration increased to 4.45 µmol/L. A thoracic and abdominal CT scan revealed right iliac venous thrombosis associated with bilateral pulmonary embolism.

Conclusion Nitrous oxide inhibits the activity of methionine synthetase. We therefore observed an increase in plasma homocysteine and 5-methyl-THF. The increase in homocysteine could be responsible for the pro-thrombotic activity resulting from nitrous oxide intoxication. At present, no threshold or duration of exposure has been identified as being particularly likely to cause complications. It is likely that other factors coexist, such as coagulation disorders and polymorphisms of the MHTFR gene, which can lead to hyperhomocysteinaemia, cannabis consumption, inflammatory conditions and others. Treatment is based on vitamin B12 supplementation and curative anticoagulation. Some authors also recommend folate supplementation.

Consumption of nitrous oxide could be associated with arterial and venous thromboembolic disease.

Keywords Thrombosis, Pulmonary embolism, Nitrous oxide abuse, Vitamin B12, Hyperhomocysteinaemia

Background

The recreational use of nitrous oxide is becoming increasingly common among teenagers and young adults [1]. The first notifications to the national drug safety agency were made in 2012, but it was not until 2018 that the use of nitrous oxide increased exponentially and became a public health problem [2]. Nitrous oxide is the second most commonly used drug among young adults aged 16 to 24 years [3]. Approximately 63% of users believe that this substance is safe [4]. Nitrous oxide is consumed in the form of a freely available food additive, known colloquially as “whippets” (food gas cartridges) [4, 5]. The

*Correspondence:

Thomas Bizouard
Thomas.bizouard@chu-angers.fr

¹ Department of Emergency Medicine, University Hospital of Angers, 49100 Angers, France

² EHESP, Irset (Institut de Recherche en Santé, SFR ICAT, Univ Angers, CHU Angers, Univ Rennes, CAPTV CDC, Environnement Et Travail) - UMR_S 1085, InsermAngers, France

³ UMR MitoVasc CNRS 6215 INSERM 1083, UNIV Angers, Angers, France



complications are manifold: neurological (mainly cerebral thrombosis and neuropathy) [1, 6, 7], psychiatric [1, 4], digestive [1], and cardiovascular (acute coronary syndrome and arterial and venous thrombosis) [1, 8]. We are going to present the case of a young patient who went to accident and emergency (A&E) and was referred by his general practitioner.

Case presentation

A 23-year-old patient was referred for deterioration in general condition, vomiting, diarrhea and febrile headache at 39 °C. He reported using alcohol, cannabis and nitrous oxide for one month. He reported increased abdominal pain in the right iliac fossa three days prior to consultation. The outpatient laboratory report revealed hyponatremia at 130 mmol/L, acute renal failure with creatinemia at 106 µmol/L, hepatic cytolysis with ASAT at 51 IU/L, ALAT at 79 IU/L, and elevated range-GT at 61 IU/L, all of which are associated with inflammatory syndrome with hyperleukocytosis at 13 G/L with neutrophils (10 G/L) and CRP at 212 mg/L. The only history was psoriasis and depression, and smoking was estimated at 9 pack-years. He consumed alcohol associated with nitrous oxide daily. His blood pressure was 125/72 mmHg, his heart rate was 90/min, his capillary oxygen saturation was 98%, and his temperature was 38.5 °C. On clinical examination, there were signs of extracellular dehydration with dry mucous membranes, and the abdomen was painful and tender in the hypochondrium, flank, right iliac fossa and epigastrium. Ultrasound ruled out abdominal compartment infection. Biologically, the authors reported the persistence of inflammatory syndrome with CRP at 200 mg/L and hyperleukocytosis at 10.7 G/L and of renal failure with creatinemia at 98 µmol/L and no increase in lipase at 70 IU/L. In addition, homocysteine was measured at 51.9 µmol/L, plasma methyl malonate was increased to 4.45 µmol/L, and anti-cardiolipin and anti-beta 2 antibodies were negative.

A abdominal scan was performed if appendicitis or cholecystitis was suspected, revealing right iliac venous thrombosis. The radiologist then extended the CT scan to the thorax which revealed bilateral pulmonary embolism. He was then anticoagulated with 7000 IU of enoxaparin, followed by rivaroxaban in the medical ward. At a subsequent follow-up visit, the biological work-up and inflammatory syndrome showed a marked improvement. Similarly, the digestive symptoms had completely improved.

Discussion

This case highlights the possible association between the consumption of nitrous oxide and the occurrence of thrombotic events, which have rarely been described [1].

The pro-thrombotic effects are thought to be linked to the interaction of nitrous oxide with the intracellular metabolism of vitamin B12 [3, 7, 9]. Its active form, adenosyl cobalamin, decreases with the efficiency of methionine synthase, resulting in an increase in homocysteine as well as cardiovascular and thrombotic risks (see Fig. 1) [9].

The cofactor activity of vitamin B12 for methionine synthase and methylmalonyl-CoA mutase is affected by nitrous oxide. Nitrous oxide oxidizes methylcobalamin and thus inhibits the activity of methionine synthase. This enzyme catalyses the conversion of homocysteine and 5-methyl-THF to methionine and THF. We therefore observed an increase in plasma homocysteine and 5-methyl-THF. Methylcobalamin is involved in the migration of methylcobalamin-CoA mutase from the mitochondria to the cytosol, resulting in an alteration in lipid metabolism and an accumulation of methylmalonic acid [9, 10] (see Fig. 2).

The increase in homocysteine could be responsible for the pro-thrombotic activity resulting from nitrous oxide intoxication [3]. However, the results of clinical case reviews are ambivalent: not all patients have an increase in homocysteine, and not all have a decrease in vitamin B12 [1].

At present, no threshold or duration of exposure has been identified as being particularly likely to cause complications. This is especially true given that the action of nitrous oxide varies and likely differs depending on the metabolic pathway.

Diagnosis is therefore difficult and depends on a range of factors, including a history of the disease, nitrous oxide consumption and elevated homocysteine and methylmalonic acid levels. It is likely that other factors coexist, such as coagulation disorders and polymorphisms of the MHTFR gene, which can lead to hyperhomocysteinaemia, cannabis consumption, inflammatory conditions and others.

Treatment is based on vitamin B12 supplementation and curative anticoagulation [1, 3]. Some authors also recommend folate supplementation [1, 5, 7]. Depending on the organ affected, thrombectomy procedures are discussed. The duration of anticoagulation is unknown, but it should be assumed that hyperhomocysteinaemia persists despite the cessation of nitrous oxide consumption [3].

There is no specific marker for nitrous oxide intoxication, especially because vitamin B12 is rarely decreased and is not correlated with the severity of intoxication. However, an increase in homocysteine is associated with recent increases in nitrous oxide consumption and methylmalonic acid [11].

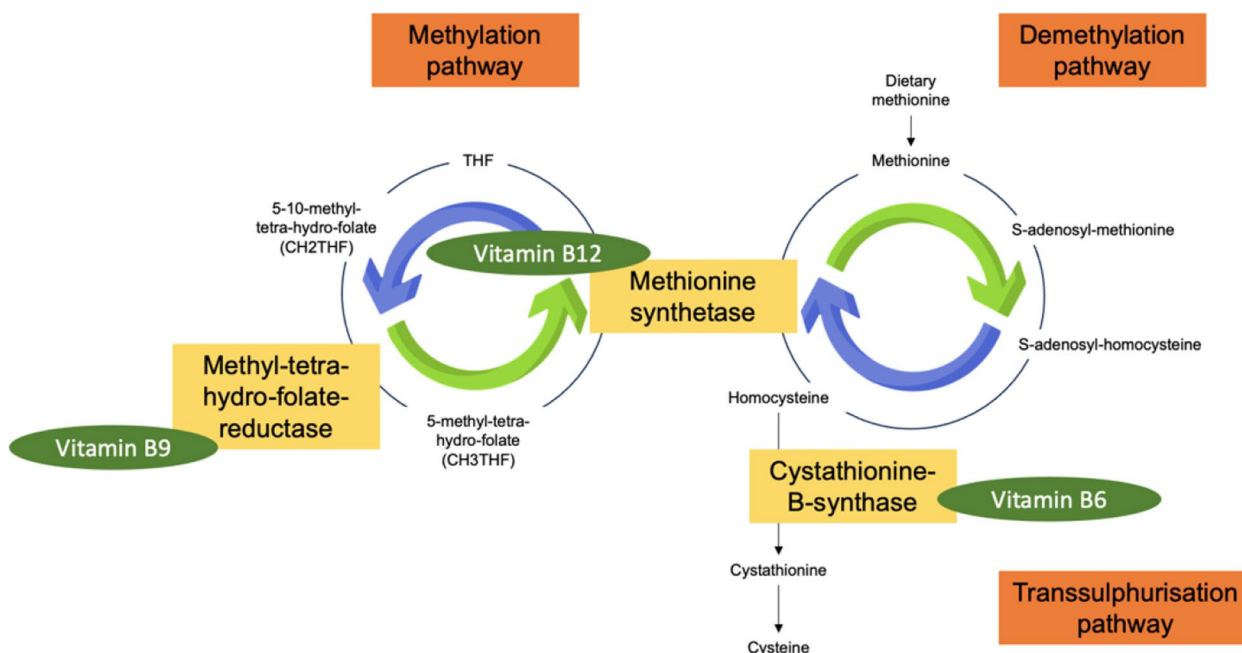


Fig. 1 Homocysteine metabolism [10]

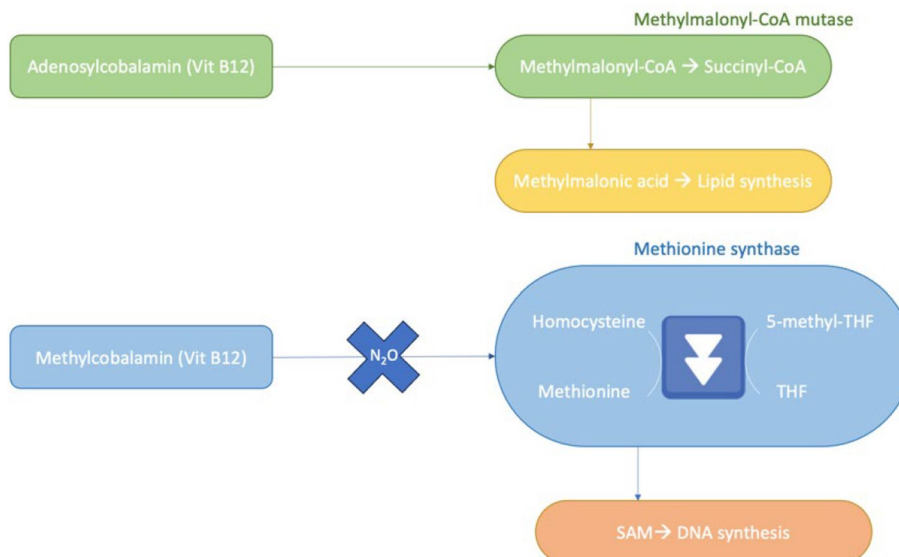


Fig. 2 Adenosyl-cobalamin is a cofactor of the mitochondrial methylmalonyl-CoA mutase [10]

Conclusion

Nitrous oxide consumption could be associated with arterial and venous thromboembolic disease. At present, it is not possible to identify a threshold frequency of consumption that should be of concern to clinicians.

Abbreviations

A and E Accident and emergency facility
 ANSM Agency National Safety Drug

CT Computed tomography
 THF Tetra-hydrofolate

Authors' contributions

The first author (TB) is responsible for writing the text, and all authors are responsible for proofreading and editing. All the authors (CC, DDu, DS, DDo) read and approved the final manuscript.

Funding

No funding.

Availability of data and materials

The datasets analysed during the current study are not publicly available due to in terms of the patient's medical record but are available from the corresponding author on reasonable request.

Declarations

Ethics approval and consent to participate

Not applicable for this study.

Consent for publication

The patient consents to the publication of his data.
Consent to participate patient consent to the use of their data.

Competing interests

The authors declare that they have no competing interests.

Received: 6 March 2024 Accepted: 26 August 2024

Published online: 04 November 2024

References

1. Oulkadi S, Peters B, Vliegen A-S. Thromboembolic complications of recreational nitrous oxide (ab)use: a systematic review. *J Thromb Thrombolysis*. 2022;54(4):686–95. <https://doi.org/10.1007/s11239-022-02673-x>.
2. Guerlais, M., Aquizerate, A., Lionnet, A., Daveluy, A., Duval, M., Gérardin, M.; et al. Nitrous oxide: a unique official French addictovigilance national survey. *Front Public Health*. 2023;11. <https://doi.org/10.3389/fpubh.2023.1167746>.
3. Er C, Breen K, Cohen AT. Nitrous oxide misuse: a clue not to be missed in young patients with venous thromboembolism. *Clin Med (Lond)*. 2023;23(2):170–2. <https://doi.org/10.7861/clinmed.2022-0516>.
4. Fidalgo, M.; Prud'homme, T.; Allio, A.; Bronnec, M.; Bulteau, S.; Jolliet, P.; et al. Nitrous oxide: What do we know about its use disorder potential? Results of the French Monitoring Centre for Addiction network survey and literature review. *Substance Abuse* 2019, 40(1), 33–42. <https://doi.org/10.1080/08897077.2019.1573210>.
5. Pratt DN, Patterson KC, Quin K. Venous thrombosis after nitrous oxide abuse, a case report. *J Thromb Thrombolysis*. 2020;49(3):501–3. <https://doi.org/10.1007/s11239-019-02010-9>.
6. de Valck L, Defelippe VM, Bouwman NAMG. Cerebral venous sinus thrombosis: a complication of nitrous oxide abuse. *BMJ case reports*. 2021;14(8):e244478. <https://doi.org/10.1136/bcr-2021-244478>.
7. Farhat W, Pariante A, Mijahed R. Extensive Cerebral Venous Thrombosis Secondary to Recreational Nitrous Oxide Abuse. *Cerebrovascular Diseases (Basel, Switzerland)*. 2022;51(1):114–7. <https://doi.org/10.1159/000518524>.
8. Oomens T, Fokkema TMM, van den Bogaard B, de Metz J, van Nieuwenhuizen RC, Riezebos RK, et al. Thromboembolisms due to recreational use of nitrous oxide. *Ned Tijdschr Geneesk*. 2021;165:D5607.
9. Vollenbrock SE, Fokkema TM, Leijdekkers VJ, Vahl AC, Konings R, van Nieuwenhuizen RC. Nitrous Oxide Abuse Associated with Severe Thromboembolic Complications. *European Journal of Vascular and Endovascular Surgery: The Official Journal of the European Society for Vascular Surgery*. 2021;62(4):656–7. <https://doi.org/10.1016/j.ejvs.2021.05.041>.
10. Hyperhomocystéinémie : facteur de risque de thrombose veineuse ? - ClinicalKey Student. <<https://www.clinicalkey.com/student/content/emc/51-s2.0-S2211036418903924>> Accessed 23.08.18.
11. Grzych G, Deheul S, Gernez E, Davion J-B, Dobbelaere D, Carton L, et al. Comparison of biomarker for diagnosis of nitrous oxide abuse: challenge of cobalamin metabolic parameters, a retrospective study. *J Neurol*. 2023;270(4):2237–45. <https://doi.org/10.1007/s00415-023-11570-z>.

Publisher's Note

Springer Nature remains neutral with regard to jurisdictional claims in published maps and institutional affiliations.