



HAL
open science

French AFU Cancer Committee Guidelines u2013 Update 2024u20132026: Management of kidney cancer

Pierre Bigot, Romain Boissier, Zine Eddine Khene, Laurence Albigès, Jean Christophe Bernhard, Jean Michel Correas, Stéphane de Vergie, Nicolas Doumerc, Matthieu Ferragu, Alexandre Ingels, et al.

► **To cite this version:**

Pierre Bigot, Romain Boissier, Zine Eddine Khene, Laurence Albigès, Jean Christophe Bernhard, et al.. French AFU Cancer Committee Guidelines u2013 Update 2024u20132026: Management of kidney cancer. *The French Journal of Urology*, 2024, 34 (12), 10.1016/j.fjurol.2024.102735 . hal-04822743

HAL Id: hal-04822743

<https://hal.science/hal-04822743v1>


Submitted on 17 Dec 2024

HAL is a multi-disciplinary open access archive for the deposit and dissemination of scientific research documents, whether they are published or not. The documents may come from teaching and research institutions in France or abroad, or from public or private research centers.

L'archive ouverte pluridisciplinaire **HAL**, est destinée au dépôt et à la diffusion de documents scientifiques de niveau recherche, publiés ou non, émanant des établissements d'enseignement et de recherche français ou étrangers, des laboratoires publics ou privés.



Distributed under a Creative Commons Attribution 4.0 International License



Recommendations

French AFU Cancer Committee Guidelines – Update 2024–2026: Management of kidney cancer



Pierre Bigot^{a,b,*}, Romain Boissier^{a,c}, Zine-Eddine Khene^{a,d}, Laurence Albigès^{a,e}, Jean-Christophe Bernhard^{a,f}, Jean-Michel Correas^{a,g}, Stéphane De Vergie^{a,h}, Nicolas Doumerc^{a,i}, Matthieu Ferragu^{a,b}, Alexandre Ingels^{a,j}, Gaëlle Margue^{a,f}, Idir Ouzaïd^{a,k}, Caroline Pettenati^{a,l}, Nathalie Rioux-Leclercq^{a,m}, Paul Sargos^{a,n}, Thibaut Waeckel^{a,o}, Philippe Barthelemy^{a,p}, Morgan Rouprêt^{a,q}

^a Oncology Committee of the French Urology Association, Kidney Group, Maison de l'Urologie, 11, rue Viète, 75017 Paris, France

^b Department of Urology, Angers University Hospital, Angers, France

^c Department of Urology and Kidney Transplantation, Conception University Hospital, Aix-Marseille University, AP-HM, Marseille, France

^d Department of Urology, Rennes University Hospital, Rennes, France

^e Department of Cancer Medicine, Gustave-Roussy, Paris-Saclay University, Villejuif, France

^f Department of Urology, Hôpital Pellegrin, Bordeaux University Hospital, Bordeaux, France

^g Department of Adult Radiology, Hôpital Necker, University of Paris, AP-HP Centre, Paris, France

^h Department of Urology, Nantes University Hospital, Nantes, France

ⁱ Department of Urology and Renal Transplantation, Toulouse University Hospital, Toulouse, France

^j Department of Urology, UPEC, Hôpital Henri-Mondor, Créteil, France

^k Department of Urology, Bichat University Hospital, AP-HP, Paris, France

^l Department of Urology, Hôpital Foch, University of Versailles – Saint-Quentin-en-Yvelines, 40, rue Worth, 92150 Suresnes, France

^m Department of Pathology, Rennes University Hospital, Rennes, France

ⁿ Department of Radiotherapy, Hôpital Pellegrin, Bordeaux University Hospital, Bordeaux, France

^o Department of Urology, Caen University Hospital, Caen, France

^p Medical Oncology, Institut de Cancérologie Strasbourg Europe, Strasbourg, France

^q Urology, Hôpital Pitié-Salpêtrière, Predictive Onco-Urology, GRC 5, Sorbonne University, AP-HP, 75013 Paris, France

ARTICLE INFO

Keywords:

Kidney cancer

Recommendation

French Association of Urology

ABSTRACT

Objective: To update the French recommendations for the management of kidney cancer.

Methods: A systematic review of the literature was conducted for the period from 2014 to 2024. The most relevant articles concerning the diagnosis, classification, surgical treatment, medical treatment, and follow-up of kidney cancer were selected and incorporated into the recommendations. The recommendations have been updated specifying the level of evidence (strong or weak).

Results: Kidney cancer following prolonged occupational exposure to trichloroethylene should be considered an occupational disease. The reference examination for the diagnosis and staging of kidney cancer is the contrast-enhanced thoraco-abdominal CT scan. PET scans are not indicated in the staging of kidney cancer. Percutaneous biopsy is recommended in situations where its results will influence therapeutic decisions. It should be used to reduce the number of surgeries for benign tumors, particularly avoiding unnecessary radical nephrectomies. Kidney tumors should be classified according to the pTNM 2017 classification, the WHO 2022 classification, and the ISUP nucleolar grade. Metastatic kidney cancers should be classified according to IMDC criteria. Surveillance of tumors smaller than 2 cm should be prioritized and can be offered regardless of patient age. Robot-assisted laparoscopic partial nephrectomy is the reference surgical treatment for T1 tumors. Ablative therapies and surveillance are options for elderly patients with comorbidities for tumors larger than 2 cm. Stereotactic radiotherapy is an option to discuss for treating localized kidney tumors in patients not eligible for other treatments. Radical nephrectomy is the first-line treatment for locally advanced localized cancers. Pembrolizumab is recommended for patients at high risk of recurrence after surgery for localized kidney cancer. In metastatic patients, cytoreductive nephrectomy can be immediate in cases of good prognosis, delayed in cases of intermediate or poor prognosis for patients stabilized by medical treatment, or as “consolidation” in patients with complete or major partial response at metastatic sites after

* Corresponding author. Oncology Committee of the French Urology Association, Kidney Group, Maison de l'Urologie, 11, rue Viète, 75017 Paris, France.
E-mail address: pibigot@chu-angers.fr (P. Bigot).

systemic treatment. Surgical or local treatment of metastases can be proposed for single lesions or oligometastases. Recommended first-line drugs for metastatic clear cell renal carcinoma are combinations of axitinib/pembrolizumab, nivolumab/ipilimumab, nivolumab/cabozantinib, and lenvatinib/pembrolizumab. Patients with non-clear cell metastatic kidney cancer should be presented to the CARARE Network and prioritized for inclusion in clinical trials.

Conclusion: These updated recommendations are a reference that will enable French and French-speaking practitioners to optimize their management of kidney cancer.

© 2024 The Author(s). Published by Elsevier Masson SAS. This is an open access article under the CC BY license (<http://creativecommons.org/licenses/by/4.0/>).

1. Epidemiology, risk factors

1.1. Epidemiology

Kidney cancer is the 14th most common cancer worldwide. Its incidence varies widely by region, with the highest rates observed in men, those aged 75 years and older, and in the Western Hemisphere, particularly in Europe and North America. [1]. The number of kidney cancers cases has increased in most countries in recent decades, particularly in younger populations (< 50 years) [2]. The reasons for this trend are debated, but possible explanations include increased use of imaging examinations leading to incidental findings, a rise in risk factors like obesity, and an aging population [3]. However, our understanding of this phenomenon is still limited and requires focused attention on a global scale [4].

It is estimated that 17,141 new cases of kidney cancer will be diagnosed in France in 2023, which represents a 199% increase in incidence rates between 1990 and 2023. This increase was particularly pronounced among individuals under the age of 50 and in men. [5]. Notwithstanding the considerable rise in the incidence of kidney cancer in France, mortality rates have remained relatively stable, with 5589 deaths recorded in 2018 [6].

A review of the histological characteristics of kidney cancers reveals that the vast majority (90%) of cases are renal cell carcinomas (RCCs). The principal subtypes are clear cell RCC (70%), papillary RCC (10–15%), and chromophobe RCC (5%). The remaining subtypes are exceedingly rare, with an incidence of less than or equal to 1% [7].

1.2. Risk factors

The non-modifiable risk factors for kidney cancer are age, with a peak in incidence after the age of 75 [8] gender, with a male/female incidence ratio of 2/1 [9] and familial forms, which account for 3% to 5% of kidney cancers [10].

Modifiable risk factors are lifestyle-related and can be targeted for primary prevention. These include metabolic syndrome (RR 1.62 [1.41–1.87]), obesity (RR: 2.16 [1.77–2.63]), arterial hypertension (RR: 1.70 [1.30–2.22]) and smoking (RR: 1.39 [1.28–1.51]) [2,11–17]. Additionally, chronic renal failure is also associated with an increased risk of kidney cancer (RR 2.58, 95% CI 1.21–5.50) [7,16]. Chronic end-stage renal disease is associated with bilateral and/or multifocal forms that are generally not highly aggressive [18–21]. The role of diabetes as an independent risk factor for kidney cancer remains a topic of debate [7,14,16].

Since 2021, kidney cancer can be recognized as an occupational disease in the case of exposure to trichloroethylene for more than 10 years, with a waiting period for reimbursement of 40 years. [22]. Trichloroethylene is a chlorinated solvent with a long history of use in industry, mainly for degreasing metal parts and dry-cleaning clothes, but also as a component of paints, varnishes and pesticides. [23]. Its use by private individuals has been restricted in France since 1985, and has been definitively banned in the European Union since 2016 [24,25]. The restrictive list of work recognized by the new table is: “degreasing and cleaning of tools, mechanical or electrical equipment and metal parts before 1995” [22].

For anyone diagnosed with kidney cancer, it is essential to investigate their past employment and exposure circumstances, particularly to carcinogens known to cause kidney cancer, such as trichloroethylene.

Tools may be employed to assess exposure based on industrial toxicology data (INRS), documents from past companies attesting to exposure (exposure certificates, nuisance job sheets or others such as the single document, the occupational health file, Ministry of Labour), or such as job-exposure matrices (Matg  n   from Sant   publique France direct access).

Patients currently under the care of an occupational health physician or a regional center for occupational and environmental pathology should be referred to these professionals to confirm or rule out exposure and consider subsequent steps, such as compensation, prevention, and potential return to work if appropriate (Recommendation Table 1).

1.3. Protective factors and prevention

A physically active lifestyle and a diet rich in vegetables, fruit, and vitamin C may confer protection against kidney cancer [7,26–30]. However, the underlying mechanisms remain poorly described, and there are no high-level studies on this subject. The most effective primary prevention strategy is to promote healthy behaviors, including smoking prevention and cessation, reduction of obesity, and promotion of physical activity [2,7,28,31] (Recommendation Table 2).

1.4. Screening

The low prevalence of kidney cancer represents a significant challenge to the effectiveness of systematic screening. To date, no biomarker (blood or urine) or imaging protocol has demonstrated a favorable cost-benefit ratio [31–34]. Nevertheless, an increasing number of studies are examining the potential for integrating CT screening for kidney cancer with lung cancer [35,36].

It seems reasonable to suggest that surveillance of high-risk individuals is an appropriate course of action. In the case of Von Hippel-Lindau disease, the current recommendation is for screening by abdominal MRI every two years from the age of 15 [37]. Other familial forms of hereditary kidney cancer could benefit from screening [38].

Recommendation Table 1

Exposure to trichloroethylene and occupational disease.

Recommendation	Grade
A patient diagnosed with kidney cancer after more than 10 years' occupational exposure to trichloroethylene should be referred to a specialist in occupational medicine and/or to a regional center for occupational and environmental pathology.	High

Recommendation Table 2

Primary prevention of kidney cancer.

Recommendation	Grade
Smoking cessation, physical activity and weight loss in obese patients are recommended as primary prevention to reduce the risk of kidney cancer.	High

Recommendation Table 3
Kidney cancer and screening.

Recommendations	Grade
Kidney cancer screening is not recommended in the general population	High
Screening for kidney cancer in certain at-risk populations, such as hereditary kidney cancer, hemodialysis patients and transplant patients, should be discussed with the patient.	High

Monitoring patients with end-stage renal disease, who have a tenfold increased risk of developing RCC, may also be a valid approach [39]. The Transplantation Committee of the French Urology Association (CTAFU) recommends regular monitoring of native kidneys using appropriate imaging in transplant patients (low grade) [40] (Recommendation Table 3).

2. Diagnostic evaluation of a kidney tumour

2.1. Imaging techniques: techniques and results

Most renal tumours are discovered incidentally on abdominal ultrasound or computed tomography (CT) scans ordered for other medical reasons [41]. The diagnosis and characterization of renal masses are based on three complementary imaging techniques – Doppler ultrasound, CT and MRI – which can be performed with or without contrast injection (Recommendation Table 4).

2.1.1. Doppler ultrasound

Ultrasound often detects renal masses, incidentally, providing essential characterization elements such as distinguishing between cystic or solid masses, identifying typical or atypical features, and identifying a distinctly hyperechoic appearance suggestive of angiomyolipoma (AML). When combined with Doppler ultrasound, it can assess the vascularization of the mass and evaluate vascular extension into the renal vein or inferior vena cava. Ultrasound is also useful for active surveillance to measure the renal tumor and provides highly effective guidance for biopsies by allowing real-time visualization of the needle’s trajectory.

The use of an intravenous contrast agent, such as Sonovue®, enhances the characterization of poorly vascularized solid masses, atypical cystic masses, and venous thrombi, helping differentiate between tumor and cruciate thrombi. It also aids in guiding biopsies toward non-necrotic areas in large tumors [42–44]. The contrast agent is well tolerated in clinical practice, with no contraindication related to renal function [42].

2.1.2. Computed tomography (CT)

2.1.2.1. Iodinated contrast media (ICP). ICPs are less well-tolerated contrast agents, with hypersensitivity reactions occurring in up to 3% of cases, including 0.04% of severe anaphylactic reactions. The risk of renal

Recommendation Table 4

Recommendations for imaging kidney tumours.

Recommendations for imaging kidney tumours	Grade
The pre-therapeutic assessment of a renal tumour should include an abdominal and pelvic CT scan if there is no contraindication to the use of iodinated contrast products. It should include at least three phases.	High
Masses with a cystic component must be analyzed according to the Bosniak classification.	High
MRI is an alternative in cases of renal failure, in the exploration of cystic tumours and tumours poorly characterized by other imaging examinations.	High
18-FDG PET scans are not recommended for the initial assessment of kidney tumours.	High

function deterioration ranges from 2% to 6%, depending on the route of administration for low osmolality contrast products [45–47]. Patients at risk of contrast-induced nephropathy include those with:

- acute renal failure;
- a glomerular filtration rate (GFR) of less than 45 mL/min/1.73 m² for suprarenal intra-arterial injection or patients hospitalized in intensive care;
- a GFR of less than 30 mL/min/1.73 m² for sub-renal intra-arterial or intravenous injection (e.g., in CT scans).

In patients at risk, alternative imaging modalities such as MRI or ultrasound with contrast injection should be considered, or precautions like ensuring adequate hydration should be taken. It’s recommended to space ICP injections at least three days apart, limit the injected dose to the minimum necessary, and monitor creatinine levels 48 to 72 hours post-injection.

Hemodialysis after contrast injection does not reduce renal toxicity from ICPs [47]. However, for dialysis patients, CT with contrast injection is preferable to MRI with injection if the diagnostic benefit is comparable. For diabetic patients on metformin, there is no need to stop the medication due to the risk of lactic acidosis if the GFR is above 30 mL/min/1.73 m². If the GFR is below this threshold, metformin should be discontinued on the day of injection and resumed only after checking creatinine levels at 48 hours, provided there is no significant change in renal function. Lastly, even secretory light chain myeloma is no longer an absolute contraindication to the use of ICPs, depending on renal function [48].

2.1.2.2. Technical. CT is the reference examination for the evaluation of kidney tumors in the absence of contraindications to ICP. The dose of ICP must be sufficient to detect enhancement of hypovascular tumors and Bosniak III and IV cystic masses (0.2 mL/kg of a product containing 350 mg/mL iodine). A CT scan may comprise four phases:

- acquisition without injection, which is essential for defining contrast (> + 20 HU between the tubular phase and acquisition without injection);
- acquisition at the cortical phase, which should occur 30 to 40 seconds after injection;
- acquisition at the nephrogenic phase, which should occur 80 to 100 seconds after injection (this is different from the portal phase, which is acquired 60 seconds after injection and in which the medullary is not yet enhanced);
- late excretory acquisition.

In accordance with the indications, these phases may be combined with the objective of limiting irradiation. The acquisition in the excretory phase is dependent on the indication, with the aim of either searching for late enhancement or studying the relationship between the tumor and the excretory tract [49–51].

For renal imaging, it is recommended that patients should not fast, and that the digestive tract should not be opacified. Dual-energy and spectral CT is a new technology whose results could be promising for the study of renal pathology [52]. Spectral mode CT imaging is under development and has promising applications in the study of renal pathology. There are various technologies available, involving either the emission of the X-ray beam or the sensors. In current practice, they provide access to single-energy images and iodine mapping (with measurement of iodine concentration). These examinations can be carried out with a lower dose of contrast product (less than 80–100 mL) while reducing the radiation dose. Artefacts associated with pseudo-enhancement of central renal masses and metallic artefacts are reduced. Lowering the keV improves the sensitivity of the technique for detecting low enhancement (papillary carcinomas) [53–55]. In several preliminary studies, improved enhancement detection has led to better characterization of cystic masses [56,57]. Nevertheless, it should be emphasized that these new technologies require a new definition of enhancement thresholds, which must be adapted to the energy levels used for image reconstruction. In the study of solid masses, spectral scanning could make it possible to develop new biomarkers such as the normalized iodine concentration, the measurement of enhancement at a fixed energy (such as 70 keV) and the slope of the spectral energy. These parameters could allow better differentiation between high-grade tumours [58,59].

2.1.2.3. Results and indications. CT is the preferred technique for identifying angiomyolipoma (AML), as it is capable of detecting macroscopic islands of fat (density < -20 HU). However, it should be noted that fatty metaplasia associated with calcifications may occur in clear cell carcinomas, albeit exceptionally. In the absence of macroscopic fat, AML may exhibit moderate spontaneous hyperdensity (density > 45 HU) and homogeneous enhancement [60].

Cystic lesions must be analyzed according to the Bosniak classification, which distinguishes five categories according to the risk of malignancy. This classification is applicable to cystic masses in the absence of any infectious context or autosomal polycystic disease. However, there is considerable variability in the rate of malignancy due to differences in diagnostic criteria, study bias, acquisition technique, and imaging method (CT vs. MRI vs. contrast ultrasound).

Additionally, CT provides information regarding the characterization of RCC, specifically whether the enhancement is hypervascular or homogeneous. Nevertheless, these findings are merely indicative and should prompt the patient to undergo a renal puncture biopsy as soon as the nature of the result allows for modification of the management plan.

A computed tomography (CT) examination with an injection is the primary diagnostic tool used in the preoperative assessment of a kidney tumor. The optimal imaging protocol would entail a pre-injection study and three post-injection phases, with multiplanar and maximum intensity projection (MIP) reconstructions. This allows for a precise assessment of the tumor, including its size, location, relationship with the upper excretory tract and vessels, as well as the perirenal fat. The use of grading according to the RENAL or PADUA scores may prove useful in predicting the complexity of partial nephrectomy [61]. In the case of venous thrombosis, the level of the upper portion of the thrombus in relation to the diaphragm and the ostium of the suprahepatic veins must be determined. It looks for a synchronous tumour in the contralateral kidney.

2.1.3. MRI

Magnetic resonance imaging (MRI) has become a preferred alternative to computed tomography (CT) in cases where IPC injection is contraindicated, such as in patients with renal failure with a glomerular filtration rate (GFR) below 30 mL/min or a history of anaphylactic reaction to PCI injection. It is indicated for characterizing atypical cystic and solid masses that remain undetermined on CT scan, for extension assessment (particularly vascular), and for monitoring patients with familial hereditary cancer. Nevertheless, the pre-therapeutic assessment of kidney tumors continues to rely primarily on CT.

2.1.3.1. Gadolinium-based contrast media (GBM) [46,47]. They are very well tolerated in clinical practice, and systemic nephrogenic fibrosis is now a very rare side effect, and has even disappeared [62]. It used to occur in patients with severe renal insufficiency (GFR < 15 mL/min/1.73 m²) or dialysis, and its incidence was linked to the stability of the Gadolinium chelating complex. In patients at risk, injection is not currently contraindicated if the clinical benefit outweighs the risk, which is the case for kidney cancer, but only products with high stability should be used (Gadobutrol, Gadoterate meglumine and Gadoteridol). PCG can lead to the accumulation of gadolinium in the basal ganglia, though no specific neurological symptoms have been linked to these deposits so far. Additionally, gadolinium can accumulate in bone, liver, and skin. In the skin, this can result in erythematous plaques similar to those seen in systemic nephrogenic fibrosis, although these occurrences are not associated with renal failure.

2.1.3.2. MRI technique. The multiparametric study includes axial and coronal T2-weighted sequences without and with saturation of the fat signal, T1-weighted gradient echo in phase and phase opposition (detection of intra-tumour fat on the phase opposition sequence), diffusion at high B (800 to 1000), and finally a dynamic sequence after injection of contrast medium with acquisition of late times (study of tumour wash-out, contrast of central stellate fibrosis in oncocytoma).

2.1.3.3. Results and indications. T2-weighted sequences (with or without saturation of the fat signal) can be used to differentiate between solid tumors and typical (even sub-centimeter-sized) or atypical fluid masses, as well as to a lesser extent, AML (even low-fat) in T2 hyposignal (hemorrhagic suffusions, papillary formations, or muscle cells) [63,64]. Clear cell carcinomas and oncocytic tumours frequently exhibit a hypersignal [65,66]. The dynamic T1-weighted sequence, conducted before and after the injection of PCG, allows for the differentiation of hypervascular and heterogeneous tumors (which correspond to clear cell carcinomas and AML) from homogeneous, less enhanced tumors (which are characteristic of chromophobe carcinomas) or weakly enhanced tumors (which are characteristic of papillary carcinomas). The presence of a signal drop in phase opposition and on fat saturation sequences is not specific to AML with a low fat contingent, as it is described in many carcinomas [67]. MRI can also be used to identify microcystic areas or necrotic-hemorrhagic changes. A central stellate hypovascular zone is compatible with the diagnosis of oncocytoma but may also be found in renal carcinomas [68]. Diffusion imaging is very sensitive for detecting small subcentimetric tumours that are difficult to characterize by other sequences [69]. Diffusion imaging is also very sensitive for the identification of lymph node, adrenal, pancreatic or hepatic metastases during extension work-up or surveillance [70,71].

MRI can provide supplementary data to computed tomography (CT) in the preoperative assessment of renal tumors with venous thrombus. It offers a superior evaluation of the extent of venous wall invasion, which may necessitate surgical reconstruction or the delineation of the upper thrombus limit [72–75].

Although MRI can assist in the identification of different types of solid tumors, it is not a definitive diagnostic tool due to the lack of specificity of the various combined signs. In cases where subsequent treatment may be modified based on the histological results, biopsy remains an essential procedure [76].

2.1.4. Metabolic imaging

The fluorine-18-fluorodeoxyglucose positron emission tomography (PET) scanner (18-FDG PET) is a valuable tool for assessing the extent of many cancers. It is not a useful modality for characterizing kidney tumors. Nevertheless, its potential is currently being investigated in the context of the initial extension assessment and post-surgical recurrence detection. The evaluation of additional tracers may facilitate the acquisition of data pertaining to the histological subtypes of kidney tumors. Single-photon

emission tomography with ^{99m}Tc sestamibi appears to have good specificity for characterizing the oncocytoma and chromophobe subtypes [77,78]. Girentuximab (cG250), a chimeric anti-CAIX antibody, is used in molecular imaging for PET/CT imaging when labelled with isotopes such as ^{131}I , ^{124}I or ^{111}In , paving the way for radioimmunotherapy (RIT) in clear cell CRC (ccCCR). Lindenberg et al. evaluated the PET/CT potential of ^{124}I -labelled girentuximab in 195 patients surgically treated for renal tumour and concluded that it had a sensitivity and specificity of 86% for the detection of malignant renal tumours [79]. Hekman et al. conducted a study using ^{89}Zr -labelled girentuximab in PET/CT imaging, demonstrating its ability to predict the histological subtype of ccCCR and exclude recurrence in previously treated patients [80]. Minn et al. developed a novel dual-motif ligand, ^{64}Cu -XYIMSR-06, with high affinity for CAIX, facilitating PET/CT imaging programs compared with girentuximab [81]. More recently, the prospective phase 3 ZIRCON trial studied ^{89}Zr -DFO-girentuximab in 300 patients. PET positivity was assessed by 3 independent readers blinded to ccCCR status. Mean sensitivity and specificity were 86% and 87% respectively in the overall population, and 85% and 90% in the subgroup ≤ 4 cm. Sensitivity and specificity for lesions ≤ 2 cm were 90% and 100%, respectively. Inter- and intra-reader agreement was 91% and 100%, respectively. In the subgroup ≤ 4 cm, the positive and negative predictive values were 93.4% and 78%, respectively [82]. Girentuximab PET scans could be used to assess small renal tumours and could be particularly useful for tumours smaller than 2 cm and/or cystic tumours that are inaccessible to biopsy.

2.1.5. Outlook

The advent of novel imaging modalities and artificial intelligence, particularly radiomics, should facilitate more precise characterization of tumor subtypes and their propensity for progression [83] and their potential response to treatment [84].

2.2. Assessment of extension

The standard extension assessment is based on thoracic and abdominal-pelvic CT scans, both with and without injection. The thoraco-abdominal-pelvic scan is performed concurrently with the arterial nephrography. In the event that a PCI injection is contraindicated, a thoraco-abdominal and pelvic CT scan without injection may be combined with an abdominal MRI scan without and with injection.

In cases of metastatic disease, it is recommended that systematic brain imaging (either MRI or CT) and bone scintigraphy be performed if symptoms are present.

2.3. Anatomical classifications

Morphometric classifications have been developed with the objective of aiding clinicians in surgical planning and providing patients with information regarding conservative surgical options [85]. The oldest are the RENAL [61] and PADUA [86] but over the last 10 years, 16 other classifications have been described [87]. The majority of available studies are retrospective. The predictive values of the RENAL and PADUA scores are superior when they are used for categorization, particularly for estimating the risk of overall or major perioperative complications and the duration of renal ischemia. The principal benefit of these scores is that they offer an objective classification of tumor characteristics, facilitating the comparison of scientific literature.

2.4. What biological tests are carried out?

2.4.1. Standard biological work-up

The standard biological work-up for a localized renal tumor should include:

- serum creatinine measurement with GFR calculation;
- blood count.

In the case of metastatic cancer, the following additional tests should be conducted:

- liver function tests (AST, ALT, PAL, total and conjugated bilirubin);
- full ionogram, including phosphorus and magnesium levels;
- protein and albumin levels;
- lipasemia;
- calcemia with calculation of corrected calcemia;
- endocrine assessment (necessary before immunotherapy): cortisolemia, ACTH, TSH, T4;
- serologies (required before immunotherapy): HIV, hepatitis B, and hepatitis C;
- alkaline phosphatases;
- LDH;
- urine dipstick \pm 24-hour proteinuria.

The aim of this assessment is to evaluate renal function, to determine the prognostic factors for IMDC [88] (in the metastatic setting), screen for possible paraneoplastic syndrome (anemia, polycythemia, hypercalcemia, cholestasis), monitor and screen for contraindications to immunotherapy [89,90].

2.4.2. Assessment of renal function

The reference technique for estimating glomerular filtration rate is the calculation of creatinine clearance using the Chronic Kidney Disease Epidemiology Collaboration 2009 (CKD EPI) equation. The CKD EPI equation is considered to outperform the Cockcroft/Gault and MDRD (Modification of Diet in Renal Disease) methods [91]. However, there are situations in which calculating creatinine clearance does not provide a reliable assessment of renal function: extreme situations of muscle mass (obesity, cachexia), inhibition of renal tubule secretion (trimethoprim and fenofibrate) and extra-renal elimination of creatinine by the microbiota (broad-spectrum antibiotic therapy). In the preoperative assessment, it is advisable to assess separate renal function by scintigraphy in cases of renal insufficiency or bilateral tumours [92]. Performing a DMSA renal scan allows the relative renal function of each kidney to be assessed, which may be important in the surgical strategy for renal preservation.

Recent work has demonstrated the reliability of the estimation of renal function by late-stage CT imaging with a good correlation with the standard method of measuring iohexol clearance [56].

3. Histological diagnosis

3.1. WHO 2022 classification

In the latest WHO classification (2022, 5th edition), malignant renal tumors in adults have been divided into six groups: clear cell tumors, papillary tumors, oncocytic and chromophobe tumors, collecting duct tumors, tumors with molecular alterations, and a group of new entities (Table 1) [93].

The group of clear cell tumors includes clear cell renal cell carcinoma, which remains the most frequent histological subtype, and multilocular cystic neoplasia of low malignant potential. The latter is a macrocystic tumor on imaging and histologically, with clusters of non-atypical clear cells measuring less than 1 mm in the cyst wall. This allows for differentiation from cystic clear cell renal cell carcinoma [94,95].

In the case of papillary renal cell carcinomas, the former subtypes 1 and 2 have been superseded by the ISUP nucleolar grade. In light of the ongoing clinical trials that include patients according to these two subtypes, it is recommended that subtypes 1 and 2 be retained until the completion of these trials. Moreover, in the context of a papillary carcinoma, particularly if it is of high grade, it is imperative to systematically rule out FH-deficient carcinoma through immunohistochemistry (which may be associated with hereditary leiomyomatosis, necessitating genetic counseling) and carcinoma with a

Table 1
WHO 2022 classification of adult renal tumors.

<p>Renal cell tumours</p> <p><u>Tumours with a clear cell component</u></p> <p>Clear cell carcinoma of the kidney</p> <p>Multilocular cystic neoplasia with low malignant potential</p> <p><u>Papillary tumours</u></p> <p>Papillary adenoma</p> <p>Papillary renal cell carcinoma</p> <p><u>Oncocytic and chromophobic tumours</u></p> <p>Oncocytoma</p> <p>Chromophobe cell carcinoma</p> <p>Other oncocytic cell tumours</p> <p><u>Collecting duct tumours</u></p> <p>Carcinoma of the collecting duct</p> <p><u>Other renal tumours</u></p> <p>Papillary clear cell tumour</p> <p>Tubular and mucinous spindle cell carcinoma</p> <p>Tubulocystic carcinoma</p> <p>Carcinoma associated with acquired cystic disease</p> <p>Solid and cystic eosinophilic cell carcinoma</p> <p>Renal cell carcinoma NOS</p> <p><u>Renal carcinomas with molecular alterations</u></p> <p>Carcinoma with TFE3 rearrangement</p> <p>Carcinoma with TFE3 alterations</p> <p>Mutated ELOC carcinoma (formerly TCEB1)</p> <p>Carcinoma fumarate hydratase/FH deficient</p> <p>Carcinoma linked to succinate dehydrogenase deficiency (SDHB)</p> <p>Rearranged ALK carcinoma</p> <p>SMARCB1-deficient medullary carcinoma</p>	<p>Metanephric tumours</p> <p>Metanephric adenoma</p> <p>Metanephric adenofibroma</p> <p>Metanephric stromal tumour</p> <p>Mixed epithelial and stromal tumours</p> <p>Mixed epithelial and stromal tumour</p> <p>Adult mesenchymal tumours</p> <p>Angiomyolipoma/pecoma</p> <p>Epithelioid angiomyolipoma</p> <p>Hemangioblastoma</p> <p>Juxta glomerular tumour</p> <p>Renomedullary interstitial tumour</p> <p>Embryonal tumours</p> <p>Nephroblastic tumours</p> <p>Nephrogenic remains</p> <p>Partially differentiated cystic nephroblastoma</p> <p>Nephroblastoma</p> <p>Rare tumours</p> <p>Germ cell tumours</p>
---	---

TFE3 translocation through immunohistochemistry and cytogenetic analysis in FISH [96].

The classification of kidney tumors that are still in the process of being dismembered corresponds to that of oncocytic cell tumors, which still includes oncocytoma and chromophobe carcinoma. However, new entities have emerged that are diagnosed based on histological analysis and immunohistochemical markings. These include low-grade oncocytic tumors (LOT), vacuolated eosinophilic tumors (formerly high-grade oncocytic tumor/HOT), and solid and cystic eosinophilic cell carcinoma. These tumors are typically indolent and may be associated with abnormalities in the mTOR pathway or mutations in the TSC1/TSC2 genes [97–99].

The diagnosis of certain histological subtypes of renal cell carcinoma now necessitates the performance of a molecular analysis. These are primarily carcinomas of the MITF family, namely renal cell carcinoma with TFE3 or TFE3 translocation and carcinoma with TFE3 amplification. These carcinomas must be considered in the differential diagnosis when a particular histology is observed, namely, a papillary and solid architecture with clear and eosinophilic cells. This is particularly relevant when the patient is younger than 40 years of age. Carcinomas with TFE3 amplification are the most aggressive, with a stage of at least pT3a at the time of diagnosis, and progress to metastases in more than two-thirds of cases. A diagnosis is made on the basis of immunohistochemical and, most notably, cytogenetic FISH analysis. The remaining histological subtypes associated with a specific molecular anomaly are mutated ELOC carcinoma (formerly mutated TCEB1), which presents as a carcinoma with a clear cell component separated by a leiomyomatous stroma with a mutation in the ELOC/TCEB1 gene, and in FISH cytogenetic analysis, a monosomy 8. The occurrence of SDHB-mutated or ALK-rearranged carcinomas is less frequent, as is that of medullary carcinoma, which is a highly aggressive neoplasm predominantly observed in individuals with sickle cell anemia. This particular carcinoma is distinguished by its deficiency in INI1/SMARCB1 [100–104].

The 2022 WHO classification has identified a group of tumors that are often associated with a favorable prognosis and which are characterized by the presence of a cystic component. These include tubulocystic carcinomas, carcinomas associated with acquired cystic disease, and solid and cystic eosinophilic cell carcinomas [93].

3.2. pTNM classification 2017

The Union for International Cancer Control (UICC) pTNM classification has remained unchanged since 2017. In 2019, the American Joint Committee on Cancer (AJCC) conducted a review of the classification, but the two systems remain identical (Table 2) [105–107].

In light of the advent of adjuvant immunotherapies, it is imperative that pathologists exercise caution to avoid overlooking a pT3a stage, regardless of whether it involves infiltration of hilar or perirenal fat, the

Table 2
AJCC/UICC pTNM classification 2017 of malignant tumours of the kidney, 8th edition.

AJCC/UICC (2017)	Status
Tumour (T)	
Tx	Tumour status cannot be defined
T1a	Tumour ≤ 4 cm located in the kidney
T1b	Tumour > 4 cm and ≤ 7 cm located in the kidney
T2a	Tumour located in the kidney > 7 to ≤ 10 cm
T2b	Tumour located in the kidney > 10 cm
T3a	Invasion of peri-renal adipose tissue and/or hilar adipose tissue but not Gerota's fascia and/or macroscopic thrombus in the renal vein or in one of its branches and/or infiltration of the pyelocaliceal cavities
T3b	Thrombus in the vena cava under the diaphragm
T3c	Tumour extending into the vena cava above the diaphragm or invading the muscular wall of the vena cava
T4	Tumour infiltrating beyond Gerota's fascia and/or contiguous invasion of the adrenal gland
Lymph node metastasis (N)	
Nx	No assessment of lymph node status
N0	No lymph node metastases
N1	Regional lymph node metastasis in a single lymph node
N2	Regional lymph node metastasis in more than one lymph node
Remote metastasis (M)	
Mx	No assessment of metastatic status
M0	No metastases
M1	Remote tissue metastasis

pyelocaliceal cavities, or a thrombus in the renal vein or one of its branches.

3.3. What should the pathology report include?

In the case of all kidney cancers, the conclusion of the pathology report must include all the information required for prognostic assessment and patient management. These items have been defined by the Société française de pathologie and the Institut national du cancer (<http://www.sfpathol.org/>; www.e-cancer.fr).

A typical conclusion for kidney cancer should include the following items [108]:

- type of surgery (partial or radical nephrectomy);
- laterality (right/left);
- histological subtype according to WHO 2022 classification;
- the size of the tumour at its largest diameter in cm. In the case of multiple tumours, enter the size of the largest tumour;
- ISUP nucleolar grade from 1 to 4;
- the presence or absence of a sarcomatoid component and assessment of its %;
- presence or absence of a rhabdoid component and assessment of its %;
- presence or absence of necrosis (focal vs. extensive);
- the presence or absence of microscopic vascular emboli;
- locoregional extension of the tumour according to the UICC/AJCC 2017 pTNM classification;
- the presence or absence of lymph node metastases;
- the quality of surgical margins in the case of lumpectomy/partial nephrectomy and at the level of the renal vein in the case of tumour thrombus;

Recommendation Table 5
Anatomopathology and oncogenetics.

- the appearance of the non-tumourous kidney and other associated lesions.

Recommendation Table 5

3.4. Histopronostic factors

The histopronostic factors for kidney cancer described in the WHO 2016 classification have been incorporated into the 2022 version. These include histological subtype (the most aggressive renal carcinomas being medullary carcinomas, collecting-tube carcinomas and clear-cell carcinomas), ISUP nucleolar grade, the presence of necrosis, especially when extensive (except in low-grade papillary carcinomas, formerly subtype 1), pTNM stage, the presence of vascular emboli and especially the presence of a sarcomatoid or rhabdoid component [93,109,110].

The ISUP nucleolar grade 4 sarcomatoid component is indicative of an epithelial-mesenchymal transition, even if it is only present in a minority of cases, in a manner analogous to the rhabdoid component. The presence of this factor in more than 10% of the tumor is associated with a poor prognosis. Furthermore, this factor is relevant in the context of therapeutic management, as it is associated with a diminished response to tyrosine kinase inhibitors and is postulated to be linked to a more favorable response to immunotherapies (Recommendation Table 5).

3.5. When should an oncogenetic consultation be requested?

In accordance with the 2020 recommendations of the INCA/Predir network, an oncogenetic consultation should be proposed if one or more of the following criteria are present (Recommendation Table 5).

Recommendations	Grade
The WHO 2022 and pTNM 2017 classifications should be used to describe a renal tumour.	High
The main histopronostic factors to be used to describe a kidney tumour are: - Histological subtype - The ISUP nucleolar grade - Tumour necrosis - The pTNM stage - The presence of vascular emboli - The presence of a sarcomatoid or rhabdoid component	High
A centralized review by an expert pathologist from the CARARE network should be proposed for kidney cancer: - kidney cancer in young patients < 40 years old - located outside the papilla, chromophobe and clear cells - metastatic non-clear cell	Low
An oncogenetic consultation should be offered to all patients with: - diagnosis before the age of 45 years - histological subtype other than clear cell - multiple and/or bilateral tumours - family history of kidney cancer - extra-renal manifestations suggesting a personal or family syndromic form	Low

The following criteria should be considered for the recommendation of an oncogenetic consultation:

- age of onset of renal tumor before 45 year for clear cell carcinomas;
- routinely, regardless of the patient's age, for all other histological subtypes;
- if the tumors are multiple and/or bilateral;
- if there is a family history of kidney cancer;
- if there are extrarenal manifestations suggestive of a personal or familial syndromic form (www.e-cancer.fr) [111–115].

3.6. When should I request a Carare proofreading?

The Carare network, which addresses the rare cancers of the adult kidney, was accredited by the Inca from 2013 to 2018. It is currently undergoing the reaccreditation process. The objective of this initiative is to facilitate a histopathological review of renal cell carcinomas occurring in young adults under the age of 40 years, rare renal cell carcinomas (all except clear cell, chromophobe, and papillary subtypes), and metastatic renal cell carcinomas, excluding clear cell carcinoma, through a national network of pathologists with expertise in kidney tumors. This network relies on the UroCCR network for patient data and on the national network of pathologists, which encompasses 16 professionals distributed across all regions of France. Since the conclusion of 2022, the Carare network has made available a virtual endoscopic retrograde cholangiopancreatography (eRCP) platform for any practitioner interested in discussing complex cases and/or the management of kidney cancer, whether surgical or oncological. These eRCPs are held every fortnight on Wednesdays at 5:30 p.m. and are led by two oncologists, two urologists who are members of the board of the Association Française d'Urologie (AFU) kidney cancer committee, and two pathologists, all of whom are experts in renal tumor pathology. Cases may be registered up to 24 hours prior to the scheduled eRCP date via the Pulsy website (carare@icans.eu). The dates of the eRCPs and the procedure for registering are available on the GETUG website (<https://recherche.unicancer.fr/fr/les-groupes-d-experts/groupe-detude-des-tumeurs-urogenitales-getug/>) and the Carare website (www.carare.fr) (Recommendation Table 5).

4. The role of biopsy

4.1. Technique

The biopsy can be performed under local anesthesia, on an outpatient basis, under ultrasound or CT scan guidance. The CCAFU recommends using a 16–18 G coaxial needle to avoid the risk of tumor spread, avoiding biopsies in necrotic areas and taking at least two samples.

It is recommended that antiaggregant and anticoagulant treatments be suspended and that a hemostasis and coagulation test be performed prior to the biopsy.

Cytopuncture is not effective and is no longer recommended [116].

Biopsies should be fixed in 4% buffered formaldehyde for histologic analysis, FISH, and genetic sequencing. Unfixed conditioning for freezing is recommended for pediatric renal tumors, but freezing is optional for adult renal tumors.

4.2. Diagnostic performance

In 2016, two systematic reviews of the literature assessed the performance of renal biopsy [116,117]:

- for the diagnosis of malignancy, sensitivity and specificity were > 95%;
- for the determination of the histologic subtype, the concordance between the biopsy and the surgical specimen was 90%.

Diagnosis of oncocytoma by biopsy is difficult. The concordance between the biopsy and the operative specimen when the biopsy concludes to a renal oncocytoma varies from 65% to 91% depending on

the series [118–120]. Discrepancies between biopsy and surgical specimen in the diagnosis of renal oncocytoma mainly concern other tumors in the oncocytic group (18% to 26% chromophobe carcinoma, hybrid tumour, HOT), more rarely clear cell carcinoma (3% to 13%) [118–121].

The performance of renal biopsy for nuclear grading ranged from 43% to 93%. For renal tumors <4 cm, grade concordance was 86% with a simplified high/low grade classification. In the majority of cases, the grade error was an underestimate compared to the surgical specimen [122,123].

The rate of non-contributory biopsies was heterogeneous, ranging from 10% to 20%. The main predictive factors for non-contributory biopsies were skin-to-tumor distance and tumor size [124].

In the case of non-contributory biopsy, a new biopsy was contributory in more than 90% of cases, with a diagnosis of malignancy in the majority of cases [125,126].

4.3. Complications

Complications are rare, occurring in only 2–5% of cases. According to the Clavien-Dindo classification, these complications are typically considered low grade [124,127]. The most common complication is hematoma, which occurs early in the post-biopsy period and usually does not require specific treatment [128].

Major complications requiring intervention (such as embolization, drainage of pneumothorax) occur in 0.4 to 2% of biopsies [116,124,129]. Therefore, clinical observation for at least one hour after biopsy is recommended. Tumor seeding in the path of biopsy is exceptional and may manifest late as recurrence in the path of puncture [130,131].

4.4. The role of biopsy in small tumors

For tumors ≤ 4 cm, the diagnostic contribution of biopsy is 90% [123,132]. Sensitivity and specificity for the diagnosis of malignancy are > 95%. The concordance is 96% for histologic subtype and 87% for grade [125]. Biopsy series for small renal masses report up to 30% benign pathology [133]. Tumor biopsy reduces the rate of surgery for benign tumors by up to 50%, usually to the benefit of active surveillance [127,134–143]. However, several surveys of urologists report that tumor biopsy is performed for less than 20% of localized kidney tumors [134,144–147]. Finally, performing a biopsy prior to partial nephrectomy does not appear to increase the technical difficulty of surgery or the risk of positive surgical margins or postoperative complications [148,149].

4.5. What are the indications?

The practice of biopsy varies widely in France. More and more questions are being asked about the “medico-legal” nature of biopsy, which could prevent a certain number of benign tumours from being removed [127,134–141].

The position of the CCAFU (expert opinion) is to recommend biopsy in the following situations (Recommendation Table 6, Fig. 1):

- prior to medical treatment in the absence of a histologic diagnosis;
- prior to focal treatment (radiofrequency, brachytherapy, or radiotherapy);
- before extended nephrectomy for localized tumor when partial nephrectomy is not considered feasible (cT1, cT2);
- before partial nephrectomy for tumors with high surgical complexity and risk of totalization;
- for single kidney and bilateral tumors;
- in cases of diagnostic uncertainty (lymphoma, metastasis of another cancer, urothelial carcinoma, sarcoma).

Recommendation Table 6
Recommendations for kidney biopsies.

Recommendations	Grade
It is recommended for renal biopsies: <ul style="list-style-type: none"> - Control of imaging guidance - Discontinue antiplatelet agents, anticoagulants, and coagulation testing. - Use of 16-18 G coaxial biopsy needles - At least two biopsies, avoiding necrotic areas 	Low
Renal biopsy is recommended in the following situations <ul style="list-style-type: none"> - Before medical treatment in the absence of a histologic diagnosis - Before focal treatment - Before extended nephrectomy for localized tumor when partial nephrectomy is not considered feasible (cT1, cT2) - Before partial nephrectomy for tumors with high surgical complexity and risk of totalization - For urgent indications, single kidney and bilateral tumors - In cases of diagnostic uncertainty (lymphoma, metastases from other cancers, urothelial carcinoma, sarcoma) 	High
Biopsy is not recommended: <ul style="list-style-type: none"> - If urothelial cancer is suspected - High risk of bleeding - Cystic tumor without solid component - Typical angiomyolipoma appearance 	Low

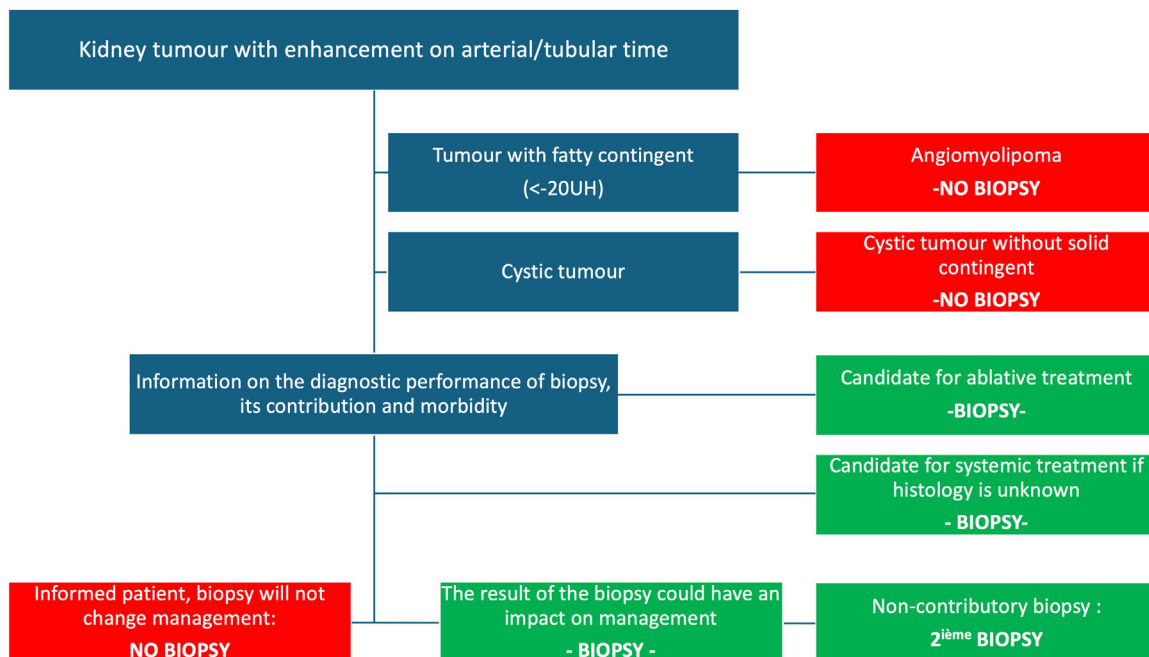


Fig. 1. CCAFU recommendations regarding the indication for kidney biopsies.

The position of the CCAFU (expert opinion) is not to propose biopsy in the following situations

- suspicion of urothelial carcinoma;
- high risk of bleeding;
- cystic tumor without solid component;
- typical angiomyolipoma appearance.

5. Treatment of small T1a kidney tumours (≤ 4 cm)

5.1. Place of partial nephrectomy (PN)

5.1.1. Interest and objectives

PN is the surgical technique of choice for small renal masses. It must meet three imperatives: oncologic control, preservation of renal function and limitation of perioperative complications (Recommendation Table 7).

5.1.2. Oncology monitoring

Several studies have demonstrated equivalent oncological control in the case of PN or radical nephrectomy (RN) [150,151]. After NP for a T1a tumour, 5-year recurrence-free survival is >95% [152,153]. A positive surgical margin increases the risk of local recurrence but does not appear to have any impact on specific survival [154,155]. In the case of a positive surgical margin, simple surveillance with regular imaging examinations is recommended. Immediate totalization by nephrectomy is not necessary [156,157]. In the case of an aggressive high-grade tumour and/or a large positive margin, totalization may be discussed at the multidisciplinary consultation meeting (RCP). Treatment of local recurrence has been little evaluated. Enlarged nephrectomy, a second partial nephrectomy or ablative treatment may be used depending on the time to recurrence, histological type and grade [157,158]. The UroCCR RePart study, published in 2022, reports on the value of ablatothermies for the treatment of local recurrence after PN. Compared with surgical salvage treatment, these percutaneous techniques allow better preservation of renal function and less morbidity [159].

5.1.3. Preserving renal function

PN allows optimal preservation of the renal parenchyma, which limits the deterioration of renal function [160]. This functional preservation reduces the risk of cardiovascular events and could increase overall survival compared with RN [161–163]. Renal preservation is also associated with a positive psychological impact and a better quality of life [164].

Recommendation Table 7

Recommendations for surgery on small kidney tumours.

5.1.3.1. Duration of ischemia. The effect of the duration of ischemia on the decline in renal function is controversial. Renal ischemia may be more detrimental in patients with pre-existing renal insufficiency [165]. Data in the literature are conflicting, but it is advisable to limit the duration of renal pedicle clamping to less than 25 minutes [166–168]. Techniques without clamping or with selective clamping reduce the risk of deterioration in early postoperative renal function but have not been shown to result in better long-term renal preservation compared with total clamping < 25 minutes [169–173].

5.1.3.2. The renorrhaphy technique. Few studies have evaluated the different reconstructive techniques, but some authors suggest that “sutureless” techniques may result in a smaller reduction in GFR in the immediate postoperative period, without demonstrating any difference in terms of GFR in the late postoperative period, morbidity or oncological outcome [174,175].

5.1.3.3. Preservation of parenchymal volume. Preservation of healthy renal parenchyma appears to be the most important factor in maintaining renal function [166,168,176]. Tumour enucleation techniques preserving a minimal margin of healthy tissue do not appear to increase the rate of local recurrence, but their contribution to preserving renal function is uncertain [177,178].

5.1.4. Morbidity

There is a significant morbidity associated with PN, which has been reported in the literature to be approximately 20%. The two most feared complications are secondary hemorrhage (false aneurysm) and urinary fistula [179]. The rate of serious complications after NP can be as high as 11%. The risk of complications is influenced by a number of factors: tumour complexity, age, co-morbidities, surgeon’s experience, size of center, approach [180–182]. The prospective UroCCR study RoPAN [183] published in 2023 assesses late complications after robotic-assisted PN. Approximately 10% of patients are affected in the first year following surgery. These are mainly vascular, infectious and parietal complications occurring during the first 3 months.

5.1.5. Technique: open route vs. laparoscopy vs. robot-assisted laparoscopy

Regardless of the approach (open vs. laparoscopic vs. robotic-assisted) for PN, there is no difference in terms of specific survival and overall survival [184,185].

Recommendations	Grade
Partial nephrectomy is the recommended first-line surgical treatment for T1a tumours.	High
The use of a minimally invasive approach (laparoscopic with or without robotic assistance) is less morbid and should be preferred when performing partial or total nephrectomy for localized tumours.	High
Transperitoneal or retroperitoneal routes for partial nephrectomy are equivalent in terms of morbidity, rate of positive surgical margins and renal function.	Low
Close monitoring is recommended in the case of positive surgical margins	Low
A radical nephrectomy may be proposed for a small renal mass if: - non-functioning kidney - suspected T3a tumour - complexity deemed too high after confirmation of a second opinion from an expert center - confirmed histological diagnosis of malignant tumour by biopsy	High

Compared with the open approach, laparoscopy reduces blood loss and length of stay. On the other hand, operating and ischemia times are longer. Postoperative complications and long-term renal function are similar [185–187]. Some teams propose preoperative embolization of tumors to facilitate surgery and reduce postoperative complications [188]. Compared with the open approach, robot-assisted laparoscopy appears superior in terms of blood loss, length of stay, complications and duration of ischemia. The rate of positive margins and residual renal function are similar [189–191]. This reduction in morbidity makes it possible to offer outpatient management for selected patients [192,193]. Compared with the laparoscopic approach, the robot-assisted approach has an advantage in terms of the duration of ischemia and conversion to the open approach [184,194]. There is also an advantage in terms of the rate of conversion to RN, particularly for complex and hilar tumours [185,195].

Robotic assistance coupled with three-dimensional modelling techniques is enabling the development of image-guided surgery, and its value is currently being evaluated. A French study (UroCCR-51) reported an overall improvement in the surgical procedure (trifecta) [196].

5.1.6. *Transperitoneal vs. retroperitoneal laparoscopic approach*

A prospective multicenter observational study showed no significant difference between transperitoneal NP and retroperitoneal NP in terms of postoperative complications, positive surgical margins and functional outcomes (GFR). Shorter operative time and less frequent intraoperative complications favored the transperitoneal approach [197].

5.1.7. *The center effect in France*

A prospective study carried out in France in 2010 in hospital, university and private practice institutions suggested a center effect of PN, with an increase in morbidity and the rate of positive margins in centers with a smaller volume [198]. A CCAFU study also demonstrated better results in high-volume centers for robotic PN [199]. Although it seems difficult to make recommendations on a possible threshold, the CCAFU encourages teams to organize themselves in such a way that the PN activity is concentrated on a few expert surgeons according to the volume of activity.

5.2. *Place of radical nephrectomy (RN)*

5.2.1. *Interest and objectives*

RN is not recommended as a first-line treatment for small kidney tumours. It may be proposed in cases of non-functioning kidney, suspected locally advanced tumour (T3a) or significant complexity. If the

tumour is deemed too complex, it is advisable to seek the advice of an expert center before undergoing RN.

5.2.2. *Technique: open route vs. laparoscopy vs. robot-assisted laparoscopy*

The oncological results of the different approaches are equivalent [200,201]. Laparoscopy is associated with a shorter hospital stay, a reduction in the use of analgesics and a reduction in operative bleeding [202]. Transperitoneal or retroperitoneal laparoscopic approaches have equivalent oncological results and quality of life [203]. Very few studies have compared the robot-assisted technique with standard laparoscopy, whose results appear to be equivalent [204].

5.3. *Place of ablative therapies (AT)*

5.3.1. *Technique and results*

Small renal tumors can be treated with ablative therapies (AT). A biopsy of the lesion is required beforehand. There are several different AT techniques:

- radiofrequency and microwaves;
- cryotherapy;
- irreversible electroporation.

AT may be offered as an option to patients whose tumor can be treated completely. The long-term technical and functional results of TA are good [205–207]. There are no randomized studies comparing TA vs. PN and the published retrospective studies have numerous biases [208]. Several retrospective studies nevertheless suggest inferior local oncological control after TA compared with PN [206,209,210]. TA seems to allow better preservation of renal function compared with PN [211–214] as well as lower overall or major complication rates for TA compared with PN [215–217].

5.3.2. *How do AT relate to NP?*

There are no randomized studies comparing the two techniques. All the recommendations are based on retrospective studies with numerous methodological biases. A meta-analysis of 26 studies and 11 systematic reviews was published by the EAU Kidney Cancer Recommendations Group [208]. It concludes that the level of evidence regarding AT is very low, with current data not allowing conclusions to be drawn regarding its clinical efficacy compared with PN, and that it is therefore difficult in this context to establish recommendations. The CCAFU recommends that patients be informed that TA offers good oncological results, even if they appear to be inferior to those of PN, but that the long-term data are still uncertain (Table of recommendations 8).

Recommendation Table 8

Indications for ablative treatments for localized tumours.

Recommendations	Grade
The validated indications for ablative treatment are: - Small renal tumors less than 3 cm in size for which partial nephrectomy appears to be associated with excessive morbidity - local recurrence following partial nephrectomy	Low
Indications to be discussed when ablative treatment is required are: - localized tumor larger than 3 cm - cystic tumor - tumor on kidney transplant	Low
Biopsy of the renal mass must be performed prior to ablative treatment and not concurrently (in the absence of prior histologic diagnosis).	Low

5.4. Place of ablative stereotactic radiotherapy

Ablative stereotactic radiotherapy has been evaluated as a therapeutic option in patients with cT1a and cT1b tumours who are inoperable or whose surgery is considered at high risk of complications [218,219]. It has the advantage of being non-invasive and not requiring anesthesia.

There is no consensus on the optimal dose and number of fractions, with delivery methods varying according to the series (26–60 Gy in 1, 3 or 5 fractions) [218–221]. However, the IROCK (International Radiosurgery Oncology Consortium for Kidney) recommendations suggest doses of 25 to 26 Gy in a single fraction for tumours smaller than 4 cm [222].

Several retrospective observational studies, mainly including cT1 tumours, with median follow-up between 16 and 34 months, report local controls between 90 and 97.2% and prolonged survival [218–220,223–226]. The prospective observational FASTRACK II study evaluated the oncological results of stereotactic radiotherapy in 77 inoperable patients with glomerular function > 30 mL/min, with localized kidney tumours of less than 10 cm, 23 of whom had tumours of less than 4 cm without contact with the intestine (organ at risk). The recommended dose was 26 Gy in one fraction for tumours smaller than 4 cm and 42 Gy in 3 fractions for larger tumours. The median age of the patients included was 77 years. Oncological results at 48 months' follow-up showed a local control rate of 100%. The rate of grade 3 toxicities in this study was 10%, mainly pain and nausea/vomiting [227]. The impact on renal function appears to be moderate, with a decrease in GFR estimated at between 5 and 17 mL/min in the years following radiotherapy and stabilization of the loss of renal function after 2 years of follow-up [221,228]. After stereotactic radiotherapy, toxicities appear moderate overall, mainly grade 1 (fatigue, nausea, chest or back pain, diarrhea or gastritis) with 0 to 9% grade 3–4 [218,219,221]. This treatment modality therefore appears to be of interest for frail patients with co-morbidities or on anticoagulants in whom a more invasive treatment (surgery or TA) would be contraindicated [229].

However, more evidence from prospective studies with longer follow-up is still needed to validate this indication in elective situations. Finally, the definition of response to stereotactic radiotherapy needs to be better codified.

Recommendation Table 9

5.5. The role of active surveillance

Active surveillance (AS) is defined as the monitoring of a patient with a small kidney tumour through repeated clinical and imaging examinations (ultrasound, CT or MRI). Patients may be taken off active surveillance, and treatment may therefore be proposed, in the event of clinical progression (increase in volume or tumour becoming symptomatic). This must be distinguished from abstention/surveillance, which consists of clinical surveillance alone in patients with a limited life expectancy or who cannot be operated on because of their comorbidities, with the aim of exclusive symptomatic treatment. AS series report slow and predominantly linear growth of kidney tumours with mean tumour growths varying between 0.09 and 0.37 cm per year [230–233]. There does not appear to be any difference in tumour growth rate between benign and malignant tumours [231]. One series reported faster growth in clear cell carcinomas compared with type 1 tubulopapillary carcinomas (0.25 vs. 0.02 cm/year; $P < 0.001$) but this should be interpreted with caution due to the small number of type 1 papillary carcinoma included

Recommendation Table 9

Place of stereotactic radiotherapy in the treatment of localized kidney tumours.

Recommendations	Grade
Ablative stereotactic radiotherapy is a treatment option to be discussed for patients with unresectable cT1a and cT1b tumors who are not candidates for ablative treatments.	High

and the wide variability in growth rate [234]. In the main series of small tumours observed, 20 to 30% of tumours did not progress and 10 to 20% of tumours grew rapidly at a rate of more than 0.5 cm/year. The majority of studies included both solid and cystic tumours. It has also been described that the growth rate of small renal masses was faster past the threshold of 3 cm largest diameter [235].

The occurrence of metastatic progression in patients under surveillance for a tumour of less than 4 cm varies from 0 to 6% (up to 7 years of follow-up) [231,233,235–239]. In the vast majority of cases, patients under surveillance had not had a biopsy. High tumour size and rapid growth rate have been found to be associated with an increased risk of local and metastatic progression [235].

The main multicenter DISSRM registry studied the feasibility of AS for tumours ≤ 4 cm and reported similar overall (92% vs. 75%; $P = 0.06$) and specific (99% vs. 100%; $P = 0.3$) survival at 7 years between patients treated upfront (with NP or TA) and those initially monitored [240]. The update of these data at 7 years confirms the feasibility of AS with similar specific survival between PN and AS. In this series, preservation of renal function was superior in patients undergoing AS and psychological tolerance was identical in the 3 groups (PN, TA, AS) [238].

In terms of quality of life, AS was associated with poorer physical health (although these patients were older and more comorbid at the time of inclusion) and greater anxiety than patients managed with immediate intervention (surgery or ablative treatment) [241–243].

Although AS was initially reserved for elderly patients or patients with co-morbidity, recent data suggest that this management is also safe in younger patients. Data from the DISSRM registry showed that there was no difference in cancer-specific survival and overall survival between patients aged under 60 managed with definitive therapy ($n = 156$) or AS ($n = 68$). The rate of progression to definitive treatment was lower in patients with tumours less than 2 cm than in those with tumours 2–4 cm (15.1% versus 33.3%) [237].

Follow-up procedures in the different active surveillance cohorts were heterogeneous, both in terms of the type of imaging (MRI, CT, ultrasound) and the frequency of follow-up. Tumour biopsy at inclusion was not systematic. Finally, there was no consensus on thoracic imaging. In the studies, patients were followed up with abdominal imaging every 3 to 6 months for the first year, then every 6 to 12 months if the lesion remained stable. Chest imaging was offered at inclusion and annually.

Biopsy is not compulsory in order to propose AS, but should be considered when the result may alter the patient's management (see chapter 4 – The role of biopsy).

Based on data from historical prospective observational studies, it has been suggested that AS should be discontinued and treatment offered in the event of a growth rate greater than 0.5 cm per year, a symptomatic patient or a tumour size greater than 4 cm (Recommendation Table 10).

5.6. Choice of treatment

The choice of treatment for small tumours offered to patients depends mainly on their life expectancy and the size of the tumour. In patients with limited life expectancy, simple, clinically based surveillance may be proposed. For tumours less than 2 cm in size, active surveillance with deferred treatment if necessary is the preferred treatment option, particularly for elderly patients with numerous co-morbidities. For tumours larger than 3 cm, the gold standard remains partial nephrectomy (Fig. 2).

6. Treatment of localized kidney tumours > 4 cm

6.1. Place of partial nephrectomy (PN)

For cT1b tumors, PN is non-inferior in terms of specific survival to RN [150,162,244–246]. There is only one prospective study, which was stopped early, showing non-inferiority of PN versus RN for localized tumors less than 5 cm [151].

Recommendation Table 10
Monitoring of small kidney tumours.

Recommendations	Grade
Active surveillance is the preferred strategy for small kidney tumours < 2 cm, given their low growth rate and the low probability of aggressive histology.	Low
Active surveillance may be offered as an option to patients with a small kidney tumour measuring 2 to 4 cm.	Low
A tumour size greater than 4 cm or annual tumour growth of more than 0.5 cm/year means that the patient must be withdrawn from active surveillance.	Low
Simple abstention from monitoring can be proposed to elderly patients with small renal masses and with co-morbidities and/or limited life expectancy.	Low

For cT2 tumors, the level of evidence from studies concerning optimal surgical treatment is very limited. Retrospective studies comparing PN and RN show a trend in favor of PN in terms of survival and functional results, but with higher blood loss and higher complication rates [245,247,248]. A recent multicenter study demonstrated a benefit of PN vs. RN in terms of specific and overall survival with a median follow-up of 102 months [249].

For pT3a tumors, three retrospective studies reported on the follow-up of patients with tumors initially cT1 and cT2 requalified as pT3a on postoperative pathological analysis. The results were divergent with two studies showing comparable oncological results between PN and RN [250,251]. A third study showed that a pT3a stage after PN was associated with shorter recurrence-free survival [252]. A recent meta-analysis including 1278 patients in the PN group and 2113 patients in the RN group with a pT3a tumor showed no specific difference in survival between the two treatments [253].

The complexity of the tumor can be assessed using morphometric scores (RENAL score, PADUA score, C-Index, etc.). These scores could be useful in predicting renal function impairment and prognosis in the case of tumors > 7 cm [254–256]. An increase in tumor size and complexity is associated with an increased risk of pT3a tumors and local recurrence [251,252,257].

The robot-assisted laparoscopic approach appears to reduce the morbidity of PN for tumors > 4 cm. It is associated with less bleeding, fewer complications and a shorter hospital stay than open surgery [258,259] and less surgical conversion, less warm ischemia and less impairment of renal function than standard laparoscopy [194,260]. Perioperative morbidity remains comparable to that of RN in expert centers [258,259,261].

6.2. Place of radial nephrectomy (RN)

6.2.1. Laparoscopic radical nephrectomy

No randomized controlled trial has compared the oncologic outcomes of laparoscopic RN versus open RN. A retrospective comparative study showed an advantage in terms of overall survival in the minimally invasive RN group compared with the open approach, as well as in terms of length of hospital stay, readmission rate and mortality at 30 and 90 days [262]. Retrospective systematic reviews and a prospective non-randomized study have shown comparable oncologic outcomes even in locally advanced tumors [202,204,263] with lower morbidity and shorter hospital stays [164,201,263,264].

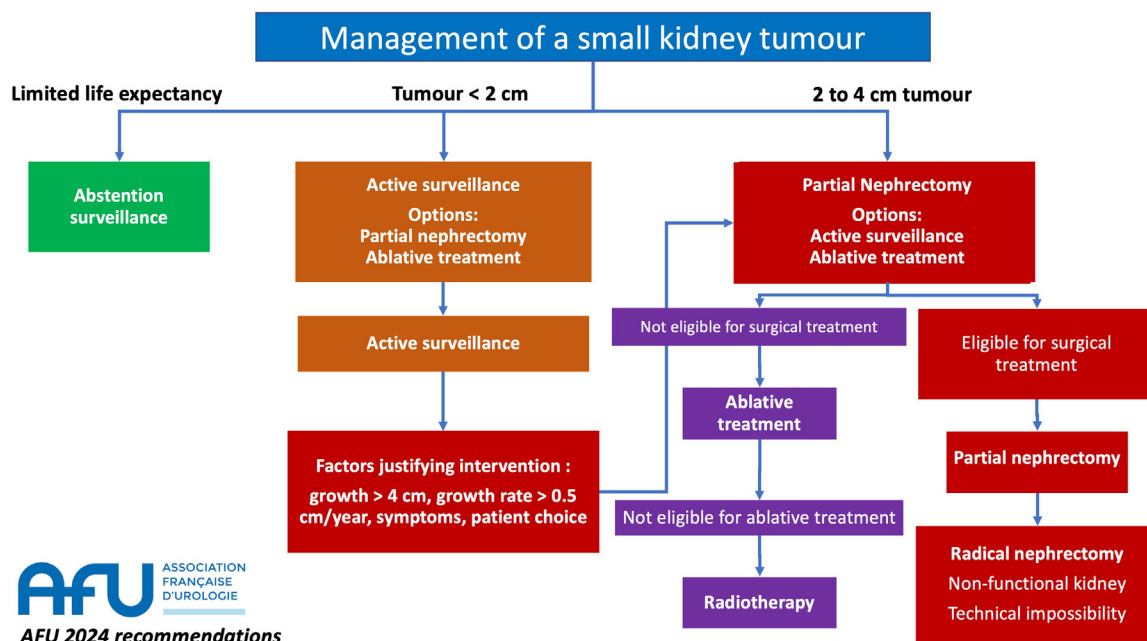


Fig. 2. CCAFU recommendations for the treatment of small kidney tumors.

6.2.2. Robot-assisted laparoscopic radical nephrectomy

In a meta-analysis including 1832 patients, robot-assisted RN was non-inferior to standard laparoscopy in terms of perioperative results and complications [265]. Other retrospective studies have confirmed oncological results comparable to other approaches [266,267] but with a significant additional cost [268].

6.2.3. Adrenalectomy for cT1b-cT2 cN0 tumors

A single prospective non-randomized study compared RN with or without ipsilateral adrenalectomy. Location at the upper pole of the tumor was not predictive of adrenal invasion. There was no significant difference in overall survival at 10 years [269]. It is not necessary to perform an adrenalectomy except in the case of contiguous invasion detected during the operation or an abnormality suggestive of a secondary lesion on preoperative imaging [269,270].

6.2.4. Lymphadenectomy for cT1b-cT2 cN0 tumors

The indications and surgical limits of lymph node dissection associated with RN remain controversial [270–272]. A large retrospective multicenter study published in 2018 analyzed data from 2722 patients. Lymphadenectomy combined with RN did not improve oncological outcomes in terms of progression-free, specific and overall survival [273]. A retrospective analysis of the SEER (Surveillance, Epidemiology and End Results) database of more than 9000 patients showed no effect of extended lymphadenectomy (eLND) on specific survival in cN0 [274]. Only one randomized study evaluating the clinical benefit of lymphadenectomy associated with surgical treatment of a kidney tumor has been published. This EORTC study did not show any benefit of lymph node dissection for cN0 patients and concluded that it was of interest only for staging [275]. In a meta-analysis of 1983 patients, the value of lymph node dissection was demonstrated in terms of specific survival in tumors

with poor prognostic factors such as the presence of sarcomatoid variants or a large tumor volume, without increasing the morbidity of RN [271].

6.3. Embolization of cT2 tumours

There is no benefit in performing renal artery embolization before RN [276]. Embolization may be discussed in the event of symptoms (hematuria, pain) in patients not eligible for surgery [277].

6.4. Use of thermo-ablative techniques (TA)

Several retrospective studies have reported the results of TA for tumours larger than 4 cm, with short follow-up times and inconsistent results in terms of morbidity and oncological control [209,213,278–282]. An analysis of 5763 patients from the SEER database showed a specific mortality risk multiplied by 2.5 compared with RN for cT1b treated with AT [210].

6.5. Place of ablative stereotactic radiotherapy

Some studies suggest that cT1b lesions can be treated effectively with stereotactic radiotherapy. A retrospective study by the IROCK consortium including 95 patients treated with stereotactic radiotherapy for cT1b renal cell carcinomas with a median follow-up of 2.7 years showed a 2.9% failure of local control and a 4-year progression-free survival of 64.9%, with no grade ≥ 3 toxicities reported [283]. In the prospective observational FASTRACK II study, 47 inoperable patients had localized tumours greater than 4 cm and less than 10 cm. In these patients, local control (assessed radiologically by tumour size) was 100% with a median follow-up of 48 months [227]. The treatment modalities recommended by the consortium for tumours > 4 cm are 35 to 45 Gy in 3 fractions or 40 to 50 Gy in 5 fractions [221,222,228] (Recommendation Table 11).

Recommendation Table 11

Treatment of cT1b and cT2 kidney tumours.

Recommendations	Grade
Partial nephrectomy should be proposed for cT1b-T2 tumours when feasible.	High
Radical nephrectomy is recommended for localized cT1b-T2 tumours for which partial nephrectomy is not technically feasible or in the case of a non-functioning kidney.	High
Laparoscopy is less morbid than the open approach and should be preferred for radical nephrectomy of a cT1b-T2 tumour.	High
Partial nephrectomy should be offered to patients with a cT2 tumour and an imperative indication (single kidney, renal failure), if technically feasible.	High
Adrenalectomy is not recommended in cases of radical nephrectomy for a cT1b-T2 tumour in the absence of radiological and/or intraoperative signs of invasion.	High
Systematic lymph node dissection is not recommended in the case of nephrectomy for a cT1b-T2 cN0 tumour.	High
Ablative therapies are not recommended for the treatment of cT1b-T2 tumors, but may be considered on a case-by-case basis in centers of expertise.	High
Stereotactic radiotherapy is not recommended for the treatment of cT1b-T2 tumors but may be considered on a case-by-case basis in centers of expertise.	High
Renal artery embolization may be proposed in symptomatic inoperable patients to control symptoms.	Low

7. Treatment of locally advanced kidney cancer

7.1. Definition of locally advanced kidney cancer

Locally advanced kidney cancers are those that are neither intracapsular (pT1, pT2) nor metastatic (M1). This definition does not formally include a tumour size criterion. Recent surgical series report 4–15% reclassification of localized tumours \leq cT2 to pT3a by definitive histology [284–286]. This restaging \geq pT3a was associated with unfavorable oncological outcomes in terms of recurrence and overall survival compared with tumours \leq pT2 [284–286]. Within the pT3a group, there appear to be prognostic differences with a worse prognosis from invasion of the renal vein or a segmental branch, versus invasion of sinus fat or perirenal fat, which appear to have the same prognostic value [287]. Contemporary series of tumours associated with a venous thrombus (T3b and T3c) confirm the prognostic value of the TNM classification with a prognosis significantly correlated with the infra versus supra-diaphragmatic level of the tumour thrombus [288,289].

7.2. The principles of extended nephrectomy

7.2.1. Technique: open versus laparoscopic and robot-assisted laparoscopic approach

Surgery in this situation is intended as a curative treatment. The main objective, whatever the technique, is to obtain negative surgical margins [290]. The standard approach for locally advanced kidney tumors is the open approach. Several series report the feasibility of the laparoscopic or robotic-assisted laparoscopic approach with favorable perioperative results in selected cases. The minimally invasive approach is possible provided that healthy excision margins can be obtained [291–293].

7.2.2. Benefits and indications of lymph node dissection

The value of lymph node dissection during nephrectomy was evaluated in a prospective randomized phase III trial. The lymph node dissection performed in this study was “extensive” (from the diaphragm to the aortic bifurcation, periaortic on the left, latero-caval + pre-caval + inter-aortic-caval on the right). This trial did not demonstrate any oncological benefit from systematic lymphadenectomy. In the absence of adenomegaly seen on preoperative CT or peroperatively, the risk of microscopic lymph node involvement was 4%. A limitation of this study is that it only included 28 and 30% of locally advanced T3–T4 [294]. Even in series of kidney tumours at high risk of recurrence, the rate of pN+ is 4 to 6% [294–297]. Finally, in cN+ patients, up to 58% of reactive hyperplasia without tumour invasion has been reported, particularly in cases of large tumours, tumour necrosis and/or tumour thrombus [298].

Lymph node dissection is recommended in the case of palpable lymph nodes or lymph nodes identified on preoperative imaging [299,300]. In the absence of identified lymph nodes, the usefulness for oncology or tumour stage assessment has not been demonstrated. In the case of lymph node involvement, the survival rate after nephrectomy is 10 to 45% at 5 years, and lymph node dissection is essentially considered to have a staging role [297,300].

7.3. What role do neoadjuvant treatments play?

In the neoadjuvant setting, primary tumor responses of 9 to 28% have been observed with targeted anti-angiogenic therapy and tumor volume reductions of up to 35% with immunotherapy [301–307]. In the case of tumor cave thrombus, preoperative systemic treatment is associated with a reduction in thrombus height of up to 35% [308,309].

To date, a neoadjuvant strategy can only be considered in the context of clinical trials or discussed on a case-by-case basis in the tumor setting [310]. The level of evidence is low, the impact on surgical technique

appears to be limited, and the oncologic benefit has not been demonstrated [311].

7.4. Special situations

7.4.1. In the event of invasion of adjacent organs

Invasion of adjacent organs is difficult to predict [312]. Many cT4 patients are over-staged and may benefit from surgical resection. Survival at this stage is less than 10% at 5 years, and the existence of negative margins is an important prognostic factor [313–315].

7.4.2. Tumour thrombus in the vena cava

At present, excision surgery is the reference treatment for kidney tumours with thrombus, whatever the level of thrombus, subject to the following conditions: the tumour and thrombus are technically resectable within a healthy margin and the extension work-up is unequivocal (cM0) [316,317]. Involvement of cN+ lymph nodes on extension is not necessarily contraindicate surgery [316]. In fact, up to 50% of kidney tumours staged as cN+ turn out to be pN0, tumour necrosis and the presence of a venous thrombus being precisely the factors associated with reactive lymph node hyperplasia without tumour invasion [298].

7.4.2.1. Preoperative assessment. It should be remembered that no metabolic imaging is recommended in the preoperative work-up for nephrectomy, even in the case of a tumor associated with a venous thrombus [316]. Finally, no strategy involving systemic treatment prior to surgery, whether a TKI alone, immunotherapy or a combination of immunotherapy and TKIs, has been shown to have a significant and reproducible impact on reducing the stage of thrombus, facilitating surgery or improving oncological prognosis [316,318,319].

The operability assessment may also be an obstacle to surgery, particularly for the most fragile patients, as thrombus surgery is associated with a mortality rate >90 days of up to 20% and a complication rate that increases with the level of thrombus [320]. The operability assessment must be adapted to the expected difficulty of the surgery and the type of clamping of the IVC: for the simplest cases of level I thrombus, partial or total but brief clamping of the juxta-renal inferior vena cava is sufficient; clamping of the hepatic hilum and the supra-hepatic veins is necessary for the most complex cases of level 3 to 4 thrombus, or even in certain cases of level 4, beating heart surgery and extra-corporeal circulation. In the case of high-level thrombi, the presence of a disturbance in the liver balance should raise the possibility of Budd-Chiari syndrome or obstruction of the suprahepatic veins [320].

7.4.2.2. Surgical technique. The surgical technique is determined by the upper level of the thrombus and the risk of invasion of the IVC wall. In most cases, infiltration of the vena cava and adhesion of the thrombus can only be suspected preoperatively. Only the presence of a tumor signal crossing the vena cava on MRI can formally confirm the presence of an adherent thrombus, which requires removal or even prosthetic replacement of the IVC [321–323]. Computed tomography with injection and MRI have a similar overall diagnostic performance with regard to the risk of invasion of the vena cava wall, and the radiological signs most often taken into account are: maximum thrombus diameter >4 cm and thrombus diameter at the ostium of the renal vein [324]. New dynamic imaging techniques can be used to assess thrombus adhesion to the vena cava, but these are currently being evaluated. The presence of fibrin-cruciate thrombosis of the IVC beneath the thrombus or in the iliac vessels and thrombus invasion of the lumbar veins are factors associated with poor prognosis in oncology.

The initiation of anticoagulation at the time of diagnosis and until surgery is controversial. The benefits of preventive versus curative anticoagulation are currently being studied. In the situation of locally advanced renal tumor with venous thrombus, preventive anticoagulation seems to be a reasonable compromise (expert opinion).

Surgery for vena cava thrombosis is an oncologic emergency, and the progression of the thrombus level is a major concern in surgical planning, especially for high-grade thrombi. Therefore, it is recommended that the thrombus level be rechecked on imaging and that liver function tests be performed in the 24–48 hours prior to surgery. The occurrence of abnormal liver function tests indicates obstruction of the suprahepatic veins (or Budd-Chiari syndrome), which should prompt reconsideration of the indication for surgery, as there is a high risk of intraoperative and postoperative complications and positive margins [325]. In most cases, the thrombus level remains stable or progresses only slightly, and it is preferable to prioritize the safety of the surgical procedure over the delay before surgery.

Cava thrombus surgery, especially at high levels, is a multidisciplinary procedure (vascular, hepatic, and cardiothoracic surgery) that requires not only surgical skill, but also anesthesia expertise and an intensive care unit experienced in major surgery.

Open surgery is the recommended approach for the surgical treatment of cava thrombosis. The minimally invasive approach using robotic surgery has been reported in recent years, with evidence of a reduction in the risk of transfusion and overall complications, but with no significant difference in the occurrence of major complications [326–329].

7.4.2.3. Postoperative prognosis. In a contemporary French series, the median time to recurrence after nephrectomy for RCC associated with a tumour thrombus (304 renal vein thrombi [pT3a], 87 infra-diaphragmatic thrombi [pT3b], 18 supra-diaphragmatic thrombi [pT3c]) was 36 months for all stages combined [330]. The predictive factors for recurrence were: tumour necrosis (HR = 2.92), pN+ invasion (HR = 2.53) and tumour size > 10 cm (HR = 1.56); adjuvant treatment was a protective factor against recurrence (HR = 0.33) [330].

The Phase III trial (Keynote 564), which randomized a cohort of 994 nephrectomies for kidney tumours at high risk of recurrence to 1 year of adjuvant treatment with Pembrolizumab versus placebo, demonstrated a 37% reduction in the risk of recurrence and a significant benefit in overall survival (HR: 0.64; 95%CI [0.44–0.87]) [331,332]. The proposal of adjuvant treatment following nephrectomy for RCC with tumour thrombus has therefore become the standard approach, provided that the tumour contains at least one clear cell contingent (tubulo-papillary RCC are not eligible for adjuvant treatment) [331,332].

Finally, a recent retrospective study analyzed the distribution of histological subtypes in CRC with tumour thrombus: 89% clear cell, 7% papillary, 4% chromophobe, and highlighted the prognostic value of the histological subtype, with a more unfavorable oncological outcome in papillary RCC compared with clear cell RCC, while the prognosis for

chromophobe RC seemed more favorable [333] (Table of recommendations 12).

8. Specific clinical situations

8.1. Tumours in an imperative situation

Imperative situations are those where radical nephrectomies would entail a high risk of end-stage renal failure or permanent dialysis: anatomically or functionally unique kidney, bilateral renal tumour, pre-existing renal insufficiency. In this context, partial nephrectomy is the standard treatment. It is recommended that a biopsy be performed prior to any therapeutic decision (Recommendation Table 13).

Retrospective studies suggest that in imperative situations, PN and TA preserve renal function in identical fashion. On the other hand, there is a higher risk of recurrence with TA [334]. A CCAFU study published in 2017 and including 284 patients compared 172 NP with 112 TA in the imperative situation [335]. Recurrence-free survival was better in the PN group despite larger and more complex tumours. On the other hand, morbidity was lower in TA: fewer transfusions, shorter hospital stays and fewer complications despite higher comorbidities.

It is unlikely that randomized studies comparing the two techniques will ever be available. In these imperative situations, NP remains the reference treatment when it is technically feasible. The UroCCR-54 study reported the feasibility of the laparoscopic approach with robotic assistance, in the case of a single kidney, with results equivalent to those of the open approach [336]. In order to maintain optimal renal function, the healthy parenchyma must be preserved as much as possible and ischemia must be limited by early de-clamping or by using ischemia-sparing techniques (no clamping or supra-selective clamping) [337–341]. Given the complexity of these situations, it is advisable to refer these patients to an expert center.

8.2. Tumours on renal transplants and native kidneys in chronic renal failure patients

Recommendations have been made by the Transplantation Committee of the French Association of Urology (CTAFU) on this specific subject [342]. Tumours in renal transplants are rare, with a prevalence of between 0.2% and 0.5% [343–345]. These tumours are mostly discovered at a localized stage (T1a) because of the regular monitoring of renal transplant patients by ultrasound-doppler [343,346]. These tumours may be multifocal or bilateral [347,348]. Clear cell renal cell carcinoma is the most common histological type [343,349]. In the case of a non-functioning graft, the lesion tends to be papillary [350]. The management

Recommendation Table 12

Recommendations for the treatment of locally advanced tumours.

Recommendations	Grade
In the case of locally advanced tumours, extended radical nephrectomy is recommended if technically feasible with the aim of achieving healthy margins.	High
In the case of locally advanced tumours, the therapeutic value of systematic lymph node dissection is uncertain. It is recommended in the case of suspicious lymph nodes identified on preoperative or intraoperative imaging.	Low
In the case of tumours with venous thrombus, extended radical nephrectomy combined with surgical thrombectomy is recommended for M0 patients in good general condition.	High
No neoadjuvant treatment can be proposed outside of clinical trials.	High
For carcinomas with a pT3-4 clear cell component, adjuvant treatment with pembrolizumab is recommended.	High

Recommendation Table 13

Recommendations for the treatment of tumours in imperative situations.

Recommendations	Grade
In imperative cases, it is recommended that a biopsy be performed before any therapeutic decision is taken.	High
In imperative cases, partial nephrectomy is the preferred treatment.	High
In imperative situations, it is recommended to limit renal ischemia and preserve as much healthy renal parenchyma as possible.	High
In imperative situations, percutaneous ablative treatments are an option.	Low
In imperative situations not eligible for surgical or ablative treatment, stereotactic radiotherapy may be discussed as an alternative.	Low
In imperative situations, it is advisable to refer the patient to an expert center.	Low

of tumours on renal transplants must be considered as a situation of imperative indication (single functional kidney with pre-existing chronic renal disease). Partial nephrectomy is the standard treatment. Several series have reported experience of conservative surgery, mainly for stage T1a renal transplant tumours, with excellent oncological and functional results [351–354]. Nevertheless, this surgery is potentially complex and morbid, requiring recourse to an expert center [342]. This complexity is mainly related to the dissection of the transplant vessels. Endovascular occlusion of the transplant artery during partial nephrectomy could be of interest in this indication [355]. Transplantectomy may be discussed when renal function is impaired, in cases of locally advanced tumour or symptoms. In published series, the majority of symptomatic or stage ≥T1b tumours were treated by transplantectomy [356,357]. Thermoablative treatments (radiofrequency and cryotherapy) can be used for cT1a [342,358]. These treatments appear to be increasingly preferred to PN, particularly in frail, elderly patients and/or when the tumour location is favourable to a percutaneous approach [359,360]. In summary, the management strategy for tumours on kidney transplants must be determined on a case-by-case basis by a multidisciplinary team, considering the expected difficulty of the surgery, the function of the transplant and the technical resources available (Recommendation Table 14).

In the case of lesions in the native kidneys, the reference treatment is laparoscopic total nephrectomy, with a morbidity similar to that of the general population [361,362]. Focal treatment, although not validated in this population, may be discussed if there is a need to preserve residual diuresis [346].

With regard to the waiting period after transplantectomy, the joint CCAFU/CTAFU recommendations do not impose a waiting period for a 2nd transplant in the following cases: papillary histology (low grade, formerly type 1) or clear cell histology (excluding translocation

carcinomas), stage < pT3 and low grade ISUP (expert opinion). In other situations, a minimum waiting period of two years is proposed, to be discussed in a collegial manner [342].

8.3. Familial tumours

Tumours arising in the context of a hereditary syndrome (mutations in *VHL*, *MET*, *FLCN*, *FH*, *TSC*, *SDH* or *BAP1*) are rare (2 to 3% of renal tumours) but are difficult clinical situations because of the frequently multifocal nature of the tumours and their high risk of recurrence. They require discussion within multidisciplinary teams (urologist, oncologist, oncogeneticist, interventional radiologist). Treatment options include active surveillance, multiple tumour resection and ablative therapies. They are discussed on a case-by-case basis depending on the site, size, location and complexity of the tumour, the type of genetic alteration and the technical facilities available.

Historical series suggest an arbitrary threshold of 3 cm above which it is advisable to treat a tumour in the context of a hereditary syndrome. This threshold would make it possible to preserve the renal parenchyma as much as possible while controlling the risk of metastasis for these tumours, which are thought to grow slowly. However, a study of the growth of tumours from hereditary syndromes in 292 patients and 435 tumours suggests different rates of growth depending on the type of mutation. An average tumour growth rate of 0.6 cm per year was reported for *BAP1* mutations, 0.37 cm per year for *VHL* mutations, 0.1 cm per year for *FLCN* mutations and 0.15 cm per year for *MET* mutations. Younger patients had faster tumour growth and tumours within the same patient progressed at the same rate. This study suggests caution in monitoring patients with *BAP1* [363].

Furthermore, *FH* mutations described in hereditary leiomyomatosis and succinate dehydrogenase (*SDH*)-deficient renal cancers in hereditary

Recommendation Table 14

Recommendations for the management of renal lesions in renal transplants and native kidneys in chronic renal failure patients.

Recommendations	Grade
Partial nephrectomy is the standard treatment for small tumours on renal transplants	Low
In the case of lesions in the native kidneys, the standard treatment is laparoscopic radical nephrectomy.	Low
A temporary contraindication to transplantation should not be imposed in the case of papillary (low grade) or clear cell histology (excluding translocation carcinomas), stage <pT3 and low ISUP grade.	Low

Recommendation Table 15

Recommendations for the treatment of kidney tumours arising in the context of hereditary syndromes.

Recommendations	Grade
The management of kidney tumours arising in the context of hereditary syndromes requires multidisciplinary management, including oncogenetic advice.	High
Kidney tumours arising in patients with mutations in VHL, MET, FLCN, TSC, SDH or BAP1 should be managed conservatively because of the high risk of contralateral recurrence. Surveillance is a priority option for tumours smaller than 3 cm.	Low
Tumours arising in patients with an FH mutation and succinate dehydrogenase (SDH)-deficient RCCs must be treated immediately with the certainty of obtaining negative surgical margins.	High

paranglioma/pleochromocytoma syndrome (HPP) are associated with particularly aggressive tumours in young subjects and require immediate management. In this rare situation, it is imperative to obtain negative surgical margins and extended nephrectomy may be considered even for small tumours [364,365] (Recommendation Table 15).

There are no recommendations on systemic treatments for hereditary kidney cancer. In hereditary MET-mutated papillary renal cancer (HPRC), phase II and III studies have demonstrated the efficacy of tyrosine kinase and multikinase inhibitors (MET/VEGFR2) [366,367]. In von Hippel-Lindau disease, a phase II trial demonstrated the clinical activity and good tolerability of belzutifan (an oral inhibitor of HIF-2 α), with a phase III trial in progress [368].

8.4. Cystic tumours of the kidney

Kidney cancers have a cystic appearance in 5 to 7% of cases. Cystic tumours are generally non-aggressive, low grade and the most common histological subtype is clear cell carcinoma [369,370]. Cross-sectional imaging (CT or MRI) is recommended to best characterize cystic lesions of the kidney. Contrast ultrasound may be performed if CT or MRI is contraindicated. MRI and contrast ultrasonography have better sensitivity and specificity for characterizing a complex cystic tumour (Bosniak IIF or III) [371,372]. Cystic tumours are classified according to the Bosniak classification into 5 stages (I, II, IIF, III, IV), according to six radiological parameters: the appearance of the cyst wall, the contents of the cyst, the presence of partitions and/or calcifications, the presence of vegetations, the enhancement of the cyst wall and/or its contents after injection of contrast medium (Fig. 3) [373–375].

The emergence of artificial intelligence and machine learning may make it possible to improve the assessment of cystic lesions. Ramachandran et al. evaluated three different machine learning algorithms based on the scannographic aspect, enabling better detection of cancerous lesions in a retrospective series of 144 patients. For the moment the level of evidence is not sufficient to recommend them in clinical practice [376].

The risk of malignancy that Bosniak initially reported for each category was updated in a systematic review of the literature [377]. The risk of malignancy was 9% (5–14%) for Bosniak II, 18% (12–26%) for Bosniak IIF, 51% (42–61%) for Bosniak III and 86% (81–89%) for Bosniak IV [377].

In 2018, a CCAFU multicenter study assessed the malignancy rates and histological characteristics of Bosniak III and IV lesions in France among 216 cystic tumours from the national uroCCR database. A central review by experienced pathologists was carried out: the malignancy rates for Bosniak III and IV cysts were 69% and 91% respectively. The tumours were mainly of low stage (86% pT1–2), low grade (68% ISUP grade 1–2) and good prognosis (recurrence 1.1%, specific survival 100%) [369]. In a second national multicenter study, the CCAFU reported the long-term oncological outcome of 152 cystic CRCs, Bosniak IIF (6%), III (53%) and

IV (41%), with a median follow-up of 61 months [370]. Bosniak stage was associated with a higher prevalence of high-grade tumours (36 vs. 12%, $P < 0.01$) [370]. However, Bosniak category was not predictive of oncological outcome, with favourable and similar recurrence-free survival rates for Bosniak III and IV of 92% vs. 92% at 5 years and 84 vs. 83% at 10 years ($P = 0.60$) [370].

The management of cystic tumours is determined by the Bosniak classification. For Bosniak I and II cysts, no treatment or follow-up is recommended. A radiological surveillance period (using cross-sectional imaging) of 5 years is recommended for IIF [377]. This follow-up makes it possible to distinguish stable IIF cysts from IIF cysts that progress to Bosniak \geq III and require surgical removal due to a high risk of malignancy (Fig. 3) [377].

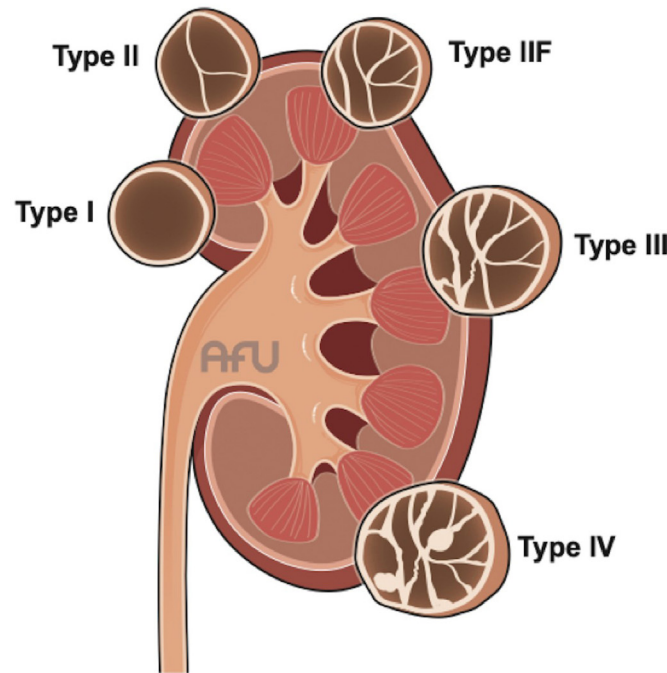
The identification of malignant tumours within Bosniak III cysts is uncertain. The new Bosniak classification including MRI aims to better identify malignant tumours but has not yet been validated [373]. The value of percutaneous biopsy of cystic tumours of the kidney has not been reported apart from the presence of a tissue component (Bosniak IV) [378]. Bosniak III cysts are benign in around 40% of cases and cystic cancers are predominantly of low stage/grade with an excellent long-term prognosis. The CCAFU therefore considers that surveillance is a possible alternative to surgical treatment [369,370,377,379] and can be discussed depending on the complexity of the tumour and the patient's co-morbidities. For Bosniak IV tumours, complete surgical excision is justified by the high risk of malignancy (Recommendation Table 16).

Intraoperative rupture of a cystic tumour is a frequent event, which raises the question of oncological risk. A French multicenter retrospective study reported 50 (18.7%) cases of rupture in a series of 268 cystic tumours operated. No patient developed peritoneal carcinosis. Rupture of the cyst was not associated with a higher risk of recurrence and the results were similar between robot-assisted laparoscopic surgery and open surgery [380]. These results confirm that cystic tumours have a low potential for malignancy. Intraoperative rupture should be avoided as far as possible but appears to have little oncological consequences. However, the CCAFU recommends surgical removal of a cystic tumour without rupturing its wall during the operation, whatever the approach used.

8.5. Oncocytoma

Oncocytoma is the most common benign tumour of the kidney, accounting for 3–7% of all kidney tumours and up to 18% of small renal masses (≤ 4 cm) [381]. Renal oncocytoma is a solid tumour, more rarely cystic, classically single and more rarely multiple in the context of oncocytosis (multiple oncocytic tumours with renal failure in a potential context of Birt-Hogg-Dubé syndrome) [382,383].

Apart from diagnostic excision surgery, diagnosis can be made on tumour biopsy, but this is becoming increasingly difficult because of the



Types	TDM Signs	Diagnosis and Management
Type I	Benign cyst with a water density, thin smooth wall, no enhancement, septa, calcification, or contrast medium washout	No surveillance
Type II	Benign cyst that may have enhancing thin septa, thin calcification or daughter cysts	No surveillance
Type IIF	cyst with smooth thickened enhancing wall, regular calcification or with many enhancing septa	surveillance with CT every year for 5 years
Type III	Solid enhancement, significant thick enhancement of the walls irregular and , or necrosis	probability of malignancy about 50%, Surgical resection with oncological rules, or surveillance for selected patients
Type IV	one or more enhancing septa, nodules	malignancy cyst, Surgical resection with oncological rules

Fig. 3. Bosniak classification of cystic kidney tumors.

new emerging entities of oncocytic cell tumours [119,125,384]. The correlation between the biopsy and the operative specimen when the biopsy concludes a renal oncocytoma varies from 65% to 91% depending on the series [118–120,385]. Discrepancies between biopsy and operative

specimen in the diagnosis of renal oncocytoma mainly concern other tumours in the oncocytic tumour group: 18 to 26% of chromophobe carcinomas in their eosinophilic variant, low grade oncocytic tumours/LOT, vacuolated eosinophilic cell tumours/HOT, hybrid tumours, solid

Recommendation Table 16

Recommendations for the treatment of cystic kidney tumours.

Recommendations	Grade
Cystic kidney lesions should be classified according to the Bosniak classification	High
Complete surgical removal is recommended for Bosniak IV cysts.	High
Complete surgical removal is recommended as first-line treatment for Bosniak III cysts.	Low
Monitoring may be discussed as an option depending on the complexity of the lesion and the co-morbidities of patients with Bosniak III cysts.	Low
Bosniak IIF cysts must be monitored regularly; surgical removal is recommended if they progress to category III or IV.	Low
Percutaneous biopsy of cystic renal tumours is not recommended unless there is a significant tissue component.	High

and cystic eosinophilic cell carcinoma, NOS oncocytic tumours and more rarely clear cell carcinoma (3% to 13%) [98,118–121].

A CCAFU systematic review and meta-analysis recently synthesized data from series of biopsied and monitored renal oncocytomas [384], which led to the following conclusions about the natural history of renal oncocytomas:

- the average tumour size at diagnosis is 26 mm (IC95% [17–34.6]) but can exceed 7 cm;
- the average growth rate is 1 to 3 mm/year.

In the case of a small renal mass, it appears that growth rate is not a reliable criterion for distinguishing a malignant tumour from an oncocytoma, as their growth rates are similar. In addition, the growth rate of renal oncocytomas is heterogeneous, with 14% of renal oncocytomas remaining stable in size, while 14% of oncocytomas grow rapidly > 5 mm/year [386].

The strategy for monitoring biopsied oncocytomas is based on a low level of evidence because the series are non-comparative, with an average follow-up of only 3 years (30 to 39 months), and a heterogeneous follow-up methodology, both in terms of the nature of the imaging examinations (ultrasound, CT scan, MRI) and the chronology of these examinations [121,384,387–396].

The rate of conversion from an active surveillance strategy to radical treatment (surgery or ablation) was 5 to 40% at 3 years. The most frequently reported reason (65%) for discontinuing surveillance in favour of surgery was tumour growth (although no threshold rate could be identified). In 13% of cases, the patient’s wish to stop surveillance and opt for radical treatment [384,387–396].

Factors associated with conversion from surveillance to surgical management were: age at diagnosis, low Charlson comorbidity score, and tumour size at diagnosis [384,387–396] (Recommendation Table 17).

In these series, no case of metastatic progression or specific death was reported, either for patients who remained on surveillance or for patients who had deferred treatment after a period of surveillance.

8.6. Management of sporadic angiomyolipomas and angiomyolipomas evolving in the context of tuberous sclerosis

Renal angiomyolipoma (AML) is a benign tumor with three components: vascular, fatty and smooth muscle [397]. Most of these tumors are asymptomatic with a sex ratio of 4 women to 1 man [398]. Diagnosis is based on CT (or MRI), which reveals a tumor containing fat with very high sensitivity and specificity, making biopsy unnecessary in typical forms [399]. Fat-poor AMLs are more difficult to diagnose. In this situation, biopsy is often necessary, and their management is similar to that of solid renal masses.

These tumors are sporadic in 80% of cases, but some are part of a genetic syndrome (20%), tuberous sclerosis complex (TSC) [400,401].

The major risk of these tumours is hemorrhagic rupture, which can cause a hematoma of the retroperitoneum. This retroperitoneal hemorrhage, also known as “Wunderlich syndrome”, can exceptionally be so massive as to be life-threatening [402]. The predictive factors for

rupture have not been clearly identified. The risk seems to increase with the size of the tumour and the proportion of the vascular component [403].

Given the benign nature of this tumour, active surveillance (AS) is the treatment of choice [404]. However, more than half of AMLs diagnosed are actively treated, mainly by partial or radical nephrectomy or arterioembolization [398,403]. The over-treatment of these tumours is based on an old dogma, which stated that the risk of bleeding was increased when the tumour size exceeded 4 cm [405]. The relevance of this threshold is highly controversial [403]. Studies evaluating ADT for LMA have shown a minimal rate of serious complications (< 1%) and slow tumour growth (between 0.02 and 0.25 cm/year), confirming the exceptional nature of the much feared cataclysmic hemorrhage [406,407]. Surveillance for tumours larger than 4 cm is a safe option [408]. The modalities of surveillance are not clearly established [406]. Certain situations require active treatment to be discussed: high risk of bleeding from abdominal trauma (contact sports, army, motorcyclists), women of childbearing age, inability to access emergency care in the event of hemorrhagic rupture or refusal of monitoring. The active treatment of choice is partial nephrectomy, which is associated with a lower rate of recurrence than arterioembolization (0.85% vs. 31%) [403]. In the event of a threatening hemorrhage, emergency arterioembolization is indicated. Ablative treatments have been little studied in this indication (Recommendation Table 18).

Epithelioid AMLs are a distinct entity with the potential for malignancy, including the risk of metastasis and death from cancer. These are low-fat tumours. They are often diagnosed on biopsy or after partial nephrectomy. The management of epithelioid AML is similar with the management of localized and metastatic non-clear cell renal cancers [409].

Tuberous sclerosis complex (TSC) is a genetic syndrome with a multi-systemic, autosomal dominant involvement linked, most often, to a mutation of the TSC1 (chromosome 9) and TSC2 (chromosome 16) genes [410]. Its incidence is estimated at 1 in 6500 to 13,520 births [411]. The presence of AML of the kidney in this condition is a major clinical diagnostic criterion [401]. In the event of suspicion, genetic counselling is recommended. Renal assessment and monitoring include MRI (every 1 to 3 years), renal function, testing for hypertension and annual proteinuria. The first-line treatment is medical treatment with mTOR inhibitors, which have demonstrated their efficacy (hemorrhagic complications, preservation of renal function) in this indication. The balance of benefits and adverse effects must be weighed against the progression of the disease [412,413]. Second-line treatments include thermoablation, arterioembolization and surgical removal (lumpectomy). Radical nephrectomy should be avoided [401].

9. Perioperative management

9.1. Management of thromboprophylaxis

Open nephrectomy, whether radical or partial, induces a state of hypercoagulability. In 2005, the SFAR recommended prophylactic

Recommendation Table 17

Recommendations for the treatment of oncocytomas.

Recommendations	Grade
Surveillance is an alternative to systematic excision for biopsy-proven renal oncocytomas	High
In the absence of surgical excision, a renal oncocytoma must be monitored because of the risk of tumour growth and misdiagnosis of the biopsy.	High
In the case of multiple oncocytomas, a genetic investigation should be proposed	High

Recommendation Table 18
Management of angiomyolipomas.

Recommendations	Grade
Renal biopsy is not recommended for typical AML.	High
Surveillance is the treatment of choice for typical asymptomatic AMLs	High
Active treatment by partial nephrectomy or arterioembolization may be discussed if there is a risk of bleeding: - Large tumour (no clearly defined intervention threshold) - women of childbearing age - non-compliance with surveillance - no access to a suitable care structure - risk of abdominal trauma	Low
In the event of massive hemorrhage, emergency arterioembolization is recommended.	High
Tuberous sclerosis requires multidisciplinary care, including genetic counselling.	High
Renal assessment and monitoring of patients with tuberous sclerosis includes: - MRI every year (if tumour >3 cm) or every 3 years - Check for high blood pressure every year - Assessment of renal function every year - Testing for proteinuria every year	High
mTOR inhibitors are the first-line treatment for AML associated with tuberous sclerosis.	High
Thermoablation, arterioembolization and partial nephrectomy are the second-line treatments for MVA associated with tuberous sclerosis complex	Low
Radical nephrectomy should be avoided in patients with AML associated with tuberous sclerosis.	High

postoperative anticoagulation [414]. However, this recommendation did not distinguish between laparoscopic (\pm robotic assisted) and open surgery. The advent of these approaches may allow [415] under certain conditions, not to introduce preventive anticoagulation because the thromboembolic complication rate is low (≈ 0.6 – 0.9%) [416].

Thromboprophylaxis may therefore not be introduced if all the following criteria are met (low grade, expert opinion):

- laparoscopic approach (\pm robot-assisted);
- age < 75 years;
- BMI < 35;
- no personal or family history of thromboembolism within 1st degree.

9.2. Infectious risk management

In January 2024, the SFAR and SPILF, in conjunction with the CIAFU of the AFU, updated their recommendation on intraoperative antibiotic prophylaxis. They concluded that antibiotic prophylaxis should not be used (expert opinion, low grade).

The French multicenter study TOCUS [417], which included 269 nephrectomies, found no significant correlation between the performance of a preoperative ECBU and the risk of postoperative urinary tract infection [OR = 1.2 (0.5–2.7) ($P = 0.7$)]. Only postoperative non-infectious complications were associated with a higher risk of postoperative UTI [OR = 12 (4–37), $P < 0.001$]. Furthermore, no study has demonstrated an increased risk of postoperative infection in the case of an untreated positive preoperative UTI. It is therefore not necessary to perform a ECBU prior to nephrectomy in order to prevent postoperative sepsis (expert opinion, low grade).

9.3. Enhanced Recovery After Surgery (ERAS)

In June 2022, the AFU issued recommendations on this subject. The introduction of a RAAC program within each establishment, specific to its ecosystem, is recommended. Coordination by paramedical staff plays a central role [418]. The addition of a digital device to the RAAC pathway is currently being evaluated: UROCCR 126 – DiPRU.

These measures can be divided into three parts: preoperative, intraoperative and postoperative (Recommendation Table 19).

9.3.1. Preoperative

Particular attention should be paid to informing the patient, especially about possible complications. The AFU leaflets can be used as a basis for these explanations. Treatment with adjuvant immunotherapy should be discussed prior to surgery.

In the event of malnutrition, appropriate nutritional support should be offered. However, immuno-nutrition (such as Oral Impact[®]) is not recommended (weak evidence, low grade). Fasting may last for only six hours, with the possibility of taking clear liquids up to two hours before surgery. A carbohydrate load of 50 grams the same morning is also recommended [419].

In general, it is advisable to stop smoking and drinking alcohol before surgery (medium level of evidence, high grade).

Radical or partial nephrectomy is also feasible with these measures in elderly patients [420] after possible oncogeriatric optimization and, if possible, adapted physical assistance (APA).

9.3.2. Perioperative

Laparoscopic surgery (\pm robot-assisted) and preservation of the parenchyma by partial nephrectomy is recommended as long as this is

Recommendation Table 19

Recommendations for the perioperative management of patients undergoing nephrectomy.

Recommendations	Grade
Pre-operative ECBU not recommended before radical and partial nephrectomy	Low
It is advisable to encourage patients to stop smoking and drinking alcohol before surgery.	High
It is important to be vigilant about the information given to the patient before and after the operation, particularly with regard to the possibility of using adjuvant immunotherapy.	Low
Pre-operative immuno-nutrition is not recommended	Low
Fasting can last as little as six hours, with the possibility of taking clear liquids up to two hours before surgery. A carbohydrate load of 50 grams that morning is also recommended.	Low
Preference should be given to laparoscopy (+/- robot-assisted) and preservation of the renal parenchyma as long as this is technically feasible.	High
Antibiotic prophylaxis should not be used	Low
Limit morphine and intraoperative filling volumes	Low
Limiting postoperative drainage	Low
Encourage mobilization and re-feeding on D0	Low
Thromboprophylaxis may not be introduced if all the following criteria are met: - laparoscopic approach (+/- robot-assisted) - age < 75 - BMI < 35 - No personal or family history of thromboembolism in the 1 ^{er} degree range	Low

technically feasible in view of the oncological results. Anesthesia should limit the use of morphine and filling volumes. In the event of drainage or bladder catheterization, these should be removed as soon as possible.

9.3.3. Postoperative care

Early mobilization under multimodal analgesia is an essential part of PAC, and reduces postoperative complications. As a result, light chair feeding is recommended from day 0. Monitoring instructions must be explained and given to patients on discharge.

10. Prognostic factors and monitoring after treatment of localized or locally advanced kidney cancer

10.1. The benefits of monitoring

There is no real consensus on the modalities of surveillance after kidney cancer treatment [421]. Although some retrospective series suggest a potential benefit of early detection of recurrence, no high-level evidence study has demonstrated an impact on survival with regular follow-up [422,423]. Kidney tumor surgery causes a deterioration in renal function and increases the risk of de novo hypertension whatever the type of surgery, with 19% of de novo hypertension at 6 months after surgery in the prospective VAPANCR-UROCCR study [424].

The aims of follow-up after surgical treatment for non-metastatic kidney cancer are:

- detect local or distant recurrence that may benefit from curative or systemic treatment;
- monitor renal function and blood pressure and implement appropriate nephroprotective measures [424,425].

There is no consensus on the ideal duration of follow-up, which should take into account the patient’s age, comorbidities, prognostic factors and life expectancy [426]. The majority of recurrences occur within 5 years, but in the case of poor prognostic factors, the risk remains significant

beyond 5 years (of the order of 20%), justifying prolonged and close follow-up in the early years [427].

10.2. Prognostic factors

Prognostic factors include clinico-biological, anatomical, histological and molecular factors.

Clinico-biological factors include performance status (ECOG, Karnofsky index), local symptoms, cachexia, anemia, platelet count, neutrophil count, lymphocyte count, C-reactive protein, albumin and various indices derived from these factors such as neutrophil/lymphocyte ratio (NLR) [428–431]. As a marker of the systemic inflammatory response, a high preoperative NLR appears to be associated with a poor prognosis [431]. However, there is significant heterogeneity in the data and no prognostic threshold can be proposed.

Anatomical factors include tumour size, venous invasion (renal vein, inferior vena cava), overgrowth of the renal capsule and invasion of local lymph nodes. All these factors are considered in the TNM classification.

Histological factors include tumour grade, histological subtype, lymphovascular invasion, tumour necrosis, invasion of the collecting system, rhabdoid and sarcomatoid component [432–435]. The percentage of the sarcomatoid component also seems to have a prognostic value, however, there is no agreement on the optimal prognostic threshold [436,437].

Numerous molecular markers such as expression of carbonic anhydrase IX (CA IX), VEGF and PD-L1 have been studied [438]. However, they have been tested in small cohorts with very little external validation. Their systematic use in clinical practice is therefore not recommended.

10.3. Prognostic systems in localized or locally advanced kidney cancer

TNM classification and nuclear grade play a predominant role as prognostic systems in non-metastatic kidney cancer. However, these

systems are often undermined by the sometimes-unpredictable course of kidney cancer.

As a result, several models and nomograms have been developed largely on the basis of retrospective data to predict the risk of death or metastases distant from surgery [439]. However, their ability to predict the risk of recurrence is limited [440] and even the sophisticated models proposed from prospective data by teams of experts show no improvement when evaluated externally [441].

Artificial intelligence (AI) techniques offer an innovative approach to analysis, distinct from traditional methods. These technologies can learn and improve their capabilities autonomously, without the need for explicit programming. In a context where healthcare data is abundant, AI offers a modern and accurate method for estimating individualized survival outcomes, thereby improving healthcare decision-making.

Several studies have used clinico-pathological data to predict post-nephrectomy recurrence, with many results suggesting superior performance of machine learning systems compared with traditional models [442–444].

The UROPREDICT algorithm developed by the CCAFU from prospective UROCCR data is available online (www.uroccr.fr) and can be used to estimate the individual risk of each patient [445].

Although the performance of AI-based models is promising, further steps are needed to improve their interpretability and ensure robust external validation before wider dissemination in clinical practice.

10.4. What regimen may be recommended after surgical treatment of localized or locally advanced kidney cancer?

10.4.1. Risk stratification

In the absence of a validated scheme, we suggest adapting follow-up to the risk of tumour recurrence, which can be assessed simply using the UISS system (Tables 3 and 4).

The UISS system is simple to use and is applicable to the three most frequent histological subtypes [446,447].

The risk of developing metastases after surgery was estimated at between 30 and 40%, with a median delay of 15 months. The 5-year specific survival after management of localized kidney cancer was estimated according to the UISS score to be 91.1%, 80.4% and 54.7% for patients at low, moderate and high risk [448].

10.4.2. Monitoring procedures

Abdominal CT is better than ultrasound for detecting local recurrence [449,450].

The risk of developing a tumour on the contralateral kidney is rare (estimated at 2%) [451].

The primary site of metastatic progression is the lung. CT is superior to radiography in detecting lung lesions [452].

For patients in the low-risk group, the use of irradiating imaging examinations can be limited, with ultrasound or MRI being preferred.

Table 4
Proposed postoperative follow-up after surgery for localized or locally advanced kidney cancer.

Risk	Low	Intermediate	High
Terms and conditions	CT TAP Possible alternation with ultrasound or renal MRI	CT TAP or Abdominal MRI and thoracic CT scan	CT TAP Or Abdominal MRI and thoracic CT scan
Frequency	At 6 months Then every year for 3 years Final check at 5 years	Every 6 months for two years Then every year for 4 years Then every two years for 4 years	Every 3 months for 1 year Then every 6 months for 4 years Then every year for 5 years
Duration	5 years	10 years	10 years

Table 3
UISS classification algorithm for localized and locally advanced kidney cancer.

Stage T	T1	T2	T3	T4
Fuhrman	1–2	3–4	1–4	1
ECOG	0	1–3	0–3	0
Risk	Low	Intermediate	High	

10.5. What follow-up is required after ablative treatment for localized kidney cancer?

Ablative therapies require monitoring with imaging at 3 months, 6 months, 1 year and then every year for a period that is not clearly defined [453].

If surveillance is based on MRI, the search for secondary lung lesions requires annual lung scans (without iodinated contrast injection). Diagnosis of early local recurrence is often difficult and requires careful comparison with pre-treatment imaging. Given the difficulties in guiding the biopsy, the diagnosis of recurrence is not based on the biopsy, and new treatment may be proposed based on the presence of an oval-shaped contrast enhancement, most often located at the periphery of the lesion in contact with the deep part or non-tumorous renal parenchyma (Table of recommendations 20).

11. Adjuvant treatment in kidney cancer

11.1. Anti-angiogenic agents

Most randomized trials investigating the value of adjuvant anti-angiogenic therapy in patients at high risk of recurrence after nephrectomy have reported negative results [454]. Only the S-TRAC study, which evaluated the value of sunitinib treatment in patients at high risk of recurrence, showed an improvement in recurrence-free survival but no improvement in overall survival in the sunitinib-treated group [455]. The results of trials conducted with anti-angiogenic agents have not validated in France the indication for adjuvant treatment with anti-angiogenic agents (TKIs and mTOR inhibitors) after surgery for localized kidney cancer [456–461].

11.2. The role of immunotherapy

The phase 3 KEYNOTE-564 study evaluated the efficacy of pembrolizumab administered in the adjuvant setting after nephrectomy in patients with localized clear cell renal cancer at intermediate-high and high risk of recurrence, as well as in oligometastatic patients with no visible residual disease after resection of metastases within one year of nephrectomy (M1NED). Adjuvant therapy was initiated within 12 weeks of surgery and for up to 1 year at a dose of 200 mg administered every 3 weeks in ECOG 0 or 1 patients [462]. A total of 994 patients were randomized 1:1 to pembrolizumab or placebo. The study population included patients at risk of recurrence defined as follows: patients at intermediate-high risk of recurrence (pT2 Grade 4 or sarcomatoid, pT3 all grades N0, M0), patients at high risk of recurrence (pT4 all grades N0, M0 or pT all stages, N+, M0) and metastatic patients with no residual

Recommendation Table 20

Recommendations for follow-up after treatment of a localised tumour.

Recommendations	Grade
After treatment for non-metastatic kidney cancer, follow-up thoracic abdominal and pelvic imaging should be carried out.	High
The monitoring schedule after treatment for non-metastatic kidney cancer must be adapted to the risk of recurrence and the patient's life expectancy.	High
The risk of recurrence can be assessed by predictive nomograms (UISS) or by algorithms using Machine Learning and artificial intelligence.	Low
For low-risk diseases, radiation examinations should be limited	Low
After surgery or ablative treatment of a localized kidney tumour, renal function and blood pressure should be monitored.	High
Patients with post-operative chronic renal failure should be referred to a nephrologist or their General Practitioner for appropriate assessment, given the potentially higher risk of cardiovascular problems.	High

lesion after resection of all metastases within less than 12 months of nephrectomy (M1 NED – no evidence of disease). With a median follow-up of 57.2 months (47.9–74.5 months), the primary objective was achieved, with a 28% reduction in the risk of recurrence. The 4-year DFS rate was 64.9% in the pembrolizumab group versus 56.6% in the placebo group (HR: 0.72; 95% CI: 0.59–0.87; $P = 0.001$). The benefit existed in all 3 patient subgroups and was more marked in the “metastatic operated (M1NED)” group (HR: 0.40). In addition, adjuvant treatment with pembrolizumab significantly reduced the risk of death by 38%, with overall survival not reached in the 2 arms (HR = 0.62 (95CI: 0.44–0.87); $P = 0.002$). Overall survival at 4 years was 91.2% in the pembrolizumab arm versus 86% in the placebo arm. However, this gain in overall survival was not apparent in the subgroup analysis of high-risk and M1NED patients. Grade 3–4 pembrolizumab-related adverse events occurred in 18.6% of pembrolizumab-treated patients versus 1.2% of placebo-treated patients, leading to permanent discontinuation of treatment in 18.2% of pembrolizumab-treated patients versus 0.8% of placebo-treated patients. There was no death related to treatment side effects. The rate of immunomediated adverse events requiring high-dose corticosteroid therapy (> 40 mg) was 7.4% in the pembrolizumab group versus 0.6% in the placebo group [463]. Treatment with pembrolizumab did not reduce patients' quality of life [464].

Based on the improvement in recurrence-free survival and overall survival, pembrolizumab administered in the adjuvant setting for up to 12 months and initiated within 12 weeks of nephrectomy for localized intermediate-high and high-risk clear cell renal cancers as defined by the study (pT2 Grade 4 or sarcomatoid, pT3 all grades N0, M0 and pT4 all grades N0, M0 or pT any stage, N+, M0) is a standard treatment to be offered to patients. Patients should be given clear information about the potential side effects of pembrolizumab (Recommendation Table 21).

For patients in remission after complete resection of metastases, adjuvant treatment with pembrolizumab is recommended. However, it should be pointed out that the reference first-line treatment for metastatic kidney cancer is based on anti-PD1-based combinations, and that these situations of metastases operated on within the first year of diagnosis are exceptional. The cohort of M1 patients operated on in the KEYNOTE 564 study was small (56 pts, 6% in each group) with the majority, but not exclusively, resections of adrenal, proximal lymph node and nephrectomy sites [465–468].

KEYNOTE 564 is the only positive study in the adjuvant treatment of localized clear cell kidney cancer after nephrectomy. The CheckMate

914 study, evaluating nivolumab as a single agent or in combination with ipilimumab, compared with placebo, showed no benefit in terms of recurrence-free survival (HR: 0.87 [0.62–1.21], HR: 0.92 [0.71–1.19] respectively) [469]. The PROSPER study evaluating perioperative nivolumab was negative [469]. The IMmotion 010 study, evaluating atezolizumab vs. placebo, was also negative for recurrence-free survival (HR: 0.93 [0.75–1.15]) [470]. The RAMPART trial (NCT03288532, durvalumab vs. durvalumab + tremelimumab vs. placebo) and the LITESPARK trial (NCT05239728 pembrolizumab vs. pembrolizumab + belzutifan) have completed recruitment and the first results should be available shortly (Recommendation Table 21).

12. Treatment of metastatic kidney cancer

12.1. IMDC classification (Heng)

The prognostic classification of the International Metastatic RCC Database Consortium [471] (IMDC) is now the most widely used in clinical practice [472]. The prognostic score incorporates the Karnofsky index (< 80%), hemoglobin level (< normal), neutrophil count (> normal), platelet count (> normal), corrected calcium level (> normal) and the time between diagnosis and initiation of systemic therapy. This score has also been validated in second-line treatment [473] in clear cell carcinomas and in non-clear cell carcinomas [474] (Table 5). Median overall survival in the era of targeted therapy is 43, 23, and 8 months in groups with favorable (0 factors), intermediate (1 or 2 factors), and unfavorable (≥ 3 factors) prognosis, respectively [472].

12.2. Place of immediate or delayed cytoreductive nephrectomy (CRN) in metastatic renal cancer (mRCC)

12.2.1. In the era of 1st line TKIs

Two long-standing prospective randomized trials (EORTC and SWOG), as well as a third study combining the two trials, have demonstrated an improvement in overall survival after cytoreductive nephrectomy (CRN) prior to IFN-alpha treatment in patients in good general condition with metastatic renal cancer (mRCC) [475].

In the era of single agent 1st line anti-angiogenic treatments, two prospective randomized trials have assessed the value of NCR in MRC: CARMENA and SURTIME. The CARMENA trial assessed the benefit of NCR in addition to sunitinib, while the SURTIME trial looked at the

Recommendation Table 21

Recommendations concerning adjuvant treatment after surgery for localized kidney cancer or kidney cancer in remission after removal of metastases.

Recommendations	Grade
Adjuvant anti-angiogenic treatment is not recommended after surgery for localized kidney cancer.	High
Adjuvant treatment with pembrolizumab is recommended in patients at intermediate-high and high risk of recurrence after nephrectomy for clear cell renal cancer (pT2 Grade 4 or sarcomatoid, pT3 all grades N0, M0 and pT4 all grades N0, M0 or pT all stages, N+, M0).	High
Treatment with pembrolizumab is recommended after surgical complete remission of metastases occurring within one year of nephrectomy for clear cell renal cancer.	Low
Adjuvant treatment with pembrolizumab is not recommended for non-clear cell renal cell carcinoma.	High
The patient must be informed: - Individual risk of recurrence based on recent prognostic models - Proven benefits and side effects of treatment	Low

benefit of immediate NCR versus delayed NCR after treatment with sunitinib.

The CARMENA trial reported non-inferiority of sunitinib alone versus NCR followed by sunitinib (median overall survival: 18.4 versus 13.9 months; HR: 0.89; 95%: 0.71–1.10; non-inferiority limit: ≤ 1.20) in patients with MRC of intermediate or poor prognosis according to the MSKCC model [476]. These data have been updated and confirm the non-inferiority of sunitinib alone in patients with intermediate or poor prognosis MRC using the prognostic criteria of the IMDC (median overall survival: 19.8 vs. 15.6 months; HR: 0.97; 95%CI: 0.79–1.19; $P = 0.8$).

Post-hoc analysis of CARMENA identified a sub-group of patients within the intermediate-risk IMDC population for whom immediate NCR could be discussed: patients with a single risk factor (overall survival benefit in the nephrectomy followed by sunitinib group, non-significant result: 31.4 months versus 25.2 months; HR 1.30, 95%IC 0.85–1.98; $P = 0.2$), patients with a single metastatic site (notably pulmonary with a median overall survival of 44 months [23.2–64.6] versus 31.5 months [14.7–64.4]; HR, 1.4; 95%CI 0.62–2.47) and patients who responded well to sunitinib treatment and underwent secondary surgery (median overall survival of 48.5 months for patients with secondary nephrectomy versus 15.7 months for patients who did not undergo surgery after sunitinib (HR, 0.34; 95%CI 0.22–0.54) [477].

The SURTIME trial showed no benefit in progression-free survival at 28 weeks (amended primary endpoint) in patients with mRCC treated with immediate versus delayed CRN in combination with sunitinib (42%

Table 5

IMDC prognostic classification of metastatic kidney cancer.

IMDC classification	
Karnofsky index	Less than 80
Interval between diagnosis and systemic treatment	Less than one year
Hemoglobin level	Below normal
Corrected blood calcium	Above normal
Platelet count	Above normal
Neutrophil count	Above normal
0 factor: good prognosis	
1 or 2 factors: intermediate prognosis	
3 or more factors: poor prognosis	

versus 43%, $P = 0.61$). In contrast, there was evidence of prolonged overall survival (secondary endpoint) in the delayed CRN arm (32.4 [14.5–65.3] months versus 15 [9.3–29.5] months; [HR: 0.57, 95% CI: 0.34–0.95, $P = 0.032$]). However, the trial enrolled only a small number of patients and lacked power [478].

In the light of these two prospective trials, immediate CRN should no longer be recommended as first-line treatment for patients with an intermediate or poor prognosis.

12.2.2. In the era of immunotherapies and 1-line immunotherapy-TKI combinations

Since the publication of CARMENA and SURTIME, combined treatments with checkpoint inhibitors (ICI) have become the reference first-line treatments for metastatic kidney cancer, with anti-angiogenic monotherapies becoming an option in cases where checkpoint inhibitors are contraindicated or unavailable (see the section on systemic treatment). The role of cytoreductive nephrectomy remains undetermined, and the available data are essentially retrospective.

In phase 3 trials of ICI-ICI and ICI-TKI combinations in 1st lines, up to 30% of patients were treated with their primary tumor in place [479–483]. In this group of patients, there was a benefit in progression-free survival and overall survival in favour of combinations with ICI versus sunitinib. A meta-analysis published in 2022 confirmed the benefit of treatment with ICI versus sunitinib in the groups of patients with or without nephrectomy: in overall survival (HR 0.67 [0.59–0.77] and HR 0.69 [0.57–0.85] respectively) and progression-free survival (HR 0.57 [0.44–0.74] and HR 0.63 [0.52–0.77] respectively), suggesting that nephrectomy would not provide any benefit. However, it is important to distinguish between nephrectomies performed before the metastatic stage and cytoreductive nephrectomies performed in synchronous metastatic disease. These data were not available in the various studies analyzed [484].

A retrospective study of the National Cancer Database (NCDB) including 391 patients treated with nephrectomy (immediate or deferred) and immunotherapy ($n = 221$) or immunotherapy alone ($n = 170$), reported a benefit in overall survival in favor of the nephrectomy group (median overall survival: NA vs. 11.6 months, HR 0.23 [95% CI 0.15–0.37] ($P < 0.001$)). In multivariate analysis, cytoreductive nephrectomy

was the only factor associated with overall survival [485]. Other retrospective studies and meta-analyses concur with these conclusions regarding the overall survival benefit of immediate or delayed nephrectomy. However, these studies all have the bias of retrospective analyses, with patients selected in the nephrectomy group [486–488].

The morbidity of delayed nephrectomy after immunotherapy remains poorly assessed due to the lack of hindsight and the small number of cases reported in the literature. Two initial studies reported the feasibility of total or partial nephrectomy after immunotherapy, with the main surgical complexity being the presence of reactive inflammatory tissue making dissection of the hilum more difficult [489,490]. More recent series report reassuring data in terms of specific postoperative complications [491–493].

In the absence of randomized studies on the role of nephrectomy in the era of immunotherapy, first-line systemic treatment is still recommended in intermediate and poor risk groups.

The role of delayed nephrectomy in good responder patients remains to be determined.

Trials are currently underway to study the benefits of treating the primary tumour at the metastatic stage by delayed nephrectomy (NORDIC SUN [NCT03977571], PROBE [NCT04510597] Cyto-KIK [NCT04322955]) or stereotactic radiotherapy of the primary tumour (CYTOSHRINK [NCT04090710] and NRG-GU012 SAMURAI trial).

First-line medical treatments achieve a complete response to cancer metastases in 8 to 16% of cases [479–483]. On the other hand, response to treatment of the primary tumour is less frequent. In this population of patients with a major response to treatment and a primary tumour in place, delayed nephrectomy, known as “closure nephrectomy”, makes it possible to obtain a status without residual tumour. Once complete remission has been achieved, systemic treatments may be discontinued. This strategy is currently being evaluated, but appears to be a preferred indication for nephrectomy at the metastatic stage (Recommendation Table 22).

12.2.3. Special situations

12.2.3.1. Symptomatic patients. In a prospective observational study from 1988 to 2019, 66% of patients with metastatic kidney cancer were symptomatic at diagnosis. A further 37% had symptoms related to the primary tumour. Nephrectomy improved all symptoms in 71% of cases,

and local symptoms in 95% of cases, but was associated with a complication rate of 37% of cases (10% Clavien-Dindo ≥ 3), a mortality rate of 3% and a situation described as deleterious in 4% of cases (non-resolution of symptoms, associated with a major complication). There is also the risk of not being able to administer systemic treatment after nephrectomy in the event of complications or deterioration in the patient’s general condition (17.7% of patients in the CARMENA trial were unable to receive sunitinib after nephrectomy). Patients should be informed of this [477,494].

12.2.3.2. Nephrectomy in oligometastatic patients. The KEYNOTE 564 trial demonstrated a benefit in terms of disease-free and overall survival of adjuvant treatment with pembrolizumab in patients undergoing surgery for localized clear cell renal cell carcinoma at high risk of recurrence (see adjuvant chapter) [463,495]. The study included patients with no residual disease after treatment of metastases within 12 months of nephrectomy (M1 NED). In this oligometastatic situation with possible complete treatment of the primary and metastatic sites, immediate nephrectomy may be discussed, accompanied by adjuvant treatment with pembrolizumab.

12.2.3.3. Metastatic non-clear cell kidney cancer. The main studies of cytoreductive nephrectomy (CARMENA, SURTIME) have included clear cell renal cell carcinomas, to the exclusion of other histological types. The same applies to therapeutic trials of checkpoint inhibitors and TKIs in 1st line metastatic renal cell carcinoma. The available studies on cytoreductive nephrectomy of metastatic non-clear cell cancers are essentially retrospective and of low level of evidence. A systematic review published in 2019 found an overall survival benefit in favour of cytoreductive nephrectomy for non-clear cell histological subtypes (analysis based on three observational studies) [496]. A recent retrospective study also found a survival benefit for cytoreductive nephrectomy in a matched population of 222 patients treated for metastatic non-clear cell renal cancer (median overall survival 36.8 months vs. 20.8 months; $P < 0.01$) [497].

In the absence of a strong level of evidence, cytoreductive nephrectomy should be discussed on a case-by-case basis for patients with metastatic non-clear cell renal cancer because of the lower likelihood of response to first-line medical treatments and the possible benefit of

Recommendation Table 22

Recommendations for cytoreductive nephrectomy.

Recommendations	Grade
Immediate cytoreductive nephrectomy is not recommended in patients with intermediate and poor prognosis metastatic renal cancer.	High
Immediate cytoreductive nephrectomy can be offered to metastatic patients in good general condition who do not require systemic treatment.	Low
Immediate cytoreductive nephrectomy may be discussed in intermediate-risk patients with a single prognostic risk factor and a single metastatic site.	Low
Immediate cytoreductive nephrectomy may be proposed in oligometastatic patients in association with local treatment of metastases if the complete remission can be obtained.	Low
Delayed cytoreductive nephrectomy may be discussed in patients who have responded well to systemic treatment.	Low
Immediate cytoreductive nephrectomy may be discussed for patients with metastatic non-clear cell renal cancer in good general condition.	Low
Immediate cytoreductive nephrectomy may be proposed for symptomatic purposes	Low

nephrectomy. These patients should be discussed at the CARARE multidisciplinary oncological meeting.

12.3. Local treatment of metastases

12.3.1. Indications

Local treatment of metastases may be justified in several situations:

- for symptomatic purposes;
- to prevent local complications;
- to defer the introduction of systemic treatment;
- to achieve complete remission and consider a therapeutic pause in oligometastatic patients

The aim of targeted treatment of metastases would be to improve patient survival while preserving quality of life, on the one hand by delaying the introduction of or change to systemic treatment, and on the other hand by limiting the complications associated with metastases.

Oligometastatic and oligoprogressive situations should be considered at a multidisciplinary meeting in order to discuss the alternatives of surveillance, systemic treatment and/or local surgical or ablative treatment of the metastases (Recommendation Table 23).

12.3.2. Surgery

Among the alternatives for local treatment of metastases, surgery has been the most extensively studied. However, survival data for surgical treatment of kidney cancer metastases are based on retrospective series with highly selected patients. The recommendations must therefore be taken with the reservation of a low level of evidence.

12.3.2.1. Metastectomy versus no surgical treatment of metastases. Several retrospective studies report a benefit in terms of overall survival, specific survival and progression-free survival in favour of metastectomy in selected patients and have been the subject of literature reviews [498–501]. This benefit was not found in patients with a poor prognosis [502,503]

12.3.2.2. Complete metastectomy versus incomplete metastectomy. In 2014, a systematic review of surgery for kidney cancer metastases,

including 16 studies with a total of 2,235 patients, concluded that complete treatment of metastases was associated with a specific survival of 41 months compared with 15 months in the absence of treatment and/or incomplete treatment. The gain in survival with complete treatment concerned all metastatic sites (lung, liver, bone, pancreas) and reached in particular 142 vs. 27 months for liver metastases ($P = 0.003$). [499].

In a series of 586 patients published in 2020, 2-year survival was 84% for complete resection versus 54% for incomplete resection ($P < 0.001$). Complete surgical resection was the main prognostic factor for survival [504].

According to a 2021 systematic review, incomplete or unperformed metastectomy had a negative impact on overall survival compared with complete metastectomy (HR 2.15; $P < 0.00001$), with synchronous and multiple metastases being associated negative factors [505]. The benefit of complete metastectomy also seems to be confirmed in the era of immunotherapies [506,507].

12.3.2.3. Other prognostic factors related to metastectomy. Other prognostic factors have been put forward, such as the number of metastatic sites and the disease-free interval. The prognostic impact of the organ affected is less clear: the most favourable survival data seem to concern surgery for pulmonary, pancreatic, hepatic, thyroid and adrenal metastases, as opposed to bone, brain and lymph node metastases [498].

12.3.2.4. Morbidity of surgery for metastases. Surgery for metastases can therefore only be considered when it is thought to be complete, in a patient in good general condition, with a limited number of metastatic sites and slowly progressive disease [498,499,508,509]. However, this should be weighed against the risks involved: according to a study based on the SEER database, the complication rate and intra-hospital mortality after metastectomy were 55% and 4.6% respectively. In a multicenter series published in 2023, including 740 metastectomies in 522 patients, 8% of patients had a major complication and 1% died perioperatively. Age, multiple resected sites and pancreatic surgery were associated with the risk of major complication [510].

Recommendation Table 23

Recommendations for local treatment of kidney cancer metastases.

Recommendations	Grade
In oligometastatic patients, local treatment of metastases may be offered for oncological purposes if it achieves a complete response.	Low
Surgery for metastases should only be considered for carcinological purposes if complete surgical resection is possible.	Low
Local treatment of metastases can also be proposed in the following cases: - Palliative for symptomatic purposes, - To prevent local complications, - To defer the introduction of systemic treatment, - To delay a change in therapeutic line - To take a therapeutic break from a systemic treatment - To control dissociated responses	Low
The modalities for local treatment of metastases should be discussed at the multidisciplinary consultation meeting (RCP). Surgery, radiotherapy and percutaneous ablative therapies are possible.	Low

12.3.3. Stereotactic radiotherapy

Stereotactic radiotherapy (SABR or SBRT) has demonstrated its superiority over conventionally fractionated radiotherapy with a high rate of local control (> 90%) and low morbidity [511–515].

12.3.3.1. In oligometastatic situations (≤ 5 metastases). Complete treatment of all metastatic sites with stereotactic radiotherapy provides a benefit in terms of progression-free survival and specific survival compared with no treatment or incomplete treatment [516]. A 2019 meta-analysis of 1602 oligometastatic patients treated with stereotactic radiotherapy reported a 1-year local control rate of 89.1% and 90.1% for extracranial and intracranial metastases respectively, and 1-year overall survival of 86.8% and 49.7%. The tolerability of stereotactic radiotherapy was acceptable, with a grade 3–4 toxicity of 0.7% at 1 year. Different radiotherapy regimens were used: 1 fraction of 25 Gy, 36 Gy in 3 fractions or 40 Gy in 5 fractions. However, the inclusion criteria were heterogeneous (oligometastatic, oligoprogressive), with heterogeneous and suboptimal concomitant systemic treatment protocols [513].

In selected patients (a single metastasis, metachronous), stereotactic radiotherapy could make it possible in oligometastatic situations to delay the introduction of a first line of systemic treatment [511,517] by just over a year. A 1-year systemic treatment-free survival rate of 82% was reported in a phase II trial. In another trial published in 2022, Hannan et al. reported a 1-year systemic treatment-free rate of 91.3% [518].

12.3.3.2. In situations of oligoprogression. There may also be a role for stereotactic radiotherapy of metastases (one to 5 metastases), with the aim of delaying switching to a different line of systemic treatment. Several prospective multicenter phase II studies have reported a local control rate at 1 year ranging from 83 to 100% and a median time to change treatment line of around 12 months [514,517–519]. The GETUG-StORM-01 trial (NCT04299646) is currently being enrolled in patients receiving first- or second-line TKI or immunotherapy, with 1 to 3 oligoprogressive metastatic sites.

12.3.3.3. Radiotherapy and immunotherapy. The role of stereotactic radiotherapy is also being studied in the era of immunotherapy, with the hypothesis of an abscopal effect. Current data are based on retrospective studies or studies with a low level of evidence, with the limitations of small numbers and relatively short follow-up. Radiotherapy protocols (doses and fractions) and patient selection criteria have yet to be determined. Randomized trials are underway to determine the benefits of stereotactic radiotherapy for metastatic sites (RADVAX RCC, OligoRARE (NCT04498767), SABR-COMET-3 (NCT03866291), SABR-COMET 10 (NCT03721342)).

The single-arm NIVES trial studied nivolumab in second- and third-line metastatic disease, in combination with stereotactic radiotherapy to a single metastatic site. There was no evidence of benefit from combining radiotherapy with immunotherapy in this study [520]. Preliminary results from the RADVAX RCC trial, investigating the combination of nivolumab-ipilimumab with stereotactic radiotherapy at 1–2 metastatic sites (50 Gy in 5 fractions) in intermediate- and high-risk IMDC patients, were reported at ASCO 2020, with an objective response rate of 56% (Hammers et al.). The RAPPORT phase 1–2 trial analyzed the benefit of stereotactic radiotherapy (single 20 Gy fraction) to all metastatic sites (1–5 sites) followed by treatment with pembrolizumab in patients on 1st or 2nd lines of systemic therapy. The objective response rate was 63% with overall survival of 90 and 74% and progression-free survival of 60 and 45% at 1 and 2 years respectively, associated with grade ≥ 3 toxicity of 13% [521].

12.3.3.4. Specificity of brain metastases. Surgery or stereotactic radiotherapy gives similar or better results than panencephalic radiotherapy [522]. Panencephalic radiotherapy should be reserved for patients with numerous lesions or patients with a poor prognosis [523].

12.3.3.5. Management of systemic treatments during stereotactic radiotherapy. Continuation of anti-angiogenic treatment during radiotherapy does not appear to increase toxicity or the risk of complications [524,525]. In practice, and according to expert opinion, it is recommended that anti-angiogenic treatments be stopped during radiotherapy for visceral metastases and continued during treatment for bone metastases.

The morbidity of radiotherapy associated with checkpoint inhibitors appears to be acceptable (toxicity grade mostly ≤ 3). [526]. On the basis of expert opinion, it is not necessary to discontinue checkpoint inhibitors during radiotherapy treatment.

12.3.4. Radiofrequency and ablative treatments

Few data are available on the use of ablative treatments (radiofrequency (RF) or cryoablation) for metastases. The first retrospective studies focused on pulmonary, hepatic and adrenal sites, with 3-year local control rates of 77% to 91% for pulmonary and adrenal sites, and 3-year recurrence-free survival of 83% for hepatic sites [527–532]. RF can be considered for single or few metastases that are not accessible to surgery in patients with a good or intermediate prognosis. In the treatment of pulmonary metastases, the main complication is pneumothorax (42–89%), which requires pleural drainage in 7–25% of cases [528].

12.4. Medical treatments

12.4.1. Treatment of metastatic clear cell kidney cancer

12.4.1.1. Results of trials using immunotherapy combinations. Since the last CCAFU recommendations were published, several updates of the main phase 3 registration studies evaluating combinations of immunotherapies and anti-angiogenic agents have been published.

12.4.1.2. CheckMate-214 (NCT02231749), nivolumab plus ipilimumab versus sunitinib. The CheckMate 214 study is a prospective randomized phase 3 trial that evaluated the efficacy of the combination of nivolumab-ipilimumab versus sunitinib in first-line locally advanced or metastatic clear cell kidney cancer. Initial results from this study were published in April 2018 [533] and updated in October 2020 [534]. The latest analyses reported at ASCO GU 2024 confirm, with a median follow-up of 99.1 months in patients in the intermediate- and poor-risk groups, the superiority of the immunotherapy combination on overall survival (HR = 0.69; 46.7 vs. 26.0 months; $P < 0.0001$), progression-free survival (HR = 0.73, 0.61–0.87) and objective response rate (42% vs. 27%; $P = 0.0001$). The overall survival benefit was not significant for patients in the favourable risk group (HR = 0.82; 77.8 months vs. 66.7 months). There was also a complete response rate of 12% in the intermediate- and poor-risk patient population for the immunotherapy combination versus 3% for sunitinib. Finally, the median duration of response was achieved with 8.3 months versus 19.8 months for the sunitinib arm in the intermediate/poor prognosis group [535].

12.4.1.3. The Keynote-426 study (NCT02853331), pembrolizumab plus axitinib versus sunitinib. The Keynote-426 study is a prospective randomized phase 3 trial that evaluated the efficacy of the combination of pembrolizumab-axitinib versus sunitinib in first-line metastatic clear cell kidney cancer. The results of this study were published in March 2019 and updated in 2020 [480,536]. A further update of the study was published in 2023 with a median follow-up of 43 months. Progression-free survival remained unchanged (15.7 vs. 11.1 months, HR = 0.68, $P < 0.001$). Overall survival remained in favour of the combination arm (45.7 vs. 40.1 months, $P < 0.001$, HR = 0.73). The reported objective response rate was 60.4% for the combination arm, including 10% complete responses (vs. 3.5% for sunitinib). The median duration of response was 24 months versus 15 months in the pembrolizumab-axitinib arm versus sunitinib, respectively [537].

12.4.1.4. The CheckMate 9ER study (NCT03141177), nivolumab plus cabozantinib versus sunitinib. The CheckMate 9ER study is a prospective randomized phase 3 trial that evaluated the efficacy of the combination of nivolumab and cabozantinib versus sunitinib as first-line treatment for metastatic clear cell kidney cancer. The results of this study were published in 2021 [479]. The last update with a median follow-up of 55.6 months was at ASCO GU 2024. Progression-free survival remained unchanged (16.4 vs. 8.4 months, HR = 0.58 [0.49–0.70]). Overall survival favoured the combination arm (46.5 vs. 36.0 months, HR = 0.77 [0.63–0.95]). The objective response rate was 55.7% for the combination arm, including 13.6% complete responses (vs. 4.6% for sunitinib). Subgroup analyses reported no benefit in overall survival for patients in the favourable IMDC group (HR 1.10, 52.9 months vs. 58.9 months) with, however, an improvement in progression-free survival (HR = 0.69, 21.4 vs. 12.8 months) and a response rate of 66.2% with 16.2% complete responses [538].

12.4.1.5. The CLEAR study (NCT02811861), pembrolizumab plus lenvatinib versus everolimus plus lenvatinib versus sunitinib. The CLEAR study is a prospective randomized phase 3 trial that evaluated the efficacy of the combination of pembrolizumab and lenvatinib versus sunitinib versus everolimus and lenvatinib as first-line treatment for metastatic clear cell kidney cancer. The results of this study were published in March 2021 [482]. The latest update was reported with 49.8 months median follow-up at ASCO GU 2024. The combination of pembrolizumab and lenvatinib improved overall survival (HR = 0.79, 53.7 months vs. 54.3 months. $P = 0.0424$), progression-free survival (23.9 vs. 9.2 months; HR = 0.47; $P < 0.001$) and objective response rate (71.3% vs. 36.7%). The complete response rate was 18.3% vs. 4.8% for the sunitinib arm. Subgroup analyses reported no overall survival benefit for patients in the favourable IMDC arm (HR 0.94; 59.9 months vs. NR) with, however, an improvement in progression-free survival (HR = 0.50; 28.6 vs. 12.9 months) [539].

12.4.1.6. Recommendations for first-line treatment of metastatic disease. In patients with a good prognosis, the following combinations are recommended with a high level of evidence: pembrolizumab-axitinib, pembrolizumab-levatinib and nivolumab-cabozantinib. There is no preferred combination of anti-PD1 and anti-VEGFR inhibitors, and comparisons between studies are not recommended. Overall survival data in subgroup analysis for each of the combinations show that overall survival is not superior to sunitinib. However, progression-free survival as well as objective response rates and complete response rates are in favour of the combinations. In patients with a contraindication to immunotherapy, pazopanib or sunitinib are the recommended treatments. Close monitoring with deferred treatment is an option to be discussed by the PCR in this population, whose course is often indolent.

In patients with an intermediate or poor prognosis, the following combinations are recommended with the same high level of evidence: nivolumab-ipilimumab, pembrolizumab-axitinib, pembrolizumab-levatinib and nivolumab-cabozantinib. If immunotherapy is contraindicated, pazopanib and sunitinib are the recommended treatments (Table of recommendations 24).

Recommendations for second-line treatment of metastatic disease. In the event of failure of anti-VEGFR treatment, two molecules are recommended: nivolumab [540] and cabozantinib [541]. Axitinib and sorafenib are also possible options.

After double immunotherapy or a combination of immunotherapy and TKIs, there are no randomized data to define the best therapeutic sequence. Treatment options are based on the sequential use of anti-VEGFR targeted therapies not previously used (expert opinion).

The CONTACT 03 study evaluated the value of maintaining immunotherapy after failure of a previous line including immunotherapy. The study randomized 522 patients with metastatic clear cell renal cell carcinoma who had failed prior immunotherapy to cabozantinib (60 mg/

Recommendation Table 24

Summary of recommendations for 1st line systemic treatments in clear cell MRC.

IMDC prognostic classification	1st line	
Favorable	Standard	pembrolizumab + axitinib nivolumab + cabozantinib pembrolizumab + lenvatinib
	Options	sunitinib pazopanib
Intermediate	Standard	nivolumab + ipilimumab pembrolizumab + axitinib nivolumab + cabozantinib pembrolizumab + lenvatinib
	Options	sunitinib pazopanib
Poor	Standard	nivolumab + ipilimumab pembrolizumab + axitinib nivolumab + cabozantinib pembrolizumab + lenvatinib
	Options	sunitinib pazopanib

d) monotherapy ($n = 263$) or a combination of cabozantinib (60 mg/d) and atezolizumab (1200 mg/3wk). The primary objective was not met with a progression-free survival of 10.8 months for the combination arm and 10.6 months for the cabozantinib alone arm [542]. The study was negative, suggesting that there is no benefit in continuing immunotherapy in this setting. Other studies are underway, in particular the TiNivo-2 study, the results of which are expected shortly. In view of the initial results, this strategy is not currently recommended (expert opinion) (Table of recommendations 25).

12.4.2. Treatment of metastatic non-clear cell renal cell carcinoma

12.4.2.1. Main prospective studies evaluating the therapeutic management of metastatic non-clear cell renal cell carcinoma. We report the results of the main prospective studies that have investigated the efficacy of targeted therapies and immunotherapy alone or in combination with targeted therapies. These studies are mostly non-randomized, small in number and heterogeneous in terms of the different histological subtypes and the aggressiveness of the cancer at diagnosis. However, they represent the most objective data available.

12.4.2.1.1. Studies evaluating targeted therapies alone.

12.4.2.1.1.1. CALYPSO study. The CALYPSO study is a prospective, single-arm phase 2 trial which investigated the efficacy of durvalumab in combination with the MET inhibitor savolitinib in patients with metastatic papillary cancer. The study included 41 patients and the objective response rate was 29%. Median progression-free survival was 4.9 months (95% CI, 2.5–10) and overall survival was 14.1 months (95% CI, 7.3–30.7). Patients with MET gene alteration had a higher response rate (progression-free survival of 12 months (95% CI 7.3–30.7) and overall survival of 27.4 months (95% CI 9.3 – not achieved) [543].

12.4.2.1.1.2. Study KNOWLEDGE. The SAVOIR study is a multicenter randomized phase 3 trial that compared the efficacy of savolitinib versus sunitinib in patients with tubulopapillary carcinoma with MET gene alteration. The study included 33 patients in the savolitinib arm and 27 patients in the sunitinib arm. The objective response rate was 27% in

Recommendation Table 25

Summary of recommendations for 2nd line systemic treatments for clear cell MRC.

Treatment received in 1 st Line	2 nd Line	3 rd Line
sunitinib pazopanib	cabozantinib nivolumab	nivolumab cabozantinib
pembrolizumab + axitinib pembrolizumab + lenvatinib nivolumab + cabozantinib	Anti-VEGF TKI not used in 1 st line	Other targeted therapy
nivolumab + ipilimumab	Anti-VEGF TKI	Other targeted therapy

the savolitinib arm and 7% in the sunitinib arm. Median progression-free survival was 7 months (95% CI, 2.8 – not achieved) in the savolitinib arm and 5.6 months (95% CI, 4.1–6.9) in the sunitinib arm ($P = 0.31$). Savolitinib was better tolerated than sunitinib. The study was stopped early due to the lack of a positive signal in favour of savolitinib [544].

12.4.2.1.1.3. PAMMET study. SWOG’s randomized phase 2 study, PAMMET, evaluated cabozantinib ($n = 44$) versus sunitinib ($n = 28$) versus savolitinib ($n = 29$) and crizotinib ($n = 28$) in metastatic papillary renal cell carcinoma. The arms evaluating savolitinib, a specific MET inhibitor, and crizotinib were discontinued due to futility. The primary endpoint of progression-free survival was significantly improved by cabozantinib (9 months vs. 5.6 months, HR = 0.60 (95% CI 0.37–0.97), $P = 0.02$). Cabozantinib was associated with a higher response rate (23% vs. 4%) than sunitinib. Overall survival was not significantly improved due to lack of power (20 months vs. 16 months) [545].

12.4.2.1.1.4. ASPEN study. The ASPEN study is a randomized phase 2 trial that investigated the efficacy of sunitinib versus everolimus in patients with metastatic non-clear cell renal cell carcinoma. This study included 108 patients, 76 (70.3%) with tubulo-papillary carcinoma and 16 (14.8%) with chromophobe carcinoma. Sunitinib was associated with superior progression-free survival compared with everolimus (8.3 months [5.8–11.4] vs. 5.6 months [5.5–6.0]; HR: 1.41 [80% CI 1.03–1.92]; $P = 0.16$). There was heterogeneity in response to treatment across histological subtypes with a better response rate to sunitinib in papillary carcinomas [546].

12.4.2.1.1.5. AXIPAP study. The AXIPAP study is a prospective, single-arm, multicenter phase 2 trial coordinated by GETUG, which investigated the efficacy of axitinib in first-line metastatic papillary carcinoma. This study included 44 patients. The objective response rate was 28.6% (12 partial responses). Median progression-free survival was 6.6 months (95% CI, 5.5–9.2) and overall survival was 18.9 months (95% CI, 12.8 – not reached) [547].

12.4.2.1.1.6. ESPN study. The ESPN study is a prospective randomized phase 2 trial that compared the efficacy of sunitinib versus everolimus with group switching at the time of progression in patients with metastatic non-clear cell renal cell carcinoma. The study included 68 patients, 27 with tubulopapillary carcinoma and 12 with chromophobe carcinoma. The objective response rate was 9% in first-line treatment with sunitinib and 2.8% in first-line treatment with everolimus. First-line progression-free survival was 6.1 months for sunitinib and 4.1 months for everolimus ($P = 0.6$) [548].

12.4.2.1.1.7. RAPTOR study. The RAPTOR study is a multicenter, single-arm, phase 2 trial which evaluated the efficacy of everolimus in first-line metastatic disease in patients with papillary carcinoma. The study

included 92 patients. The objective response rate was 1% (one partial response). Median progression-free survival was 4.1 months (95% CI 3.6–5.5) [549].

12.4.2.1.1.8. SUPAP study. The SUPAP study is a single-arm, multicenter, phase 2 GETUG study that evaluated the efficacy of sunitinib in patients with metastatic tubulopapillary cancer (PTC). The study enrolled 51 patients, including 14 patients with type 1 PTC and 47 patients with type 2 PTC. The objective response rate was 13% for type 1 PTC and 11% for type 2 PTC. Median progression-free survival for type 1 and type 2 PTC was 6.6 months (95% CI 2.8–14.8) and 5.5 months (95% CI 3.8–7.1), respectively [550].

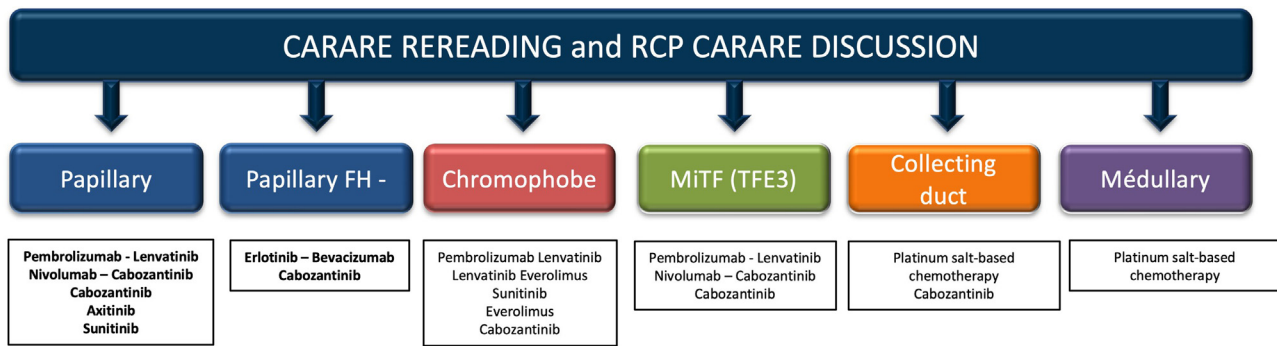
12.4.2.1.2. Study evaluating immunotherapy alone.

12.4.2.1.2.1. KEYNOTE 427 (cohort B). KEYNOTE 427 is a prospective, single-arm study investigating the efficacy of single-agent pembrolizumab as first-line therapy in patients with metastatic renal cell carcinoma. Cohort B studied non-clear cell RCC. The study included 165 patients, 71.5% of whom had tubulopapillary carcinomas, 12.7% chromophobe carcinomas and 15.8% unclassified carcinomas. The objective response rate was 26.7% (28.8% for tubulopapillary carcinomas, 9.5% for chromophobe carcinomas and 30.8% for unclassified carcinomas). Median progression-free survival for the overall cohort, papillary and chromophobe subtypes were 4.2 months (95% CI, 2.9–5.6), 5.5 months (95% CI 3.9–6.9) and 3.9 months (95% CI 2.6–6.9), respectively [551].

12.4.2.1.3. Studies evaluating targeted therapies in combination with immunotherapy.

12.4.2.1.3.1. Study Keynote B-61. Keynote B-61 is a prospective, non-randomized, single-arm phase 2 study investigating the efficacy and safety of the combination of pembrolizumab and lenvatinib as first-line therapy in metastatic non-clear cell renal cell carcinoma. The study included 158 patients with a median follow-up of 14.9 months. The disease control rate was 82% and the objective response rate was 49%, including 6% complete response and 44% partial response. The progression-free survival rate was 18 months (95% CI [14 – not achieved]). Grade 3–4 adverse events occurred in 51% of patients, the most common being hypertension (23%). Patient populations were composed of 93 (59%) papillary carcinomas, 29 (18.3%) chromophobe carcinomas, 21 (13%) unclassified carcinomas, 6 (3.7%) translocation carcinomas and 9 (5.6%) other histologies. Patients with collecting-tube carcinoma (Bellini carcinoma) were excluded from this study. Response to treatment was similar in all histological subtypes but this should be interpreted with caution due to the heterogeneity of the population and the small number of patients [552].

12.4.2.1.3.2. Nivolumab plus cabozantinib. This prospective, single-arm, single-center study investigated the efficacy of cabozantinib in



Non-hierarchical therapeutic options in the absence of randomized phase 3 studies and direct comparison

Fig. 4. CCAFU recommendations for the treatment of metastatic non-clear cell renal cell cancer.

combination with nivolumab in first- or second-line metastatic disease (after anti-VEGF) in patients with metastatic non-clear cell renal cell carcinoma. The study enrolled 47 patients, including 40 patients with tubulopapillary carcinoma and 7 patients with chromophobe carcinoma. In patients with tubulopapillary carcinoma, the objective response rate was 48% (19 partial responses) and progression-free survival was 12.5 months (95% CI, 6.3–16.4). In patients with chromophobe carcinoma, no objective response was observed and progression-free survival could not be determined due to the small size of the cohort [553].

12.4.2.1.4. Studies specific to renal cell carcinoma of the collecting tubes.

12.4.2.1.4.1. Gemcitabine combined with cisplatin or carbaplatin. This prospective single-arm GETUG trial evaluated the efficacy of gemcitabine combined with cisplatin or carboplatin (in cases of renal failure) in patients with metastatic collecting-tube cancer. The study included 23 patients, 6 (26%) of whom had an objective response to treatment (one complete response and 4 partial responses). Median progression-free and overall survival were 7.1 (95% CI 3–11.3) and 10.5 (95% CI 3.8–17.1) months [554].

12.4.2.1.4.2. Gemcitabine combined with Sorafenib and Cisplatin. This prospective single-arm phase 2 trial evaluated the combination of cisplatin, gemcitabine and sorafenib in 26 patients with metastatic collecting-tube carcinoma. The objective response rate was 30.8%. Median progression-free and overall survival were 8.8 months (95% CI: 6.7–10.9) and 12.5 months (95% CI: 9.6–15.4), respectively [555].

12.4.2.1.4.3. Bonzai study. The Bonzai study is a prospective, single-arm, phase 2 trial which evaluated the efficacy of cabozantinib (60 mg/day) in patients with metastatic collecting-tube carcinoma. The study included 25 patients, 23 of whom were treated. The objective response rate was 35% (one complete response and 7 partial responses). Median progression-free and overall survival were 4 months (95% CI: 3–13) and 7 months (95% CI: 3–31) [556].

12.4.2.1.4.4. BEVABEL study. The BEVABEL study is a single-arm phase 2 GETUG trial which evaluated the efficacy of the combination of gemcitabine, cisplatin and bevacizumab in patients with collecting-tube carcinoma. The study included 34 patients and was stopped early due to lack of efficacy signals and toxicity (82% grade 3–4 toxicity and 2 grade 5). Median overall survival was 11.1 months (95% CI: 7.6–24.2) [557].

12.4.2.2. CARARE multidisciplinary consultation meeting. Given the difficulties of histological diagnosis, it is recommended that a specific anatomopathological review be proposed to the CARARE network of French experts. With regard to systemic management, it is proposed that cases be discussed at the national CARARE RCP and that priority be given to including patients in clinical trials. The CARARE virtual RCP is organized every 15 days. The quorum is made up of two pathologists, two oncologists and two urologists (Recommendation Table 26, Fig. 4).

Recommendation Table 26

Management of non-clear cell MRC.

Recommendations	Grade
A centralized review by the CARARE network of expert pathologists is recommended.	Low
It is recommended that files be discussed at the CARARE RCP.	Low
It is recommended that inclusion in a therapeutic trial be proposed as a priority	High
The treatment options are shown in Figure 4.	Low

Disclosure of interest

- Pierre Bigot: MSD, Ipsen, Bms, Astellas, Pfizer.
- Philippe Barthelemy: Ipsen, Bms, Pfizer, Astellas, Janssen, Cilag, Amgen, Bayer, Gilead, Astrazeneca, Novartis.
- Alexandre Ingels: Ipsen, Bms, Msd, Bayer, Astellas, Intuitive.
- Caroline Pettenati: Ipsen, Bms, Astellas, Msd, Janssen.
- Jean Michel Correas: Bracco, GUerbet, Johnson et Johnson, Canon, Supersonic, imagine, General electric, Fujifilm, Siemens, Philips.
- Nathalie Rioux Leclercq: Ipsen, Bms, Astellas, Msd, Janssen.
- Stéphane De Vergie: Astellas, Ipsen, Bms, Msd, Janssen, Intuitive, Lamidey Noury.
- Romain Boissier: Ipsen, Merck, Bms, Astellas, Novartis, Bayer, AstraZenca.
- Nicolas Doumerc: Intuitive Surgical, Ipsen, Msd, Pierre Fabre, Ferring.
- Morgan Rouprêt: Roche, Bms, Ipsen, Msd, Novartis, Bayer, Astellas, Pfizer, Janssen, Provepharm, Intuitive, Medtronics, Photocure Curium.
- Jean Christophe Bernhard: Ipsen, Bms, Msd, Fujifilm, Intuitive.
- Idir Ouzaïd: Bms, Astellas, Msd, Jansen, Ipsen, Bayer, Novartis.

References

- Capitanio U, Bensalah K, Bex A, Boorjian SA, Bray F, Coleman J, et al. Epidemiology of renal cell carcinoma. *Eur Urol* 2019;75:74–84, doi:http://dx.doi.org/10.1016/j.eururo.2018.08.036.
- Huang J, Leung DK-W, Chan EO-T, Lok V, Leung S, Wong I, et al. A global trend analysis of kidney cancer incidence and mortality and their associations with smoking, alcohol consumption, and metabolic syndrome. *Eur Urol Focus* 2022;8:200–9, doi:http://dx.doi.org/10.1016/j.euf.2020.12.020.
- Wong MCS, Huang J, Wang J, Chan PSF, Lok V, Chen X, et al. Global, regional and time-trend prevalence of central obesity: a systematic review and meta-analysis of 13.2 million subjects. *Eur J Epidemiol* 2020;35:673–83, doi:http://dx.doi.org/10.1007/s10654-020-00650-3.
- Scelo G, Hofmann JN, Banks RE, Bigot P, Bhatt RS, Cancel-Tassin G, et al. International cancer seminars: a focus on kidney cancer. *Ann Oncol* 2016;27:1382–5, doi:http://dx.doi.org/10.1093/annonc/mdw186.
- Lapôte-Ledoux B, Remontet L, Uhry Z, Dantony E, D’Almeida T. Incidence of the main cancers in metropolitan France in 2023 and trends since 1990. *Bull Epidemiol Hebd* 2023;12:188–204.

- [6] Defossez G, Le Guyader-Peyro S, Uhry Z, Grosclaude P, Colonna M, Dantony E, et al. National estimates of cancer incidence and mortality in metropolitan France between 1990 and 2018 n.d.
- [7] Bukavina L, Bensalah K, Bray F, Carlo M, Challacombe B, Karam JA, et al. Epidemiology of renal cell carcinoma: 2022 update. *Eur Urol* 2022;82:529–42, doi: <https://dx.doi.org/10.1016/j.eururo.2022.08.019>.
- [8] Znaor A, Lortet-Tieulent J, Laversanne M, Jemal A, Bray F. International variations and trends in renal cell carcinoma incidence and mortality. *Eur Urol* 2015;67:519–30, doi: <https://dx.doi.org/10.1016/j.eururo.2014.10.002>.
- [9] Scelo G, Li P, Chanudet E, Muller DC. Variability of sex disparities in cancer incidence over 30 years: the striking case of kidney cancer. *Eur Urol Focus* 2018;4:586–90, doi: <https://dx.doi.org/10.1016/j.euf.2017.01.006>.
- [10] Haas NB, Nathanson KL. Hereditary renal cancer syndromes. *Adv Chronic Kidney Dis* 2014;21:81–90, doi: <https://dx.doi.org/10.1053/j.ackd.2013.10.001> [10.1053/j.ackd.2013.10.001].
- [11] Du W, Guo K, Jin H, Sun L, Ruan S, Song Q. Association between metabolic syndrome and risk of renal cell cancer: a meta-analysis. *Front Oncol* 2022;12:928619, doi: <https://dx.doi.org/10.3389/fonc.2022.928619>.
- [12] Graff RE, Wilson KM, Sanchez A, Chang SL, McDermott DF, Choueiri TK, et al. Obesity in relation to renal cell carcinoma incidence and survival in three prospective studies. *Eur Urol* 2022;82:247–51, doi: <https://dx.doi.org/10.1016/j.eururo.2022.04.032>.
- [13] Deng Z, Hajihosseini M, Moore JX, Khan S, Graff RE, Bondy ML, et al. Lifetime body weight trajectories and risk of renal cell cancer: a large U.S. prospective cohort study. *Cancer Epidemiol Biomarkers Prev* 2023;32:1651–9, doi: <https://dx.doi.org/10.1158/1055-9965.EPI-23-0668>.
- [14] Al-Bayati O, Hasan A, Pruthi D, Kaushik D, Liss MA. Systematic review of modifiable risk factors for kidney cancer. *Eur Urol Oncol* 2019;37:359–71, doi: <https://dx.doi.org/10.1016/j.urolonc.2018.12.008>.
- [15] Alcalá K, Mariosa D, Smith-Byrne K, Nasrollahzadeh Nesheli D, Carreras-Torres R, Ardanaz Aicua E, et al. The relationship between blood pressure and risk of renal cell carcinoma. *Int J Epidemiol* 2022;51:1317–27, doi: <https://dx.doi.org/10.1093/ije/dyac042>.
- [16] Macleod LC, Hotaling JM, Wright JL, Davenport MT, Gore JL, Harper J, et al. Risk factors for renal cell carcinoma in the VITAL study. *J Urol* 2013;190:1657–61, doi: <https://dx.doi.org/10.1016/j.juro.2013.04.130>.
- [17] Liu X, Peveri G, Bosetti C, Bagnardi V, Specchia C, Gallus S, et al. Dose-response relationships between cigarette smoking and kidney cancer: a systematic review and meta-analysis. *Crit Rev Oncol Hematol* 2019;142:86–93, doi: <https://dx.doi.org/10.1016/j.critrevonc.2019.07.019>.
- [18] Christensson A, Savage C, Sjøberg DD, Cronin AM, Frank O'Brien M, Lowrance W, et al. Association of cancer with moderately impaired renal function at baseline in a large, representative, population-based cohort followed for up to 30 years. *Int J Cancer* 2013;133:1452–8, doi: <https://dx.doi.org/10.1002/ijc.28144>.
- [19] Pan H-C, Sun C-Y, Wu I-W, Tsai T-L, Sun C-C, Lee C-C. Higher risk of malignant neoplasms in young adults with end-stage renal disease receiving haemodialysis: a nationwide population-based study. *Nephrology (Carlton)* 2019;24:1165–71, doi: <https://dx.doi.org/10.1111/nep.13555>.
- [20] Lowrance WT, Ordoñez J, Udaltsova N, Russo P, Go AS. CKD and the risk of incident cancer. *J Am Soc Nephrol* 2014;25:2327, doi: <https://dx.doi.org/10.1681/ASN.2013060604>.
- [21] Åkerlund J, Holmberg E, Lindblad P, Stendahl M, Ljungberg B, Thorstenson A, et al. Increased risk for renal cell carcinoma in end stage renal disease – a population-based case-control study. *Scand J Urol* 2021;55:209–14, doi: <https://dx.doi.org/10.1080/21681805.2021.1900387>.
- [22] Decree No. 2021-636 of 20 May 2021 revising and supplementing the tables of occupational diseases appended to Book IV of the Social Security Code. 2021.
- [23] Suttinon O, Luepromchai E, Müller R. Cometabolism of trichloroethylene: concepts, limitations and available strategies for sustained biodegradation. *Rev Environ Sci Biotechnol* 2013;12:99–114, doi: <https://dx.doi.org/10.1007/s11157-012-9291-x>.
- [24] Order of 4 May 1984 prohibiting the sale of trichloroethylene to minors and prohibiting preparations containing more than 5%. 1984.
- [25] Commission Regulation (EU) No 348/2013 of 17 April 2013 amending Annex XIV to Regulation (EC) No 1907/2006 of the European Parliament and of the Council on the Registration, Evaluation, Authorisation and Restriction of Chemicals (REACH) Text with EEA relevance 2013108..
- [26] Moore SC, Lee I-M, Weiderrass E, Campbell PT, Sampson JN, Kitahara CM, et al. Association of leisure-time physical activity with risk of 26 types of cancer in 1.44 million adults. *JAMA Intern Med* 2016;176:816–25, doi: <https://dx.doi.org/10.1001/jamainternmed.2016.1548>.
- [27] Jia L, Jia Q, Shang Y, Dong X, Li L. Vitamin C intake and risk of renal cell carcinoma: a meta-analysis. *Sci Rep* 2015;5:17921, doi: <https://dx.doi.org/10.1038/srep17921>.
- [28] Tahbaz R, Schmid M, Merseburger AS. Prevention of kidney cancer incidence and recurrence: lifestyle, medication and nutrition. *Curr Opin Urol* 2018;28:62–79, doi: <https://dx.doi.org/10.1097/MOU.0000000000000454>.
- [29] Zhang S, Jia Z, Yan Z, Yang J. Consumption of fruits and vegetables and risk of renal cell carcinoma: a meta-analysis of observational studies. *Oncotarget* 2017;8:27892–903, doi: <https://dx.doi.org/10.18632/oncotarget.15841>.
- [30] Liao Z, Fang Z, Gou S, Luo Y, Liu Y, He Z, et al. The role of diet in renal cell carcinoma incidence: an umbrella review of meta-analyses of observational studies. *BMC Med* 2022;20:39, doi: <https://dx.doi.org/10.1186/s12916-021-02229-5>.
- [31] Campi R, Rebez G, Klatte T, Roussel E, Ouizad I, Ingels A, et al. Effect of smoking, hypertension and lifestyle factors on kidney cancer – perspectives for prevention and screening programmes. *Nat Rev Urol* 2023;20:669–81, doi: <https://dx.doi.org/10.1038/s41585-023-00781-8>.
- [32] Diana P, Klatte T, Amparore D, Bertolo R, Carbonara U, Erdem S, et al. Screening programs for renal cell carcinoma: a systematic review by the EAU young academic urologists renal cancer working group. *World J Urol* 2023;41:929–40, doi: <https://dx.doi.org/10.1007/s00345-022-03993-6>.
- [33] Campi R, Stewart GD, Staehler M, Dabestani S, Kuczyk MA, Shuch BM, et al. Novel liquid biomarkers and innovative imaging for kidney cancer diagnosis: what can be implemented in our practice today? A systematic review of the literature. *Eur Urol Oncol* 2021;4:22–41, doi: <https://dx.doi.org/10.1016/j.euo.2020.12.011>.
- [34] Rossi SH, Klatte T, Usher-Smith J, Stewart GD. Epidemiology and screening for renal cancer. *World J Urol* 2018;36:1341–53, doi: <https://dx.doi.org/10.1007/s00345-018-2286-7>.
- [35] Usher-Smith JA, Godoy A, Burge SW, Burbidge S, Cartledge J, Crosbie PAJ, et al. The Yorkshire Kidney Screening Trial (YKST): protocol for a feasibility study of adding non-contrast abdominal CT scanning to screen for kidney cancer and other abdominal pathology within a trial of community-based CT screening for lung cancer. *BMJ Open* 2022;12:e063018, doi: <https://dx.doi.org/10.1136/bmjopen-2022-063018>.
- [36] Harrison H, Wood A, Pennells L, Rossi SH, Callister M, Cartledge J, et al. Estimating the effectiveness of kidney cancer screening within lung cancer screening programmes: a validation in UK biobank. *Eur Urol Oncol* 2023;6:351–3, doi: <https://dx.doi.org/10.1016/j.euo.2023.02.012>.
- [37] Daniels AB, Tirosh A, Huntoon K, Mehta GU, Spiess PE, Friedman DL, et al. Guidelines for surveillance of patients with von Hippel-Lindau disease: consensus statement of the International VHL Surveillance Guidelines Consortium and VHL Alliance. *Cancer* 2023;129:2927–40, doi: <https://dx.doi.org/10.1002/cncr.34896>.
- [38] Forde C, Lim DHK, Alwan Y, Burghel G, Butland L, Cleaver R, et al. Hereditary leiomyomatosis and renal cell cancer: clinical, molecular, and screening features in a cohort of 185 affected individuals. *Eur Urol Oncol* 2020;3:764–72, doi: <https://dx.doi.org/10.1016/j.euo.2019.11.002>.
- [39] Åkerlund J, Holmberg E, Lindblad P, Stendahl M, Ljungberg B, Thorstenson A, et al. Increased risk for renal cell carcinoma in end stage renal disease – a population-based case-control study. *Scand J Urol* 2021;55:209–14, doi: <https://dx.doi.org/10.1080/21681805.2021.1900387>.
- [40] Goujon A, Verhoest G, Sallusto F, Branchereau J, Boutin J-M, Bessedé T, et al. [Renal cell carcinoma in candidates for renal transplantation and recipients of a kidney transplant: the French guidelines from CTAUFU]. *Prog Urol* 2021;31:18–23, doi: <https://dx.doi.org/10.1016/j.purol.2020.04.030>.
- [41] Jayson M, Sanders H. Increased incidence of serendipitously discovered renal cell carcinoma. *Urology* 1998;51:203–5, doi: [https://dx.doi.org/10.1016/s0090-4295\(97\)00506-2](https://dx.doi.org/10.1016/s0090-4295(97)00506-2).
- [42] Sidhu PS, Cantisani V, Dietrich CF, Gilja OH, Saftoiu A, Bartels E, et al. The EFSUMB guidelines and recommendations for the Clinical Practice of Contrast-Enhanced Ultrasound (CEUS) in non-hepatic applications: update 2017 (short version). *Ultraschall Med* 2018;39:154–80, doi: <https://dx.doi.org/10.1055/s-0044-101254>.
- [43] Lan D, Qu H-C, Li N, Zhu X-W, Liu Y-L, Liu C-L. The value of contrast-enhanced ultrasonography and contrast-enhanced CT in the diagnosis of malignant renal cystic lesions: a meta-analysis. *PLoS One* 2016;11:e0155857, doi: <https://dx.doi.org/10.1371/journal.pone.0155857>.
- [44] Rübenthaler J, Negrão de Figueiredo G, Mueller-Peltzer K, Clevert DA. Evaluation of renal lesions using contrast-enhanced ultrasound (CEUS): a 10-year retrospective European single-centre analysis. *Eur Radiol* 2018;28:4542–9, doi: <https://dx.doi.org/10.1007/s00330-018-5504-1>.
- [45] Thomsen HS, Bush WH. Adverse effects of contrast media: incidence, prevention and management. *Drug Saf* 1998;19:313–24, doi: <https://dx.doi.org/10.2165/00002018-199819040-00006>.
- [46] van der Molen AJ, Reimer P, Dekkers IA, Bongartz G, Bellin M-F, Bertolotto M, et al. Post-contrast acute kidney injury – part 1: definition, clinical features, incidence, role of contrast medium and risk factors: recommendations for updated ESUR Contrast Medium Safety Committee guidelines. *Eur Radiol* 2018;28:2845–55, doi: <https://dx.doi.org/10.1007/s00330-017-5246-5>.
- [47] van der Molen AJ, Reimer P, Dekkers IA, Bongartz G, Bellin M-F, Bertolotto M, et al. Post-contrast acute kidney injury. Part 2: risk stratification, role of hydration and other prophylactic measures, patients taking metformin and chronic dialysis patients: recommendations for updated ESUR Contrast Medium Safety Committee guidelines. *Eur Radiol* 2018;28:2856–69, doi: <https://dx.doi.org/10.1007/s00330-017-5247-4>.
- [48] Staful F, Bertolotto M, Thomsen HS, Pozzato G, Ugolini D, Bellin M-F, et al. Iodine-based contrast media, multiple myeloma and monoclonal gammopathies: literature review and ESUR Contrast Media Safety Committee guidelines. *Eur Radiol* 2018;28:683–91, doi: <https://dx.doi.org/10.1007/s00330-017-5023-5>.
- [49] Kim JI, Cho JY, Moon KC, Lee HJ, Kim SH. Segmental enhancement inversion at biphasic multidetector CT: characteristic finding of small renal oncocytoma. *Radiology* 2009;252:441–8, doi: <https://dx.doi.org/10.1148/radiol.25220811180>.
- [50] Guzzo TJ, Pierorazio PM, Schaeffer EM, Fishman EK, Allaf ME. The accuracy of multidetector computerized tomography for evaluating tumor thrombus in patients with renal cell carcinoma. *J Urol* 2009;181:486–90, doi: <https://dx.doi.org/10.1016/j.juro.2008.10.040> [discussion 491].
- [51] Bosniak MA. The Bosniak renal cyst classification: 25 years later. *Radiology* 2012;262:781–5, doi: <https://dx.doi.org/10.1148/radiol.11111595>.
- [52] Mileto A, Nelson RC, Paulson EK, Marin D. Dual-energy MDCT for imaging the renal mass. *AJR Am J Roentgenol* 2015;204:W640–7, doi: <https://dx.doi.org/10.2214/AJR.14.14094>.
- [53] Camlıdag İ, Nural MS, Danacı M, Özden E. Usefulness of rapid kV-switching dual energy CT in renal tumor characterization. *Abdom Radiol (NY)* 2019;44:1841–9, doi: <https://dx.doi.org/10.1007/s00261-019-01897-5>.
- [54] Sadoughi N, Krishna S, Macdonald DB, Chatelain R, Flood TA, McInnes MDF, et al. Diagnostic accuracy of attenuation difference and iodine concentration thresholds at rapid-kilovoltage-switching dual-energy CT for detection of enhancement in renal

- masses. *AJR Am J Roentgenol* 2019;213:619–25, doi:http://dx.doi.org/10.2214/AJR.18.20990.
- [55] Dai C, Cao Y, Jia Y, Ding Y, Sheng R, Zeng M, et al. Differentiation of renal cell carcinoma subtypes with different iodine quantification methods using single-phase contrast-enhanced dual-energy CT: areal vs. volumetric analyses. *Abdom Radiol (NY)* 2018;43:672–8, doi:http://dx.doi.org/10.1007/s00261-017-1253-x.
- [56] Stehlé T, Wei F, Brabant S, Luciani A, Grimbert P, Prié D, et al. Glomerular filtration rate measured based on iomeprol clearance assessed at CT urography in living kidney donor candidates. *Radiology* 2023;309:e230567, doi:http://dx.doi.org/10.1148/radiol.230567.
- [57] Reizine E, Blain M, Pescatori L, Longère B, Ingels A, Boughamni W, et al. Applicability of Bosniak 2019 for renal mass classification on portal venous phase at the era of spectral CT imaging using rapid kV-switching dual-energy CT. *Eur Radiol* 2024;34:1816–24, doi:http://dx.doi.org/10.1007/s00330-023-10145-w.
- [58] Zhang H, Li F, Jing M, Xi H, Zheng Y, Liu J. Nomogram combining pre-operative clinical characteristics and spectral CT parameters for predicting the WHO/ISUP pathological grading in clear cell renal cell carcinoma. *Abdom Radiol (NY)* 2024;49:1185–93, doi:http://dx.doi.org/10.1007/s00261-024-04199-7.
- [59] Liang X, Xue C, Huang X, Wei J, Zhou J. Value of energy spectrum CT parameters in the differential diagnosis of high-grade clear cell renal cell carcinoma and type II papillary renal cell carcinoma. *Acta Radiol* 2022;63:545–52, doi:http://dx.doi.org/10.1177/02841851211002830.
- [60] Schieda N, Kiehl AZ, Al Dandan O, McInnes MDF, Flood TA. Ten uncommon and unusual variants of renal angiomyolipoma (AML): radiologic-pathologic correlation. *Clin Radiol* 2015;70:206–20, doi:http://dx.doi.org/10.1016/j.crad.2014.10.001.
- [61] Kutikov A, Uzzo RG. The R.E.N.A.L. nephrometry score: a comprehensive standardized system for quantitating renal tumor size, location and depth. *J Urol* 2009;182:844–53, doi:http://dx.doi.org/10.1016/j.juro.2009.05.035.
- [62] Wagner B, Drel V, Gorin Y. Pathophysiology of gadolinium-associated systemic fibrosis. *Am J Physiol Renal Physiol* 2016;311:F1–F11, doi:http://dx.doi.org/10.1152/ajprenal.00166.2016.
- [63] Schieda N, van der Pol CB, Moosavi B, McInnes MDF, Mai KT, Flood TA. Intracellular lipid in papillary renal cell carcinoma (pRCC): T2 weighted (T2W) MRI and pathologic correlation. *Eur Radiol* 2015;25:2134–42, doi:http://dx.doi.org/10.1007/s00330-015-3610-x.
- [64] Cornelis F, Grenier N. Multiparametric magnetic resonance imaging of solid renal tumors: a practical algorithm. *Semin Ultrasound CT MR* 2017;38:47–58, doi:http://dx.doi.org/10.1053/j.sult.2016.08.009.
- [65] de Leon AD, Kapur P, Pedrosa I. Radiomics in kidney cancer: MR imaging. *Magn Reson Imaging Clin N Am* 2019;27:1–13, doi:http://dx.doi.org/10.1016/j.mric.2018.08.005.
- [66] Lopes Vendrami C, Parada Villavicencio C, DeJulio TJ, Chatterjee A, Casalino DD, Horowitz JM, et al. Differentiation of solid renal tumors with multiparametric MR imaging. *Radiographics* 2017;37:2026–42, doi:http://dx.doi.org/10.1148/rg.2017170039.
- [67] Karlo CA, Donati OF, Burger IA, Zheng J, Moskowitz CS, Hricak H, et al. MR imaging of renal cortical tumours: qualitative and quantitative chemical shift imaging parameters. *Eur Radiol* 2013;23:1738–44, doi:http://dx.doi.org/10.1007/s00330-012-2758-x.
- [68] Galmiche C, Bernhard J-C, Yacoub M, Ravaud A, Grenier N, Cornelis F. Is multiparametric MRI useful for differentiating oncocytomas from chromophobe renal cell carcinomas? *AJR Am J Roentgenol* 2017;208:343–50, doi:http://dx.doi.org/10.2214/AJR.16.16832.
- [69] Ludwig DR, Ballard DH, Shetty AS, Siegel CL, Yano M. Apparent diffusion coefficient distinguishes malignancy in T1-hyperintense small renal masses. *AJR Am J Roentgenol* 2020;214:114–21, doi:http://dx.doi.org/10.2214/AJR.19.21907.
- [70] Maurer MH, Härmä KH, Thoeny H. Diffusion-weighted genitourinary imaging. *Urol Clin North Am* 2018;45:407–25, doi:http://dx.doi.org/10.1016/j.ucl.2018.03.003.
- [71] Schieda N, Krishna S, McInnes MDF, Moosavi B, Alrashed A, Moreland R, et al. Utility of MRI to differentiate clear cell renal cell carcinoma adrenal metastases from adrenal adenomas. *AJR Am J Roentgenol* 2017;209:W152–9, doi:http://dx.doi.org/10.2214/AJR.16.17649.
- [72] Janus CL, Mendelson DS. Comparison of MRI and CT for study of renal and perirenal masses. *Crit Rev Diagn Imaging* 1991;32:69–118.
- [73] Mueller-Lisse UG, Mueller-Lisse UL. Imaging of advanced renal cell carcinoma. *World J Urol* 2010;28:253–61, doi:http://dx.doi.org/10.1007/s00345-010-0557-z.
- [74] Kabala JE, Gillatt DA, Persad RA, Penry JB, Gingell JC, Chadwick D. Magnetic resonance imaging in the staging of renal cell carcinoma. *Br J Radiol* 1991;64:683–9, doi:http://dx.doi.org/10.1259/0007-1285-64-764-683.
- [75] Hallscheidt PJ, Fink C, Haferkamp A, Bock M, Luburic A, Zuna I, et al. Preoperative staging of renal cell carcinoma with inferior vena cava thrombus using multidetector CT and MRI: prospective study with histopathological correlation. *J Comput Assist Tomogr* 2005;29:64–8, doi:http://dx.doi.org/10.1097/01.rct.0000146113.56194.6d.
- [76] Yano M, Fowler KJ, Srisuwan S, Salter A, Siegel CL. Quantitative multiparametric MR analysis of small renal lesions: correlation with surgical pathology. *Abdom Radiol (NY)* 2018;43:3390–9, doi:http://dx.doi.org/10.1007/s00261-018-1612-2.
- [77] Basile G, Fallara G, Verri P, Uleri A, Chiti A, Gianolli L, et al. The role of 99mTc-sestamibi single-photon emission computed tomography/computed tomography in the diagnostic pathway for renal masses: a systematic review and meta-analysis. *Eur Urol* 2024;85:63–71, doi:http://dx.doi.org/10.1016/j.eururo.2023.07.013.
- [78] Schober JP, Braun A, Ginsburg KB, Bell S, Castro Bigalli AA, Chen M, et al. Clinical performance of technetium-99m-sestamibi SPECT/CT imaging in differentiating oncocytic tumors from renal cell carcinoma in routine clinical practice. *J Urol* 2023;210:438–45, doi:http://dx.doi.org/10.1097/JU.0000000000003557.
- [79] Lindenberg L, Mena E, Choyke PL, Bouchelouche K. PET imaging in renal cancer. *Curr Opin Oncol* 2019;31:216–21, doi:http://dx.doi.org/10.1097/CCO.0000000000000518.
- [80] Heckman MCH, Rijpkema M, Aarntzen EH, Mulder SF, Langenhuijsen JF, Oosterwijk E, et al. Positron emission tomography/computed tomography with 89Zr-girentuximab can aid in diagnostic dilemmas of clear cell renal cell carcinoma suspicion. *Eur Urol* 2018;74:257–60, doi:http://dx.doi.org/10.1016/j.eururo.2018.04.026.
- [81] Minn I, Koo SM, Lee HS, Brummet M, Rowe SP, Gorin MA, et al. [64Cu]XYMSR-06: a dual-motif CAIX ligand for PET imaging of clear cell renal cell carcinoma. *Oncotarget* 2016;7:56471–9, doi:http://dx.doi.org/10.18632/oncotarget.10602.
- [82] Shuch BB, Pantuck AJ, Bernhard JC, Morris MA, Master V, Scott AM, et al. Results from phase 3 study of 89Zr-DFO-girentuximab for PET/CT imaging of clear cell renal cell carcinoma (ZIRCON). *J Clin Oncol* 2023 [LBA602].
- [83] Mühlbauer J, Egen L, Kowalewski K-F, Grilli M, Walach MT, Westhoff N, et al. Radiomics in renal cell carcinoma – a systematic review and meta-analysis. *Cancers (Basel)* 2021;13:1348, doi:http://dx.doi.org/10.3390/cancers13061348.
- [84] Rallis KS, Kleeman SO, Grant M, Ordick KL, Sahdev A, Powles T. Radiomics for renal cell carcinoma: predicting outcomes from immunotherapy and targeted therapies – a narrative review. *Eur Urol Focus* 2021;7:717–21, doi:http://dx.doi.org/10.1016/j.euf.2021.04.024.
- [85] Rosevear HM, Gellhaus PT, Lightfoot AJ, Kresowik TP, Joudi FN, Tracy CR. Utility of the RENAL nephrometry scoring system in the real world: predicting surgeon operative preference and complication risk: renal nephrometry scoring system. *BJU Int* 2012;109:700–5, doi:http://dx.doi.org/10.1111/j.1464-410X.2011.10452.x.
- [86] Ficarra V, Novara G, Secco S, Macchi V, Porzionato A, De Caro R, et al. Preoperative Aspects and Dimensions Used for an Anatomical (PADUA) classification of renal tumours in patients who are candidates for nephron-sparing surgery. *Eur Urol* 2009;56:786–93, doi:http://dx.doi.org/10.1016/j.eururo.2009.07.040.
- [87] Vecchia A, Antonelli A, Uzzo RG, Novara G, Kutikov A, Ficarra V, et al. Predictive value of nephrometry scores in nephron-sparing surgery: a systematic review and meta-analysis. *Eur Urol Focus* 2020;6:490–504, doi:http://dx.doi.org/10.1016/j.euf.2019.11.004.
- [88] Heng DY, Xie W, Regan MM, Warren MA, Golshayan AR, Sahi C, et al. Prognostic factors for overall survival in patients with metastatic renal cell carcinoma treated with vascular endothelial growth factor-targeted agents: results from a large, multicenter study. *J Clin Oncol* 2009;27:5794–9, doi:http://dx.doi.org/10.1200/JCO.2008.21.4809.
- [89] Heng DY, Xie W, Regan MM, Warren MA, Golshayan AR, Sahi C, et al. Prognostic factors for overall survival in patients with metastatic renal cell carcinoma treated with vascular endothelial growth factor-targeted agents: results from a large, multicenter study. *J Clin Oncol* 2009;27:5794–9, doi:http://dx.doi.org/10.1200/JCO.2008.21.4809.
- [90] Sufirin G, Chasan S, Golio A, Murphy GP. Paraneoplastic and serologic syndromes of renal adenocarcinoma. *Semin Urol* 1989;7:158–71.
- [91] Levey AS, Becker C, Inker LA. Glomerular filtration rate and albuminuria for detection and staging of acute and chronic kidney disease in adults: a systematic review. *JAMA* 2015;313:837–46, doi:http://dx.doi.org/10.1001/jama.2015.0602.
- [92] Huang WC, Levey AS, Serio AM, Snyder M, Vickers AJ, Raj GV, et al. Chronic kidney disease after nephrectomy in patients with renal cortical tumours: a retrospective cohort study. *Lancet Oncol* 2006;7:735–40, doi:http://dx.doi.org/10.1016/S1470-2045(06)70803-8.
- [93] Moch H, Amin MB, Berney DM, Compérat EM, Gill AJ, Hartmann A, et al. The 2022 World Health Organization classification of tumours of the urinary system and male genital organs – part A: renal, penile, and testicular tumours. *Eur Urol* 2022;82:458–68, doi:http://dx.doi.org/10.1016/j.eururo.2022.06.016.
- [94] Li T, Chen J, Jiang Y, Ning X, Peng S, Wang J, et al. Multilocular cystic renal cell neoplasm of low malignant potential: a series of 76 cases. *Clin Genitourin Cancer* 2016;14:e553–7, doi:http://dx.doi.org/10.1016/j.clgc.2016.03.017.
- [95] Tretiakova M, Mehta V, Kocherginsky M, Minor A, Shen SS, Srintrapun SJ, et al. Predominantly cystic clear cell renal cell carcinoma and multilocular cystic renal neoplasm of low malignant potential form a low-grade spectrum. *Virchows Arch* 2018;473:85–93, doi:http://dx.doi.org/10.1007/s00428-018-2371-8.
- [96] Cancer Genome Atlas Research Network. Linehan WM, Spellman PT, Ricketts CJ, Creighton CJ, Fei SS, et al. Comprehensive molecular characterization of papillary renal-cell carcinoma. *N Engl J Med* 2016;374:135–45, doi:http://dx.doi.org/10.1056/NEJMoa1505917.
- [97] Tjota M, Chen H, Parilla M, Wanjari P, Segal J, Antic T. Eosinophilic renal cell tumors with a TSC and MTOR gene mutations are morphologically and immunohistochemically heterogeneous: clinicopathologic and molecular study. *Am J Surg Pathol* 2020;44:943–54, doi:http://dx.doi.org/10.1097/PAS.0000000000001457.
- [98] Trpkov K, Williamson SR, Gill AJ, Adeniran AJ, Agaimy A, Alaghebandan R, et al. Novel, emerging and provisional renal entities: the Genitourinary Pathology Society (GUPS) update on renal neoplasia. *Mod Pathol* 2021;34:1167–84, doi:http://dx.doi.org/10.1038/s41379-021-00737-6.
- [99] Trpkov K, Abou-Ouf H, Hes O, Lopez JI, Nesi G, Comperat E, et al. Eosinophilic Solid and Cystic Renal Cell Carcinoma (ESC RCC): further morphologic and molecular characterization of ESC RCC as a distinct entity. *Am J Surg Pathol* 2017;41:1299–308, doi:http://dx.doi.org/10.1097/PAS.0000000000000838.
- [100] Argani P, Reuter VE, Zhang L, Sung Y-S, Ning Y, Epstein JI, et al. TFEB-amplified renal cell carcinomas: an aggressive molecular subset demonstrating variable melanocytic marker expression and morphologic heterogeneity. *Am J Surg Pathol* 2016;40:1484–95, doi:http://dx.doi.org/10.1097/PAS.0000000000000720.
- [101] Argani P, Antonescu CR, Couturier J, Fournet J-C, Sciot R, Debiec-Rychter M, et al. PRCC-TFE3 renal carcinomas: morphologic, immunohistochemical, ultrastructural,

- and molecular analysis of an entity associated with the t(X;1)(p11.2;q21). *Am J Surg Pathol* 2002;26:1553–66, doi:http://dx.doi.org/10.1097/0000478-200212000-00003.
- [102] Xia Q-Y, Wang X-T, Fang R, Wang Z, Zhao M, Chen H, et al. Clinicopathologic and molecular analysis of the TFE3 fusion variant reveals new members of TFE3 translocation renal cell carcinomas (RCCs): expanding the genomic spectrum. *Am J Surg Pathol* 2020;44:477–89, doi:http://dx.doi.org/10.1097/PAS.0000000000001408.
- [103] Kuroda N, Trpkov K, Gao Y, Tretiakova M, Liu YJ, Ulamec M, et al. ALK rearranged renal cell carcinoma (ALK-RCC): a multi-institutional study of two cases with identification of novel partner genes *CLIP1*, *KIF5B* and *KIAA1217*. *Mod Pathol* 2020;33:2564–79, doi:http://dx.doi.org/10.1038/s41379-020-0578-0.
- [104] Jia L, Carlo MI, Khan H, Nanjangud GJ, Rana S, Cimera R, et al. Distinctive mechanisms underlie the loss of SMARCB1 protein expression in renal medullary carcinoma: morphologic and molecular analysis of 20 cases. *Mod Pathol* 2019;32:1329–43, doi:http://dx.doi.org/10.1038/s41379-019-0273-1.
- [105] Swami U, Nussenzeig RH, Haaland B, Agarwal N. Revisiting AJCC TNM staging for renal cell carcinoma: quest for improvement. *Ann Transl Med* 2019;7:S18, doi:http://dx.doi.org/10.21037/atm.2019.01.50.
- [106] Amin MB, Greene FL, Edge SB, Compton CC, Gershenwald JE, Brookland RK, et al. The eighth edition AJCC cancer staging manual: continuing to build a bridge from a population-based to a more “personalized” approach to cancer staging. *CA Cancer J Clin* 2017;67:93–9, doi:http://dx.doi.org/10.3322/caac.21388.
- [107] Paner GP, Stadler WM, Hansel DE, Montironi R, Lin DW, Amin MB. Updates in the eighth edition of the tumor-node-metastasis staging classification for urologic cancers. *Eur Urol* 2018;73:560–9, doi:http://dx.doi.org/10.1016/j.eururo.2017.12.018.
- [108] Trpkov K, Grignon DJ, Bonsib SM, Amin MB, Billis A, Lopez-Beltran A, et al. Handling and staging of renal cell carcinoma: the International Society of Urological Pathology Consensus (ISUP) conference recommendations. *Am J Surg Pathol* 2013;37:1505–17, doi:http://dx.doi.org/10.1097/PAS.0b013e31829a85d0.
- [109] Delahunt B, Chevillet JC, Martignoni G, Humphrey PA, Magi-Galluzzi C, McKenney J, et al. The International Society of Urological Pathology (ISUP) grading system for renal cell carcinoma and other prognostic parameters. *Am J Surg Pathol* 2013;37:1490–504, doi:http://dx.doi.org/10.1097/PAS.0b013e318299f0fb.
- [110] Tan PH, Cheng L, Rioux-Leclercq N, Merino MJ, Netto G, Reuter VE, et al. Renal tumors: diagnostic and prognostic biomarkers. *Am J Surg Pathol* 2013;37:1518–31, doi:http://dx.doi.org/10.1097/PAS.0b013e318299f12e.
- [111] Verkarre V, Morini A, Denize T, Ferlicot S, Richard S. [Hereditary kidney cancers: the pathologist's view in 2020]. *Ann Pathol* 2020;40:148–67, doi:http://dx.doi.org/10.1016/j.annpat.2020.02.022.
- [112] Hahn AW, Lebenthal J, Genovese G, Sircar K, Tannir NM, Msaouel P. The significance of sarcomatoid and rhabdoid dedifferentiation in renal cell carcinoma. *Cancer Treat Res Commun* 2022;33:100640, doi:http://dx.doi.org/10.1016/j.ctarc.2022.100640.
- [113] Halabi S, Armstrong AJ. Sarcomatoid renal cell carcinoma: an immune checkpoint-responsive subset? *Eur Urol* 2021;79:663–4, doi:http://dx.doi.org/10.1016/j.eururo.2021.01.042.
- [114] Mouallem NE, Smith SC, Paul AK. Sarcomatoid renal cell carcinoma: biology and treatment advances. *Urol Oncol* 2018;36:265–71, doi:http://dx.doi.org/10.1016/j.urolonc.2017.12.012.
- [115] Blum KA, Gupta S, Tickoo SK, Chan TA, Russo P, Motzer RJ, et al. Sarcomatoid renal cell carcinoma: biology, natural history and management. *Nat Rev Urol* 2020;17:659–78, doi:http://dx.doi.org/10.1038/s41585-020-00382-9.
- [116] Marconi L, Dabestani S, Lam TB, Hofmann F, Stewart F, Norrie J, et al. Systematic review and meta-analysis of diagnostic accuracy of percutaneous renal tumour biopsy. *Eur Urol* 2016;69:660–73, doi:http://dx.doi.org/10.1016/j.eururo.2015.07.072.
- [117] Pierorazio PM, Johnson MH, Patel HD, Sozio SM, Sharma R, Iyoha E, et al. Management of renal masses and localized renal cancer. Rockville (MD): Agency for Healthcare Research and Quality (US); 2016.
- [118] Patel HD, Druskin SC, Rowe SP, Pierorazio PM, Gorin MA, Allaf ME. Surgical histopathology for suspected oncocytoma on renal mass biopsy: a systematic review and meta-analysis. *BJU Int* 2017;119:661–6, doi:http://dx.doi.org/10.1111/bju.13763.
- [119] Branger N, Bigot P, Pignot G, Lorusso V, Audenet F, Parier B, et al. Oncocytoma on renal mass biopsy: is it still the same histology when surgery is performed? Results from UroCCR-104 study. *World J Urol* 2023;41:483–9, doi:http://dx.doi.org/10.1007/s00345-022-04261-3.
- [120] Baboudjian M, Moser D, Yanagisawa T, Gondran-Tellier B, Compérat EM, Ambrosetti D, et al. Benefit and harm of active surveillance for biopsy-proven renal oncocytoma: a systematic review and pooled analysis. *Eur Urol Open Sci* 2022;41:8–15, doi:http://dx.doi.org/10.1016/j.eururo.2022.04.009.
- [121] Rodger FE, Brown K, Leung S, Coode-Bate J, Armitage J, Warren A, et al. Real world outcomes of biopsy-proven oncocytic neoplasm of the kidney managed by surveillance. *BJU Compass* 2022;3:291–7, doi:http://dx.doi.org/10.1002/bco2.141.
- [122] Richard PO, Lavallée LT, Pouliot F, Komisarenko M, Martin L, Lattouf J-B, et al. Is routine renal tumor biopsy associated with lower rates of benign histology following nephrectomy for small renal masses? *J Urol* 2018;200:731–6, doi:http://dx.doi.org/10.1016/j.juro.2018.04.015.
- [123] Richard PO, Jewett MAS, Tanguay S, Saarela O, Liu ZA, Pouliot F, et al. Safety, reliability and accuracy of small renal tumour biopsies: results from a multi-institution registry. *BJU Int* 2017;119:543–9, doi:http://dx.doi.org/10.1111/bju.13630.
- [124] Posielski NM, Bui A, Wells SA, Best SL, Gettle LM, Ziemlewicz TJ, et al. Risk factors for complications and nondiagnostic results following 1155 consecutive percutaneous core renal mass biopsies. *J Urol* 2019;201:1080–7, doi:http://dx.doi.org/10.1097/JU.0000000000001113.
- [125] Marconi L, Dabestani S, Lam TB, Hofmann F, Stewart F, Norrie J, et al. Systematic review and meta-analysis of diagnostic accuracy of percutaneous renal tumour biopsy. *Eur Urol* 2016;69:660–73, doi:http://dx.doi.org/10.1016/j.eururo.2015.07.072.
- [126] Menogue SR, O'Brien BA, Brown AL, Cohen RJ. Percutaneous core biopsy of small renal mass lesions: a diagnostic tool to better stratify patients for surgical intervention. *BJU Int* 2013;111:E146–51, doi:http://dx.doi.org/10.1111/j.1464-410X.2012.11384.x.
- [127] Amaral BS, Macek P, Arora A, Pazeto CL, Zugail AS, Mombet A, et al. Renal tumor biopsy: rationale to avoid surgery in small renal masses. *Curr Urol Rep* 2021;22:46, doi:http://dx.doi.org/10.1007/s11934-021-01064-8.
- [128] Robert SC, Cossetto T, Miao TL, Li K, Habib E, Mocanu V, et al. Complications after renal mass biopsy: frequency, nature, timing, and associated characteristics. *AJR Am J Roentgenol* 2023;221:344–53, doi:http://dx.doi.org/10.2214/AJR.23.29059.
- [129] Garbens A, Wallis CJD, Klaassen Z, Saskin R, Plumpré L, Kodama R, et al. Comprehensive assessment of the morbidity of renal mass biopsy: a population-based assessment of biopsy-related complications. *Can Urol Assoc J* 2021;15:42–7, doi:http://dx.doi.org/10.5489/cauj.6477.
- [130] Macklin PS, Sullivan ME, Tapping CR, Cranston DW, Webster GM, Roberts ISD, et al. Tumour seeding in the tract of percutaneous renal tumour biopsy: a report on seven cases from a UK tertiary referral centre. *Eur Urol* 2019;75:861–7, doi:http://dx.doi.org/10.1016/j.eururo.2018.12.011.
- [131] Staehler M, Rodler S, Brinkmann J, Stief CG, Graser A, Götz M, et al. Long-term follow-up in patients undergoing renal mass biopsy: seeding is not anecdotal. *Clin Genitourin Cancer* 2024;22:189–92, doi:http://dx.doi.org/10.1016/j.clgc.2023.10.012.
- [132] Richard PO, Jewett MAS, Bhatt JR, Kachura JR, Evans AJ, Zlotka AR, et al. Renal tumor biopsy for small renal masses: a single-center 13-year experience. *Eur Urol* 2015;68:1007–13, doi:http://dx.doi.org/10.1016/j.eururo.2015.04.004.
- [133] Vijay V, Vokshi FH, Smigelski M, Nagpal S, Huang WC. Incidence of benign renal masses in a contemporary cohort of patients receiving partial nephrectomy for presumed renal cell carcinoma. *Clin Genitourin Cancer* 2023;21:e114–8, doi:http://dx.doi.org/10.1016/j.clgc.2022.11.006 [S1558-7673(22)00240-3].
- [134] Patel AK, Lane BR, Chintalapati P, Fouad L, Butaney M, Budzyn J, et al. Utilization of renal mass biopsy for T1 renal lesions across Michigan: results from MUSIC-KIDNEY. A statewide quality improvement collaborative. *Eur Urol Open Sci* 2021;30:37–43, doi:http://dx.doi.org/10.1016/j.eururo.2021.06.004.
- [135] Jasinski M, Siekiera J, Tworokiewicz M. Ultrasound-guided renal mass biopsy and its clinical utility: a single-centre experience. *Urol Int* 2022;106:560–6, doi:http://dx.doi.org/10.1159/000521153.
- [136] Jiang P, Arada RB, Okhunov Z, Afyouni AS, Peta A, Brevik A, et al. Multidisciplinary approach and outcomes of pretreatment small (cT1a) renal mass biopsy: single-center experience. *J Endourol* 2022;36:703–11, doi:http://dx.doi.org/10.1089/end.2021.0664.
- [137] Ferrari M, Cartolari R, Barizzi J, Pereira Mestre R, D'Antonio E, Renard J. Percutaneous biopsy of small renal mass: can diagnostic accuracy be affected by hospital volume? *Cent European J Urol* 2021;74:334–40, doi:http://dx.doi.org/10.5173/ceju.2021.3.0104.
- [138] Okhunov Z, Gorin MA, Jefferson FA, Afyouni AS, Allaf ME, Pierorazio PM, et al. Can preoperative renal mass biopsy change clinical practice and reduce surgical intervention for small renal masses? *Urol Oncol* 2021;39:735.e17–23, doi:http://dx.doi.org/10.1016/j.urolonc.2021.05.024.
- [139] Lobo JM, Clements MB, Bitner DP, Mikula MD, Noona SW, Sultan MI, et al. Does renal mass biopsy influence multidisciplinary treatment recommendations? *Scand J Urol* 2020;54:27–32, doi:http://dx.doi.org/10.1080/21681805.2019.1703805.
- [140] Couture F, Finelli T, Breaux RH, Mallick R, Bhandi B, Tanguay S, et al. The increasing use of renal tumor biopsy amongst Canadian urologists: when is biopsy most utilized? *Urol Oncol* 2021;39:499.e15–22, doi:http://dx.doi.org/10.1016/j.urolonc.2021.05.026.
- [141] Patel HD, Nichols PE, Su ZT, Gupta M, Cheaib JG, Allaf ME, et al. Renal mass biopsy is associated with reduction in surgery for early-stage kidney cancer. *Urology* 2020;135:76–81, doi:http://dx.doi.org/10.1016/j.urology.2019.08.043.
- [142] Ali SN, Tano Z, Landman J. The changing role of renal mass biopsy. *Urol Clin North Am* 2023;50:217–25, doi:http://dx.doi.org/10.1016/j.ucl.2023.01.002.
- [143] Sinks A, Miller C, Holck H, Zeng L, Gaston K, Riggs S, et al. Renal mass biopsy mandate is associated with change in treatment decisions. *J Urol* 2023;210:72–8, doi:http://dx.doi.org/10.1097/JU.0000000000003429.
- [144] Prebay ZJ, Patel A, Johnson A, Kim T, Fonshell C, Raman JD, et al. Perspectives on the role of biopsy for management of T1 renal masses: survey results from two regional quality improvement collaboratives. *Urology* 2022;165:206–11, doi:http://dx.doi.org/10.1016/j.urology.2022.01.038 [S0090-4295(22)00093-0].
- [145] Patel DN, Ghali F, Meagher MF, Javier-Desloges J, Patel SH, Soliman S, et al. Utilization of renal mass biopsy in patients with localized renal cell carcinoma: a population-based study utilizing the National Cancer Database. *Urol Oncol* 2021;39:79.e1–8, doi:http://dx.doi.org/10.1016/j.urolonc.2020.10.015.
- [146] Ozambela M, Wang Y, Leow JJ, Silverman SG, Chung BI, Chang SL. Contemporary trends in percutaneous renal mass biopsy utilization in the United States. *Urol Oncol* 2020;38:835–43, doi:http://dx.doi.org/10.1016/j.urolonc.2020.07.022.
- [147] Michel J, Lenis AT, Lec PM, Golla V, Johnson DC, Gollapudi K, et al. Analysis of guideline recommended use of renal mass biopsy and association with treatment. *Can J Urol* 2020;27:10285–93.

- [148] Pasquier D, Rozet F, Fregeville A, Barret E, Lanz C, Macek P, et al. Renal tumor biopsy does not increase the risk of surgical complications of minimally invasive partial nephrectomy. *Prog Urol* 2022;32:843–8, doi:http://dx.doi.org/10.1016/j.purol.2022.03.006.
- [149] Shahait M, Jackman S, Landman J, Lechevallier E, Billiet I, Fossion L, et al. Utilization and operative influence of renal mass biopsy in the small renal mass: analysis from the Clinical Research Office of the Endourological Society Small Renal Mass registry. *J Endourol* 2020;34:99–106, doi:http://dx.doi.org/10.1089/end.2019.0297.
- [150] Kunath F, Schmidt S, Krabbe L-M, Miernik A, Dahm P, Cleves A, et al. Partial nephrectomy versus radical nephrectomy for clinical localised renal masses. *Cochrane Database Syst Rev* 2017;5:CD012045, doi:http://dx.doi.org/10.1002/14651858.CD012045.pub2.
- [151] Van Poppel H, Da Pozzo L, Albrecht W, Matveev V, Bono A, Borkowski A, et al. A prospective, randomised EORTC intergroup phase 3 study comparing the oncologic outcome of elective nephron-sparing surgery and radical nephrectomy for low-stage renal cell carcinoma. *Eur Urol* 2011;59:543–52, doi:http://dx.doi.org/10.1016/j.eururo.2010.12.013.
- [152] Talenfeld AD, Gennarelli RL, Elkin EB, Atria CL, Durack JC, Huang WC, et al. Percutaneous ablation versus partial and radical nephrectomy for T1a renal cancer: a population-based analysis. *Ann Intern Med* 2018;169:69–77, doi:http://dx.doi.org/10.7326/M17-0585.
- [153] Jamil ML, Keeley J, Sood A, Dalela D, Arora S, Peabody JO, et al. Long-term risk of recurrence in surgically treated renal cell carcinoma: a post hoc analysis of the Eastern Cooperative Oncology Group – American College of Radiology Imaging Network E2805 Trial Cohort. *Eur Urol* 2020;77:277–81, doi:http://dx.doi.org/10.1016/j.eururo.2019.10.028.
- [154] Bensalah K, Pantuck AJ, Rioux-Leclercq N, Thuret R, Montorsi F, Karakiewicz PI, et al. Positive surgical margin appears to have negligible impact on survival of renal cell carcinomas treated by nephron-sparing surgery. *Eur Urol* 2010;57:466–71, doi:http://dx.doi.org/10.1016/j.eururo.2009.03.048.
- [155] Bernhard J-C, Pantuck AJ, Wallerand H, Crepel M, Ferrière J-M, Bellec L, et al. Predictive factors for ipsilateral recurrence after nephron-sparing surgery in renal cell carcinoma. *Eur Urol* 2010;57:1080–6, doi:http://dx.doi.org/10.1016/j.eururo.2010.02.019.
- [156] Kim SP, Abouassaly R. Treatment of patients with positive margins after partial nephrectomy. *J Urol* 2016;196:301–2, doi:http://dx.doi.org/10.1016/j.juro.2016.05.078.
- [157] Wood EL, Adibi M, Qiao W, Brandt J, Zhang M, Tamboli P, et al. Local tumor bed recurrence following partial nephrectomy in patients with small renal masses. *J Urol* 2018;199:393–400, doi:http://dx.doi.org/10.1016/j.juro.2017.09.072.
- [158] Kriegmair MC, Bertolo R, Karakiewicz PI, Leibovich BC, Ljungberg B, Mir MC, et al. Systematic review of the management of local kidney cancer relapse. *Eur Urol Oncol* 2018;1:512–23, doi:http://dx.doi.org/10.1016/j.euo.2018.06.007.
- [159] Brassier M, Khene Z-E, Bernhard J-C, Dang VT, Ouzaid I, Nohaud FX, et al. Percutaneous ablation versus surgical resection for local recurrence following partial nephrectomy for renal cell cancer: a propensity score analysis (REPART Study-UroCCR 71). *Eur Urol Focus* 2022;8:210–6, doi:http://dx.doi.org/10.1016/j.euf.2021.02.007.
- [160] Scosyrev E, Messing EM, Sylvester R, Campbell S, Van Poppel H. Renal function after nephron-sparing surgery versus radical nephrectomy: results from EORTC randomized trial 30904. *Eur Urol* 2014;65:372–7, doi:http://dx.doi.org/10.1016/j.eururo.2013.06.044.
- [161] Miller DC, Schonlau M, Litwin MS, Lai J, Saigal CS. Urologic Diseases in America Project. Renal and cardiovascular morbidity after partial or radical nephrectomy. *Cancer* 2008;112:511–20, doi:http://dx.doi.org/10.1002/cncr.23218.
- [162] Capitanio U, Terrone C, Antonelli A, Minervini A, Volpe A, Furlan M, et al. Nephron-sparing techniques independently decrease the risk of cardiovascular events relative to radical nephrectomy in patients with a T1a-T1b renal mass and normal preoperative renal function. *Eur Urol* 2015;67:683–9, doi:http://dx.doi.org/10.1016/j.eururo.2014.09.027.
- [163] Huang WC, Elkin EB, Levey AS, Jang TL, Russo P. Partial nephrectomy versus radical nephrectomy in patients with small renal tumors – is there a difference in mortality and cardiovascular outcomes? *J Urol* 2009;181:55–61, doi:http://dx.doi.org/10.1016/j.juro.2008.09.017 [discussion 61–62].
- [164] Gratzke C, Seitz M, Bayrle F, Schlenker B, Bastian PJ, Haseke N, et al. Quality of life and perioperative outcomes after retroperitoneoscopic radical nephrectomy (RN), open RN and nephron-sparing surgery in patients with renal cell carcinoma. *BJU Int* 2009;104:470–5, doi:http://dx.doi.org/10.1111/j.1464-410X.2009.08439.x.
- [165] Huang WC, Donin NM, Levey AS, Campbell SC. Chronic kidney disease and kidney cancer surgery: new perspectives. *J Urol* 2020;203:475–85, doi:http://dx.doi.org/10.1097/JU.0000000000000326.
- [166] Volpe A, Blute ML, Ficarra V, Gill IS, Kutikov A, Porpiglia F, et al. Renal ischemia and function after partial nephrectomy: a collaborative review of the literature. *Eur Urol* 2015;68:61–74, doi:http://dx.doi.org/10.1016/j.eururo.2015.01.025.
- [167] Mir MC, Ercole C, Takagi T, Zhang Z, Velet L, Remer EM, et al. Decline in renal function after partial nephrectomy: etiology and prevention. *J Urol* 2015;193:1889–98, doi:http://dx.doi.org/10.1016/j.juro.2015.01.093.
- [168] Zhang Z, Zhao J, Dong W, Remer E, Li J, Demirjian S, et al. Acute kidney injury after partial nephrectomy: role of parenchymal mass reduction and ischemia and impact on subsequent functional recovery. *Eur Urol* 2016;69:745–52, doi:http://dx.doi.org/10.1016/j.eururo.2015.10.023.
- [169] Greco F, Autorino R, Altieri V, Campbell S, Ficarra V, Gill J, et al. Ischemia techniques in nephron-sparing surgery: a systematic review and meta-analysis of surgical, oncological, and functional outcomes. *Eur Urol* 2019;75:477–91, doi:http://dx.doi.org/10.1016/j.eururo.2018.10.005.
- [170] Dong W, Wu J, Suk-Ouichai C, Caraballo Antonio E, Remer EM, Li J, et al. Ischemia and functional recovery from partial nephrectomy: refined perspectives. *Eur Urol Focus* 2018;4:572–8, doi:http://dx.doi.org/10.1016/j.euf.2017.02.001.
- [171] Cignoli D, Basile G, Fallara G, Rosiello G, Belladelli F, Cei F, et al. Risks and benefits of partial nephrectomy performed with limited or with zero ischaemia time. *BJU Int* 2023;132:283–90, doi:http://dx.doi.org/10.1111/bju.16009.
- [172] Fong KY, Gan VHL, Lim BJH, Chan YH, Castellani D, Chen K, et al. Off-clamp vs. on-clamp robot-assisted partial nephrectomy: a systematic review and meta-analysis. *BJU Int* 2024;133:375–86, doi:http://dx.doi.org/10.1111/bju.16250.
- [173] Mellouki A, Bentellis I, Morrone A, Doumerc N, Beauval J-B, Roupret M, et al. Evaluation of oncological outcomes of robotic partial nephrectomy according to the type of hilar control approach (on-clamp vs. off-clamp), a multicentric study of the French network of research on kidney cancer-UROCCR 58-NCT03293563. *World J Urol* 2023;41:287–94, doi:http://dx.doi.org/10.1007/s00345-020-03558-5.
- [174] Liu P, Li Y, Shi B, Zhang Q, Guo H. The outcome of sutureless in partial nephrectomy: a systematic review and meta-analysis. *Biomed Res Int* 2022;25260131, doi:http://dx.doi.org/10.1155/2022/5260131.
- [175] Introini C, Di Domenico A, Ennas M, Campodonico F, Brusasco C, Benelli A. Functional and oncological outcomes of 3D clampless sutureless laparoscopic partial nephrectomy for renal tumors with low nephrometry score. *Minerva Urol Nefrol* 2020;72:723–8, doi:http://dx.doi.org/10.23736/S0393-2249.20.04005-9.
- [176] Wu J, Suk-Ouichai C, Dong W, Zhang Z, Tanaka H, Wang Y, et al. Vascularized parenchymal mass preserved with partial nephrectomy: functional impact and predictive factors. *Eur Urol Oncol* 2019;2:97–103, doi:http://dx.doi.org/10.1016/j.euo.2018.06.009.
- [177] Cao D-H, Liu L-R, Fang Y, Tang P, Li T, Bai Y, et al. Simple tumor enucleation may not decrease oncologic outcomes for T1 renal cell carcinoma: a systematic review and meta-analysis. *Urol Oncol* 2017;35:661.e15–21, doi:http://dx.doi.org/10.1016/j.urolonc.2017.07.007.
- [178] Bertolo R, Pecoraro A, Carbonara U, Amparore D, Diana P, Muselaers S, et al. Resection techniques during robotic partial nephrectomy: a systematic review. *Eur Urol Open Sci* 2023;52:7–21, doi:http://dx.doi.org/10.1016/j.euros.2023.03.008.
- [179] Potretzke AM, Knight BA, Zargar H, Kaouk JH, Barod R, Rogers CG, et al. Urinary fistula after robot-assisted partial nephrectomy: a multicentre analysis of 1791 patients. *BJU Int* 2016;117:131–7, doi:http://dx.doi.org/10.1111/bju.13249.
- [180] Khene Z, Peyronnet B, Fretton L, Graffelle V, Pradere B, Robert C, et al. What is better for predicting morbidity of robotic partial nephrectomy – a score or your clinical judgement? *Eur Urol Focus* 2020;6:313–9, doi:http://dx.doi.org/10.1016/j.euf.2018.10.016.
- [181] Simhan J, Smaldone MC, Tsai KJ, Canter DJ, Li T, Kutikov A, et al. Objective measures of renal mass anatomic complexity predict rates of major complications following partial nephrectomy. *Eur Urol* 2011;60:724–30, doi:http://dx.doi.org/10.1016/j.eururo.2011.05.030.
- [182] Khene Z-E, Mazouin C, Larcher A, Peyronnet B, Gasmí A, Roumiguié M, et al. Predicting complications after robotic partial nephrectomy: back to simplicity. *Eur Urol Focus* 2022;8:777–83, doi:http://dx.doi.org/10.1016/j.euf.2021.04.017.
- [183] Margue G, Ingels A, Bensalah K, Doumerc N, Vaessen C, Roupret M, et al. Late complications and 5 years outcomes of robotic partial nephrectomy in France: prospective assessment in the French Kidney Cancer Research Network (UroCCR 10). *World J Urol* 2023;41:2281–8, doi:http://dx.doi.org/10.1007/s00345-023-04491-z.
- [184] Chang KD, Abdel Raheem A, Kim KH, Oh CK, Park SY, Kim YS, et al. Functional and oncological outcomes of open, laparoscopic and robot-assisted partial nephrectomy: a multicenter comparative matched-pair analyses with a median of 5 years' follow-up. *BJU Int* 2018;122:618–26, doi:http://dx.doi.org/10.1111/bju.14250.
- [185] Bravi CA, Larcher A, Capitanio U, Mari A, Antonelli A, Artibani W, et al. Perioperative outcomes of open, laparoscopic, and robotic partial nephrectomy: a prospective multicenter observational study (the RECORd 2 Project). *Eur Urol Focus* 2021;7:390–6, doi:http://dx.doi.org/10.1016/j.euf.2019.10.013.
- [186] Gill IS, Kavoussi LR, Lane BR, Blute ML, Babineau D, Colombo JR, et al. Comparison of 1800 laparoscopic and open partial nephrectomies for single renal tumors. *J Urol* 2007;178:41–6, doi:http://dx.doi.org/10.1016/j.juro.2007.03.038.
- [187] Guglielmetti GB, Dos Anjos GC, Sawczyn G, Rodrigues G, Cardili L, Cordeiro MD, et al. A prospective, randomized trial comparing the outcomes of open vs. laparoscopic partial nephrectomy. *J Urol* 2022;208:259–67, doi:http://dx.doi.org/10.1097/JU.0000000000002695.
- [188] Panayotopoulos P, Bouvier A, Besnier L, Rousset MC, Nedelcu C, Baize N, et al. Laparoscopic partial nephrectomy following tumor embolization in a hybrid room. Feasibility and clinical outcomes. *Surg Oncol* 2017;26:377–81, doi:http://dx.doi.org/10.1016/j.suronc.2017.07.012.
- [189] Peyronnet B, Seisen T, Oger E, Vaessen C, Grassano Y, Benoit T, et al. Comparison of 1800 robotic and open partial nephrectomies for renal tumors. *Ann Surg Oncol* 2016;23:4277–83, doi:http://dx.doi.org/10.1245/s10434-016-5411-0.
- [190] Ni Y, Yang X. A systematic review and meta-analysis of comparison of outcomes of robot-assisted versus open partial nephrectomy in clinical T1 renal cell carcinoma patients. *Urol Int* 2022;106:757–67, doi:http://dx.doi.org/10.1159/000521881.
- [191] Masson-Lecomte A, Yates DR, Hupertan V, Haertig A, Chartier-Kastler E, Bitker M-O, et al. A prospective comparison of the pathologic and surgical outcomes obtained after elective treatment of renal cell carcinoma by open or robot-assisted partial nephrectomy. *Urol Oncol* 2013;31:924–9, doi:http://dx.doi.org/10.1016/j.urolonc.2011.08.004.
- [192] Bernhard J-C, Robert G, Ricard S, Michiels C, Capon G, Boulenger de Hauteclouque A, et al. Day-case robotic-assisted partial nephrectomy: feasibility and preliminary results of a prospective evaluation (UroCCR-25 AMBU-REIN study). *World J Urol* 2022;40:1351–7, doi:http://dx.doi.org/10.1007/s00345-020-03283-z.

- [193] Bernhard J-C, Robert G, Ricard S, Rogier J, Degryse C, Michiels C, et al. Nurse-led coordinated surgical care pathways for cost optimization of robotic-assisted partial nephrectomy: medico-economic analysis of the UroCCR-25 AMBU-REIN study. *World J Urol* 2023;41:325–33, doi:http://dx.doi.org/10.1007/s00345-022-04066-4.
- [194] Choi JE, You JH, Kim DK, Rha KH, Lee SH. Comparison of perioperative outcomes between robotic and laparoscopic partial nephrectomy: a systematic review and meta-analysis. *Eur Urol* 2015;67:891–901, doi:http://dx.doi.org/10.1016/j.eururo.2014.12.028.
- [195] Long J-A, Yakoubi R, Lee B, Guillotreau J, Autorino R, Laydner H, et al. Robotic versus laparoscopic partial nephrectomy for complex tumors: comparison of perioperative outcomes. *Eur Urol* 2012;61:1257–62, doi:http://dx.doi.org/10.1016/j.eururo.2012.03.012.
- [196] Michiels C, Khene Z-E, Prudhomme T, Boulenger de Hauteclouque A, Cornelis FH, Percot M, et al. 3D-Image guided robotic-assisted partial nephrectomy: a multi-institutional propensity score-matched analysis (UroCCR study 51). *World J Urol* 2023;41:303–13, doi:http://dx.doi.org/10.1007/s00345-021-03645-1.
- [197] Porpiglia F, Mari A, Amparore D, Fiori C, Antonelli A, Artibani W, et al. Transperitoneal vs. retroperitoneal minimally invasive partial nephrectomy: comparison of perioperative outcomes and functional follow-up in a large multi-institutional cohort (the RECORD 2 Project). *Surg Endosc* 2021;35:4295–304, doi:http://dx.doi.org/10.1007/s00464-020-07919-4.
- [198] Couapel J-P, Bensalah K, Bernhard J-C, Pignot G, Zini L, Lang H, et al. Is there a volume-outcome relationship for partial nephrectomy? *World J Urol* 2014;32:1323–9, doi:http://dx.doi.org/10.1007/s00345-013-1213-1.
- [199] Peyronnet B, Tondut L, Bernhard J-C, Vaessen C, Doumerc N, Sebe P, et al. Impact of hospital volume and surgeon volume on robot-assisted partial nephrectomy outcomes: a multicentre study. *BJU Int* 2018;121:916–22, doi:http://dx.doi.org/10.1111/bju.14175.
- [200] Auffenberg GB, Curry M, Gennarelli R, Blum KA, Elkin E, Russo P. Comparison of cancer specific outcomes following minimally invasive and open surgical resection of early stage kidney cancer from a National Cancer Registry. *J Urol* 2020;203:1094–100, doi:http://dx.doi.org/10.1097/JU.0000000000000741.
- [201] Hemal AK, Kumar A, Kumar R, Wadhwa P, Seth A, Gupta NP. Laparoscopic versus open radical nephrectomy for large renal tumors: a long-term prospective comparison. *J Urol* 2007;177:862–6, doi:http://dx.doi.org/10.1016/j.juro.2006.10.053.
- [202] Wang L, Li K, Yin S, Yang L, Zhu P. Oncologic and perioperative outcomes of laparoscopic versus open radical nephrectomy for the treatment of renal tumor (> 7 cm): a systematic review and pooled analysis of comparative outcomes. *World J Surg Oncol* 2023;21:35, doi:http://dx.doi.org/10.1186/s12957-023-02916-y.
- [203] Desai MM, Strzempkowski B, Matin SF, Steinberg AP, Ng C, Meraney AM, et al. Prospective randomized comparison of transperitoneal versus retroperitoneal laparoscopic radical nephrectomy. *J Urol* 2005;173:38–41, doi:http://dx.doi.org/10.1097/01.ju.0000145886.26719.73.
- [204] Hemal AK, Kumar A. A prospective comparison of laparoscopic and robotic radical nephrectomy for T1–2N0M0 renal cell carcinoma. *World J Urol* 2009;27:89–94, doi:http://dx.doi.org/10.1007/s00345-008-0321-9.
- [205] Uhlig J, Strauss A, Rücker G, Seif Amir Hosseini A, Lotz J, Trojan L, et al. Partial nephrectomy versus ablative techniques for small renal masses: a systematic review and network meta-analysis. *Eur Radiol* 2019;29:1293–307, doi:http://dx.doi.org/10.1007/s00330-018-5660-3.
- [206] Andrews JR, Atwell T, Schmit G, Lohse CM, Kurup AN, Weisbrod A, et al. Oncologic outcomes following partial nephrectomy and percutaneous ablation for cT1 renal masses. *Eur Urol* 2019;76:244–51, doi:http://dx.doi.org/10.1016/j.eururo.2019.04.026.
- [207] Larcher A, Fossati N, Mistretta F, Lughezzani G, Lista G, Dell'Oglio P, et al. Long-term oncologic outcomes of laparoscopic renal cryoablation as primary treatment for small renal masses. *Urol Oncol* 2015;33:22.e1–9, doi:http://dx.doi.org/10.1016/j.urolonc.2014.09.003.
- [208] Abu-Ghanem Y, Fernández-Pello S, Bex A, Ljungberg B, Albiges L, Dabestani S, et al. Limitations of available studies prevent reliable comparison between tumour ablation and partial nephrectomy for patients with localised renal masses: a systematic review from the European Association of Urology Renal Cell Cancer Guideline Panel. *Eur Urol Oncol* 2020;3:433–52, doi:http://dx.doi.org/10.1016/j.euo.2020.02.001.
- [209] Cazzala G, Klein C, Piana G, De Kerviler E, Gangi A, Puech P, et al. A multicenter comparative matched-pair analysis of percutaneous tumor ablation and robotic-assisted partial nephrectomy of T1b renal cell carcinoma (AblatT1b study-UroCCR 80). *Eur Radiol* 2023;33:6513–21, doi:http://dx.doi.org/10.1007/s00330-023-09564-6.
- [210] Pecoraro A, Palumbo C, Knipper S, Mistretta FA, Tian Z, Shariat SF, et al. Cryoablation predisposes to higher cancer specific mortality relative to partial nephrectomy in patients with nonmetastatic pT1b kidney cancer. *J Urol* 2019;202:1120–6, doi:http://dx.doi.org/10.1097/JU.0000000000000460.
- [211] Patel HD, Pierorazio PM, Johnson MH, Sharma R, Iyoha E, Allaf ME, et al. Renal functional outcomes after surgery, ablation, and active surveillance of localized renal tumors: a systematic review and meta-analysis. *Clin J Am Soc Nephrol* 2017;12:1057–69, doi:http://dx.doi.org/10.2215/CJN.11941116.
- [212] Pantelidou M, Challacombe B, McGrath A, Brown M, Ilyas S, Katsanos K, et al. Percutaneous radiofrequency ablation versus robotic-assisted partial nephrectomy for the treatment of small renal cell carcinoma. *Cardiovasc Intervent Radiol* 2016;39:1595–603, doi:http://dx.doi.org/10.1007/s00270-016-1417-z.
- [213] Chang X, Zhang F, Liu T, Ji C, Zhao X, Yang R, et al. Radio frequency ablation versus partial nephrectomy for clinical T1b renal cell carcinoma: long-term clinical and oncologic outcomes. *J Urol* 2015;193:430–5, doi:http://dx.doi.org/10.1016/j.juro.2014.07.112.
- [214] Yu J, Zhang X, Liu H, Zhang R, Yu X, Cheng Z, et al. Percutaneous microwave ablation versus laparoscopic partial nephrectomy for cT1a renal cell carcinoma: a propensity-matched cohort study of 1955 patients. *Radiology* 2020;294:698–706, doi:http://dx.doi.org/10.1148/radiol.2020190919.
- [215] Breen DJ, King AJ, Patel N, Lockyer R, Hayes M. Image-guided cryoablation for sporadic renal cell carcinoma: three- and 5-year outcomes in 220 patients with biopsy-proven renal cell carcinoma. *Radiology* 2018;289:554–61, doi:http://dx.doi.org/10.1148/radiol.2018180249.
- [216] Katsanos K, Mailli L, Krokidis M, McGrath A, Sabharwal T, Adam A. Systematic review and meta-analysis of thermal ablation versus surgical nephrectomy for small renal tumours. *Cardiovasc Intervent Radiol* 2014;37:427–37, doi:http://dx.doi.org/10.1007/s00270-014-0846-9.
- [217] Krokidis ME, Orsi F, Katsanos K, Helmlinger T, Adam A. CIRSE guidelines on percutaneous ablation of small renal cell carcinoma. *Cardiovasc Intervent Radiol* 2017;40:177–91, doi:http://dx.doi.org/10.1007/s00270-016-1531-y.
- [218] Ali M, Mooi J, Lawrentschuk N, McKay RR, Hannan R, Lo SS, et al. The role of stereotactic ablative body radiotherapy in renal cell carcinoma. *Eur Urol* 2022;82:613–22, doi:http://dx.doi.org/10.1016/j.eururo.2022.06.017.
- [219] Correa RJM, Louie AV, Zaorsky NG, Lehrer EJ, Ellis R, Ponsky L, et al. The emerging role of stereotactic ablative radiotherapy for primary renal cell carcinoma: a systematic review and meta-analysis. *Eur Urol Focus* 2019;5:958–69, doi:http://dx.doi.org/10.1016/j.euf.2019.06.002.
- [220] Siva S, Pham D, Kron T, Bressel M, Lam J, Tan TH, et al. Stereotactic ablative body radiotherapy for inoperable primary kidney cancer: a prospective clinical trial. *BJU Int* 2017;120:623–30, doi:http://dx.doi.org/10.1111/bju.13811.
- [221] Siva S, Louie AV, Kotecha R, Barber MN, Ali M, Zhang Z, et al. Stereotactic body radiotherapy for primary renal cell carcinoma: a systematic review and practice guideline from the International Society of Stereotactic Radiosurgery (ISRS). *Lancet Oncol* 2024;25:e18–28, doi:http://dx.doi.org/10.1016/S1470-2045(23)00513-2.
- [222] Siva S, Ellis RJ, Ponsky L, Teh BS, Mahadevan A, Muacevic A, et al. Consensus statement from the International Radiosurgery Oncology Consortium for kidney for primary renal cell carcinoma. *Future Oncol* 2016;12:637–45, doi:http://dx.doi.org/10.2217/fo.16.2.
- [223] Grelier L, Baboudjian M, Gondran-Tellier B, Couderc A-L, McManus R, Deville J-L, et al. Stereotactic body radiotherapy for frail patients with primary renal cell carcinoma: preliminary results after 4 years of experience. *Cancers (Basel)* 2021;13:3129, doi:http://dx.doi.org/10.3390/cancers13133129.
- [224] Glicksman RM, Cheung P, Korol R, Niglas M, Nusrat H, Erler D, et al. Stereotactic body radiotherapy for renal cell carcinoma: oncological and renal function outcomes. *Clin Oncol (R Coll Radiol)* 2023;35:20–8, doi:http://dx.doi.org/10.1016/j.clon.2022.06.007.
- [225] Grubb WR, Ponsky L, Lo SS, Kharouta M, Traugher B, Sandstrom K, et al. Final results of a dose escalation protocol of stereotactic body radiotherapy for poor surgical candidates with localized renal cell carcinoma. *Radiother Oncol* 2021;155:138–43, doi:http://dx.doi.org/10.1016/j.radonc.2020.10.031.
- [226] Tatar SU, Bohoudi O, Senan S, Palacios MA, Oei SS, Wel AM, et al. The role of daily adaptive stereotactic MR-guided radiotherapy for renal cell cancer. *Cancers (Basel)* 2020;12:2763, doi:http://dx.doi.org/10.3390/cancers12102763.
- [227] Siva S, Bressel M, Sidhom M, Sridharan S, Vanneste B, Davey R, et al. Stereotactic ablative body radiotherapy for primary kidney cancer (TROG 15.03 FASTER II): a non-randomised phase 2 trial. *Lancet Oncol* 2024;25:308–16, doi:http://dx.doi.org/10.1016/S1470-2045(24)00020-2.
- [228] Siva S, Bressel M, Sidhom M, Sridharan S, Vanneste B, Davey R, et al. TROG 15.03/ANZUP international multicenter phase II trial of Focal Ablative STereotactic RAdiotherapy for Cancers of the Kidney (FASTRACK II). *Int J Radiat Oncol Biol Phys* 2023;117:S3, doi:http://dx.doi.org/10.1016/j.ijrobp.2023.06.208.
- [229] Bentahila R, Bensalah K, Benziane-Ouaritini N, Barthelemy P, Rioux-Leclerc N, Correas J-M, et al. Stereotactic body radiotherapy for primary renal cell carcinoma: a review on behalf of the CC AFU. *Fr J Urol* 2024;34:102660, doi:http://dx.doi.org/10.1016/j.fjurol.2024.102660.
- [230] Mir MC, Capitanio U, Bertolo R, Ouzaid I, Salagierski M, Kriegmair M, et al. Role of active surveillance for localized small renal masses. *Eur Urol Oncol* 2018;1:177–87, doi:http://dx.doi.org/10.1016/j.euo.2018.05.001.
- [231] Jewett MAS, Mattar K, Basiuk J, Morash CG, Pautler SE, Siemens DR, et al. Active surveillance of small renal masses: progression patterns of early stage kidney cancer. *Eur Urol* 2011;60:39–44, doi:http://dx.doi.org/10.1016/j.eururo.2011.03.030.
- [232] Uzosike AC, Patel HD, Alam R, Schwen ZR, Gupta M, Gorin MA, et al. Growth kinetics of small renal masses on active surveillance: variability and results from the DISSRM registry. *J Urol* 2018;199:641–8, doi:http://dx.doi.org/10.1016/j.juro.2017.09.087.
- [233] Klatter T, Berni A, Serni S, Campi R. Intermediate- and long-term oncological outcomes of active surveillance for localized renal masses: a systematic review and quantitative analysis. *BJU Int* 2021;128:131–43, doi:http://dx.doi.org/10.1111/bju.15435.
- [234] Finelli A, Cheung DC, Al-Matar A, Evans AJ, Morash CG, Pautler SE, et al. Small renal mass surveillance: histology-specific growth rates in a biopsy-characterized cohort. *Eur Urol* 2020;78:460–7, doi:http://dx.doi.org/10.1016/j.eururo.2020.06.053.
- [235] Smaldone MC, Kutikov A, Egleston BL, Canter DJ, Viterbo R, Chen DYT, et al. Small renal masses progressing to metastases under active surveillance: a systematic review and pooled analysis. *Cancer* 2012;118:997–1006, doi:http://dx.doi.org/10.1002/cncr.26369.
- [236] Pierorazio PM, Johnson MH, Ball MW, Gorin MA, Trock BJ, Chang P, et al. Five-year analysis of a multi-institutional prospective clinical trial of delayed intervention and

- surveillance for small renal masses: the DISSRM registry. *Eur Urol* 2015;68:408–15, doi:http://dx.doi.org/10.1016/j.eururo.2015.02.001.
- [237] Metcalf MR, Cheab JG, Biles MJ, Patel HD, Peña VN, Chang P, et al. Outcomes of active surveillance for young patients with small renal masses: prospective data from the DISSRM registry. *J Urol* 2021;205:1286–93, doi:http://dx.doi.org/10.1097/JU.0000000000001575.
- [238] Alam R, Patel HD, Osumah T, Srivastava A, Gorin MA, Johnson MH, et al. Comparative effectiveness of management options for patients with small renal masses: a prospective cohort study. *BJU Int* 2019;123:42–50, doi:http://dx.doi.org/10.1111/bju.14490.
- [239] Petros FG, Venkatesan AM, Kaya D, Ng CS, Fellman BM, Karam JA, et al. Conditional survival of patients with small renal masses undergoing active surveillance. *BJU Int* 2019;123:447–55, doi:http://dx.doi.org/10.1111/bju.14486.
- [240] Patel N, Cranston D, Akhtar MZ, George C, Jones A, Leiblich A, et al. Active surveillance of small renal masses offers short-term oncological efficacy equivalent to radical and partial nephrectomy. *BJU Int* 2012;110:1270–5, doi:http://dx.doi.org/10.1111/j.1464-410X.2012.11130.x.
- [241] Goldberg H, Ajaj R, Cáceres JOH, Berlin A, Chandrasekar T, Klaassen Z, et al. Psychological distress associated with active surveillance in patients younger than 70 with a small renal mass. *Urol Oncol* 2020;38:603.e17–25, doi:http://dx.doi.org/10.1016/j.urolonc.2020.02.015.
- [242] Parker PA, Alba F, Fellman B, Urbauer DL, Li Y, Karam JA, et al. Illness uncertainty and quality of life of patients with small renal tumors undergoing watchful waiting: a 2-year prospective study. *Eur Urol* 2013;63:1122–7, doi:http://dx.doi.org/10.1016/j.eururo.2013.01.034.
- [243] Pierorazio P, McKiernan J, Allaf M. 633 quality of life on active surveillance for a small renal masses versus immediate intervention: interim analysis of the dissrm (delayed intervention and surveillance for small renal masses) registry. *J Urol* 2013;189:e259, doi:http://dx.doi.org/10.1016/j.juro.2013.02.185.
- [244] Lee HJ, Liss MA, Derweesh IH. Outcomes of partial nephrectomy for clinical T1b and T2 renal tumors. *Curr Opin Urol* 2014;24:448–52, doi:http://dx.doi.org/10.1097/MOU.0000000000000081.
- [245] Mir MC, Derweesh I, Porpiglia F, Zargar H, Mottrie A, Autorino R. Partial nephrectomy versus radical nephrectomy for clinical T1b and T2 renal tumors: a systematic review and meta-analysis of comparative studies. *Eur Urol* 2017;71:606–17, doi:http://dx.doi.org/10.1016/j.eururo.2016.08.060.
- [246] Borghesi M, Schiavina R, Gan M, Novara G, Mottrie A, Ficarra V. Expanding utilization of robotic partial nephrectomy for clinical T1b and complex T1a renal masses. *World J Urol* 2013;31:499–504, doi:http://dx.doi.org/10.1007/s00345-013-1095-2.
- [247] Klett DE, Tsvian M, Packiam VT, Lohse CM, Ahmed ME, Potretzke TA, et al. Partial versus radical nephrectomy in clinical T2 renal masses. *Int J Urol* 2021;28:1149–54, doi:http://dx.doi.org/10.1111/iju.14664.
- [248] Huang R, Zhang C, Wang X, Hu H. Partial nephrectomy versus radical nephrectomy for clinical T2 or higher stage renal tumors: a systematic review and meta-analysis. *Front Oncol* 2021;11:680842, doi:http://dx.doi.org/10.3389/fonc.2021.680842.
- [249] Janssen MWW, Linxweiler J, Terwey S, Rugge S, Ohlmann C-H, Becker F, et al. Survival outcomes in patients with large (≥ 7 cm) clear cell renal cell carcinomas treated with nephron-sparing surgery versus radical nephrectomy: results of a multicenter cohort with long-term follow-up. *PLoS One* 2018;13:e0196427, doi:http://dx.doi.org/10.1371/journal.pone.0196427.
- [250] Patel SH, Uzzo RG, Larcher A, Peyronnet B, Lane BR, Pruthi D, et al. Oncologic and functional outcomes of radical and partial nephrectomy in pT3a pathologically upstaged renal cell carcinoma: a multi-institutional analysis. *Clin Genitourin Cancer* 2020;18:e723–9, doi:http://dx.doi.org/10.1016/j.clgc.2020.05.002.
- [251] Boulenger de Hauteclouque A, Ferrer L, Ambrosetti D, Ricard S, Bigot P, Bensalah K, et al. Machine-learning approach for prediction of pT3a upstaging and outcomes of localized renal cell carcinoma (UroCCR-15). *BJU Int* 2023;132:160–9, doi:http://dx.doi.org/10.1111/bju.15959.
- [252] Shah PH, Moreira DM, Patel VR, Gaunay G, George AK, Alom M, et al. Partial nephrectomy is associated with higher risk of relapse compared with radical nephrectomy for clinical stage T1 renal cell carcinoma pathologically up staged to T3a. *J Urol* 2017;198:289–96, doi:http://dx.doi.org/10.1016/j.juro.2017.03.012.
- [253] Liu H, Kong Q-F, Li J, Wu Y-Q, Pan K-H, Xu B, et al. A meta-analysis for comparison of partial nephrectomy vs. radical nephrectomy in patients with pT3a renal cell carcinoma. *Transl Androl Urol* 2021;10:1170–8, doi:http://dx.doi.org/10.21037/tau-20-1262.
- [254] Kutikov A, Uzzo RG. The R.E.N.A.L. nephrometry score: a comprehensive standardized system for quantitating renal tumor size, location and depth. *J Urol* 2009;182:844–53, doi:http://dx.doi.org/10.1016/j.juro.2009.05.035.
- [255] Kopp RP, Liss MA, Mehrazin R, Wang S, Lee HJ, Jabaji R, et al. Analysis of renal functional outcomes after radical or partial nephrectomy for renal masses ≥ 7 cm using the RENAL score. *Urology* 2015;86:312–9, doi:http://dx.doi.org/10.1016/j.urol.2015.02.067.
- [256] Kopp RP, Mehrazin R, Palazzi KL, Liss MA, Jabaji R, Mirheydar HS, et al. Survival outcomes after radical and partial nephrectomy for clinical T2 renal tumours categorised by R.E.N.A.L. nephrometry score. *BJU Int* 2014;114:708–18, doi:http://dx.doi.org/10.1111/bju.12580.
- [257] Srivastava A, Patel HD, Joice GA, Semerjian A, Gorin MA, Johnson MH, et al. Incidence of T3a up-staging and survival after partial nephrectomy: size-stratified rates and implications for prognosis. *Urol Oncol* 2018;36:12.e7–12.e13, doi:http://dx.doi.org/10.1016/j.urolonc.2017.09.005.
- [258] Wang Y, Shao J, Ma X, Du Q, Gong H, Zhang X. Robotic and open partial nephrectomy for complex renal tumors: a matched-pair comparison with a long-term follow-up. *World J Urol* 2017;35:73–80, doi:http://dx.doi.org/10.1007/s00345-016-1849-8.
- [259] Garisto J, Bertolo R, Dagenais J, Sagalovich D, Fareed K, Fergany A, et al. Robotic versus open partial nephrectomy for highly complex renal masses: comparison of perioperative, functional, and oncological outcomes. *Urol Oncol* 2018;36:471.e1–9, doi:http://dx.doi.org/10.1016/j.urolonc.2018.06.012.
- [260] Hinata N, Shiroki R, Tanabe K, Eto M, Takenaka A, Kawakita M, et al. Robot-assisted partial nephrectomy versus standard laparoscopic partial nephrectomy for renal hilar tumor: a prospective multi-institutional study. *Int J Urol* 2021;28:382–9, doi:http://dx.doi.org/10.1111/iju.14469.
- [261] Bradshaw AW, Autorino R, Simone G, Yang B, Uzzo RG, Porpiglia F, et al. Robotic partial nephrectomy vs. minimally invasive radical nephrectomy for clinical T2a renal mass: a propensity score-matched comparison from the ROSULA (Robotic Surgery for Large Renal Mass) Collaborative Group. *BJU Int* 2020;126:114–23, doi:http://dx.doi.org/10.1111/bju.15064.
- [262] Dursun F, Elshabrawy A, Wang H, Rodriguez R, Liss MA, Kaushik D, et al. Survival after minimally invasive vs. open radical nephrectomy for stage I and II renal cell carcinoma. *Int J Clin Oncol* 2022;27:1068–76, doi:http://dx.doi.org/10.1007/s10147-022-02153-5.
- [263] Ebbing J, Wiebach T, Kempkensteffen C, Miller K, Bachmann A, Günzel K, et al. Evaluation of perioperative complications in open and laparoscopic surgery for renal cell cancer with tumor thrombus involvement using the Clavien-Dindo classification. *Eur J Surg Oncol* 2015;41:941–52, doi:http://dx.doi.org/10.1016/j.ejso.2015.02.009.
- [264] MacLennan S, Imamura M, Lapitan MC, Omar MI, Lam TBL, Hilvano-Cabungcal AM, et al. Systematic review of perioperative and quality-of-life outcomes following surgical management of localised renal cancer. *Eur Urol* 2012;62:1097–117, doi:http://dx.doi.org/10.1016/j.eururo.2012.07.028.
- [265] Li J, Peng L, Cao D, Cheng B, Gou H, Li Y, et al. Comparison of perioperative outcomes of robot-assisted vs. laparoscopic radical nephrectomy: a systematic review and meta-analysis. *Front Oncol* 2020;10:551052, doi:http://dx.doi.org/10.3389/fonc.2020.551052.
- [266] Asimakopoulos AD, Miano R, Annino F, Micali S, Spera E, Iorio B, et al. Robotic radical nephrectomy for renal cell carcinoma: a systematic review. *BMC Urol* 2014;14:75, doi:http://dx.doi.org/10.1186/1471-2490-14-75.
- [267] Anele UA, Marchioni M, Yang B, Simone G, Uzzo RG, Lau C, et al. Robotic versus laparoscopic radical nephrectomy: a large multi-institutional analysis (ROSULA Collaborative Group). *World J Urol* 2019;37:2439–50, doi:http://dx.doi.org/10.1007/s00345-019-02657-2.
- [268] Jeong IG, Khandwala YS, Kim JH, Han DH, Li S, Wang Y, et al. Association of robotic-assisted vs. laparoscopic radical nephrectomy with perioperative outcomes and health care costs, 2003 to 2015. *JAMA* 2017;318:1561–8, doi:http://dx.doi.org/10.1001/jama.2017.14586.
- [269] Lane BR, Tiong H-Y, Campbell SC, Fergany AF, Weight CJ, Larson BT, et al. Management of the adrenal gland during partial nephrectomy. *J Urol* 2009;181:2430–6, doi:http://dx.doi.org/10.1016/j.juro.2009.02.027 [discussion 2436–2437].
- [270] Bekema HJ, MacLennan S, Imamura M, Lam TBL, Stewart F, Scott N, et al. Systematic review of adrenalectomy and lymph node dissection in locally advanced renal cell carcinoma. *Eur Urol* 2013;64:799–810, doi:http://dx.doi.org/10.1016/j.eururo.2013.04.033.
- [271] Capitanio U, Suardi N, Matloob R, Roscigno M, Abdollah F, Di Trapani E, et al. Extent of lymph node dissection at nephrectomy affects cancer-specific survival and metastatic progression in specific sub-categories of patients with renal cell carcinoma (RC). *BJU Int* 2014;114:210–5, doi:http://dx.doi.org/10.1111/bju.12508.
- [272] John NT, Blum KA, Hakimi AA. Role of lymph node dissection in renal cell cancer. *Urol Oncol* 2019;37:187–92, doi:http://dx.doi.org/10.1016/j.urolonc.2018.03.006.
- [273] Gershman B, Thompson RH, Boorjian SA, Larcher A, Capitanio U, Montorsi F, et al. Radical nephrectomy with or without lymph node dissection for high risk nonmetastatic renal cell carcinoma: a multi-institutional analysis. *J Urol* 2018;199:1143–8, doi:http://dx.doi.org/10.1016/j.juro.2017.11.114.
- [274] Whitson JM, Harris CR, Reese AC, Meng MV. Lymphadenectomy improves survival of patients with renal cell carcinoma and nodal metastases. *J Urol* 2011;185:1615–20, doi:http://dx.doi.org/10.1016/j.juro.2010.12.053.
- [275] Blom JHM, van Poppel H, Maréchal JM, Jacqmin D, Schröder FH, de Prijck L, et al. Radical nephrectomy with and without lymph-node dissection: final results of European Organization for Research and Treatment of Cancer (EORTC) randomized phase 3 trial 30881. *Eur Urol* 2009;55:28–34, doi:http://dx.doi.org/10.1016/j.eururo.2008.09.052.
- [276] May M, Brookman-Amisshah S, Pflanz S, Roigas J, Hoschke B, Kendel F. Pre-operative renal arterial embolisation does not provide survival benefit in patients with radical nephrectomy for renal cell carcinoma. *Br J Radiol* 2009;82:724–31, doi:http://dx.doi.org/10.1259/bjr/17514226.
- [277] Maxwell NJ, Saleem Amer N, Rogers E, Kiely D, Sweeney P, Brady AP. Renal artery embolisation in the palliative treatment of renal carcinoma. *Br J Radiol* 2007;80:96–102, doi:http://dx.doi.org/10.1259/bjr/31311739.
- [278] Shapiro DD, Wells SA, Best SL, Hedican SP, Ziemlewicz TJ, Lubner MG, et al. Comparing outcomes for patients with clinical T1b renal cell carcinoma treated with either percutaneous microwave ablation or surgery. *Urology* 2020;135:88–94, doi:http://dx.doi.org/10.1016/j.urol.2019.09.024.
- [279] Hasegawa T, Yamanaka T, Gobara H, Miyazaki M, Takaki H, Sato Y, et al. Radiofrequency ablation versus cryoablation for T1b renal cell carcinoma: a multicenter study. *Jpn J Radiol* 2018;36:551–8, doi:http://dx.doi.org/10.1007/s11604-018-0756-x.
- [280] Yanagisawa T, Mori K, Kawada T, Motlagh RS, Mostafaei H, Quhal F, et al. Differential efficacy of ablation therapy versus partial nephrectomy between clinical

- T1a and T1b renal tumors: a systematic review and meta-analysis. *Urol Oncol* 2022;40:315–30, doi:http://dx.doi.org/10.1016/j.urolonc.2022.04.002.
- [281] Schmit GD, Atwell TD, Callstrom MR, Farrell MA, Leibovich BC, Patterson DE, et al. Percutaneous cryoablation of renal masses > or = 3 cm: efficacy and safety in treatment of 108 patients. *J Endourol* 2010;24:1255–62, doi:http://dx.doi.org/10.1089/end.2009.0328.
- [282] Atwell TD, Farrell MA, Callstrom MR, Charboneau JW, Leibovich BC, Frank I, et al. Percutaneous cryoablation of large renal masses: technical feasibility and short-term outcome. *AJR Am J Roentgenol* 2007;188:1195–200, doi:http://dx.doi.org/10.2214/AJR.06.1152.
- [283] Siva S, Correa RJM, Warner A, Staehler M, Ellis RJ, Ponsky L, et al. Stereotactic ablative radiotherapy for \geq T1b primary renal cell carcinoma: a report from the International Radiosurgery Oncology Consortium for Kidney (IROCK). *Int J Radiat Oncol Biol Phys* 2020;108:941–9, doi:http://dx.doi.org/10.1016/j.ijrobp.2020.06.014.
- [284] Almdalal T, Sundqvist P, Harmenberg U, Hellström M, Lindskog M, Lindblad P, et al. Clinical T1a renal cell carcinoma, not always a harmless disease – a national register study. *Eur Urol Open Sci* 2022;39:22–8, doi:http://dx.doi.org/10.1016/j.euros.2022.03.005.
- [285] Boulenger de Hauteclouque A, Ferrer L, Ambrosetti D, Ricard S, Bigot P, Bensalah K, et al. Machine-learning approach for prediction of pT3a upstaging and outcomes of localized renal cell carcinoma (UroCCR-15). *BJU Int* 2023;132:160–9, doi:http://dx.doi.org/10.1111/bju.15959.
- [286] Vecchia A, Falagarò U, Martini A, Marchioni M, Antonelli A, Simeone C, et al. Upstaging to pT3a in patients undergoing partial or radical nephrectomy for cT1 renal tumors: a systematic review and meta-analysis of outcomes and predictive factors. *Eur Urol Focus* 2021;7:574–81, doi:http://dx.doi.org/10.1016/j.euf.2020.05.013.
- [287] Guo S, Liu Z, Li X, Yao K, Dong P, Chen D, et al. The prognostic value of the site of invasion in T3aN0M0 clear cell renal cell carcinoma. *Urol Oncol* 2019;37:301.e11–7, doi:http://dx.doi.org/10.1016/j.urolonc.2019.01.019.
- [288] Wagner B, Patard J-J, Méjean A, Bensalah K, Verhoest G, Zigeuner R, et al. Prognostic value of renal vein and inferior vena cava involvement in renal cell carcinoma. *Eur Urol* 2009;55:452–9, doi:http://dx.doi.org/10.1016/j.euro.2008.07.053.
- [289] Martínez-Salamanca JL, Huang WC, Millán I, Bertini R, Bianco FJ, Carballido JA, et al. Prognostic impact of the 2009 UICC/AJCC TNM staging system for renal cell carcinoma with venous extension. *Eur Urol* 2011;59:120–7, doi:http://dx.doi.org/10.1016/j.euro.2010.10.001.
- [290] Zini L, Perrotte P, Jeldres C, Capitanio U, Pharand D, Arjane P, et al. Nephrectomy improves the survival of patients with locally advanced renal cell carcinoma. *BJU Int* 2008;102:1610–4, doi:http://dx.doi.org/10.1111/j.1464-410X.2008.07917.x.
- [291] Bragayrac LAN, Abbotot D, Attwood K, Darwiche F, Hoffmeyer J, Kauffman EC, et al. Outcomes of minimal invasive vs. open radical nephrectomy for the treatment of locally advanced renal-cell carcinoma. *J Endourol* 2016;30:871–6, doi:http://dx.doi.org/10.1089/end.2016.0082.
- [292] Verhoest G, Couapel J-P, Oger E, Rioux-Leclercq N, Pignot G, Patard J-J, et al. Safety and feasibility of laparoscopic nephrectomy for big tumors (\geq 10 cm): a retrospective multicentric study. *Clin Genitourin Cancer* 2016;14:e335–40, doi:http://dx.doi.org/10.1016/j.clgc.2016.01.007.
- [293] Becher E, Jericevic D, Huang WC. Minimally invasive surgery for patients with locally advanced and/or metastatic renal cell carcinoma. *Urol Clin North Am* 2020;47:389–97, doi:http://dx.doi.org/10.1016/j.ucl.2020.04.004.
- [294] Blom JHM, van Poppel H, Maréchal JM, Jacqmin D, Schröder FH, de Prieck L, et al. Radical nephrectomy with and without lymph-node dissection: final results of European Organization for Research and Treatment of Cancer (EORTC) randomized phase 3 trial 30881. *Eur Urol* 2009;55:28–34, doi:http://dx.doi.org/10.1016/j.euro.2008.09.052.
- [295] Choueiri TK, Escudier B, Powles T, Mainwaring PN, Rini BI, Donskov F, et al. Cabozantinib versus everolimus in advanced renal-cell carcinoma. *N Engl J Med* 2015;373:1814–23, doi:http://dx.doi.org/10.1056/NEJMoa1510016.
- [296] Bekema HJ, MacLennan S, Imamura M, Lam TBL, Stewart F, Scott N, et al. Systematic review of adrenalectomy and lymph node dissection in locally advanced renal cell carcinoma. *Eur Urol* 2013;64:799–810, doi:http://dx.doi.org/10.1016/j.euro.2013.04.033.
- [297] Gershman B, Thompson RH, Moreira DM, Boorjian SA, Tollefson MK, Lohse CM, et al. Radical nephrectomy with or without lymph node dissection for nonmetastatic renal cell carcinoma: a propensity score-based analysis. *Eur Urol* 2017;71:560–7, doi:http://dx.doi.org/10.1016/j.euro.2016.09.019.
- [298] Studer UE, Scherz S, Scheidegger J, Kraft R, Sonntag R, Ackermann D, et al. Enlargement of regional lymph nodes in renal cell carcinoma is often not due to metastases. *J Urol* 1990;144:243–5, doi:http://dx.doi.org/10.1016/s0022-5347(17)39422-3.
- [299] Bhindi B, Wallis CJD, Boorjian SA, Thompson RH, Farrell A, Kim SP, et al. The role of lymph node dissection in the management of renal cell carcinoma: a systematic review and meta-analysis. *BJU Int* 2018;121:684–98, doi:http://dx.doi.org/10.1111/bju.14127.
- [300] Correa AF, Jegede OA, Haas NB, Flaherty KT, Pins MR, Adeniran A, et al. Predicting disease recurrence, early progression, and overall survival following radical resection for high-risk localized and locally advanced renal cell carcinoma. *Eur Urol* 2021;80:20–31, doi:http://dx.doi.org/10.1016/j.euro.2021.02.025.
- [301] Abel EJ, Culp SH, Tannir NM, Matin SF, Tamboli P, Jonasch E, et al. Primary tumor response to targeted agents in patients with metastatic renal cell carcinoma. *Eur Urol* 2011;59:10–5, doi:http://dx.doi.org/10.1016/j.euro.2010.09.034.
- [302] Karam JA, Devine CE, Urbauer DL, Lozano M, Maity T, Ahrar K, et al. Phase 2 trial of neoadjuvant axitinib in patients with locally advanced nonmetastatic clear cell renal cell carcinoma. *Eur Urol* 2014;66:874–80, doi:http://dx.doi.org/10.1016/j.euro.2014.01.035.
- [303] Lebacqz C, Bensalah K, Bernhard J-C, Albiges L, Laguerre B, Gross-Goupil M, et al. Evaluation of axitinib to downstage cT2a renal tumours and allow partial nephrectomy: a phase II study. *BJU Int* 2019;123:804–10, doi:http://dx.doi.org/10.1111/bju.14581.
- [304] Zhu M, Liu Z, Zhou Y, Jiang Z, Chen S, Wang W, et al. Effects of neoadjuvant VEGF-TKI treatment on surgery for renal cell carcinoma: a systematic review and meta-analysis. *Oncol Lett* 2024;27:162, doi:http://dx.doi.org/10.3892/ol.2024.14295.
- [305] Gorin MA, Patel HD, Rowe SP, Hahn NM, Hammers HJ, Pons A, et al. Neoadjuvant nivolumab in patients with high-risk nonmetastatic renal cell carcinoma. *Eur Urol* 2022;5:113–7, doi:http://dx.doi.org/10.1016/j.euro.2021.04.002.
- [306] Albiges L, Tannir NM, Burotto M, McDermott D, Plimack ER, Barthélémy P, et al. First-line nivolumab plus ipilimumab versus sunitinib in patients without nephrectomy and with an evaluable primary renal tumor in the CheckMate 214 trial. *Eur Urol* 2022;81:266–71, doi:http://dx.doi.org/10.1016/j.euro.2021.10.001.
- [307] Carlo MI, Attalla K, Mazaheri Y, Gupta S, Yildirim O, Murray SJ, et al. Phase II study of neoadjuvant nivolumab in patients with locally advanced clear cell renal cell carcinoma undergoing nephrectomy. *Eur Urol* 2022;81:570–3, doi:http://dx.doi.org/10.1016/j.euro.2022.01.043 [S0302-2838(22)00086-0].
- [308] Gu L, Peng C, Li H, Jia T, Chen X, Wang H, et al. Neoadjuvant therapy in renal cell carcinoma with tumor thrombus: a systematic review and meta-analysis. *Crit Rev Oncol Hematol* 2024;196:104316, doi:http://dx.doi.org/10.1016/j.critrevonc.2024.104316.
- [309] Stewart G, Johnson L, Ganesh H, Davenport D, Smelser W, Crispin P, et al. Stone size limits the use of hounsfield units for prediction of calcium oxalate stone composition. *Urology* 2015;85:295–305, doi:http://dx.doi.org/10.1016/j.urol.2014.10.006.
- [310] Westerman ME, Shapiro DD, Wood CG, Karam JA. Neoadjuvant therapy for locally advanced renal cell carcinoma. *Urol Clin North Am* 2020;47:329–43, doi:http://dx.doi.org/10.1016/j.ucl.2020.04.010.
- [311] Leow JJ, Ray S, Dason S, Singer EA, Chang SL. The promise of neoadjuvant and adjuvant therapies for renal cancer. *Urol Clin North Am* 2023;50:285–303, doi:http://dx.doi.org/10.1016/j.ucl.2023.01.011.
- [312] Tanaka H, Ding X, Ye Y, Wang Y, Campbell RA, DeWitt-Foy ME, et al. Infiltrative renal masses: clinical significance and fidelity of documentation. *Eur Urol Oncol* 2021;4:264–73, doi:http://dx.doi.org/10.1016/j.euro.2019.07.015.
- [313] Borregales LD, Kim DY, Staller AL, Qiao W, Thomas AZ, Adibi M, et al. Prognosticators and outcomes of patients with renal cell carcinoma and adjacent organ invasion treated with radical nephrectomy. *Urol Oncol* 2016;34:237.e19–26, doi:http://dx.doi.org/10.1016/j.urolonc.2015.11.020.
- [314] Capitanio U, Perrotte P, Zini L, Jeldres C, Shariat SF, Isbarn H, et al. Nephrectomy improves survival in patients with invasion of adjacent viscera and absence of nodal metastases (stage T4N0 renal cell carcinoma). *BJU Int* 2009;104:795–9, doi:http://dx.doi.org/10.1111/j.1464-410X.2009.08484.x.
- [315] Margulis V, Sánchez-Ortiz RF, Tamboli P, Cohen DD, Swanson DA, Wood CG. Renal cell carcinoma clinically involving adjacent organs: experience with aggressive surgical management. *Cancer* 2007;109:2025–30, doi:http://dx.doi.org/10.1002/cncr.22629.
- [316] Bigot P, Barthelemy P, Boissier R, Khene Z-E, Pettenati C, Bernhard J-C, et al. French AFU Cancer Committee Guidelines – update 2022–2024: management of kidney cancer. *Prog Urol* 2022;32:1195–274, doi:http://dx.doi.org/10.1016/j.purol.2022.07.146.
- [317] Reese AC, Whitson JM, Meng MV. Natural history of untreated renal cell carcinoma with venous tumor thrombus. *Urol Oncol* 2013;31:1305–9, doi:http://dx.doi.org/10.1016/j.urolonc.2011.12.006.
- [318] Cost NG, Delacroix SE, Sleeper JP, Smith PJ, Youssef RF, Chapin BF, et al. The impact of targeted molecular therapies on the level of renal cell carcinoma vena caval tumor thrombus. *Eur Urol* 2011;59:912–8, doi:http://dx.doi.org/10.1016/j.euro.2011.02.032.
- [319] Stewart GD, Welsh SJ, Ursprung S, Gallagher FA, Jones JO, Shields J, et al. A phase II study of neoadjuvant axitinib for reducing the extent of venous tumour thrombus in clear cell renal cell cancer with venous invasion (NAXIVA). *Br J Cancer* 2022;127:1051–60, doi:http://dx.doi.org/10.1038/s41416-022-01883-7.
- [320] Agochukwu N, Shuch B. Clinical management of renal cell carcinoma with venous tumor thrombus. *World J Urol* 2014;32:581–9, doi:http://dx.doi.org/10.1007/s00345-014-1276-7.
- [321] Psutka SP, Boorjian SA, Thompson RH, Schmit GD, Schmitz JJ, Bower TC, et al. Clinical and radiographic predictors of the need for inferior vena cava resection during nephrectomy for patients with renal cell carcinoma and caval tumour thrombus. *BJU Int* 2015;116:388–96, doi:http://dx.doi.org/10.1111/bju.13005.
- [322] Gohji K, Yamashita C, Ueno K, Shimogaki H, Kamidono S. Preoperative computerized tomography detection of extensive invasion of the inferior vena cava by renal cell carcinoma: possible indication for resection with partial cardiopulmonary bypass and patch grafting. *J Urol* 1994;152:1993–6, doi:http://dx.doi.org/10.1016/s0022-5347(17)32288-7 [discussion 1997].
- [323] Smith RK, Navaratnam A, Vivian P. Systematic review and meta-analysis of preoperative imaging prediction of renal cell carcinoma tumour thrombus inferior vena cava wall invasion. *Clin Radiol* 2023;78:540–7, doi:http://dx.doi.org/10.1016/j.crad.2023.02.022.
- [324] Lawrentschuk N, Gani J, Riordan R, Esler S, Bolton DM. Multidetector computed tomography vs. magnetic resonance imaging for defining the upper limit of tumour thrombus in renal cell carcinoma: a study and review. *BJU Int* 2005;96:291–5, doi:http://dx.doi.org/10.1111/j.1464-410X.2005.05617.x.
- [325] Shirodkar SP, Soloway MS, Ciancio G. Budd-Chiari syndrome in urology: impact on nephrectomy for advanced renal cell carcinoma. *Indian J Urol* 2011;27:351–6, doi:http://dx.doi.org/10.4103/0970-1591.85439.

- [326] Garg H, Psutka SP, Hakimi AA, Kim HL, Mansour AM, Pruthi DK, et al. A decade of robotic-assisted radical nephrectomy with inferior vena cava thrombectomy: a systematic review and meta-analysis of perioperative outcomes. *J Urol* 2022;208:542–60, doi:http://dx.doi.org/10.1097/JU.0000000000002829.
- [327] Shi T, Huang Q, Liu K, Du S, Fan Y, Yang L, et al. Robot-assisted cavectomy versus thrombectomy for level II inferior vena cava thrombus: decision-making scheme and multi-institutional analysis. *Eur Urol* 2020;78:592–602, doi:http://dx.doi.org/10.1016/j.eururo.2020.03.020.
- [328] Abaza R, Eun DD, Gallucci M, Gill IS, Menon M, Mottrie A, et al. Robotic surgery for renal cell carcinoma with vena caval tumor thrombus. *Eur Urol Focus* 2016;2:601–7, doi:http://dx.doi.org/10.1016/j.euf.2017.01.001.
- [329] Gill IS, Metcalfe C, Abreu A, Duddalwar V, Chopra S, Cunningham M, et al. Robotic level III inferior vena cava tumor thrombectomy: initial series. *J Urol* 2015;194:929–38, doi:http://dx.doi.org/10.1016/j.juro.2015.03.119.
- [330] Baboudjian M, Gondran-Tellier B, Khene Z, Bigot P, Mejean A, Lang H, et al. Predictive factors of recurrence after surgery in patients with non-metastatic renal cell carcinoma with venous tumor thrombus (UroCCR-56 study). *World J Urol* 2023;41:295–302, doi:http://dx.doi.org/10.1007/s00345-021-03640-6.
- [331] Choueiri TK, Tomczak P, Park SH, Venugopal B, Ferguson T, Chang Y-H, et al. Adjuvant pembrolizumab after nephrectomy in renal-cell carcinoma. *N Engl J Med* 2021;385:683–94, doi:http://dx.doi.org/10.1056/NEJMoa2106391.
- [332] Powles T, Tomczak P, Park SH, Venugopal B, Ferguson T, Symeonides SN, et al. Pembrolizumab versus placebo as post-nephrectomy adjuvant therapy for clear cell renal cell carcinoma (KEYNOTE-564): 30-month follow-up analysis of a multicentre, randomised, double-blind, placebo-controlled, phase 3 trial. *Lancet Oncol* 2022;23:1133–44, doi:http://dx.doi.org/10.1016/S1470-2045(22)00487-9.
- [333] Fleury R, Bertail T, Bensalah K, Bernhard J-C, Audenet F, Waeckel T, et al. The impact of histological variants on oncological outcomes after surgical resection of a nonmetastatic renal cell carcinoma with tumor thrombus: a multi-institutional study. *Eur Urol Open Sci* 2024;62:123–30, doi:http://dx.doi.org/10.1016/j.euro.2024.02.015.
- [334] Yang Q, Meng F, Li K, Wang T, Nie Q, Che Z, et al. Safety and efficacy of thermal ablation for small renal masses in solitary kidney: evidence from meta-analysis of comparative studies. *PLoS One* 2015;10:e0131290, doi:http://dx.doi.org/10.1371/journal.pone.0131290.
- [335] Long J-A, Bernhard J-C, Bigot P, Lanchon C, Paparel P, Rioux-Leclercq N, et al. Partial nephrectomy versus ablative therapy for the treatment of renal tumors in an imperative setting. *World J Urol* 2017;35:649–56, doi:http://dx.doi.org/10.1007/s00345-016-1913-4.
- [336] Benichou Y, Audenet F, Bensalah K, Roupret M, Paparel P, Lebacle C, et al. Partial nephrectomy in solitary kidneys: comparison between open surgery and robotic-assisted laparoscopy on perioperative and functional outcomes (UroCCR-54 study). *World J Urol* 2023;41:315–24, doi:http://dx.doi.org/10.1007/s00345-022-04026-y.
- [337] Badani KK, Kothari PD, Okhawere KE, Eun D, Hemal A, Abaza R, et al. Selective clamping during robot-assisted partial nephrectomy in patients with a solitary kidney: is it safe and does it help? *BJU Int* 2020;125:893–7, doi:http://dx.doi.org/10.1111/bju.15043.
- [338] Attawettayanon W, Yasuda Y, Zhang JH, Rathi N, Munoz-Lopez C, Kazama A, et al. Functional recovery after partial nephrectomy in a solitary kidney. *Urol Oncol* 2024;42:32.e17–27, doi:http://dx.doi.org/10.1016/j.urolonc.2023.12.004.
- [339] Thompson RH, Lane BR, Lohse CM, Leibovich BC, Fergany A, Frank I, et al. Comparison of warm ischemia versus no ischemia during partial nephrectomy on a solitary kidney. *Eur Urol* 2010;58:331–6, doi:http://dx.doi.org/10.1016/j.eururo.2010.05.048.
- [340] Anceschi U, Brassetti A, Bertolo R, Tuderti G, Ferriero MC, Mastroianni R, et al. On-clamp versus purely off-clamp robot-assisted partial nephrectomy in solitary kidneys: comparison of perioperative outcomes and chronic kidney disease progression at two high-volume centers. *Minerva Urol Nephrol* 2021;73:739–45, doi:http://dx.doi.org/10.23736/S2724-6051.20.03795-9.
- [341] Brassetti A, Cacciamani GE, Mari A, Garisto JD, Bertolo R, Sundaram CP, et al. On-clamp vs. off-clamp robot-assisted partial nephrectomy for cT2 renal tumors: retrospective propensity-score-matched multicenter outcome analysis. *Cancers* 2022;14:4431, doi:http://dx.doi.org/10.3390/cancers14184431.
- [342] Tillou X, Doerfler A, Szabla N, Verhoest G, Defortescu G, Bessedé T, et al. [Renal cell carcinoma of the kidney transplant: the French guidelines from CTAUF]. *Prog Urol* 2021;31:24–30, doi:http://dx.doi.org/10.1016/j.purol.2020.04.029.
- [343] Griffith JJ, Amin KA, Waingankar N, Lerner SM, Delaney V, Ames SA, et al. Solid renal masses in transplanted allograft kidneys: a closer look at the epidemiology and management. *Am J Transplant* 2017;17:2775–81, doi:http://dx.doi.org/10.1111/ajt.14366.
- [344] Minkovich M, Wong RBK, Famure O, Li Y, Kim SJ, Lee JY. Renal cell carcinoma in kidney transplant recipients: incidence, trends, clinical management & outcomes. *World J Urol* 2023;41:2389–95, doi:http://dx.doi.org/10.1007/s00345-023-04495-9.
- [345] Gigante M, Neuzillet Y, Patard J-J, Tillou X, Thuret R, Branchereau J, et al. Renal cell carcinoma (RCC) arising in native kidneys of dialyzed and transplant patients: are they different entities? *BJU Int* 2012;110:E570–3, doi:http://dx.doi.org/10.1111/j.1464-410X.2012.11273.x.
- [346] Goujon A, Verhoest G, Sallusto F, Branchereau J, Boutin J-M, Bessedé T, et al. [Renal cell carcinoma in candidates for renal transplantation and recipients of a kidney transplant: the French guidelines from CTAUF]. *Prog Urol* 2021;31:18–23, doi:http://dx.doi.org/10.1016/j.purol.2020.04.030.
- [347] Hora M, Hes O, Reischig T, Urge T, Klecka J, Ferda J, et al. Tumours in end-stage kidney. *Transplant Proc* 2008;40:3354–8, doi:http://dx.doi.org/10.1016/j.transproceed.2008.08.135.
- [348] Pan H-C, Sun C-Y, Wu I-W, Tsai T-L, Sun C-C, Lee C-C. Higher risk of malignant neoplasms in young adults with end-stage renal disease receiving haemodialysis: a nationwide population-based study. *Nephrology (Carlton)* 2019;24:1165–71, doi:http://dx.doi.org/10.1111/nep.13555.
- [349] Tillou X, Doerfler A, Collon S, Kleinclauss F, Patard J-J, Badet L, et al. De novo kidney graft tumors: results from a multicentric retrospective national study. *Am J Transplant* 2012;12:3308–15, doi:http://dx.doi.org/10.1111/j.1600-6143.2012.04248.x.
- [350] Vaudreuil L, Bessedé T, Boissier R, Bouye S, Branchereau J, Caillet K, et al. De novo renal carcinoma arising in non-functional kidney graft: a national retrospective study. *Int Urol Nephrol* 2020;52:1235–41, doi:http://dx.doi.org/10.1007/s11255-020-02422-0.
- [351] Swords DC, Al-Geizawi SM, Farney AC, Rogers J, Burkart JM, Assimos DG, et al. Treatment options for renal cell carcinoma in renal allografts: a case series from a single institution. *Clin Transplant* 2013;27:E199–205, doi:http://dx.doi.org/10.1111/ctr.12088.
- [352] Ploussard G, Chambade D, Meria P, Gaudez F, Tariel E, Verine J, et al. Biopsy-confirmed de novo renal cell carcinoma (RCC) in renal grafts: a single-centre management experience in a 2396 recipient cohort. *BJU Int* 2012;109:195–9, doi:http://dx.doi.org/10.1111/j.1464-410X.2011.10315.x.
- [353] Viart L, Surga N, Collon S, Jauregui M, Elalouf Y, Tillou X. The high rate of de novo graft carcinomas in renal transplant recipients. *Am J Nephrol* 2013;37:91–6, doi:http://dx.doi.org/10.1159/000346624.
- [354] Dahle DO, Skauby M, Langberg CW, Brabrand K, Wessel N, Midtvedt K. Renal cell carcinoma and kidney transplantation: a narrative review. *Transplantation* 2022;106:e52–63, doi:http://dx.doi.org/10.1097/TP.0000000000003762.
- [355] Laclergerie F, Delchier M-C, Covin B, Sallusto F, Soulie M, Gamé X, et al. Robot-assisted laparoscopic partial nephrectomy with renal artery clamping using an endovascular balloon catheter for an allograft kidney tumor: a new perspective to manage renal vascular control? *Am J Transplant* 2019;19:1239–40, doi:http://dx.doi.org/10.1111/ajt.15151.
- [356] Tydén G, Wernersson A, Sandberg J, Berg U. Development of renal cell carcinoma in living donor kidney grafts. *Transplantation* 2000;70:1650–6, doi:http://dx.doi.org/10.1097/00007890-200012150-00018.
- [357] Mindrup S, Rayhill S, Fallon B. Renal cell carcinoma in a transplanted kidney. *J Urol* 2001;165:1990, doi:http://dx.doi.org/10.1097/00005392-200106000-00039.
- [358] Cornelis F, Buy X, André M, Oyen R, Bouffard-Vercelli J, Blandino A, et al. De novo renal tumors arising in kidney transplants: midterm outcome after percutaneous thermal ablation. *Radiology* 2011;260:900–7, doi:http://dx.doi.org/10.1148/radiol.11110122.
- [359] Gul ZG, Griffith JJ, Welch C, Fischman A, Palese MA, Badani KK, et al. Focal ablative therapy for renal cell carcinoma in transplant allograft kidneys. *Urology* 2019;125:118–22, doi:http://dx.doi.org/10.1016/j.urol.2018.12.003.
- [360] Favi E, Raison N, Ambrogi F, Delbue S, Clementi MC, Lamperti L, et al. Systematic review of ablative therapy for the treatment of renal allograft neoplasms. *World J Clin Cases* 2019;7:2487–504, doi:http://dx.doi.org/10.12998/wjcc.v7.i17.2487.
- [361] Tsaur I, Obermüller N, Jonas D, Blaheta R, Juengel E, Scheuermann E-H, et al. De novo renal cell carcinoma of native and graft kidneys in renal transplant recipients. *BJU Int* 2011;108:229–34, doi:http://dx.doi.org/10.1111/j.1464-410X.2010.09856.x.
- [362] Butler AM, Olshan AF, Kshirsagar AV, Edwards JK, Nielsen ME, Wheeler SB, et al. Cancer incidence among US Medicare ESRD patients receiving hemodialysis, 1996–2009. *Am J Kidney Dis* 2015;65:763–72, doi:http://dx.doi.org/10.1053/j.ajkd.2014.12.013.
- [363] Ball MW, An JY, Gomella PT, Gautam R, Ricketts CJ, Vocke CD, et al. Growth rates of genetically defined renal tumors: implications for active surveillance and intervention. *J Clin Oncol* 2020;38:1146–53, doi:http://dx.doi.org/10.1200/JCO.19.02263.
- [364] Gomella PT, Linehan W, Ball MW. Precision surgery and kidney cancer: knowledge of genetic alterations influences surgical management. *Genes* 2021;12:261, doi:http://dx.doi.org/10.3390/genes12020261.
- [365] Grubb RL, Franks ME, Toro J, Middleton L, Choyke L, Fowler S, et al. Hereditary leiomyomatosis and renal cell cancer: a syndrome associated with an aggressive form of inherited renal cancer. *J Urol* 2007;177:2074–9, doi:http://dx.doi.org/10.1016/j.juro.2007.01.155 [discussion 2079–2080].
- [366] Choueiri TK, Vaishampayan U, Rosenberg JE, Logan TF, Harzstark AL, Bukowski RM, et al. Phase II and biomarker study of the dual MET/VEGFR2 inhibitor foretinib in patients with papillary renal cell carcinoma. *JCO* 2013;31:181–6, doi:http://dx.doi.org/10.1200/JCO.2012.43.3383.
- [367] Choueiri TK, Heng DYC, Lee JL, Cancel M, Verheijen RB, Mellemaard A, et al. Efficacy of savolitinib vs. sunitinib in patients with met-driven papillary renal cell carcinoma: the SAVOIR phase 3 randomized clinical trial. *JAMA Oncol* 2020;6:1247–55, doi:http://dx.doi.org/10.1001/jamaoncol.2020.2218.
- [368] Jonasch E, Donskov F, Iliopoulos O, Rathmell WK, Narayan VK, Maughan BL, et al. Belzutifan for renal cell carcinoma in von Hippel-Lindau disease. *N Engl J Med* 2021;385:2036–46, doi:http://dx.doi.org/10.1056/NEJMoa2103425.
- [369] Nouhaud F-X, Bernhard J-C, Bigot P, Khene Z-E, Audenet F, Lang H, et al. Contemporary assessment of the correlation between Bosniak classification and histological characteristics of surgically removed atypical renal cysts (UroCCR-12 study). *World J Urol* 2018;36:1643–9, doi:http://dx.doi.org/10.1007/s00345-018-2307-6.
- [370] Boissier R, Ouzaid I, Nouhaud FX, Khene Z, Dariane C, Chkir S, et al. Long-term oncological outcomes of cystic renal cell carcinoma according to the Bosniak classification. *Int Urol Nephrol* 2019;51:951–8, doi:http://dx.doi.org/10.1007/s11255-019-02085-6.

- [371] Gerst S, Hann LE, Li D, Gonen M, Tickoo S, Sohn MJ, et al. Evaluation of renal masses with contrast-enhanced ultrasound: initial experience. *AJR Am J Roentgenol* 2011;197:897–906, doi:http://dx.doi.org/10.2214/AJR.10.6330.
- [372] Defortescu G, Cornu J-N, Béjar S, Giverc A, Gobet F, Werquin C, et al. Diagnostic performance of contrast-enhanced ultrasonography and magnetic resonance imaging for the assessment of complex renal cysts: a prospective study. *Int J Urol* 2017;24:184–9, doi:http://dx.doi.org/10.1111/iju.13289.
- [373] Silverman SG, Pedrosa I, Ellis JH, Hindman NM, Schieda N, Smith AD, et al. Bosniak classification of cystic renal masses, version 2019: an update proposal and needs assessment. *Radiology* 2019;292:475–88, doi:http://dx.doi.org/10.1148/radiol.2019182646.
- [374] Bosniak MA. The Bosniak renal cyst classification: 25 years later. *Radiology* 2012;262:781–5, doi:http://dx.doi.org/10.1148/radiol.11111595.
- [375] Warren KS, McFarlane J. The Bosniak classification of renal cystic masses. *BJU Int* 2005;95:939–42, doi:http://dx.doi.org/10.1111/j.1464-410X.2005.05442.x.
- [376] Ramachandran A. Differentiating benign from malignant cystic renal masses using CT texture-based machine learning algorithms. *Radiol Imaging Cancer* 2024;6:e249007, doi:http://dx.doi.org/10.1148/rycan.249007.
- [377] Schoots IG, Zaccari K, Hunink MG, Verhagen PCMS. Bosniak classification for complex renal cysts reevaluated: a systematic review. *J Urol* 2017;198:12–21, doi:http://dx.doi.org/10.1016/j.juro.2016.09.160.
- [378] Marconi L, Dabestani S, Lam TB, Hofmann F, Stewart F, Norrie J, et al. Systematic review and meta-analysis of diagnostic accuracy of percutaneous renal tumour biopsy. *Eur Urol* 2016;69:660–73, doi:http://dx.doi.org/10.1016/j.eururo.2015.07.072.
- [379] Westerman ME, Chevillat JC, Lohse CM, Sharma V, Boorjian SA, Leibovich BC, et al. Long-term outcomes of patients with low grade cystic renal epithelial neoplasms. *Urology* 2019;133:145–50, doi:http://dx.doi.org/10.1016/j.urology.2019.07.017.
- [380] Pradere B, Peyronnet B, Delporte G, Manach O, Khene Z-E, Moulin M, et al. Intraoperative cyst rupture during partial nephrectomy for cystic renal masses—does it increase the risk of recurrence? *J Urol* 2018;200:1200–6, doi:http://dx.doi.org/10.1016/j.juro.2018.06.025.
- [381] Moch H, Cubilla AL, Humphrey PA, Reuter VE, Ulbright TM. The 2016 WHO classification of tumours of the urinary system and male genital organs – part A: renal, penile, and testicular tumours. *Eur Urol* 2016;70:93–105, doi:http://dx.doi.org/10.1016/j.eururo.2016.02.029.
- [382] Adamy A, Lowrance WT, Yee DS, Chong KT, Bernstein M, Tickoo SK, et al. Renal oncocytosis: management and clinical outcomes. *J Urol* 2011;185:795–801, doi:http://dx.doi.org/10.1016/j.juro.2010.10.068.
- [383] Hes O, Petersson F, Kuroda N, Hora M, Michal M. Renal hybrid oncocytic/chromophobe tumors – a review. *Histol Histopathol* 2013;28:1257–64, doi:http://dx.doi.org/10.14670/HH-28.1257.
- [384] Baboudjian M, Moser D, Yanagisawa T, Gondran-Tellier B, Compérat EM, Ambrosetti D, et al. Benefit and harm of active surveillance for biopsy-proven renal oncocytoma: a systematic review and pooled analysis. *Eur Urol Open Sci* 2022;41:8–15, doi:http://dx.doi.org/10.1016/j.euro.2022.04.009.
- [385] Deledalle F-X, Ambrosetti D, Durand M, Michel F, Baboudjian M, Gondran-Tellier B, et al. Active surveillance for biopsy proven renal oncocytomas: outcomes and feasibility. *Urology* 2021;156:185–90, doi:http://dx.doi.org/10.1016/j.urology.2021.05.034 [S0090-4295(21)00453-2].
- [386] Patel HD, Druskin SC, Rowe SP, Piorozzo PM, Gorin MA, Allaf ME. Surgical histopathology for suspected oncocytoma on renal mass biopsy: a systematic review and meta-analysis. *BJU Int* 2017;119:661–6, doi:http://dx.doi.org/10.1111/bju.13763.
- [387] Neuzillet Y, Lechevallier E, Andre M, Daniel L, Nahon O, Coulange C. Follow-up of renal oncocytoma diagnosed by percutaneous tumor biopsy. *Urology* 2005;66:1181–5, doi:http://dx.doi.org/10.1016/j.urology.2005.06.001.
- [388] Kawaguchi S, Fernandes KA, Finelli A, Robinette M, Fleschner N, Jewett MAS. Most renal oncocytomas appear to grow: observations of tumor kinetics with active surveillance. *J Urol* 2011;186:1218–22, doi:http://dx.doi.org/10.1016/j.juro.2011.05.080.
- [389] Kurup AN, Thompson RH, Leibovich BC, Harmsen WS, Sebo TJ, Callstrom MR, et al. Renal oncocytoma growth rates before intervention. *BJU Int* 2012;110:1444–8, doi:http://dx.doi.org/10.1111/j.1464-410X.2012.011136.x.
- [390] Richard PO, Jewett MAS, Bhatt JR, Evans AJ, Timilsina N, Finelli A. Active surveillance for renal neoplasms with oncocytic features is safe. *J Urol* 2016;195:581–6, doi:http://dx.doi.org/10.1016/j.juro.2015.09.067.
- [391] Liu S, Lee S, Rashid P, Bangash H, Hamid A, Lau J, et al. Active surveillance is suitable for intermediate term follow-up of renal oncocytoma diagnosed by percutaneous core biopsy. *BJU Int* 2016;118(Suppl. 3):30–4, doi:http://dx.doi.org/10.1111/bju.13538.
- [392] Alderman MA, Daignault S, Wolf JS, Palapattu GS, Weizer AZ, Hafez KS, et al. Categorizing renal oncocytic neoplasms on core needle biopsy: a morphologic and immunophenotypic study of 144 cases with clinical follow-up. *Hum Pathol* 2016;55:1–10, doi:http://dx.doi.org/10.1016/j.humpath.2016.03.017.
- [393] Neves JB, Varley R, Agnesi S, Withington J, Rodrigues FB, Warren H, et al. Growth and renal function dynamics of renal oncocytomas in patients on active surveillance. *BJU Int* 2021;128:722–7, doi:http://dx.doi.org/10.1111/bju.15499.
- [394] Deledalle F-X, Ambrosetti D, Durand M, Michel F, Baboudjian M, Gondran-Tellier B, et al. Active surveillance for biopsy proven renal oncocytomas: outcomes and feasibility. *Urology* 2021;156:185–90, doi:http://dx.doi.org/10.1016/j.urology.05.034 [S0090-4295(21)00453-2].
- [395] Meagher MF, Lane BR, Capitanio U, Mehrazin R, Bradshaw AW, Noyes S, et al. Comparison of renal functional outcomes of active surveillance and partial nephrectomy in the management of oncocytoma. *World J Urol* 2021;39:1195–201, doi:http://dx.doi.org/10.1007/s00345-020-03299-5.
- [396] Miller BL, Mankowski Gettle L, Van Roo JR, Ziemlewicz TJ, Best SL, Wells SA, et al. Comparative analysis of surgery, thermal ablation, and active surveillance for renal oncocytic neoplasms. *Urology* 2018;112:92–7, doi:http://dx.doi.org/10.1016/j.urology.2017.09.016.
- [397] Tamboli P, Ro JY, Amin MB, Ligato S, Ayala AG. Benign tumors and tumor-like lesions of the adult kidney. Part II: benign mesenchymal and mixed neoplasms, and tumor-like lesions. *Adv Anat Pathol* 2000;7:47–66, doi:http://dx.doi.org/10.1097/00125480-200007010-00007.
- [398] Flum AS, Hamoui N, Said MA, Yang XJ, Casalino DD, McGuire BB, et al. Update on the diagnosis and management of renal angiomyolipoma. *J Urol* 2016;195:834–46, doi:http://dx.doi.org/10.1016/j.juro.2015.07.126.
- [399] Simpfendorfer C, Herts BR, Motta-Ramirez GA, Lockwood DS, Zhou M, Leibler M, et al. Angiomyolipoma with minimal fat on MDCT: can counts of negative-attenuation pixels aid diagnosis? *AJR Am J Roentgenol* 2009;192:438–43, doi:http://dx.doi.org/10.2214/AJR.08.1180.
- [400] Sivalingam S, Nakada SY. Contemporary minimally invasive treatment options for renal angiomyolipomas. *Curr Urol Rep* 2013;14:147–53, doi:http://dx.doi.org/10.1007/s11934-013-0311-3.
- [401] Northrup H, Aronow ME, Bebin EM, Bissler J, Darling TN, de Vries PJ, et al. Updated international tuberous sclerosis complex diagnostic criteria and surveillance and management recommendations. *Pediatr Neurol* 2021;123:50–66, doi:http://dx.doi.org/10.1016/j.pediatrneurol.2021.07.011.
- [402] Zhang JQ, Fielding JR, Zou KH. Etiology of spontaneous perirenal hemorrhage: a meta-analysis. *J Urol* 2002;167:1593–6, doi:http://dx.doi.org/10.1097/00005392-200204000-00006.
- [403] Fernández-Pello S, Hora M, Kuusk T, Tahbaz R, Dabestani S, Abu-Ghanem Y, et al. Management of sporadic renal angiomyolipomas: a systematic review of available evidence to guide recommendations from the European Association of Urology Renal Cell Carcinoma Guidelines Panel. *Eur Urol Oncol* 2020;3:57–72, doi:http://dx.doi.org/10.1016/j.euo.2019.04.005.
- [404] Ljungberg B, Bensalah K, Canfield S, Dabestani S, Hofmann F, Hora M, et al. EAU guidelines on renal cell carcinoma: 2014 update. *Eur Urol* 2015;67:913–24, doi:http://dx.doi.org/10.1016/j.eururo.2015.01.005.
- [405] Oesterling JE, Fishman EK, Goldman SM, Marshall FF. The management of renal angiomyolipoma. *J Urol* 1986;135:1121–4, doi:http://dx.doi.org/10.1016/s0022-5347(17)46013-7.
- [406] Ouzaid I, Autorino R, Fatica R, Herts BR, McLennan G, Remer EM, et al. Active surveillance for renal angiomyolipoma: outcomes and factors predictive of delayed intervention. *BJU Int* 2014;114:412–7, doi:http://dx.doi.org/10.1111/bju.12604.
- [407] Bhatt JR, Richard PO, Kim NS, Finelli A, Manickavachagam K, Legere L, et al. Natural history of renal angiomyolipoma (AML): most patients with large AMLs > 4 cm can be offered active surveillance as an initial management strategy. *Eur Urol* 2016;70:85–90, doi:http://dx.doi.org/10.1016/j.eururo.2016.01.048.
- [408] Grassano Y, Rollin P, Hermieu N, Schoentgen N, Xylina E, Hermieu J-F, et al. [Results of active surveillance for sporadic renal angiomyolipomas greater than 4 cm: a pledge for active surveillance]. *Prog Urol* 2021;31:99–104, doi:http://dx.doi.org/10.1016/j.purol.2020.08.004.
- [409] Nese N, Martignoni G, Fletcher CD, Gupta R, Pan C-C, Kim H, et al. Pure epithelioid PEComas (so-called epithelioid angiomyolipoma) of the kidney: a clinicopathologic study of 41 cases: detailed assessment of morphology and risk stratification. *Am J Surg Pathol* 2011;35:161–76, doi:http://dx.doi.org/10.1097/PAS.0b013e318206f2a9.
- [410] Crino PB, Nathanson KL, Henske EP. The tuberous sclerosis complex. *N Engl J Med* 2006;355:1345–56, doi:http://dx.doi.org/10.1056/NEJMra055323.
- [411] Ebrahimi-Fakhari D, Mann LL, Poryo M, Graf N, von Kries R, Heinrich B, et al. Incidence of tuberous sclerosis and age at first diagnosis: new data and emerging trends from a national, prospective surveillance study. *Orphanet J Rare Dis* 2018;13:117, doi:http://dx.doi.org/10.1186/s13023-018-0870-y.
- [412] Bissler JJ, Kingswood JC, Radzikowska E, Zonnenberg BA, Frost M, Belousova E, et al. Everolimus for angiomyolipoma associated with tuberous sclerosis complex or sporadic lymphangioleiomyomatosis (EXIST-2): a multicentre, randomised, double-blind, placebo-controlled trial. *Lancet* 2013;381:817–24, doi:http://dx.doi.org/10.1016/S0140-6736(12)61767-X.
- [413] Kingswood JC, Belousova E, Benedik MP, Carter T, Cottin V, Curatolo P, et al. Renal manifestations of tuberous sclerosis complex: key findings from the final analysis of the TOSCA study focussing mainly on renal angiomyolipomas. *Front Neurol* 2020;11:972, doi:http://dx.doi.org/10.3389/fneur.2020.00972.
- [414] Samama C-M, Albaladejo P, Laversin S, Marret E. [Prevention of venous thromboembolism in surgery and obstetrics]. *Ann Fr Anesth Reanim* 2005;24:853–61, doi:http://dx.doi.org/10.1016/j.annfar.2005.06.011.
- [415] Tikkinen KAO, Craigie S, Agarwal A, Violette PD, Novara G, Cartwright R, et al. Procedure-specific risks of thrombosis and bleeding in urological cancer surgery: systematic review and meta-analysis. *Eur Urol* 2018;73:242–51, doi:http://dx.doi.org/10.1016/j.eururo.2017.03.008.
- [416] Azawi NH, Tolouee S, Dabestani S. Incidence and associated risk factors of venous thromboembolism after open and laparoscopic partial nephrectomy in patients administered short-period thromboprophylaxis: a Danish nationwide population-based cohort study. *Scand J Urol* 2023;57:81–5, doi:http://dx.doi.org/10.1080/21681805.2023.2171112.
- [417] Ayoub E, Kutchukian S, Bigot P, Dinh A, Gondran-Tellier B, Robin H, et al. Asymptomatic bacteriuria prior to partial and radical nephrectomy: to screen or not to screen? Results from the national and multicenter TOCUS database. *World J Urol* 2024;42:179, doi:http://dx.doi.org/10.1007/s00345-024-04853-1.
- [418] Chen Y-C, Chang Y-J, Tsou Y-C, Chen M-C, Pai Y-C. Effectiveness of nurse case management compared with usual care in cancer patients at a single medical center

- in Taiwan: a quasi-experimental study. *BMC Health Serv Res* 2013;13:202, doi: <http://dx.doi.org/10.1186/1472-6963-13-202>.
- [419] Chen S, He Z, Yao S, Xiong K, Shi J, Wang G, et al. Enhanced recovery after surgery protocol optimizes results and cost of laparoscopic radical nephrectomy. *Front Oncol* 2022;12:840363, doi: <http://dx.doi.org/10.3389/fonc.2022.840363>.
- [420] Ingels A, Duc S, Bensalah K, Bigot P, Paparel P, Beauval J-B, et al. Postoperative outcomes of elderly patients undergoing partial nephrectomy. *Sci Rep* 2021;11:17201, doi: <http://dx.doi.org/10.1038/s41598-021-96676-y>.
- [421] Dabestani S, Marconi L, Kuusk T, Bex A. Follow-up after curative treatment of localised renal cell carcinoma. *World J Urol* 2018;36:1953–9, doi: <http://dx.doi.org/10.1007/s00345-018-2338-z>.
- [422] Beisland C, Guðbrandsdóttir G, Reisæter LAR, Bostad L, Hjelle KM. A prospective risk-stratified follow-up programme for radically treated renal cell carcinoma patients: evaluation after eight years of clinical use. *World J Urol* 2016;34:1087–99, doi: <http://dx.doi.org/10.1007/s00345-016-1796-4>.
- [423] Merrill SB, Sohl BS, Hamirani A, Lehman EB, Lehman KK, Kaag MG, et al. Capturing renal cell carcinoma recurrences when asymptomatic improves patient survival. *Clin Genitourin Cancer* 2019;17:132–8, doi: <http://dx.doi.org/10.1016/j.clgc.2018.11.009>.
- [424] Bigot P, Bernhard J-C, Khene Z-E, Dariane C, Lebdaï S, Doumerc N, et al. Nephrectomy for kidney tumour increases the risk of de novo arterial hypertension. *BJU Int* 2023;132:575–80, doi: <http://dx.doi.org/10.1111/bju.16124>.
- [425] Leppert JT, Lamberts RW, Thomas I-C, Chung BI, Sonn GA, Skinner EC, et al. Incident CKD after radical or partial nephrectomy. *J Am Soc Nephrol* 2018;29:207–16, doi: <http://dx.doi.org/10.1681/ASN.2017020136>.
- [426] Dabestani S, Beisland C, Stewart GD, Bensalah K, Gudmundsson E, Lam TB, et al. Long-term outcomes of follow-up for initially localised clear cell renal cell carcinoma: RECUR database analysis. *Eur Urol Focus* 2019;5:857–66, doi: <http://dx.doi.org/10.1016/j.euf.2018.02.010>.
- [427] Jamil ML, Keeley J, Sood A, Dalela D, Arora S, Peabody JO, et al. Long-term risk of recurrence in surgically treated renal cell carcinoma: a post hoc analysis of the Eastern Cooperative Oncology Group – American College of Radiology Imaging Network E2805 trial cohort. *Eur Urol* 2020;77:277–81, doi: <http://dx.doi.org/10.1016/j.eururo.2019.10.028>.
- [428] Bensalah K, Leray E, Fergelot P, Rioux-Leclercq N, Tostain J, Guillé F, et al. Prognostic value of thrombocytosis in renal cell carcinoma. *J Urol* 2006;175:859–63, doi: [http://dx.doi.org/10.1016/S0022-5347\(05\)00526-4](http://dx.doi.org/10.1016/S0022-5347(05)00526-4).
- [429] Hu X, Liao D-W, Yang Z-Q, Yang W-X, Xiong S-C, Li X. Sarcopenia predicts prognosis of patients with renal cell carcinoma: a systematic review and meta-analysis. *Int Braz J Urol* 2020;46:705–15, doi: <http://dx.doi.org/10.1590/S1677-5538.IBJU.2019.0636>.
- [430] Kim HL, Han K-R, Zisman A, Figlin RA, Belldegrin AS. Cachexia-like symptoms predict a worse prognosis in localized t1 renal cell carcinoma. *J Urol* 2004;171:1810–3, doi: <http://dx.doi.org/10.1097/01.ju.0000121440.82581.d3>.
- [431] Shao Y, Wu B, Jia W, Zhang Z, Chen Q, Wang D. Prognostic value of pretreatment neutrophil-to-lymphocyte ratio in renal cell carcinoma: a systematic review and meta-analysis. *BMC Urol* 2020;20:90, doi: <http://dx.doi.org/10.1186/s12894-020-00665-8>.
- [432] Nocera L, Collà Ruvolo C, Stolzenbach LF, Wenzel M, Tian Z, Larcher A, et al. Tumor stage and substage predict cancer-specific mortality after nephrectomy for nonmetastatic renal cancer: histological subtype-specific validation. *Eur Urol Focus* 2022;8:182–90, doi: <http://dx.doi.org/10.1016/j.euf.2021.02.009>.
- [433] Khor L-Y, Dhakal HP, Jia X, Reynolds JP, McKenney JK, Rini BI, et al. Tumor necrosis adds prognostically significant information to grade in clear cell renal cell carcinoma: a study of 842 consecutive cases from a single institution. *Am J Surg Pathol* 2016;40:1224–31, doi: <http://dx.doi.org/10.1097/PAS.0000000000000690>.
- [434] Delahunt B, Chevillat JC, Martignoni G, Humphrey PA, Magi-Galluzzi C, McKenney J, et al. The International Society of Urological Pathology (ISUP) grading system for renal cell carcinoma and other prognostic parameters. *Am J Surg Pathol* 2013;37:1490–504, doi: <http://dx.doi.org/10.1097/PAS.0b013e318299f0fb>.
- [435] Bailey GC, Boorjian SA, Ziegelmann MJ, Westerman ME, Lohse CM, Leibovich BC, et al. Urinary collecting system invasion is associated with poor survival in patients with clear-cell renal cell carcinoma. *BJU Int* 2017;119:585–90, doi: <http://dx.doi.org/10.1111/bju.13669>.
- [436] Adibi M, Thomas AZ, Borregales LD, Merrill MM, Slack RS, Chen H-C, et al. Percentage of sarcomatoid component as a prognostic indicator for survival in renal cell carcinoma with sarcomatoid dedifferentiation. *Urol Oncol* 2015;33:427.e17–23, doi: <http://dx.doi.org/10.1016/j.urolonc.2015.04.011>.
- [437] Kim T, Zargar-Shostari K, Dhillon J, Lin H-Y, Yue B, Fishman M, et al. Using percentage of sarcomatoid differentiation as a prognostic factor in renal cell carcinoma. *Clin Genitourin Cancer* 2015;13:225–30, doi: <http://dx.doi.org/10.1016/j.clgc.2014.12.001>.
- [438] Petitprez F, Ayadi M, de Reyniès A, Fridman WH, Sautès-Fridman C, Job S. Review of prognostic expression markers for clear cell renal cell carcinoma. *Front Oncol* 2021;11:643065, doi: <http://dx.doi.org/10.3389/fonc.2021.643065>.
- [439] Usher-Smith JA, Li L, Roberts L, Harrison H, Rossi SH, Sharp SJ, et al. Risk models for recurrence and survival after kidney cancer: a systematic review. *BJU Int* 2022;130:562–79, doi: <http://dx.doi.org/10.1111/bju.15673>.
- [440] Correa AF, Jegede O, Haas NB, Flaherty KT, Pins MR, Messing EM, et al. Predicting renal cancer recurrence: defining limitations of existing prognostic models with prospective trial-based validation. *J Clin Oncol* 2019;37:2062–71, doi: <http://dx.doi.org/10.1200/JCO.19.00107>.
- [441] Khene Z-E, Larcher A, Bernhard J-C, Doumerc N, Ouzaid I, Capitanio U, et al. External validation of the ASSURE model for predicting oncological outcomes after resection of high-risk renal cell carcinoma (RESCUE study: UroCCR 88). *Eur Urol Open Sci* 2021;33:89–93, doi: <http://dx.doi.org/10.1016/j.euro.2021.09.004>.
- [442] Kim JK, Lee S, Hong SK, Kwak C, Jeong CW, Kang SH, et al. Machine learning based prediction for oncologic outcomes of renal cell carcinoma after surgery using Korean Renal Cell Carcinoma (KORCC) database. *Sci Rep* 2023;13:5778, doi: <http://dx.doi.org/10.1038/s41598-023-30826-2>.
- [443] Khene Z-E, Bigot P, Doumerc N, Ouzaid I, Boissier R, Nouhaud F-X, et al. Application of machine learning models to predict recurrence after surgical resection of nonmetastatic renal cell carcinoma. *Eur Urol Oncol* 2023;6:323–30, doi: <http://dx.doi.org/10.1016/j.euo.2022.07.007>.
- [444] Margue G, Ferrer L, Etchepare G, Bigot P, Bensalah K, Mejean A, et al. UroPredict: machine learning model on real-world data for prediction of kidney cancer recurrence (UroCCR-120). *Npj Precis Onc* 2024;8:45, doi: <http://dx.doi.org/10.1038/s41698-024-00532-x>.
- [445] Margue G, Ferrer L, Etchepare G, Bigot P, Bensalah K, Mejean A, et al. UroPredict: Machine learning model on real-world data for prediction of kidney cancer recurrence (UroCCR-120). *NPJ Precis Oncol* 2024;8:45, doi: <http://dx.doi.org/10.1038/s41698-024-00532-x>.
- [446] Cindolo L, Chiodini P, Gallo C, Ficarra V, Schips L, Tostain J, et al. Validation by calibration of the UCLA integrated staging system prognostic model for nonmetastatic renal cell carcinoma after nephrectomy. *Cancer* 2008;113:65–71, doi: <http://dx.doi.org/10.1002/cncr.23517>.
- [447] Han K-R, Bleumer I, Pantuck AJ, Kim HL, Dorey FJ, Janzen NK, et al. Validation of an integrated staging system toward improved prognostication of patients with localized renal cell carcinoma in an international population. *J Urol* 2003;170:2221–4, doi: <http://dx.doi.org/10.1097/01.ju.0000096049.64863.a1>.
- [448] Patard J-J, Kim HL, Lam JS, Dorey FJ, Pantuck AJ, Zisman A, et al. Use of the University of California Los Angeles integrated staging system to predict survival in renal cell carcinoma: an international multicenter study. *J Clin Oncol* 2004;22:3316–22, doi: <http://dx.doi.org/10.1200/JCO.2004.09.104>.
- [449] Tollefson MK, Takahashi N, Leibovich BC. Contemporary imaging modalities for the surveillance of patients with renal cell carcinoma. *Curr Urol Rep* 2007;8:38–43.
- [450] Gires B, Khene Z-E, Bigot P, Alimi Q, Peyronnet B, Verhoest G, et al. Impact of routine imaging in the diagnosis of recurrence for patients with localized and locally advanced renal tumor treated with nephrectomy. *World J Urol* 2019;37:2727–36, doi: <http://dx.doi.org/10.1007/s00345-019-02724-8>.
- [451] Antonelli A, Cozzoli A, Zani D, Zanotelli T, Nicolai M, Cunico SC, et al. The follow-up management of non-metastatic renal cell carcinoma: definition of a surveillance protocol. *BJU Int* 2007;99:296–300.
- [452] Canvasser NE, Stouder K, Lay AH, Gahan JC, Lotan Y, Margulis V, et al. The usefulness of chest X-rays for T1a renal cell carcinoma surveillance. *J Urol* 2016;196:321–6, doi: <http://dx.doi.org/10.1016/j.juro.2016.02.068>.
- [453] Casalino DD, Remer EM, Bishoff JT, Coursey CA, Dighe M, Harvin HJ, et al. ACR appropriateness criteria post-treatment follow-up of renal cell carcinoma. *J Am Coll Radiol* 2014;11:443–9, doi: <http://dx.doi.org/10.1016/j.jacr.2014.01.023>.
- [454] Sun M, Marconi L, Eisen T, Escudier B, Giles RH, Haas NB, et al. Adjuvant vascular endothelial growth factor-targeted therapy in renal cell carcinoma: a systematic review and pooled analysis. *Eur Urol* 2018;74:611–20, doi: <http://dx.doi.org/10.1016/j.eururo.2018.05.002>.
- [455] Ravaud A, Motzer RJ, Pandha HS, George DJ, Pantuck AJ, Patel A, et al. Adjuvant sunitinib in high-risk renal-cell carcinoma after nephrectomy. *N Engl J Med* 2016;375:2246–54, doi: <http://dx.doi.org/10.1056/NEJMoa1611406>.
- [456] Motzer RJ, Russo P, Haas N, Doehn C, Donskov F, Gross-Goupil M, et al. Adjuvant pazopanib versus placebo after nephrectomy in patients with localized or locally advanced renal cell carcinoma: final overall survival analysis of the phase 3 PROTECT trial. *Eur Urol* 2021;79:334–8, doi: <http://dx.doi.org/10.1016/j.eururo.2020.12.029>.
- [457] Haas NB, Manola J, Uzzo RG, Flaherty KT, Wood CG, Kane C, et al. Adjuvant sunitinib or sorafenib for high-risk, non-metastatic renal-cell carcinoma (ECOG-ACRIN E2805): a double-blind, placebo-controlled, randomised, phase 3 trial. *Lancet* 2016;387:2008–16, doi: [http://dx.doi.org/10.1016/S0140-6736\(16\)00559-6](http://dx.doi.org/10.1016/S0140-6736(16)00559-6).
- [458] Ravaud A, Motzer RJ, Pandha HS, George DJ, Pantuck AJ, Patel A, et al. Adjuvant sunitinib in high-risk renal-cell carcinoma after nephrectomy. *N Engl J Med* 2016;375:2246–54, doi: <http://dx.doi.org/10.1056/NEJMoa1611406>.
- [459] Gross-Goupil M, Kwon TG, Eto M, Ye D, Miyake H, Seo SI, et al. Axitinib versus placebo as an adjuvant treatment of renal cell carcinoma: results from the phase III, randomized ATLAS trial. *Ann Oncol* 2018;29:2371–8, doi: <http://dx.doi.org/10.1093/annonc/mdy454>.
- [460] Synold TW, Plets M, Tangen CM, Heath EI, Palapattu GS, Mack PC, et al. Everolimus exposure as a predictor of toxicity in renal cell cancer patients in the adjuvant setting: results of a pharmacokinetic analysis for SWOG S0931 (EVEREST), a phase III study (NCT01120249). *Kidney Cancer* 2019;3:111–8, doi: <http://dx.doi.org/10.3233/KCA-180049>.
- [461] Eisen T, Frangou E, Oza B, Ritchie AWS, Smith B, Kaplan R, et al. Adjuvant sorafenib for renal cell carcinoma at intermediate or high risk of relapse: results from the SOURCE randomized phase III intergroup trial. *J Clin Oncol* 2020;38:4064–75, doi: <http://dx.doi.org/10.1200/JCO.20.01800>.
- [462] Choueiri TK, Powles T. Adjuvant pembrolizumab after nephrectomy in renal-cell carcinoma, reply. *N Engl J Med* 2021;385:1920, doi: <http://dx.doi.org/10.1056/NEJMc2115204>.
- [463] Choueiri TK, Tomczak P, Park SH. Overall survival results from the phase 3 KEYNOTE-564 study of adjuvant pembrolizumab versus placebo for the treatment of clear cell renal cell carcinoma (ccRCC). *Lancet Oncol* 2022;23:1133–44.
- [464] Choueiri TK, Tomczak P, Park SH, Venugopal B, Symeonides S, Hajek J, et al. Patient-reported outcomes in KEYNOTE-564: adjuvant pembrolizumab versus placebo for renal cell carcinoma. *Oncologist* 2024;29:142–50, doi: <http://dx.doi.org/10.1093/oncol/oyad231>.

- [465] Motzer R, Alekseev B, Rha S-Y, Porta C, Eto M, Powles T, et al. Lenvatinib plus pembrolizumab or everolimus for advanced renal cell carcinoma. *N Engl J Med* 2021;384:1289–300, doi:http://dx.doi.org/10.1056/NEJMoa2035716.
- [466] Motzer RJ, Rini BI, McDermott DF, Arén Frontera O, Hammers HJ, Carducci MA, et al. Nivolumab plus ipilimumab versus sunitinib in first-line treatment for advanced renal cell carcinoma: extended follow-up of efficacy and safety results from a randomised, controlled, phase 3 trial. *Lancet Oncol* 2019;20:1370–85, doi:http://dx.doi.org/10.1016/S1470-2045(19)30413-9.
- [467] Powles T, Plimack ER, Soulières D, Waddell T, Stus V, Gafanov R, et al. Pembrolizumab plus axitinib versus sunitinib monotherapy as first-line treatment of advanced renal cell carcinoma (KEYNOTE-426): extended follow-up from a randomised, open-label, phase 3 trial. *Lancet Oncol* 2020;21:1563–73, doi:http://dx.doi.org/10.1016/S1470-2045(20)30436-8.
- [468] Choueiri TK, Powles T, Burotto M, Escudier B, Bourlon MT, Zurawski B, et al. Nivolumab plus cabozantinib versus sunitinib for advanced renal-cell carcinoma. *N Engl J Med* 2021;384:829–41, doi:http://dx.doi.org/10.1056/NEJMoa2026982.
- [469] Motzer RJ, Russo P, Grünwald V, Tomita Y, Zurawski B, Parikh O, et al. Adjuvant nivolumab plus ipilimumab versus placebo for localised renal cell carcinoma after nephrectomy (CheckMate 914): a double-blind, randomised, phase 3 trial. *Lancet* 2023;401:821–32, doi:http://dx.doi.org/10.1016/S0140-6736(22)02574-0.
- [470] Pal SK, Uzzo R, Karam JA, Master VA, Donskov F, Suarez C, et al. Adjuvant atezolizumab versus placebo for patients with renal cell carcinoma at increased risk of recurrence following resection (IMmotion010): a multicentre, randomised, double-blind, phase 3 trial. *Lancet* 2022;400:1103–16, doi:http://dx.doi.org/10.1016/S0140-6736(22)01658-0.
- [471] Heng DY, Xie W, Regan MM, Warren MA, Golshayan AR, Sahi C, et al. Prognostic factors for overall survival in patients with metastatic renal cell carcinoma treated with vascular endothelial growth factor-targeted agents: results from a large, multicenter study. *J Clin Oncol* 2009;27:5794–9, doi:http://dx.doi.org/10.1200/JCO.2008.21.4809.
- [472] Heng DY, Xie W, Regan MM, Harshman LC, Bjarnason GA, Vaishampayan UN, et al. External validation and comparison with other models of the International Metastatic Renal-Cell Carcinoma Database Consortium prognostic model: a population-based study. *Lancet Oncol* 2013;14:141–8, doi:http://dx.doi.org/10.1016/S1470-2045(12)70559-4.
- [473] Ko JJ, Choueiri TK, Rini BI, Lee J-L, Kroeger N, Srinivas S, et al. First-, second-, third-line therapy for mRCC: benchmarks for trial design from the IMDC. *Br J Cancer* 2014;110:1917–22, doi:http://dx.doi.org/10.1038/bjc.2014.25.
- [474] Kroeger N, Xie W, Lee J-L, Bjarnason GA, Knox JJ, Mackenzie MJ, et al. Metastatic non-clear cell renal cell carcinoma treated with targeted therapy agents: characterization of survival outcome and application of the International mRCC Database Consortium criteria. *Cancer* 2013;119:2999–3006, doi:http://dx.doi.org/10.1002/cncr.28151.
- [475] Flanigan RC, Mickisch G, Sylvester R, Tangen C, Van Poppel H, Crawford ED. Cytoreductive nephrectomy in patients with metastatic renal cancer: a combined analysis. *J Urol* 2004;171:1071–6, doi:http://dx.doi.org/10.1097/01.ju.0000110610.61545.ae.
- [476] Méjean A, Ravaud A, Thezenas S, Colas S, Beauval J-B, Bensalah K, et al. Sunitinib alone or after nephrectomy in metastatic renal-cell carcinoma. *N Engl J Med* 2018;379:417–27, doi:http://dx.doi.org/10.1056/NEJMoa1803675.
- [477] Méjean A, Ravaud A, Thezenas S, Chevreau C, Bensalah K, Geoffrois L, et al. Sunitinib alone or after nephrectomy for patients with metastatic renal cell carcinoma: is there still a role for cytoreductive nephrectomy? *Eur Urol* 2021;80:417–24, doi:http://dx.doi.org/10.1016/j.eururo.2021.06.009.
- [478] Bex A, Mulders P, Jewett M, Wagstaff J, van Thienen JV, Blank CU, et al. Comparison of immediate vs. deferred cytoreductive nephrectomy in patients with synchronous metastatic renal cell carcinoma receiving sunitinib: the SURTIME randomized clinical trial. *JAMA Oncol* 2019;5:164–70, doi:http://dx.doi.org/10.1001/jamaoncol.2018.5543.
- [479] Choueiri TK, Powles T, Burotto M, Escudier B, Bourlon MT, Zurawski B, et al. Nivolumab plus cabozantinib versus sunitinib for advanced renal-cell carcinoma. *N Engl J Med* 2021;384:829–41, doi:http://dx.doi.org/10.1056/NEJMoa2026982.
- [480] Rini BI, Plimack ER, Stus V, Gafanov R, Hawkins R, Nosov D, et al. Pembrolizumab plus axitinib versus sunitinib for advanced renal-cell carcinoma. *N Engl J Med* 2019;380:1116–27, doi:http://dx.doi.org/10.1056/NEJMoa1816714.
- [481] Motzer RJ, Penkov K, Haanen J, Rini B, Albiges L, Campbell MT, et al. Avelumab plus axitinib versus sunitinib for advanced renal-cell carcinoma. *N Engl J Med* 2019;380:1103–15, doi:http://dx.doi.org/10.1056/NEJMoa1816047.
- [482] Motzer R, Alekseev B, Rha S-Y, Porta C, Eto M, Powles T, et al. Lenvatinib plus pembrolizumab or everolimus for advanced renal cell carcinoma. *N Engl J Med* 2021;384:1289–300, doi:http://dx.doi.org/10.1056/NEJMoa2035716.
- [483] Choueiri TK, Eto M, Motzer R, De Giorgi U, Buchler T, Basappa NS, et al. Lenvatinib plus pembrolizumab versus sunitinib as first-line treatment of patients with advanced renal cell carcinoma (CLEAR): extended follow-up from the phase 3, randomised, open-label study. *Lancet Oncol* 2023;24:228–38, doi:http://dx.doi.org/10.1016/S1470-2045(23)00049-9.
- [484] Mori K, Quhal F, Yanagisawa T, Katayama S, Pradere B, Laukhtina E, et al. The effect of immune checkpoint inhibitor combination therapies in metastatic renal cell carcinoma patients with and without previous cytoreductive nephrectomy: a systematic review and meta-analysis. *Int Immunopharmacol* 2022;108:108720, doi:http://dx.doi.org/10.1016/j.intimp.2022.108720.
- [485] Singla N, Hutchinson RC, Ghandour RA, Freifeld Y, Fang D, Sagalowsky AI, et al. Improved survival after cytoreductive nephrectomy for metastatic renal cell carcinoma in the contemporary immunotherapy era: an analysis of the National Cancer Database. *Urol Oncol* 2020;38:604.e9–604.e17, doi:http://dx.doi.org/10.1016/j.urolonc.2020.02.029.
- [486] Bakouny Z, El Zarif T, Dudani S, Connor Wells J, Gan CL, Donskov F, et al. Upfront cytoreductive nephrectomy for metastatic renal cell carcinoma treated with immune checkpoint inhibitors or targeted therapy: an observational study from the International Metastatic Renal Cell Carcinoma Database Consortium. *Eur Urol* 2023;83:145–51, doi:http://dx.doi.org/10.1016/j.eururo.2022.10.004.
- [487] Chen B, Li J, Huang Y, Tang B, Jiang J, Chen Z, et al. The role of cytoreductive nephrectomy in metastatic renal cell carcinoma in the targeted therapy and immunological therapy era: a systematic review and meta-analysis. *Int J Surg* 2023;109:982–94, doi:http://dx.doi.org/10.1097/JS9.0000000000000314.
- [488] Ghatalia P, Handorf EA, Geynisman DM, Deng M, Zibelman MR, Abbosh P, et al. The role of cytoreductive nephrectomy in metastatic renal cell carcinoma: a real-world multi-institutional analysis. *J Urol* 2022;208:71–9, doi:http://dx.doi.org/10.1097/JU.0000000000002495.
- [489] Pignot G, Thiery-Vuillemin A, Walz J, Lang H, Bigot P, Werle P, et al. Nephrectomy after complete response to immune checkpoint inhibitors for metastatic renal cell carcinoma: a new surgical challenge? *Eur Urol* 2020;77:761–3, doi:http://dx.doi.org/10.1016/j.eururo.2019.12.018.
- [490] Singla N, Elias R, Ghandour RA, Freifeld Y, Bowman IA, Rapoport L, et al. Pathologic response and surgical outcomes in patients undergoing nephrectomy following receipt of immune checkpoint inhibitors for renal cell carcinoma. *Urol Oncol* 2019;37:924–31, doi:http://dx.doi.org/10.1016/j.urolonc.2019.08.012.
- [491] Shapiro DD, Karam JA, Zemp L, Master VA, Sexton WJ, Ghasemzadeh A, et al. Cytoreductive nephrectomy following immune checkpoint inhibitor therapy is safe and facilitates treatment-free intervals. *Eur Urol Open Sci* 2023;50:43–6, doi:http://dx.doi.org/10.1016/j.euro.2023.01.016.
- [492] Yip W, Ghoreifi A, Gerald T, Lee R, Howard J, Asghar A, et al. Perioperative complications and oncologic outcomes of nephrectomy following immune checkpoint inhibitor therapy: a multicenter collaborative study. *Eur Urol Oncol* 2023;6:604–10, doi:http://dx.doi.org/10.1016/j.euro.2023.03.003.
- [493] Pignot G. Oncological outcomes of delayed nephrectomy after optimal response to immune checkpoint inhibitors for metastatic renal cell carcinoma. *Eur Urol Oncol* 2022;5:577–84.
- [494] Larcher A, Fallara G, Rosiello G, Re C, Baiamonte G, Agnesi S, et al. Cytoreductive nephrectomy in metastatic patients with signs or symptoms: implications for renal cell carcinoma guidelines. *Eur Urol* 2020;78:321–6, doi:http://dx.doi.org/10.1016/j.eururo.2020.05.014.
- [495] Choueiri TK, Tomczak P, Park SH, Venugopal B, Ferguson T, Chang Y-H, et al. Adjuvant pembrolizumab after nephrectomy in renal-cell carcinoma. *N Engl J Med* 2021;385:683–94, doi:http://dx.doi.org/10.1056/NEJMoa2106391.
- [496] Bhandi B, Abel EJ, Albiges L, Bensalah K, Boorjian SA, Daneshmand S, et al. Systematic review of the role of cytoreductive nephrectomy in the targeted therapy era and beyond: an individualized approach to metastatic renal cell carcinoma. *Eur Urol* 2019;75:111–28, doi:http://dx.doi.org/10.1016/j.eururo.2018.09.016.
- [497] Fiala O, Buti S, Bamias A, Massari F, Pichler R, Maruzzo M, et al. Real-world impact of upfront cytoreductive nephrectomy in metastatic non-clear cell renal cell carcinoma treated with first-line immunotherapy combinations or tyrosine kinase inhibitors (a sub-analysis from the ARON-1 retrospective study). *Target Oncol* 2024;19:587–99, doi:http://dx.doi.org/10.1007/s11523-024-01065-w.
- [498] Ouzaid I, Capitanio U, Staehler M, Wood CG, Leibovich BC, Ljungberg B, et al. Surgical metastasectomy in renal cell carcinoma: a systematic review. *Eur Urol Oncol* 2019;2:141–9, doi:http://dx.doi.org/10.1016/j.euro.2018.08.028.
- [499] Dabestani S, Marconi L, Hofmann F, Stewart F, Lam TBL, Canfield SE, et al. Local treatments for metastases of renal cell carcinoma: a systematic review. *Lancet Oncol* 2014;15:e549–61, doi:http://dx.doi.org/10.1016/S1470-2045(14)70235-9.
- [500] Zaid HB, Parker WP, Safdar NS, Gershman B, Erwin PJ, Murad MH, et al. Outcomes following complete surgical metastasectomy for patients with metastatic renal cell carcinoma: a systematic review and meta-analysis. *J Urol* 2017;197:44–9, doi:http://dx.doi.org/10.1016/j.juro.2016.07.079.
- [501] Mikhail M, Chua KJ, Khizir L, Tabakin A, Singer EA. Role of metastasectomy in the management of renal cell carcinoma. *Front Surg* 2022;9:943604, doi:http://dx.doi.org/10.3389/fsurg.2022.943604.
- [502] Fares AF, Araujo DV, Calsavara V, Saito AO, Formiga MN, Dettino AA, et al. Complete metastasectomy in renal cell carcinoma: a propensity-score matched by the International Metastatic RCC Database Consortium prognostic model. *Eccancermediscience* 2019;13:967, doi:http://dx.doi.org/10.3332/eccancer.2019.967.
- [503] Wu K, Liu Z, Shao Y, Li X. Nomogram predicting survival to assist decision-making of metastasectomy in patients with metastatic renal cell carcinoma. *Front Oncol* 2020;10:592243, doi:http://dx.doi.org/10.3389/fonc.2020.592243.
- [504] Lyon TD, Thompson RH, Shah PH, Lohse CM, Boorjian SA, Costello BA, et al. Complete surgical metastasectomy of renal cell carcinoma in the post-cytokine era. *J Urol* 2020;203:275–82, doi:http://dx.doi.org/10.1097/JU.0000000000000488.
- [505] Hsieh P-Y, Hung S-C, Li J-R, Wang S-S, Yang C-K, Chen C-S, et al. The effect of metastasectomy on overall survival in metastatic renal cell carcinoma: a systematic review and meta-analysis. *Urol Oncol* 2021;39:422–30, doi:http://dx.doi.org/10.1016/j.urolonc.2021.02.026.
- [506] Tayeh GA, Alkassis M, De La Taille A, Vordos D, Champy CM, Pelegrin T, et al. Surgical metastasectomy for metastatic renal cell carcinoma in the era of targeted and immune therapy: a narrative review. *World J Urol* 2024;42:51, doi:http://dx.doi.org/10.1007/s00345-023-04706-3.
- [507] Stühler V, Herrmann L, Maas M, Walz S, Rausch S, Stenzl A, et al. Prognostic impact of complete metastasectomy in metastatic renal cell carcinoma in the era of immunotherapy-based combination therapies. *World J Urol* 2022;40:1175–83, doi:http://dx.doi.org/10.1007/s00345-022-03960-1.
- [508] Dragomir A, Nazha S, Wood LA, Rendon RA, Finelli A, Hansen A, et al. Outcomes of complete metastasectomy in metastatic renal cell carcinoma patients: the Canadian

- Kidney Cancer information system experience. *Urol Oncol* 2020;38:799.e1–799.e10, doi:<http://dx.doi.org/10.1016/j.urolonc.2020.07.021>.
- [509] Meagher MF, Mir MC, Autorino R, Minervini A, Kriegmair M, Maurer T, et al. Impact of metastasectomy on cancer specific and overall survival in metastatic renal cell carcinoma: analysis of the REMARCC registry. *Clin Genitourin Cancer* 2022;20:326–33, doi:<http://dx.doi.org/10.1016/j.clgc.2022.03.013>.
- [510] Lyon TD, Roussel E, Sharma V, Carames G, Lohse CM, Costello BA, et al. International multi-institutional characterization of the perioperative morbidity of metastasectomy for renal cell carcinoma. *Eur Urol Oncol* 2023;6:76–83, doi:<http://dx.doi.org/10.1016/j.euo.2022.11.003>.
- [511] Zhang Y, Schoenhals J, Christie A, Mohamad O, Wang C, Bowman I, et al. Stereotactic ablative radiation therapy (SABR) used to defer systemic therapy in oligometastatic renal cell cancer. *Int J Radiat Oncol Biol Phys* 2019;105:367–75, doi:<http://dx.doi.org/10.1016/j.ijrobp.2019.07.023>.
- [512] Wang CJ, Christie A, Lin M-H, Jung M, Weix D, Huelsmann L, et al. Safety and efficacy of stereotactic ablative radiation therapy for renal cell carcinoma extracranial metastases. *Int J Radiat Oncol Biol Phys* 2017;98:91–100, doi:<http://dx.doi.org/10.1016/j.ijrobp.2017.01.032>.
- [513] Zaorsky NG, Lehrer EJ, Kothari G, Louie AV, Siva S. Stereotactic ablative radiation therapy for oligometastatic renal cell carcinoma (SABR ORCA): a meta-analysis of 28 studies. *Eur Urol Oncol* 2019;2:515–23, doi:<http://dx.doi.org/10.1016/j.euo.2019.05.007>.
- [514] Franzese C, Franceschini D, Di Brina L, D'Agostino GR, Navarria P, Comito T, et al. Role of stereotactic body radiation therapy for the management of oligometastatic renal cell carcinoma. *J Urol* 2019;201:70–5, doi:<http://dx.doi.org/10.1016/j.juro.2018.08.049>.
- [515] Ingrassio G, Becherini C, Francolini G, Lancia A, Ali E, Cainsi S, et al. Stereotactic body radiotherapy (SBRT) in combination with drugs in metastatic kidney cancer: a systematic review. *Crit Rev Oncol Hematol* 2021;159:103242, doi:<http://dx.doi.org/10.1016/j.critrevonc.2021.103242>.
- [516] Liu Y, Long W, Zhang Z, Zhang Z, Mai L, Huang S, et al. Metastasis-directed stereotactic body radiotherapy for oligometastatic renal cell carcinoma: extent of tumor burden eradicated by radiotherapy. *World J Urol* 2021;39:4183–90, doi:<http://dx.doi.org/10.1007/s00345-021-03742-1>.
- [517] Meyer E, Pasquier D, Bernadou G, Calais G, Maroun P, Bossi A, et al. Stereotactic radiation therapy in the strategy of treatment of metastatic renal cell carcinoma: a study of the Getug group. *Eur J Cancer* 2018;98:38–47, doi:<http://dx.doi.org/10.1016/j.ejca.2018.04.008>.
- [518] Hannan R, Christensen M, Christie A, Garant A, Pedrosa I, Robles L, et al. Stereotactic ablative radiation for systemic therapy-naïve oligometastatic kidney cancer. *Eur Urol Oncol* 2022;5:695–703, doi:<http://dx.doi.org/10.1016/j.euo.2022.06.008>.
- [519] Cheung P, Patel S, North SA, Sahgal A, Chu W, Soliman H, et al. Stereotactic radiotherapy for oligoprogression in metastatic renal cell cancer patients receiving tyrosine kinase inhibitor therapy: a phase 2 prospective multicenter study. *Eur Urol* 2021;80:693–700, doi:<http://dx.doi.org/10.1016/j.eururo.2021.07.026>.
- [520] Masini C, Iotti C, De Giorgi U, Bellia RS, Buti S, Salaroli F, et al. Nivolumab in combination with stereotactic body radiotherapy in pretreated patients with metastatic renal cell carcinoma. Results of the phase II NIVES study. *Eur Urol* 2022;81:274–82, doi:<http://dx.doi.org/10.1016/j.eururo.2021.09.016>.
- [521] Siva S, Bressel M, Wood ST, Shaw MG, Loi S, Sandhu SK, et al. Stereotactic Radiotherapy and short-course pembrolizumab for oligometastatic renal cell carcinoma – the RAPPORT trial. *Eur Urol* 2022;81:364–72, doi:<http://dx.doi.org/10.1016/j.eururo.2021.12.006>.
- [522] Juloori A, Miller JA, Parsai S, Kotecha R, Ahluwalia MS, Mohammadi AM, et al. Overall survival and response to radiation and targeted therapies among patients with renal cell carcinoma brain metastases. *J Neurosurg* 2019;132:188–96, doi:<http://dx.doi.org/10.3171/2018.8.JNS182100>.
- [523] Fokas E, Henzel M, Hamm K, Surber G, Kleinert G, Engenhardt-Cabillie R. Radiotherapy for brain metastases from renal cell cancer: should whole-brain radiotherapy be added to stereotactic radiosurgery? Analysis of 88 patients. *Strahlenther Onkol* 2010;186:210–7, doi:<http://dx.doi.org/10.1007/s00066-010-2055-z>.
- [524] Langrand-Escure J, Vallard A, Rivoirard R, Méry B, Guy J-B, Espenel S, et al. Safety assessment of molecular targeted therapies in association with radiotherapy in metastatic renal cell carcinoma: a real-life report. *Anticancer Drugs* 2016;27:427–32, doi:<http://dx.doi.org/10.1097/CAD.0000000000000349>.
- [525] Klausner G, Troussier I, Biau J, Jacob J, Schernberg A, Canova C-H, et al. Stereotactic radiation therapy for renal cell carcinoma brain metastases in the tyrosine kinase inhibitors era: outcomes of 120 patients. *Clin Genitourin Cancer* 2019;17:191–200, doi:<http://dx.doi.org/10.1016/j.clgc.2019.02.007>.
- [526] Peng J, Lalani A-K, Swaminath A. Cytoreductive stereotactic body radiotherapy (SBRT) and combination SBRT with immune checkpoint inhibitors in metastatic renal cell carcinoma. *Can Urol Assoc J* 2021;15:281–6, doi:<http://dx.doi.org/10.5489/auaj.6963>.
- [527] de Baère T, Aupérin A, Deschamps F, Chevallier P, Gaubert Y, Boige V, et al. Radiofrequency ablation is a valid treatment option for lung metastases: experience in 566 patients with 1037 metastases. *Ann Oncol* 2015;26:987–91, doi:<http://dx.doi.org/10.1093/annonc/mdv037>.
- [528] Shu Yan Huo A, Lawson Morris D, King J, Glenn D. Use of percutaneous radiofrequency ablation in pulmonary metastases from renal cell carcinoma. *Ann Surg Oncol* 2009;16:3169–75, doi:<http://dx.doi.org/10.1245/s10434-009-0664-5>.
- [529] Soga N, Yamakado K, Gohara H, Takaki H, Hiraki T, Yamada T, et al. Percutaneous radiofrequency ablation for unresectable pulmonary metastases from renal cell carcinoma. *BJU Int* 2009;104:790–4, doi:<http://dx.doi.org/10.1111/j.1464-410X.2009.08459.x>.
- [530] Hasegawa T, Yamakado K, Nakatsuka A, Uraki J, Yamanaka T, Fujimori M, et al. Unresectable adrenal metastases: clinical outcomes of radiofrequency ablation. *Radiology* 2015;277:584–93, doi:<http://dx.doi.org/10.1148/radiol.2015142029>.
- [531] Gonnet A, Salabert L, Roubaud G, Catena V, Brouste V, Buy X, et al. Renal cell carcinoma lung metastases treated by radiofrequency ablation integrated with systemic treatments: over 10 years of experience. *BMC Cancer* 2019;19:1182, doi:<http://dx.doi.org/10.1186/s12885-019-6345-2>.
- [532] Welch BT, Callstrom MR, Morris JM, Kurup AN, Schmit GD, Weisbrod AJ, et al. Feasibility and oncologic control after percutaneous image guided ablation of metastatic renal cell carcinoma. *J Urol* 2014;192:357–63, doi:<http://dx.doi.org/10.1016/j.juro.2014.03.006>.
- [533] Motzer RJ, Tannir NM, McDermott DF, Arén Frontera O, Melichar B, Choueiri TK, et al. Nivolumab plus ipilimumab versus sunitinib in advanced renal-cell carcinoma. *N Engl J Med* 2018;378:1277–90, doi:<http://dx.doi.org/10.1056/NEJMoa1712126>.
- [534] Albiges L, Tannir NM, Burotto M, McDermott D, Plimack ER, Barthélémy P, et al. Nivolumab plus ipilimumab versus sunitinib for first-line treatment of advanced renal cell carcinoma: extended 4-year follow-up of the phase III CheckMate 214 trial. *ESMO Open* 2020;5:e001079, doi:<http://dx.doi.org/10.1136/esmoopen-2020-001079>.
- [535] Tannir N, Escudier B, McDermott D. Nivolumab plus ipilimumab (NIVO + IPI) vs. sunitinib (SUN) for first-line treatment of advanced renal cell carcinoma (aRCC): long-term follow-up data from the phase 3 CheckMate 214 trial. *J Clin Oncol* 2024 [S0923-7534(24)01516-3].
- [536] Powles T, Plimack ER, Soulières D, Waddell T, Stus V, Gafanov R, et al. Pembrolizumab plus axitinib versus sunitinib monotherapy as first-line treatment of advanced renal cell carcinoma (KEYNOTE-426): extended follow-up from a randomised, open-label, phase 3 trial. *Lancet Oncol* 2020;21:1563–73, doi:[http://dx.doi.org/10.1016/S1470-2045\(20\)30436-8](http://dx.doi.org/10.1016/S1470-2045(20)30436-8).
- [537] Plimack ER, Powles T, Stus V, Gafanov R, Nosov D, Waddell T, et al. Pembrolizumab plus axitinib versus sunitinib as first-line treatment of advanced renal cell carcinoma: 43-month follow-up of the phase 3 KEYNOTE-426 study. *Eur Urol* 2023;84:449–54, doi:<http://dx.doi.org/10.1016/j.eururo.2023.06.006>.
- [538] Bourlon MT, Escudier B, Burotto M. Nivolumab plus cabozantinib (N + C) vs. sunitinib (S) for previously untreated advanced renal cell carcinoma (aRCC): results from 55-month follow-up of the CheckMate 9ER trial. *Lancet Oncol* 2022;23:888–98.
- [539] Motzer R, Porta C, Masatoshi E. Lenvatinib plus pembrolizumab versus sunitinib in first-line treatment of advanced renal cell carcinoma: final prespecified overall survival analysis of CLEAR, a phase III study. *J Clin Oncol* 2024;42:1222–8.
- [540] Motzer RJ, Escudier B, McDermott DF, George S, Hammers HJ, Srinivas S, et al. Nivolumab versus everolimus in advanced renal-cell carcinoma. *N Engl J Med* 2015;373:1803–13, doi:<http://dx.doi.org/10.1056/NEJMoa1510665>.
- [541] Choueiri TK, Escudier B, Powles T, Tannir NM, Mainwaring PN, Rini BI, et al. Cabozantinib versus everolimus in advanced renal cell carcinoma (METEOR): final results from a randomised, open-label, phase 3 trial. *Lancet Oncol* 2016;17:917–27, doi:[http://dx.doi.org/10.1016/S1470-2045\(16\)30107-3](http://dx.doi.org/10.1016/S1470-2045(16)30107-3).
- [542] Pal SK, Albiges L, Tomczak P, Suárez C, Voss MH, de Velasco G, et al. Atezolizumab plus cabozantinib versus cabozantinib monotherapy for patients with renal cell carcinoma after progression with previous immune checkpoint inhibitor treatment (CONTACT-03): a multicentre, randomised, open-label, phase 3 trial. *Lancet* 2023;402:185–95, doi:[http://dx.doi.org/10.1016/S0140-6736\(23\)00922-4](http://dx.doi.org/10.1016/S0140-6736(23)00922-4).
- [543] Suárez C, Larkin JMG, Patel P, Valderrama BP, Rodriguez-Vida A, Glen H, et al. Phase II study investigating the safety and efficacy of savolitinib and durvalumab in metastatic papillary renal cancer (CALYPSO). *J Clin Oncol* 2023;41:2493–502, doi:<http://dx.doi.org/10.1200/JCO.22.01414>.
- [544] Choueiri TK, Heng DY, Lee JL, Cancel M, Verheijen RB, Mellemgaard A, et al. Efficacy of savolitinib vs. sunitinib in patients with MET-driven papillary renal cell carcinoma: the SAVOIR phase 3 randomized clinical trial. *JAMA Oncol* 2020;6:1247–55, doi:<http://dx.doi.org/10.1001/jamaoncol.2020.2218>.
- [545] Pal SK, Tangen C, Thompson IM, Balzer-Haas N, George DJ, Heng DY, et al. A comparison of sunitinib with cabozantinib, crizotinib, and savolitinib for treatment of advanced papillary renal cell carcinoma: a randomised, open-label, phase 2 trial. *Lancet* 2021;397:695–703, doi:[http://dx.doi.org/10.1016/S0140-6736\(21\)00152-5](http://dx.doi.org/10.1016/S0140-6736(21)00152-5).
- [546] Armstrong AJ, Halabi S, Eisen T, Broderick S, Stadler WM, Jones RJ, et al. Everolimus versus sunitinib for patients with metastatic non-clear cell renal cell carcinoma (ASPEN): a multicentre, open-label, randomised phase 2 trial. *Lancet Oncol* 2016;17:378–88, doi:[http://dx.doi.org/10.1016/S1470-2045\(15\)00515-X](http://dx.doi.org/10.1016/S1470-2045(15)00515-X).
- [547] Negrier S, Rioux-Leclercq N, Ferlay C, Gross-Goupil M, Gravis G, Geoffrois L, et al. Axitinib in first-line for patients with metastatic papillary renal cell carcinoma: results of the multicentre, open-label, single-arm, phase II AXIPAP trial. *Eur J Cancer* 2020;129:107–16, doi:<http://dx.doi.org/10.1016/j.ejca.2020.02.001>.
- [548] Tannir NM, Jonasch E, Albiges L, Altinmakas E, Ng CS, Matin SF, et al. Everolimus versus sunitinib prospective evaluation in metastatic non-clear cell renal cell carcinoma (ESPN): a randomized multicenter phase 2 trial. *Eur Urol* 2016;69:866–74, doi:<http://dx.doi.org/10.1016/j.eururo.2015.10.049>.
- [549] Escudier B, Molinier V, Bracarda S, Maroto P, Szczylik C, Nathan P, et al. Open-label phase 2 trial of first-line everolimus monotherapy in patients with papillary metastatic renal cell carcinoma: RAPTOR final analysis. *Eur J Cancer* 2016;69:226–35, doi:<http://dx.doi.org/10.1016/j.ejca.2016.08.004>.
- [550] Ravaud A, Oudard S, De Fromont M, Chevreau C, Gravis G, Zanetta S, et al. First-line treatment with sunitinib for type 1 and type 2 locally advanced or metastatic papillary renal cell carcinoma: a phase II study (SUPAP) by the French Genitourinary Group (GETUG)j. *Ann Oncol* 2015;26:1123–8, doi:<http://dx.doi.org/10.1093/annonc/mdv149>.
- [551] McDermott DF, Lee J-L, Ziobro M, Suarez C, Langiewicz P, Matveev VB, et al. Study of pembrolizumab monotherapy as first-line therapy in patients with advanced non-

- clear cell renal cell carcinoma. *J Clin Oncol* 2021;39:1029–39, doi:<http://dx.doi.org/10.1200/JCO.20.02365>.
- [552] Albiges L, Gurney H, Atduev V, Suarez C, Climent MA, Pook D, et al. Pembrolizumab plus lenvatinib as first-line therapy for advanced non-clear-cell renal cell carcinoma (KEYNOTE-B61): a single-arm, multicentre, phase 2 trial. *Lancet Oncol* 2023;24:881–91, doi:[http://dx.doi.org/10.1016/S1470-2045\(23\)00276-0](http://dx.doi.org/10.1016/S1470-2045(23)00276-0).
- [553] Lee C-H, Voss MH, Carlo MI, Chen Y-B, Zucker M, Knezevic A, et al. Phase II trial of cabozantinib plus nivolumab in patients with non-clear-cell renal cell carcinoma and genomic correlates. *J Clin Oncol* 2022;40:2333–41, doi:<http://dx.doi.org/10.1200/JCO.21.01944>.
- [554] Oudard S, Banu E, Vieillefond A, Fournier L, Priou F, Medioni J, et al. Prospective multicenter phase II study of gemcitabine plus platinum salt for metastatic collecting duct carcinoma: results of a GETUG (Groupe d'Études des Tumeurs Uro-Génitales) study. *J Urol* 2007;177:1698–702, doi:<http://dx.doi.org/10.1016/j.juro.2007.01.063>.
- [555] Sheng X, Cao D, Yuan J, Zhou F, Wei Q, Xie X, et al. Sorafenib in combination with gemcitabine plus cisplatin chemotherapy in metastatic renal collecting duct carcinoma: a prospective, multicentre, single-arm, phase 2 study. *Eur J Cancer* 2018;100:1–7, doi:<http://dx.doi.org/10.1016/j.ejca.2018.04.007>.
- [556] Procopio G, Sepe P, Claps M, Buti S, Colecchia M, Giannatempo P, et al. Cabozantinib as first-line treatment in patients with metastatic collecting duct renal cell carcinoma: results of the BONSAI trial for the Italian Network for Research in Urologic-Oncology (Meet-URO 2 study). *JAMA Oncol* 2022;8:910, doi:<http://dx.doi.org/10.1001/jamaoncol.2022.0238>.
- [557] Thibault C, Fléchon A, Albiges L, Joly C, Barthelemy P, Gross-Goupil M, et al. Gemcitabine plus platinum-based chemotherapy in combination with bevacizumab for kidney metastatic collecting duct and medullary carcinomas: results of a prospective phase II trial (BEVABEL-GETUG/AFU24). *Eur J Cancer* 2023;186:83–90, doi:<http://dx.doi.org/10.1016/j.ejca.2023.03.018>.