



HAL
open science

Complications and outcomes in 69 consecutive patients with floating hip

Alexandre Cech, Clémentine Rieussec, Gaël Kerschbaumer, Olivier Seurat, Clémentine Corbet, Benoît Vibert, Camille Tronc, Sébastien Ruatti, Pierre Bouzat, Jérôme Tonetti, et al.

► To cite this version:

Alexandre Cech, Clémentine Rieussec, Gaël Kerschbaumer, Olivier Seurat, Clémentine Corbet, et al.. Complications and outcomes in 69 consecutive patients with floating hip. *Orthopaedics & Traumatology: Surgery & Research*, 2021, 107 (6), pp.102998. 10.1016/j.otsr.2021.102998 . hal-04821094

HAL Id: hal-04821094

<https://hal.science/hal-04821094v1>

Submitted on 19 Dec 2024

HAL is a multi-disciplinary open access archive for the deposit and dissemination of scientific research documents, whether they are published or not. The documents may come from teaching and research institutions in France or abroad, or from public or private research centers.

L'archive ouverte pluridisciplinaire **HAL**, est destinée au dépôt et à la diffusion de documents scientifiques de niveau recherche, publiés ou non, émanant des établissements d'enseignement et de recherche français ou étrangers, des laboratoires publics ou privés.



Distributed under a Creative Commons Attribution - NonCommercial 4.0 International License

Complications and Outcomes in 69 Consecutive Patients with Floating Hip

Alexandre **Cech**^b, Clémentine **Rieussec**^b, Gaël **Kerschbaumer**^b, Olivier **Seurat**^b, Clémentine **Corbet**^b, Benoît **Vibert**^b, Camille **Tronc**^b, Sébastien **Ruatti**^b, Pierre **Bouzat**^c, Jérôme **Tonetti**^{a,b}, Mehdi **Boudissa**^{a,b,*}

a. Service de chirurgie orthopédique et traumatologique, Centre Hospitalier Universitaire de Grenoble, Université Grenoble Alpes, La Tronche, 38700, France

b. TIMC-IMAG lab, Univ. Grenoble Alpes, CNRS UMR 5525, La Tronche, 38700, France

c. Service de réanimation et déchochage, Centre Hospitalier Universitaire de Grenoble, Université Grenoble Alpes, La Tronche, 38700, France

***Corresponding author:** Mehdi Boudissa,

Service de Chirurgie Orthopédique et Traumatologique, CHU Grenoble, Hôpital Nord,
Boulevard de la Chantourne, 38700 La Tronche, Grenoble, France

Telephone: +33601046824

E-mail: mboudissa@chu-grenoble.fr

ABSTRACT

Background: Floating hip is a rare and potentially serious injury. The objective of this study was to evaluate our management strategy for patients with floating hip.

Hypothesis: A standardized strategy with specialised multidisciplinary management is associated with a low mortality rate.

Methods: Consecutive patients who had surgery to treat floating hip between January 2010 and December 2019 were included in this single-centre retrospective study. Epidemiological, clinical, and radiological data were collected and analysed. Patients were managed according to a standardised strategy adapted to the haemodynamic status and type of floating hip (type A, femoral and pelvic ring fractures; type B, femoral and acetabular fractures; and type C, femoral, acetabular, and pelvic ring fractures). The clinical outcome at last follow-up was determined by a telephone interview, based on the Majeed and Oxford scores, sports resumption, and work resumption. To assess the radiological outcomes, we applied Matta's criteria for the acetabulum and Tornetta's criteria for the pelvic ring.

Results: We included 69 patients with a mean age of 38.5 years. Among them, 39 (57%) had haemodynamic instability requiring embolisation (n=15, 22%) or multiple blood transfusions (n=24, 35%). Type A injuries predominated (n=57, 83%). The need for multiple blood transfusions was significantly associated with type C floating hip, underlining the risk of heavy bleeding with this injury. Two (3%) patients died. When management was complete, the reduction was anatomical or satisfactory for 76% (13/17) of the acetabula according to Matta's criteria (maximum residual displacement <3 mm) and for 85% (56/66) of the pelvic rings according to Tornetta's criteria (maximum residual displacement <10 mm). One or more complications occurred in 45 (65%) patients. After a mean follow-up of 5 years, the mean Oxford Hip Score in patients with acetabular fractures was 35.5 and the mean Majeed score in patients with pelvic ring fractures was 71.5. Only 30% of patients were able to resume physical activities at the former level and to return to their former professional activities.

Conclusion: Type C floating hip, which combines fractures of the pelvic ring and acetabulum, carries a high risk of bleeding. Special attention should be directed to the reduction of pelvic ring fractures, to avoid malunion. Acetabular fractures that are complex in the Letournel classification carry a risk of imperfect reduction. The results of this study

confirm the severity of these rare injuries and the need for specialised multidisciplinary management according to a standardised strategy that is appropriate for the haemodynamic status and type of floating hip (A, B, or C).

Level of evidence: IV; retrospective study

Key words: Floating hip. Femoral fracture. Pelvic ring fracture. Acetabular fracture. Ipsilateral fractures.

1. Introduction

The term ‘floating joint’ designates a group of injuries characterised by ipsilateral fractures of the bones on either side of the joint, which is thus deprived of its connection to the skeleton [1]. The term ‘floating hip’ was first used in 1992 by Liebergall and colleagues to designate a combination of pelvic ring or acetabular fractures and of ipsilateral femoral fractures involving the neck, trochanter, and/or femoral shaft. Two types were distinguished, both with a femoral fracture, combined with either a pelvic ring fracture (type A) or an acetabular fracture (type B) [2]. In 1999, Muller and co-workers added type C characterised by pelvic ring, acetabular, and femoral fractures, as well as supracondylar femoral fractures [3].

The main published data are limited to anecdotal reports and a few clinical cohort studies. This paucity of information is ascribable to the rarity of floating hip, whose incidence rate has been estimated at 1/10 000 fractures and which is seen in trauma centres only 2 to 8 times each year [2-7]. Moreover, variations in the definition of floating hip combined with the scarcity of these injuries result in considerable heterogeneity across published studies. Nonetheless, the published information highlight the severity and management difficulties

associated with these injuries, which result in numerous complications [2-7]. In the current state of knowledge, no consensus exists about the optimal management of floating hip.

The objective of this study was to evaluate the strategy used at our trauma centre to manage patients with floating hip.

2. Material and Methods

Patients

We conducted a single-centre retrospective study of patients managed between January 2010 and December 2019. Consecutive patients who underwent surgery for floating hip during the study period were included.

Epidemiological, clinical, and radiological data were collected and analysed. Pelvic ring fractures were classified according to Tile, acetabular fractures according to Letournel, and femoral fractures according to the AO classification [8,9]. We also collected data on intensive care (Injury Severity Score [ISS], blood transfusions, embolisation) and surgery [10]. Complications were recorded.

The primary endpoint was survival from treatment initiation to correction of shock and at hospital discharge. The clinical and radiological outcomes were the secondary endpoints. At last follow-up, the clinical outcomes were evaluated during a telephone call, based on the Majeed score and Oxford Hip Score (OHS) and on the resumption of sports and work [11,12]. To assess the radiological outcomes, Matta's criteria were applied for the acetabulum (anatomical reduction, minimum residual displacement [MRD] <2 mm; imperfect reduction, MRD=2-3 mm, and poor reduction, MRD>3 mm) and Tornetta's criteria for the pelvic ring (anatomical reduction, MRD≤5 mm; good reduction, MRD=5–10 mm; fair reduction, MRD =10–20 mm; and poor reduction, MRD>20 mm [13,14].

Description of patient management

Patients were managed according to a standardised strategy adapted to the degree of haemodynamic stability and to the type of floating hip (A, femoral and pelvic ring fractures; B, femoral and acetabular fractures; and C, femoral, acetabular, and pelvic ring fractures [15,16]. All patients were wearing a pelvic belt when they arrived at the shock unit. Patients whose haemodynamic parameters were stable had the belt removed in the presence of the trauma surgeon. If the status of the patient worsened during belt removal, the belt was put on again and the treatment was continued according to the decision tree described below.

For type A injuries, internal fixation of the femur was performed first to allow effective trans-osseous traction of the pelvic ring. Femoral fixation may be challenging in patients with floating hip, because the effect of the traction table is diminished due to the concomitant pelvic fracture. Special attention must be directed to restoring femoral length, which may require open reduction of the fracture site. Secondly, a definitive procedure appropriate for the anterior and posterior injuries was performed, with a preference for plate fixation of anterior fractures and for percutaneous ilio-sacral screw fixation if possible for the posterior lesions; when the patient's anatomical characteristics precluded this last procedure, trans-iliac plate fixation was performed [17,18]. In patients with haemodynamic instability, the pelvic ring and femoral fractures were stabilised by external fixation and the posterior lesion was managed by percutaneous ilio-sacral screw fixation [18]. For overweight or obese patients, we prefer the use of an anterior subcutaneous pelvic fixator (INFIX) for follow-on stabilisation after external fixation [19].

For type B injuries, starting by internal fixation of the femoral fracture contributes to and facilitates the reduction of the acetabulum. Effective trans-osseous traction complying with recommendations for managing acetabular fractures is followed after about 5 days by

fixation of the acetabular fractures [16]. In patients with femoral neck fractures and in those who are elderly or have adverse prognostic factors (e.g., major cartilage impaction, severe femoral head damage...), we prefer total hip arthroplasty (THA) combined with same-stage internal fixation of the acetabulum [20,21].

In type C injuries, the initial management is the same as for type A injuries. Internal fixation of the acetabular fractures is then performed around the 5th day, while maintaining effective trans-osseous traction [15].

Figure 1 illustrates the surgical strategy used at our centre to manage patients with floating hip.

Statistical analysis

The statistical analysis was conducted using Statview 5.5 software (SAS Institute, Cary, NC, USA). Comparisons were performed by applying the chi-square test for qualitative variables and Student's test for quantitative variables. When the data were not normally distributed (subgroup analyses), Fisher's exact test for qualitative variables was used. Values of *p* below 0.05 were taken to indicate significant differences and were confirmed by a specific statistical analysis based on an ANOVA model.

3. Results

Patients and injuries (Table 1)

Between January 2010 and December 2019, 69 patients were managed at our centre for floating hip. There were 18 (26%) females and 51 (74%) males with a mean age of 38.5±15.7 years (range, 16–88 years). The injury was caused by a high-energy accident in all 69 patients, with the most common causes being road traffic accidents (n=28; 41%) and

mountaineering accidents (n=18, 26%). Type A injuries predominated (n=52, 75%), followed by type C injuries (n=14, 20%) then by type B injuries (n=3, 4%). Among the pelvic ring fractures, Tile B injuries were the most common (n=29, 42%), followed by Tile C injuries (n=26, 38%) [8]. In the Letournel classification, a small majority of the acetabular lesions were simple fractures (9/17, 53%). Diaphyseal fractures were the most common femoral lesions (n=35, 51%), followed by proximal fractures (n=31, 45%). All 69 patients had at least one other injury and therefore met the definition of polytrauma victim. Most of these other injuries involved the chest (n=49, 71%) and head (n=43, 62%). Finally, 9 (13%) patients had open femoral fractures and 4 (6%) open pelvic ring fractures.

As shown in Table 1, the pelvic ring fractures classified according to Tile differed significantly between the groups with type A and type C fractures ($p=0.03$). Presence of an open pelvic fracture ($p<0.01$) and presence of a spinal injury ($p<0.01$) were significantly associated with type B or type C floating hip.

Management

Over half the patients (n=39, 57%) had haemodynamic instability requiring embolisation (n=15, 22%) or multiple blood transfusions (n=24, 35%). The damage control orthopaedics approach was needed in 59 (86%) patients, most of whom received trans-osseous femoral traction (n=44, 64%). Application of a pelvic C-clamp was required for only 3 (4%) patients. A more often used method was external fixation, which was applied to the femur in 9 (13%) patients and to the pelvis in 10 (14%) patients.

The mean time from injury to surgery was 2 days for the femur, 8.3 days for the acetabulum, and 3.7 days for the pelvic ring. Most femoral fractures were treated by intramedullary nailing (n=51, 74%). However, 9 (13%) patients required open reduction to restore femoral length. The treatment of the pelvic ring fractures consisted in isolated anterior

internal fixation in 7 (11%) patients using a 6-hole symphyseal plate (Synthes, West Chester, PA, USA) and in isolated posterior fixation in 24 (36%) patients using percutaneous ilio-sacral screw fixation with 7.3-mm cannulated screws (Synthes). Isolated posterior fixation using a U-shaped locking compression plate (Synthes) was performed in 2 (3%) patients and anterior subcutaneous pelvic fixation (INFIX) in 2 (3%) patients. In 29 (42%) patients, combined anterior and posterior fixation was achieved using a symphyseal plate and ilio-sacral screw fixation. Of the 17 acetabular fractures, 8 (47%) required internal fixation and 3 (17%) prosthetic replacement combined with internal fixation. Application of Tornetta's criteria to the 66 pelvic ring fractures (floating hip types A and C) indicated that reduction was good or excellent in 56 (85%) patients. According to Matta's criteria, reduction was anatomical or imperfect for 6 (75%) of the 8 surgically treated acetabular fractures. Table 2 reports the radiological outcomes and recapitulates the management strategy. A requirement for multiple blood transfusions was significantly associated with type C floating hip ($p<0.01$), underlining the risk of severe bleeding with this lesion. Type C floating hip was significantly associated with treatment using an anterior symphyseal plate and one or more posterior ilio-sacral screws ($p=0.03$).

Two (3%) patients died. One was a 65-year-old male with a type A floating hip involving a Tile C3-2 pelvic ring fracture. Haemodynamic instability required embolisation of the internal iliac artery. The ISS score was 53. Intramedullary nailing of the femur was performed on the day of the accident, and a pelvic C-clamp was placed to stabilise the pelvic ring fracture. The patient died on the fifth day, in the intensive care unit, due to severe head and lung injuries. The other patient was a 34-year-old male with type A floating hip involving a Tile C-1 pelvic ring fracture. He had haemodynamic instability that required embolisation of a gluteal artery. His ISS score was 51. Intra-medullary nailing of the femur was performed on the day of the accident, as well as percutaneous posterior ilio-sacral screw fixation. An

external fixator was used to stabilise the pelvic ring. This patient died on the eighth day, also in the intensive care unit and due to severe head and lung injuries.

One or more complications developed in 45 (65%) patients. Table 3 lists the complications. Thrombo-embolism was the most common complication (n=11, 16%), followed by peripheral nerve injuries (n=8, 12%; including 2 [3%] iatrogenic injuries). Heterotopic ossifications developed in 8 (8/69; 12%) patients among the 17 (8/17, 47%) patients with acetabular fractures. The development of heterotopic ossifications was significantly associated with having an acetabular fracture (type B or C floating hip, $p<0.01$).

Mean follow-up was 5 ± 3 years (range, 1–10 years). At last follow-up, 19 (28%) patients could not be contacted for the telephone interview. Of the remaining 50 patients, 3 had an isolated acetabular lesion, 38 an isolated pelvic ring lesion, and 9 lesions of both the acetabulum and pelvic ring. In the 12 patients with acetabular lesions, the mean Oxford Hip Score was 35.5 ± 10 (range, 16–46). In the 47 patients with pelvic ring lesions, the mean Majeed score was 71.5 ± 22.6 (range, 22–100). Of the 50 patients, 35 (70%) had been unable to resume sports at their previous level and 21 (n=42%) had been forced to change jobs due to their health. Only 15 (30%) patients resumed sports at the same level and 17 (34%) at a lower level. Finally, 15 (30%) patients were able to return to their previous job and 14 (28%) were not working at the time of the interview.

Univariate analyses followed by a multivariate analysis were performed to identify factors associated with the quality of reduction of the acetabular fractures (Matta's criteria) and pelvic ring fractures (Tornetta's criteria). The following variables were tested: age at the time of the injury, haemodynamic instability at admission, need for embolisation, ISS score, Tile classification, Letournel classification (simple vs. complex fractures), type of floating hip (A, B, or C), presence of an open pelvic ring fracture, time from the injury to surgery, Majeed's score, Oxford Hip Score, return to sports, return to work, presence of a neurological

injury, non-union, malunion, and secondary total hip arthroplasty [8-14]. Poor or imperfect acetabular reduction (8/17 patients) was significantly associated with a complex fracture in the Letournel classification ($p=0.04$) [9]. Also, poor or fair pelvic ring reduction (10/66 patients) was significantly associated with malunion ($p=0.009$) [14]. No statistically significant associations were found between the quality of the reduction and the functional outcome (Oxford Hip Score and Majeed's score, return to sports, return to work ($p>0.05$), or any of the other tested variables.

4. Discussion

Floating hip is a serious diagnosis that usually occurs in patients who with haemodynamic instability caused by concomitant injuries to vital organs. The mechanism is usually a high-energy trauma. Early multidisciplinary management by intensivists, interventional radiologists, and surgeons is crucial. The strategy must be appropriate for the haemodynamic status of the patient (resuscitation and vital organ support, damage control orthopaedics) then to the type of floating hip (prompt internal fixation of the femur followed, when the patient's status has improved, by fixation of the pelvic ring and acetabulum)(figure 2 and 3). This strategy limits the mortality rate, which was 3% in our population. Death is usually due to haemodynamic instability and generally occurs at the initial phase of management. Thus, in studies of patients with floating hip involving pelvic ring fractures, Muller et al. reported 2/40 (5%) deaths within the first 24 hours, while Wu et al. observed a higher mortality rate of 5/40 (12.5%) [3,5]. These data underline the importance of management in trauma centres, as shown by the low mortality rate in our population, which is all the more remarkable that no patients required intra-aortic balloon pump therapy [15,22].

Delayed mortality is due to the concomitant lesions frequently seen in patients with floating hip. Thus, in our study, all 69 patients had at least one other concomitant injury. Liebergall et al. observed fractures at other sites in nearly two-thirds of patients, with half these lesions being open fractures [2,4]. The presence of concomitant lesions often increases the time from injury to definitive surgery on the floating hip, which varied from a mean of 87 to 132 hours studies by Burd et al. and Muller et al, respectively [3,7].

Two currents of thought exist regarding floating hip. According to one, floating hip constitutes a fracture entity with its own specific pattern of pathophysiological factors, concomitant injuries, and management requirements. The other holds that the concomitant injuries and management approach are the same as for each lesion occurring alone [3,23]. We believe that it is the accumulation of lesions often seen in patients with floating hip that generates the management difficulties and, in particular, the high complication rate. There seems to be a multiplier effect of the various lesions and their consequences, as opposed to an additive effect. Thus, in our study 45 patients, i.e., 65% of the population, experienced at least one complication. These complications are well documented in the literature and include neurological lesions, found in 16% to 50% of patients, and heterotopic ossifications, reported in 34% to 42% of floating hip cases with acetabular fractures [2-7]. In our population, 8 patients developed heterotopic ossifications, i.e., only 12% of the overall population but 47% (8/17) of the patients with acetabular fractures. Malunion and non-union are not rare, with a frequency of up to 10% of patients in the study by Muller et al [3]. We observed 4 (6%) cases of non-union, at the femur in 2 (3%) patients and at the pelvic ring in the other 2 (3%) patients. Malunion occurred in 5 (7%) patients, at the femur in 1 (1%) patient and at the pelvic ring in 4 (6%) patients.

Injuries to vital organs are common due to the high energy of the trauma and may be life threatening. In our population, most of these injuries involved the chest (n=49, 71%) and head (n=43, 62%).

The functional outcomes should be interpreted in the light of these concomitant injuries and of the complications, which can severely affect the functional prognosis. However, this point is not universally agreed on in the literature. Thus, Pavelka et al. observed no significant differences in outcomes compared to the outcomes of each lesion occurring in isolation, a finding consistent with a report by Zamora-Navas et al. [24,25]. Outcomes in patients with type B floating hip seemed favourable according to Liebergall et al, who reported a mean Harris Hip Score of 83.8 after 74 months of mean follow-up in 20 patients, of whom 2 (10%) required secondary THA [4]. Of our 69 patients, 3 (4%) required secondary THA. In all, 17 patients had acetabular fractures (type B or C floating hip). All 3 patients who required secondary THA were among the 17 patients with acetabular fractures, a subgroup in which secondary THA was therefore required in 18% of cases (3/17).

The heterogeneity of published studies, low incidence of floating hip, and difficulty in interpreting the clinical outcomes given the impact of the many concomitant injuries and complications constitute substantial obstacles to comparisons across studies. Also, the lack of a standardised management approach and the variability in the treatments used (e.g., plate fixation, nailing, external fixation, or minimally invasive procedures) preclude reliable comparisons of radiological and functional outcomes.

Our study has many limitations. The retrospective design can only provide a low level of evidence. Another limitation of the retrospective design is the high proportion of patients lost to follow-up (19/69, 28%), which complicates the interpretation of the clinical results. The collection during a telephone interview performed at last follow-up, after 5 years, involved having the patients conduct self-evaluations using clinical scores whose reliability

remains open to criticism. Finally, the main limitation of our work is the heterogeneity of the population, with a predominance of type A floating hip (52/69, 75%) and only 3 (4%) patients with type B floating hip. Nevertheless, several strengths of our study deserve to be pointed out. The absence of missing data for the primary endpoint allows an assessment of the efficacy of our management strategy in ensuring survival. The mean follow-up of 5 years and high number of patients with this rare and particularly serious injury indicate that our clinical and radiological data deserve careful attention.

5. Conclusion

Type C floating hip, which combines acetabular and pelvic ring fractures, is associated with a higher risk of bleeding. Careful attention should be directed to the reduction of the pelvic ring lesions in order to minimise the risk of malunion. Complex acetabular lesions in the Letournel classification carry a higher risk of poor reduction. Our results confirm the severity and the need for specialised multidisciplinary management of these rare lesions, which require a standardised strategy appropriate for the degree of haemodynamic stability and the type of floating hip (A, B, or C).

Conflicts of interest

None of the authors has any conflicts of interest to declare in relation to this work.

Funding

None

Contributions of each author

Jérôme Tonetti and Mehdi Boudissa conceived the study.

Alexandre Cech, Clémentine Rieussec, Olivier Seurat, Benoit Vibert, Clémentine Corbet,

Camille Tronc, Gael Kerschbaumer, and Sébastien Ruatti managed the study data.

Mehdi Boudissa wrote the article.

References

- [1] Simpson NS, Jupiter JB. Complex fracture patterns of the upper extremity. *Clin Orthop Relat Res.* 1995;318:43-53.
- [2] Liebergall M, Lowe J, Whitelaw GP, Wetzler MJ, Segal D. The floating hip. Ipsilateral pelvic and femoral fractures. *J Bone Joint Surg Br.* 1992;74:93-100.
- [3] Müller EJ, Siebenrock K, Ekkernkamp A, Ganz R, Muhr G. Ipsilateral fractures of the pelvis and the femur--floating hip? A retrospective analysis of 42 cases. *Arch Orthop Trauma Surg.* 1999;119:179-82.
- [4] Liebergall M, Mosheiff R, Safran O, Peyser A, Segal D. The floating hip injury: patterns of injury. *Injury.* 2002;33:717-22.
- [5] Wu CL, Tseng IC, Huang JW, Yu YH, Su CY, Wu CC. Unstable pelvic fractures associated with femoral shaft fractures: a retrospective analysis. *Biomed J.* 2013;36:77-83.
- [6] Suzuki T, Shindo M, Soma K. The floating hip injury: which should we fix first? *Eur J Orthop Surg Traumatol.* 2006;16:214-218.
- [7] Burd TA, Hughes MS, Anglen JO. The floating hip: complications and outcomes. *J Trauma.* 2008;64:442-8.
- [8] Tile M. Classification of pelvic fracture. In: *Fracture of the pelvis and acetabulum.* Baltimore: Wilkins W; 1995. pp.66-101.
- [9] Letournel E. Acetabulum fractures: classification and management. *Clin Orthop Relat Res* 1980;151:81-106.
- [10] Baker SP, O'Neill B, Haddon W Jr, Long WB. The injury severity score: a method for describing patients with multiple injuries and evaluating emergency care. *J Trauma* 1974;14:187-196.
- [11] Majeed SA. Grading the outcome of pelvic fractures. *J Bone Joint Surg Br* 1989;71:304-6.

- [12] Murray DW, Fitzpatrick R, Rogers K, Pandit H, Beard DJ, Carr AJ, Dawson J. The use of the Oxford hip and knee scores. *J Bone Joint Surg Br.* 2007;89:1010-4.
- [13] Matta JM, Merritt PO. Displaced acetabular fractures, *Clin Orthop Relat Res* 1988, 230, 83-97, 1988
- [14] Tornetta P 3rd, Matta JM. Outcome of operatively treated unstable posterior pelvic ring disruptions. *Clin Orthop Relat Res* 1996;329:186-93.
- [15] Ruatti S, Guillot S, Brun J, Thony F, Bouzat P, Payen JF, Tonetti J. Which pelvic ring fractures are potentially lethal? *Injury.* 2015;46:1059-63. doi: 10.1016/j.injury.2015.01.041.
- [16] Tonetti J, Jouffroy P; Pelvis-Acetabulum Club. Recent progress in the diagnosis and treatment of pelvic ring and acetabular fracture. *Orthop Traumatol Surg Res.* 2017;103:631-632.
- [17] Boudissa M, Saad M, Kerschbaumer G, Ruatti S, Tonetti J. Posterior transiliac plating in vertically unstable sacral fracture. *Orthop Traumatol Surg Res.* 2020;106:85-88. doi: 10.1016/j.otsr.2019.06.014
- [18] Tonetti J, van Overschelde J, Sadok B, Vouaillat H, Eid A. Percutaneous ilio-sacral screw insertion. fluoroscopic techniques. *Orthop Traumatol Surg Res.* 2013;99:965-72. doi: 10.1016/j.otsr.2013.08.010.
- [19] Steer R, Balendra G, Matthews J, Wullschlegler M, Reidy J. The use of anterior subcutaneous internal fixation (INFIX) for treatment of pelvic ring injuries in major trauma patients, complications and outcomes. *SICOT J.* 2019;5:22. doi: 10.1051/sicotj/2019019.
- [20] Boudissa M, Ruatti S, Kerschbaumer G, Milaire M, Merloz P, Tonetti J. Part 2: outcome of acetabular fractures and associated prognostic factors-a ten-year retrospective study of one hundred and fifty six operated cases with open reduction and internal fixation. *Int Orthop.* 2016;40:2151-2156.

- [21] Boudissa M, Francony F, Drevet S, Kerschbaumer G, Ruatti S, Milaire M, Merloz P, Tonetti J. Operative versus non-operative treatment of displaced acetabular fractures in elderly patients. *Aging Clin Exp Res*. 2019. doi: 10.1007/s40520-019-01231-5.
- [22] Pieper A, Thony F, Brun J, Rodière M, Boussat B, Arvieux C, Tonetti J, Payen JF, Bouzat P. Resuscitative endovascular balloon occlusion of the aorta for pelvic blunt trauma and life-threatening hemorrhage: A 20-year experience in a Level I trauma center. *J Trauma Acute Care Surg*. 2018;84:449-453. doi: 10.1097/TA.0000000000001794.
- [23] Zamora-Navas P, Guerado E. Vascular complications in floating hip. *Hip Int*. 2010;20 S7:S11-8.
- [24] Pavelka T, Salášek M, Weisová D. Floating Hip Injuries: Treatment Outcomes and Complications. *Acta Chir Orthop Traumatol Cech*. 2016;83:311-316.
- [25] Zamora-Navas P, Estades-Rubio FJ, Cano JR, Guerado E. Floating hip and associated injuries. *Injury*. 2017;48:S75-S80.

FIGURE LEGENDS

Figure 1: Surgical management strategy for patients with floating hip

Figure 2: Example of damage control orthopaedics in a 46-year-old male with type A floating hip and haemodynamic instability at admission. He had a Gustilo 3C open fracture of the femoral shaft with an arterial injury. The ipsilateral tibial plateau was fractured, creating a floating knee.

(A) 3D reconstruction at admission. External femoral fixation and bypass surgery of the superficial femoral artery were the first treatments. After removal of the pelvic C-clamp and multiple blood transfusions, the patients recovered stable haemodynamics.

(B) On the second day, external fixation of the pelvis to reduce the anterior displacement and avoid ascension of the left hemi-pelvis; percutaneous ilio-sacral screw fixation of the posterior fracture

(C) (D) (E) Follow-up computed tomography scan, axial view showing good reduction of the posterior fracture

Figure 3: Example of definitive treatment after damage control orthopaedics

(A) 3D reconstruction showing intra-medullary nailing after removal of the external fixator on day 10

(B) Antero-posterior pelvic radiograph showing removal of the external fixator and fixation by a 6-hole symphyseal plate on day 15

(C) (D) (E) Trans-tibial amputation was required due to ischaemia. Radiographs of the left lower limb on day 45

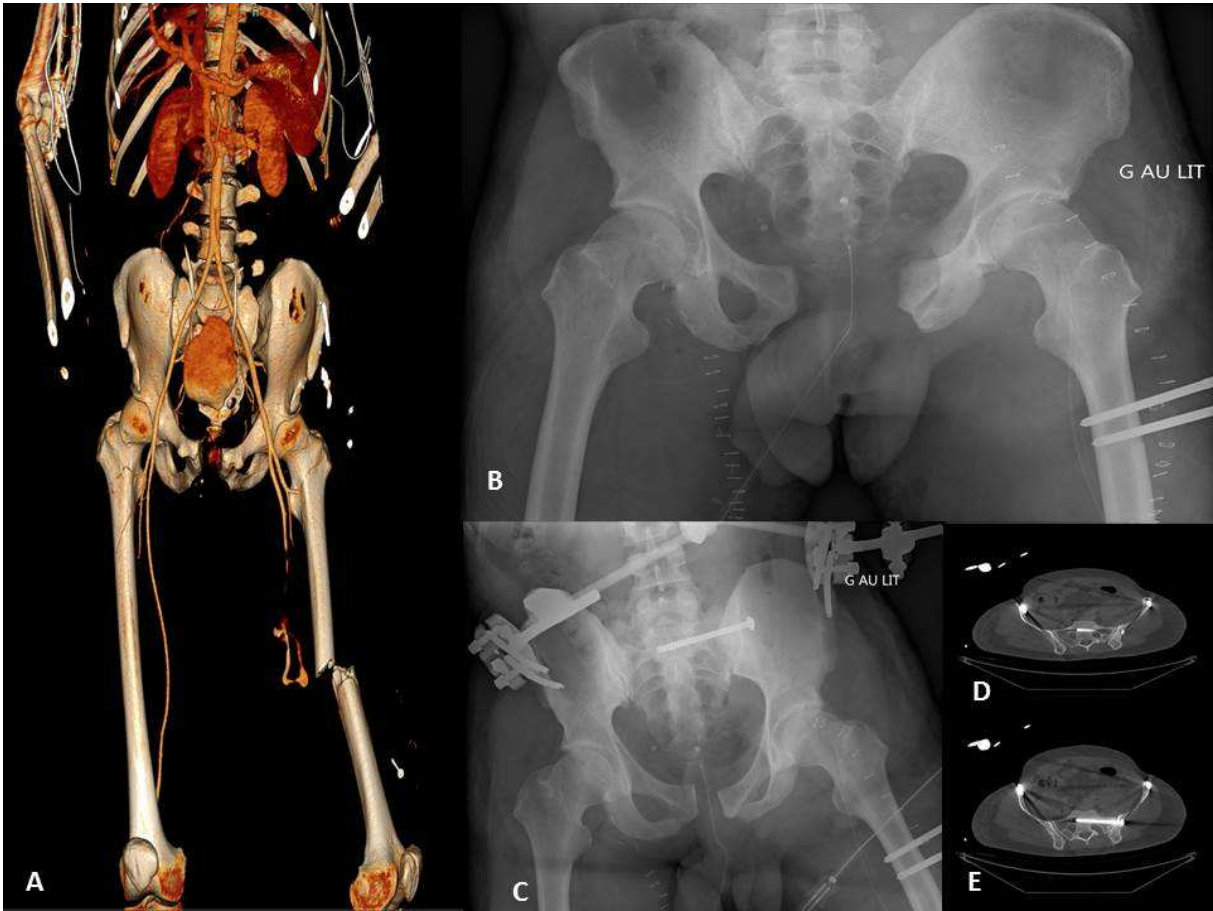
(F) 3D reconstruction on day 45

Table 1: Main features of the study patients

Table 2: Management strategy and radiological outcomes

Table 3: Complications

Fig 2



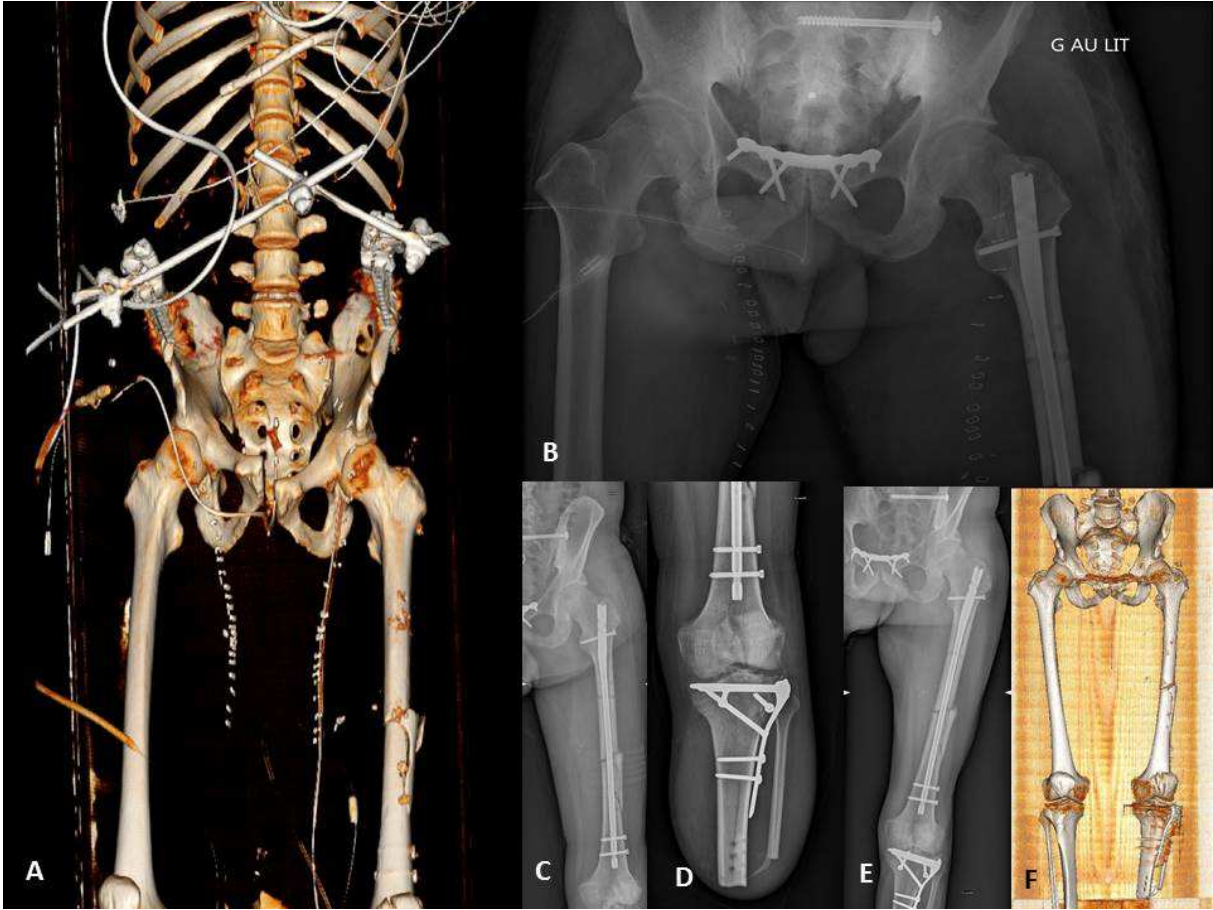


Fig 3

Table 1 :

Variables	Overall population n=69 (%)	Type A n=52 (%)	Type B n=3 (%)	Type C n=14 (%)	p value
Sex					
<i>Females (%)</i>	18 (26%)	13 (25%)	0 (0%)	5 (36%)	0.41
<i>Males (%)</i>	51 (74%)	39 (75%)	3 (100%)	9 (64%)	0.41
Age, years (range)	38.5 (16-88)	38.2 (17-88)	39 (24-55)	39.3 (16-68)	0.97
Body Mass Index (kg/m ²) (range)	23 (17-38)	23 (17-33)	24.3 (23-27)	23.2 (18-38)	0.83
Mechanism of injury					
<i>Traffic accident (%)</i>	28 (41%)	22 (42%)	0 (0%)	6 (43%)	0.13
<i>Mountain climbing accident (%)</i>	18 (26%)	13 (25%)	3 (100%)	2 (14%)	0.13
<i>Work-related accident (%)</i>	3 (4%)	2 (4%)	0 (0%)	1 (7%)	0.13
<i>Other (%)</i>	20 (29%)	15 (29%)	0 (0%)	5 (36%)	0.13
Type of floating hip					
<i>A = femur + pelvic ring (%)</i>	52 (75%)	52 (100%)	0 (0%)	0 (0%)	-
<i>B = femur + acetabulum (%)</i>	3 (4%)	0 (0%)	3 (100%)	0 (0%)	-
<i>C = femur + acetabulum +pelvic ring (%)</i>	14 (20%)	0 (0%)	0 (0%)	14 (100%)	-
Tile's classification [8]	n= 66 (%)				
<i>A (%)</i>	11 (16%)	11 (21%)	-	0 (0%)	0.03
<i>B (%)</i>	29 (42%)	19 (37%)	-	10 (71%)	0.03
<i>C (%)</i>	26 (38%)	22 (42%)	-	4 (29%)	0.03
Letournel's classification [9]	n = 17 (%)				
Simple (%)	9 (53%)	-	2 (67%)	7 (50%)	1
<i>Anterior wall (%)</i>	4 (24%)	-	0 (0%)	4 (29%)	0.54
<i>Posterior wall (%)</i>	3 (18%)	-	2 (67%)	1 (7%)	0.06
<i>Anterior column (%)</i>	2 (12%)	-	0 (0%)	2 (14%)	1
Complex (%)	8 (47%)	-	1 (33%)	7 (50%)	1
<i>T (%)</i>	3 (18%)	-	1 (33%)	2 (14%)	0.46
<i>Anterior column and posterior hemi-transverse fracture (%)</i>	2 (12%)	-	0 (0%)	2 (14%)	1
<i>Both columns (%)</i>	3 (18%)	-	0 (0%)	3 (21%)	1
AO classification of the femoral fracture					
<i>31 Proximal (%)</i>	27 (39%)	21 (40%)	0 (0%)	6 (43%)	0.51
<i>32 Diaphyseal (%)</i>	39 (57%)	28 (54%)	3 (100%)	8 (57%)	0.51
<i>33 Distal (%)</i>	3 (4%)	3 (6%)	0 (0%)	0 (0%)	0.51
Open fractures					
<i>Femur (%)</i>	9 (13%)	8 (15%)	0 (0%)	1 (7%)	0.56
<i>Pelvis (%)</i>	4 (6%)	0 (0%)	2 (67%)	2 (14%)	p<0.01
Other lesions					
<i>Thorax (%)</i>	49 (71%)	36 (69%)	2 (67%)	11 (79%)	0.78
<i>Head (%)</i>	43 (62%)	33 (63%)	3 (100%)	7 (50%)	0.25
<i>Abdomen (%)</i>	31 (45%)	24 (46%)	0 (0%)	7 (50%)	0.26
<i>Urogenital injuries (%)</i>	13 (19%)	10 (19%)	0 (0%)	3 (21%)	0.68
<i>Spine (%)</i>	12 (17%)	4 (8%)	2 (67%)	6 (43%)	p<0.01
<i>Maxillo-facial injuries (%)</i>	33 (48%)	23 (44%)	1 (33%)	9 (64%)	0.36
<i>Vascular (arterial) injuries (%)</i>	22 (32%)	17 (33%)	1 (33%)	4 (29%)	0.95
Limbs					

<i>Upper limb (%)</i>	17 (25%)	14 (27%)	1 (33%)	2 (14%)	0.58
<i>Lower limb (%)</i>	19 (28%)	16 (31%)	1 (33%)	2 (14%)	0.45
<i>Upper and lower limbs (%)</i>	11 (16%)	6 (12%)	1 (33%)	4 (29%)	0.21
ISS [10] (range)	26.1 (9-53)	25.4 (9-53)	30 (20-41)	27.6 (11-47)	0.71

Table 2:

Variables	Overall population n=69 (%)	Type A n=52 (%)	Type B n=3 (%)	Type C n=14 (%)	p value
Haemodynamic status at arrival					
<i>Stable (%)</i>	30 (43%)	23 (44%)	1 (33%)	6 (43%)	0.93
<i>Unstable (%)</i>	39 (57%)	29 (56%)	2 (67%)	8 (57%)	0.93
Number of transfused red-blood-cell packs (range)	2.7 (1-9)	2.7 (1-9)	2 (1-5)	2.9 (1-5)	0.88
Haemostatic interventions	a				
<i>Embolisation (%)</i>	15 (22%)	10 (19%)	1 (33%)	4 (29%)	0.67
<i>Multiple blood transfusions (%)</i>	24 (35%)	10 (19%)	2 (67%)	12 (86%)	p<0.01
<i>REBOA (%) [21]</i>	0 (0%)	0 (0%)	0 (0%)	0 (0%)	1
<i>Pelvic clamp (%)</i>	3 (4%)	3 (6%)	0 (0%)	0 (0%)	1
Damage control orthopaedics					
<i>Trans-osseous traction (%)</i>	44 (64%)	33 (63%)	2 (67%)	9 (64%)	0.99
<i>Pelvic clamp (%)</i>	3 (4%)	3 (6%)	0 (0%)	0 (0%)	1
<i>External fixation, femoral fracture (%)</i>	9 (13%)	6 (12%)	1 (33%)	2 (14%)	0.54
<i>External fixation, pelvic fracture (%)</i>	10 (14%)	8 (15%)	0 (0%)	2 (14%)	1
Mean injury-to-surgery time, days (range)					
<i>femur</i>	1.95 (0-45)	2.2 (0-45)	0.33 (0-1)	1.21 (0-3)	0.46
<i>acetabulum</i>	8.3 (5-13)	-	5 (4-6)	5.5 (3-9)	0.54
<i>pelvic ring</i>	3.7 (0-14)	4 (0-14)	-	3.5 (0-13)	0.32
Definitive femoral ORIF					
<i>nail</i>	51 (74%)	37 (71%)	2 (67%)	12 (86%)	0.52
<i>locking plate</i>	18 (26%)	15 (29%)	1 (33%)	2 (14%)	0.52
Definitive acetabular fixation	n=17 (%)				
<i>ORIF via the anterior approach (%)</i>	4 (23%)	-	0 (0%)	4 (29%)	0.54
<i>ORIF via the posterior approach (%)</i>	3 (18%)	-	2 (67%)	1 (7%)	0.06
<i>ORIF via both approaches (%)</i>	2 (12%)	-	0 (0%)	2 (14%)	1
<i>THA (%)</i>	3 (18%)	-	1 (33%)	2 (14%)	0.46
<i>Non-surgical orthopaedic treatment (%)</i>	5 (29%)	-	0 (0%)	5 (36%)	0.51
Definitive pelvic ring fixation	n=66 (%)				
Anterior lesion only					
<i>Symphyseal plate (%)</i>	7 (11%)	6 (12%)	-	1 (7%)	1
Posterior lesion only					
<i>Ilio-sacral screw fixation (%)</i>	24 (36%)	22 (42%)	-	2 (14%)	0.06
<i>U-shaped plate bridging the sacrum (%)</i>	2 (3%)	2 (4%)	-	0 (0%)	1
Anterior and posterior lesions					
<i>Symphyseal plate + ilio-sacral screw fixation (%)</i>	29 (44%)	19 (37%)	-	10 (71%)	0.03
<i>"INFIX" + ilio-sacral screw fixation (%)</i>	2 (3%)	2 (4%)	-	0 (0%)	1
<i>External fixation + ilio-sacral screw fixation (%)</i>	2 (3%)	1 (2%)	-	1 (7%)	0.38
Quality of reduction according to Tornetta's criteria (pelvic ring) [13]	n=66 (%)				
<i>Excellent (%)</i>	43 (65%)	36 (69%)	-	7 (50%)	0.21
<i>Good (%)</i>	13 (20%)	9 (17%)	-	4 (29%)	0.44

<i>Fair (%)</i>	6 (9%)	5 (10%)	-	1 (7%)	1
<i>Poor (%)</i>	4 (6%)	2 (4%)	-	2 (14%)	0.19
Reduction quality according to Matta's criteria (acetabulum) [12]	n=17 (%)		-		
<i>Anatomical (%)</i>	9 (53%)	-	1 (33%)	8 (57%)	0.57
<i>Imperfect (%)</i>	3 (18%)	-	1 (33%)	2 (14%)	0.46
<i>Poor (%)</i>	5 (29%)	-	1 (33%)	4 (29%)	1

REBOA: resuscitative endovascular balloon occlusion of the aorta; ORIF: open reduction and internal fixation; THA: total hip arthroplasty

Table 3:

Complications	Overall population n=69 (%)	Type A n=52 (%)	Type B n=3 (%)	Type C n=14 (%)	p value
Death (%)	2 (3%)	2 (4%)	0 (0%)	0 (0%)	0.71
Thrombo-embolism (%)	11 (16%)	8 (15%)	0 (0%)	3 (21%)	0.63
<i>Deep vein thrombosis (%)</i>	11 (16%)	8 (15%)	0 (0%)	3 (21%)	0.63
<i>Pulmonary embolism (%)</i>	11 (16%)	8 (15%)	0 (0%)	3 (21%)	0.63
Peripheral neurological deficit (%)	8 (12%)	8 (15%)	0 (0%)	0 (0%)	0.22
<i>Pre-operative (%)</i>	6 (9%)	6 (12%)	0 (0%)	0 (0%)	0.34
<i>Iatrogenic (%)</i>	2 (3%)	2 (4%)	0 (0%)	0 (0%)	0.71
Amputation (%)	3 (4%)	3 (6%)	0 (0%)	0 (0%)	0.59
Fat embolism (%)	3 (4%)	2 (4%)	0 (0%)	1 (7%)	0.81
Sepsis (%)	6 (9%)	5 (10%)	0 (0%)	1 (7%)	0.82
Non-union (%)	4 (6%)	4 (8%)	0 (0%)	0 (0%)	0.49
<i>Femur (%)</i>	2 (3%)	2 (4%)	0 (0%)	0 (0%)	0.71
<i>Pelvic ring (%)</i>	2 (3%)	2 (4%)	0 (0%)	0 (0%)	0.71
<i>Acetabulum (%)</i>	0 (0%)	0 (0%)	0 (0%)	0 (0%)	1
Malunion (%)	5 (7%)	4 (8%)	0 (0%)	1 (7%)	0.88
<i>Femur (%)</i>	1 (1%)	1 (2%)	0 (0%)	0 (0%)	0.55
<i>Pelvic ring (%)</i>	4 (6%)	3 (6%)	0 (0%)	1 (7%)	0.89
Heterotopic ossification (%)	8 (12%)	1 (2%)	2 (67%)	5 (36%)	p<0.01
Delated THA (%)	3 (4%)	-	1 (50%)	2 (17%)	0.39

THA: total hip arthroplasty