



HAL
open science

Clinical heterogeneity of NADSYN1-associated VCRL syndrome

Marion Aubert-mucca, Caroline Janel, Valérie Porquet-Bordes, Olivier Patat, Renaud Touraine, Thomas Edouard, Caroline Michot, Aude Tessier, Valérie Cormier-Daire, Tania Attie-bitach, et al.

► **To cite this version:**

Marion Aubert-mucca, Caroline Janel, Valérie Porquet-Bordes, Olivier Patat, Renaud Touraine, et al.. Clinical heterogeneity of NADSYN1-associated VCRL syndrome. *Clinical Genetics*, 2023, 104 (1), pp.114 - 120. 10.1111/cge.14328 . hal-04819631

HAL Id: hal-04819631

<https://hal.science/hal-04819631v1>

Submitted on 4 Dec 2024

HAL is a multi-disciplinary open access archive for the deposit and dissemination of scientific research documents, whether they are published or not. The documents may come from teaching and research institutions in France or abroad, or from public or private research centers.




L'archive ouverte pluridisciplinaire **HAL**, est destinée au dépôt et à la diffusion de documents scientifiques de niveau recherche, publiés ou non, émanant des établissements d'enseignement et de recherche français ou étrangers, des laboratoires publics ou privés.



Distributed under a Creative Commons Attribution - NonCommercial - NoDerivatives 4.0 International License

SHORT REPORT

Clinical heterogeneity of *NADSYN1*-associated VCRL syndrome

Marion Aubert-Mucca^{1,2}  | Caroline Janel³ | Valérie Porquet-Bordes² |
Olivier Patat¹ | Renaud Touraine⁴ | Thomas Edouard² | Caroline Michot⁵ |
Aude Tessier⁵ | Valérie Cormier-Daire^{5,6}  | Tania Attie-Bitach⁵  | Geneviève Baujat⁵

¹Service de Génétique Médicale, Hôpital Purpan, CHU Toulouse, Toulouse, France

²Endocrine, Bone Diseases and Genetics Unit, Reference Centre for Rare Diseases of Calcium and Phosphate Metabolism, ERN BOND, OSCAR Network, Children's Hospital, Toulouse University Hospital, RESTORE, INSERM U1301, Toulouse, France

³Service de Biochimie et Génétique Moléculaire, CHU Gabriel Montpied, & Laboratoire AURAGEN, Clermont-Ferrand, France

⁴Service de Génétique Clinique, Chromosomique et Moléculaire, CHU-Hôpital Nord, & Laboratoire AURAGEN, Saint Étienne, France

⁵Service de Médecine Génomique des Maladies rares, AP-HP, Bone Diseases expert center, OSCAR network, ERN BOND, Hôpital Necker-Enfants-malades, Paris, France

⁶Université Paris Cité, INSERM UMR 1163, Institut Imagine, Hôpital Necker Enfants Malades, Paris, France

Correspondence

Geneviève Baujat: Service de Médecine Génomique des Maladies rares, AP-HP, Bone Diseases Expert Center, OSCAR network, ERN BOND, Hôpital Necker-Enfants-malades, Paris, France.
Email: genevieve.baujat@aphp.fr

Abstract

The *NADSYN1* gene [MIM*608285] encodes the NAD synthetase 1 enzyme involved in the final step of NAD biosynthesis, crucial for cell metabolism and organ embryogenesis. Perturbing the role of NAD biosynthesis results in the association of vertebral, cardiac, renal, and limb anomalies (VCRL). This condition was initially characterized as severe with perinatal lethality or developmental delay and complex malformations in alive cases. Sixteen *NADSYN1*-associated patients have been published so far. This study illustrates the wide phenotypic variability in *NADSYN1*-associated NAD deficiency disorder. We report the clinical and molecular findings in three novel cases, two of them being siblings with the same homozygous variant and presenting with either a very severe prenatal lethal or a mild phenotypic form. In addition to an exhaustive literature, we validate the expansion of the spectrum of NAD deficiency disorder. Our findings indicate that NAD deficiency disorder should be suspected not only in the presence of the full spectrum of VCRL, but even a single of the aforementioned organs is affected. Decreased plasmatic levels of NAD should then strongly encourage the screening for any of the genes responsible for a NAD deficiency disorder.

KEYWORDS

NAD deficiency disorder, *NADSYN1*, spondylocostal dysostosis, VCRL

1 | INTRODUCTION

The nicotinamide adenine dinucleotide (NAD) is a major coenzyme involved in various metabolic pathways in human cells.¹ NAD biosynthesis occurs either by a de novo pathway-synthetizing from Tryptophan or by a salvage pathway recycling from nicotinamide mononucleotide, nicotinamide riboside, nicotinamide, and nicotinic acid.² The gene *NADSYN1* [MIM*608285] encodes the NAD Synthetase 1 enzyme, which catalyzes the final step of the de novo NAD biosynthesis.^{1,3} A NAD pathway defect has been associated with various

congenital defects: vertebral, cardiac, renal, and limb anomalies (VCRL), where the genes *HAAO* [MIM*604521], *KYNU* [MIM*605197], and *NADSYN1* [MIM*608285] have been implicated.^{4,5} These malformations overlap with a fraction of cases affected with what is known as the VATER/VACTERL association [MIM%192 350]. This malformation sequence is defined by at least three of the following features: vertebral, anal, cardiac, tracheal-esophageal, renal, or limb anomalies.⁶ The same spectrum of NAD deficiency malformations can be reproducibly induced in mice by a dietary restriction in the NAD precursors tryptophan and vitamin B3.⁷

This is an open access article under the terms of the [Creative Commons Attribution-NonCommercial-NoDerivs](https://creativecommons.org/licenses/by-nc-nd/4.0/) License, which permits use and distribution in any medium, provided the original work is properly cited, the use is non-commercial and no modifications or adaptations are made.

© 2023 The Authors. *Clinical Genetics* published by John Wiley & Sons Ltd.

In total, 16 individuals carrying biallelic *NADSYN1* variants have been reported.^{3,8,9} The clinical phenotype described in *NADSYN1*-Associated NAD Deficiency Disorder was initially presented as very severe (five perinatal lethal presentations).³ The molecular screening of a VACTERL cohort allowed to identify nine cases with pathogenic variants in *NADSYN1*, thus expanding the spectrum to living patients with vertebral segmentation defects and a milder phenotype.⁸ Two recent cases also had cardiac and vertebral anomalies, in whom one survived with a mild developmental delay.⁹

The clinical description of *NADSYN1*-associated NAD deficiency disorder still needs to be extended to help clinicians understanding the variability of the phenotype and give diagnostic criteria to screen for a NAD deficiency disorder associated gene. We present here clinical and molecular description of three novel cases from two unrelated families with a remarkable intrafamilial variability, and provide new insights into the phenotypic variability in NAD deficiency disorders with an exhaustive literature review.

2 | MATERIALS AND METHODS

We used clinical networks to collect a multicentric cohort of patients with *NADSYN1*-Associated NAD Deficiency Disorder, evaluated by clinical geneticists and fetal pathologists. Genetic variations were classified following ACMG recommendations.

3 | RESULTS

3.1 | Family 1

The first case (P1) was a 20-year-old male, the second child of a non-consanguineous union of parents aged 30 and 31, presenting with short stature, spondylocostal dysostosis and congenital heart malformation. At birth, the parameters were in the normal range for gestational age. Developmental milestones were acquired normally and he followed a regular education. Multiple heart surgeries were performed due to the complex cardiopathy, including coarctation of aorta, perimembranous ventricular septal defect, small atrial septal defect and hypoplasia of the mitral valve. He underwent surgery for a class 3 maxillo-mandibular dysmorphia. Skeletal findings consisted in various costovertebral malformations with scoliosis and dorsal kyphosis – multiple spine orthopedic surgeries were necessary. Those findings were noticeable on x-rays with the presence of rib synostosis extending from T8 to T11 and vertebral segmentation defects with butterfly vertebrae between L1-L2 and L3-L4 (Figure 1A–C). Height was impacted at 155 cm (–3.6 SDS), with no limb abnormalities. Bifid uvula was observed.

Array-CGH found no copy number variant and skeletal dysplasia next-generation sequencing panel found no variant. Whole genome libraries were prepared using the TruSeq DNA PCR-free kit according to the manufacturers' instructions (Illumina). After quality control using TapeStation (Agilent) and quantitative PCR (Collibri Library

Quantification kit, Invitrogen), samples were sequenced in paired end 2x150 bp on a NovaSeq 6000 (Illumina). Bioinformatic analysis was done with AURAGEN pipeline. Trio genome sequencing revealed the presence of two heterozygous variants in *NADSYN1* (NM_018161.5) in the patient. The pathogenic variation c.1717G > A, p.(Ala573Thr) (PP5 +8, PM2 +2, PP4 +1, BP1 -1) was inherited from the father and has been previously described.^{3,9} The likely pathogenic variation c.644 T > C, p.(Leu215Pro) (PP3 +4, PM2 +2, PM3 +2, PP4 +1, BP1 -1), inherited from the mother, was absent from gnomAD and predicted to be deleterious by multiple computational tools (MetaRNN = 0.988).

3.2 | Family 2

In the second family, two sibs were affected. The parents originated from the same neighborhood and were aged 24 and 26 when the first pregnancy occurred. The first child (P2) was a nine-year-old female with congenital cardiopathy, vertebral dysostosis and limb anomalies. At birth, she was in the normal range for gestational age. Heart surgery was performed at 3 months of age to correct an anomalous left coronary artery from the pulmonary artery. Early developmental milestones were not delayed. Minor hand and foot abnormalities were noted, including proximal implantation of the thumbs and an enlargement between the first and the second toes (sandal gap). She presented with a stature of 126 cm at 7.5 years-old (+0.25 SDS), and had no developmental delay. Skeletal findings consisted of pectus excavatum, kyphosis, and limb anomalies with pronation defect (Figure 1E). X-rays revealed: multiple vertebral anomalies with butterfly vertebrae extending from T8 to T10, bilateral radioulnar synostosis predominant on left side (Figure 1G–I). Derotation osteotomy of the left forearm was performed at 6 years-old. Abdomino-renal and genital examination by ultrasound did not reveal any anatomical defect.

The second case of this family (P3) died 1 h after birth. During the pregnancy, a 16 weeks ultrasound revealed severe cardiopathy with a single ventricle, bilateral renal agenesis, and foot malposition with anamniotic bands. The pregnancy ended with a premature delivery at 27 weeks and 5 days. Weight and length parameters were on the 90th centile for gestational age. Fetopathology analysis revealed a pulmonary hypoplasia associated with a complex cardiopathy with dilatation of the pulmonary artery, hypoplasia of left atrium, ascending aortic stenosis and major hypoplasia of the left ventricle with aortic and mitral atresia. Bilateral renal agenesis, uterus and fallopian tubes agenesis were described. External genitalia found an absence of vaginal and urethra opening. Multiple vertebral segmentation defects and brachymetacarpia were detected on x-rays (Figure 1J).

Array-CGH found no copy number variant.

Exome sequencing analysis using the SureSelect Human All Exon kit (Agilent) revealed the presence of the pathogenic c.1717G > A, p.(Ala573Thr) variant in *NADSYN1*, homozygous in both sibs and heterozygous in parents.

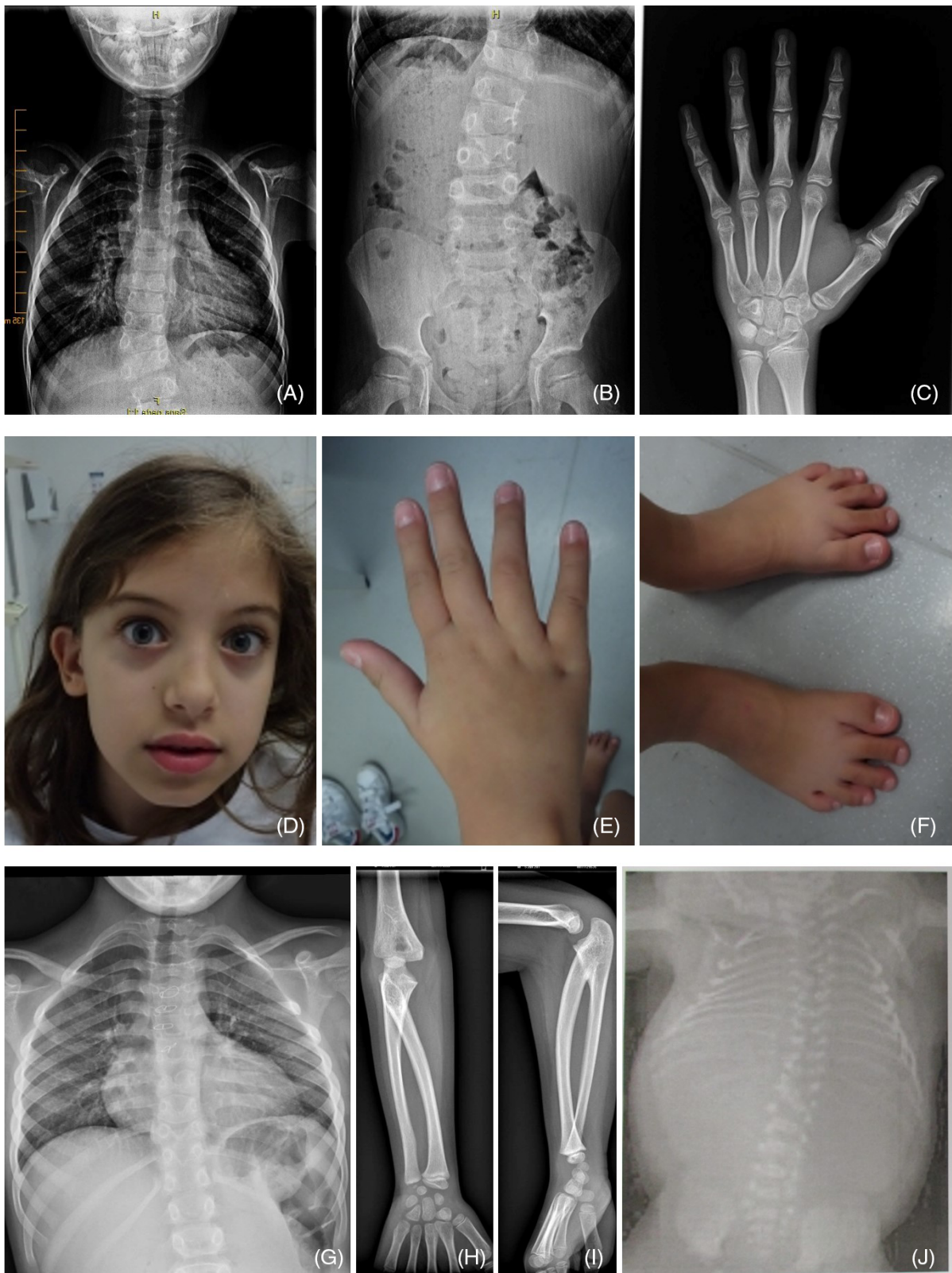


FIGURE 1 Radiological (A–C, G–J), facial (D) and extremities (E–F) findings in patients P1 (A–C), P2 (D–I), and P3 (J). (A) Rib synostosis from T8 to T11 and vertebral segmentation defects with T10 wedge-shaped vertebra; (B) vertebral segmentation defects with butterfly vertebrae between L1, L2 and L3, L4; (C) hand of P1 without anomalies; (D) mild dysmorphic features with broad tip of nose, full lips; (E) proximal implantation of the thumbs and deviation of digits, (F) proximal implantation of halluces and sandal gap; (G) multiple vertebral anomalies with butterfly vertebrae extending from T8 to T10; (H–I) radioulnar synostosis; and (J) multiple segmentation and formation defects of the vertebrae. [Colour figure can be viewed at wileyonlinelibrary.com]

TABLE 1 Genetic and clinical data of the three patients compared to the literature.

	P1	P2	P3	Total	Literature (n = 16)
General data					
Gender	M	F	F	F 2/3, M 1/3	M 11/16, F 5/16
Outcome	Alive, 20 years-old	Alive, 9 years-old	Premature death H1	Alive 2/3, premature death 1/3	Alive 11/16, premature death 3/16, TOP 2/16
genetics					
cDNA variant	c.644 T > C; c.1717G > A	c.1717G > A; c.1717G > A	c.1717G > A; c.1717G > A	c.644 T > C, p. (Leu215Pro): n = 1	c.85 + 1G > C, p.?: n = 1 c.145 T > C, p.(Cys49Arg): n = 1 c.232G > A, p.(Val78Ile): n = 1 c.395G > T, p.(Trp132Leu): n = 2 c.709G > A, p.(Gly237Arg): n = 1 c.735 T > A, p.(Cys245*): n = 1 c.861delT, p.(Arg288Glufs*14): n = 1 c.1037G > A, p.(Arg346Gln): n = 1 c.1216C > T, p.(Arg406*): n = 1 c.1511G > A, p.(Arg504Gln): n = 1 c.1717G > A, p.(Ala573Thr): n = 4 c.1762G > A, p.(Glu588Lys): n = 1 c.1819del, p.(Val607Trpfs*30): n = 1 c.1839C > G, p.(Tyr613*): n = 1 c.2014C > T, p.(Arg672*): n = 1 c.2083G > A, p.(Glu695Lys): n = 1
Protein	p.(Leu215Pro); p. (Ala573Thr)	p.(Ala573Thr); p. (Ala573Thr)	p.(Ala573Thr); p.(Ala573Thr)	c.1717G > A, p. (Ala573Thr): n = 2	compound heterozygous 14/16, homozygous 2/16
Development					
Inheritance	Compound heterozygous	Homozygous	Homozygous	Compound heterozygous 1/2, homozygous 1/2	Mild DD 1/1 Expressive language delay 1/1 18 months 1/1
Global DD	No DD	No DD	NA	No DD 2/2	
Language abilities	No speech delay	No speech delay	NA	No speech delay 2/2	
Age of walking	17 months	12 months	NA	Normal range 2/2	
Heart					
Cardiopathy	Coarctation of aorta, perimembranous VSD, small ASD and hypoplasia of the mitral valve	ALCAPA	Dilatation of the pulmonary artery, hypoplasia of left atrium, ascending aortic stenosis and unique ventricle	3/3	8/14: ALCAPA 1/14, anomalous common origin of the left common carotid artery and the right brachiocephalic artery 1/14, hypoplastic left heart 2/14, ASD 1/14, VSD 2/14, hypoplastic mitral valve 3/14, hypoplastic aortic valve 2/14, bicuspid aortic valve 2/14, hypoplastic TAA 2/14, tortuous distal TAA 1/14, absent left ventricle and pulmonary trunk 1/14, right ventricular outlet to the aorta 1/14, double outlet right ventricle, transposition of the great arteries 1/14, PDA 1/14, left aortic arch 1/14, mitral insufficiency 1/14

(Continues)

TABLE 1 (Continued)

	P1	P2	P3	Total	Literature (n = 16)
Genitourinary	Kidneys abnormalities	No	Bilateral renal agenesis,	1/3	8/16: Uni- or bilateral renal agenesis 5/16, bilateral hypoplasia 1/16, hyperchoic cortex 1/16, oligohydramnios 1/16, hydronephrosis 1/16 Unilateral ureter agenesis 1/16
	Bladder and ureteral abnormalities	No	Hypoplastic bladder	1/3	
	Genitalia abnormalities	No	Uterus agenesis, aplastic fallopian tubes, absence of genital and urinary opening	1/3	Left undescended testicle 1/16, hydrocele 1/16, inguinal hernia 1/16
Skeletal findings	Rib abnormalities	Rib synostosis T8 to T11	Small thorax, pectus excavatum	3/3	2/14: 11 Rib pairs 1/14, rib abnormalities 1/14, small thorax 1/14
	Vertebral segmentation defects	lumbar vertebral defect	Thoracic vertebral defect	3/3	14/14: Cervical 1/14, thoracic 12/14, lumbar 4/14, sacral 2/14
	Limb abnormalities	No	Radioulnar synostosis, hands and feet anomalies	2/3	6/15: Shortening and humeri and femora 2/15, fifth digit clinodactyly 1/15, bowing of lower extremities 1/15, micromelia 1/15, short proximal long bones 1/15, talipes 1/15, polydactyly 1/15
Other	Other findings	Bifid uvula, short stature	Pulmonary hypoplasia		Complete tracheal rings 1/16, asymmetry between right and left helices 1/16, sacral dimple 1/16, closed sacral dimple with tuft of hair 1/16, spina bifida 1/16, tethered cord 2/16, mucocele 1/16 hydrocephalus 1/16, pulmonary hypoplasia 1/16, polysplenia 1/16, splenomegaly 1/16, echogenic bowel 1/16, diastematomyelia 3/16, dilatation of central canal of spinal cord 1/16, multiple hepatic polycysts 1/16, maxillary sinusitis 1/16

Note: The aim of shading the last column was to differentiate our new data from the previous published ones.

Abbreviations: ALCAPA, left coronary artery from the pulmonary artery; ASD, atrial septal defect; DD, developmental delay; NA, not assessed; PDA, patent ductus arteriosus; TAA, transverse aortic arch; TOP, termination of pregnancy; VSD, ventricular septal defect.

4 | DISCUSSION

In this study, we confirm the high clinical variability in NADSYN1-Associated NAD Deficiency Disorder, by describing an extreme spectrum of presentation in the same family.

Between siblings, both a prenatal lethal form with multiple congenital malformations and a child with a mild presentation were described. No changes in environment (diet or medications) during the second pregnancy, started five years after the first one, could explain this variability.⁴ This condition, initially described as very severe with only perinatal lethal presentation,³ must now be characterized as a highly variable disorder including moderate postnatal phenotypes.

The first living patients described with NAD deficiency disorder all presented with neurodevelopmental disorder.⁵ Combining our findings with the nine cases described in Lin et al., we now confirm that pathogenic variants in NADSYN1 can be responsible for milder phenotypes, without any developmental delay, but rather congenital malformations affecting the skeleton, heart, and genitourinary tract.⁸ We found the majority of the nineteen cases described to date represents living patients (68%, 13/19), which changes the initial pejorative prognosis associated with the condition (Table 1). Unsurprisingly, the severity of the phenotype seems to be related to the number of organs affected. In our two families, none of the living cases did present a genitourinary tract defect, nor additional malformation other than skeletal and heart defects (Table 1). Our findings support the notion that vertebral organogenesis is critically dependent on NAD production: vertebral segmentation defect was present in 100% of the cases, mainly affecting the thoracic level (82%, 14/17). In contrast, only 52% of the mice model of induced NAD deficiency cases had skeletal malformations.⁷ The cardiopathy, initially always associated with the vertebral defect, was found at the end associated less often, in 65% of the cases (11/17). Genitourinary tract defects were also found in 53% of the cases (10/19). Similarly, limb anomalies were described in about half of the cases (44%, 8/18), whereas abnormal rib findings concerned only a third of them (29%, 5/17). If the patients survive beyond the neonatal period, then it is likely that no neurodevelopmental disorder will be presented (92%, 11/12). We describe here also for the first time an orofacial cleft with a bifid uvula, expanding the spectrum of phenotypic findings associated with NADSYN1.

At the molecular level, we did not identify any genotype-phenotype correlation that could explain this variability. The variants identified were in majority missense variants (70%, 16/23), but also nonsense (17%, 4/23), frameshift (8.7%, 2/23) and one variant impacting splicing (Table 1). One of the variants we identified was the recurrent missense variant c.1717G > A, p.(Ala573Thr), encountered six times in total. This variant has been previously reported, and functional analysis performed proved its pathogenicity, causing a reduction in NAD enzymatic activity.³ Its presence at the homozygous/compound heterozygous state with either another missense, frameshift, or nonsense variant in trans, can be associated with both very severe and mild phenotypes.^{3,9} No mutational hotspot has been found, but the localisation of the variants suggested they all impact

critical functional domains of NADSYN1 protein.⁸ Genome sequencing on family 2 could be done to search for a gene that could have a modifier effect on the phenotype.

Other than diet, various environmental changes and the existence of gene modifiers could be responsible for this variability, thus affecting the final NAD metabolome.^{4,10} NAD levels were shown to be decreased in patients with NAD deficiency disorders.⁴ At the same time, niacin supplementation during pregnancy prevented embryo defects caused by NAD deficiency in mice.⁴ Recommendations should be adapted during pregnancies of women at risk to have a child with a NAD deficiency disorder.

5 | CONCLUSION

These cases illustrate the large clinical heterogeneity of NADSYN1-Associated VCRL Syndrome, with high inter- and intra- familial variability.

Clinicians should consider this diagnosis when a patient presents with congenital malformations, especially when vertebral, cardiac, renal, or limb defects are present. Even if only one or few organs are affected, NAD deficiency disorder should be considered. Diagnosis can be supported by checking NAD levels in plasma, and screening for NADSYN1, KYNU, and HAAO genes if levels are low. High-dose niacin supplementation should be encouraged to prevent the recurrence of the congenital malformations in the following pregnancies.

AUTHOR CONTRIBUTIONS

Marion Aubert-Mucca: Data collection, Data analysis, Manuscript writing, Manuscript editing. Caroline Janel, Valérie Porquet-Bordes, Olivier Patat, Renaud Touraine, Thomas Edouard, Caroline Michot, Aude Tessier, Valérie Cormier-Daire, Tania Attie-Bitach: Data collection, Manuscript editing. Geneviève Baujat: Study conception, Data collection, Data analysis, Manuscript editing. All authors read and approved the final manuscript.

ACKNOWLEDGEMENTS

We acknowledge generous support from the patients and their families as well as Varun Sriram for his precious help. Part of this work was done through the France Genomic Medicine Plan 2025 (AURAGEN).

CONFLICT OF INTEREST STATEMENT

The authors declare no conflict of interest.

PEER REVIEW

The peer review history for this article is available at <https://www.webofscience.com/api/gateway/wos/peer-review/10.1111/cge.14328>.

DATA AVAILABILITY STATEMENT

Data supporting Figure 1 and Table 1 are not publicly available in order to protect patient privacy.

PATIENT CONSENT

Written consents for genetic testing and publication were obtained locally from all participants or their representatives. When included, photo consent was obtained from the patient.

ORCID

Marion Aubert-Mucca  <https://orcid.org/0000-0002-8638-2630>

Tania Attie-Bitach  <https://orcid.org/0000-0002-1155-3626>

REFERENCES

- Hara N, Yamada K, Terashima M, Osago H, Shimoyama M, Tsuchiya M. Molecular identification of human glutamine- and ammonia-dependent NAD synthetases. Carbon-nitrogen hydrolase domain confers glutamine dependency. *J Biol Chem*. 2003;278(13):10914-10921.
- Rajman L, Chwalek K, Sinclair DA. Therapeutic potential of NAD-boosting molecules: the In vivo evidence. *Cell Metab*. 2018;27(3):529-547.
- Szot JO, Campagnolo C, Cao Y, et al. Bi-allelic mutations in NADSYN1 cause multiple organ defects and expand the genotypic Spectrum of congenital NAD deficiency disorders. *Am J Hum Genet*. 2020;106(1):129-136.
- Shi H, Enriquez A, Rapadas M, et al. NAD deficiency, congenital malformations, and niacin supplementation. *N Engl J Med*. 2017;377(6):544-552.
- Szot JO, Slavotinek A, Chong K, et al. New cases that expand the genotypic and phenotypic spectrum of congenital NAD deficiency disorder. *Hum Mutat*. 2021;42:862-876.
- van de Putte R, Dworschak GC, Brosens E, et al. A Genetics-first approach revealed monogenic disorders in patients with ARM and VACTERL anomalies. *Front Pediatr*. 2020;8:310.
- Cuny H, Rapadas M, Gereis J, et al. NAD deficiency due to environmental factors or gene-environment interactions causes congenital malformations and miscarriage in mice. *Proc Natl Acad Sci U S A*. 2020;117(7):3738-3747.
- Lin J, Zhao L, Zhao S, et al. Disruptive NADSYN1 variants implicated in congenital vertebral malformations. *Genes (Basel)*. 2021;12(10):1615.
- Kortbawi H, Ames E, Pritchard A, Devine P, van Ziffle J, Slavotinek A. Further description of two patients with biallelic variants in NADSYN1 in association with cardiac and vertebral anomalies. *Am J Med Genet A*. 2022;188(8):2479-2484.
- Nikiforov A, Kulikova V, Ziegler M. The human NAD metabolome: functions, metabolism and compartmentalization. *Crit Rev Biochem Mol Biol*. 2015;50(4):284-297.

How to cite this article: Aubert-Mucca M, Janel C, Porquet-Bordes V, et al. Clinical heterogeneity of NADSYN1-associated VCRL syndrome. *Clinical Genetics*. 2023; 104(1):114-120. doi:[10.1111/cge.14328](https://doi.org/10.1111/cge.14328)