



HAL
open science

Ultrasound Applications in Ophthalmology: A Review

Sylvain Poinard, Alice Ganeau, Maxime Lafond, Oliver Dorado, Stefan Catheline, Cyril Lafon, Florent Aptel, Gilles Thuret, Philippe Gain

► **To cite this version:**

Sylvain Poinard, Alice Ganeau, Maxime Lafond, Oliver Dorado, Stefan Catheline, et al.. Ultrasound Applications in Ophthalmology: A Review. *Innovation and Research in BioMedical engineering*, 2024, 45 (2), pp.100828. 10.1016/j.irbm.2024.100828 . hal-04815662

HAL Id: hal-04815662

<https://hal.science/hal-04815662v1>

Submitted on 3 Dec 2024

HAL is a multi-disciplinary open access archive for the deposit and dissemination of scientific research documents, whether they are published or not. The documents may come from teaching and research institutions in France or abroad, or from public or private research centers.

L'archive ouverte pluridisciplinaire **HAL**, est destinée au dépôt et à la diffusion de documents scientifiques de niveau recherche, publiés ou non, émanant des établissements d'enseignement et de recherche français ou étrangers, des laboratoires publics ou privés.

Ultrasound applications in ophthalmology: a review

Sylvain POINARD^{1,2}, Alice GANEAU³, Maxime LAFOND³, Oliver DORADO^{1,2}, Stefan CATHELINE³, Cyril LAFON³, Florent APTEL⁴, Gilles THURET^{1,2}, Philippe GAIN^{1,2}

1. Laboratory Biology, Engineering and Imaging for Ophthalmology, BiiO, Health Innovation Campus, Faculty of Medicine, Jean Monnet University, Saint-Etienne, France

2. Ophthalmology Department, University Hospital, Saint-Etienne, France

3. LabTAU, INSERM, Centre Léon Bérard, Université Lyon 1, Univ Lyon, F-69003, LYON, France

4. Groupe Visis, Médipôle Elsan, Perpignan, France

Corresponding Author

Doctor Sylvain POINARD ORCID 0000-0003-3660-6541

Laboratory Biology, Engineering and Imaging for Ophthalmology (BiiO), EA 2521

Faculty of Medicine, Pole Santé Innovation

10, Rue de la Marandière

42055 Saint-Etienne Cedex 2, France.

Tel: +33 (0)4 77 12 77 93

Fax: +33 (0)4 77 12 09 95

E-mail: sylvain.poinard@univ-st-etienne.fr

Funding : Supported by The National Agency for Research ANR PRESBINNOV-US (ANR-21-CE19-0059)

1 Introduction

The level of energy and its delivery mode give ultrasound a variety of physical effects that can interact with biological tissue. From diagnosis using low intensity linear transducers to therapy using high-intensity pulsed or continuous focused ultrasound, the possibilities are vast. The anatomical characteristics of the eye require the use of fine focal spots, the minimization of heating and the consideration of eye movements in the design of devices. Ultrasound is the daily routine of the ophthalmologist with the use of ultrasonography which can be complementary to the optical clinical examination when the optical transparency of the media is lacking. Ultrasound imaging can also provide quantitative information on tissue composition (attenuation, elasticity, density...) or blood flow (Doppler effect). Ultrasound can micro-fragment the lens tissue, making cataract surgery less invasive, and performed in an outpatient basis worldwide. The selective and controlled burning of the ciliary bodies to lower the intraocular pressure of glaucoma has gained in safety, reproducibility and predictability thanks to the action of high intensity focused ultrasound (HIFU) independent of tissue pigmentation. The mechanisms of action at the origin of the biological effects are not always elucidated because they are complex and multiple. The creation of mechanical cavitations by the pulsed delivery of ultrasound opens the way to the transient rupture of biological barriers, thus increasing the penetrability of drugs. However, it remains at the stage of preclinical studies. The objective of this article is to review the diversity of ultrasound applications in ophthalmology today and tomorrow.

2 Applications

1.1 Useful anatomy for the use of ultrasound in the eye

The functional organization of the eye can be compared to that of a camera. A objective lens (cornea and crystalline lens) coupled to a diaphragm (iris) focus and adjust the quantity of photons directed on a detector (retina), the entire assembly being placed in a dark room (vitreous cavity). The visual signal is transmitted by a cable (optic nerve) to be processed by a computer (visual cortex).

The eyeball, which has an average axial length of 23 mm, is protected by a bony shell called the orbit, which determines the accessibility and geometry of ultrasound instruments. More precisely, the eye is made up of a container organized according to 3 concentric tunics and of a content with transparent properties. (Figure 1)

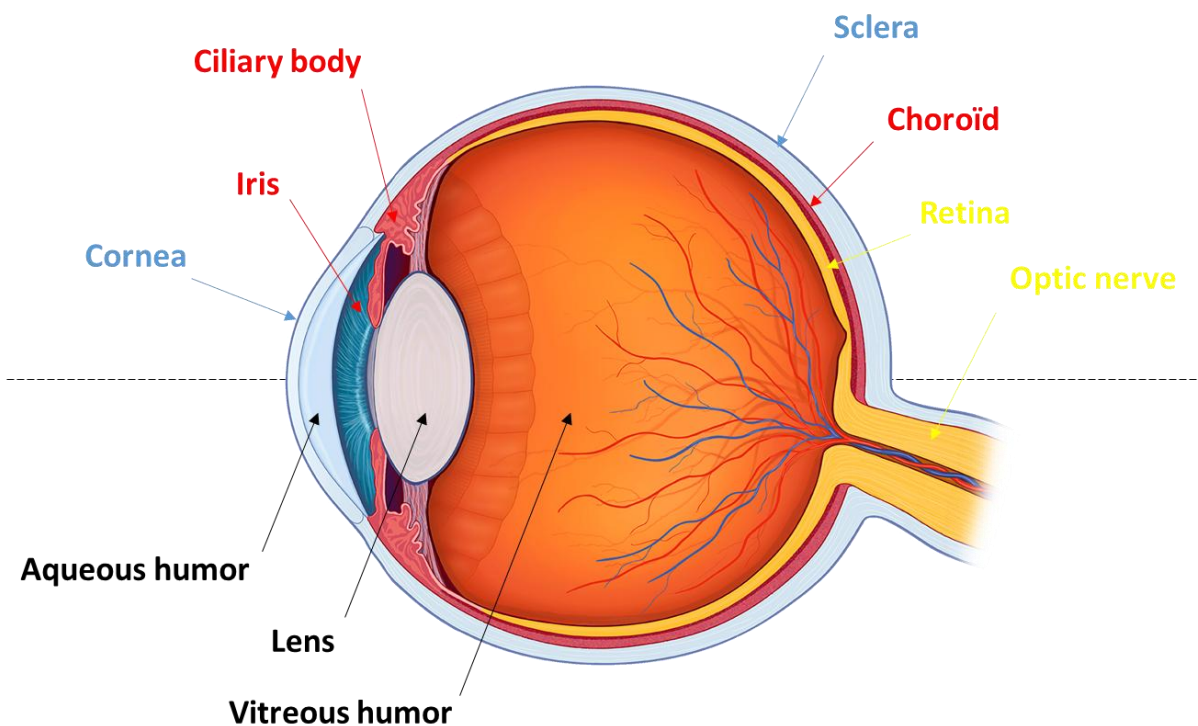


Figure 1 : Eye anatomy. External tunica corneoscleral (blue), Intermediate tunica or uvea (red), Internal tunica neurosensory (yellow), Transparent intraocular media (black).

The first tunic, the corneal shell and the sclera, forms a real framework for the globe which is directly exposed to the external environment. Thus, it acts as mechanical protection and barrier for the more internal structures. The corneal part is

rendered transparent by a complex structured organization of its collagen and the maintenance of a state of relative dehydration thanks to cellular pumps. Its refractive index and its curvature give it two thirds of the dioptric power of the eye. The second tunic, called the uvea, comprises three distinct parts arranged from front to back: the iris, the ciliary body and the choroid. These structures share the common characteristic of being highly vascularized. The choroid, located near the retina, provides direct nourishment through its extensive network of blood vessels, while the ciliary body indirectly nourishes the anterior segment by producing aqueous humor. Due to the significant vascularization of the uvea, accounting for 95% of the ocular blood flow, damage to this tissue can result in massive hemorrhage. [1] The last tunic, the deepest, is a succession of layers of precious specialized nerve cells that form the retina and which join together to form the optic nerve.

The content of the eye is liquid in its anterior part (aqueous humor) and colloidal in the form of a gel in its posterior segment (vitreous). These two compartments are separated by an asymmetrical biconvex lens with viscoelastic properties which ensures the remaining tier of the dioptric power of the eye: the crystalline lens. The deformation of the latter realizes the function of accommodation allowing to modulate the dioptric power of the eye.

Thus, the eye is composed of a succession of interfaces of different densities and ultrasound propagation speed at the origin of impedance variations. (Table 1)

Table 1 : Velocity of ultrasound in eye

Media	Speed (m/s)*	Density(g/cm ³)**
Aqueous/vitreous	1532	1.007/1.005
Cornea	1620	1.058
Lens	1641	1.098
Sclera	1630	1.077

*datas from human according to Byrne & al. [2]

**datas from bovine according to Su & al. [3] These values were measured on bovine samples but one could expect the human data to be similar. Given the very low variations between the density values compared to variations observed in speed of sound, this parameter can be fixed to ease modeling [4]

Ultrasound can be used to image the ocular apparatus. For more intense ultrasound applications (HIFU), it will be necessary to verify that the energy deposition on these interfaces is limited and does not cause thermal heating. Indeed,

the protein-rich composition of the ocular components (collagen of the corneal stroma and vitreous, crystalline lens) is at risk of thermocoagulation which can not only alter the transparency of the media but also the mechanical properties of the tissues. [5]. The Food and Drug Administration (FDA) maintains specific limits for ocular applications to ensure safety. These limits include a thermal index (TI) ≤ 1 , a spatial-peak temporal-average intensity (ISPTA) $\leq 50 \text{ mW/cm}^2$ and a mechanical index (MI) ≤ 0.23 [6].

2.1 Ultrasonography

The application of ultrasound to the eye initially originated in the diagnostic field. As early as the 1950s, Mundt and Hughes [7] reported the possibility of exploring differences in tissue density for the diagnosis of intraocular tumors or the search for foreign bodies. Initially developed in a one-dimensional A-mode, further development such as the actual image display as commonly used nowadays (B-mode) and Doppler mode which allow observing blood flow, increased the attractiveness of ultrasound in a diagnosis setting.

The frequencies used during ultrasound examinations of the eye are determined based on the specific sector being studied and the desired level of detail. However, a trade-off between resolution and depth of penetration must be considered; higher frequencies offer better resolution at the expense of greater attenuation and reduced depth of penetration (Figure 2). The high frequency ultrasound 50 MHz called "UBM" (Ultrasound Biomicroscopy) is used for the precise exploration of the iridocorneal angle/ciliary body complex like glaucoma or tumors. Conversely, to analyze the posterior segment, frequencies ranging from 10 to 20 MHz are typically necessary.

Ultrasound can overcome the limitations of optical observation methods when the ocular environment does not allow for sufficient transparency. This enables measurements of the axial length of the eye, which is crucial for calculating the cataract surgery implant. Ultrasound is also useful for examining the posterior segment and identifying potential pathologies before surgery, even when the crystalline lens is significantly opacified. In addition, ultrasound can provide valuable information on the malignant potential of tumors based on their attenuation behavior. .

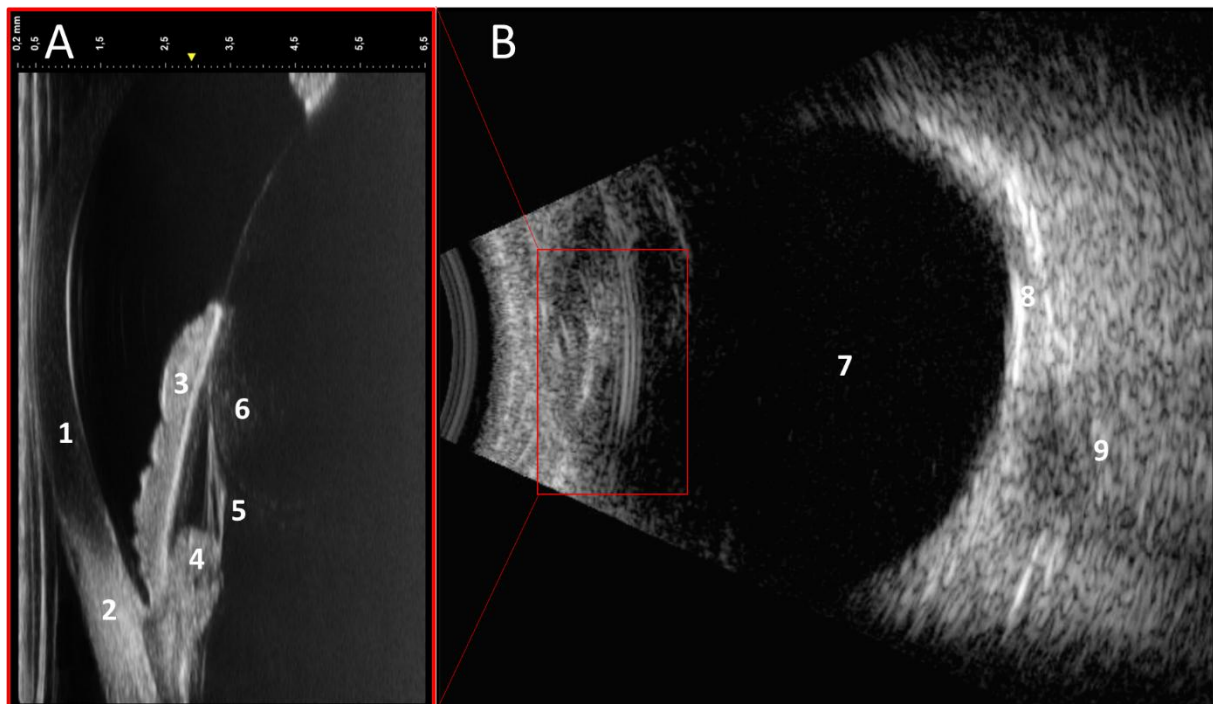


Figure 2 : A) 50 MHz, high resolution ultrasonography of anterior segment structures 1. Cornea 2. Sclera 3. Iris 4. Ciliary process 5. Zonule 6. Crystalline lens B) 10 MHz ultrasonography, observation of the posterior segment at the expense of resolution 7. Vitreous 8. scleral wall 9. Optic nerve. Note the shallow depth of penetration of the 50 MHz ultrasound limited to the area of the red frame

2.2 Phacoemulsification

The opacification of the crystalline lens or cataract, constitutes one of the first causes of curable blindness in the world [8]. Phacoemulsification is the most widely practiced surgical technique with more than 27 million operations performed each year. It consists of an intraocular fragmentation of the lens by ultrasound and its aspiration before deploying an artificial lens. The rise of this approach can be explained by the fact that before the 1980's the techniques were purely manual and required large corneal incisions over 180° to remove the lens in one piece [9] [Figure 3](#).

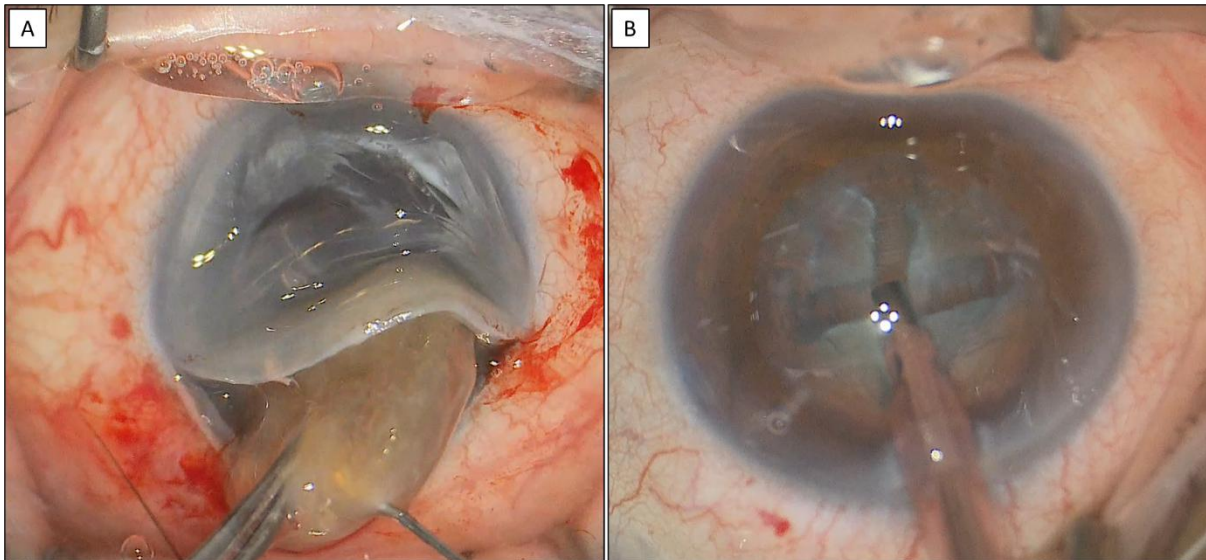


Figure 3 : A) Historical technique of manual extraction of the entire lens through a large corneal incision B) Current technique of extraction by intraocular fragmentation of the lens using ultrasound through a small 2.2 mm corneal incision

The drastic reduction in the size of the incisions, now around 2 mm, reduces the risk of complications such as expulsive hemorrhages, and capsular integrity **and allows visual acuity to be regained more quickly because there are no sutures, which are a source of astigmatism** [10]. Furthermore, the procedure can now be safely performed under **topical anesthesia (eyedrops only without needle)** on an ambulatory basis [11]. **So although the direct cost of an ultrasound procedure is more expensive than a manual procedure, the speed of recovery from phacoemulsification reduces indirect and therefore total costs for active patients** [12].

To do this, the phacoemulsification devices integrate, in addition to an ultrasound transducer, an irrigation-aspiration fluid system. The whole system is presented in the form of a "handpiece". It is a tube containing a piezoelectric crystal activated at a frequency of 28 to 45 kHz [13]. The shape of the tube is conical and ends with a tip to concentrate the ultrasound. This tip is introduced through the small corneal incision and will be in direct contact with the lens. The ultrasound delivered vibrates the tip of the instrument, generating longitudinal and transverse waves [14]. This vibration enhances the fragmentation of the lens, making it easier to remove. The tip is hollow to allow aspiration of the fragments. Additionally, a pierced sleeve is fitted to the tip to create an irrigation system to compensate for the loss of volume and ensure the fragments are directed in a directional flow. (Figure 4)

Despite having been used for several decades, the mechanisms by which ultrasound fragments the lens during phacoemulsification are still a matter of

discussion and not completely understood. The primary mechanism of action, which is generally accepted, is the "Jackhammer" effect due to the direct contact between the vibrating tip and the lens. However, there is also possibility of cavitation, especially since modern phacoemulsifiers use pulsed ultrasound in order to optimize the amount of energy delivered to the eye [15]. To minimize the risk of complications, such as burning of the corneal incision edges in contact with the tip, the performance of the transducer is crucial, especially for advanced cataract surgery that requires the use of a large amount of ultrasound [16].



Figure 4 : Phacoemulsification handpiece A. Overview with 1) Transducer within a conical tube 2) Suction tubing 3) Irrigation tubing 4) Tip B. Magnification on the hollow tip with a sleeve (purple) that disperses the irrigation flow

2.3 Glaucoma

Glaucoma refers to a group of conditions characterized by optic neuropathy resulting from the loss of specialized retinal cells known as ganglion cells. Glaucomas can be classified in several ways: acute/chronic, primary/secondary, open/closed iridocorneal angle. Regardless of their specific classification, they invariably lead to degeneration and characteristic anatomical and functional abnormalities of the optic nerve. It is the second leading cause of blindness in the world, after cataract, with the difference that the damage is irreversible [8]. Several risk factors have been identified, such as age, ethnicity, heredity, high myopia, and intraocular pressure. The latter is not only a major and proportional risk factor, but also the only therapeutic target currently available in clinical practice.

Intraocular pressure (IOP) is maintained through a delicate balance between the production and resorption of aqueous humor. This clear liquid is produced by the villosities of the ciliary body, which are arteriolar expansions lined with a bistratified epithelium: the ciliary processes. The ultrafiltration of blood plasma into aqueous

humor by these structures reaches a production of about 2.4 $\mu\text{L}/\text{min}$ and imposes the presence of resorption pathways in the inextensible ocular cavity. The trabecular pathway is the primary mode of resorption responsible for approximately 80% of aqueous humor drainage. This pathway consists of the trabeculum and Schlem's canal. The uveoscleral pathway, known as accessory, ensures the remaining 20% of fluid drainage by infiltration of the ciliary and scleral walls. [17]

Current glaucoma treatments aim to lower intraocular pressure by decreasing aqueous humor production or increasing its resorption [Table 2] :

Table 2 : Summary of current glaucoma treatments. AH = aqueous humor; SLT = selective laser trabeculoplasty; MIGS = minimally invasive glaucoma surgery; HiFU = high intensity focused ultrasound

	Decrease in AH production	Increase in AH resorption
Eye drops		
	Beta-blockers	Prostaglandins
	AlphaAgonists	
	Carbonic anhydrase inhibitor	
Lasers		
		Argon trabeculoplasty
		Argon Iridoplasty
		SLT Trabeculoplasty
	Transscleral cyclophotocoagulation with diode laser	
	Ultrasound Cyclo-Plasty (HiFU)	
Surgery		
		Sclerectomy
		MIGS implants
		Valves

The therapeutic arsenal available for glaucoma include a wide range of possibilities that are adapted based on the severity of the glaucoma. These options include eye drops, surgery, and physical agents such as lasers and ultrasound.

In the 1980s, the first use of ultrasound for the treatment of glaucoma was introduced with the Sonocare device developed by Colemann and Lizzi [18]. **It is also**

the first HIFU device approved in medicine by the FDA. Its principle is to create a coagulation necrosis of the ciliary bodies (or “cyclodestruction”) through the scleral wall in order to reduce the production of aqueous humour : the Ultrasound Cyclo-Plasty (UCP). This device consisted of a focused single-element transducer with a frequency of 4.6 MHz and a focal spot of 0.4 mm diameter and 3.0 mm length. It was used with a water-filled cone to allow proper coupling between the transducer and the eye. The assembly required precise alignment using a laser pointer for the lateral axes and a planar A-mode ultrasound transducer for the vertical axis **Figure 5**. The device was directed towards the ciliary body and moved in several zones, with the aim of creating localized thermal lesions in 4 to 6 seconds with intensities up to 4800 W/cm² to decrease the production of aqueous humor.




Figure 5 : The sonocare device adapted from [19]

Several clinical studies have been conducted with Sonocare, and these have suggested that ultrasound cyclodestruction was an effective method with favourable results between 38.4% and 83% in terms of IOP reduction [20] [21] [22] [23] [24] [25] [26]. This variability in results reflects the diversity of cases included in the studies in terms of severity or type of glaucoma and the assessment criteria used.

However, the complexity of aligning the Sonocare device prevented its widespread use, and it was not until the 2010s that ultrasound regained interest in glaucoma treatment with the introduction of a new transducer design called EyeOP1,

marketed by EyeTechCare (Rillieux-la-Pape, France) [27]. This device is composed of 6 focused 21-MHz ultrasound transducers emitting sequentially, and integrated in a circular coupling interface. Each element focuses at 10.2 mm, and measures 4.5 mm in width and 7 mm in length. The device can be placed directly on the eye and targets the ciliary body on all 360°, eliminating the problems of alignment and eye tracking. (Figure 6). However, the size of the globe can vary between individuals, especially in cases of ametropia (myopia and hyperopia), so that the device size should be adapted in order for the focal spot to keep targetting the ciliary body. In rare cases, the prominent orbital bones of certain patients can represent difficulties for the positioning the transducer.




Figure 6 : HIFU EyeOP1 cyclo-plasty device 1. 6-element circular piezoelectric transducer 2. Interface cone with the eye performing a suction and then filled with sterile water in order to decrease the impedance differences with the air and to stabilize the globe

In terms of results, unlike diode lasers, which are also used to coagulate the ciliary body through the sclera, ultrasound propagation is independent of the optical properties of the medium. Indeed, the sclera is an optically scattering medium and the inhomogeneity of the pigmentation of the ciliary epithelium leads to variability in the response of the laser-tissue interaction [28]. This can lead to dramatic side effects associated with overdosing, such as eyeball atrophy or phthisis, due to the total and definitive suppression of aqueous humor production. Ultrasound delivers energy in a more controlled way [29]. Furthermore, the EyeTechCare device has been found to have several biological mechanisms of action that contribute to reducing IOP. These mechanisms include reducing the production of aqueous humor by causing atrophy of the ciliary processes and loss of the epithelial bilayer as well as rarefaction of the vascular framework [30]. Additionally, the device has been shown to promote the drainage of aqueous humor by opening of the uveoscleral and transscleral spaces [31] [32]. Over time, three generations of the EyeTechCare device have been developed. Each generation has increased the treated surfaces by using larger transducers and more treatment zones, with the latest generation consisting of 8 zones. Clinical studies have shown that the newer generations of the device are more effective in reducing IOP, without causing additional side effects despite the higher energy delivered [33].

The UCP was first evaluated and shown to be effective as a second-line treatment for refractory glaucoma after surgery. Indications gradually expanded to include different forms of glaucoma (primary [34] [35] and secondary [36] [37]), as well as first- [38] or second-line treatment (after surgery [39] or first session of UCP [40] [41]). Future studies will have to determine more precisely the appropriate place for UCP the therapeutic arsenal compared with surgery in terms of cost effectiveness and persistence of effect over the long term.

2.4 Futures applications : Drug delivery

The presence of static barriers, such as tear film, variable lipophilicity and hydrophilicity of the corneal layers, intercellular tight junctions, and dynamic barriers, such as palpebral blink, lacrimal flow, aqueous humor renewal, vascular flow, pose significant challenges for drug bioavailability in the eye. Invasive injections into various ocular compartments (anterior chamber, subconjunctivo-tenone spaces,

vitreous cavity) offer a solution but is a source of anxiety for the patient and carry a risk of traumatic and infectious complications [42].

The modulation of ultrasound parameters (frequency, insonification duration, intensity, pulse repetition frequency) has potential for improving drug delivery by creating physical effects, notably heating and cavitations, that interact with biological tissues. Cavitation, which involves the oscillatory activity of bubbles or bubbles clouds under ultrasound, is widely studied for drug delivery. These bubbles can be injected into the human body in the form of ultrasound contrast agents, and reach the target organ through the bloodstream. Alternatively, ultrasound can directly generate bubble clouds in the target tissue by applying short, intense ultrasonic pulses, creating sufficient negative pressure (around 25 MPa [43]). Depending on the ultrasound parameters, bubbles can either maintain a state of oscillation equilibrium (stable cavitation) or collapse under the surrounding fluid's momentum when the intensities and oscillation radii are higher (inertial cavitation). Stable cavitation creates microstreaming in the surrounding fluids, shear waves, and tissue modifications[44] [45]. Bubble collapse during inertial cavitation generates shock waves and jetting towards nearby surfaces. Both mechanisms can affect tissues by involving cells, their junction systems, or the extra-cellular matrix.

Shock and shear waves can modify the cell membrane by locally rupturing of the lipid bilayer in the form of pores (sonoporation) [46]. They can also trigger the internalization of the membrane in the form of vesicles (endocytosis) via an efflux of calcium from the pores or the stimulation of mechanosensitive calcium channels. The mechanism of action on the extracellular matrix such as the collagen network that constitutes the sclera is still unclear. Indeed, although ultrasound can increase the permeability of this tissue, no histological lesions have been reported suggesting the need for additional means of observation or other mechanisms of action such as the rearrangement of proteoglycans [47] [48] [49]. The ruptures may also involve the intercellular adhesion protein systems (junctions) of the epithelia or the vascular walls (Figure 7). The prior administration of a sensitizing agent in the vessels increases the targeting of this compartment. Whatever the mode of action, the integrity of the barriers disrupted by ultrasound can be transient thanks to mechanisms of epithelial reconstitution or connective tissue remodeling. This allows for a suspensive effect of the ultrasound treatment and a reduction of the risk of side effects due to the lasting alteration of the defense mechanism constituted by the barriers.

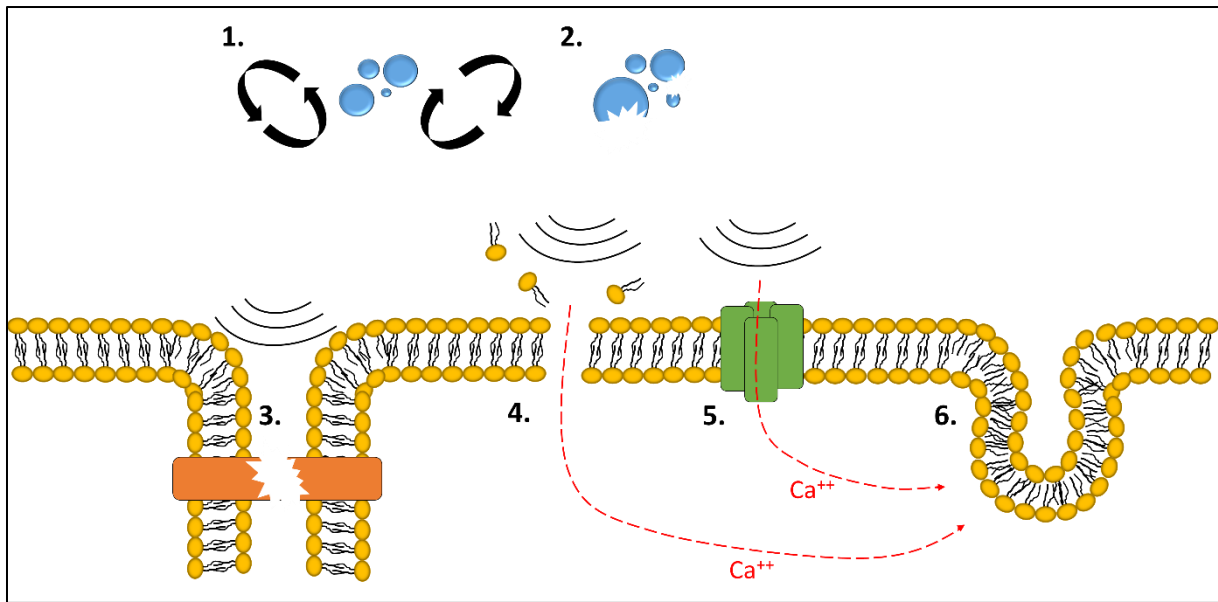


Figure 7 : Mechanisms of action of ultrasound for drug delivery 1. Stable cavitation with creation of microstreamings 2. Inertial cavitation with bubble implosion 3. Rupture of intercellular junctions 4. Creation of pores in the plasma membrane 5. Stretching of mechanosensitive calcium transport channels 6. Triggering of vesicular internalization of the membrane (endocytosis phenomenon)

The potential applications of drug delivery could be directed toward chronic pathologies that require repeated administration in priority, as they represent a compliance burden for patients and an enormous market to attract the interest of manufacturers. Glaucoma, for instance, requires daily or twice-daily administration of hypotensive eye drops to ensure satisfactory bioavailability (Table 2). The delivery of anti-infectious or anti-inflammatory agents is also being studied, albeit more anecdotally [50] [51]. Therefore, the anterior segment is the focus of research using transcorneal targeting [52] [5] [50] [53]. However, to date, there are no studies evaluating the efficacy or safety of such an application in humans, and the development stage remains in the pre-clinical field, or in vitro on cells and tissues[54] [55]. The most frequent retinal pathologies, such as venous occlusion, diabetic retinopathy, age-related macular degeneration, inflammation, are another major application of ultrasound drug delivery because the molecules used (cortisone derivatives or anti-VEGF monoclonal antibodies) cannot reach the retina other than by repeated monthly intravitreal injections. The transcleral route is one of the possible accesses for the posterior segment [56] [57] [58] [59]. However, the retina is embryologically an extension of the brain and, therefore, has a histological organization similar to the blood-brain barrier. The hemoretinal barrier is thus

composed of specialized nerve support cells (Müller cells) that isolate the retinal vessels from the rest of the tissue and make it difficult for drugs to penetrate. Proof of concept of the opening of this type of barrier has already been established for the brain in tumor applications [60] [61] or neurodegenerative diseases [62] [63] with the development of dedicated start-ups such as Carthera (Paris, France), Insightec (Tirat Carmel, Israel). Vessel targeting can be considerably improved by the prior injection of contrast agents composed of gases encapsulated by a protein, lipid or polymer envelope [64] [65].

Like the anterior segment, this research topic is still at a preclinical stage [66] [67] but a patent has recently been filed, demonstrating the interest in this topic [68].

Finally, in a more distant future, in addition to increasing the bioavailability of conventional therapy drugs that could allow to decrease the frequency of administration or to bypass invasive access routes, ultrasound can also be used as a gene therapy vector in order to repair a causal genetic defect or to allow cells to produce a drug in situ [69] [70] [71].

3 Conclusions

Ultrasound therapy in ophthalmology has gained increasing interest and is a promising area of research with potential clinical applications. The two main areas of focus are high-intensity focused ultrasound (HIFU) for the treatment of glaucoma and ultrasound drug delivery for improving the bioavailability of ocular drugs.

HIFU has advantages over laser that it can focus energy through optically opaque media like the sclera making possible a partial coagulation of the ciliary body and, consequently, of reducing intraocular pressure and the risk of glaucoma. The numerous publications on the subject show multiple mechanisms of action, reproducibility, and a favorable tolerance profile, which makes ultrasound a valuable addition to the therapeutic arsenal.

Bioavailability of ocular drugs also remains a challenge because multiple barriers of entry and tear drainage make it difficult to obtain sufficient concentration of drugs for many diseases involving the anterior and posterior segments of the eye. Whether it is the anterior wall of the eye (cornea and anterior sclera) as a route of entry for topically applied drugs and the retinal blood circulation for systemic drugs, local

delivery of ultrasound has been proposed as a means of improving drug or gene delivery and activity. While experimental studies have shown promising results, further clinical evidence is needed to confirm its efficacy and safety. Overall, ultrasound therapy shows great potential for improving the treatment of ocular diseases and warrants continued research and development.

4 References

- [1] A. Bill, « Blood circulation and fluid dynamics in the eye », *Physiological Reviews*, juill. 1975, doi: 10.1152/physrev.1975.55.3.383.
- [2] S. F. Byrne et R. L. Green, *Ultrasound of the Eye and Orbit*. Jaypee Brothers Medical Publishers Pvt. Limited, 2010. [En ligne]. Disponible sur: <https://books.google.fr/books?id=CVn3ygAACAAJ>
- [3] X. Su, C. Vesco, J. Fleming, et V. Choh, « Density of Ocular Components of the Bovine Eye », *Optometry and Vision Science*, vol. 86, n° 10, p. 1187, oct. 2009, doi: 10.1097/OPX.0b013e3181baaf4e.
- [4] M. Nabili, C. Geist, et V. Zderic, « Thermal safety of ultrasound-enhanced ocular drug delivery: A modeling study », *Med Phys*, vol. 42, n° 10, p. 5604- 5615, oct. 2015, doi: 10.1118/1.4929553.
- [5] R. Lamy *et al.*, « Ultrasound-enhanced penetration of topical riboflavin into the corneal stroma », *Invest Ophthalmol Vis Sci*, vol. 54, n° 8, p. 5908- 5912, août 2013, doi: 10.1167/iovs.13-12133.
- [6] C. for D. and R. Health, « Marketing Clearance of Diagnostic Ultrasound Systems and Transducers », U.S. Food and Drug Administration. Consulté le: 27 juin 2022. [En ligne]. Disponible sur: <https://www.fda.gov/regulatory-information/search-fda-guidance-documents/marketing-clearance-diagnostic-ultrasound-systems-and-transducers>

- [7] G. H. Mundt et W. F. Hughes, « Ultrasonics in ocular diagnosis », *Am J Ophthalmol*, vol. 41, n° 3, p. 488- 498, mars 1956, doi: 10.1016/0002-9394(56)91262-4.
- [8] GBD 2019 Blindness and Vision Impairment Collaborators et Vision Loss Expert Group of the Global Burden of Disease Study, « Trends in prevalence of blindness and distance and near vision impairment over 30 years: an analysis for the Global Burden of Disease Study », *Lancet Glob Health*, vol. 9, n° 2, p. e130- e143, févr. 2021, doi: 10.1016/S2214-109X(20)30425-3.
- [9] G. Davis, « The Evolution of Cataract Surgery », *Mo Med*, vol. 113, n° 1, p. 58- 62, 2016.
- [10] A. Li *et al.*, « Comparison of visual acuity between phacoemulsification and extracapsular cataract extraction: a systematic review and meta-analysis », *Ann Palliat Med*, vol. 11, n° 2, p. 551- 559, févr. 2022, doi: 10.21037/apm-21-3633.
- [11] E. J. Linebarger, D. R. Hardten, G. K. Shah, et R. L. Lindstrom, « Phacoemulsification and modern cataract surgery », *Surv Ophthalmol*, vol. 44, n° 2, p. 123- 147, 1999, doi: 10.1016/s0039-6257(99)00085-5.
- [12] N. Kara-Junior, M. G. G. Mazurek Sirtoli, M. R. Santhiago, T. R. R. Parede, R. F. de Espíndola, et R. de Souza Carvalho, « Phacoemulsification versus extracapsular extraction: governmental costs », *Clinics (Sao Paulo)*, vol. 65, n° 4, p. 357- 361, avr. 2010, doi: 10.1590/S1807-59322010000400002.
- [13] Zaluski, « Phacoemulsificators », in *report of the french ophthalmology society 2012 : Presbyopia*.
- [14] Y. B. Ozkurt *et al.*, « Comparison of burst, pulse, and linear modes used in phacoemulsification surgery », *Eur J Ophthalmol*, vol. 20, n° 2, p. 353- 364, 2010, doi: 10.1177/112067211002000215.
- [15] M. Packer, W. J. Fishkind, I. H. Fine, B. S. Seibel, et R. S. Hoffman, « The physics of phaco: a review », *J Cataract Refract Surg*, vol. 31, n° 2, p. 424- 431, févr. 2005, doi: 10.1016/j.jcrs.2004.11.027.
- [16] W. K. Ngo, L. W. Lim, C. S. H. Tan, et W. J. Heng, « Heat profiling of phacoemulsification tip using a thermal scanning camera », *Int Ophthalmol*, vol. 33, n° 6, p. 645- 649, déc. 2013, doi: 10.1007/s10792-013-9752-4.
- [17] C. B. Toris, M. E. Yablonski, Y.-L. Wang, et C. B. Camras, « Aqueous humor dynamics in the aging human eye », *American Journal of Ophthalmology*, vol. 127, n° 4, p. 407- 412, avr. 1999, doi: 10.1016/S0002-9394(98)00436-X.
- [18] D. J. Coleman *et al.*, « Therapeutic ultrasound in the treatment of glaucoma. II. Clinical applications », *Ophthalmology*, vol. 92, n° 3, p. 347- 353, mars 1985, doi: 10.1016/s0161-6420(85)34028-9.
- [19] J. Tavakkoli et N. Sanghvi, « Ultrasound-guided HIFU and Thermal Ablation », in *Therapeutic Ultrasound: Mechanisms to Applications*, 2011, p. 137- 161.
- [20] D. J. Coleman *et al.*, « Therapeutic Ultrasound in the Treatment of Glaucoma: II. Clinical Applications », *Ophthalmology*, vol. 92, n° 3, p. 347- 353, mars 1985, doi: 10.1016/S0161-6420(85)34028-9.
- [21] S. E. P. Burgess *et al.*, « Treatment of Glaucoma with High-Intensity Focused Ultrasound », *Ophthalmology*, vol. 93, n° 6, p. 831- 838, juin 1986, doi: 10.1016/S0161-6420(86)33672-8.
- [22] J. Haut, J. P. Colliac, L. Falque, et Y. Renard, « [Indications and results of Sonocare (ultrasound) in the treatment of ocular hypertension. A preliminary study of 395 cases] », *Ophthalmologie*, vol. 4, n° 2, p. 138- 141, 1990.
- [23] F. Valtot et P. Denis, « [The treatment of failed trabecular surgery in glaucoma with ultrasound (Sonocare)] », *Ophthalmologie*, vol. 4, n° 2, p. 142- 144, 1990.
- [24] R. H. Silverman, B. Vogelsang, M. J. Rondeau, et D. J. Coleman, « Therapeutic Ultrasound for the Treatment of Glaucoma », *American Journal of Ophthalmology*, vol. 111, n° 3, p. 327- 337, mars 1991, doi: 10.1016/S0002-9394(14)72318-9.
- [25] S. L. Maskin, A. I. Mandell, J. A. Smith, R. C. Wood, et S. A. Terry, « Therapeutic ultrasound for refractory glaucoma: a three-center study », *Ophthalmic Surg*, vol. 20, n° 3, p. 186- 192, mars 1989.
- [26] C. C. Sterk, P. H. M. v.d. Valk, C. L. M. van Hees, J. L. van Delft, J. A. van Best, et J. A. Oosterhuis, « The effect of therapeutic ultrasound on the average of multiple intraocular pressures

- throughout the day in therapy-resistant glaucoma », *Graefe's Arch Clin Exp Ophthalmol*, vol. 227, n° 1, p. 36- 38, janv. 1989, doi: 10.1007/BF02169822.
- [27] T. Charrel *et al.*, « Development of a miniaturized HIFU device for glaucoma treatment with conformal coagulation of the ciliary bodies », *Ultrasound Med Biol*, vol. 37, n° 5, p. 742- 754, mai 2011, doi: 10.1016/j.ultrasmedbio.2011.01.017.
- [28] B. Nemati, H. G. Rylander Iii, et A. J. Welch, « Optical properties of conjunctiva, sclera, and the ciliary body and their consequences for transscleral cyclophotocoagulation », *Appl Opt*, vol. 35, n° 19, p. 3321- 3327, juill. 1996, doi: 10.1364/AO.35.003321.
- [29] S. G. Ye, K. A. Harasiewicz, C. J. Pavlin, et F. S. Foster, « Ultrasound characterization of normal ocular tissue in the frequency range from 50 MHz to 100 MHz », *IEEE Transactions on Ultrasonics, Ferroelectrics, and Frequency Control*, vol. 42, n° 1, p. 8- 14, janv. 1995, doi: 10.1109/58.368319.
- [30] F. Aptel, T. Charrel, X. Palazzi, J.-Y. Chapelon, P. Denis, et C. Lafon, « Histologic effects of a new device for high-intensity focused ultrasound cyclocoagulation », *Invest Ophthalmol Vis Sci*, vol. 51, n° 10, p. 5092- 5098, oct. 2010, doi: 10.1167/iovs.09-5135.
- [31] F. Aptel *et al.*, « Short- and Long-Term Effects on the Ciliary Body and the Aqueous Outflow Pathways of High-Intensity Focused Ultrasound Cyclocoagulation », *Ultrasound in Medicine and Biology*, vol. 40, n° 9, p. 2096- 2106, sept. 2014, doi: 10.1016/j.ultrasmedbio.2014.04.017.
- [32] R. Mastropasqua, V. Fasanella, A. Mastropasqua, M. Ciancaglini, et L. Agnifili, « High-Intensity Focused Ultrasound Circular Cyclocoagulation in Glaucoma: A Step Forward for Cyclodestruction? », *Journal of Ophthalmology*, vol. 2017, 2017, doi: 10.1155/2017/7136275.
- [33] R. Jf et A. F, « Efficacy and Safety of Ultrasound Cycloplasty for Refractory Glaucoma: A 3-Year Study », *Journal of glaucoma*, vol. 30, n° 5, janv. 2021, doi: 10.1097/IJG.0000000000001796.
- [34] G. Giannaccare *et al.*, « Ultrasound Cyclo-Plasty in Patients with Glaucoma: 1-Year Results from a Multicentre Prospective Study », *Ophthalmic Res*, vol. 61, n° 3, p. 137- 142, 2019, doi: 10.1159/000487953.
- [35] C. Paul, J. Divya, S. Sengupta, R. Kamal, A. Paul, et I. Mitra, « Efficacy and safety of ultrasound cycloplasty in Indian eyes with open-angle glaucoma », *Indian J Ophthalmol*, vol. 70, n° 12, p. 4168- 4171, déc. 2022, doi: 10.4103/ijo.IJO_827_22.
- [36] Z. Longfang, H. Die, L. Jie, L. Yameng, L. Mingyuan, et P. Xiaojing, « Efficacy and safety of single Ultrasound Cyclo-Plasty to treat refractory glaucoma: Results at 1 year », *Eur J Ophthalmol*, vol. 32, n° 1, p. 268- 274, janv. 2022, doi: 10.1177/1120672120973605.
- [37] W. Ruixue, W. Tao, et L. Ning, « A Comparative Study between Ultrasound Cycloplasty and Cyclocryotherapy for the Treatment of Neovascular Glaucoma », *J Ophthalmol*, vol. 2020, p. 4016536, janv. 2020, doi: 10.1155/2020/4016536.
- [38] M. Figus *et al.*, « Ultrasound Cyclo Plasty for Treatment of Surgery-Naïve Open-Angle Glaucoma Patients: A Prospective, Multicenter, 2-Year Follow-Up Trial », *J Clin Med*, vol. 10, n° 21, p. 4982, oct. 2021, doi: 10.3390/jcm10214982.
- [39] F. A. Almobarak, A. Alrubean, W. K. Alsarhani, A. Aljenaidel, et E. Osman, « Ultrasound Cyclo Plasty After Failed Glaucoma Surgery: Outcomes and Complications », *Ophthalmol Ther*, vol. 11, n° 4, p. 1601- 1610, août 2022, doi: 10.1007/s40123-022-00538-3.
- [40] F. Aptel, M. Tadjine, et J.-F. Rouland, « Efficacy and Safety of Repeated Ultrasound Cycloplasty Procedures in Patients With Early or Delayed Failure After a First Procedure », *J Glaucoma*, vol. 29, n° 1, p. 24- 30, janv. 2020, doi: 10.1097/IJG.0000000000001400.
- [41] A. De Gregorio, E. Pedrotti, G. Stevan, M. Montali, et S. Morselli, « Safety and efficacy of multiple cyclocoagulation of ciliary bodies by high-intensity focused ultrasound in patients with glaucoma », *Graefes Arch Clin Exp Ophthalmol*, vol. 255, n° 12, p. 2429- 2435, déc. 2017, doi: 10.1007/s00417-017-3817-4.
- [42] R. Gaudana, H. K. Ananthula, A. Parenky, et A. K. Mitra, « Ocular drug delivery. », *AAPS J*, vol. 12, n° 3, p. 348- 360, sept. 2010, doi: 10.1208/s12248-010-9183-3.

- [43] A. D. Maxwell, C. A. Cain, T. L. Hall, J. B. Fowlkes, et Z. Xu, « Probability of Cavitation for Single Ultrasound Pulses Applied to Tissues and Tissue-Mimicking Materials », *Ultrasound in Medicine & Biology*, vol. 39, n° 3, p. 449- 465, mars 2013, doi: 10.1016/j.ultrasmedbio.2012.09.004.
- [44] J. Collis *et al.*, « Cavitation microstreaming and stress fields created by microbubbles », *Ultrasonics*, vol. 50, n° 2, p. 273- 279, févr. 2010, doi: 10.1016/j.ultras.2009.10.002.
- [45] W. L. Nyborg, « Ultrasonic microstreaming and related phenomena », *Br J Cancer Suppl*, vol. 5, p. 156- 160, mars 1982.
- [46] P. Marmottant et S. Hilgenfeldt, « Controlled vesicle deformation and lysis by single oscillating bubbles », *Nature*, vol. 423, n° 6936, Art. n° 6936, mai 2003, doi: 10.1038/nature01613.
- [47] W.-L. L. Suen, J. Jiang, H. S. Wong, J. Qu, et Y. Chau, « Examination of Effects of Low-Frequency Ultrasound on Scleral Permeability and Collagen Network », *Ultrasound Med Biol*, vol. 42, n° 11, p. 2650- 2661, nov. 2016, doi: 10.1016/j.ultrasmedbio.2016.07.013.
- [48] S. K. Murugappan et Y. Zhou, « Transsclera Drug Delivery by Pulsed High-Intensity Focused Ultrasound (HIFU): An Ex Vivo Study », *Curr Eye Res*, vol. 40, n° 11, p. 1172- 1180, 2015, doi: 10.3109/02713683.2014.980006.
- [49] A. Razavi *et al.*, « Contribution of inertial cavitation in the enhancement of in vitro transscleral drug delivery », *Ultrasound Med Biol*, vol. 40, n° 6, p. 1216- 1227, juin 2014, doi: 10.1016/j.ultrasmedbio.2013.12.032.
- [50] C. Allison, B. Cellum, B. Karpinecz, F. Nasrallah, et V. Zderic, « Ultrasound-Enhanced Transcorneal Drug Delivery for Treatment of Fungal Keratitis », *Cornea*, vol. 41, n° 7, p. 894- 900, juill. 2022, doi: 10.1097/ICO.0000000000002916.
- [51] M. Nabili, H. Patel, S. P. Mahesh, J. Liu, C. Geist, et V. Zderic, « Ultrasound-enhanced delivery of antibiotics and anti-inflammatory drugs into the eye », *Ultrasound Med Biol*, vol. 39, n° 4, p. 638- 646, avr. 2013, doi: 10.1016/j.ultrasmedbio.2012.11.010.
- [52] V. Zderic, J. I. Clark, R. W. Martin, et S. Vaezy, « Ultrasound-Enhanced Transcorneal Drug Delivery », *Cornea*, vol. 23, n° 8, p. 804, nov. 2004, doi: 10.1097/01.ico.0000134189.33549.cc.
- [53] M. Nabili, H. Patel, S. P. Mahesh, J. Liu, C. Geist, et V. Zderic, « Ultrasound-enhanced delivery of antibiotics and anti-inflammatory drugs into the eye », *Ultrasound Med Biol*, vol. 39, n° 4, p. 638- 646, avr. 2013, doi: 10.1016/j.ultrasmedbio.2012.11.010.
- [54] M. Lafond, F. Aptel, J.-L. Mestas, et C. Lafon, « Ultrasound-mediated ocular delivery of therapeutic agents: a review », *Expert Opin Drug Deliv*, vol. 14, n° 4, p. 539- 550, avr. 2017, doi: 10.1080/17425247.2016.1198766.
- [55] C. D. Yang, J. Jessen, et K. Y. Lin, « Ultrasound-assisted ocular drug delivery: A review of current evidence », *J Clin Ultrasound*, avr. 2022, doi: 10.1002/jcu.23214.
- [56] H. Zhang, D. Yang, J. P. Wigg, H. Unger, M. Unger, et J. G. Crowston, « Ultrasound-mediated transscleral delivery of Avastin to the posterior segment of rabbit eye in vivo », *Investigative Ophthalmology & Visual Science*, vol. 55, n° 13, p. 1804, avr. 2014.
- [57] W.-L. L. Suen, H. S. Wong, Y. Yu, L. C. M. Lau, A. C.-Y. Lo, et Y. Chau, « Ultrasound-mediated transscleral delivery of macromolecules to the posterior segment of rabbit eye in vivo », *Invest Ophthalmol Vis Sci*, vol. 54, n° 6, p. 4358- 4365, juin 2013, doi: 10.1167/iovs.13-11978.
- [58] A. C. Y. Cheung, Y. Yu, D. Tay, H. S. Wong, R. Ellis-Behnke, et Y. Chau, « Ultrasound-enhanced intrascleral delivery of protein », *Int J Pharm*, vol. 401, n° 1- 2, p. 16- 24, nov. 2010, doi: 10.1016/j.ijpharm.2010.09.001.
- [59] D. H. Geroski et H. F. Edelhauser, « Transscleral drug delivery for posterior segment disease », *Adv Drug Deliv Rev*, vol. 52, n° 1, p. 37- 48, oct. 2001, doi: 10.1016/s0169-409x(01)00193-4.
- [60] A. Sabbagh *et al.*, « Opening of the Blood-Brain Barrier Using Low-Intensity Pulsed Ultrasound Enhances Responses to Immunotherapy in Preclinical Glioma Models. », *Clin Cancer Res*, vol. 27, n° 15, p. 4325- 4337, août 2021, doi: 10.1158/1078-0432.CCR-20-3760.
- [61] A. Idbah *et al.*, « A phase I/IIa study to evaluate the safety and efficacy of blood-brain barrier (BBB) opening with the SonoCloud-9 implantable ultrasound device in recurrent glioblastoma patients receiving IV carboplatin. », *JCO*, vol. 39, n° 15_suppl, p. 2049- 2049, mai 2021, doi: 10.1200/JCO.2021.39.15_suppl.2049.

- [62] C. Gasca-Salas *et al.*, « Blood-brain barrier opening with focused ultrasound in Parkinson's disease dementia », *Nat Commun*, vol. 12, n° 1, Art. n° 1, févr. 2021, doi: 10.1038/s41467-021-21022-9.
- [63] A. Abrahao *et al.*, « First-in-human trial of blood–brain barrier opening in amyotrophic lateral sclerosis using MR-guided focused ultrasound », *Nat Commun*, vol. 10, n° 1, Art. n° 1, sept. 2019, doi: 10.1038/s41467-019-12426-9.
- [64] C. Rousou *et al.*, « Ultrasound and Microbubbles for the Treatment of Ocular Diseases: From Preclinical Research towards Clinical Application », *Pharmaceutics*, vol. 13, n° 11, p. 1782, oct. 2021, doi: 10.3390/pharmaceutics13111782.
- [65] C. Rousou *et al.*, « The Effect of Microbubble-Assisted Ultrasound on Molecular Permeability across Cell Barriers », *Pharmaceutics*, vol. 14, n° 3, Art. n° 3, mars 2022, doi: 10.3390/pharmaceutics14030494.
- [66] L. Peeters *et al.*, « Can Ultrasound Solve the Transport Barrier of the Neural Retina? », *Pharm Res*, vol. 25, n° 11, p. 2657- 2665, nov. 2008, doi: 10.1007/s11095-008-9684-2.
- [67] J. Park, Y. Zhang, N. Vykhodtseva, J. D. Akula, et N. J. McDannold, « Targeted and reversible blood-retinal barrier disruption via focused ultrasound and microbubbles », *PLoS One*, vol. 7, n° 8, p. e42754, 2012, doi: 10.1371/journal.pone.0042754.
- [68] « US Patent Application for TRANSIENT DISRUPTION OF THE BLOOD-RETINAL BARRIER OF A HUMAN AND USES THEREOF FOR TREATING A RETINA DISORDER Patent Application (Application #20200046556 issued February 13, 2020) - Justia Patents Search ». Consulté le: 26 juin 2022. [En ligne]. Disponible sur: <https://patents.justia.com/patent/20200046556>
- [69] T. Yamashita *et al.*, « A novel bubble liposome and ultrasound-mediated gene transfer to ocular surface: RC-1 cells in vitro and conjunctiva in vivo », *Exp Eye Res*, vol. 85, n° 6, p. 741- 748, déc. 2007, doi: 10.1016/j.exer.2007.08.006.
- [70] S. Sonoda *et al.*, « Gene transfer to corneal epithelium and keratocytes mediated by ultrasound with microbubbles », *Invest Ophthalmol Vis Sci*, vol. 47, n° 2, p. 558- 564, févr. 2006, doi: 10.1167/iovs.05-0889.
- [71] H. L. Li, X. Z. Zheng, H. P. Wang, F. Li, Y. Wu, et L. F. Du, « Ultrasound-targeted microbubble destruction enhances AAV-mediated gene transfection in human RPE cells in vitro and rat retina in vivo », *Gene Ther*, vol. 16, n° 9, p. 1146- 1153, sept. 2009, doi: 10.1038/gt.2009.84.