



**HAL**  
open science

## **Current and future role of HIFU in obstetric gynaecology**

Benoit De la Fournière, Manon Basso, Morgane Dairien, Cyril Huissoud, Cyril Lafon, Gil Dubernard, Marion Cortet, David Melodelima, Charles-André Philip

### ► **To cite this version:**

Benoit De la Fournière, Manon Basso, Morgane Dairien, Cyril Huissoud, Cyril Lafon, et al.. Current and future role of HIFU in obstetric gynaecology. Innovation and Research in BioMedical engineering, 2024, <10.1016/j.irbm.2023.100819>. <hal-04813540>

**HAL Id: hal-04813540**

**<https://hal.science/hal-04813540v1>**

Submitted on 2 Dec 2024

**HAL** is a multi-disciplinary open access archive for the deposit and dissemination of scientific research documents, whether they are published or not. The documents may come from teaching and research institutions in France or abroad, or from public or private research centers.

L'archive ouverte pluridisciplinaire **HAL**, est destinée au dépôt et à la diffusion de documents scientifiques de niveau recherche, publiés ou non, émanant des établissements d'enseignement et de recherche français ou étrangers, des laboratoires publics ou privés.



HAL Authorization

## Current and future role of HIFU in obstetric gynaecology

Benoit DE LA FOURNIERE<sup>1,2,3</sup>, Manon BASSO<sup>1,2,3</sup>, Morgane DAIRIEN<sup>1,2,3</sup>, Cyril HUISSOUD<sup>1,3,4</sup>, Cyril LAFON<sup>1,3</sup>, Gil DUBERNARD<sup>1,2,3</sup>, Marion CORTET<sup>1,2,3</sup>, David MELODELIMA<sup>1,3</sup>, Charles-André PHILIP<sup>1,2,3</sup>

1: LabTAU (INSERM 1032), Cours Albert Thomas Lyon, France

2: Department of Gynaecology and Obstetrics, Hôpital de la Croix-Rousse, Hospices Civils de Lyon

3: Université Claude Bernard Lyon 1, Lyon, France

4: Department of Gynaecology and Obstetrics, Hôpital Femme-Mère-Enfant, Hospices Civils de Lyon

Corresponding author: David MELODELIMA

Address: LabTau Inserm U1032, 151 Cr Albert Thomas, 69003 Lyon

Telephone: 04 72 68 19 30

## ABSTRACT

Obstetric gynaecology, as a field in which diagnostic ultrasound has quickly found its place, especially in screening for birth defects and monitoring pregnancies, is also a specialty in which therapeutic ultrasound is used extensively.

In pelvic gynaecology, HIFU therapy is used more specifically in two types of uterine conditions: fibroids and adenomyosis. In both cases, studies have shown significant efficacy in reducing pain and bleeding associated with the conditions, secondarily (more moderately but still significantly) reducing the volume of the lesions. Impact on fertility has yet to be demonstrated.

In rectosigmoid endometriosis, clinical data indicates good treatment feasibility and significant efficacy on digestive and gynaecologic pain symptoms, as well as on quality of life, with no associated severe complications. Should the efficacy of HIFU in treating endometriosis be confirmed over time, it could revolutionise the management of digestive endometriosis by offering a valid minimally invasive alternative to rectosigmoid surgery.

In senology, where visible scars have a particularly significant psychological impact, several teams have been researching the use of HIFU for the destruction of some types of breast lesions (fibroadenomas and breast tumours).

In obstetrics, HIFU could become a treatment of choice for vascular anomalies such as twin-to-twin transfusion syndrome in twin pregnancies. Promising studies are also available regarding the use of HIFU in the treatment of post-partum placenta accreta.

## INTRODUCTION

Obstetric gynaecology is a field where diagnostic ultrasound has rapidly gained significance, particularly in birth defect screening and pregnancy monitoring. Therapeutic ultrasound, especially high-intensity focused ultrasound (HIFU), plays a pivotal role in this specialty. While there are several research avenues in this field, the only validated application in our specialty is the treatment of fibroids. HIFU therapy operates through two primary mechanisms: direct thermal effects and mechanical cavitation effects. The thermal effect results from the release of ultrasound wave energy, causing localized heat accumulation through particle friction. Focused high-energy ultrasound is precisely directed at specific points to elevate temperatures locally and induce tissue coagulation. Furthermore, ultrasound can impart a mechanical impact on tissues by harnessing the phenomenon of cavitation. Robust and brief ultrasonic pulses induce the formation of bubbles, generating sufficient force to displace tissues. As these bubbles attain a critical size, they implode, generating shockwaves within tissues and releasing free radicals (refer to Figures 1 and 2). In this comprehensive review, we provide insights into the present state and the evolving role of HIFU therapy in obstetric and gynaecological practice.

### HIFU in gynaecology

#### HIFU in pelvic gynaecology

In pelvic gynaecology, HIFU therapy is used more specifically in two types of uterine conditions: fibroids and adenomyosis. It also seems promising in the management of endometriosis, another frequent condition.

#### *HIFU and uterine fibroids*

*Uterine fibroids, also known as leiomyomas, represent common benign tumors that significantly impact the quality of life for women. The prevalence of these tumors varies by ethnicity, affecting 20-30% of Caucasian women and up to 50% of Black women.(1,2) Fibroids are associated with a range of symptoms, including pelvic pain, infertility, and excessive bleeding that can lead to anemia. The management of fibroids depends on various factors, including patient preferences, age, and hormonal status. Treatment options include hormonal approaches, a range of surgical procedures from hysteroscopy to laparoscopy, and*

*in some cases, laparotomy. An alternative to surgery, particularly for women considering future pregnancy, is uterine artery embolization. A significant advancement in fibroid treatment is the use of HIFU. This non-invasive technique represents a promising first gynecological application. HIFU treatment for fibroids can be guided by magnetic resonance imaging (MRI) or ultrasound, offering increased precision and reduced side effects. The efficacy of HIFU in treating uterine fibroids is known today, with numerous publications on extracorporeal transperitoneal treatments, whether ultrasound- or MRI-guided.*

The first international publications were mostly introduced by teams using MRI-guided HIFU, from 2003. (3–5)

In the first study by Hindley *et al.* on 108 patients, 79,3% reported an improvement in symptoms and quality of life, in spite of only a moderate reduction of the average volume (13%).(4) The FDA authorised the use of HIFU with MRI control for the treatment of fibroids in 2009, especially in women with future pregnancy plans.

There were no further publications on ultrasound-guided HIFU for fibroid treatment until 2009, when more Chinese teams evidenced that the technique was equally effective, safe and well-tolerated by patients.(6,7)

Regarding the efficacy of MRI-guided HIFU at 1 year, a 2015 review reported a volume reduction rate between 9 and 30% from various studies, with 4 to 30% repeated treatments. In terms of alleviating symptoms, results from a 2011 metanalysis indicated 87.6% efficacy.(8,9) As for the efficacy of ultrasound-guided HIFU in treating fibroids, a 2013 literature review recorded between 50 and 78.9% average volume reduction at 1 year and up to 89% symptom improvement at 6 months.

Today, we have also demonstrated that the use of ultrasound to guide HIFU treatments leads to time savings compared to MRI, the average treatment length being respectively 114 and 174 minutes.(10)

Recent meta-analyses report a re-intervention rate over than 20% at 3 years. This rate is lower for UAE and myomectomy. (11) However, the quality of the studies used in these meta-analyses is mediocre, very heterogeneous, non-randomised and with groups that are

not very comparable. There is one randomised study comparing HIFU with MRI control and UAE. The re-intervention rate was higher in the HIFU group.(11)

Interestingly, a number of criteria have been identified to predict the efficacy of HIFU therapy. Fibroids with a T2 hyperintense signal, high T1 contrast (blood flow and blood volume) and/or a high permeability marker on the MRI ( $K^{trans}$ ) lead to poorer treatment results with HIFU, in terms of early loss of perfusion, distant volume reduction and efficacy on symptoms.(12) It therefore appears that the more 'cellular' cases, especially 'highly perfused' ones, are less sensitive to HIFU, probably resulting from a greater cooling effect from the blood and lesser attenuation within those fibroids. More intuitively, 'anterior', 'intramural' and 'under 5 cm' fibroids, as well as 'thinner' patients or with an 'anteverted uterus' are all criteria associated with good transperietal treatment efficacy, due to easier access.(13,14)

To compensate for hypervascularisation issues, but also for a quicker procedure and to potentiate the efficacy of HIFU on fibroids, some teams have suggested using sulphur hexafluoride microbubbles (SONOVUE®) injected intravascularly during treatment. These techniques have long been used for real-time vascularisation mapping during an ultrasound scan and help better appreciate HIFU efficacy, namely on the perfusion of the fibroid. However, by creating a strongly attenuating interface within the vessels situated in the focalisation field, these microbubbles also generate a kind of sonic wall that releases a high level of energy at the focal point or sometimes even ahead of it. The gas content in the microbubbles increases the 'thermal' effect by adding an intense local cavitation and a significant shock wave phenomenon, as described above. In spite of some valid concerns regarding these intense and uncontrollable effects, several studies (two randomised and controlled studies in particular) report reassuring results in terms of safety, and some efficacy benefits compared to the standard procedure.(15,16)

Other teams, basing themselves on the peripheral vascularisation of fibroids and the efficacy of embolization techniques, have explored a peripheral only HIFU treatment of fibroids, which main objective is its devascularisation.(17) The first reported results are relatively similar to those of conventional treatments, though with a much shorter treatment time at an average duration of only 4 minutes.(15) A 2014 study further reported that, even with

MRI mediation, HIFU therapy had a similar cost-efficacy ratio and could even be cheaper than the two reference techniques (myomectomy and uterine artery embolization). This would likely be even more pronounced with an ultrasound-guided approach. (11,18)

Certain teams are also interested in potentiating the effect of HIFU by pre-operative treatment with GnRH analogues. *Park and al.* show that a single dose prior to MRgFUS could improve treatment efficiency. A single dose of GnRH analogues could increase the non-perfused volume of fibroids even with the use of lower HIFU power (19).

Several articles show promise for the impact of HIFU on fertility. Kim et al. show that endometrial enhancement after HIFU ablation of submucosal uterine fibroids is preserved. In the meta-analysis by Liu et al, the pregnancy rate was higher in women treated with HIFU than in those treated with UAE, but it is difficult to draw conclusions from this, as pregnancy rate was only a secondary endpoint. A recent publication by Li et al shows that HIFU, in particular g-HIFU, may be an alternative fertility-sparing modality for patients with uterine fibroids over 40 years of age. HIFU can help improve pregnancy rates by increasing uterine blood flow impedance.(20–23)

**In conclusion, regarding uterine fibroids, HIFU has found its place in the treatment arsenal. It offers an alternative to surgical treatment or to uterine artery embolization that is particularly valuable to younger patients who still wish for a pregnancy. Data on pregnancies occurring after the HIFU treatment of a fibroid is reassuring, with no evidence of a higher risk of obstetrical complications such as uterine rupture or placental implantation, although these events, being rare, would require a wider dataset to evidence a statistically significant difference, if any.(24)**

#### *HIFU and uterine adenomyosis*

*Adenomyosis is a gynecological condition characterized by the infiltration of endometrial glands and/or stroma into the myometrial layer of the uterus. This pathological process triggers inflammation and a reactive hypertrophy of the myometrium, giving rise to lesions that can be localized or diffuse. Some of these lesions may manifest as pseudotumors or cystic formations, collectively termed adenomyosis. The diagnosis of adenomyosis frequently coincides with that of endometriosis, either due to a strong association, particularly in diffuse*

or 'intrinsic' forms, or because adenomyosis can be viewed as a clinical variation of deep uterine endometriosis, particularly in cases of focal 'extrinsic' lesions. Consequently, there exists a strong scientific basis for exploring the utility of High-Intensity Focused Ultrasound (HIFU) as a potential therapeutic approach for adenomyosis, with implications for evaluating its effectiveness in managing other forms of endometriosis, such as those affecting the rectosigmoid region. However, it is notable that the majority of studies investigating the efficacy and safety of HIFU in treating adenomyosis originate from China, highlighting a gap in international research collaboration and diversity in patient populations studied.

Yang *et al.* started the first clinical study on the treatment of adenomyosis lesions with HIFU (2002, published in 2009). They demonstrated the possibility to create HIFU lesions before a hysterectomy in 30 patients with focal adenomyosis, using a 20 mm diameter probe specifically manufactured by HAIFU® (Chongqing, China) to come directly into contact with the uterus.(25) Fukunishi *et al.* (2008) reported results from 20 patients with adenomyosis treated with MRI-guided HIFU, including a significant improvement of symptoms at 6 months.(26) Concurrently, Zhou *et al.* evaluated the efficacy of a transperietal treatment using ultrasound-guided HIFU in 78 adenomyosis patients with dysmenorrhea and menorrhagia. With a median follow-up of 24 months for 69 of those patients, they reported symptom improvement in 89.9% of cases (n=62).(27) A MRI scan performed on Day 1 of the study revealed that 87% of patients had coagulative necrosis lesions and 68% of patients showed a reduced perfusion ratio of the adenomyosis lesion over 50%.(27) HIFU treatment was well tolerated, with only light pain (VAS <4) and no reported serious adverse event. Comparably, a Korean team conducted a large retrospective study on 346 patients treated for adenomyosis in the same centre and showed a relief of symptoms at 12 months in almost 60% of patients, with significant improvement in overall QoL.(28) Table 1 summarises the medium- to long-term efficacy of HIFU therapy from four prospective studies, showing efficacy rates of 83% to 100% at up to 3 years.

As with uterine fibroids, several teams have explored the predictive factors of treatment efficacy. In a series of 208 patients followed for a minimum of 40 months, Liu *et al.* showed that the post-treatment ratio of non-perfused volume (NPV) and the patient's age were both correlated to the long-term efficacy of the procedure.(29) Similarly, Zhang *et al.* have shown

that patients with focal adenomyosis responded to the treatment significantly better than those with diffuse adenomyosis according to MRI results.(30)

**Table 1: Medium- to long-term efficacy on dysmenorrhea of a treatment of adenomyosis with HIFU**

Authors: year (Ref.)	Procedure	Patients	Follow-up*	Efficacy rate
Fukunishi, H. <i>et al.</i> : 2008 (26)	MRgHIFU	20	6	100%
Zhou, M. <i>et al.</i> : 2011 (27)	USgHIFU	69	24.2	89.9%
Shui, L. <i>et al.</i> : 2015 (31)	USgHIFU	203	24	82.3%
Liu, X. <i>et al.</i> : 2016 (29)	USgHIFU	208	40	83.2%

**Key:** MRgHIFU: MRI-guided HIFU; USgHIFU: ultrasound-guided HIFU / Efficacy: rate of improvement of dysmenorrhea (pre-treatment vs post-treatment VAS scores) out of all patients treated / Prospective studies only / \*in months

Regarding the treatment's safety and tolerability, most reported severe complications were cutaneous burns and neurological lesions of the sacral nerve roots (mainly resulting in sacral pain and lower limb hypoesthesia or pain), which were rather frequent.(27,28) However, with the improvement of the equipment and the expertise of practitioners, the complication rate reported in the literature seems to have significantly decreased in recent large series. For example, both Liu *et al.* and Lee *et al.* report complications in under 1% of procedures, most of which spontaneously resolve in the two weeks following treatment.(28,29) The company HAIFU® (Chongqing, China) published results from 10,310 adenomyosis patients treated with their 'JC' model between 2011 and 2015, showing an overall complication rate of 23% of all treated patients. The analysis of side effects finds pelvic pain in 22% of cases, vaginal discharge in 11% of cases and sacral pain in 6% of cases. Out of the entire series, 13 patients (0.1%) reported loss of feeling and/or pain in a lower limb, all resolving spontaneously between 2 weeks and 2 months after treatment. The most severe complications reported were 21 cutaneous burns (0.2%) and 2 digestive injuries (0.02%), the latter having required surgical treatment.(30)

To conclude on adenomyosis, whether administered with an MRI-guided or ultrasound-guided device, HIFU appears to be a safe and rather effective alternative to hysterectomy, the reference surgical treatment. As with other 'conservative' treatments for adenomyosis, such as endometrectomy or uterine artery embolization techniques, HIFU therapy shows significant though incomplete efficacy. The persistence of painful symptoms such as dysmenorrhea or dyspareunia after a full treatment of the adenomyosis, as reported in some studies, could also be linked to a lack of understanding of the pelvic endometriosis lesions that are often associated to the condition.(30) Hence, any patient treated for adenomyosis, especially if they are treatment-resistant, should be offered diagnostic testing for endometriosis.

#### *HIFU and endometriosis*

*Endometriosis is a chronic and often painful gynecological condition characterized by the ectopic presence of endometrial-like tissue outside the uterine cavity. This condition triggers inflammation, pain, and can lead to fertility issues. The diagnosis of endometriosis frequently coincides with that of adenomyosis, either due to their frequent coexistence or because adenomyosis can be viewed as a clinical variation of deep uterine endometriosis. Given the substantial overlap between these conditions, there is a strong scientific basis for exploring the potential of HIFU as a therapeutic approach for endometriosis, which could also have implications for its application in challenging anatomical locations, including the rectosigmoid.*

The first reported application of HIFU for non-uterine endometriosis regarded the treatment of abdominal wall endometriosis with ultrasound-guided HIFU. Luo *et al.* completed a retrospective study on a series of 32 patients with parietal endometriosis treated with HIFU using the JC-200 model from HAIFU® (Chongqing, China). They reported a significant reduction of the volume of lesions within 6 months of treatment compared to baseline (respectively,  $1.33 \pm 0.31$  cc vs  $2.80 \pm 0.12$  cc,  $p < 0.05$ ) and a significant improvement of pain symptoms at 6 months (post-HIFU VAS score:  $1.80 \pm 0.3$  vs  $6.80 \pm 2.64$  pre-HIFU). (32)

Similarly, Zhu *et al.* conducted a non-randomised retrospective head-to-head trial on 51 patients and reported no significant difference between ultrasound-guided HIFU and surgical treatment in terms of pain alleviation at 1-, 3-, 6- and 12-months post-treatment. There was

no residual palpable lesion with surgery, while the advantage with HIFU therapy was the absence of scarring, no bleeding, as well as a shorter length of hospitalisation.(33) Zhao *et al.* also reported comparable results in a retrospective study on 54 patients.(34)

Dubernard *et al.* have suggested using transrectal USgHIFU for the treatment of deep rectosigmoid endometriosis, mirroring a treatment option that may be offered for prostate cancer.(35) An initial phase I clinical trial on 23 patients conducted by Philip *et al.* shows an 87% feasibility rate, with significant improvement of gynaecologic and digestive symptoms as well as quality of life at 6 months, and no serious adverse effects. (36) These results point to the feasibility and potential efficacy and safety of transrectal USgHIFU in the treatment of rectal endometriosis, offering a minimally invasive alternative to surgery in this indication. A phase II study on 60 patients from the same team is currently ongoing to evaluate the efficacy and tolerability of the treatment (NCT04494568).

**Endometriosis, characterized by the presence of ectopic endometrial-like tissue, poses a complex clinical challenge that necessitates diverse management strategies. These include hormonal therapies, surgical interventions, and pain management approaches, all tailored to address the patient's unique clinical presentation. Importantly, the significant overlap between endometriosis and adenomyosis, especially in their deep and diffuse forms, underscores the scientific rationale for exploring HIFU as a potential therapeutic option for endometriosis. Investigating HIFU in the context of endometriosis may not only broaden the treatment spectrum for this complex gynecological condition but also offer insights into its applicability in managing challenging anatomical locations, including the rectosigmoid, thereby enhancing therapeutic options for patients with endometriosis.**

### HIFU in senology

*Breast cancer remains a major public health problem, as it is the most common cancer in women, with 2.3 million new cases diagnosed and 600,000 deaths expected by 2020. Despite considerable progress in early detection and conservative surgical treatment, the psychological and physical impact on patients persists. HIFU could be a promising alternative to these invasive procedures, offering the possibility of treating breast cancer without skin incision, paving the way for a less invasive and potentially more clinically and psychosocially favorable approach for patients suffering from this devastating disease. High-intensity*

*focused ultrasound (HIFU) has demonstrated notable potential in the management of breast cancer, with two main applications emerging. Ablation of isolated tumors: HIFU offers an innovative approach to the targeted destruction of breast tumors without the need for conventional surgery. The technique relies on the precise focusing of high-intensity ultrasound waves on the cancerous lesion, inducing localized thermal elevation and subsequent coagulation. This approach enables the selective eradication of tumor cells while preserving the surrounding healthy breast tissue, thus mitigating the physical and psychological impact often associated with mastectomy or lumpectomy. Combination with chemotherapy or immunotherapy: One application of HIFU lies in its potential as a synergistic therapeutic modality when combined with pharmacological treatments such as chemotherapy or immunotherapy. This combination is particularly promising due to HIFU's ability to improve tumor cell membrane permeability, thereby facilitating the entry of chemotherapeutic or immunotherapeutic agents into the tumor. In addition, the thermal effect induced by HIFU can enhance the efficacy of specific anticancer agents by facilitating their targeted release and increasing their uptake by cancer cells. This multimodal approach offers interesting prospects in the search for improved breast cancer therapies.*

As early as 2001, Hynynen *et al.* reported the efficacy and safety of treating breast fibroadenoma in 11 patients using an MRI-guided HIFU probe, with a significant reduction in size at 6 months. (37) In 2018, Hahn *et al.* performed USgHIFU on 27 cases of fibroadenoma and reported volume reduction in 89% of their patients. (38) Similarly, Peek *et al.* (2018) obtained a 43% volume reduction at 1 year in a series of 51 cases measuring an average 2.6 cm in diameter, with no severe adverse effects.(39)

Since 2005, some teams have also been evidencing the non-inferiority of HIFU in treating small-size breast cancers with a good prognosis, obtaining rates of disease-free survival of over 90%.(40,41)

An Italian study on 10 patients with localised ductal carcinoma under 2 cm, treated with HIFU prior to surgery showed a complete response rate of 90% with a 5 mm margin of undamaged cells around the targeted area.(42) In a review of 9 studies (6 with MRgHIFU [n=116] and 3 with USgHIFU [n=51]) on HIFU efficacy in invasive cancers when administered before a final surgery, results showed a 46% CRR (55/119) and very good tolerability (50%

moderate pain) with a good safety profile. Therefore, although further studies including a larger population are necessary to confirm those results, HIFU appears to be a valid alternative to surgical treatment in small-size breast cancer with a good prognosis and benign lesions such as fibroadenomas.(43)

HIFU can also play a role in potentialising the effects of chemotherapy through the activation of an antitumoral immune response, as demonstrated *in-vitro* by Fant *et al.* in 2019 (with doxorubicin) and *in-vivo* in a mouse model by Shaybani *et al.* in 2020 (with gemcitabine).(44,45) Preclinical studies have also shown a capacity to increase the efficacy of immunotherapy in some cancers, including breast cancer.(46) Focused ultrasound could also assist in the local-regional delivery of certain drugs in the breast area through the use of nanoparticles, as suggested by Kim *et al.* with albumin + doxorubicin nanoparticles in a BLAB/c Nude murine model study.(47)

**In conclusion, the applications of HIFU in senology are promising, but they remain experimental data. Additional data are necessary before considering this treatment as a non-invasive alternative to surgery.**

## HIFU and pregnancy

### HIFU and ectopic pregnancy

*Ectopic pregnancy is a medical condition characterized by the abnormal implantation and growth of a fertilized egg outside the uterine cavity, often attaching to reproductive organs such as the fallopian tubes, ovaries, or other abdominal structures. This condition poses serious complications and significant risks to maternal health when not promptly diagnosed and managed.*

Some medical teams have proposed the use of High-Intensity Focused Ultrasound (HIFU) for the management of ectopic pregnancies. Notably, this treatment option shows promise in cases involving pregnancies on a cesarean section scar. In a study conducted by Liu *and al* in 2020, comprising 225 patients randomly assigned to receive either USgHIFU prior to curettage or curettage alone (n=122), the HIFU treatment demonstrated significantly higher efficacy compared to the control group (98% vs. 91%; p<0.05). Additionally, blood loss was reduced, and no specific complications were reported.(48)

In a meta-analysis by Xiao *and al.* in 2019, which included eight studies involving 715 patients, HIFU treatment was compared with uterine artery embolization for the same indication. Patients treated with HIFU experienced less blood loss (-22mL;  $p < 0.05$ ), fewer adverse effects (OR 0.17;  $p < 0.05$ ), shorter hospitalization duration (-0.96 days;  $p < 0.05$ ), albeit with a relatively slower normalization rate of beta-human chorionic gonadotropin levels.(49)

While the majority of ectopic pregnancies (93%) occur in the fallopian tubes, the application of HIFU to this pathology remains limited, with only one published study by He *and al.* in 2011, which included 40 patients treated with USgHIFU, reporting an 82% success rate. To date, no other research teams have published data on this specific approach.(50)

No other team has published any data since.

**In conclusion, the applications of HIFU for ectopic pregnancies are promising, but they remain experimental data. Additional data are necessary before considering this treatment as a non-invasive alternative to surgery.**

#### HIFU and placenta accreta

*The occurrence of placenta accreta is linked to an abnormal invasion at the placental implantation site, most commonly associated with uterine weakening due to a prior cesarean section. The prevalence of this condition varies in studies but may reach as high as 1 case per 550 pregnancies, representing a tenfold increase over the past five decades. In cases of placenta accreta, the placenta becomes firmly adhered to the uterine muscle, rendering it inseparable from the uterine cavity.(51,52) (53) Any attempt to remove the placenta carries a high risk of hemorrhage, with an elevated likelihood of immediate hysterectomy if the accretion is not pre-known. Notably, this condition poses a substantial maternal mortality risk, estimated at 7%.(54) Current management options for placenta accreta encompass two primary approaches: radical treatment through hysterectomy, leading to permanent sterility, and conservative treatment, involving the retention of the placenta until complete resorption. An attitude of uterine conservation should be offered to patients desiring to avoid permanent sterility through hysterectomy. Conservative management entails performing a cesarean section at the uterine fundus, rather than at its lower segment, before labor onset, while leaving the placenta in situ. However, this strategy presents challenges, often involving*

*prolonged and highly discomforting experiences for the patient, characterized by pain and the potential for hemorrhagic and infectious complications. This comprehensive overview underscores the intricate nature of placenta accreta, emphasizing the significance of appropriate management decisions in safeguarding maternal health and fertility. Further research is warranted to explore improved strategies for the management of this challenging obstetric condition.*(55)

In this context, HIFU may offer the potential to expedite conservative treatment while reducing the risk-laden latency phase for patients. Notably, all available studies regarding HIFU application after conservative treatment have been conducted in China. Among these, three are retrospective studies, and one is a prospective study.(51,52,56) (53) The latter exclusively enrolled women who delivered naturally, excluding placentas exceeding a specific size threshold (half the uterine cavity), which raises concerns about the accuracy of the diagnosis.(56)

In all these studies, the duration of sonication ranged from 200 to 2,500 seconds, and HIFU therapy was complemented with uterine aspiration and curettage or hysteroscopic resection to eliminate necrotic tissue. Following HIFU treatment, ultrasound scans consistently demonstrated a significant reduction in placenta mass size and vascularization, accompanied by marked reductions in MRI signal intensity and enhancement levels. The resumption of menstruation occurred, on average, after 48.8 days. Importantly, no severe complications were reported in any of the studies, and the majority of patients reported minimal or no pain during or after the procedure. (51,52,56) (53)

A comprehensive 2020 review conducted by Abd Elazeem *and al.*, comprising 63 studies comparing various treatment approaches for post-partum placenta accreta, reported a 100% success rate for HIFU therapy in cases of partial placenta retention, positioning it as the superior strategy compared to uterine artery embolization, preoperative prophylactic placement of an internal iliac/aortic balloon, uterine ligature, or no treatment.(57)

Similarly, a 2020 cohort study by Jiang et al. compared 63 patients treated with HIFU to 31 patients treated with uterine artery embolization and hysteroscopic resection, yielding comparable results in terms of efficacy and safety while hinting at potential benefits for fertility preservation.(58)

However, certain limitations inherent in the existing studies should be duly acknowledged. Notably, these studies predominantly enrolled patients with partial placental retention and without any indications of bleeding or infection, which are the primary complications associated with conservative approaches. Additionally, it is worth highlighting that the only prospective study exclusively focused on patients who underwent natural childbirth, a departure from the conventional diagnosis of placenta accreta, which typically arises in the context of cesarean sections. This raises questions regarding the accuracy of the initial ultrasound diagnosis and, indeed, the existence of the pathology itself. Conversely, a notable challenge exists when dealing with a completely retained placenta following a conservative approach, as there are currently no established treatments for this scenario. (59)

Furthermore, we would like to draw attention to an ongoing French study conducted at our center, which aims to assess the feasibility and efficacy of employing a toroidal conductivity sensor to expedite the resorption of a fully retained placenta (ClinicalTrials.gov Identifier: NCT04003428).

**In conclusion, the outcomes achieved through High-Intensity Focused Ultrasound (HIFU) therapy have offered significant hope and assurance to patients striving to preserve their fertility. HIFU represents a precise treatment modality that mitigates collateral tissue damage, expedites placental elimination, and facilitates the restoration of normal uterine function. Nevertheless, it is imperative to acknowledge that these findings are experimental in nature, and further rigorous clinical trials are essential before contemplating its transition into routine clinical practice.**

#### [HIFU in monochorionic twin pregnancies](#)

*Within the context of monochorionic pregnancies, wherein twins share a common placenta, an inevitable commingling of circulatory fluids occurs through anastomotic connections within the vascular network. In approximately 15% of instances, these anastomoses assume a pathological character, resulting in an unbalanced transfer of vascular resources between the twins. This clinical entity is referred to as twin-to-twin transfusion syndrome (TTTS), and it stands as the preeminent etiological factor contributing to mortality and morbidity in the realm of twin gestations.(60) The TTTS accounts for 12% of deaths and 17% of neonatal pathologies occurring in all twin pregnancies.(61). In the presence of TTTS, one of the fetuses*

*experiences an excessive accretion of resources, leading to disproportionate fetal growth, while its counterpart endures the converse predicament of growth restriction.* The reference treatment is a surgical approach with fetoscopy, an invasive approach aiming to destroy only superficial vascular anomalies *in utero* using a laser *characterized by the insertion of a fetoscope equipped with a laser apparatus into the amniotic cavity.* (62) *The paramount objective during this procedure is to effectuate laser coagulation of anastomotic vessels, which should be performed judiciously so as to obviate traversing the placental structure. Regrettably, the feasibility of this intervention is notably compromised when the placenta assumes an anterior disposition. Furthermore, the scope of the intervention is confined to addressing superficial chorionic anastomoses exclusively. The invasive nature of fetoscopic laser ablation bespeaks a concomitant heightened risk profile, notably encompassing the peril of inadvertent rupture of the amniotic cavity and resultant fetal demise.* (63) *Regrettably, the overall survival rate for both fetuses following this intervention stands at a regrettable sub-60% threshold. The depth of anastomoses limits the benefit of a laser treatment as it can only reach superficial vessels,*(64) *and residual anastomoses can remain, with a persistence of the TTTS or TAPS (twin anaemia polycythaemia sequence),*(65) *an associated condition occurring frequently after a laser treatment (11 to 13% of cases).*

The first studies regarding the application of HIFU in foetal medicine are only recent. Peak *et al.* have evidenced the possibility of obtaining *in vivo* tissue necrosis in foetal tissues such as the liver, lungs, kidneys and heart.(66) A study on pregnant rabbits by Ichizuka *et al.* has shown coagulation results on the intra-abdominal portion of the umbilical cord.(67)

Kim *et al.* assessed tissue necrosis capability with HIFU based on a pregnant ewe. Cavitation lesions in the foetus were obtained with a focalised transducer in 60% of cases.(68) These are promising first studies, paving the way to *in utero* therapeutic applications, but research remains insufficient. HIFU therapy applications in foetal or maternal pathologies are limited, namely, by factors such as lesions size and focal distance. Additionally, the experimental models studied cannot be extrapolated to a human population, due to how the size of the uterus, its location, its shape and its position within the cavity can differ from human anatomy. A clinical study initiated by Okai *et al.* in 2013 explored the possibility of inducing a selective reduction of the pregnancy using HIFU therapy administered with a spherical transducer. Successive insonifications were performed on the umbilical cord of an acardiac

twin to stop the blood flow through the cord to this acardiac twin.(69) The study resulted in a healthy birth for the other twin. The same team published in 2019 a series of six cases of TRAP, five of which were treated before 16 weeks of amenorrhea using the same procedure. Success rate was 83%, with 63% live births.(70)

Applications to the placenta, especially with an anterior placement of the latter, seem novel.

Our team was the first to evidence the feasibility and safety of both *ex-vivo* and *in-vivo* HIFU treatment using a simian model for TTTS syndrome. After performing 13 HIFU procedures, five placenta lesions were observed; average diameters were  $6.4 \pm 0.5$  mm and  $7.8 \pm 0.7$  mm and average depth was  $3.8 \pm 1.5$  mm.

Shaw *et al.* further highlighted the effect of distant HIFU in extending foetal recovery and maintaining normal foetal physiology.(71) They randomised 12 ewes at 116 days of gestation between a HIFU group and a control group. Vascular occlusion of the placenta with HIFU mediation was performed through the mother's intact skin. Maternal and foetal wellbeing was then monitored for 20 days. Placenta vessels were occluded following HIFU administration in 100% of cases (36/36) and occlusion continued for 20 days. All foetuses survived, and no difference in clinical parameters was observed between the two groups. However, HIFU treatment resulted in burns on the uterus and foetus. This procedure is a novel alternative to surgery and allows for a highly selective vascular obstruction on all pathological placental anastomoses without breaking the skin. It removes the risks associated with surgery while offering an effective treatment, especially through its action on deeper blood vessels. As such, HIFU could be the treatment strategy of the future, given its safety (no breach in skin nor amniotic cavity) and its ability to induce a degree of destruction in a controlled area. We are currently exploring the possibility of placental bichorionisation through the juxtaposition of HIFU lesions in an animal *in-vivo* study, which has never been evidenced so far.

**In conclusion, the applications of HIFU for TTTS are promising, but they remain experimental data. Additional data are necessary before considering this treatment as a non-invasive alternative to surgery.**

## CONCLUSION

Offering the possibility of a thermal and mechanical destruction of deep lesions that leaves nearby tissues unaffected, HIFU therapy is a minimally invasive alternative to surgery that has gathered interest in several medical fields, namely oncology. Promising research also support its use in obstetrics for conditions associated with monochorionic twin pregnancies.

In senology, HIFU is already a valid alternative to the surgical treatment of adenofibromas, and several sets of preclinical and clinical data also suggest its future therapeutic potential in the management of invasive breast cancer.

HIFU also has its place in gynaecology as an already widespread treatment for uterine fibroids, with worldwide publications reporting their efficacy and safety. Lastly, with promising efficacy in treating adenomyosis and parietal endometriosis, which histology and pathophysiological mechanisms are closely related to those of deep endometriosis, HIFU therapy is a serious emerging treatment option for rectosigmoid endometriosis. The first clinical results in this indication are extremely positive.

## REFERENCES

1. Day Baird D, Dunson DB, Hill MC, Cousins D, Schectman JM. High cumulative incidence of uterine leiomyoma in black and white women: Ultrasound evidence. *Am J Obstet Gynecol.* janv 2003;188(1):100- 7.
2. Marsh EE, Ekpo GE, Cardozo ER, Brocks M, Dune T, Cohen LS. Racial differences in fibroid prevalence and ultrasound findings in asymptomatic young women (18–30 years old): a pilot study. *Fertil Steril.* juin 2013;99(7):1951- 7.
3. Tempany CMC, Stewart EA, McDannold N, Quade BJ, Jolesz FA, Hynynen K. MR Imaging–guided Focused Ultrasound Surgery of Uterine Leiomyomas: A Feasibility Study. *Radiology.* mars 2003;226(3):897- 905.
4. Hindley J, Gedroyc WM, Regan L, Stewart E, Tempany C, Hynnen K, et al. MRI Guidance of Focused Ultrasound Therapy of Uterine Fibroids: Early Results. *Am J Roentgenol.* déc 2004;183(6):1713- 9.
5. Stewart EA, Rabinovici J, Tempany CMC, Inbar Y, Regan L, Gastout B, et al. Clinical outcomes of focused ultrasound surgery for the treatment of uterine fibroids. *Fertil Steril.* janv 2006;85(1):22- 9.
6. Ren XL, Zhou XD, Yan RL, Liu D, Zhang J, He GB, et al. Sonographically Guided Extracorporeal Ablation of Uterine Fibroids With High-Intensity Focused Ultrasound: Midterm Results. *J Ultrasound Med.* janv 2009;28(1):100- 3.
7. Wang W, Wang Y, Wang T, Wang J, Wang L, Tang J. Safety and efficacy of US-guided high-intensity focused ultrasound for treatment of submucosal fibroids. *Eur Radiol.* nov 2012;22(11):2553- 8.
8. Pron G. Magnetic Resonance–Guided High-Intensity Focused Ultrasound (MRgHIFU) Treatment of Symptomatic Uterine Fibroids: An Evidence–Based Analysis. 2015;15(4).
9. Gorny KR, Woodrum DA, Brown DL, Henrichsen TL, Weaver AL, Amrami KK, et al. Magnetic Resonance–guided Focused Ultrasound of Uterine Leiomyomas: Review of a 12-month Outcome of 130 Clinical Patients. *J Vasc Interv Radiol.* juin 2011;22(6):857- 64.
10. Wang Y, Wang ZB, Xu YH. Efficacy, Efficiency, and Safety of Magnetic Resonance-Guided High-Intensity Focused Ultrasound for Ablation of Uterine Fibroids: Comparison with Ultrasound-Guided Method. *Korean J Radiol.* 2018;19(4):724.
11. Laughlin-Tommaso S, Barnard EP, AbdElmagied AM, Vaughan LE, Weaver AL, Hesley GK, et al. FIRSST study: randomized controlled trial of uterine artery embolization vs focused ultrasound surgery. *Am J Obstet Gynecol.* févr 2019;220(2):174.e1-174.e13.
12. Cheng H, Wang C, Tian J. Correlation between magnetic resonance imaging features of uterine fibroids and therapeutic effects of high-intensity focused ultrasound ablation. *Pak J Med Sci [Internet].* 31 déc 1969 [cité 27 nov 2023];31(4). Disponible sur: <http://pjms.com.pk/index.php/pjms/article/view/7294>

13. Fan HJ, Zhang C, Lei HT, Cun JP, Zhao W, Huang JQ, et al. Ultrasound-guided high-intensity focused ultrasound in the treatment of uterine fibroids. *Medicine (Baltimore)*. mars 2019;98(10):e14566.
14. Zhang W, He M, Huang G, He J. A comparison of ultrasound-guided high intensity focused ultrasound for the treatment of uterine fibroids in patients with an anteverted uterus and a retroverted uterus. *Int J Hyperthermia*. 17 août 2016;32(6):623- 9.
15. Orsi F, Monfardini L, Bonomo G, Krokidis M, Della Vigna P, Disalvatore D. Ultrasound guided high intensity focused ultrasound (USgHIFU) ablation for uterine fibroids: Do we need the microbubbles? *Int J Hyperthermia*. 3 avr 2015;31(3):233- 9.
16. Chen Y, Jiang J, Zeng Y, Tian X, Zhang M, Wu H, et al. Effects of a microbubble ultrasound contrast agent on high-intensity focused ultrasound for uterine fibroids: a randomised controlled trial. *Int J Hyperthermia*. 17 nov 2018;34(8):1311- 5.
17. Parsons JE, Lau MPH, Martin PJ, Islas Lagos JJ, Aguilar Aguirre JM, Garza Leal JG. Pilot Study of the Mirabilis System Prototype for Rapid Noninvasive Uterine Myoma Treatment Using an Ultrasound-Guided Volumetric Shell Ablation Technique. *J Minim Invasive Gynecol*. mai 2017;24(4):579- 91.
18. Cain-Nielsen AH, Moriarty JP, Stewart EA, Borah BJ. Cost-effectiveness of uterine-preserving procedures for the treatment of uterine fibroid symptoms in the USA. *J Comp Eff Res*. sept 2014;3(5):503- 14.
19. Park H, Yoon SW. Efficacy of single-dose gonadotropin-releasing hormone agonist administration prior to magnetic resonance-guided focused ultrasound surgery for symptomatic uterine fibroids. *Radiol Med (Torino)*. août 2017;122(8):611- 6.
20. Bohlmann M, Hoellen F, Hunold P, David M. High-Intensity Focused Ultrasound Ablation of Uterine Fibroids – Potential Impact on Fertility and Pregnancy Outcome. *Geburtshilfe Frauenheilkd*. 4 mars 2014;74(02):139- 45.
21. Kim Y sun, Kim TJ, Lim HK, Rhim H, Jung SH, Ahn JH, et al. Preservation of the endometrial enhancement after magnetic resonance imaging-guided high-intensity focused ultrasound ablation of submucosal uterine fibroids. *Eur Radiol*. sept 2017;27(9):3956- 65.
22. Liu L, Wang T, Lei B. Uterine Artery Embolization Compared with High-intensity Focused Ultrasound Ablation for the Treatment of Symptomatic Uterine Myomas: A Systematic Review and Meta-analysis. *J Minim Invasive Gynecol*. févr 2021;28(2):218- 27.
23. Li F, Chen J, Yin L, Zeng D, Wang L, Tao H, et al. HIFU as an alternative modality for patients with uterine fibroids who require fertility-sparing treatment. *Int J Hyperthermia*. 31 déc 2023;40(1):2155077.
24. Cheung VYT. High-intensity focused ultrasound therapy. *Best Pract Res Clin Obstet Gynaecol*. janv 2018;46:74- 83.

25. Yang Z, Cao YD, Hu LN, Wang ZB. Feasibility of laparoscopic high-intensity focused ultrasound treatment for patients with uterine localized adenomyosis. *Fertil Steril.* juin 2009;91(6):2338- 43.
26. Fukunishi H, Funaki K, Sawada K, Yamaguchi K, Maeda T, Kaji Y. Early Results of Magnetic Resonance-guided Focused Ultrasound Surgery of Adenomyosis: Analysis of 20 Cases. *J Minim Invasive Gynecol.* sept 2008;15(5):571- 9.
27. Zhou M, Chen JY, Tang LD, Chen WZ, Wang ZB. Ultrasound-guided high-intensity focused ultrasound ablation for adenomyosis: the clinical experience of a single center. *Fertil Steril.* mars 2011;95(3):900- 5.
28. Lee JS, Hong GY, Park BJ, Kim TE. Ultrasound-guided high-intensity focused ultrasound treatment for uterine fibroid & adenomyosis: A single center experience from the Republic of Korea. *Ultrason Sonochem.* nov 2015;27:682- 7.
29. Liu X, Wang W, Wang Y, Wang Y, Li Q, Tang J. Clinical Predictors of Long-term Success in Ultrasound-guided High-intensity Focused Ultrasound Ablation Treatment for Adenomyosis: A Retrospective Study. *Medicine (Baltimore).* janv 2016;95(3):e2443.
30. Zhang L, Rao F, Setzen R. High intensity focused ultrasound for the treatment of adenomyosis: selection criteria, efficacy, safety and fertility. *Acta Obstet Gynecol Scand.* juin 2017;96(6):707- 14.
31. Shui L. High-intensity focused ultrasound (HIFU) for adenomyosis: Two-year follow-up results. *Ultrason Sonochem.* 2015;
32. Luo S, Zhang C, Huang JP, Huang GH, He J. Ultrasound-guided high-intensity focused ultrasound treatment for abdominal wall endometriosis: a retrospective study. *BJOG : an international journal of obstetrics and gynaecology* 2017; 124 Suppl 3: 59-63.
33. Zhu X, Chen L, Deng X, Xiao S, Ye M, Xue M. A comparison between high-intensity focused ultrasound and surgical treatment for the management of abdominal wall endometriosis. *BJOG : an international journal of obstetrics and gynaecology* 2017; 124 Suppl 3: 53-58.
34. Zhao L, Deng Y, Wei Q, Chen J, Zhao C. Comparison of ultrasound-guided high-intensity focused ultrasound ablation and surgery for abdominal wall endometriosis. *Int J Hyperthermia.* 31 déc 2018;35(1):528- 33.
35. Transrectal high-intensity focused ultrasound as focal therapy for posterior deep infiltrating endometriosis G Dubernard 1 2, A Gelet 2 3, C Lafon 2, N Guillen 4, F Chavrier 2, J-Y Chapelon 2, C Huissoud 1 2, C-A Philip 1 2.
36. Philip C -A., Warembourg S, Dairien M, Lefevre C, Gelet A, Chavrier F, et al. Transrectal high-intensity focused ultrasound ( HIFU ) for management of rectosigmoid deep infiltrating endometriosis: results of PHASE-I clinical trial. *Ultrasound Obstet Gynecol.* sept 2020;56(3):431- 42.

37. Hynynen K, Pomeroy O, Smith DN, Huber PE, McDannold NJ, Kettenbach J, et al. MR Imaging-guided Focused Ultrasound Surgery of Fibroadenomas in the Breast: A Feasibility Study. *Radiology*. avr 2001;219(1):176- 85.
38. Hahn M, Fugunt R, Schoenfish B, Oberlechner E, Gruber IV, Hoopmann U, et al. High intensity focused ultrasound (HIFU) for the treatment of symptomatic breast fibroadenoma. *Int J Hyperthermia*. 31 déc 2018;35(1):463- 70.
39. Peek MCL, Ahmed M, Scudder J, Baker R, Charalampoudis P, Pinder SE, et al. High-intensity focused ultrasound in the treatment of breast fibroadenomata (HIFU-F trial). *Int J Hyperthermia*. 3 oct 2018;34(7):1002- 9.
40. Wu F, Wang ZB, Zhu H, Chen WZ, Zou JZ, Bai J, et al. Extracorporeal high intensity focused ultrasound treatment for patients with breast cancer. *Breast Cancer Res Treat*. juill 2005;92(1):51- 60.
41. Furusawa H, Namba K, Nakahara H, Tanaka C, Yasuda Y, Hirabara E, et al. The evolving non-surgical ablation of breast cancer: Mr Guided focused ultrasound (MRgFUS). *Breast Cancer*. janv 2007;14(1):55- 8.
42. Napoli A, Anzidei M, Ciolina F, Marotta E, Cavallo Marincola B, Brchetti G, et al. MR-Guided High-Intensity Focused Ultrasound: Current Status of an Emerging Technology. *Cardiovasc Intervent Radiol*. oct 2013;36(5):1190- 203.
43. Maloney E, Hwang JH. Emerging HIFU applications in cancer therapy. *Int J Hyperthermia*. 3 avr 2015;31(3):302- 9.
44. Fant C, Lafond M, Rogez B, Castellanos IS, Ngo J, Mestas JL, et al. In vitro potentiation of doxorubicin by unseeded controlled non-inertial ultrasound cavitation. *Sci Rep*. 30 oct 2019;9(1):15581.
45. Sheybani ND, Witter AR, Thim EA, Yagita H, Bullock TNJ, Price RJ. Combination of thermally ablative focused ultrasound with gemcitabine controls breast cancer via adaptive immunity. *Open Access*.
46. Abe S, Nagata H, Crosby EJ, Inoue Y, Kaneko K, Liu CX, et al. Combination of ultrasound-based mechanical disruption of tumor with immune checkpoint blockade modifies tumor microenvironment and augments systemic antitumor immunity. *J Immunother Cancer*. janv 2022;10(1):e003717.
47. Kim D, Lee SS, Yoo WY, Moon H, Cho A, Park SY, et al. Combination Therapy with Doxorubicin-Loaded Reduced Albumin Nanoparticles and Focused Ultrasound in Mouse Breast Cancer Xenografts. *Pharmaceutics*. 7 sept 2020;13(9):235.
48. Liu CN, Tang L, Sun Y, Liu YH, Yu HJ. Clinical outcome of high-intensity focused ultrasound as the preoperative management of cesarean scar pregnancy. *Taiwan J Obstet Gynecol*. mai 2020;59(3):387- 91.

49. Xiao X, Feng Z, Li T, Yi B, Zhang S, Wang W. Comparing the Efficacy and Safety of High-Intensity Focused Ultrasound and Uterine Artery Embolization in Caesarean Scar Pregnancy: A Meta-analysis. *Adv Ther.* juin 2019;36(6):1314- 25.
50. He GB, Luo W, Zhou XD, Liu LW, Yu M, Ma XD. A preliminary clinical study on high-intensity focused ultrasound therapy for tubal pregnancy. *Scott Med J.* nov 2011;56(4):214- 9.
51. Bai Y, Luo X, Li Q, Yin N, Fu X, Zhang H, Qi H. High-intensity focused ultrasound treatment of placenta accreta after vaginal delivery: a preliminary study. *Ultrasound Obstet Gynecol* 2016; 47: 492-498.
52. Jiang X, Tang Q, Yang B, Ye F, Cai L, Wang X, et al. High-intensity focused ultrasound combined procedures treatment of retained placenta accreta with marked vascularity after abortion or delivery. *Int J Hyperthermia.* 1 janv 2019;36(1):420- 6.
53. Ye M, Yin Z, Xue M, Deng X. High-intensity focused ultrasound combined with hysteroscopic resection for the treatment of placenta accreta. *BJOG : an international journal of obstetrics and gynaecology* 2017; 124 Suppl 3: 71-77.
54. Khong TY, Robertson WB. Placenta creta and placenta praevia creta. *Placenta* 1987; 8: 399-409.
55. Kayem G, Deneux-Tharaux C, Sentilhes L, The PACCRETA group. PACCRETA : Clinical situations at high risk of Placenta ACCRETA /Percreta: impact of diagnostic methods and management on maternal morbidity. *Acta Obstet Gynecol Scand.* avr 2013;92(4):476- 82.
56. Liu Y, Zhang WW, He M, Gong C, Xie B, Wen X, et al. Adverse effect analysis of high-intensity focused ultrasound in the treatment of benign uterine diseases. *Int J Hyperthermia.* 31 déc 2018;35(1):56- 61.
57. Abd Elazeem HAS, Saad MM, Ahmed IA, Sayed EG, AlMahdy AM, Atef F, Ellassall GM, Ashraf Salah M, Ali AK, Ragab EY, Shazly SA. High-intensity focused ultrasound in management of placenta accreta spectrum: A systematic review. *Int J Gynaecol Obstet* 2020; 151: 325-332.
58. Jiang J, Wang C, Xue M. High-intensity focused ultrasound versus uterine artery embolization for patients with retained placenta accreta. *Eur J Obstet Gynecol Reprod Biol.* sept 2020;252:82- 6.
59. Obstetricians ACo, Gynecologists. ACOG committee opinion no. 266, January 2002: placenta accreta. *Obstet Gynecol* 2002; 99: 169-170.
60. Sebire NJ, Snijders RJM, Hughes K, Sepulveda W, Nicolaidis KH. The hidden mortality of monochorionic twin pregnancies. *BJOG Int J Obstet Gynaecol.* oct 1997;104(10):1203- 7.
61. Fisk NM, Duncombe GJ, Sullivan MHF. The Basic and Clinical Science of Twin–Twin Transfusion Syndrome. *Placenta.* mai 2009;30(5):379- 90.

62. Marie-Victoire S, Jan D, Michel B, Alain P, Norbert W, Yves V. Endoscopic Laser Surgery versus Serial Amnioreduction for Severe Twin-to-Twin Transfusion Syndrome. *N Engl J Med.* 2004;
63. Caloone J, Huissoud C, Kocot A, Vincenot J, Dehay C, Giroud P, Misery P, Allias F, Rudigoz RC, Melodelima D. Non-invasive high-intensity focused ultrasound treatment of the placenta: a preliminary in-vivo study using a simian model. *Ultrasound Obstet Gynecol* 2017; 50: 635-641.
64. Wee LY, Taylor M, Watkins N, Franke V, Parker K, Fisk NM. Characterisation of deep arterio-venous anastomoses within monochorionic placentae by vascular casting. *Placenta.* janv 2005;26(1):19- 24.
65. Robyr R, Lewi L, Salomon LJ, Yamamoto M, Bernard JP, Deprest J, et al. Prevalence and management of late fetal complications following successful selective laser coagulation of chorionic plate anastomoses in twin-to-twin transfusion syndrome. *Am J Obstet Gynecol.* mars 2006;194(3):796- 803.
66. Paek B, Foley J, Zderic V, Starr F, Shields LE, Vaezy S. Selective reduction of multifetal pregnancy using high-intensity focused ultrasound in the rabbit model. *Ultrasound Obstet Gynecol* 2005; 26: 267-270.
67. Ichizuka K. Basic study of less invasive high-intensity focused ultrasound (HIFU) in fetal therapy for twin reversed arterial perfusion (TRAP) sequence. 2016;
68. Kim Y, Gelehrter SK, Fifer CG, Lu JC, Owens GE, Berman DR, Williams J, Wilkinson JE, Ives KA, Xu Z. Non-invasive pulsed cavitation ultrasound for fetal tissue ablation: feasibility study in a fetal sheep model. *Ultrasound Obstet Gynecol* 2011; 37: 450-457.
69. Okai T, Ichizuka K, Hasegawa J, Matsuoka R, Nakamura M, Shimodaira K, Sekizawa A, Kushima M, Umemura S. First successful case of non-invasive in-utero treatment of twin reversed arterial perfusion sequence by high-intensity focused ultrasound. *Ultrasound Obstet Gynecol* 2013; 42: 112-114.
70. Seo K, Ichizuka K, Okai T, Dohi S, Nakamura M, Hasegawa J, Matsuoka R, Yoshizawa S, Umemura SI, Nagatsuka M, Sekizawa A. Treatment of twin-reversed arterial perfusion sequence using high-intensity focused ultrasound. *Ultrasound Obstet Gynecol* 2019; 54: 128-134.
71. Shaw CJ, Rivens I, Civale J, Botting KJ, Allison BJ, Brain KL, et al. Maternal and fetal cardiometabolic recovery following ultrasound-guided high-intensity focused ultrasound placental vascular occlusion. *J R Soc Interface.* mai 2019;16(154):20190013.

**Appendix :**

**Figure 1: thermal and mechanical effects of ultrasound**

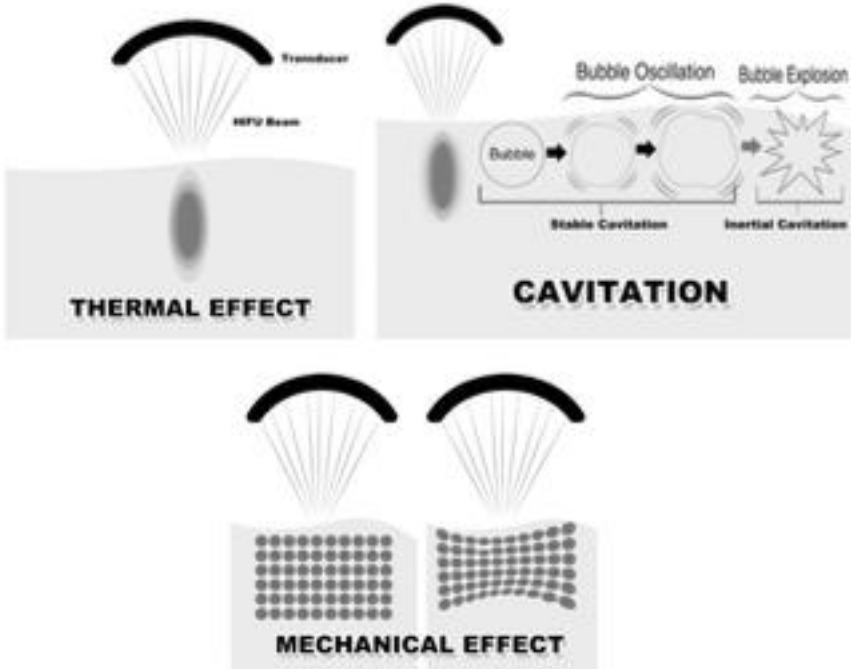


Figure 2: biological effects of ultrasound based on intensity (source: Maxwell, Acoustics Today, 2012)

