



HAL
open science

Urinary Organs at Risk for Prostate Cancer External Beam Radiation Therapy: Contouring Guidelines on Behalf of the Francophone Group of Urological Radiation Therapy

Jennifer Le Guévelou, Thomas Zilli, Ludovic Ferretti, Luc Beuzit, Olivier de Hertogh, Samuel Palumbo, Marjory Jolicoeur, Gilles Crehange, Talar Derashodian, Renaud de Crevoisier, et al.

► To cite this version:

Jennifer Le Guévelou, Thomas Zilli, Ludovic Ferretti, Luc Beuzit, Olivier de Hertogh, et al.. Urinary Organs at Risk for Prostate Cancer External Beam Radiation Therapy: Contouring Guidelines on Behalf of the Francophone Group of Urological Radiation Therapy. *Practical Radiation Oncology: An official journal of the American Society for Radiation Oncology*, 2024, 14 (6), pp.541-554. 10.1016/j.prro.2024.05.009 . hal-04812312

HAL Id: hal-04812312

<https://hal.science/hal-04812312v1>

Submitted on 30 Nov 2024

HAL is a multi-disciplinary open access archive for the deposit and dissemination of scientific research documents, whether they are published or not. The documents may come from teaching and research institutions in France or abroad, or from public or private research centers.

L'archive ouverte pluridisciplinaire **HAL**, est destinée au dépôt et à la diffusion de documents scientifiques de niveau recherche, publiés ou non, émanant des établissements d'enseignement et de recherche français ou étrangers, des laboratoires publics ou privés.



Distributed under a Creative Commons Attribution - NonCommercial - NoDerivatives 4.0 International License

Special Article

Urinary Organs at Risk for Prostate Cancer External Beam Radiation Therapy: Contouring Guidelines on Behalf of the Francophone Group of Urological Radiation Therapy



Jennifer Le Guévelou, MD,^{a,*} Thomas Zilli, MD,^b Ludovic Ferretti, MD,^c Luc Beuzit, MD,^d Olivier De Hertogh, MD,^e Samuel Palumbo, MD,^f Marjory Jolicoeur, MD,^g Gilles Crehange, MD,^h Talar Derashodian, MD,^g Renaud De Crevoisier, MD,^a Olivier Chapet, MD,ⁱ Mario Terlizzi, MD,^j Stéphane Supiot, MD,^k Carl Salembier, MD,^l and Paul Sargos, MD^m

^aDepartment of Radiation Oncology, Centre Eugène Marquis, Rennes, France; ^bDepartment of Radiation Oncology, Oncology Institute of Southern Switzerland, EOC, Bellinzona, Switzerland; Università della Svizzera Italiana, Lugano, Switzerland; Faculty of Medicine, University of Geneva, Geneva, Switzerland; ^cDepartment of urology, MSP Bordeaux Bagatelle, Talence, France; ^dDepartment of Radiology, Centre Hospitalier Universitaire Pontchaillou, Rennes, France; ^eDepartment of Radiation Oncology, CHR Verviers East Belgium, Verviers, Belgium; ^fDepartment of Radiation Oncology, Hôpital de Jolimont, La Louvière, Belgium; ^gDepartment of Radiation Oncology, Charles LeMoyne Hospital, CISSS Montérégie-center, Montréal, Quebec, Canada; ^hDepartment of Radiation Oncology, Institut Curie, Saint-Cloud, France; ⁱDepartment of Radiation Oncology, Centre Hospitalier Lyon Sud, Pierre Benite, France; ^jDepartment of Radiation Oncology, Institut Gustave Roussy, Villejuif, France; ^kDepartment of Radiation Oncology, Institut de Cancérologie de l'Ouest, Nantes Saint-Herblain, France; ^lUnité en Sciences Biologiques et Biotechnologies, University of Nantes, Nantes, France; ^mDepartment of Radiation Oncology, Europe Hospitals Brussels, Brussels, Belgium; and ^mDepartment of Radiation Oncology, Institut Bergonié, Bordeaux, France

Received 23 April 2024; accepted 14 May 2024

Purpose: The occurrence of genitourinary (GU) toxicity is a common adverse event observed after external beam radiation therapy (EBRT) for prostate cancer (PCa). Recent findings suggest that the dose delivered to specific urinary organs at risk (OARs) such as the ureters, bladder trigone, and urethra is involved in the development of GU toxicity.

Methods and Materials: A multidisciplinary task force including 3 radiation oncologists, a urologist, and a urologist was created in 2022. First, OARs potentially involved in GU toxicity were identified and discussed. A literature review was performed, addressing several questions relative to urinary OARs: anatomic and radiological definition, radiation-induced injury, and dose-volume parameters. Second, results were presented and discussed with a panel of radiation oncologists and members of the “Francophone Group of Urological Radiation Therapy.” Thereafter, the “Francophone Group of Urological Radiation Therapy” experts were asked to answer a dedicated questionnaire, including 35 questions on the controversial issues related to the delineation of urinary OARs.

Sources of support: This work had no specific funding.

*Corresponding author: Jennifer Le Guévelou, MD; Email: Jennifer.leguevelou@gmail.com

<https://doi.org/10.1016/j.prro.2024.05.009>

1879-8500/© 2024 The Authors. Published by Elsevier Inc. on behalf of American Society for Radiation Oncology. This is an open access article under the CC BY-NC-ND license (<http://creativecommons.org/licenses/by-nc-nd/4.0/>)

Results: The following structures were identified as critical for PCa EBRT: ureters, bladder, bladder neck, bladder trigone, urethra (intraprostatic, membranous, and spongious), striated sphincter, and postnucleation or posttransurethral resection of the prostate cavity. A consensus was obtained for 32 out of 35 items.

Conclusions: This consensus highlights contemporary urinary structures in both the upper and lower urinary tract to be considered for EBRT treatment planning of PCa. The current recommendations also propose a standardized definition of urinary OARs for both daily practice and future clinical trials.

© 2024 The Authors. Published by Elsevier Inc. on behalf of American Society for Radiation Oncology. This is an open access article under the CC BY-NC-ND license (<http://creativecommons.org/licenses/by-nc-nd/4.0/>)

Introduction

External beam radiation therapy (EBRT) is a standard of care treatment of localized prostate cancer (PCa).¹ The technological improvements over the past decade with both intensity modulated RT (IMRT) or rotational techniques and image guided RT have enabled a mitigation of both acute and late genitourinary (GU) toxicity occurring after EBRT.²⁻⁴ Yet, despite these advances, PCa EBRT still demonstrates an impact on quality of life, specifically on voiding symptoms and nocturia scores.⁵

Local control is a critical issue for the management of PCa. Local failure because of insufficient total dose is prognostic for death from PCa because of a second wave of metastases observed 5 to 10 years after primary treatment.⁶ Recently, the GETUG-18 trial has shown an improvement in 10-year overall survival with a dose escalation up to 80 Gy on the prostate gland associated with a long-term androgen deprivation therapy compared with a lower dose of 70 Gy (77.0% vs 65.9%, $P = .003$).⁷ The FLAME trial also demonstrated an improvement in 5-year biochemical relapse-free survival with the addition of a focal boost on the dominant intraprostatic lesion (92% vs 85% with and without a boost, respectively, $P < .001$).⁸ At the same time, prostate stereotactic body RT (SBRT) has been established as a new standard of care strategy in the management of low- to intermediate-risk PCa following the results of the PACE-B trial, but at the cost of a cumulative incidence of grade ≥ 2 GU toxicity.⁹ An increasing number of trials are testing dose escalation strategies in extremely hypofractionated schedules,¹⁰⁻¹² which might come at the cost of a rise in both acute and late severe toxicity. Last but not least, prostate reirradiation has been tested in several clinical trials, with early results showing an increased risk of GU toxicity.¹³ Hence, a better description of the relationship between the dose to GU organs at risk (OARs) and their risk of toxicity is needed.

The analysis of bladder dose-volume histograms (parameters) led to the implementation of various bladder dose constraints for PCa EBRT.¹⁴ However, dosimetric analysis of dose-escalated PCa EBRT trials using either normo or extreme hypofractionated schedules recently raised concerns on the role of additional urinary structures, such as the ureters,¹⁵ the bladder trigone,¹⁶⁻¹⁸ and the urethra.¹⁹⁻²¹ To date, no standardized definition of these urinary structures exists.

This work aims to provide an expert consensus on urinary OAR delineation for PCa EBRT on behalf of the “Francophone Group of Urological Radiation Therapy” (GFRU), useful for both daily routine practice and implementation in future clinical trials.

Methods and Materials

A multidisciplinary task force including 3 radiation oncologists (J.L.G., P.S., T.Z.), a urologist (L.B.), and a urologist (L.F.) was created in 2022 (Fig. 1). First, OARs potentially involved in urinary toxicity were identified and discussed. The following structures were considered critical for PCa EBRT: ureters, bladder, bladder neck, bladder trigone, urethra (intraprostatic, membranous, spongious), striated sphincter, and postnucleation or posttransurethral resection of the prostate (TURP) cavity.

Second, a literature review was performed (J.L.G.), addressing several questions relative to urinary OARs: anatomic and radiological definition, radiation-induced injury, and dose-volume parameters. The literature search was performed on April 2023 on PubMed, with the terms (ureters) AND (prostate cancer) AND (radiotherapy); (urethra) AND (prostate cancer) AND (radiotherapy); (bladder) AND (prostate cancer) AND (radiotherapy); (bladder trigone) AND (prostate cancer) AND (radiotherapy); (bladder neck) AND (prostate cancer) AND (radiotherapy); (striated sphincter) AND (prostate cancer) AND (radiotherapy), (TURP) AND (prostate cancer) AND (radiotherapy). Because of the scarcity of data regarding both radiation-induced injuries and dose-volume parameters, the literature review was not constrained to EBRT but included also brachytherapy (BT) data.

Third, once this review was performed, results were presented and discussed with a panel of experienced radiation oncologists, and members of the GFRU. Thereafter, a dedicated questionnaire including 35 questions was developed, addressing the main questions for the delineation of urinary OARs. The questionnaire was divided into major sections as follows:

1. General recommendations (2 questions)
2. Ureters (2 questions)
3. Bladder/bladder wall (3 questions)
4. Bladder trigone (3 questions)

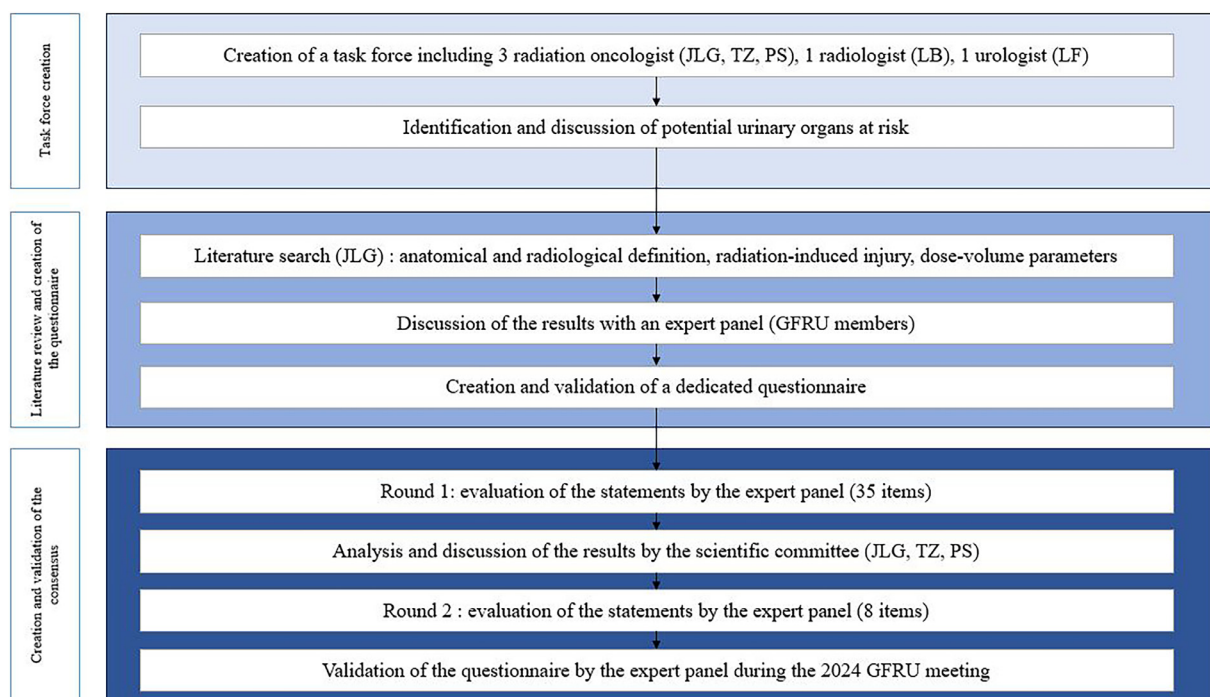


Figure 1 Flow chart of the study.

Abbreviation: GFRU = Francophone Group of Urological Radiation Therapy.

5. Bladder neck (4 questions)
6. Intraprostatic urethra (3 questions)
7. Membranous urethra (4 questions)
8. Bulbous urethra (4 questions)
9. Striated sphincter (5 questions)
10. TURP cavity (5 questions)

The questionnaire was submitted in January 2024 to all participants, using a Google Form, in accordance with the Delphi methodology. An anonymized summary of the individual answers was sent to all participants before the next round. Based on the participant's feedback, some questions were modified before the second round. A consensus was defined as an agreement of more than 80% among participants. Questions achieving consensus were excluded for the next round. Agreement was defined as 60% to 80% rates in favor of a proposition. A final synthesis of the consensus was performed during the 2024 GFRU meeting in March 2024.

Results

General recommendations

Similar to other recommendations, the GFRU group advocates in favor of the planification of PCa RT with a comfortably full bladder. Experts recommend treatment planning to be performed on a computed tomography (CT) without a contrast agent (agreement).

Definition of urinary structures and treatment-related toxicities

Upper urinary tract

Ureters. Anatomic and radiological definition: the ureters are urine excretory ducts extending from the pyelic cavities and abutting in the bladder. The ureters are hardly visible on nonenhanced planning CT yet can be visualized on T2-weighted magnetic resonance (MR) as a low-intensity signal with a central high-intensity signal because of the urine content (Table 1, Fig. 2).

Radiation-induced injury: ureteral injury occurring after RT results from a pathologic wound healing process, leading to fibrosis and ultimately to narrowing of the ureteral lumen. Ureteral stenosis results ultimately in renal failure and obstructive pyelonephritis.

Dose-volume parameters: the literature on dose-volume parameters is scarce. It remains a rare complication after PCa RT, which has been estimated to occur in 1.3% of the patients before the IMRT era.²² The ureters could be adversely affected when SBRT is performed in their close proximity.^{15,23}

Consensus: the ureters should be delineated from the kidney (excluding the pyelic cavities) up to the entrance of the bladder. If impossible, or alternatively, ureters should at least be delineated over the whole area of interest (treatment area). Because the distal position of the ureters varies with bladder filling, delineation of the

Table 1 Anatomic description of the urinary tract structures

Structure	Imaging modality	Anatomic definition
Upper urinary tract		
Ureters	CT-based	Urine excretory duct extending from the pyelic cavity. Composed of 2 segments: a lumboiliac segment and a pelvic segment. The pelvic ureter runs in the pelvic subperitoneal space and has 3 portions (parietal, visceral, and bladder). The ureters enter the bladder posteriorly and inferiorly, at the upper portion of the bladder trigone. Visible in T2-weighted sequences as a hyposignal with central hypersignal (urine).
Lower urinary tract		
Bladder		
Whole cavity	CT-based	Cavity collecting urine composed of a smooth muscle (detrusor) and a urothelial epithelium. Two portions can be distinguished: a fixed portion at its base (trigone) and an extensible superior part (dome). Its thickness depends on its repletion and is estimated at 3 mm. Its caudal part continues with the prostatic urethra.
Bladder wall		Bladder muscle and urothelial epithelium, with exclusion of the cavity. Visible in T2-weighted sequences as a hyposignal.
Bladder neck	MR-based	Most of the caudal part of the bladder composed of the bladder apex and the internal urethral sphincter. The bladder neck is in close contact with the prostate base. Is composed of 3 muscle layers and has an average thickness of 3-5 mm.
Bladder trigone	MR-based	Triangle-shaped area located in the posterior wall of the bladder. Continuation and termination of both ureters and ureteric musculature within the bladder.
Striated sphincter	MR-based	Is located within the genitourinary sphincter and is in relative hyposignal in T2-weighted sequences. In its center, the urethra is visible in hyposignal with a hypersignal in its center (epithelium), in T2-weighted sequences. Starts cranially at the lower border of the prostate gland. Stops at the first visible slice of penile bulb.
Urethra		
Intraprostatic portion	MR-based	The prostatic urethra is moderately hyperintense in the central to posterior portion of the prostate and is sometimes easily visible because of hyperintense urine signals within T2-weighted sequences.
Membranous portion		Portion of urethra that passes through the genitourinary diaphragm. The urethra is in hyposignal in T2-weighted sequences (conjunctive tissue), with moderate hypersignal within (epithelial surface).
Bulbous portion		Portion of urethra that passes through the penile bulb.
TURP cavity	MR-based	Funneled or conical defect within transition zone filled with urine in high-intensity hypersignal on T2-weighted sequences. Should include the necrotic tissues surrounding the cavity.
<i>Abbreviations:</i> CT = computed tomography; MR = magnetic resonance; TURP = transurethral resection of the prostate.		

ureters should be performed using CT, and can be performed without contrast agent (Agreement). Alternatively, the ureters can be delineated using T2-weighted MR sequences.

Lower urinary tract

The lower urinary tract includes the bladder and the urethra, which can be divided in several substructures.

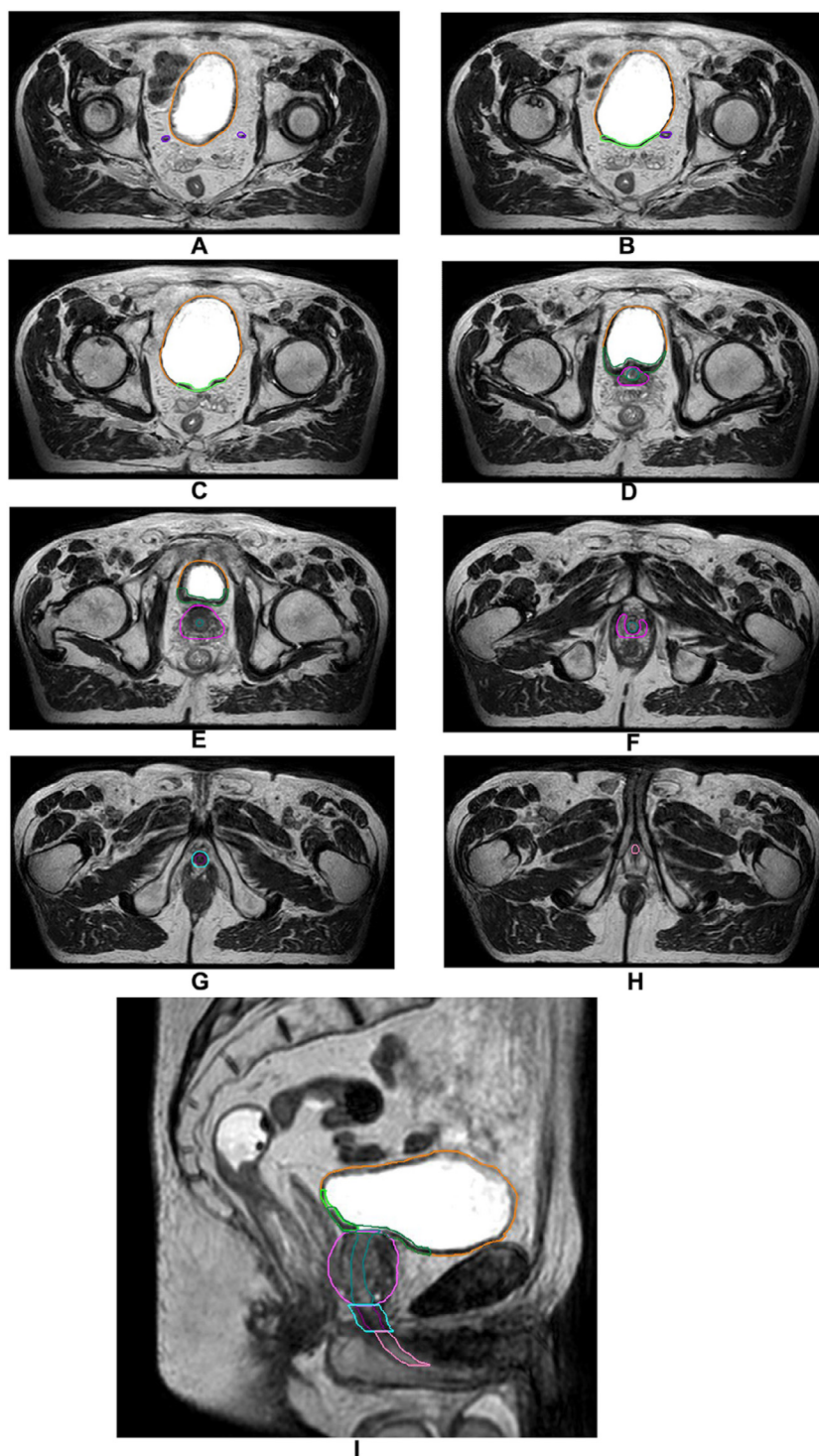


Figure 2 Illustration of urinary organs at risk (T2-weighted MR sequence). Case: patient who received the diagnosis of intermediate-risk prostate cancer, PSA = 7 ng/mL, IRM = T2a lesion on the prostate apex, biopsy = Gleason 7 (3 + 4) on 5 cores/12 (+2 positive targeted biopsies). Orange: bladder/purple: ureters/green: bladder trigone/dark green: bladder neck/prostate gland (clinical target volume): pink/blue-green: intraprostatic urethra/dark purple: membranous urethra/cyan: striated sphincter/light pink: bulbous urethra.

Abbreviations: MR = magnetic resonance; PSA = prostate-specific antigen.

Bladder/bladder wall. Anatomic and radiological definition: the bladder is a muscular elastic structure that can be divided into several segments. The upper part (dome) is mobile and deformable. The lower part is fixed and is composed of key structures for micturition, with both bladder neck and bladder trigone. The bladder wall is visible in T2-weighted sequences as a hyposignal.

Radiation-induced injury: the bladder remains relaxed during filling and contracts during micturition. From a pathologic point of view, radiation-induced bladder damage includes both endothelial cell injury and perivascular fibrosis, leading ultimately to ischemic phenomena.²⁴ Symptoms are broad and include noninfective cystitis, urinary frequency/urgency, urinary incontinence, dysuria, urinary retention, urinary tract pain, and hematuria.

Dose-volume parameters: various dose constraints exist for PCa RT.¹⁴ However, dose constraints in OARs vary from one reference to another, with a low agreement between studies.

Consensus: the bladder should be delineated using the planning CT. The Radiation Therapy Oncology Group proposes the delineation of the bladder in toto by outlining its external surface. Similarly, the GFRU group also advocates in favor of the delineation of the bladder in toto, including the bladder neck and bladder trigone. The Groupe d'Etudes des Tumeurs Uro-Genitales (GETUG) advocates in favor of the analysis of dose parameters delivered to the bladder wall (defined with a 7-mm internal margin).¹⁴ Variations in the definition of the bladder wall exist between trials. From an anatomic point of view, the bladder wall is 3-mm thick.²⁵ Experts of the GFRU did not find consensus on the definition of the bladder wall (Table 2).

Bladder trigone. Anatomic and radiological definition: the bladder trigone is a triangle-shaped area located in the posterior wall of the bladder and represents the continuation of the ureters and ureteric musculature within the bladder.

Radiation-induced injury: the bladder trigone is highly innervated and contains stretch-sensitive receptors responsible for the sensation of full bladder and the subsequent need to void. After EBRT, the innervation of the bladder trigone can be injured and result in urinary urgency.

Dose-volume parameters: to date, no constraints exist with regards to the trigone. Two teams suggested the dose delivered to the bladder trigone to be associated with acute urinary toxicity after conventionally fractionated PCa EBRT,¹⁶ with the volume of trigone receiving >72 Gy as a predictor of acute urinary retention.²⁶ Similarly, Ghadjar et al¹⁷ reported an association between several trigone dose parameters and both severe GU toxicity and late obstructive voiding symptoms. Greco et al²⁷ also showed an association between severe GU toxicity and doses delivered to the bladder trigone ($D5\% \geq 19$ Gy,

$D50\% > 9$ Gy) after PCa SBRT. The dose delivered to the bladder trigone has been correlated also with the onset of overall GU toxicity with MR-guided RT (MRgRT).¹⁸ Last but not least, Schaake et al²⁸ showed that the dose delivered to the bladder trigone correlated with the onset of incontinence. Dosimetric optimization on the trigone, both on high doses and on volumetric parameters, could therefore be effective in limiting high-grade toxicities.

Consensus: the bladder trigone should be delineated using T2-weighted MR sequences. The bladder trigone should be defined as starting cranially from the entrance of the ureters into the bladder, up to the start of the intraprostatic urethra caudally.¹⁷ Laterally, the trigone structure should encompass the distal portion of the ureters. In situations when ureters enter the bladder wall at different planes, the cranial boundary should be defined by the upper ureter. The most caudal slices of bladder, bladder neck, and trigone should be similar.

Bladder neck. Anatomic and radiological definition: the bladder neck is located at the lowest part of the bladder. It is composed of both bladder apex and internal urethral sphincter and is in close contact with the prostate gland. It is visualized as a hyposignal on T2 sequences because of the presence of 3 muscle layers (belonging to both the detrusor and the internal urethral sphincter).

Radiation-induced injury: both bladder neck and prostatic smooth muscle relaxation play a crucial part in the early steps of micturition. Radiation-induced toxicity on the bladder neck also consists of the development of fibrosis, impairing muscular relaxation, and ultimately results in dysuria.

Dose-volume parameters: bladder neck $D_{2\text{ cm}^3} > 50\%$ was identified as a strong predictor for acute and late urinary toxicity in patients treated with low-dose rate BT with and without supplemental EBRT. In addition, in regard to high-dose rate (HDR) BT, the dose delivered to the bladder neck has been suggested to be a predictor of acute toxicity.^{29,30} However, this association has not been reported in patients treated in EBRT.

Consensus: delineation of the bladder neck should be performed using T2-weighted MR sequences. No strict anatomic definition of the bladder neck exists. Its delineation should include the entire apical (axial) portion of the bladder, in proximity with the prostate gland. The internal urethral sphincter, which represents the termination of the bladder muscular fibers, must be included in the bladder neck. As a result, an overlap may exist between the bladder neck and the prostate gland.

Urethra. The urethra stands in direct continuity with the bladder neck and internal urethral sphincter. It is usually divided into its posterior (intraprostatic) and anterior (bulbous and membranous) portions.

Radiation-induced injury: urethral strictures represent a rare complication after PCa EBRT, ranging between 0.5% and 4% of the patients and occurring after a few

Table 2 Summary of the guidelines regarding urinary organs at risk delineation

Consensus	Proposed responses	Agreement level	Round
General recommendations			
What bladder repletion recommendations should be given for the planification of PCa RT?	Empty bladder Comfortably full bladder	Consensus	Round 1: 100% Comfortably full bladder
Which protocol would you recommend for the planification of PCa RT?	No intravenous contrast agent Intravenous injection of contrast agent and image acquisition in arterial phase Intravenous injection of contrast agent and image acquisition in excretory phase	Agreement	Round 1: 70% No intravenous contrast agent, Round 2: 70% No intravenous contrast agent
Ureters			
Which imaging modality should be used for the delineation of the ureters?	CT scan without contrast agent CT scan with contrast agent in excretory phase T2-weighted MR sequences Other: specify	Agreement	Round 1: 40% CT scan without contrast agent, Round 2: 70% CT scan without contrast agent
The ureters should be defined from the kidney (excluding the pyelic cavities), up to the entrance in the bladder	Agree Disagree	Consensus	Round 1: 90% Agree
Bladder/bladder wall			
Which imaging modality should be used for the delineation of the bladder/ bladder wall?	CT scan without contrast agent CT scan with contrast agent in excretory phase T2-weighted MR sequences Other: specify	Consensus	Round 1: CT scan without contrast agent
The bladder should be defined as the organ in toto (including bladder neck and bladder trigone, excluding the ureters and the urethra).	Agree Disagree	Consensus	Round 1: 100% Agree
What should be the internal margin to obtain the bladder wall?	3 mm 5 mm 7 mm Other: specify	-	Round 1: 40% 3 mm, Round 2: 40% 3 mm
Bladder trigone			
Which imaging modality should be used for the delineation of the bladder trigone?	CT scan without contrast agent CT scan with contrast agent in excretory phase T2-weighted MR sequences Other: specify	Consensus	Round 1: 50% CT scan without contrast agent, Round 2: 90% T2-weighted MR sequences
The bladder trigone should start cranially from the entrance of the ureters into the bladder, and shall encompass them laterally	Agree Disagree	Consensus	Round 1: 100% Agree
The bladder trigone ends caudally at the first slice of intraprostatic urethra (excluding it)	Agree Disagree	Consensus	Round 1: 100% Agree

(Continued)

Table 2 (Continued)

Consensus	Proposed responses	Agreement level	Round
Bladder neck			
Which imaging modality should be used for the delineation of the bladder neck?	CT scan without contrast agent CT scan with contrast agent in excretory phase T2-weighted MR sequences Other: specify	Consensus	Round 1: 80% T2 weighted MR sequences
The bladder neck should encompass the entire apical portion of bladder, in close proximity with the prostate gland.	Agree Disagree	Consensus	Round 1: 90% Agree
Caudally, the bladder neck should include the whole internal urethral sphincter	Agree Disagree	Consensus	Round 1: 100% Agree
An overlap may exist between the bladder neck and the prostate gland	Agree Disagree	Consensus	Round 1: 70% Agree, Round 2: 80% Agree
Intraprostatic urethra			
Which imaging modality should be used for the delineation of the intraprostatic urethra?	CT scan without contrast agent CT scan with contrast agent in excretory phase T2-weighted MR sequences Urethrogram Other: specify	Consensus	Round 1: 100% T2 weighted MR sequences
Cranially, the intraprostatic urethra extends from the bladder neck and should be delineated when the internal urethral sphincter is no more visible.	Agree Disagree	Consensus	Round 1: 100% Agree
Caudally, the intraprostatic urethra should stop at the last slice of prostate gland.	Agree Disagree	Consensus	Round 1: 100% Agree
Membranous urethra			
Which imaging modality should be used for the delineation of the membranous urethra?	CT scan without contrast agent CT scan with contrast agent in excretory phase T2-weighted MR sequences Urethrogram Other: specify	Consensus	Round 1: 100% T2 weighted MR sequences
The membranous urethra must be delineated on the entire portion of the genitourinary diaphragm.	Agree Disagree	Consensus	Round 1: 100% Agree
Cranially, the membranous urethra should start at the first slice where the prostate gland is no longer visible.	Agree Disagree	Consensus	Round 1: 100% Agree
Caudally, the membranous urethra should stop when the penile bulb is visible.	Agree Disagree	Consensus	Round 1: 100% Agree
Bulbous urethra			
Which imaging modality should be used for the delineation of the bulbous urethra?	CT scan without contrast agent CT scan with contrast agent in excretory phase T2-weighted MR sequences Urethrogram Other: specify	Consensus	Round 1: T2 weighted MR sequences

(Continued)

Table 2 (Continued)

Consensus	Proposed responses	Agreement level	Round
The bulbous urethra should be delineated over the entire penile bulb height.	Agree Disagree	Consensus	Round 1: 100% Agree
Cranially, the bulbous urethra should start at the first slice of penile bulb.	Agree Disagree	Consensus	Round 1: 100% Agree
Caudally, the bulbous urethra should stop at the last slice of penile bulb	Agree Disagree	Consensus	Round 1: 100% Agree
Striated sphincter			
Which imaging modality should be used for the delineation of the striated sphincter?	CT scan without contrast agent CT scan with contrast agent in excretory phase T2-weighted MR sequences Other: specify	Consensus	Round 1: 100% T2 weighted MR sequences
Cranially, the striated sphincter should start when the prostate apex is no longer visible.	Agree Disagree	Consensus	Round 1: 100% Agree
Caudally, the striated sphincter should stop when the penile bulb is visible (excluding it).	Agree Disagree	Consensus	Round 1: 100% Agree
Laterally, the striated sphincter is bounded by the elevator ani muscle.	Agree Disagree	Consensus	Round 1: 100% Agree
The striated sphincter should start and stop at the same slice than the bulbous urethra.	Agree Disagree	Consensus	Round 1: 70% Agree, Round 2: 80% Agree
Enucleation/TURP cavity			
Which imaging modality should be used for the delineation of the enucleation/TURP cavity?	CT scan without contrast agent CT scan with contrast agent in excretory phase T2-weighted MR sequences Urethrogram Other: specify	Consensus	Round 1: 90% T2 weighted MR sequences
The enucleation/TURP cavity should replace the urethra only in the proximal portions that have been resected	Agree Disagree	Consensus	Round 1: 50% Disagree, Round 2: 90% Agree
The enucleation/TURP cavity should be defined as the whole resection cavity and the fibrotic tissues surrounding it.	Agree Disagree	Consensus	Round 1: 80% Agree
Cranially, the enucleation/TURP cavity should start at the first visible slice of prostate gland	Agree Disagree	Consensus	Round 1: 100% Agree
Caudally, the enucleation/TURP cavity should stop at the last visible slice of cavity or necrotic tissues	Agree Disagree	Consensus	Round 1: 60% Agree, Round 2: 100% Agree
<i>Abbreviations:</i> CT = computed tomography; RT = radiation therapy; MRI = magnetic resonance imaging; MRgRT = magnetic resonance guided radiation therapy; PRV = planning organ at risk volume; TURP = transurethral resection of the prostate.			

years of follow-up.^{19,31} Yet, urethral strictures have been shown to be more frequent following adjuvant RT to the prostate bed, raising up to 17.8% in the study led by Thompson et al.³² Because most strictures probably remain asymptomatic if not circumferential and tight, this number may be underestimated. Some authors

suggested a different sensitivity to radiation between the urethral portions. Indeed, strictures are most frequently observed at the level of the anterior urethra, whereas in contrast, the delivered dose here is normally significantly lower than the dose administered to the intraprostatic urethra.^{33,34} Because strictures in the anterior urethra are

caused by collagen deposition, on the contrary, strictures occurring within the intraprostatic urethra are caused by necrotic deposits emanating from the prostate gland. Besides strictures, several studies demonstrated an association between the dose delivered to the urethra and overall GU toxicity.^{19-21,35}

Posterior urethra (intraprostatic urethra). Anatomic and radiological definition: the intraprostatic urethra is a muscular structure paved with a transitional cell epithelium. The internal and longitudinal plane forms a ridge on the posterior urethral wall (urethral crest), and drains the glandular elements of the prostate. More caudally, the urethral crest widens to form the seminal colliculus, in which the ejaculatory ducts enter the prostatic urethra. The intraprostatic urethra is moderately hyperintense in the central to posterior portion of the prostate and is sometimes easily visible because of hyperintense urine signals within T2-weighted sequences.

Dose-volume parameters: Groen et al¹⁹ showed within the FLAME trial a 24% rate of late cumulative grade ≥ 2 GU toxicity, with a median $D_{0.1 \text{ cm}^3}$ delivered to the urethra of 75 Gy. A dose-effect relation was observed, with an adjusted odds ratio of 1.12 (95% CI, 1.11-1.14; $P < .0001$). Therefore, the authors proposed to constraint the urethra $D_{0.1 \text{ cm}^3} \leq 91.2$ GyEQD2 when dose escalation is performed.¹⁹ The dose-relationship between maximal doses delivered to the urethra and the onset of severe (grade ≥ 2) GU toxicity was further demonstrated in the meta-analysis led by Leeman et al,²¹ with each increase of 1 Gy to maximal urethral doses resulting in 0.8% and 1% in acute and late grade ≥ 2 GU toxicity. By fitting grade ≥ 2 toxicity results and prescription doses of different studies, Zilli et al²⁰ showed that the development of late-severe GU toxicity remained independent from fractionation, with a risk of late GU toxicity approximating 10% when maximal urethral doses ranged between 95 and 100 Gy EQD₂ ($\alpha/\beta = 3$ Gy). Also, urethra dose-reduction strategies decreasing the urethral dose below 70 GyEQD2 ($\alpha/\beta = 3$) showed exceedingly low rates of severe GU toxicity (<8% at 5 years).³⁶

Consensus: because the urethra is not clearly visible on CT, its delineation is not feasible using conventional approaches. The Groupe Européen de Curiethérapie (GEC) and the European Society for Radiotherapy & Oncology- European Association of Urology (GEC/ESTRO-EAU) defined the prostatic urethra using a Foley catheter at the time of planning CT.³⁷ However, this technique carries both the drawbacks of being invasive and generating a shift of the upper portion of the urethra by more than 3 mm.³⁸ As many teams,^{39,40} we advocate in favor of a delineation using coregistered sagittal T2-weighted MR slices. Cranially, the intraprostatic urethra extends from the bladder neck and should be delineated when the internal urethral sphincter is no more visible. Caudally, the intraprostatic urethra should stop at the last slice of prostate gland.

Anterior urethra. - Membranous portion. Anatomic and radiological definition: the membranous urethra is the urethral segment going through the genitourinary diaphragm. Its length varies with the length of the striated sphincter but ranges from 1 to 1.5 cm. The conjunctive portion of the membranous urethra is visible as a hypointense signal in T2-weighted sequences. The internal portion composed of epithelium is visible in hypersignal.

Dose-volume parameters: no data are available on the dose constraints to apply to the membranous portion of the urethra. Retrospective data with HDR BT suggest that the membranous and bulbous portions are the most frequently affected by strictures, thereby might be the most radiosensitive portions.³⁴ Also, Mohammed et al⁴¹ reported a significant association between the maximal doses delivered to the bulbomembranous urethra and the probability to develop urethral stricture. As a result, caution is required at the time of treatment planning, especially when noncoplanar treatments are performed.

Consensus: several authors implemented a definition of the membranous urethra for BT treatments. Merrick et al⁴² defined the membranous urethra as starting from the apical slice of the prostate gland and extending 20 mm in length, but this definition carries the disadvantage of covering part of the bulbous portion. Díez et al⁴³ delineated it from the prostate apex to the penile bulb. Cranially, we advocate to delineate the membranous urethra from the slice where the prostate apex is no longer visible. Caudally, we advocate to stop the membranous urethra stops when the penile bulb is visible. The membranous urethra should be delineated using T2-weighted MR imaging (MRI).

- Bulbous portion. Anatomic and radiological definition: the bulbous portion of the urethra runs from the inferior margin of the genitourinary diaphragm to the penoscrotal junction.⁴⁴ The Cowper's gland ducts enter its upper portion. Laterally to the bulbous urethra run both penile bulb and crura. In most cases, diagnostic MRIs stop at the level of the genitourinary diaphragm and do not provide imaging of the bulbous urethra. However, the bulbous portion of the urethra is more easily visualized on CT than the other portions because of its spontaneous contrast with the bulb.

Dose-volume parameters: no specific data are available on dose-volume parameters for the bulbous portion of the urethra, which has mostly been analyzed conjunctively with the membranous portion.

Consensus: the bulbous urethra should be delineated over the entire penile bulb height using T2-weighted MRI. Cranially, the bulbous urethra should start when the first slice of penile bulb is visible. Caudally, the bulbous urethra should stop at the base of the penis (when both corpus cavernosum and corpus spongiosum appear).⁴⁴

Genitourinary diaphragm and striated sphincter. Anatomic and radiological definition: the genitourinary diaphragm is located between the prostate and the penile

bulb. It is composed of 2 structures: first, the external sphincter (also known as striated sphincter), visualized in hyposignal on T2-weighted sequences. The striated sphincter is a skeletal muscle located around the membranous portion of the urethra. The striated sphincter is visible in T2-weighted sequences as a hyposignal and has a sharp contrast with the surrounding fat-containing tissue (in hypersignal on T2-weighted sequences). Second, the bulbourethral glands (Cowper's glands), which are located

at the lower portion of the urogenital diaphragm and are responsible for the secretion of a fluid lubricating the urethra before ejaculation. The Cowper's glands are visualized as a hypersignal on T2-weighted sequences. The genitourinary diaphragm is located between the 2 layers of the deep perineal fascia.

Radiation-induced injury: the striated sphincter stays contracted during bladder filling and relaxes during mic-turition. Therefore, it is responsible for urinary

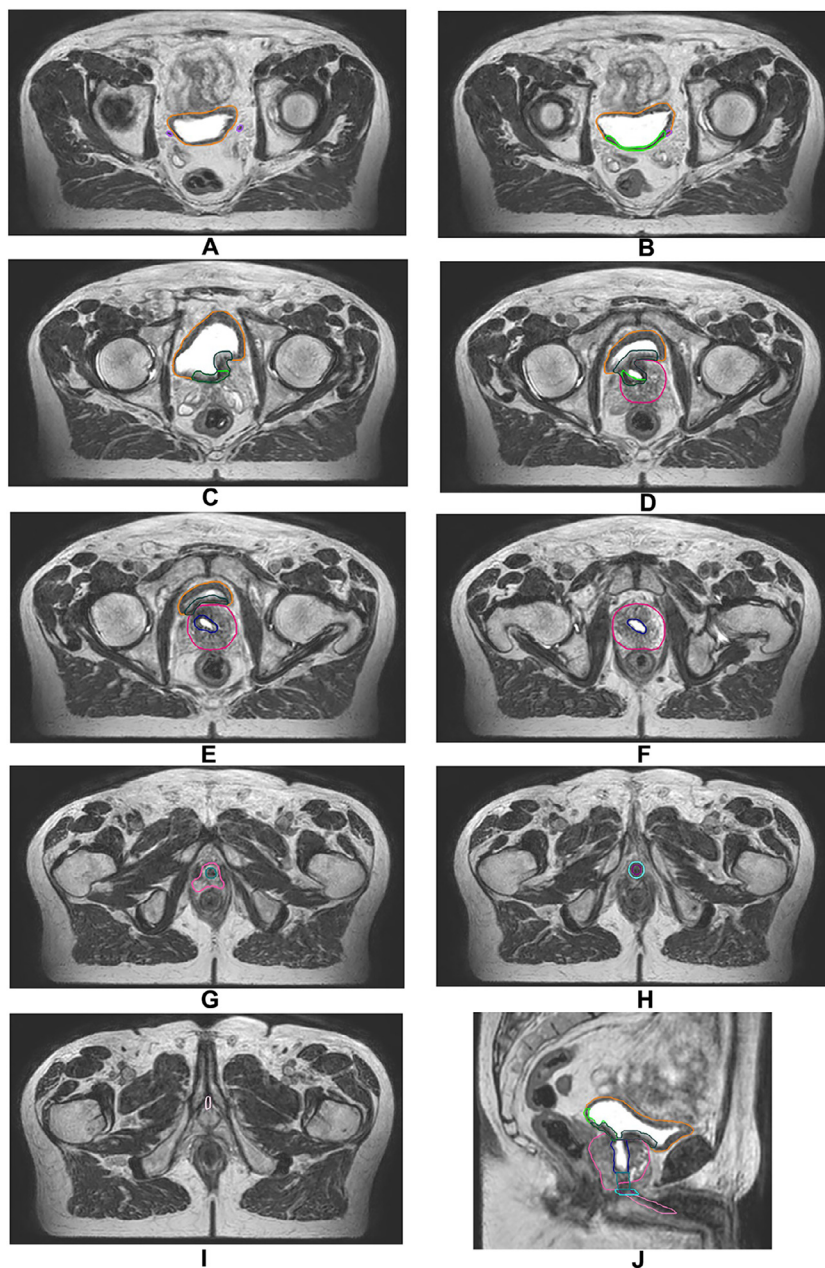


Figure 3 Illustration of urinary organs at risk, in a patient that has received TURP (T2-weighted MR sequence). Case: patient who received the diagnosis of intermediate-risk prostate cancer, PSA = 9.5 ng/mL, MRI = T2a on 7p zone, biopsy = Gleason 7 (3 + 4) on 3 cores/12 with cribriform pattern, (+3 positive targeted biopsies). Orange: bladder/purple: ureters/green: bladder trigone/dark green: bladder neck/prostate gland (clinical target volume): pink/dark blue: TURP cavity/blue-green: intraprostatic urethra/dark purple: membranous urethra/cyan: striated sphincter/light pink: bulbous urethra.

Abbreviations: MR = magnetic resonance; MRI = magnetic resonance imaging; PSA = prostate-specific antigen; TURP = transurethral resection of the prostate.

continence. After RT, fibrosis can occur and hamper the contractile abilities of the sphincter, generating urinary incontinence.

Dose-volume parameter: to date, no data are available with regards to either genitourinary diaphragm or striated sphincter, and the onset of GU toxicity. Because of their proximity, both doses delivered to the genitourinary diaphragm and striated sphincter may be surrogates of the dose delivered to the membranous urethra.

Consensus: the striated sphincter should start cranially when the prostate apex is no longer visible. Laterally, the striated sphincter is bound by the elevator ani muscle. Caudally, the striated sphincter stops at the first slice of penile bulb. Its length should be similar to the length of the membranous urethra. The striated sphincter can be created using a 3 mm expansion around the membranous urethra. The membranous urethra should be excluded from it.

Enucleation/TURP cavity

Anatomic and radiological definition: TURP or enucleation are performed in men presenting with prostatic benign hyperplasia with symptoms not responsive to medical treatment, and in cases of repetitive or complicated lower urinary tract symptoms.⁴⁵ TURP consists in an endoscopic resection of the basal and central part of the prostate gland, passing through the urethra. The TURP cavity is a funneled or conical defect within the transition zone. On MRI this central defect in the prostate might be filled with urine resulting in a high-intensity signal T2. Enucleation consists in the ablation of both median and lateral prostate lobes, through a cervicoprostatic incision.

Radiation-induced injury: For a long time, a past history of TURP has been considered a (relative) contraindication for BT. However, BT can be safely performed in selected patients and following strict guidelines. Data regarding PCa EBRT in men with a history of TURP are conflicting. SBRT to the prostate in men with a history of TURP or with previous interventions on the prostate was shown to be associated with an increase of GU toxicity and an approximately 50% incremented risk of late hematuria.⁴⁶ More recent studies seem to demonstrate lower rates of GU morbidity. Huck et al⁴⁷ reported late grade 2 and 3 GU toxicity in 33% and 17% of patients with a previous history of surgical treatment of benign prostatic hyperplasia, occurring more frequently in patients with prior adenectomy, multiple TURP, and/or large volumes of the intraprostatic resection cavity. Up to 42% of the patients experienced at least 1 episode of hematuria. However, Murthy et al⁴⁸ did not report any increase in either incontinence, urethral stricture, or overall GU morbidity in a propensity-matched cohort of patients receiving PCa SBRT. Recommendations from the GETUG radiation oncology group propose to perform PCa SBRT

in men with a history of TURP with a minimal time interval of 3 months.⁴⁹

Dose-volume parameters: specific contouring and dose-volume parameters have been published in regard to prostate BT in a post-TURP setting.⁵⁰ To date, however, no data are available on dose-volume parameters associated with the onset of GU toxicity regarding EBRT or SBRT. A uniform practice in the delineation of the post-TURP or postenucleation cavity and the consequent application in all prospective trials should give us more information on how to adapt our RT procedures in this specific clinical situation. In addition, one should bear in mind that, in analogy with BT, the onset of EBRT or SBRT should be delayed in patients that have received a TURP recently.

Consensus: because for other lower urinary tract OARs, the enucleation/TURP cavity should be delineated using T2-weighted MRI. They should be defined as the whole resection cavity and the fibrotic tissues surrounding it (Fig. 3). The enucleation/TURP cavity should start at the upper slice of the prostate gland. The risk of post-TURP incontinence being correlated with the distance of the resection area from the prostate apex, the lower portion of the intraprostatic urethra usually preserves its integrity. Therefore, the enucleation/TURP cavity should replace the intraprostatic urethra only in the proximal portions that have been resected. Caudally, the cavity should stop at the last visible slice of cavity/necrotic tissues.

Summary of the Consensus

The consensus is presented in Table 2. Among the 13 experts contacted, 10 participated in the study and completed the 2 rounds of the Delphi consensus. Of the 35 questions, 27 reached consensus after the first round, leaving 8 questions to be evaluated for the second round. Of these 8 questions, 5 of them found a consensus after the second round, and 2 found an agreement. Therefore, after discussion, it was decided not to perform a third round.

Conclusions

New challenges are arising in the mitigation of GU toxicity with the wide implementation of SBRT schedules for PCa RT. This consensus highlights new urinary structures in both the upper and lower urinary tracts to be considered for PCa treatment planning. The current recommendations also propose a standardized definition for both daily practice and future clinical trials. We hope that this will lead to a better understanding of the underlying mechanism of GU toxicity and the development of a new consensus in terms of urinary dose constraints for PCa EBRT.

Disclosures

None.

References

- Mottet N, van den Bergh RCN, Briers E, et al. EAU-EANM-ESTRO-ESUR-SIOG guidelines on prostate cancer—2020 update. Part 1: Screening, diagnosis, and local treatment with curative intent. *Eur Urol*. 2021;79:243-262.
- Hatano K, Tohyama N, Kodama T, Okabe N, Sakai M, Konoeda K. Current status of intensity-modulated radiation therapy for prostate cancer: History, clinical results and future directions. *Int J Urol*. 2019;26:775-784.
- Bauman G, Rumble RB, Chen J, Loblaw A, Warde P, Members of the IMRT Indications Expert Panel. Intensity-modulated radiation therapy in the treatment of prostate cancer. *Clin Oncol R Coll Radiol*. 2012;24:461-473.
- Latorzeff I, Mazurier J, Boutry C, Dudouet P, Richaud P, de Crevoisier R. Apports de la radiothérapie avec modulation d'intensité guidée par l'image dans les cancers prostatiques [Benefit of intensity modulated and image-guided radiotherapy in prostate cancer]. *Cancer Radiother*. 2010;14:479-487.
- Achard V, Zilli T. Prostate cancer intensity-modulated radiation therapy and long term genitourinary toxicity: An evolving therapeutic landscape. *Prostate Cancer Prostatic Dis*. 2023;26:1-2.
- Kishan AU, Chu FI, King CR, et al. Local failure and survival after definitive radiation therapy for aggressive prostate cancer: An individual patient-level meta-analysis of six randomized trials. *Eur Urol*. 2020;77:201-208.
- Hennequin C, Sargos P, Roca L, et al. Long-term results of dose escalation (80 vs 70 Gy) combined with long-term androgen deprivation in high-risk prostate cancers: GETUG-AFU 18 randomized trial. *J Clin Oncol*. 2024;42. LBA259-LBA259.
- Kerkmeijer LGW, Groen VH, Pos FJ, et al. Focal boost to the intraprostatic tumor in external beam radiation therapy for patients with localized prostate cancer: Results from the FLAME randomized phase III trial. *J Clin Oncol*. 2021;39:787-796.
- Tree AC, Ostler P, van der Voet H, et al. Intensity-modulated radiation therapy versus stereotactic body radiation therapy for prostate cancer (PACE-B): 2-year toxicity results from an open-label, randomised, phase 3, non-inferiority trial. *Lancet Oncol*. 2022;23:1308-1320.
- Hannan R, Salamekh S, Desai NB, et al. SABR for high-risk prostate cancer: A prospective multilevel MRI-based dose escalation trial. *Int J Radiat Oncol*. 2022;113:290-301.
- Poon DMC, Yuan J, Yang B, et al. A prospective study of stereotactic body radiation therapy (SBRT) with concomitant whole-pelvic radiation therapy (WPRT) for high-risk localized prostate cancer patients using 1.5 tesla magnetic resonance guidance: The preliminary clinical outcome. *Cancers (Basel)*. 2022;14:3484.
- Houlihan OA, Redmond K, Fairmichael C, et al. A randomized feasibility trial of stereotactic prostate radiation therapy with or without elective nodal irradiation in high-risk localized prostate cancer (SPORT Trial). *Int J Radiat Oncol*. 2023;17:594-609.
- Pasquier D, Lacomberie T, Supiot S, et al. The safety and efficacy of salvage stereotactic radiation therapy in patients with intraprostatic tumor recurrence after previous external radiation therapy: Phase 1 results from the GETUG-AFU 31 study. *Eur Urol Oncol*. 2023;6:399-405.
- de Crevoisier R, Supiot S, Créhange G, et al. External radiation therapy for prostatic cancers. *Cancer Radiother*. 2022;26:329-343.
- Sampath S, Frankel P, del Vecchio BD, et al. Stereotactic body radiation therapy to the prostate bed: Results of a phase I dose-escalation trial. *Int J Radiat Oncol*. 2020;106:537-545.
- Improta I, Palorini F, Cozzarini C, et al. Bladder spatial-dose descriptors correlate with acute urinary toxicity after radiation therapy for prostate cancer. *Phys Med*. 2016;32:1681-1689.
- Ghadjar P, Zelefsky MJ, Spratt DE, et al. Impact of dose to the bladder trigone on long-term urinary function after high-dose intensity modulated radiation therapy for localized prostate cancer. *Int J Radiat Oncol*. 2014;88:339-344.
- Pham J, Neilsen BK, Liu H, et al. Dosimetric predictors for genitourinary toxicity in MR-guided stereotactic body radiation therapy (SBRT): Substructure with fraction-wise analysis. *Med Phys*. 2024;51:612-621.
- Groen VH, van Schie M, Zuithoff NPA, et al. Urethral and bladder dose-effect relations for late genitourinary toxicity following external beam radiation therapy for prostate cancer in the FLAME trial. *Radiother Oncol*. 2022;167:127-132.
- Zilli T, Achard V, Guevelou JL. Intraprostatic urethra: the new kid on the block for prostate cancer radiation therapy? *Int J Radiat Oncol*. 2022;113:92-95. <https://doi.org/10.1016/j.ijrobp.2022.01.022>.
- Leeman JE, Chen Y-H, Catalano P, et al. Radiation dose to the intraprostatic urethra correlates strongly with urinary toxicity after prostate stereotactic body radiation therapy: A combined analysis of 23 prospective clinical trials. *Int J Radiat Oncol Biol Phys*. 2022;112:75-82.
- Arcangeli G, Micheli A, Arcangeli G, et al. Definitive radiation therapy for localized prostatic adenocarcinoma. *Int J Radiat Oncol Biol Phys*. 1991;20:439-446.
- Muggeo-Bertin E, Moeckli R, Vallet V, et al. A new method to visualize and to spare the ureters during SBRT for oligo metastatic patients. *Tech Innov Patient Support Radiat Oncol*. 2021;19:7-10.
- Pascoe C, Duncan C, Lamb BW, Davis NF, Lynch TH, Murphy DG, et al. Current management of radiation cystitis: a review and practical guide to clinical management. *BJU Int*. 2019;123:585-594.
- Hakenberg OW, Linne C, Manseck A, Wirth MP. Bladder wall thickness in normal adults and men with mild lower urinary tract symptoms and benign prostatic enlargement. *Neurourol Urodyn*. 2000;19:585-593.
- Mylona E, Ebert M, Kennedy A, et al. Rectal and urethro-vesical subregions for toxicity prediction after prostate cancer radiation therapy: validation of voxel-based models in an independent population. *Int J Radiat Oncol*. 2020;108:1189-1195.
- Greco C, Pares O, Pimentel N, et al. Safety and efficacy of virtual prostatectomy with single-dose radiation therapy in patients with intermediate-risk prostate cancer: Results from the PROSINT phase 2 randomized clinical trial. *JAMA Oncol*. 2021;7:700-708.
- Schaake W, van der Schaaf A, van Dijk LV, van den Bergh ACM, Langendijk JA. Development of a prediction model for late urinary incontinence, hematuria, pain and voiding frequency among irradiated prostate cancer patients. *PLoS One*. 2018;13: e0197757.
- Hathout L, Folkert MR, Kollmeier MA, Yamada Y, Cohen GN, Zelefsky MJ. Dose to the bladder neck is the most important predictor for acute and late toxicity after low-dose-rate prostate brachytherapy: Implications for establishing new dose constraints for treatment planning. *Int J Radiat Oncol*. 2014;90:312-319.
- Sanmamed N, Chung P, Berlin A, et al. Dose to the bladder neck in MRI-guided high-dose-rate prostate brachytherapy: Impact on acute urinary toxicity and health-related quality of life. *Brachytherapy*. 2019;18:477-483.
- King CR, Brooks JD, Gill H, Presti JC. Long-term outcomes from a prospective trial of stereotactic body radiation therapy for low-risk prostate cancer. *Int J Radiat Oncol*. 2012;82:877-882.
- Thompson IM, Tangen CM, Paradelo J, et al. Adjuvant radiation therapy for pathologically advanced prostate cancer: a randomized clinical trial. *JAMA*. 2006;296:2329-2335.
- Bece A, Patanjali N, Jackson M, Whitaker M, Hruby G. High-dose-rate brachytherapy boost for prostate cancer: Outcomes and genitourinary toxicity. *Brachytherapy*. 2015;14:670-676.

34. Hindson BR, Millar JL, Matheson B. Urethral strictures following high-dose-rate brachytherapy for prostate cancer: Analysis of risk factors. *Brachytherapy*. 2013;12:50-55.
35. Le Guevelou J, Bosetti DG, Castronovo F, Angrisani A, de Crevoisier R, Zilli T. State of the art and future challenges of urethra-sparing stereotactic body radiation therapy for prostate cancer: a systematic review of literature. *World J Urol*. 2023;41:3287-3299.
36. Zilli T, Jorcano S, Bral S, et al. Every-other-day versus once-a-week urethra-sparing prostate stereotactic body radiation therapy: 5-Year results of a randomized phase 2 trial. *Int J Radiat Oncol Biol Phys*. 2023;117:791-798.
37. Kovács G, Pötter R, Loch T, et al. GEC/ESTRO-EAU recommendations on temporary brachytherapy using stepping sources for localised prostate cancer. *Radiother Oncol*. 2005;74:137-148.
38. Dekura Y, Nishioka K, Hashimoto T, et al. The urethral position may shift because of urethral catheter placement in the treatment planning for prostate radiation therapy. *Radiat Oncol*. 2019;14:226.
39. Bruynzeel AME, Tetar SU, Oei SS, et al. A prospective single-arm phase 2 study of stereotactic magnetic resonance guided adaptive radiation therapy for prostate cancer: Early toxicity results. *Int J Radiat Oncol*. 2019;105:1086-1094.
40. Herrera FG, Valerio M, Berthold D, et al. 50-Gy Stereotactic body radiation therapy to the dominant intraprostatic nodule: Results from a phase 1a/b trial. *Int J Radiat Oncol*. 2019;103:320-334.
41. Mohammed N, Kestin L, Ghilezan M, et al. Comparison of acute and late toxicities for three modern high-dose radiation treatment techniques for localized prostate cancer. *Int J Radiat Oncol Biol Phys*. 2012;82:204-212.
42. Merrick GS, Butler WM, Tollenaar BG, Galbreath RW, Lief JH. The dosimetry of prostate brachytherapy-induced urethral strictures. *Int J Radiat Oncol Biol Phys*. 2002;52:461-468.
43. Díez P, Mullassery V, Dankulchai P, et al. Dosimetric analysis of urethral strictures following HDR 192Ir brachytherapy as monotherapy for intermediate- and high-risk prostate cancer. *Radiother Oncol*. 2014;113:410-413.
44. Lumen N, Campos-Juanatey F, Greenwell T, et al. European Association of Urology Guidelines on urethral stricture disease (Part 1): Management of male urethral stricture disease. *Eur Urol*. 2021;80:190-200.
45. Oelke M, Bachmann A, Descazeaud A, et al. EAU guidelines on the treatment and follow-up of non-neurogenic male lower urinary tract symptoms including benign prostatic obstruction. *Eur Urol*. 2013;64:118-140.
46. Pepin A, Aghdam N, Shah S, et al. Urinary morbidity in men treated with stereotactic body radiation therapy (SBRT) for localized prostate cancer following transurethral resection of the prostate (TURP). *Front Oncol*. 2020;10:555.
47. Huck C, Achard V, Zilli T. Surgical treatments of benign prostatic hyperplasia and prostate cancer stereotactic radiation therapy: impact on long-term genitourinary toxicity. *Clin Oncol R Coll Radiol G B*. 2022;34:e392-e399.
48. Murthy V, Sinha S, Kannan S, et al. Safety of prostate stereotactic body radiation therapy after transurethral resection of prostate (TURP): A propensity score matched pair analysis. *Pract Radiat Oncol*. 2019;9:347-353.
49. Lapierre A, Hennequin C, Beneux A, et al. Highly hypofractionated schedules for localized prostate cancer: Recommendations of the GETUG radiation oncology group. *Crit Rev Oncol Hematol*. 2022;173: 103661.
50. Salembier C, Rijnders A, Henry A, Niehoff P, André Siebert F, Hoskin P. Prospective multi-center dosimetry study of low-dose Iodine-125 prostate brachytherapy performed after transurethral resection. *J Contemp Brachytherapy*. 2013;5:63-69.