



HAL
open science

Chronic low-back pain modulation is enhanced by hypnotic analgesic suggestion by recruiting an emotional network:A PET imaging study

Fanny Nusbaum, Jérôme Redouté, Didier Le Bars, Pierre Volckmann, François Simon, Salem Hannoun, Gérard Ribes, Jacques Gaucher, Bernard Laurent, Dominique Sappey-Marinier

► To cite this version:

Fanny Nusbaum, Jérôme Redouté, Didier Le Bars, Pierre Volckmann, François Simon, et al.. Chronic low-back pain modulation is enhanced by hypnotic analgesic suggestion by recruiting an emotional network:A PET imaging study. *International Journal of Clinical and Experimental Hypnosis*, 2010, 59 (1), pp.27 - 44. <10.1080/00207144.2011.522874>. <hal-04806956>

HAL Id: hal-04806956

<https://hal.science/hal-04806956v1>

Submitted on 27 Nov 2024

HAL is a multi-disciplinary open access archive for the deposit and dissemination of scientific research documents, whether they are published or not. The documents may come from teaching and research institutions in France or abroad, or from public or private research centers.

L'archive ouverte pluridisciplinaire HAL, est destinée au dépôt et à la diffusion de documents scientifiques de niveau recherche, publiés ou non, émanant des établissements d'enseignement et de recherche français ou étrangers, des laboratoires publics ou privés.



HAL Authorization

CHRONIC LOW-BACK PAIN MODULATION IS ENHANCED BY HYPNOTIC ANALGESIC SUGGESTION BY RECRUITING AN EMOTIONAL NETWORK: A PET *Imaging Study*^{1,2}

FANNY NUSBAUM³

University of Lyon II, France

JÉRÔME REDOUTÉ AND DIDIER LE BARS

CERMEP-Imagerie du Vivant, Bron, France

PIERRE VOLCKMANN

Générale de Santé, Marcy l'Étoile, France

FRANÇOIS SIMON AND SALEM HANNOUN

University of Lyon I, France

GÉRARD RIBES AND JACQUES GAUCHER

University of Lyon II, France

BERNARD LAURENT

University of Saint-Étienne, France

DOMINIQUE SAPPEY-MARINIER

University of Lyon I, France

Manuscript submitted October 20, 2009; final revision accepted February 18, 2010.

¹This work was supported by the APICIL Foundation and the CNP Assurances Foundation.

²We greatly appreciate all the staff from the CERMEP-Imagerie du vivant imaging center for assisting in PET acquisition. And we extend our gratitude to Drs. S. Mazza, M. Magnin, and L. Garcia-Larrea from the INSERM research unit of U879 for their helpful discussions.

³Address correspondence to Fanny Nusbaum, Université Lyon II, Laboratoire « Santé-Individu-Société », 5 avenue Pierre Mendès France – Bâtiment K – 69500 Bron, France. E-mail: f.nusbaum@wanadoo.fr

Abstract: This study aimed to characterize the neural networks involved in patients with chronic low-back pain during hypnoanalgesia. PET was performed in 2 states of consciousness, normal alertness and hypnosis. Two groups of patients received direct or indirect analgesic suggestion. The normal alertness state showed activations in a cognitive-sensory pain modulation network, including frontotemporal cortex, insula, somatosensory cortex, and cerebellum. The hypnotic state activated an emotional pain modulation network, including frontotemporal cortex, insula, caudate, accumbens, lenticular nuclei, and anterior cingulate cortex (ACC). Direct suggestion activated cognitive processes via frontal, prefrontal, and orbitofrontal cortices, while indirect suggestion activated a widespread and more emotional network including frontal cortex, anterior insula, inferior parietal lobule, lenticular nucleus, and ACC. Confirmed by visual analog scale data, these results suggest that chronic pain modulation is greater with hypnosis, which enhances both activated networks.

Hypnosis has proven to be an efficient psychological treatment for acute and chronic pain (Jensen & Patterson, 2006). During hypnosis, the subject is driven into a particular state of consciousness (Faymonville et al., 2003; Gruzeliier, 2006), which is believed to enhance the efficiency of the therapeutic suggestion administered afterward. A suggestion is a colorful communication given to induce a specific, involuntary, and often unconscious response by the subject. However, brain mechanisms involved in hypnosis remain poorly understood regarding acute pain and are even less clear regarding chronic pain, while 30% of the U.S. population and 19% of the European population (Bouhassira, Lanteri-Minet, Attal, Laurent, & Touboul, 2008; Breivik, Collett, Ventafridda, Cohen, & Gallacher, 2006; Tollison, 1998) suffer from chronic pain.

Functional neuroimaging studies in experimental acute pain have shown that hypnotic analgesic suggestions modulate the activity in brain regions associated with the "pain matrix," such as the thalamus and the primary somatosensory cortex (SI), secondary somatosensory cortex (SII), insula, and anterior cingulate cortex (ACC) (Faymonville et al., 2000; Hofbauer, Rainville, Duncan, & Bushnell, 2001; Rainville, Duncan, Price, Carrier, & Bushnell, 1997). A particular attention was given to the ACC, which seems to play a major role in the hypnotic modulation of pain experience (Faymonville, Laureys, et al., 2000; Rainville, 2002; Rainville et al., 1997). Whereas these studies were performed in experimental pain conditions, only two have reported the effect of hypnosis using functional neuroimaging in patients suffering from fibromyalgia. First, a Positron Emission Tomography (PET) study (Wik, Fischer, Bragee, Finer, & Fredrikson, 1999) has shown that hypnoanalgesia induced an increased activity in the thalamus, orbito-frontal, and inferior parietal cortices and decreased activity in ACC. Second, a functional magnetic resonance imaging (fMRI)

study in fibromyalgic patients has reported, during hypnosis, increased activations in several regions including the cerebellum, ACC, and anterior and posterior insula (Derbyshire, Whalley, & Oakley, 2009).

Nevertheless, these studies have suggested that the hypnotic state alone is not always analgesic and may need specific analgesic suggestions in order to be so. If brain activity changes were found in the SI when hypnotic suggestions were given to modulate perceived pain intensity (Hofbauer et al., 2001), ACC activity was modulated if suggestions were used to selectively modulate pain unpleasantness (Rainville et al., 1997). These findings could reflect the dissociation between the sensory-discriminative and the affective-motivational dimensions of pain, suggesting that the analgesic effect of hypnotic suggestions may strongly depend on the suggestion itself and is not only a characteristic of the hypnotic state (Rainville, Carrier, Hofbauer, Bushnell, & Duncan, 1999). Further, it has been shown that suggestions need to be hypnotically inducted for a greater analgesic effect (De Pascalis, Cacace, & Massicolle, 2008; Derbyshire et al., 2009; Faymonville et al., 2003). Thus, the nature of analgesic suggestion may have a different impact on chronic pain, which is characterized by a stronger cognitive and emotional component compared to the somatosensory dimension of acute pain (Gracely et al., 2004; Moroni & Laurent, 2006; Young Casey, Greenberg, Nicassio, Harpin, & Hubbard, 2008). Then, we can wonder if the nature of the analgesic suggestion (direct or indirect) would show different effects on chronic low-back pain.

Therefore, the goal of this PET study was first to characterize the neural networks involved in chronic low-back pain patients during analgesic suggestions in a hypnotic compared to a normal alert state and, second, to compare, in both states, the efficiency of direct and indirect suggestions to modulate pain and the corresponding neural activations.

METHOD

Subjects

The sample comprised 14 right-handed men with an average age 40.9 years ($SD = 12.5$) with chronic low-back pain lasting more than 3 months with at least two pain episodes a week of any intensity. Free of surgery and refractory to pharmacological treatment, the subjects had psychological and medical examinations.

All patients showed a normal neurological examination and answered a questionnaire about their quality of life and functional incapacities (Roland Morris Disability Questionnaire) and were selected using the eight-itemed French version of the Stanford Hypnotic Susceptibility Scale: Form R (SHSS:R; Michaux, 1979), based

on a score higher than three. Their eventual painkilling treatment could include any of the World Health Organization’s class I, II, or III analgesic drugs with the exception of neuropathic drugs. Written informed consent was obtained from all subjects. The study received ethical approval from the local ethics committee.

Experimental and Imaging Protocol

PET examination was performed using a Siemens ECAT HR+ camera. Subjects were injected 12 times every 10 minutes with 333MBq Oxygen-15 labeled water before the 1-minute image acquisition. Two functional volumes were acquired during the resting conditions and three during the suggestion conditions. Each acquisition consisted of 63 contiguous slices of 2.42 mm thickness with a 4 mm spatial resolution and covered the entire brain.

The cohort was divided into two groups (A and B) of 7 subjects each, depending on the type of administrated analgesic suggestion. Subjects of Group A were given a direct suggestion, referring to the pain itself, its location, and relief. Subjects of Group B were given an indirect suggestion, referring to the subject’s well-being without mentioning the pain itself or its location.

As described in Figure 1, the protocol was applied to Groups A and B in five sequential conditions: three resting conditions of 20 minutes each alternating with the analgesic suggestions of 30 minutes each, (a) in normal alertness state and (b) in hypnotic state. Hypnotic state was reached following a 15-minute hypnotic induction (invitation to enter a hypnotic state). The hypnotist and the patient were wearing headphones and a microphone to communicate. Before each acquisition of the hypnotic condition, the hypnotist asked the patient if he was experiencing hypnosis. Moreover, an oculography was performed to observe any roving eye movements, known to be

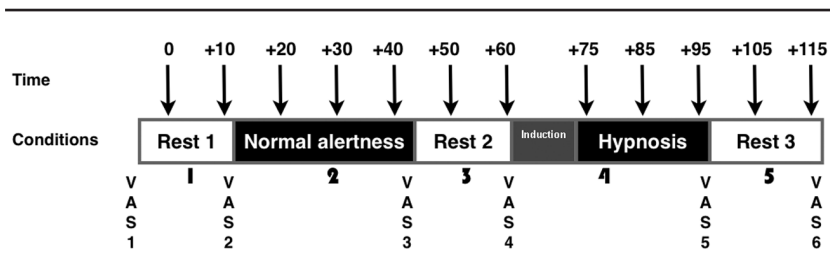

Figure 1. The experimental PET acquisition protocol was constituted of five sequential conditions: 3 resting periods of 20 min each, alternated with the analgesic suggestion periods of 30 min, first in normal alertness state, and second in hypnotic state, preceded by its induction period of 15 min. VAS were measured before and after each condition. Vertical arrows indicate the times of the 12 PET data acquisitions.

symptomatic of hypnotic state (Maquet et al., 1999). The hypnotic condition always occurred after the normal alertness condition to avoid any carryover effect. During the normal alertness state, the analgesic suggestion was given in a conversation-like manner, whereas, during the hypnotic state, the volume and tone of voice were softer and the speech slower and more quiet. Each time, the hypnotist remained silent for 2 minutes during the PET acquisition itself. Before and after every condition, a 1-to-10 visual analog scale (VAS) was used by the subject to estimate his pain perception. During the entire PET session, an electroencephalogram (EEG) was recorded to check that the subject had not fallen asleep.

Data Analysis

Data were preprocessed and analyzed using SPM5 (Statistical Parametric Mapping, Wellcome Department of Cognitive Neurology, London). PET images were realigned to minimize any subject movement from one acquisition to another. All subjects' images were then normalized into the International Consortium for Brain Mapping (ICBM) standard stereotaxic space. Finally, the images were smoothed using an isotropic 12 mm Gaussian kernel to increase signal-to-noise ratio and to decrease intersubject anatomical disparities. Statistical analyses were performed by contrasting regional cerebral blood flow (rCBF) images obtained during both analgesic suggestions with their respective resting conditions. Contrasts of interest were: Normal Alertness vs. Rest 1 (NA – R1) and Hypnosis vs. Rest 2 (H – R2). Decreases of rCBF were detected by using the inverse contrasts. Inclusive or exclusive masking procedures were used to identify respectively common and specific brain regions for both contrasts.

Resulting statistical maps were initially thresholded at $p < .001$, uncorrected for multiple comparisons, and regions about which we had an a priori hypothesis were reported at this threshold (Friston et al., 1995). For other brain regions, a more stringent procedure was applied and only voxels surviving a threshold of $p < .05$, corrected for multiple comparisons, both at the voxel or at the cluster level, were reported. VAS scores were compared using the Wilcoxon signed-rank nonparametric test using Data Analysis and Statistical Software (STATA, Version 9.2, StataCorp, Texas, USA).

RESULTS

Visual Analog Scale (VAS)

VAS scores measured in between each condition of the protocol are reported in Table 1. Baseline pain intensity was similar in both patient groups, as shown by the VAS1 measurements. Compared to

Table 1
VAS Values (Mean \pm Standard Deviation) of Pain Perception

	VAS 1	VAS 2	VAS 3*	VAS 4	VAS 5**	VAS 6
Group A: Direct suggestion	3.27 \pm 1.66	4.19 \pm 1.43	2.66 \pm 1.47	3.71 \pm 1.47	1.73 \pm 1.46	2.51 \pm 2.29
Group B: Indirect suggestion	3.64 \pm 1.14	4.23 \pm 1.52	3.59 \pm 2.22	3.70 \pm 2.22	1.66 \pm 2.09	1.33 \pm 1.55

* $p < .05$ when comparing VAS3 to VAS2. ** $p < .05$ when comparing VAS5 to VAS4.

their previous rest, the analgesic suggestions significantly decreased pain intensity by 28% ($p = .015$) after normal alertness state and by 64% ($p = .001$) after hypnotic state. This result was obtained in all subjects since there were no significant differences between the two groups (direct and indirect suggestions). Indeed, hypnotic state pain intensity decreased significantly ($p = .02$) in both direct (65%) and indirect (62%) groups, whereas normal alertness state decreased pain intensity significantly ($p = .02$) only in the direct group by 20%.

Neuroimaging

Normal alertness and hypnotic analgesic suggestions. Compared to their own resting states (Table 2), analgesic suggestions in normal alertness and hypnotic states activated common brain regions including the left medial prefrontal cortex (BA10), the right superior temporal gyrus (BA38), and the bilateral anterior insula. Common deactivations were also observed in the bilateral cuneus (BA18–19), the right parahippocampal gyrus (BA30), and the right middle temporal gyrus (BA39).

When normal alertness state was compared to its previous rest R1 (see Figure 2), analgesic suggestion (direct or indirect) was specifically associated with activations in the superior temporal (BA38) and orbitofrontal gyri (BA11) of the left hemisphere, in the inferior frontal cortex (BA47) of the right hemisphere, and bilaterally in the cerebellum. Deactivations were found in the bilateral middle occipital (BA19) and the somatosensory SI–SII (BA1–2–3) cortices, the right precentral gyrus (BA4), and the left inferior parietal lobule (BA40) and fusiform gyrus (BA37).

When hypnotic state was compared to its previous rest R2 (see Figure 2), analgesic suggestion (direct or indirect) was associated with activations in the anterior insula and nucleus accumbens of the left hemisphere, and in the lenticular and caudate nuclei bilaterally. We also found significant (uncorrected) activations in the ACC (BA32). In contrast, deactivations appeared in the left precuneus (BA7) and the right posterior cingulate cortex (PCC, BA31).

Direct and indirect analgesic suggestions. When comparing direct and indirect analgesic suggestions (Table 3), without any distinction of state of consciousness (hypnosis or normal alertness), both conditions showed common activations in the left prefrontal (BA9), right inferior frontal (BA47), and superior temporal (BA38) cortices, and deactivation in the right precuneus (BA7). Several differences were also found between these two conditions. During direct suggestion, activations were localized in medial and lateral prefrontal (BA10–11–46) cortices of the left hemisphere and in the orbitofrontal cortex (BA47) bilaterally. In contrast, deactivations were detected in PCC (BA30) and the middle

Table 2
Brain Regions Activated or Deactivated (Italicized) in All Patients During Analgesic Suggestion, in Normal Alertness and Hypnotic Conditions, Compared to their Respective Previous Rest

Normal Alertness		Hypnosis		Common	
Brain Region (BA) MNI Coordinates	z-score	Brain Region (BA) MNI Coordinates	z-score	Brain Region (BA) MNI Coordinates	z-score
Superior temporal gyrus (38) [#] -46, 12, -22	4.2	Anterior insula ⁺ -46, 4, -4	4.9	Anterior insula ⁺ -34, 10, -4	4.87
Inferior frontal gyrus (47) [#] 60, 26, -6	4.53	Lenticular nucleus [#] -14, -8, 0	3.35	Anterior insula ⁺ 38, 10, -12	4.94
Orbitofrontal cortex (11) [#] -10, 22, -24	4.21	Lenticular nucleus [#] 14, 10, -14	3.39	Superior temporal gyrus (38) ⁺ 44, 6, -18	4.84
Cerebellum [#] 40, -60, -36	4.14	Accumbens nucleus [#] -16, 16, -12	3.77	Medial prefrontal cortex (10) [#] -26, 50, 14	4.37
Cerebellum [#] -46, -54, -46	4.03	Caudate nucleus [#] -14, 10, 6	3.7	Cuneus (18) ⁺ -10, -84, 26	5.23
Middle occipital cortex (19) ⁺ -52, -68, -2		Caudate nucleus [#] 10, 8, 0	3.38	Cuneus (19) [#] 20, -90, 28	4.31
Middle occipital cortex (19) ⁺ 54, -60, -16		Anterior cingulate cortex (32) [*] 18, 36, 18	3.81	Parahippocampal gyrus (30) ⁺ 26, -56, 10	4.77
Somatosensory cortex (SI-SII) ⁺ -62, -16, 34	5.18	<i>Precuneus</i> (7) ⁺ -8, -82, 30	4.81	Middle temporal gyrus (39) ⁺ 40, -70, 22	4.67
Somatosensory cortex (SI-SII) [#] 58, -24, 34	5.12	<i>Posterior cingulate</i> (31) [#] 4, -66, 20	3.54		

<i>Inferior parietal lobule (40)</i> [#]	5.28
-38, -36, 50	
<i>Precentral gyrus (4)</i> ⁺	4.06
66, -10, 30	
<i>Fusiform gyrus (37)</i> [#]	4.61
-34, -42, -16	
	4.91
	4.3

Regions were significant at different levels: ⁺ voxel and cluster, [#] corrected or *uncorrected. BA: Brodmann Area.

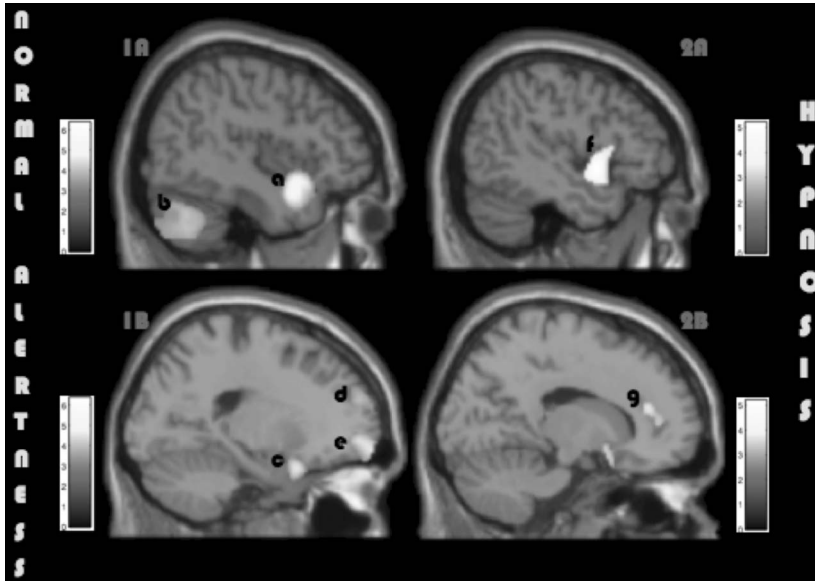


Figure 2. Brain activities were observed during analgesic suggestions (1) in normal alertness state in superior temporal gyrus (BA38) (a), cerebellum (b), inferior frontal (BA47) (c), medial prefrontal (BA10) (d), and orbitofrontal (BA11) cortices (e) as shown on sagittal slices 1A ($x = 44$) and 1B ($x = -19$); and (2) in hypnotic state in anterior insula (f) and ACC (BA32) (g) regions as shown on sagittal slices 2A ($x = -46$) and 2B ($x = 15$). Height threshold $p < .001$, uncorrected.

temporal cortex (BA39) of the right hemisphere, and in the parahippocampal (BA19) and precentral gyri (BA4) of the left hemisphere. During indirect suggestion, activations were found in the anterior insula and precentral gyrus (BA6) bilaterally, and in the inferior parietal lobule (BA40) and lenticular nucleus of the left hemisphere. Right ACC (BA32) was also activated (uncorrected). In contrast, deactivations were found in the precuneus (BA31) and cuneus (BA17) of the left hemisphere and in the superior parietal lobule (BA7) of the right hemisphere.

DISCUSSION

Pain sensation was decreased by analgesic suggestions in normal alertness and even more in the hypnotic state. These results confirm the efficiency of hypnosis on pain modulation (Faymonville et al., 2003).

The major finding of this functional imaging study is that analgesic suggestion, either direct or indirect, activated a cognitive-sensory

Table 3
Brain Regions Activated or Deactivated (Italicized) During Direct (Group A) or Indirect (Group B) Analgesic Suggestions

Direct Analgesic Suggestion		Indirect Analgesic Suggestion	
Brain Region (BA) MNI Coordinates	z-score	Brain Region (BA) MNI Coordinates	z-score
Prefrontal cortex (10) ⁺		Inferior parietal lobule (40) ⁺	
-24, 62, 24	4.85	-66, -44, 22	4.81
Prefrontal cortex (11) ⁺		Frontal gyrus (6) [#]	
-32, 44, -2	4.9	-6, -4, 60	4.21
Lateral prefrontal cortex (46) ⁺		Frontal gyrus (6) [#]	
-40, 34, 14	4.69	6, 14, 52	4.43
Orbitofrontal gyrus (47) ⁺		Anterior insula ⁺	
-20, 12, -22	6.07	38, 10, -12	5.31
Orbitofrontal gyrus (47) [#]		Anterior insula ⁺	
10, 18, -32	4.18	-36, 14, -4	4.92
		Lenticular nucleus [#]	
		-28, 8, -2	4.31
		Anterior cingulate (32) [*]	
		0, 18, 32	3.34
		Anterior cingulate (32) [*]	
		12, 22, 32	3.52
Prefrontal cortex (9) ⁺		Prefrontal cortex (9) ⁺	
-46, 28, 34	5.06	-28, 44, 32	4.74
Superior temporal gyrus (38) ⁺		Superior temporal gyrus (38) ⁺	
48, 10, -14	4.91	42, 6, -22	5.12
Inferior frontal gyrus (47) ⁺		Inferior frontal gyrus (47) ⁺	
32, 20, -10	4.67	60, 32, -4	5.29
<i>Posterior cingulate</i> (30) ⁺		<i>Precuneus</i> (31) ⁺	
10, -68, 8	4.90	-14, -82, 20	5.10
<i>Parahippocampal gyrus</i> (19) ⁺		<i>Cuneus</i> (17) [#]	
-20, -48, -4	4.89	-4, -98, -4	4.42
<i>Middle temporal gyrus</i> (39) ⁺		<i>Superior parietal lobule</i> (7) [#]	
46, -72, 18	4.86	32, -60, 54	4.62
<i>Precentral gyrus</i> (4) [#]			
-44, -14, 36	3.81		
<i>Precuneus</i> (7) [#]		<i>Precuneus</i> (31) [#]	
6, -52, 54	3.64	18, -88, 28	3.88

Regions were significant at different levels: ⁺voxel and cluster, [#]corrected or ^{*}uncorrected. BA: Brodmann Area.

network when administrated during a normal alertness state and, on the other hand, activated widespread brain regions, mostly participating in an emotional-weighted network, when administrated during a hypnotic state.

Normal Alertness and Hypnotic Analgesic Suggestions

During hypnoanalgesia, this study showed activations in the fronto-limbic network, including the medial prefrontal cortex, anterior insula, and the lenticular, caudate, and accumbens nuclei. Known for their implication in emotional modulation of acute (Duquette, Roy, Lepore, Peretz, & Rainville, 2007) and chronic pain (Apkarian, Bushnell, Treede, & Zubieta, 2005), these brain regions are particularly involved in the experience of positive emotions through the reward system (Kelley, 2004; Kringelbach & Rolls, 2004). Therefore, these findings suggest that hypnoanalgesia is effective on chronic low-back pain by activating positive emotions. Moreover, the deactivation observed in PCC, which is normally stimulated by negative emotions (Duquette et al., 2007), may confirm this hypothesis. In addition, the deactivation observed in precuneus during hypnosis may reflect a transient loss of self-consciousness (Faymonville, Boly, & Laureys, 2006) or a resting experience (Faymonville, Boly, & Laureys, 2006; Van den Heuvel, Mandl, Luigjes, & Hulshoff Pol, 2008).

However, neither thalamic nor significant (corrected) ACC activations were found in our study, in contrast with previous reports (Faymonville et al., 2006; Faymonville et al., 2000; Rainville et al., 1999; Rainville et al., 1997). This difference may result from the use of experimental pain in these previous studies that was certainly more intense than the everyday pain experienced by our patients. Another limitation of this study may come from the lack of randomization, which may have implied systematic effects of the normal alertness state's suggestion on brain activity during the hypnotic state.

During analgesic suggestions in the normal alertness state, activations were observed in the insula, in the medial prefrontal, inferior frontal, orbitofrontal and superior temporal cortices, and in the cerebellum, while deactivations were found in the inferior parietal lobule, somatosensory SI-SII cortices, and precentral gyrus. Although there were few changes in regions of the emotional network that were common to both states of consciousness, these results confirm the particular implication of a cognitive-sensory network in chronic low-back pain modulation (Neugebauer, Galhardo, Maione, & Mackey, 2009; Taber, Rashid, & Hurley, 2001; Wiech et al., 2005), in particular via the deactivation of somatosensory and precentral cortices. Also, the involvement of the inferior frontal cortex and the inferior parietal lobule suggests that pain modulation may occur by "denying" the pain

mental representation, as previously shown in spatial unilateral neglect studies (Çiçek, Gitelman, Hurley, Nobre, & Mesulam, 2007; Malhotra, Coulthard, & Husain, 2009; Thakral & Slotnick, 2009).

However, our observation of two neural networks depending on the states of consciousness contrasts with a previous study of chronic pain patients (Derbyshire et al., 2009), showing that brain activity of pain modulation was detected in similar regions during hypnotic and nonhypnotic states but with a difference in magnitude. These differences may come from the mode and nature of the suggestions used in the two studies. First, Derbyshire and colleagues chose to place the patients in an active state of mind by asking them to perform pain auto-suggestion, whereas we chose to place the patients in a passive state of mind by giving the suggestion. Second, the auto-suggestion was painful in the Derbyshire and colleagues' study whereas we provided analgesic suggestion to the patient. Thus, it is not surprising that the painful suggestion, which is based on sensory experience, activates the pain matrix (Peyron, Laurent, & Garcia-Larrea, 2000), whereas analgesic suggestion, which is more sensitive to emotional experience, may mobilize different networks according to the state of consciousness.

Direct and Indirect Analgesic Suggestions

Without any distinction in the state of consciousness (hypnosis or normal alertness), direct suggestion activated exclusively a fronto-temporal network, known to be involved in cognitive processes (Bořková, Chládek, Jurák, Halánek, & Rektor, 2007), including superior temporal, inferior frontal, medial and lateral prefrontal, and orbitofrontal cortices. As these regions are known for their role in attention in speech comprehension (Sabri et al., 2008), these findings showed that the patient was focused on listening to the hypnotherapist during direct suggestion. In contrast, indirect suggestion activated a widespread network, including superior temporal gyrus, frontal and prefrontal cortices, inferior parietal lobule, lenticular nucleus, bilateral anterior insula, and ACC. The activations found in the lenticular nucleus, anterior insula, and ACC show the emotional dimension of pain modulation (Gracely et al., 2004). Moreover, the deactivations observed during indirect suggestions in precuneus and superior parietal lobule may imply a loss of self-consciousness and spatial attention, and thus a more passive, or receptive, attitude generating automatisms and mental absorption mechanisms (Faymonville et al., 2006; Faymonville et al., 2003; Thakral & Slotnick, 2009). Finally, these results suggest that direct suggestion recruited more focused cognitive resources in chronic pain modulation, while indirect suggestion stimulated a wider and particularly emotional-weighted network.

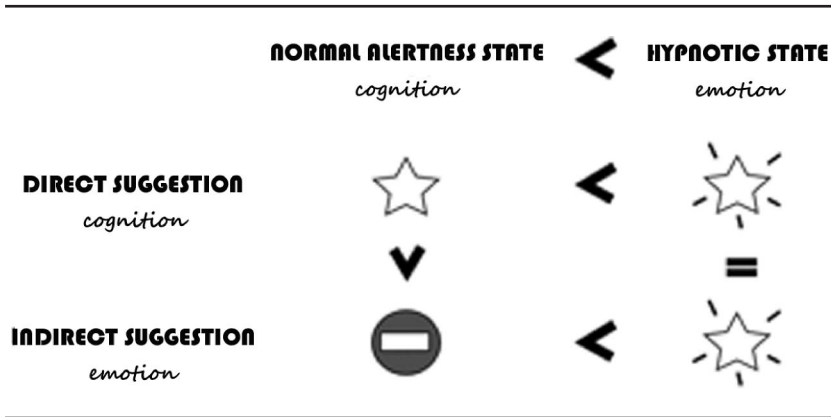


Figure 3. Relationships between direct and indirect suggestions in normal alertness and hypnotic states, based on VAS results.

Finally, the analysis of the relationships between VAS, state of consciousness (normal alertness or hypnosis), and type of suggestion (direct or indirect) suggested that normal alertness only had a significant effect on chronic pain when the suggestion used cognitive processes (direct suggestion), whereas hypnosis showed strong effects with either direct or indirect suggestion, as described in Figure 3. Although the lack of significant effect when using indirect suggestion during normal alertness may result from the large intersubject variability usually found in measurements of cognitive-emotional processes, we hypothesized that hypnosis had a strong potential to decrease pain with both suggestion types, thanks probably to the effectiveness of the emotional network.

CONCLUSION

Our results tend to show that analgesic suggestion was efficient in modulating chronic low-back pain, during both a normal alertness state and hypnosis, with a greater effect reported after hypnosis. But what seems more interesting is that pain modulation did not occur through the same networks depending on whether the suggestion was administrated during a normal alertness state or a hypnotic state. During a normal alertness state, the suggestion tended to stimulate a cognitive-sensory network, whereas, during the hypnotic state, it tended to stimulate an emotional network. The other finding of this study concerns the effect of direct and indirect suggestions. While a specific prefrontal cognitive network was mobilized with direct suggestion, a widespread and more emotional-weighted network was further mobilized with indirect suggestion. Therefore, these results

may provide useful information to hypnotherapists when choosing the kind of suggestion and the appropriate state of consciousness, according to the subject's pain specificity.

REFERENCES

- Apkarian, A. V., Bushnell, M. C., Treede, R. D., & Zubieta, J. K. (2005). Human brain mechanisms of pain perception and regulation in health and disease. *European Journal of Pain*, *9*, 463–484.
- Bošková, M., Chládek, J., Jurák, P., Haláček, J., & Rektor, I. (2007). Executive functions processed in the frontal and lateral temporal cortices: Intracerebral study. *Clinical Neurophysiology*, *118*, 2625–2636.
- Bouhassira, D., Lanteri-Minet, M., Attal, N., Laurent, B., & Touboul, C. (2008). Prevalence of chronic pain with neuropathic characteristics in the general population. *Pain*, *136*, 380–387.
- Breivik, H., Collett, B., Ventafridda, V., Cohen, R., & Gallacher, D. (2006). Survey of chronic pain in Europe: Prevalence, impact on daily life, and treatment. *European Journal of Pain*, *10*, 287–333.
- Çiçek, M., Gitelman, D., Hurlley, R. S., Nobre, A., & Mesulam, M. (2007). Anatomical physiology of spatial extinction. *Cerebral Cortex*, *17*, 2892–2898.
- De Pascalis, V., Cacace, I., & Massicolle, F. (2008). Focused analgesia in waking and hypnosis: Effects on pain, memory, and somatosensory event-related potentials. *Pain*, *134*, 197–208.
- Derbyshire, S. W. G., Whalley, M. G., & Oakley, D. A. (2009). Fibromyalgia pain and its modulation by hypnotic and non-hypnotic suggestion: An fMRI analysis. *European Journal of Pain*, *13*, 542–550.
- Duquette, M., Roy, M., Lepore, F., Peretz, I., & Rainville, P. (2007). Mécanismes cérébraux impliqués dans l'interaction entre la douleur et les émotions [Cerebral mechanisms involved in the interaction between pain and emotion]. *Revue Neurologique (Paris)*, *163*, 169–179.
- Faymonville, M. E., Boly, M., & Laureys, S. (2006). Functional neuroanatomy of the hypnotic state. *Journal of Physiology-Paris*, *99*, 463–469.
- Faymonville, M. E., Laureys, S., Degueldre, C., DelFiore, G., Luxen, A., Franck, G., . . . Maquet, P. (2000). Neural mechanisms of antinociceptive effects of hypnosis. *Anesthesiology*, *92*, 1257–1267.
- Faymonville, M. E., Roediger, L., Del Fiore, G., Delgueldre, C., Phillips, C., Lamy, M., . . . Laureys, S. (2003). Increased cerebral functional connectivity underlying the antinociceptive effects of hypnosis. *Brain Research: Cognitive Brain Research*, *17*, 255–262.
- Friston, K. J., Holmes, A. P., Worsley, K. J., Poline, J. B., Frith, C. D., & Frackowiak, R. S. (1995). Statistical parametric maps in functional imaging: A general linear approach. *Human Brain Mapping*, *2*, 189–210.
- Gracely, R. H., Geisser, M. E., Giesecke, T., Grant, M. A., Petzke, F., Williams, D. A., & Clauw, D. J. (2004). Pain catastrophizing and neural responses to pain among persons with fibromyalgia. *Brain*, *127*, 835–843.
- Gruzelier, J. H. (2006). Frontal functions, connectivity and neural efficiency underpinning hypnosis and hypnotic susceptibility. *Contemporary Hypnosis*, *23*(1), 15–32.
- Hofbauer, R. K., Rainville, P., Duncan, G. H., & Bushnell, M. C. (2001). Cortical representation of the sensory dimension of pain. *Journal of Neurophysiology*, *86*, 402–411.
- Jensen, M., & Patterson, D. R. (2006). Hypnotic treatment of chronic pain. *Journal of Behavioral Medicine*, *29*, 95–124.

- Kelley, A. E. (2004). Ventral striatal control of appetitive motivation: Role in ingestive behavior and reward-related learning. *Neuroscience & Biobehavioral Reviews*, 27, 765–776.
- Kringelbach, M. L., & Rolls, E. T. (2004). The functional neuroanatomy of the human orbitofrontal cortex: Evidence from neuroimaging and neuropsychology. *Progress in Neurobiology*, 72, 341–372.
- Malhotra, P., Coulthard, E. J., & Husain, M. (2009). Role of right posterior parietal cortex in maintaining attention to spatial locations over time. *Brain*, 132, 645–660.
- Maquet, P., Faymonville, M. E., Degueldre, C., Delfiore, G., Franck, G., Luxen, A., & Lamy, M. (1999). Functional neuroanatomy of hypnotic state. *Biological Psychiatry*, 45, 327–333.
- Michaux, D. (1979). Echelle de suggestibilité de Stanford, Forme « R » dérivée des échelles « A » et « C » de Hilgard [Stanford suggestibility scale, Form “R”, derived from Hilgard’s Forms “A” and “C”]. Mise au point et validation. Paris, France: Université Paris VII.
- Moroni, C., & Laurent, B. (2006). Influence de la douleur sur la cognition [The effect of pain on cognition]. *Psychologie et Neuropsychiatrie du Vieillessement*, 4(1), 21–30.
- Neugebauer, V., Galhardo, V., Maione, S., & Mackey, S. C. (2009). Forebrain pain mechanisms. *Brain Research Reviews*, 60(1), 226–242.
- Peyron, R., Laurent, B., & Garcia-Larrea, L. (2000). Functional imaging of brain responses to pain. A review and meta-analysis. *Clinical Neurophysiology*, 30, 263–288.
- Rainville, P. (2002). Brain mechanisms of pain affect and pain modulation. *Current Opinion in Neurobiology*, 12, 195–204.
- Rainville, P., Carrier, B., Hofbauer, R. K., Bushnell, M. C., & Duncan, G. H. (1999). Dissociation of sensory and affective dimensions of pain using hypnotic modulation. *Pain*, 82, 159–171.
- Rainville, P., Duncan, G. H., Price, D. D., Carrier, B., & Bushnell, M. C. (1997). Pain affect encoded in human anterior cingulate but not somatosensory cortex. *Science*, 277, 968–971.
- Sabri, M., Binder, J. R., Desai, R., Medler, D. A., Leitzl, M. D., & Liebenthal, E. (2008). Attentional and linguistic interactions in speech perception. *Neuroimage*, 39, 1444–1456.
- Taber, K. H., Rashid, A., & Hurley, R. A. (2001). Functional anatomy of central pain. *Journal of Neuropsychiatry and Clinical Neurosciences*, 13, 437–440.
- Thakral, P. P., & Slotnick, S. D. (2009). The role of parietal cortex during sustained visual spatial attention. *Brain Research*, 1202, 157–166.
- Tollison, C. D. (1998). *Pain and its magnitude, in Pain Management: A Practical Guide for Clinicians*. Boca Raton, FL: St. Lucie.
- Van den Heuvel, M., Mandl, R., Luijckes, J., & Hulshoff Pol, H. (2008). Microstructural organization of the cingulum tract and the level of default mode functional connectivity. *Journal of Neuroscience*, 28, 10844–10845.
- Wiech, K., Seymour, B., Kalisch, R., Enno Stephan, K., Koltzenburg, M., Driver, J., & Dolan, R. (2005). Modulation of pain processing in hyperalgesia by cognitive demand. *Neuroimage*, 27, 59–69.
- Wik, G., Fischer, H., Bragee, B., Finer, B., & Fredrikson, M. (1999). Functional anatomy of hypnotic analgesia: A PET study of patients with fibromyalgia. *European Journal of Pain*, 3, 7–12.
- Young Casey, C., Greenberg, M. A., Nicassio, P. M., Harpin, R. E., & Hubbard, D. (2008). Transition from acute to chronic pain and disability: A model including cognitive, affective, and trauma factors. *Pain*, 134, 69–79.

Die Modulation chronischer Rückenschmerzen wird durch hypnotische Suggestion im Rahmen der Schmerztherapie durch Schaffung eines emotionalen Netzwerks gesteigert: Eine PET-Bildgebungs Studie

Fanny Nusbaum, Jérôme Redouté, Didier Le Bars, Pierre Volckmann, François Simon, Salem Hannoun, Gérard Ribes, Jacques Gaucher, Bernard Laurent und Dominique Sappey-Marinier

Abstract: Diese Studie zielte darauf ab, die bei Patienten mit chronischen Rückenschmerzen während einer Hypnoanalgesie beteiligten neuronalen Netze zu charakterisieren. Das PET wurde während zwei unterschiedlichen Bewusstseinszuständen durchgeführt (bei normaler Aufmerksamkeit und unter Hypnose). Zwei Gruppen von Patienten erhielten entweder direkte oder indirekte analgetische Suggestionen. Bei normaler Aufmerksamkeit zeigten sich Aktivierungen in einem kognitiv-sensorischen, den Schmerz modulierenden Netzwerk einschließlich des frontotemporalen Kortex, der Insula, des somatosensorischen Kortex und des Kleinhirns. Im hypnotischen Zustand wurde dagegen ein Modulationsnetzwerk für emotionale Schmerzen einschließlich dem frontotemporalen Kortex, der Insula, dem Caudatus, dem Nucleus accumbens, der linsenförmigen Kerne und des anterioren cingulären Kortex (ACC) aktiviert. Direkte Suggestionen aktivierten kognitive Prozesse im frontalen, präfrontalen und orbitofrontalen Kortex, während indirekte Suggestion ein verteilteres und emotionaleres Netzwerk einschließlich dem frontalen Kortex, der anterioren Insula, dem unteren Parietallappen, der Linsenkerne und dem ACC aktivierten. Durch visuelle Analogskala Daten (VAS) bestätigt legen die Ergebnisse dieser Studie nahe, dass die Modulation chronischer Schmerzen unter Zuhilfenahme von Hypnose, wo beide aktivierten Netzwerke beeinflusst werden, stärker ist.

JAN MIKULICA
University of Konstanz, Germany

La suggestion analgésique hypnotique améliore la modulation de la douleur lombaire chronique en faisant appel au réseau émotionnel : *Une étude de l'imagerie médicale obtenue à l'aide de la tomographie par émission de positrons (TEP)*

Fanny Nusbaum, Jérôme Redouté, Didier Le Bars, Pierre Volckmann, François Simon, Salem Hannoun, Gérard Ribes, Jacques Gaucher, Bernard Laurent et Dominique Sappey-Marinier

Résumé: Cette étude visait à caractériser les réseaux neuronaux mis en cause chez des patients lombalgiques chroniques durant une hypnoanalgesie. Une TEP a été effectuée sous deux états de conscience : en éveil normal et sous hypnose. Deux groupes de patients ont reçu une suggestion analgésique directe ou indirecte. L'état d'éveil normal montrait une activité dans un réseau cognitivo-sensoriel de la modulation de la douleur, notamment dans le cortex frontotemporal, l'insula, le cortex somesthésique et le cervelet. L'état hypnotique activait un réseau émotionnel de modulation de la douleur, y compris le cortex frontotemporal, l'insula, le noyau caudé, l'accumbens, le

noyau lenticulaire et le cortex cingulaire antérieur (CCA). Une suggestion directe activait les processus cognitifs par voie des cortex frontal, préfrontal et orbitofrontal, alors qu'une suggestion indirecte activait un réseau plus étendu et plus émotionnel comprenant le cortex frontal, l'insula antérieure, le lobule pariétal inférieur, le noyau lenticulaire et le CCA. Confirmés par des données d'échelle analogique visuelles, ces résultats indiquent que la modulation de la douleur chronique est supérieure sous hypnose, laquelle augmente l'étendue des deux réseaux activés.

JOHANNE REYNAULT
C. Tr. (STIBC)

Mejoras en la modulación de dolor crónico de espalda baja a través de sugerencias de anestesia hipnótica que reclutan una red emocional: Un estudio de imagen TEP

Fanny Nusbaum, Jérôme Redouté, Didier Le Bars, Pierre Volckmann, François Simon, Salem Hannoun, Gérard Ribes, Jacques Gaucher, Bernard Laurent, y Dominique Sappey-Marinier

Resumen: El objetivo del estudio fue la caracterización de las redes neuronales involucradas durante hipnoanalgesia en pacientes con dolor crónico en espalda baja. Se utilizaron TEP en dos estados de conciencia, en estado normal de vigilia e hipnosis. Dos grupos de pacientes recibieron sugerencias analgésicas directas o indirectas. El estado de vigilia mostró activación en una red cognitivo-sensorial de modulación de dolor, incluyendo corteza frontotemporal, ínsula, corteza somatosensorial, y cerebelo. El estado hipnótico activó una red emocional de modulación de dolor, incluyendo la corteza frontotemporal, ínsula, núcleos caudado, acumbens, y lenticular, y la corteza anterior cingular (CAC). Las sugerencias directas activaron procesos cognitivos vía las cortezas frontal, prefrontal, y orbitofrontal, mientras que las sugerencias indirectas activaron una red emocional más difundida incluyendo la corteza frontal, ínsula anterior, lóbulo parietal inferior, núcleo lenticular y la CAC. Confirmado mediante datos obtenidos de la escala visual analógica, estos resultados sugieren que la modulación del dolor crónico es mayor bajo hipnosis, la cual incrementa las dos redes activadas.

OMAR SÁNCHEZ-ARMÁSS CAPPELLO
*Autonomous University of San Luis Potosí,
Mexico*