



HAL
open science

PHGDH-related microcephalic dwarfism in two fetuses: Expanding the phenotypical spectrum of L-serine biosynthesis defect

Silvestre Cuiat, Chloé Quélin, Laurent Pasquier, Philippe Loget, Dominique Aussel, Sylvie Odent, Annie Laquerrière, Maia Proisy, Sylvie Mazoyer, Marion Delous, et al.

► To cite this version:

Silvestre Cuiat, Chloé Quélin, Laurent Pasquier, Philippe Loget, Dominique Aussel, et al.. PHGDH-related microcephalic dwarfism in two fetuses: Expanding the phenotypical spectrum of L-serine biosynthesis defect. *European Journal of Medical Genetics*, 2023, 66 (11), pp.104852. 10.1016/j.ejmg.2023.104852 . hal-04801915

HAL Id: hal-04801915

<https://hal.science/hal-04801915v1>


Submitted on 25 Nov 2024

HAL is a multi-disciplinary open access archive for the deposit and dissemination of scientific research documents, whether they are published or not. The documents may come from teaching and research institutions in France or abroad, or from public or private research centers.

L'archive ouverte pluridisciplinaire **HAL**, est destinée au dépôt et à la diffusion de documents scientifiques de niveau recherche, publiés ou non, émanant des établissements d'enseignement et de recherche français ou étrangers, des laboratoires publics ou privés.



Distributed under a Creative Commons Attribution 4.0 International License



PHGDH-related microcephalic dwarfism in two fetuses: Expanding the phenotypical spectrum of L-serine biosynthesis defect

Silvestre Cuinat^{a,*}, Chloé Quélin^{b,c,1}, Laurent Pasquier^b, Philippe Loget^c, Dominique Aussel^d, Sylvie Odent^b, Annie Laquerrière^e, Maia Proisy^f, Sylvie Mazoyer^g, Marion Deloux^g, Patrick Edery^{a,g}, Nicolas Chatron^{a,h}, Gaetan Lesca^{a,h}, Audrey Putoux^{a,g,**}

^a Hospices Civils de Lyon, Service de Génétique, Centre Labélisé Anomalies du Développement CLAD Sud-Est, Lyon, France

^b CHU Hôpital Sud, Rennes, Service de Génétique Clinique, Centre de Référence Maladies Rares CLAD-Ouest, France

^c CHU Pontchaillou, Service d'Anatomie et de Cytologie Pathologiques, Rennes, France

^d Clinique La Sagesse, Service de Gynécologie-Obstétrique, Rennes, France

^e CHU de Rouen Laboratoire d'Anatomie et de Cytologie Pathologiques, Institut de biologie clinique, Rouen, France

^f CHU de Brest, Département de Radiologie, Brest University, 29609, Brest, Cedex, France

^g Centre de Recherche en Neurosciences de Lyon, équipe GENDEV, INSERM U1028 CNRS UMR5292 UCBL1, Lyon, France

^h Institut Neuromyogène, Laboratoire Physiopathologie et Génétique du Neurone et du Muscle, Equipe Métabolisme énergétique et développement neuronal, CNRS UMR 5310, INSERM U1217, Université Lyon 1, Lyon, France

ARTICLE INFO

Handling Editor: A. Verloes

Keywords:

Serine biosynthesis defect
Neu Laxova syndrome
Microcephalic dwarfism
Fetus
PHGDH

ABSTRACT

Defects in L-serine biosynthesis are a group of autosomal recessive diseases resulting in a wide phenotypic spectrum ranging from viable to lethal presentations and caused by variants in the three genes encoding the L-serine biosynthesis enzymes, *PHGDH*, *PSATI*, and *PSPH*. Neu-Laxova syndrome (NLS) is the fetal form of this group, characterized by multiple congenital anomalies including severe intrauterine growth retardation, cutaneous lesions extending from ichthyosis to severe restrictive dermopathy with ectropion and eclabion, edema, microcephaly, central nervous system abnormalities, and flexion contractures. Here we report on two unrelated fetuses with an attenuated phenotype of NLS, that initially evoked Taybi-Linder syndrome. They carry biallelic pathogenic variants in the *PHGDH* gene. These observations expand the phenotypic continuum of L-serine biosynthesis defects, and illustrate the phenotypic overlap between NLS and microcephalic primordial dwarfism.

1. Introduction

L-Serine is a non-essential amino acid involved in neurotransmission, nucleotide and lipids synthesis. It plays a vital role in embryogenesis and neurodevelopment. The *de novo* biosynthesis from phosphoglycerate involves three enzymes: 3-phosphoglycerate dehydrogenase (3-PGDH), phosphoserine aminotransferase (PSAT), and phosphoserine phosphatase (PSPH) (Tabatabaie et al., 2010).

Biallelic hypomorphic variants in the genes encoding for these three enzymes, respectively *PHGDH* (OMIM*606879), *PSATI* (OMIM*610936), and *PSPH* (OMIM*172480), cause a wide clinical spectrum, ranging from viable forms with intellectual disability, epilepsy, spasticity and progressive microcephaly (OMIM#601815,

OMIM#614023, OMIM#610992) (Tabatabaie et al., 2010), to polymalformative fetal forms in Neu-Laxova syndrome (NLS, OMIM#256520, OMIM#616038) (Acuna-Hidalgo et al., 2014).

NLS is characterized by multiple congenital anomalies including severe intrauterine growth restriction (IUGR), cutaneous lesions extending from ichthyosis to severe restrictive dermopathy, and hydropic appearance with edema of the hands and feet. Craniofacial features include microcephaly, sloping forehead, proptosis, ectropion, flat nose, round gaping mouth with eclabion, and micrognathia. Variable central nervous system (CNS) abnormalities include abnormal gyration, lissencephaly, and dysgenesis of the corpus callosum and the cerebellum. Joint contractures, pterygia and syndactyly are frequently observed due to fetal akinesia (Acuna-Hidalgo et al., 2014; Shaheen

* Corresponding author.

** Corresponding author. Hospices Civils de Lyon, Service de Génétique, Centre Labélisé Anomalies du Développement CLAD Sud-Est, Lyon, France.

E-mail addresses: silvestre.cuinat@hotmail.fr (S. Cuinat), audrey.putoux@chu-lyon.fr (A. Putoux).

¹ Both authors contributed equally to this work.

et al., 2014).

We report here two fetuses with biallelic pathogenic variants in the *PHGDH* gene. They present with a phenotype that is intermediate between NLS and the infantile form of defective L-serine biosynthesis, which was initially suggestive of microcephalic dwarfism on fetal imaging and autopsy.

2. Material and methods

The biometrics were estimated by an expert fetopathologist and fetal growth was assessed according to the corresponding pregnancy term, using the Usher and McLean standards growth curves (Usher and McLean, 1969). Informed consent for genetic analysis was obtained from the couples. DNA was extracted from parental blood samples, fetal liver tissue (patient 1) and amniotic fluid cells (patient 2). Trio Exome Sequencing (ES) was performed following protocols described in Supporting Information.

3. Results

Patient 1 was a female fetus at 32 Weeks of Gestation (WG). The second trimester sonogram at 22 WG showed a symmetrical IUGR with abdominal circumference around the 5th centile, femoral length around the 1st centile and head circumference <3rd centile (<-2 SD). The fetus had abnormal facial features with hypertelorism and retrognathism. The hands were clenched. The corpus callosum was thick and short, the cerebellum was hypoplastic and the gyration was delayed (Fig. 1A–B). Fetal cerebral MRI at 29 WG showed microcephaly, corpus callosum dysgenesis, delayed gyration, and cerebellar hypoplasia. Array-CGH performed on DNA extracted from amniotic fluid cells and karyotype were normal (46,XX). Medical termination of pregnancy was performed at 32 WG. Post-mortem examination showed a female fetus with IUGR and severe microcephaly: weight was 841 g (corresponding to 26 WG; -4.5 SD), crown-heel and crown-rump lengths were 38.5 cm (corresponding to 29 WG; -2.5 SD) and 24 cm (corresponding to 26 WG) respectively, foot length was 5.5 cm (corresponding to 28 WG) and head circumference was 22 cm (corresponding to 24 WG; -5.5 SD). The fetus presented with dysmorphic facial features, bilateral camptodactyly, adducted thumbs and rocker-bottom feet. Skin was normal (Fig. 2A–I), without ichthyotic lesion, and histology of skin samples revealed no hyperkeratotic lesions. Neuropathological examination showed an extremely simplified gyration, vermian hypoplasia, partial corpus callosum agenesis with Probst bundles, hypoplasia of the corticospinal

tracts, and neuronal paucity of the cranial nerve nuclei (Fig. 2J–N). Histological examination of the eyes showed bilateral cataract (Fig. 2O). X-rays showed delayed bone maturation with shortened long bones consistent with a gestational age of 25 WG (Fig. 2S–T). Trio ES analysis led to the identification of compound heterozygous variants in *PHGDH* (NM_006623.4): A known missense variant c.1273G>A; p.(Val425Met) (ClinVar; [VCV000003868.4]) inherited from the mother and a novel frameshift variant c.765delC, p.(Ala257Leufs*51) (ClinVar; submitted) inherited from the father (details in Supporting Information).

Patient 2 was a female fetus at 31 WG. Second-trimester ultrasound examination revealed a symmetrical IUGR, a sloping forehead, a varus deformity of one foot, agenesis of the corpus callosum, and a small cerebellum. Brain abnormalities were confirmed on fetal MRI at 30 WG showing corpus callosum agenesis, delayed gyration, cerebellar hypoplasia (Fig. 1C–F). Karyotype and array CGH on amniotic fluid were normal (46,XX). The pregnancy was terminated at 31 WG. Post-mortem external examination showed a female fetus with IUGR and severe microcephaly: a weight of 838 g (corresponding to 26 WG; -4 SD), crown-heel and crown-rump lengths of 32 cm (corresponding to 24 WG; -6 SD) and 22 cm (corresponding to 24 WG) respectively, foot length of 4.9 cm (corresponding to 26 WG) and head circumference of 22 cm (corresponding to 24 WG; -4 SD). The fetus presented with arthrogryposis, club feet and hands, pterygia of axillae, knee and elbow flexion contractures, and adducted thumbs. Dysmorphic facial features were noted with sloping forehead, hypertelorism, and micrognathia. Skin was normal, without ichthyotic lesion. Autopsy was declined by the parents. Skeletal radiographies showed delayed bone maturation with shortened long bones length consistent with a gestational age of 26 WG (Fig. 2U–V). ES analysis showed a known homozygous missense variant NM_006623.4:c.488G>A, p.(Arg163Gln) in *PHGDH* (ClinVar; [VCV000139535.4]; details in Supporting Information).

4. Discussion

Since the first report by Jaeken et al., in 1996 (Jaeken et al., 1996), out of 45 patients with *PHGDH* variants were reported in 24 publications (Fu et al., 2022), including 15 patients with NLS (Acuna-Hidalgo et al., 2014; Shaheen et al., 2014; Abdelfattah et al., 2020; Mattos et al., 2015; Bourque et al., 2019; Takeichi et al., 2018). Here we present on two fetuses with a severe defect in the L-serine biosynthesis, but lacking several major features of NLS. Termination of pregnancy was performed for severe IUGR, microcephaly, CNS malformations and joints contractures. The presence of camptodactyly, adducted thumbs, rocker-bottom

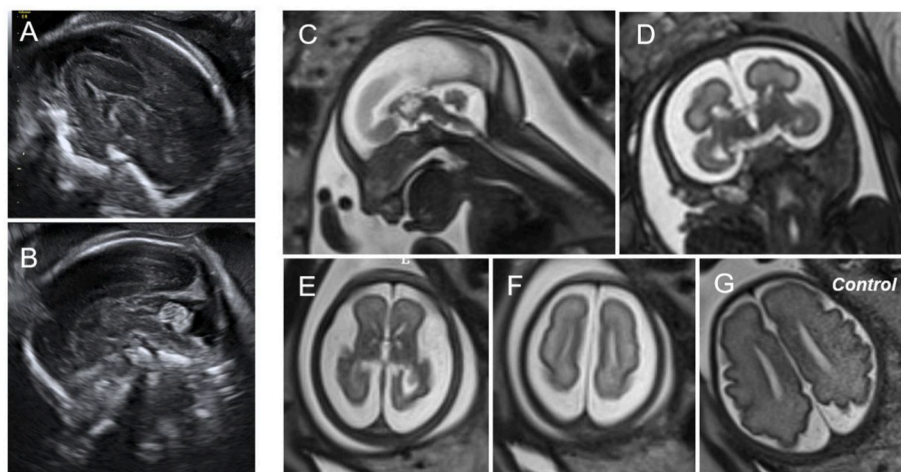


Fig. 1. Prenatal imaging. Ultrasound of patient 1 at 22 WG (A,B). Coronal section shows absence of the posterior part of corpus callosum and the insufficient gyration for term (A). Sagittal section shows the cerebellum hypoplasia and the enlarged posterior cistern (B). Brain fetal MRI of patient 2 performed at 29 + 1 weeks GA (C–F) shows the absence of corpus callosum and vermian hypoplasia on sagittal T2 weighted-imaging (C–E). Coronal (D) and axial (E–F) T2 weighted-imaging shows microcephaly and severe microencephaly with enlarged pericerebral fluid space, associated with delayed gyration compared to a control at the same term (G).

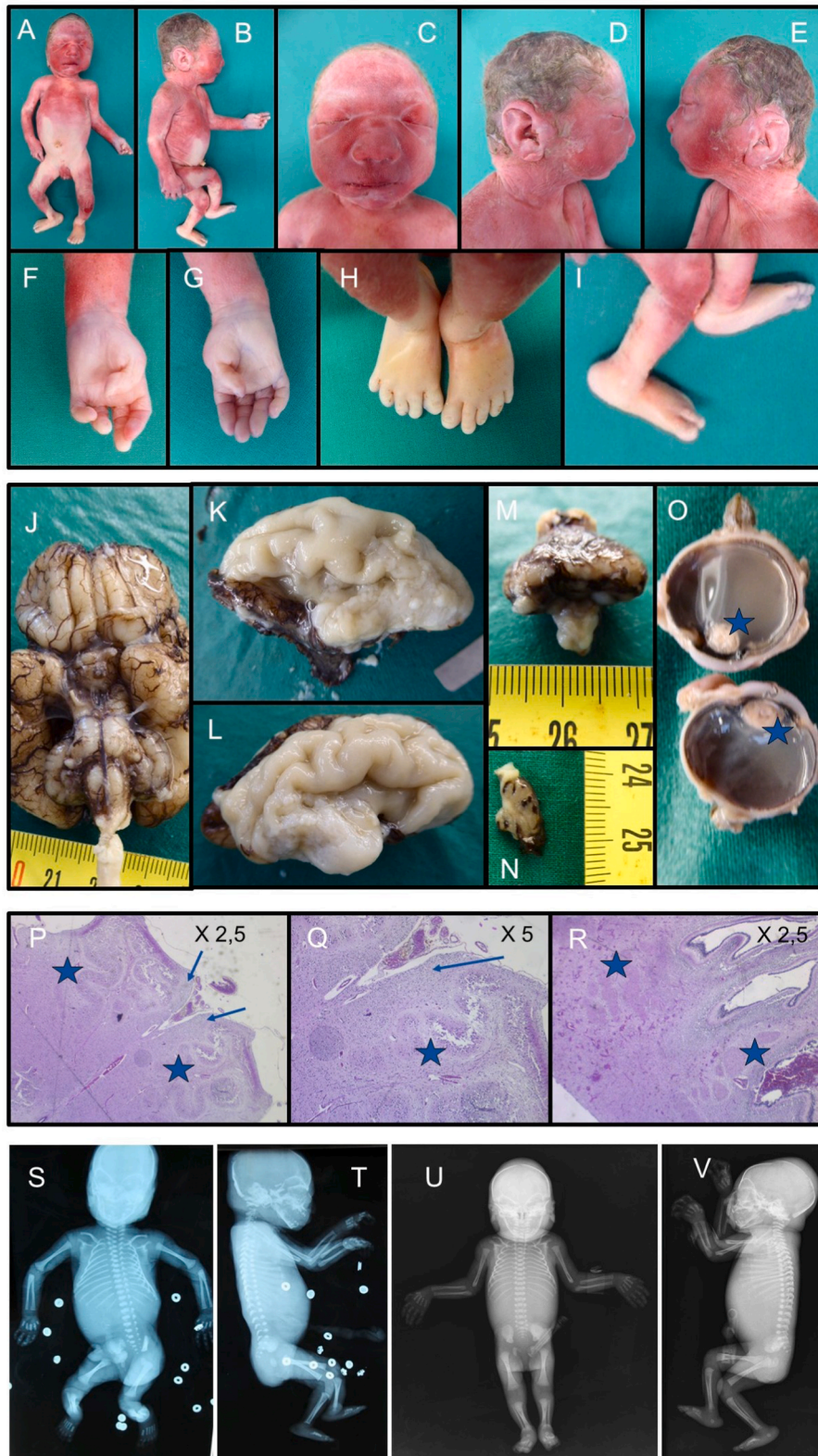

Fig. 2. Post-abortion findings. Fetal examination (fetus 1 A-I) at 32 WG revealed sloping forehead (B-D-E), hypertelorism (C), large dysplastic ears (D,E), wide nose (C), micrognathia (D,E), adducted thumbs (F,G), rocker bottom feet (I), macroscopic brain anomalies with spindly pyramids (J), simplified gyration with an open sylvian fissure (K,L), cerebellar hemispheres hypoplasia (M) and vermis (N), and bilateral cataract (O: asterisks). Neuropathological examination (HES staining) shows major hypoplasia of the pyramids (arrows) and the bulbar olives (asterisks) (P,Q) with fragmented dentate nuclei of the cerebellum (R: asterisks). Post-abortion skeletal radiographs show a delayed bone maturation in fetus 1 at 32 WG, with absence of talar, calcaneal and pubic ossification points (S,T) and in fetus 2 at 31 WG, with absence of talar calcification (U,V).

feet and arthrogryposis, associated with cerebral malformations, was suggestive of a sequence of severe fetal akinesia of neurological origin, and with a poor prognosis. Unlike the attenuated forms of NLS reported in two patients with prolonged survival (Shaheen et al., 2014; Abdelfattah et al., 2020), these fetuses did not present the classical dermatological features of NLS, i.e. ichthyosis, restrictive dermopathy, myxedematous infiltration, hand/feet edema, nor the major facial features, namely proptosis, ectropion, eclabion, round gaping mouth and flat nose. Interestingly, two fetuses with L-serine biosynthesis defect without dermatological features were also reported by Abdelfattah et al. (2020): These fetuses carried biallelic variants in *PSAT1*, mirroring our patients with 3-PGDH deficiency.

However, the severity of microcephaly and IUGR in these two fetuses was compatible with that encountered in microcephalic primordial dwarfism, and the association of sloping forehead, contractures, delayed bone maturation, delayed gyration and other CNS abnormalities had initially suggested a Taybi-Linder syndrome (TALS, or type 1 Microcephalic Osteodysplastic Primordial Dwarfism OMIM#210710), caused by biallelic mutations in *RNU4ATAC* (Edery et al., 2011; He et al., 2011) (OMIM#601428), with a striking overlap. According to these observations, TALS and other forms of microcephalic dwarfism should be considered as a differential diagnosis of NLS.

Our patients present an attenuated NLS form, extending the notion of the phenotypic continuum in serine biosynthesis defects. To date, 30 different pathogenic variants in *PHGDH* have been identified, and 13 variants showed NLS (Fu et al., 2022).

Patient 1 carries the combination of a p.(Ala257Leufs*51) truncating variant and a p.(Val425Met) missense variant already described in a patient with infantile L-serine biosynthesis defect (Klomp et al., 2000) at the homozygous state and in an exceptionally mild form with adult onset polyneuropathy (Méneret et al., 2012). It suggests that this missense variant could have a mild effect, explaining why the combination results in an attenuated form of NLS.

Likewise, the homozygous p.(Arg163Gln) variant found in patient 2 has already been reported in a NLS patient who survived 1 month (Shaheen et al., 2014). Arg163 is located in the NAD/NADP binding domain of 3-PGDH, and participates in the activation of the enzyme by homodimerization (Shaheen et al., 2014). The fact that this variant has already been described in one of the rare living forms of NLS, and in patient 1, an attenuated form, suggests some genotype-phenotype correlation.

Current observations are insufficient to corroborate strong variant-specific phenotypic associations, but the most obvious hypothesis would be that of a continuum of clinical severity between fetal and viable forms of 3-PGDH deficiency, correlated to residual enzyme activity. Indeed, the fact that biallelic complete loss-of-function was reported in only 3 cases, associated with severe fetal forms, supports this hypothesis (Mattos et al., 2015; Takeichi et al., 2018). Moreover, the ceramide biosynthesis, downstream of the L-serine biosynthesis pathway, shows such examples: in acid ceramidase deficiency (ASA1; MIM#613468), low residual enzyme activity is associated with Farber disease (MIM#228000) showing early multivisceral involvement, while higher residual activity seems responsible for spinal muscular atrophy with progressive myoclonic epilepsy (SMA-PME; #159950), with later onset and slower progression (Elsea et al., 2020). A continuum of severity based on residual acid sphingomyelinase enzyme activity (SMPD1; MIM#607608) would also explain the difference in phenotype between type A (MIM#257200, severe neurovisceral) and type B (MIM#607616, non-neuronopathic) Niemann-Pick disease (Pavlù-Perreira et al., 2005). This phenomenon could also explain the phenotypic discrepancy between neuronopathic Gaucher disease (MIM#230900) and non-neuronopathic (MIM#230800) due to beta-glucocerebrosidase deficiency (GBA; MIM#606463). It is interesting to note that the most severe forms of Gaucher disease sometimes present with neonatal ichthyosiform skin lesions with abnormalities of the stratum corneum (Sidransky et al., 1996) reminiscent of NLS (Takeichi et al., 2018).

Therefore, functional explorations assessing 3-PGDH activity for each described variant will be required to confirm the hypothesis of a genotype-phenotype correlation based on residual enzyme activity in L-serine biosynthesis defects. 3-PGDH activity has never been evaluated in NLS to our knowledge, but a similar approach was recently published, with a yeast-based assay for human PSAT1 function, allowing to evaluate the functional impact of 1,914 amino-acid substitutions in PSAT1 (Xie et al., 2023).

Modifying factors may exist, and among them, the serine intake during pregnancy could be decisive. Oral serine and glycine treatment in patients with viable serine biosynthesis defect shows rapid reduction of seizures (Jaeken et al., 1996; De Koning et al., 2002), but this treatment usually failed to improve head growth and neurocognitive development (Brassier et al., 2016). However, de Koning et al. (de Koning et al., 2004) reported one prenatal diagnosis for infantile serine biosynthesis defect, which allowed for early treatment in the mother from 20 WG. This resulted in the normalization of the fetal head circumference and a normal psychomotor development, without seizure at 4 years of age. Although the benefit of such intervention is unknown in the severe forms of 3-PGDH deficiency, this illustrates the importance of early diagnosis in L-serine biosynthesis defects.

5. Conclusion

We report on two fetuses with 3-PGDH deficiency, lacking the main facial and dermatological features of NLS, and compatible with microcephalic dwarfism. These observations extend the phenotypic continuum in L-serine biosynthesis defects to the boundary of viable and lethal forms and illustrate the overlap with microcephalic dwarfism.

Funding

The work was supported by Hospices Civils de Lyon (NewViTALS project, [ClinicalTrials.gov](https://clinicaltrials.gov) identifier (NCT number): NCT03222947)

Ethics declaration

According to the principles outlined in the Helsinki Declaration, written consent for genetic testing was obtained from the parents of the fetuses included in this study. Additional written consent for the publication of photographs was obtained for the fetus 1. The Hospices Civils de Lyon ethics committee approved the study. The Consultative Committee on Data Processing for Research in the Health Field (CCTIRS) and French National Commission for Data processing and individual liberties (CNIL) approved the consent forms. All these activities are subject to the competent Ethics Committee (CPP Comité de Protection des Personnes) and are the subject of a declaration/authorization with the French Ministry in charge of research.

CRedit authorship contribution statement

Silvestre Cuinat: designed the study and wrote the manuscript. **Chloé Quélin:** designed the study and wrote the manuscript, performed the fetal examination, were involved in the management of the families. **Laurent Pasquier:** were involved in the management of the families. **Philippe Loget:** performed the fetal examination. **Dominique Aussel:** were involved in the ultrasound diagnosis and prenatal care. **Sylvie Odent:** were involved in the management of the families. **Annie Laquerrière:** performed the fetal examination. **Maia Proisy:** were involved in the ultrasound diagnosis and prenatal care. **Sylvie Mazoyer:** have made substantial contributions to conception of the study. **Marion Delous:** have made substantial contributions to conception of the study. **Patrick Edery:** have made substantial contributions to conception of the study, All authors discussed the results and commented on the manuscript. **Nicolas Chatron:** performed the genetic studies. **Gaetan Lesca:** performed the genetic studies. **Audrey Putoux:** designed the study and

wrote the manuscript.

Declaration of competing interest

All authors declare that they have no conflict of interest.

Data availability

Data will be made available on request.

Acknowledgments

The authors are sincerely grateful to the families for participating in this study.

Appendix A. Supplementary data

Supplementary data to this article can be found online at <https://doi.org/10.1016/j.ejmg.2023.104852>.

References

- Abdelfattah, F., et al., 2020. Expanding the genotypic and phenotypic spectrum of severe serine biosynthesis disorders. *Hum. Mutat.* 41, 1615–1628.
- Acuna-Hidalgo, R., et al., 2014. Neu-laxova syndrome is a heterogeneous metabolic disorder caused by defects in enzymes of the L-serine biosynthesis pathway. *Am. J. Hum. Genet.* 95, 285–293.
- Bourque, D.K., et al., 2019. Neu-Laxova syndrome presenting prenatally with increased nuchal translucency and cystic hygroma: the utility of exome sequencing in deciphering the diagnosis. *Am. J. Med. Genet. A.* 179, 813–816.
- Brassier, A., et al., 2016. Two new cases of serine deficiency disorders treated with L-serine. *Eur. J. Paediatr. Neurol.* 20, 53–60.
- De Koning, T.J., et al., 2002. Congenital microcephaly and seizures due to 3-phosphoglycerate dehydrogenase deficiency: outcome of treatment with amino acids. *J. Inherit. Metab. Dis.* 25, 119–125.
- de Koning, T., et al., 2004. Prenatal and early postnatal treatment in 3-phosphoglycerate-dehydrogenase deficiency. *Lancet* 364, 2221–2222.
- Ederly, P., et al., 2011. Association of TALS developmental disorder with defect in minor splicing component *U4atac* snRNA. *Science* 332, 240–243.
- Elsea, S.H., et al., 2020. *ASAH1* pathogenic variants associated with acid ceramidase deficiency: Farber disease and spinal muscular atrophy with progressive myoclonic epilepsy. *Hum. Mutat.* 41, 1469–1487.
- Fu, J., Chen, L., Su, T., Xu, S., Liu, Y., 2022. Mild phenotypes of phosphoglycerate dehydrogenase deficiency by a novel mutation of *PHGDH* gene: case report and literature review. *Int. J. Dev. Neurosci.* jdn 10236. <https://doi.org/10.1002/jdn.10236>.
- He, H., et al., 2011. Mutations in *U4atac* snRNA, a component of the minor spliceosome, in the developmental disorder MOPD I. *Science* 332, 238–240.
- Jaeken, J., et al., 1996. 3-Phosphoglycerate dehydrogenase deficiency: an inborn error of serine biosynthesis. *Arch. Dis. Child.* 74, 542–545.
- Klomp, L.W.J., et al., 2000. Molecular characterization of 3-phosphoglycerate dehydrogenase deficiency—a neurometabolic disorder associated with reduced L-serine biosynthesis. *Am. J. Hum. Genet.* 67, 1389–1399.
- Mattos, E.P., et al., 2015. Identification of a premature stop codon mutation in the *PHGDH* gene in severe Neu-Laxova syndrome-evidence for phenotypic variability. *Am. J. Med. Genet. A.* 167, 1323–1329.
- Méneret, A., et al., 2012. A serine synthesis defect presenting with a charcot-marie-tooth-like polyneuropathy. *Arch. Neurol.* 69.
- Pavlů-Pereira, H., et al., 2005. Acid sphingomyelinase deficiency. Phenotype variability with prevalence of intermediate phenotype in a series of twenty-five Czech and Slovak patients. A multi-approach study. *J. Inherit. Metab. Dis.* 28, 203–227.
- Shaheen, R., et al., 2014. Neu-laxova syndrome, an inborn error of serine metabolism, is caused by mutations in *PHGDH*. *Am. J. Hum. Genet.* 94, 898–904.
- Sidrasky, E., et al., 1996. Epidermal abnormalities may distinguish type 2 from type 1 and type 3 of Gaucher disease. *Pediatr. Res.* 39, 134–141.
- Tabatabaie, L., Klomp, L.W., Berger, R., de Koning, T.J., 2010. L-Serine synthesis in the central nervous system: a review on serine deficiency disorders. *Mol. Genet. Metabol.* 99, 256–262.
- Takeichi, T., et al., 2018. Reduction of stratum corneum ceramides in Neu-Laxova syndrome caused by phosphoglycerate dehydrogenase deficiency. *J. Lipid Res.* 59, 2413–2420.
- Usher, R., McLean, F., 1969. Intrauterine growth of live-born Caucasian infants at sea level: standards obtained from measurements in 7 dimensions of infants born between 25 and 44 weeks. *J. Pediatr.* 74, 901–910.
- Xie, M.J., et al., 2023. Predicting the functional effect of compound heterozygous genotypes from large scale variant effect maps. *BioRxiv Prepr. Serv. Biol.* 2023 <https://doi.org/10.1101/2023.01.11.523651>, 01.11.523651.