



HAL
open science

Identification of rare variants in the FBXO38 gene of patients with chronic inflammatory demyelinating polyradiculoneuropathy

Antoine Pegat, Jean-Baptiste Chanson, Pierre Lozeron, Bastien Joubert, Alexandre Bani-Sadr, Isabelle Quadrio, Léo Vidoni, Philippe Latour

► To cite this version:

Antoine Pegat, Jean-Baptiste Chanson, Pierre Lozeron, Bastien Joubert, Alexandre Bani-Sadr, et al.. Identification of rare variants in the FBXO38 gene of patients with chronic inflammatory demyelinating polyradiculoneuropathy. *Journal of Neuroimmunology*, 2024, 392, pp.578381. 10.1016/j.jneuroim.2024.578381 . hal-04801796

HAL Id: hal-04801796

<https://hal.science/hal-04801796v1>


Submitted on 27 Jan 2025

HAL is a multi-disciplinary open access archive for the deposit and dissemination of scientific research documents, whether they are published or not. The documents may come from teaching and research institutions in France or abroad, or from public or private research centers.

L'archive ouverte pluridisciplinaire **HAL**, est destinée au dépôt et à la diffusion de documents scientifiques de niveau recherche, publiés ou non, émanant des établissements d'enseignement et de recherche français ou étrangers, des laboratoires publics ou privés.



Distributed under a Creative Commons Attribution - NonCommercial 4.0 International License



Short Communication

Identification of rare variants in the *FBXO38* gene of patients with chronic inflammatory demyelinating polyradiculoneuropathy

Antoine Pegat^{a,*}, Jean-Baptiste Chanson^b, Pierre Lozeron^c, Bastien Joubert^d, Alexandre Bani-Sadr^e, Isabelle Quadrio^f, Léo Vidoni^f, Philippe Latour^f

^a Service ENMG et de pathologies neuromusculaires, centre de référence des maladies neuromusculaires PACA-Réunion-Rhône Alpes, Hôpital Neurologique P. Wertheimer, Hospices Civils de Lyon, France

^b Département de neurologie, Hôpitaux universitaires de Strasbourg et centre de référence neuromusculaire Nord/Est/Ile de France, Strasbourg, France

^c Service de Physiologie clinique-Explorations fonctionnelles, Hôpital Lariboisière, APHP, Paris, France

^d Département de Neurologie, Hôpital Lyon Sud, Hospices Civils de Lyon, Lyon, France

^e Département de Neuroradiologie, Hôpital Neurologique P. Wertheimer, Hospices Civils de Lyon, France

^f Unité fonctionnelle de neurogénétique moléculaire, Groupement Hospitalier Est, Hospices Civils de Lyon, France

ARTICLE INFO

Keywords:

Chronic inflammatory demyelinating polyradiculoneuropathy
Genetic factor
FBXO38
Nerve hypertrophy
Ultrasonography

ABSTRACT

Chronic inflammatory demyelinating polyradiculoneuropathy (CIDP) is a rare immune-mediated neuropathy for which there is no clearly identified risk factor. The present study identified rare variants in the *FBXO38* gene in three familial cases of CIDP with response to corticosteroids in three generations with incomplete penetrance, and in an unrelated fourth case with diffuse nerve hypertrophy. *FBXO38* may be involved in the regulation of the immunity mediated by CD8 T cells, which have an important role in CIDP pathophysiology, through PD1 degradation. Considering these findings, *FBXO38* should be investigated as a potential genetic factor in larger cohorts of patients with CIDP.

1. Introduction

Chronic inflammatory demyelinating polyradiculoneuropathy (CIDP) is a rare immune-mediated neuropathy, with different clinical presentations (Van Den Bergh et al., 2021; Bunschoten et al., 2019). There is no risk factor clearly identified; some genetic predisposing factors, such as HLA, have been reported, although no clear association was established (Blum and McCombe, 2014). Patients with complex genetic diseases, especially those carrying *AIRE* or *CD59* mutations may present with CIDP-like neuropathies (Duchateau et al., 2019; Valenzise et al., 2017). However, since rare familial cases of inflammatory neuropathies have been described, the presence of a genetic risk factor has been questioned (Magy et al., 1997; Gabreels-Festen et al., 1986; Ullah et al., 2022).

In this report, we describe a family with three cases of CIDP in three generations and an unrelated fourth case, with rare variants in the *FBXO38* gene. This gene is included in the panel of genetic neuropathies, due to its association with rare cases of distal hereditary motor neuropathy (dHMN), a pure axonal motor neuropathy, with calf predominance (Sumner et al., 2013). *FBXO38* is an E3 ubiquitin ligase targeting

PD1, a protein of the PD1/PDL1 complex, an immune checkpoint, down-regulating the immune system and promoting self-tolerance by suppressing T cell inflammatory activity (Meng et al., 2018; Serman and Gack, 2019). T cells are the main immune cells involved in the pathophysiology of CIDP (Bunschoten et al., 2019). Furthermore, as immune check point inhibitor (ICI) (Okada et al., 2021), a therapy targeting the PD1/PDL1 complex used in cancer immunotherapy, is known to be a trigger of inflammatory polyradiculoneuropathy, we hypothesize that dysfunction of the PD1 pathway that may results from variants in *FBXO38* could induce CIDP.

2. Case series – clinical and paraclinical exams

2.1. Family 1 (familial pedigree, on Fig. 1):

2.1.1. Case 1

A 68-year-old female (I-1) presented with the subacute onset (in 3–4 months) of feet and legs hypoesthesia, and imbalance with slight distal weakness, with a demyelinating motor and sensory neuropathy on nerve conduction study (NCS). Cerebrospinal fluid (CSF) showed elevated

* Corresponding author at: Service ENMG et de pathologies neuromusculaires, Hôpital Neurologique P. Wertheimer, 59 boulevard Pinel, 69500 Bron, France.
E-mail address: antoine.pegat@chu-lyon.fr (A. Pegat).

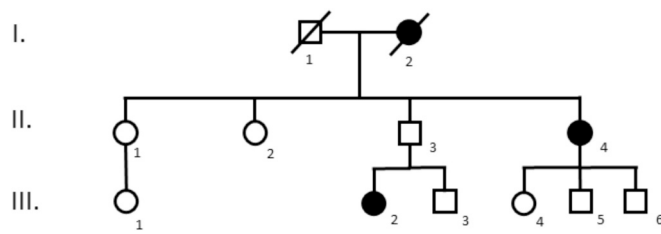


Fig. 1. Pedigrees of family 1.

Three patients had CIDP in this family (I-2, II-4, and III-2), and all carried the rare *FBXO38* variant, c.3125 A > G, p.(Asn1042Ser), except I-2 who was not tested.

protein levels at 0.7 g/L ($N < 0.5$ g/L). She was diagnosed with CIDP and treated with oral corticosteroids, which led to a good improvement, with a normal gait. In the subsequent years however, she experienced two relapses of paresthesia and walking difficulties as well as an episode of diplopia. The patient experienced an incomplete regression of symptoms with continuous need for treatment (20 mg/day of oral corticosteroids). She died at 83 years old.

2.1.2. Case 2

A 57-year-old female (II-4), daughter of case 1 (I-1), presented at the age of 35 a first episode of moderate imbalance and hypoesthesia of four limbs without work-up nor treatment. Two years later, she was hospitalized for a new episode of four limbs dysesthesia that appeared 2 months ago and imbalance that appeared 1 week ago. Proximal and distal weakness with abolished stretch reflex at lower limbs was noted. Overall Neuropathy Limitations Scale (ONLS) was evaluated at 7/12 [3/5 for upper limbs (UL) and 4/7 for lower limbs (LL)]. CSF revealed elevated protein levels at 1.73 g/L, and NCS showed demyelination sensory and motor neuropathy with conduction blocks on several nerves (Supplementary table). The laboratory work up was unremarkable, especially normal anti-gangliosides antibodies. A final diagnosis of typical CIDP was made, retrospectively fulfilling EAN/PNS 2021 criteria (Van Den Bergh et al., 2021). She was treated by intravenous immunoglobulins (IVIg) without improvement. Oral corticosteroids (1 mg/kg per day) were clinically effective with improvement of ONLS at 3/12. However, walking difficulties and quadriparesis reappeared several times (maximum ONLS at 6/12) during the six following months, when corticosteroids dosage was decreased and even stopped due to poor tolerance. Mycophenolate mofetil and then azathioprine were administered but not tolerated. Corticosteroids were reintroduced at a dose of 20 to 40 mg/day and the patient was stable until 44 years of age (ONLS at 4/12). Then, she developed a diplopia and new proximal lower limbs weakness (ONLS 6/12) with a good response (ONLS 4/12) to an increase in corticosteroid treatment (1 mg/kg). Treatment was progressively diminished. Immunological tests including antibodies anti-neurofascin 155 (NF-155), anti-contactin 1, anti-contactin-associated protein 1 (CASPR1), and anti-neurofascin 186 (NF186) were negative. Subsequent NCS at the age of 56 showed a predominantly axonal neuropathy with improvement of demyelinating abnormalities.

2.1.3. Case 3

A 31-year-old female (III-2), niece of case 2 (II-4), presented at the age of 18 with rapidly progressive (in 6 months) gait and balance disorder with weakness of four limbs. Motor deficit of dorsal and plantar flexions of feet and dorsal interossei muscles were observed as well as hypoesthesia of four limbs and abolished reflexes of lower limbs. ONLS was evaluated at 4/12 (2 for UL and 2 for LL). NCS revealed a demyelinating sensory and motor neuropathy, with conduction blocks (Supplementary table), retrospectively fulfilling EAN/PNS 2021 criteria (Van Den Bergh et al., 2021). CSF revealed elevated protein levels at 0.92 g/L. Anti-gangliosides antibodies were negative. Several courses of IVIg subsequent to the CIDP diagnosis allowed a partial improvement during

three years (ONLS 1/12). However, new episodes of milder gait disorders and weakness that occurred during the three following years led to several course of IVIg. Oral corticosteroids (1 mg/kg following by progressive tapering) were tried when she was 21 years old and led to additional improvement but were stopped due to poor tolerance. IVIg were again administered between her 22 and 25 years of age. Since, she experienced relapses two or three times a year, treated with corticosteroids (1 mg/kg, with progressive tapering) and requiring a temporarily walking aid for recurrences of gait ataxia.

In this family, the male patient (II-3), son of case 1 (I-2) and father of case 3 (III-2; Fig. 1), presented no sign nor symptom of neuropathy, and a normal NCS. This male patient progressively developed a cerebellar syndrome at adulthood, without argument for autoimmune cerebellar ataxia. However, a genetic cause was suspected but not confirmed by a large genetic exploration for cerebellar ataxia.

2.2. Family 2

2.2.1. Case 4

A 73-year-old female presented with low back pain with S1 bilateral radicular pain and feet paresthesia with imbalance for three weeks. Fifteen years ago, she had a breast cancer treated using non-neurotoxic chemotherapy. Few weeks after the onset of chemotherapy, she presented with extended paresthesia on the lower limbs and imbalance without weakness that developed in 48 h. NCS showed clear arguments for multifocal demyelination in sensory and motor nerves. An initial diagnosis of acute inflammatory demyelinating neuropathy (AIDP) was made and she was treated by IVIg, which allowed a complete clinical recovery that was followed by a relapse of the symptoms after 3 months. Hence, a second course of IVIg was administered and led to a novel complete clinical recovery. During the last control of NCS, 26 months after onset, a persistent demyelinating neuropathy with clear improvement was found.

The clinical examination performed at 73 years old, when she experienced the radicular pain, found slight weakness of dorsal feet flexion and hallux extension, distal diminished sense of vibration, and absent Achilles reflex, without pes cavus nor leg atrophy. She had no symptom/sign on upper limb, including no tremor. A cauda equina tumor was suspected after a first lumbar MRI. The MRI of the brachial and lumbosacral plexuses revealed significant hypertrophy of all peripheral nerve structures without nodular thickening nor enhancement after contrast medium injection, suggesting CIDP (Fig. 2). NCS revealed a multifocal sensory and motor demyelinating neuropathy, with proximal conduction block, with secondary axonal damage (Supplementary table), and a few distal fibrillation potentials in needle electromyography. Nerve ultrasonography confirmed a diffuse nerve enlargement of median nerve and trunks, which was in favor of CIDP (Van Den Bergh et al., 2021) (Fig. 2). CSF showed 5 cells/mm³ and major elevated protein levels at 45 g/L. Immunological tests including antibodies anti-NF-155, anti-contactin1, anti-CASPR1, and anti-NF186 were negative. A corticosteroid treatment was proposed but declined by the patient. At 6 months after onset, she had no radicular pain, she kept only distal paresthesia and weakness of dorsal feet flexion, as well as hallux extension at MRC (medical research council scale) 3/5, a slight proprioceptive ataxia, with Rasch-built Overall Disability Score (RODS) at 44/48, and ONLS at 1/12.

2.3. Genetics analyses

The analysis of 104 genes involved in hereditary neuropathies (including genes *SH3TC2*, *FIG. 4*, *SIMPLE/LITAF*, *PLEKHG5*, *MPZ*, and *GJB1*) using next generation sequencing (NGS) was performed in case 2 (II-4) and case 3 (III-2, Fig. 1) of family 1 as well as in case 4 and in her asymptomatic brother. In family 1, in II-4 and III-2, no pathogenic, nor probably pathogenic variant was found, but a rare variant of undetermined significance (VUS) was identified in the *FBXO38* gene:

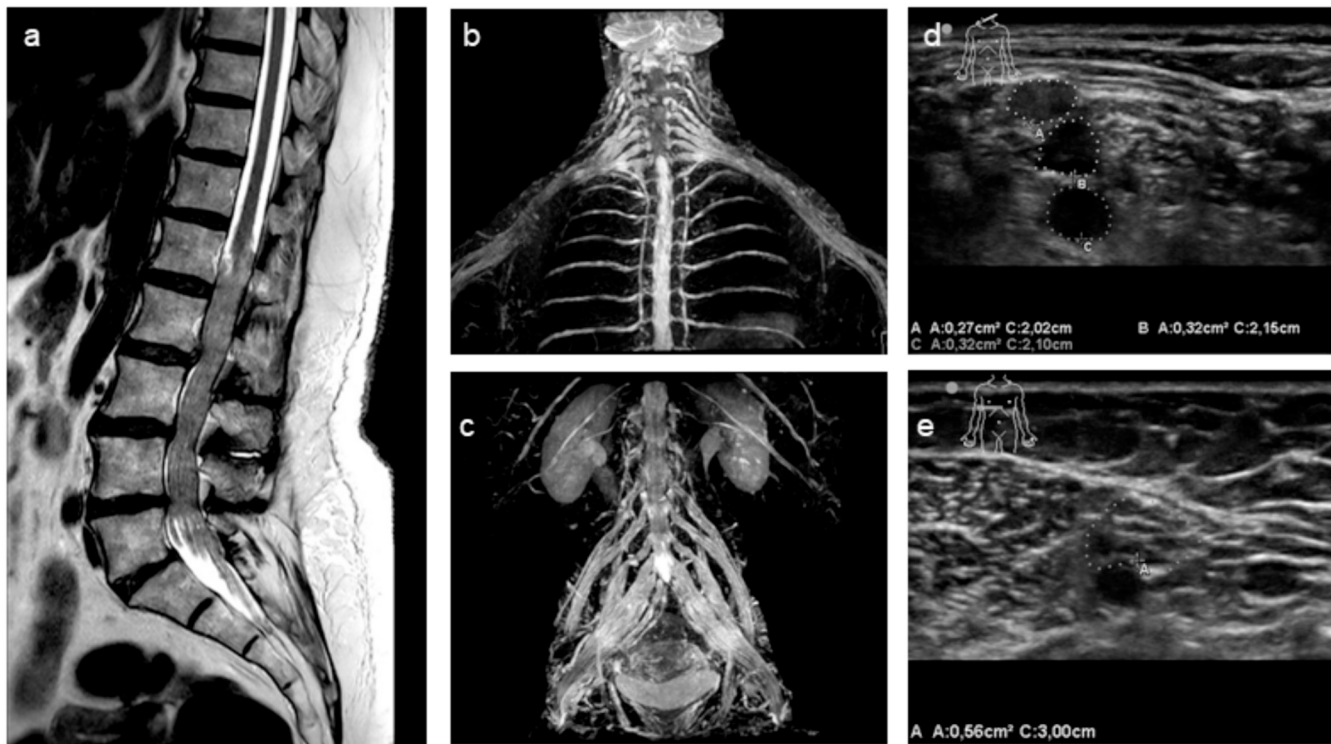


Fig. 2. Nerve, Roots and plexus MRI or/and ultrasonography of case 4 (family 2).

(a) Spinal MRI T2 images (sagittal) revealed hypertrophy of the cauda equina roots, presenting a “pseudo-tumoral” appearance. (b) MR Neurography of brachial plexuses (3D T2-Nerve View) revealed hypertrophy of the entire cervical and dorsal roots, brachial plexus, and intercostal nerves. (c) MR Neurography of lumbosacral plexuses (3D T2-Nerve View) revealed hypertrophy of the lumbar roots and lumbosacral brachial plexuses. (d) Nerve ultrasonography of the brachial plexus (interscalene): upper, middle, and lower trunk enlargement with cross-sectional area (CSA) was 27, 32, and 32mm², respectively (nerve enlargement suggesting CIDP whether CSA >9mm² for trunk (Van Den Bergh et al., 2021). (e) Nerve ultrasonography of the median nerve, at middle arm enlargement with CSA was 56mm² (nerve enlargement suggesting CIDP whether CSA for median nerve at middle arm >13mm² (Van Den Bergh et al., 2021). Also, median nerve enlargement with CSA was 27mm² at forearm and 53mm² at wrist (nerve enlargement suggesting CIDP whether CSA for median nerve at forearm >10mm² (Van Den Bergh et al., 2021). At wrist normal value is <10mm² (data not shown for these two values).

NM_030793.4(*FBXO38*):c.3125 A > G, p.(Asn1042Ser). This variant was confirmed using Sanger sequencing, and cause the substitution of an asparagine by a serine at residue 1042. It is absent from the Genome Aggregation Database (gnomAD), and was predicted “uncertain” by REVEL and “likely benign” by AlphaMissense. The asparagine residue is highly conserved throughout species. The patient I-1 was not available for genetic analysis, neither the subject II-3. However, since II-3 is the father of III-2 and the brother of II-4, who carry this variant, II-3 necessarily also carry this variant.

In case 4 (family 2), the genetic analysis was performed due to a more severe alteration of NCS compared to few clinical signs/symptoms, and diffuse major nerve enlargement. The NGS analysis did not identify pathogenic, nor probably pathogenic variant, but a rare VUS was identified in the *FBXO38* gene: NM_030793.4(*FBXO38*):c.3247C > T, p.(Arg1083Cys), which was found at a very low frequency (0.0015%) in gnomAD. This corresponds to an occurrence of 4, which is not incompatible with a deleterious effect on the protein. For instance, confirmed pathogenic variants involved in neuropathies are found in the gnomAD with occurrences of up to 13 (eg: NM_000530.8(*MPZ*): c.434 A > C, p.Tyr145Ser or NM_001540.5(*HSPB1*): c.116C > T, p.Pro39Leu). The VUS variation in *FBXO38* was predicted “uncertain” by REVEL and “likely pathogenic” by AlphaMissense. The arginine residue is highly conserved throughout species. This variant was not found in her brother, without demyelinating neuropathy on NCS. Other siblings were not available for NCS or/and genetic analysis.

3. Discussion

The present study identified rare variants in the *FBXO38* gene of patients with CIDP; the c.3125 A > G variant was found in patients from different generations of a family and the c.3247C > T variant was found in an unrelated case. Cases from family 1 showed no or insufficient response to IVIg but exhibited a positive response to corticosteroids. Penetrance was incomplete, as an individual (II-3) did not have clinical, nor electrophysiological evidence of neuropathy. All patients were female although there is no clear pathophysiological explanation for a female-susceptibility. Multifocal demyelinating abnormalities and their improvement in NCS, the acute/subacute relapses, the improvement of clinical signs using corticosteroids, the absence of osteoarticular deformities were rather in favor of CIDP and argued against a Charcot-Marie-Tooth (CMT) diagnosis. Of note, genes involved in CMT - including *SH3TC2*, *FIG. 4*, *SIMPLE/LITAF*, *PLEKHG5*, *MPZ*, and *GJB1* - that can lead to CIDP misdiagnosis due to non-uniform conduction slowing have been analyzed and did not carry any variant (Uncini et al., 2024). The unrelated case had a particularly intriguing form of CIDP, characterized by a diffuse and major hypertrophy throughout the peripheral nervous system, comprising root, plexus as well as proximal and distal parts of nerve, with markedly elevated protein levels in CSF at 45 g/L. Cases from family 1 did not undergo nerve MRI or ultrasonography.

FBXO38 plays an important role in the regulation of the anti-tumor immunity mediated by CD8 T cells since *FBXO38* participates in PD1 degradation through ubiquitination (Meng et al., 2018; Serman and Gack, 2019). In cancer, PDL1 is expressed on the surface of cancer cells and binds to PD1 that is expressed on the surface of T cells, which leads

to the inhibition of the T cells response (Meng et al., 2018, Serman and Gack, 2019). During neoplasia, *FBXO38* is downregulated in tumor-infiltrating CD8 T cells, resulting in an increased expression of PD1 on the surface of T cells and the suppression of anti-tumor immune responses (Meng et al., 2018, Serman and Gack, 2019). The use of ICIs, such as anti-PD1 and anti-PDL1, in cancer treatment disrupts this PD1/PDL1 binding, restoring the immune response of T cells against cancer cells (Okada et al., 2021). However, ICIs may induce several autoimmune complications including CIDP (Okada et al., 2021). This possible dysfunction of the PD1 pathway due to variants in *FBXO38* could induce CIDP in patients presented herein.

In addition to its role in T cells regulation, *FBXO38* is a coactivator of the transcription factor KLF7, which is crucial for neuronal axon outgrowth and repair, which could explain its association with dHMN (Sumner et al., 2013). Patients presented with progressive length-dependent muscular weakness with an axonal motor neuropathy (without demyelinating features) at NCS (Sumner et al., 2013; Grunseich et al., 2021; Akçimen et al., 2019).

In dHMN cases as well as in CIDP cases, variants were located in different regions of the gene. Variant c.616 T > C linked to dHMN is located near a region with a signaling function, specifically the second nuclear export signal (NES) domain (Sumner et al., 2013). In contrast, the variants found in patients with CIDP were located near a nuclear localization signal (NLS). These disparities in variant locations may suggest different pathophysiological roles, potentially associated with different phenotypes.

To our knowledge, cases of inflammatory demyelinating neuropathy mimicking CIDP or AIDP/Guillain-Barré syndrome (GBS) have been rarely described in the same family; in 1986 two siblings with possible CIDP at a young age were reported (Gabreels-Festen et al., 1986). Although nerve biopsy findings suggested an inflammatory component, a genetic testing was not performed, thus a potential hereditary demyelinating neuropathy was not excluded (Gabreels-Festen et al., 1986). Furthermore, the occurrence of GBS within the same family has been rarely reported (Ullah et al., 2022), leading to consider a potential genetic predisposition coupled with environmental factors. Moreover, a French family of eight members with AIDP triggered by fever were described (Magy et al., 1997); the genetic analysis of *FBXO38* was performed on a patient from this family, yet no variant was identified. It was reported that patients with proven genetic demyelinating neuropathies could present with an additional inflammatory neuropathy like CIDP or AIDP; responsive to immunotherapies (Kokubun, 2020), showing the close links between genetics and acquired factors in demyelinating neuropathies.

Genetic factors may be involved in the pathophysiology of CIDP. Specifically, patients with rare genetic diseases may develop CIDP-like neuropathy, especially those with mutations in *CD59* or *AIRE* genes. In children with inherited chronic hemolysis who carried *CD59* mutations, CIDP-like neuropathy has been described; although no mutation in *CD59* was found in 35 patients with isolated CIDP (Duchateau et al., 2019). Additionally, rare cases of patients with Autoimmune polyendocrinopathy-candidiasis-ectodermal-dystrophy (APECED), a rare primary immunodeficiency disorder, due to homozygous mutation in *AIRE* gene developed CIDP at a young age (Valenzise et al., 2017). Genetic susceptibility to CIDP has been studied, especially for HLA genes, but there is no clear HLA association in either GBS or CIDP (Blum and McCombe, 2014). Polymorphisms of *CD1* and *SH2D2A* associated with inflammatory neuropathies have been suspected but not confirmed (Blum and McCombe, 2014). Additionally, rare monoallelic variants in *PRF1* (encoding Perforin) have been identified as risk factor to develop autoimmune diseases such as CIDP (Buttini et al., 2015).

Penetrance of CIDP was incomplete, the subject (II-3) had no neuropathy, but surprisingly he had also a neurological disease with a chronic cerebellar ataxia having a suspected genetic origin, without argument for cerebellitis. A link between his cerebellar ataxia and *FBXO38* could be discussed, since cerebellitis are also a rare

complication of ICI (Dinoto et al., 2023). However, cerebellar ataxia was not described in patients with dHMN associated with variant in the gene *FBXO38*. Unfortunately, there was no genetic data available for the unaffected individuals of the family 1. Hence, it is difficult to evaluate the penetrance or the segregation of the disease with the variant. It would be interesting to perform additional studies, in animal models for example, to add arguments to the present pathophysiological hypothesis.

4. Conclusion

To conclude, herein we presented familial cases of CIDP with incomplete penetrance and an unrelated case of CIDP, with possible extensive major nerve hypertrophy, all were females and carried rare variants of *FBXO38*. These findings raise questions regarding *FBXO38* as a potential genetic risk factor for CIDP. This gene should be investigated in larger cohorts of patients with CIDP, and in rare familial cases of inflammatory neuropathies.

Funding

This research did not receive any specific grant from funding agencies in the public, commercial, or not-for-profit sectors.

CRediT authorship contribution statement

Antoine Pegat: Writing – review & editing, Writing – original draft, Investigation, Data curation, Conceptualization. **Jean-Baptiste Chanon:** Writing – review & editing, Validation, Data curation. **Pierre Lozeron:** Writing – review & editing, Validation, Data curation. **Bastien Joubert:** Writing – review & editing, Investigation. **Alexandre Bani-Sadr:** Writing – review & editing, Investigation. **Isabelle Quadrio:** Writing – review & editing, Investigation. **Léo Vidoni:** Writing – review & editing, Investigation. **Philippe Latour:** Writing – review & editing, Investigation.

Declaration of competing interest

None.

Data availability

Data will be made available on request.

Acknowledgements

The authors thank Shanez HAOUARI for help in manuscript preparation (Direction de la Recherche Clinique, Hospices Civils de Lyon, France).

Appendix A. Supplementary data

Supplementary data to this article can be found online at <https://doi.org/10.1016/j.jneuroim.2024.578381>.

References

- Akçimen, F., Vural, A., Durmuş, H., Çakar, A., Houlden, H., Parman, Y.G., Nazlı Bağak, A., 2019. A novel homozygous *FBXO38* variant causes an early-onset distal hereditary motor neuropathy type IID. *J. Hum. Genet.* 64, 1141–1144. <https://doi.org/10.1038/s10038-019-0652-y>.
- Blum, S., McCombe, P.A., 2014. Genetics of Guillain-Barré syndrome (GBS) and chronic inflammatory demyelinating polyradiculoneuropathy (CIDP): current knowledge and future directions. *J. Peripheral. Nervous. Sys.* 19, 88–103. <https://doi.org/10.1111/jns5.12074>.
- Bunschoten, C., Jacobs, B.C., Van Den Bergh, P.Y.K., Cornblath, D.R., Van Doorn, P.A., 2019. Progress in diagnosis and treatment of chronic inflammatory demyelinating

- polyradiculoneuropathy. *Lancet Neurol.* 18, 784–794. [https://doi.org/10.1016/S1474-4422\(19\)30144-9](https://doi.org/10.1016/S1474-4422(19)30144-9).
- Buttini, S., Cappellano, G., Ripellino, P., Briani, C., Cocito, D., Osio, M., Cantello, R., Dianzani, U., Comi, C., 2015. Variations of the perforin gene in patients with chronic inflammatory demyelinating polyradiculoneuropathy. *Genes Immun.* 16, 99–102. <https://doi.org/10.1038/gene.2014.59>.
- Dinoto, A., Mantovani, E., Ferrari, S., Mariotto, S., Tamburin, S., 2023. Cerebellar involvement associated with immune checkpoint inhibitors: a systematic review. *Eur. J. Neurol.* 30, 774–781. <https://doi.org/10.1111/ene.15624>.
- Duchateau, L., Martín-Aguilar, L., Lleixà, C., Cortese, A., Dols-Icardo, O., Cervera-Carles, L., Pascual-Goni, E., Diaz-Manera, J., Calegari, I., Franciotta, D., Rojas-García, R., Illa, I., Clarimon, J., Querol, L., 2019. Absence of pathogenic mutations in CD59 in chronic inflammatory demyelinating polyradiculoneuropathy. *PLoS One* 14, e0212647. <https://doi.org/10.1371/journal.pone.0212647>.
- Gabreels-Festen, A.A., Hageman, A.T., Gabreels, F.J., Joosten, E.M., Renier, W.O., Weemaes, C.M., Ter Laak, H.J., 1986. Chronic inflammatory demyelinating polyneuropathy in two siblings. *J. Neurol. Neurosurg. Psychiatry* 49, 152–156. <https://doi.org/10.1136/jnnp.49.2.152>.
- Grunseich, C., Sarkar, N., Lu, J., Owen, M., Schindler, A., Calabresi, P.A., Sumner, C.J., Roda, R.H., Chaudhry, V., Lloyd, T.E., Crawford, T.O., Subramony, S.H., Oh, S.J., Richardson, P., Tanji, K., Kwan, J.Y., Fischbeck, K.H., Mankodi, A., 2021. Improving the efficacy of exome sequencing at a quaternary care referral Centre: novel mutations, clinical presentations and diagnostic challenges in rare neurogenetic diseases. *J. Neurol. Neurosurg. Psychiatry* 92, 1186–1196. <https://doi.org/10.1136/jnnp-2020-325437>.
- Kokubun, N., 2020. Charcot–Marie–tooth disease and neuroinflammation. *Clin. Exp. Neuroim.* 11, 109–116. <https://doi.org/10.1111/cen3.12566>.
- Magy, L., Birouk, N., Vallat, J.M., Gouider, R., Maisonobe, T., Bouche, P., Lyon-Caen, O., Fontaine, B., 1997. Hereditary thermosensitive neuropathy: an autosomal dominant disorder of the peripheral nervous system. *Neurology* 48, 1684–1690. <https://doi.org/10.1212/WNL.48.6.1684>.
- Meng, X., Liu, Xiwei, Guo, X., Jiang, S., Chen, T., Hu, Z., Liu, H., Bai, Y., Xue, M., Hu, R., Sun, S., Liu, Xiaolong, Zhou, P., Huang, X., Wei, L., Yang, W., Xu, C., 2018. FBXO38 mediates PD-1 ubiquitination and regulates anti-tumour immunity of T cells. *Nature* 564, 130–135. <https://doi.org/10.1038/s41586-018-0756-0>.
- Okada, K., Seki, M., Yaguchi, H., Sakuta, K., Mukai, T., Yamada, S., Oki, K., Nakahara, J., Suzuki, S., 2021. Polyradiculoneuropathy induced by immune checkpoint inhibitors: a case series and review of the literature. *J. Neurol.* 268, 680–688. <https://doi.org/10.1007/s00415-020-10213-x>.
- Serman, T.M., Gack, M.U., 2019. FBXO38 drives PD-1 to destruction. *Trends Immunol.* 40, 81–83. <https://doi.org/10.1016/j.it.2018.12.005>.
- Sumner, C.J., d'Ydewalle, C., Wooley, J., Fawcett, K.A., Hernandez, D., Gardiner, A.R., Kalmar, B., Baloh, R.H., Gonzalez, M., Züchner, S., Stanescu, H.C., Kleta, R., Mankodi, A., Cornblath, D.R., Boylan, K.B., Reilly, M.M., Greensmith, L., Singleton, A.B., Harms, M.B., Rossor, A.M., Houlden, H., 2013. A dominant mutation in FBXO38 causes distal spinal muscular atrophy with calf predominance. *Am. J. Hum. Genet.* 93, 976–983. <https://doi.org/10.1016/j.ajhg.2013.10.006>.
- Ullah, A., Khan, S., Humayun, O., Ullah, S., Fatima, N., 2022. Simultaneous occurrence of Guillain-Barré syndrome in three members of the same family: a case report. *Cureus.* <https://doi.org/10.7759/cureus.29356>.
- Uncini, A., Cavallaro, T., Fabrizi, G.M., Manganelli, F., Vallat, J., 2024. Conduction slowing, conduction block and temporal dispersion in demyelinating, dysmyelinating and axonal neuropathies: electrophysiology meets pathology. *J. Peripheral. Nervous. Sys. jns.12625* <https://doi.org/10.1111/jns.12625>.
- Valenzise, M., Aversa, T., Salzano, G., Zirilli, G., De Luca, F., Su, M., 2017. Novel insight into chronic inflammatory demyelinating polyneuropathy in APECED syndrome: molecular mechanisms and clinical implications in children. *Ital. J. Pediatr.* 43, 11. <https://doi.org/10.1186/s13052-017-0331-6>.
- Van Den Bergh, P.Y.K., Van Doorn, P.A., Hadden, R.D.M., Avau, B., Vankrunkelsven, P., Allen, J.A., Attarian, S., Blomkwist-Markens, P.H., Cornblath, D.R., Eftimov, F., Goedee, H.S., Harbo, T., Kuwabara, S., Lewis, R.A., Lunn, M.P., Nobile-Orazio, E., Querol, L., Rajabally, Y.A., Sommer, C., Topaloglu, H.A., 2021. European academy of neurology/peripheral nerve society guideline on diagnosis and treatment of chronic inflammatory demyelinating polyradiculoneuropathy: report of a joint task force—second revision. *Eur. J. Neurol.* 28, 3556–3583. <https://doi.org/10.1111/ene.14959>.