



HAL
open science

Fatal poisoning with *Rhamnus alaternus* in two heifers

Tiphaine Blanchard, Bérengère Garapin, Francois Schelcher, Fabien Corbière,
Nathalie Priymenko

► **To cite this version:**

Tiphaine Blanchard, Bérengère Garapin, Francois Schelcher, Fabien Corbière, Nathalie Priymenko. Fatal poisoning with *Rhamnus alaternus* in two heifers. ESVCN logo European Society of Veterinary & Comparative Nutrition Congress 2022, Sep 2022, Basel, Switzerland. hal-04799643

HAL Id: hal-04799643

<https://hal.science/hal-04799643v1>

Submitted on 23 Nov 2024

HAL is a multi-disciplinary open access archive for the deposit and dissemination of scientific research documents, whether they are published or not. The documents may come from teaching and research institutions in France or abroad, or from public or private research centers.

L'archive ouverte pluridisciplinaire **HAL**, est destinée au dépôt et à la diffusion de documents scientifiques de niveau recherche, publiés ou non, émanant des établissements d'enseignement et de recherche français ou étrangers, des laboratoires publics ou privés.

Fatal poisoning with *Rhamnus alaternus* in two heifers

Blanchard T¹, Garapin B¹, Schelcher F¹, Corbière F¹, Priymenko N^{1,2}
¹ENVT, ²TOXALIM, INRAE, INP-EIP, UPS; nathalie.priymenko@envt.fr

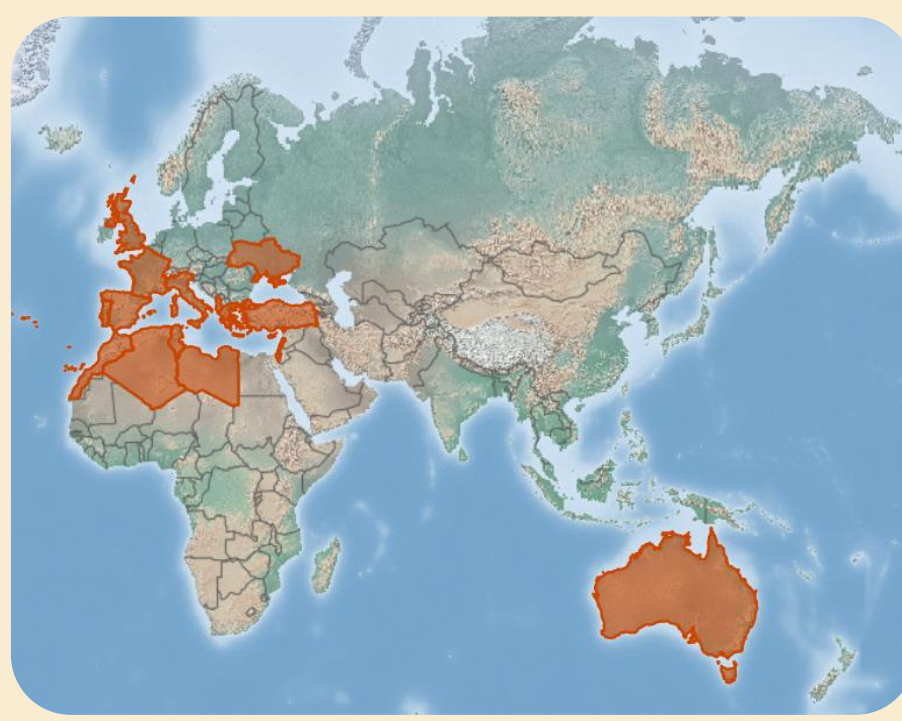
1 INTRODUCTION

Rhamnus alaternus is an evergreen shrub from Rhamnaceae family, also known as "Mediterranean buckthorn" or "Italian buckthorn".



Duhamel, Redouté (1801)

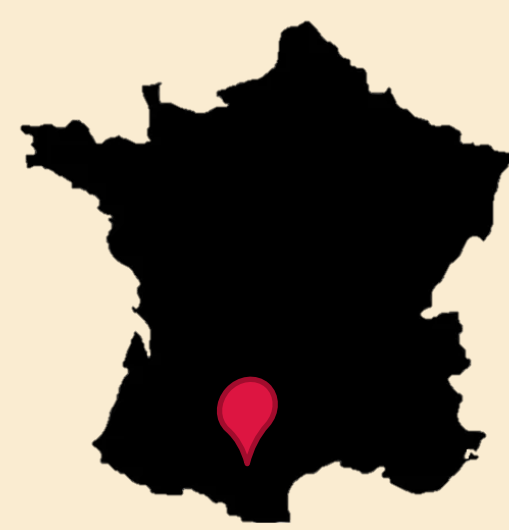The distribution of the plant is concentrated around the Mediterranean Sea, its area of origin. It has been introduced by man in other countries, perhaps for its medicinal virtues



CABI (2022)

2 CASE HISTORY

In late January 2022, two 400 kg Aubrac heifers were found dead in their meadow.



Both animals were in good general condition, with no clinical signs before death.

No clinical signs were reported in the other 3 heifers and 20 mature cows in the herd.

3 NECROPSY

Whole carcass:

- Severe dehydration
- Diffuse congestion

Epicardial fat:

- Petechiae

Endocardium:

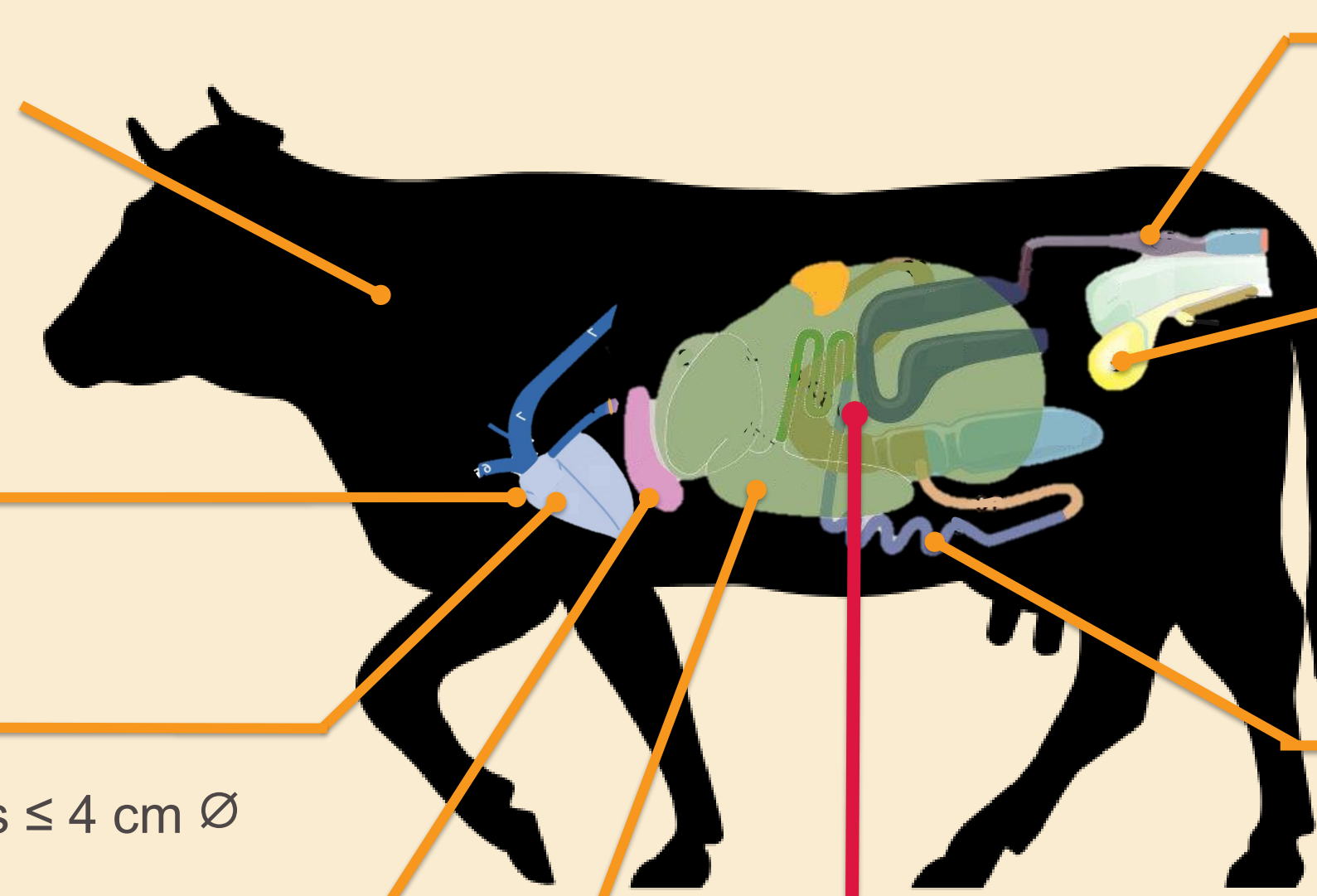
- Multifocal suffusions ≤ 4 cm Ø

Liver:

- Mild hepatic cytolysis

Abomasum:

- Haemorrhagic foci ≤ 5 cm Ø
- Pasty and greenish contents



Colon:

- Grey liquid contents with some fibers

Bladder contents:

- Yellow-green urine
- Specific gravity 1.010
- pH 8.5
- Proteins and positive peroxidase activity

Small intestine:

- Greenish to reddish liquid contents

Images from Boos (2013)

Rumen contents:

- Strong aromatic odour
- pH 6.1
- Multiple lanceolate, serrated leaves



600g sample


Phyllirea latifolia leaves



non-toxic plant

Real size

Rhamnus alaternus leaves



toxic plant

6g

Real size

4 BOTANICAL ANALYSIS

- As *Rhamnus alaternus* and *Phyllirea latifolia* are likely to be confused, a botanical analysis on site by a specialist was necessary to find and remove buckthorn and to estimate the consumption by the herd.
- There was storm and persistent heavy rains the day the two heifers died and were found 50 m near the only grove with *Rhamnus alaternus*. The other cows in the herd had taken shelter in another grove.

Cow shed

Two racks:

- ad-libitum good quality grassland
- ad-libitum alfalfa hays

Location where the second heifer was found dead

Location where the autopsied heifer was found dead

Meadow:


- 20 hectares
- dry grassland type
- groves of Mediterranean trees with shrubs

Location of *Phyllirea latifolia*



Traces of consumption

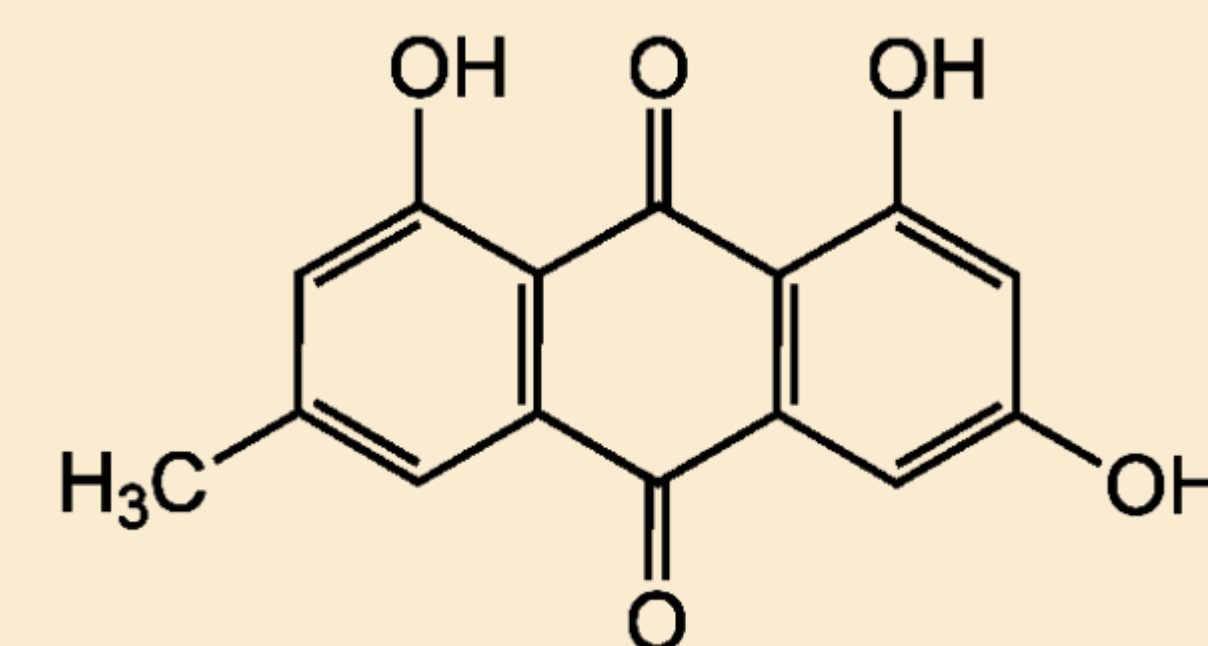
Location of *Rhamnus alaternus*



Traces of consumption

5 DISCUSSION

Toxicity of RA is believed to be caused by the anthraquinones^[1], especially emodin^[2].



Emodin molecule

Emodin can be found in humans' urines until 12 hours after consumption^[3]; urine emodin dosage may have been useful in the diagnosis of buckthorn poisoning.

Several plants containing anthraquinones are already suspected of hepatotoxicity^[4], including *Rhamnus* species: *Rhamnus purshiana*^[5] and *Rhamnus cathartica*^[6]. In the present case report, necropsy revealed a mild hepatic cytolysis, so *Rhamnus alaternus* should also be considered as a hepatotoxic plant.

Buckthorn, although considered poisonous, is widely used in herbal human medicine to treat jaundice^[7] but after excessive use, a case of intoxication has been described in a man^[8].

6 CONCLUSION

- Several sudden deaths happened in a herd.
- Necropsy revealed: diffuse congestion of the carcass + leaves of buckthorn in the rumen.
- Eaten buckthorns were found under cover of rain and sun in the woods.
- Heifers which took shelter in a grove without buckthorn did not die.

➤ First reported case of a non-human *Rhamnus alaternus* poisoning

References:

- [1] Kosalec et al. (2013) Food Chem.;
- [2] Brenes et al. (2022) J. Wildl. Dis.;
- [3] Stolk et al. (1999), Pharm. World Sci.;
- [4] Posadzki et al. (2013) Clin. Med. Lond. Engl.;

- [5] García-Cortés et al. (2008) Rev. Espanola Enfermedades Patol. Dig.;
- [6] Lichtensteiger et al. (1997), Toxicol. Pathol.;
- [7] Elyebdri et al. (2017), Int. J. Pharmacol. Pharm. Sci.;
- [8] Ben Ghezala et al. (2015) Case Rep. Emerg. Med.