



HAL
open science

Leiomyosarcoma of the Prostate: Report of Two Cases and Review of the Literature

Ons Bettaieb, Aicha Keskes, Carmen Llacer Moscardo

► **To cite this version:**

Ons Bettaieb, Aicha Keskes, Carmen Llacer Moscardo. Leiomyosarcoma of the Prostate: Report of Two Cases and Review of the Literature. *Case Reports in Oncology*, 2024, 17 (1), pp.454-462. 10.1159/000535425 . hal-04797573

HAL Id: hal-04797573

<https://hal.science/hal-04797573v1>

Submitted on 22 Nov 2024

HAL is a multi-disciplinary open access archive for the deposit and dissemination of scientific research documents, whether they are published or not. The documents may come from teaching and research institutions in France or abroad, or from public or private research centers.

L'archive ouverte pluridisciplinaire **HAL**, est destinée au dépôt et à la diffusion de documents scientifiques de niveau recherche, publiés ou non, émanant des établissements d'enseignement et de recherche français ou étrangers, des laboratoires publics ou privés.



Distributed under a Creative Commons Attribution - NonCommercial 4.0 International License

Case Report

Leiomyosarcoma of the Prostate: Report of Two Cases and Review of the Literature

Ons Bettaieb^a Aicha Keskes^b Carmen Llacer Moscardo^b

^aRadiation Oncology Department, Farhat Hached Hospital, University of Sousse, Sousse, Tunisia; ^bMontpellier Cancer Institute, Federation of Radiation Oncology of Mediterranean Occitanie, University Montpellier, INSERM U1194 IRCM, Montpellier, France

Keywords

Leiomyosarcoma · Prostate cancer · Case report · Radiotherapy

Abstract

Introduction: Leiomyosarcoma (LMS) of the prostate is an extremely rare and aggressive tumor that presents with nonspecific signs and symptoms. Treatment guidelines are not yet established. **Case Presentation:** We report two cases of LMS of the prostate. The presenting symptom was hematuria, and diagnosis was ascertained through a transurethral resection of the prostate for the 2 patients. The treatment course consisted of three courses of chemotherapy with gemcitabine and docetaxel, radical prostatectomy, and postoperative radiation therapy for the first patient and three courses of gemcitabine and radiation therapy of the prostate and the whole pelvis for the second patient. The follow-up of our 2 patients was 9 and 12 months, respectively. Recurrence occurred 10 months after treatment completion for the second case. No recurrence was noticed in the first case. **Conclusion:** These two cases highlight the importance of a multimodal approach to yield the best outcomes.

© 2024 The Author(s).
Published by S. Karger AG, Basel

Introduction

Leiomyosarcoma (LMS) of the prostate is an extremely rare malignant neoplasm of prostatic smooth cell [1]. It accounts for less than 0.1% of primary prostate malignancies [2]. Its diagnosis remains difficult due to clinical and radiological unspecificity. It has an

Correspondence to:
Ons Bettaieb, onsbettaieb90@gmail.com

aggressive clinical course and a rather dark prognosis with a median survival estimated to 17 months [3]. Due to the rarity of this entity, the treatment approach has not yet been defined, and a multidisciplinary approach including radical surgery, radiotherapy, and chemotherapy is necessary for the management of this dire aggressive disease. Thus, this article reports two cases of prostate LMS and describes the characteristics, diagnostic modalities, treatment approach, and outcomes of the disease.

Case Report

Case 1

A 74-year-old man, with a history of acute myeloid leukemia in remission, exhibited macroscopic hematuria evolving for 2 months with normal urinalysis. The patient was referred for a urological consultation. The digital rectal examination revealed an enlarged prostate. Cystoscopy was normal. Subsequently, he underwent a transurethral resection of the prostate (TURP) for suspected benign prostatic hypertrophy.

Histopathological examination of the specimen showed a grade 3 LMS according to the Fédération Nationale des Centres de Lutte Contre le Cancer (FNCLCC) grading system. The immunohistochemical study showed positivity for α -smooth muscle actin (α -SMA), desmin, and caldesmon. MDM2 and myogenin were not overexpressed. Metastatic workup including pelvic magnetic resonance imaging (MRI) and 18-fluorodeoxyglucose (FDG) positron emission tomography did not reveal any evidence of metastasis.

Optimal management was discussed in a multidisciplinary board. Regarding his history of acute leukemia treated with high-dose anthracycline, induction chemotherapy with 5 cycles of gemcitabine and docetaxel followed by complete surgery was decided. Adjuvant radiotherapy was indicated since the first surgery was carried out by fragmentation. He received three courses of chemotherapy with gemcitabine and docetaxel. However, the patient developed hand-foot syndrome, asthenia, and bone pain due to granulocyte administration. He was unable to continue for intolerance.

Radical prostatectomy was then performed. A histopathological examination confirmed the presence of infracentimetric residual focus of grade 3 LMS associated with three foci of prostatic adenocarcinoma Gleason 7 (4 + 3) without capsular effraction. Clear resection margins were obtained. The tumor was classified as pT2NxR0.

The patient was referred to our department 2 months later for adjuvant radiotherapy. Postoperative intensity-modulated radiation therapy delivering 60 Gy in 30 fractions over 6 weeks to the prostate bed was performed. The clinical target volume included the prostate bed and seminal vesicles without pelvic lymph node irradiation. The planning target volume is created by adding an isotropic 10-mm margin to clinical target volume. The patient was seen 3, 6, and 9 months after treatment completion with normal clinical examination; CT imaging of the thorax, abdomen, and pelvis and pelvic MRI were normal. Close follow-up was planned. The completed CARE Checklist for this case report is included as online supplementary material (for all online suppl. material, see <https://doi.org/10.1159/000535425>). Timeline in Table 1 summarizes the main events.

Case 2

An 84-year-old man with a history of multiple basal cell carcinomas operated on the scalp and benign prostatic hypertrophy. The patient presented a macroscopic hematuria. The physical examination was unremarkable. Uretrocystoscopy showed a heterogeneous prostate with a prominent median lobe. He underwent a TURP. Pathological examination revealed a grade 3 LMS of the prostate. The diagnosis was confirmed by immunohistochemical staining;

Table 1. Timeline summarizing the main events of case 1

Date	Summaries of visits, diagnostic testing, imaging, and treatments
March 2021	Symptoms: macroscopic hematuria digital rectal examination: enlarged prostate
May 2021	Cystoscopy: normal TURP: grade 3 LMS according to the FNCLCC grading system
May 21, 2021	Metastatic workup: the tumor was classified as T2N0M0
May 31, 2021	Multidisciplinary board: chemotherapy, surgery +/- radiotherapy
June–August 2021	Induction chemotherapy: 5 cycles of gemcitabine and docetaxel
October 2021	Surgery: radical prostatectomy with clear-margin pT2NX
Dec 13, 2021–Jan 21, 2022	Adjuvant radiotherapy: VMAT, prostate bed, 60 Gy in 30 fractions
March 29, 2022	Pelvic MRI and CT imaging of the thorax, abdomen, and pelvis: normal Follow-up: every 3 months after treatment completion: clinical examination; CT imaging of the thorax, abdomen, and pelvis; and pelvic MRI

tumor cells were positive for caldesmon, desmin, α -SMA, and Ki67 was 80%. The prostate-specific antigen at presentation was normal. The extension workup was negative. The tumor was classified as T2N0M0.

Given the significant tumor residue on the morphological evaluation, the multidisciplinary meeting proposal was to perform induction chemotherapy with doxorubicin at 80% of doses +/- dacarbazine, to not alter his autonomy, with a reevaluation after two cycles. Radiation therapy or radical surgery would then be proposed if it is not progressive and if the general state allows it. Since the patient had heart failure, doxorubicin was replaced by gemcitabine.

He received three courses of gemcitabine. The evaluation MRI showed an increase in the size of the prostate lesion from 9 to 28 mm that protrudes into the bladder and the appearance of left external iliac adenopathy of 16 mm as shown in Figure 1.

In a multidisciplinary setting, radiotherapy was offered as adjuvant treatment. Radiation therapy delivered a dose of 50 Gy in 25 fractions to the whole pelvis and an additional 20 Gy in 10 fractions to the prostate and a 10 Gy boost in 5 fractions to pathological adenopathy using the VMAT technique. Radiotherapy was complicated by a urinary blockage requiring the placement of a urinary catheter during 1 month and the relay by alpha blockers treatment. Evaluation MRI showed a partial response. The decision was to proceed with clinical and imaging follow-up every 3 months.

Thoracoabdominal CT and pelvic MRI at 9 months showed a recurrence in the abdominal wall that occurred 2 months after inguinal hernia surgery. Radiological biopsy of the abdominal wall lesion allowed histopathological confirmation of local recurrence of a high-grade LMS. Neoadjuvant radiotherapy was initially planned before surgery, but taking into account the overlap with the previous irradiation field, surgery was performed alone. Histological examination showed parietal recurrence of LMS of the prostate measuring 65 mm with minimal margin at 1 mm depth.

Close follow-up with clinical examination, CT imaging of the thorax, and abdomen and pelvic MRI were planned. The completed CARE Checklist for this case report is included as online supplementary material. Timeline in Table 2 summarizes the main events.

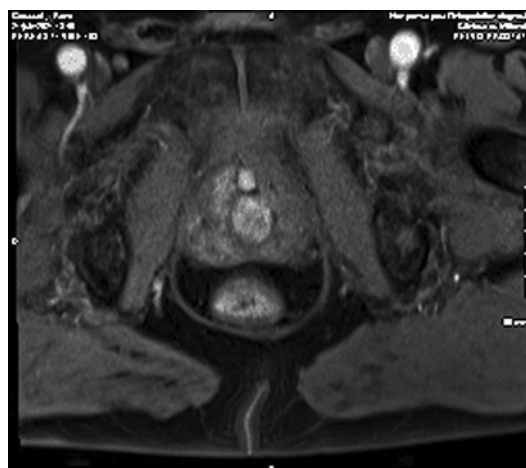


Fig. 1. Axial T1-weighted gadolinium-enhanced fat saturation MRI image.

Table 2. Timeline summarizing the main events of case 2

Date	Summaries of visits, diagnostic testing, imaging, and treatments
March 2020	Symptoms: macroscopic hematuria
March 2021	Digital rectal examination: normal Uretrocystoscopy: heterogeneous prostate with a prominent median lobe TURP: grade 3 LMS according to the FNCLCC grading system
June 2021	Metastatic workup: the tumor was classified as T2N0M0
July 2021	Multidisciplinary board: induction chemotherapy, surgery, or radiotherapy
July–September 2021	Induction chemotherapy: 3 courses of gemcitabine
October 2021	Pelvic MRI evaluation: increase in the size of the prostate lesion from 9 to 28 mm. The appearance of left external iliac adenopathy of 16 mm
Nov 9–Dec 29, 2021	Adjuvant radiotherapy: VMAT, prostate + whole pelvis + adenopathy, 70 Gy in 35 fractions
September 2022	Follow-up *CT imaging of the thorax, abdomen, and pelvis and pelvic MRI showed a recurrence in the abdominal wall *Radiological biopsy of the abdominal wall lesion: histopathological confirmation of local recurrence of a high-grade LMS according to the FNCLCC grading system
October 2022	Surgery: parietal recurrence of LMS of the prostate Follow-up: every 3 months after treatment completion: clinical examination; CT imaging of the thorax, abdomen, and pelvis; and pelvic MRI

Discussion

Adult prostate sarcoma accounts for 0.7% of primary prostate malignancies and is defined as a rare type of malignancy of mesenchymal origin. LMS, which is a smooth muscle sarcoma, is the most common primary sarcoma of the prostate in adults, representing 25% of cases, followed by rhabdomyosarcoma [2].

The ages of the 2 patients in this report are, respectively, 74 and 84 years. However, it has been reported in adults aged from 40 to 80 years [4].

Its diagnosis remains difficult due to clinical unspecificity. Most patients usually complain of lower urinary tract symptoms such as dysuria, nocturia, and urinary stream weakness. As the tumor grows, hematuria, perineal pain, urine retention, and weight loss are noticed. The digital rectal examination is also nonspecific, showing an enlarged gland that can feel benign, firm, or hard, depending on the stage of the diagnosis. Due to the lack of typical clinical symptoms and the serum prostate specific antigen value that is mostly within the normal range, the tumor is easily misdiagnosed as benign prostatic hyperplasia. The diagnosis is established by TURP and transrectal ultrasonography guided prostate biopsy [3].

The 2 patients reported here presented hematuria, had normal examination at presentation, and underwent a TURP to establish a diagnosis. Lesions may range in size from 3 to 21 cm and are often highly infiltrative. Microscopic findings are characterized by hypercellular lesions composed of intersecting bundles of spindle cells characterized by atypia. The majority of LMS were high grade, with frequent mitoses and necrosis according to the most commonly used histological FNCLCC grading system. LMS commonly expresses vimentin, actin, desmin, and caldesmon. Cytokeratin expression is observed in about one-quarter of cases [1]. Our two patients presented expression of desmin, AML, and caldesmon.

About one-third of patients present with metastatic disease. Distant metastasis was most common to the lungs and liver. Bone metastases are frequently osteolytic and are generalized throughout the skeleton. Studies have shown that LMS are also FDG-avid and that the standardized uptake value maximum of FDG-positron emission tomography is a prognosis predictor [5].

There is neither a gold standard nor recommendation for the treatment of LMS of the prostate, although complete surgery with a clear margin remains the mainstay of treatment using cysto-prostatectomy or pelvic exenteration [3]. However, prostate sarcomas are rarely cured using surgical resection alone. Balls et al. [6] showed that patients with intermediate- or high-grade prostate sarcoma treated with a multimodal approach had favorable cancer-specific survival and recurrence-free survival compared to a historical and contemporary series of surgery alone and no local recurrences.

Neoadjuvant treatments including chemotherapy or chemoradiation should be considered if the tumor is inoperable from the outset or if the surgery would be scheduled as being incomplete or with expected positive margins [3]. Chemotherapy regimens should consist of agents with activity against sarcomas such as anthracyclines, ifosfamide, cyclophosphamide, and dacarbazine [7].

Radiation therapy has a key role in the treatment of sarcoma. Several retrospective studies showed an improvement in the local control rate of uterine sarcoma with adjuvant radiotherapy but without impact on survival [8]. This can be extrapolated to prostate LMS.

The first case we report received neoadjuvant chemotherapy to facilitate complete resection. Radical prostatectomy and adjuvant radiotherapy were performed. The second case had partial surgery with a positive margin and chemotherapy and radiotherapy of the prostate.

Ball et al. [6] reported that preoperative chemoradiation therapy for 8 patients with stage III high-grade prostate sarcoma (three with LMS) improved OS. Neoadjuvant radiotherapy was administered at 45–50.4 Gy. The MAI (mesna, doxorubicin, and ifosfamide) was administered concurrently. The median OS was 67.8 months, and the survival rate at 1, 3, 5 years was 100%, 55.6%, and 55.6%, respectively. All 3 LMS patients survived.

Chevillat et al. [9] reported a series of 23 patients treated with radical surgery followed by either chemotherapy, radiotherapy, or both. Complete excision was difficult in most cases and did not cure patients. After a follow-up ranging from 2 to 72 months, 10 patients died from tumors. Local recurrence occurred in 10 patients, including 5 who had a gross residual tumor present after surgery. Metastases developed up to 40 months after surgery and most frequently involved the lungs.

Table 3. Case report of the literature: characteristics of the patient, clinical presentation, treatment approach, and outcomes

Age, years	Symptoms	PSA, ng/mL	Diagnostic	Histology (grade)	Immunohistochemistry	Metastasis	Treatment	Outcomes
Basraoui et al. [10]	49 Dysuria, weight loss	NL	Transperineal prostate biopsy	LMS (grade nonspecified)	-	M+	RTUP + Adj CT	Death
Vandoros et al. [4]	80 Frequent micturition, dysuria, poor urinary stream, nocturia	2.7	TURP	LMS (grade nonspecified)	SMA, vimentin, CD44	M+ (liver and lung)	Patient denied treatment	Death (2 weeks)
Zazzara et al. [11]	62 Nocturia, frequency	1.6	TRUSPB	LMS (HG)	Desmin, vimentin, and calponin +	M0	Surgery R0 (radical prostatectomy + extended lymphadenectomy) + Adj CT (8 docetaxel cycles of 75 mg/m ²)	Cancer-free (6 months)
Alves et al. [12]	73 Frequency, nocturia, weak urinary stream, hematuria, and urinary retention	6.45	TURP	LMS (HG)	Actin, vimentin, desmin, and protein S100	M0	Radical prostatectomy (T3C, R1), Adj RT	Death (3 months)
Loghmary et al. [13]	64 Macroscopic hematuria, and nocturia, and frequency	1.7	Biopsy of bladder mass	LMS (HG)	Vimentin, α-SMA	M0	Cystoprostatectomy	Death (cardiac arrest before surgery)
Kawaguchi et al. [14]	52 Difficulty in urination, frequency, perineal pain	0.8	TRUSPB	LMS (HG)	α-SMA, desmin, and vimentin	M0	NA CT (MAID regime), total pelvic exenteration (R0)	Cancer-free (5 years)

Table 3 (continued)

Age, years	Symptoms	PSA, ng/mL	Diagnostic	Histology (grade)	Immunohistochemistry	Metastasis	Treatment	Outcomes
Pemmaraju et al. [15] 41	Micturition, difficulty in passing urine		TRUSPB	LMS (HG)	SMA, desmin	M0	NA SBRT (30 Gy/5 fractions alternate day over a period of 2 weeks) Radical prostatectomy (pT3b, R1), Adj RT (30 Gy/15 Frct)	

MAID regime: mesna 6,000 mg/m², doxorubicin 60 mg/m², ifosfamide 7,500 mg/m², dacarbazine 900 mg/m², every 4 weeks.
TRUSPB, transrectal ultrasonography guided prostate biopsy; TURP, transurethral resection of the prostate; LMS, leiomyosarcoma; HG, high grade; Adj, adjuvant; NA, neoadjuvant; RT, radiotherapy; SBRT, stereotactic body radiotherapy; α-SMA, alpha smooth muscle actin; PSA, prostate-specific antigen.

In a population of 54 LMS of the prostate, Vandoros et al. [4] reported a median survival estimated to 17 months (95% CI: 20.7–43.7 months) and 1-, 3-, and 5-year actuarial survival rates to 68%, 34%, and 26%, respectively. The only factors that predict long-term survival were negative surgical margins and the absence of metastatic disease at presentation.

The follow-up of our 2 patients was 9 and 12 months, respectively. Recurrence occurred 10 months after treatment completion for the second case. No recurrence was noticed in the first case. Table 3 describes the characteristics, treatment approach, and the outcomes of different case reports published in the literature (Table 3). Due to the rarity of this pathology, it is really important to report periodically its occurrence, the different approaches to treatment, and their outcomes in order to improve our knowledge of its natural history.

Conclusions

LMS is a rare and aggressive neoplasm of the prostate. Early diagnosis with complete surgical resection offers patients the best chance of being cured. A multimodal approach seems to be the optimal option to yield the best outcomes. Since disease recurrence is common and may occur locally or distantly, close follow-up after the end of therapy is important.

Statement of Ethics

Ethical approval is not required for this study in accordance with national guidelines. Written informed consent was obtained from the 2 patients for the publication of their medical case and any accompanying images.

Conflict of Interest Statement

The authors have no conflicts of interest to declare.

Funding Sources

No funding was received.

Author Contributions

Data collection and assembly: Ons Bettaieb and Aicha Keskes. Data interpretation: Carmen Llacer Moscardo, Ons Bettaieb, and Aicha Keskes. Manuscript writing: Ons Bettaieb. Revising the work critically for intellectual content: Carmen Llacer Moscardo. All the authors approved the final manuscript and agree to be accountable for all aspects of the work.

Data Availability Statement

All data analyzed during this study are included in this article. Further inquiries can be directed to the corresponding author.

References

- 1 Hansel DE, Herawi M, Montgomery E, Epstein JI. Spindle cell lesions of the adult prostate. *Mod Pathol*. 2007;20(1):148–58.
- 2 Sexton WJ, Lance RE, Reyes AO, Pisters PWT, Tu SM, Pisters LL. Adult prostate sarcoma: the M. D. anderson cancer center experience. *J Urol*. 2001;166(2):521–5.
- 3 Venyo AKG. A review of the literature on primary leiomyosarcoma of the prostate gland. *Adv Urol*. 2015;2015:485786–15.
- 4 Vandoros GP, Manolidis T, Karamouzis MV, Gkermepesi M, Lambropoulou M, Papatsoris AG, et al. Leiomyosarcoma of the prostate: case report and review of 54 previously published cases. *Sarcoma*. 2008;2008:458709–5.
- 5 Andreou A, Whitten C, MacVicar D, Fisher C, Sohaib A. Imaging appearance of sarcomas of the prostate. *Cancer Imag*. 2013;13(2):228–37.
- 6 Ball MW, Sundi D, Reese AC, Meyer CF, Terezakis SA, Efron JE, et al. Multimodal therapy in the treatment of prostate sarcoma: the Johns Hopkins experience. *Clin Genitourin Cancer*. 2015;13(5):435–40.
- 7 Suppiah R, Wood L, Elson P, Budd GT. Phase I/II study of docetaxel, ifosfamide, and doxorubicin in advanced, recurrent, or metastatic soft tissue sarcoma [STS]. *Invest New Drugs*. 2006;24(6):509–14.
- 8 Le Péchoux C, Llacer C, Sargos P, Moureau-Zabotto L, Ducassou A, Sunyach MP, et al. Conformal radiotherapy in management of soft tissue sarcoma in adults. *Cancer Radiother*. 2022;26(1–2):377–87.
- 9 Cheville JC, Dundore PA, Nascimento AG, Meneses M, Kleer E, Farrow GM, et al. Leiomyosarcoma of the prostate. Report of 23 cases. *Cancer*. 1995;76(8):1422–7.
- 10 Basraoui D, Bentani N, Hiroual M, Jalal H, Cherif idrissi el ganouni N, Boukhari M, et al. Leiomyosarcome de la prostate: neoplasie rare. *Afr J Urol*. 2012;18(1):61–5.
- 11 Zazzara M, Divenuto L, Scarcia M, Cardo G, Maselli FP, Ludovico GM. Leiomyosarcoma of prostate: case report and literature review. *Urol Case Rep*. 2018;17:4–6.
- 12 Alves LJ, Gameiro CD, Lopes SP, Ascensão Jd B, Sousa RC. Prostate leiomyosarcoma: a rare misleading tumor. *Urol août*. 2019;130:13–6.
- 13 Loghmari A, Ben Othmane M, Belkacem O, Bouassida K, Hmida W, Jaidane M. Recurrent hematuria: a rare presentation of leiomyosarcoma of the prostate. *Ann Med Surg*. 2022;77:103634.
- 14 Kawaguchi T, Tanaka T, Ogasawara M, Ikuya I. Long-term disease control after upfront chemotherapy and surgery in a patient with primary prostate leiomyosarcoma. *IJU Case Rep*. 2022;5(2):88–91.
- 15 Pemmaraju G, Sharma S, Parab A, Singh A, Barsing S. A rare case of leiomyosarcoma of the prostate: treatment and review of literature. *J Radiat Cancer Res*. 2021;12(4):190.