



HAL
open science

B-cell immune deficiency in twin sisters expands the phenotype of MOPDI

Lucas W Gauthier, Morgane Gossez, Christophe Malcus, Sébastien Viel, Guillaume Monneret, Rémy Bordonné, Linda Pons, Sara Cabet, Marion Delous, Sylvie Mazoyer, et al.

► **To cite this version:**

Lucas W Gauthier, Morgane Gossez, Christophe Malcus, Sébastien Viel, Guillaume Monneret, et al.. B-cell immune deficiency in twin sisters expands the phenotype of MOPDI. *Clinical Genetics*, 2024, 106 (4), pp.476-482. 10.1111/cge.14571 . hal-04796518

HAL Id: hal-04796518

<https://hal.science/hal-04796518v1>


Submitted on 21 Nov 2024

HAL is a multi-disciplinary open access archive for the deposit and dissemination of scientific research documents, whether they are published or not. The documents may come from teaching and research institutions in France or abroad, or from public or private research centers.

L'archive ouverte pluridisciplinaire **HAL**, est destinée au dépôt et à la diffusion de documents scientifiques de niveau recherche, publiés ou non, émanant des établissements d'enseignement et de recherche français ou étrangers, des laboratoires publics ou privés.

SHORT REPORT

B-cell immune deficiency in twin sisters expands the phenotype of MOPDI

Lucas W. Gauthier¹ | Morgane Gossez^{2,3} | Christophe Malcus³ | Sébastien Viel⁴ |
 Guillaume Monneret^{3,5} | Remy Bordonné⁶ | Linda Pons⁷ | Sara Cabet^{8,9} |
 Marion Delous¹⁰ | Sylvie Mazoyer¹⁰  | Audrey Putoux^{1,10} | Patrick Edery^{1,10}

¹Department of Genetics, Clinical Genetics Unit, Centre de Référence Maladies Rares des Anomalies du Développement Sud-Est, Hospices Civils de Lyon, Université Claude Bernard Lyon 1, Bron, France

²CIRI, Centre International de Recherche en Infectiologie, Univ Lyon, Inserm U1111, Université Claude Bernard-Lyon 1, CNRS, UMR5308, ENS Lyon, Lyon, France

³Immunology Laboratory, Hospices Civils de Lyon, Edouard Herriot Hospital, Lyon, France

⁴Plateforme de Biothérapies et de production de MTI, Hôpital Edouard Herriot, Hospices Civils de Lyon, Lyon, France

⁵Equipe d'Accueil 7426, Pathophysiology of Injury-Induced Immunosuppression, Université Claude Bernard Lyon 1, Hospices Civils de Lyon – bioMérieux, Hôpital Edouard Herriot, Lyon, France

⁶Institut de Génétique Moléculaire de Montpellier, University of Montpellier, CNRS UMR5535, Montpellier, France

⁷Unité Fonctionnelle de Cytogénétique, Laboratoire de Biologie Médicale, Centre hospitalier de Valence, Valence, France

⁸Pediatric and Fetal Imaging Department, Femme-Mère-Enfant Hospital, Hospices Civils de Lyon, Claude Bernard Lyon 1 University, Lyon, France

⁹Institut NeuroMyoGène, CNRS UMR5292, INSERM U1028, Claude Bernard Lyon 1 University, Lyon, France

¹⁰Université Claude Bernard Lyon 1, INSERM, CNRS, Centre de Recherche en Neurosciences de Lyon CRNL U1028 UMR5292, Genetics of Neurodevelopment Team (GENDEV), Bron, France

Correspondence

Patrick Edery, 59 Boulevard Pinel, 69677 Bron Cedex, France.

Email: patrick.edery@chu-lyon.fr

Abstract

Microcephalic osteodysplastic primordial dwarfism type I (MOPDI) is a very rare and severe autosomal recessive disorder characterized by marked intrauterine growth retardation, skeletal dysplasia, microcephaly and brain malformations. MOPDI is caused by biallelic mutations in *RNU4ATAC*, a non-coding gene involved in U12-type splicing of 1% of the introns in the genome, which are recognized by their specific splicing consensus sequences. Here, we describe a unique observation of immunodeficiency in twin sisters with mild MOPDI, who harbor a novel n.108_126del mutation, encompassing part of the U4atac snRNA 3' stem-loop and Sm protein binding site, and the previously reported n.111G>A mutation. Interestingly, both twin sisters show mild B-cell anomalies, including low naive B-cell counts and increased memory B-cell and plasmablasts counts, suggesting partial and transitory blockage of B-cell maturation and/or excessive activation of naive B-cells. Hence, the localization of a mutation in stem II of U4atac snRNA, as observed in another *RNU4ATAC*-opathy with immunodeficiency, that is, Roifman syndrome (RFMN), is not required for the occurrence of an immune deficiency. Finally, we emphasize the importance of considering immunodeficiency in MOPDI management to reduce the risk of serious infectious episodes.

This is an open access article under the terms of the [Creative Commons Attribution-NonCommercial](https://creativecommons.org/licenses/by-nc/4.0/) License, which permits use, distribution and reproduction in any medium, provided the original work is properly cited and is not used for commercial purposes.

© 2024 The Author(s). *Clinical Genetics* published by John Wiley & Sons Ltd.

KEYWORDS

immunodeficiency, microcephalic osteodysplastic primordial dwarfism type I, MOPDI, RNU4ATAC, U4atac snRNA

1 | INTRODUCTION

Microcephalic Osteodysplastic Primordial Dwarfism type I (MOPDI; OMIM 210710), also named Taybi-Linder syndrome, is a rare autosomal recessive syndrome characterized by severe intrauterine growth retardation, dwarfism, skeletal dysplasia, microcephaly, brain malformations, dysmorphic features and reduced life expectancy.¹⁻³ Dysmorphic features include round face, sloping forehead, bulging eyes, beaked and large nose, micrognathia, short neck, sparse hair, and dry skin.

Our team and others have shown that MOPDI is caused by biallelic mutations in *RNU4ATAC*, a non-coding gene transcribed into U4atac, a small nuclear RNA component of the U12-type minor spliceosome, which is essential for the splicing of the U12-type introns.⁴⁻⁶ We described genome wide retentions of U12-type introns in various cell lines derived from patients with *RNU4ATAC* bi-allelic mutations⁷ and designed methods to predict *RNU4ATAC* variants pathogenicity.⁸

Bi-allelic *RNU4ATAC* mutations were reported in two other rare autosomal recessive diseases with a distinctive and milder phenotype, namely Roifman syndrome (RFMN, OMIM: 616651) and Lowry Wood Syndrome (LWS, OMIM: 226960). RFMN is associated with immunodeficiency mainly related to B-cell lymphocytes maturation.⁹⁻¹² Our team recently reported on an additional *RNU4ATAC*-associated disease reminiscent of the Joubert syndrome ciliopathy in five patients harboring at least one mutation in stem II of U4atac snRNA, a region consistently mutated in RFMN, among whom one patient had a B-cell immunodeficiency.¹³

Interestingly, immune deficiency has been reported also in three unrelated MOPDI patients,^{14,15} but systematic immune investigations have been hampered by early unexplained death in most MOPDI patients. Here, we report on mild B-cell immunodeficiency but no T-cell anomaly in MOPDI twin sisters, still alive at 5 y.o., who harbor the compound heterozygous n.108_126del and n.111G>A *RNU4ATAC* variants, that we studied elsewhere.¹⁶ The data presented here strongly suggest that immunodeficiency should be considered as a MOPDI feature, which may possibly trigger infectious episodes either initiating or causing early death.^{4,17}

2 | CASE REPORTS

Case 1 is the first twin born to unrelated parents with no informative family history. The pregnancy was bi-chorionic bi-amniotic, marked by intrauterine growth restriction (IUGR) below the 3rd percentile. Cesarean section at 34 WG was due to abnormal fetal heart rate and breech presentation. Apgar scores were 5/8/9/9,

with a birth weight of 1235 g (−4.5DS), height of 36 cm (−5DS), and head circumference of 26 cm (−4.5DS). Dysmorphic features included retrognathism, receding forehead, small low-set ears, prominent nose, nuchal plane angioma, clinodactyly of the 5th fingers, and bilateral skin syndactyly of toes 2–3 (Figure 1A). At 3 months, growth retardation persisted, accompanied by developmental delay. Gastroesophageal reflux and a right hip dislocation were noted. Hair abnormalities and facial xerosis were observed. At 22 months, surgical interventions addressed tracheal stenosis, reflux, and hip dislocations. By 3 years and 5 months, she had basic motor skills, and wore glasses for mild myopia and nystagmus. Thyroid workup, GH, IGFBP3 were normal. Skeletal radiographs showed ossification delay and platyspondyly (Figure 1B). Brain imaging showed partial corpus callosum agenesis, cerebellar atrophy, and gyration simplification (Figure 1C). CT scan revealed premature closure of metopic, sagittal, coronal and lambdoid sutures leading to brachycephaly and mild trigonocephaly (Figure 1D). Sanger sequencing identified compound heterozygous *RNU4ATAC* mutations (n.111G>A inherited from the father, newly described n.108_126del inherited from the mother).

Case 2, the second twin, had also marked IUGR. Her birth weight was 1475 g (−3 SD), birth height was 37.5 cm (−4.5 SD), and birth head circumference was 27 cm (−3.5 SD). Clinical examination revealed facial dysmorphism, including a round face, strabismus, microretrognathia, short neck, occipital plagiocephaly, sparse hair, dry skin, short limbs, bilateral varus feet, short fingers and toes, clinodactyly of the 5th fingers, and small hemangiomas (Figure 1A). Despite vaccinations, she experienced viral infections and respiratory issues. Immunoglobulin or alternative immune therapies were not initiated due to the benign nature of infections. At 18 months, she said a few words and stood with aid. Kyphosis and joint hyperlaxity were observed. By age 3 years, she could walk with help and wore orthopedic shoes for varus flat feet. Immune abnormalities were identified (Table 1). Brain imaging and CT scan revealed similar abnormalities as those found in her sister (Figure 1C,D). Abdominal and cardiac ultrasonography, electroencephalogram and evoked auditory potentials were normal for both sisters. Both *RNU4ATAC* pathogenic variants found in case 1 were identified.

3 | IMMUNOLOGICAL REPORTS

At 12 and 24 months, both twins exhibited similar immune alterations, revealing normal T-cell counts but a moderate increase in total and naive CD4+ T-cells. B-cell lymphopenia was marked, but elevated proportions of transitional B-cells indicated partially efficient bone marrow response. Decreased naive B-cells and elevated

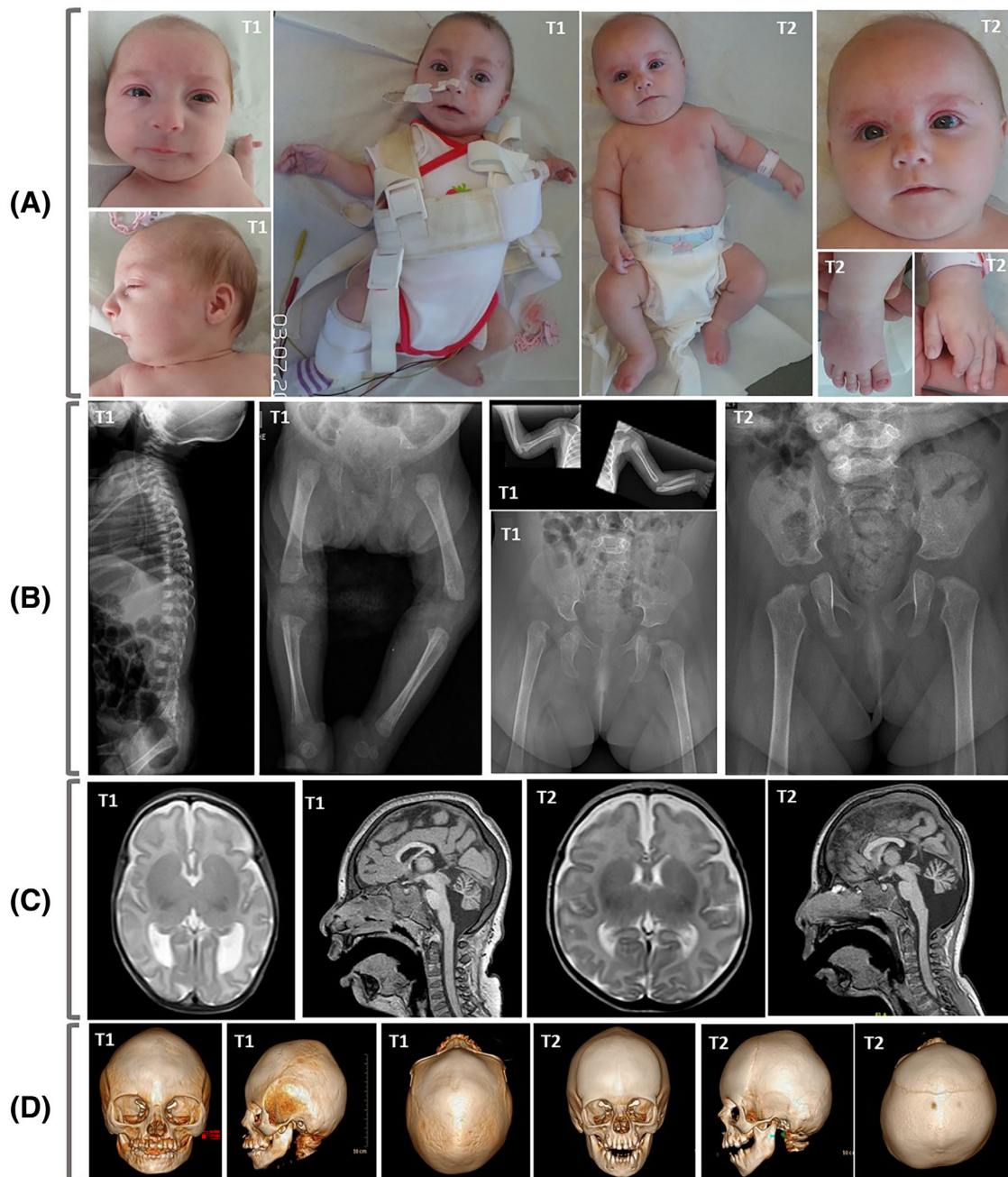


FIGURE 1 Clinical features of the patients twin 1 (T1) and twin 2 (T2). (A) Clinical features showing microcephaly, round face, sloping forehead, prominent eyes with sparse eyebrows, eyelashes and hair, beaked nose, microretrognathia, thin upper lip, small and low-set ears and short neck, short stature, short limb with brachydactyly, mild flexion contractures. (B) Radiographic features showing short and mildly curved long bones, mild platyspondyly with marked retardation of epiphyseal ossification, small and round iliac wings and coxa. valga. (C) Brain MRI showing simplified gyration pattern of the brain cortex, brief and dysplastic corpus callosum, marked hypoplasia of the cerebellar vermis. (D) Volume reconstruction of brain CT scan showing premature closure of metopic, sagittal, coronal and lambdoid sutures leading to brachycephaly and mild trigonocephaly.

memory B-cells suggested naive B cell consumption and proper peripheral B-cell maturation. Both twins displayed normal serum immunoglobulin levels and circulating antibodies. Serum protein electrophoresis was normal. Serum protein electrophoresis displayed normal protein distribution.

4 | DISCUSSION

In this work, we describe immunodeficiency associated with a mild form of MOPDI in twin sisters harboring the combination of the newly described n.108_126del *RNU4ATAC* mutation and

TABLE 1 Immunological profile.

	12 months		24 months		Normal values
	J1	J2	J1	J2	
Total lymphocytes (/μL)	7,456	7,693	6,308	5,654	3,600–8,900
T cells					
CD3+ T cells (/μL)	6,271	6,439	5,365	4,621	2,100–6,200
CD4+ T cells (/μL)	4,261	4,577	3,476	2,832	1,300–3,400
CD8+ T cells (/μL)	1,900	1,731	1,786	1,635	620–2,000
Naive CD4+ T cells (CD45RA+)					
(% of CD4 T cells)	87	89	84	84	63–91
(/μL)	3,694	4,095	2,924	2,386	1,000–2,900
Recent thymic emigrant CD4+ T cells (CD45RA+ CD31+)					
(% of CD4 T cells)	77	78	72	67	61–93
(/μL)	3,289	3,592	2,487	1,909	900–5,800
Proliferative response to mitogens (PHA, OKT3, Concanaline A)	Good	Good	Good	Good	40–100
Proliferative response to antigens					1,70–7,400
<i>Candidine</i>	Weak	Weak	Moderate	Good	
<i>Tuberculin</i>	Absent	Absent	Weak	Absent	
<i>Tetanus anatoxin</i>	Absent	Absent	Absent	Absent	
T cell receptor V beta repertoire					
% among CD3+ T cells	No anomaly	No anomaly	No anomaly	No anomaly	No anomaly
% among CD4+ T cells	No anomaly	No anomaly	No anomaly	No anomaly	0–2.6
% among CD8+ T cells	Vb11 = 3.44	No anomaly	Vb11 = 3.11 Vb16 = 4.50	Vb16 = 2.40	0.15–2.11
B cells					
CD19+ B cells (/μL)	475	549	320	382	720–2,600
Transitional B cells (CD19+CD24hiCD38hi)					
(% of B cells)	35.3	29.8	25.1	17.7	3.8–27.5
(/μL)	168	163	80	68	24–300
Naive B cells (CD19+CD27–IgD+)					
(% of B cells)	51.8	58.0	52.2	41.8	69.2–90.5

(Continues)

TABLE 1 (Continued)

	12 months		24 months		Normal values
	J1	J2	J1	J2	
(/μL)	246	318	167	160	212–1027
Total memory B cells (CD19+CD27+)					
(% of B cells)	42.3	36.5	21.2	50.1	7.0–24.3
(/μL)	201	200	68	192	45–175
Unswitched memory B cells (CD19+CD27+IgD+)					
(% of B cells)	25.5	19.5	8.3	27.0	4.6–16.3
(/μL)	121	107	27	103	23–113
Switched memory B cells (CD19+CD27+IgD–)					
(% of B cells)	16.9	17.0	13.2	21.3	2.7–12.5
(/μL)	80	93	42	81	20–93
Double negative B cells (CD19+CD27–IgD–)					
(% of B cells)	5.9	5.6	26.3	9.9	1.2–8.3
(/μL)	28	31	84	38	10–56
Plasmablasts (CD19+CD24–CD38hi)					
(% of B cells)	10	8	4.6	8	0.5–1.4
(/μL)	48	44	15	31	1–3
Serum immunoglobulins					
IgG	-	5.29	8.53	7.65	5.4–13.4
IgM	-	0.90	1.53	2.53	0.52–1.9
IgA	-	0.37	0.64	0.72	0.11–1.34
IgG subclasses	-	Normal profile (start of IgG4 production)	Normal profile	Normal profile	Normal profile
IgA subclasses	-	Normal profile	Normal profile	Normal profile	Normal profile
Vaccine responsiveness (poliovirus, diphtheria and tetanus toxoids)	-	Protective titers of antibodies	Protective titers of antibodies	-	Protective titers of antibodies
NK cells (/μL)	329	494	372	554	180–920
Serum protein electrophoresis					
	-	Alpha2 fraction increase: inflammatory syndrome	Normal protein distribution	-	

Note: Comparative analysis of lymphocyte profiles and serum protein electrophoresis alterations in twins showing similar immune alterations at 12 and 24 months of age.

TABLE 2 Immunological profile of the RNU4ATAC-opathies.

Phenotype	Roifman syndrome Heremans et al. ¹⁰ (3 patients)	Lowry-Wood syndrome Farach et al. ⁹ (1 patient)	Joubert syndrome-like Khatri et al. ¹³ (1 patient)	MOPD1		
				Hagiwara et al. ¹⁴ (1 patient)	Sirohi et al. ¹⁵ (2 patients)	MOPD1 twins (2 patients)
Immunodeficiency	+++	+ (subclinical)	+	++		
T cells abnormalities	N	ND	Profound memory T-cells deficiency. Lack of proliferation in response to antigens	CD4+ lymphopenia. Inverted CD4+/CD8+ ratio	CD8+ lymphopenia	N
NK cells abnormalities	N	ND	ND	N	N	N
B cells	B cell	↘	ND	↘	↘	↘
	Transitional B cell	↗	ND	ND	ND	↗
	Naive mature B cell	↘ (1 patient)	ND	ND	N	ND
	Mature B cell	↘	ND	↘	N	ND
	Plasmablasts	↗	ND	ND	ND	ND
Immunoglobulins	↘	↘	↘	N	↘ (1 patient)	N

Note: N: normal absolute and relative values; +, ++, +++: degree of the immunodeficiency, ↘: decreased absolute and relative values; ↗: increased absolute and relative values; ND: not done.

the n.111G>A *RNU4ATAC* mutation. The maternal n.108_126 *RNU4ATAC* deletion encompasses part of the 3' loop and the entire Sm protein-binding region (Figure S1) known to be essential in the activity of U4atac.¹⁸ The paternal n.111G>A, located in the apical 3' stem-loop, may account for the milder phenotype. Brain gyration anomalies, major ossification delay of the epiphyses, severe antenatal and post-natal growth retardation, microcephaly and characteristic dysmorphism, together with biallelic pathogenic variants located outside stem II, confirms the diagnosis of MOPDI and excludes RFMN.

Since a partial block of B-cell maturation was already reported in RFMN patients with mutations in *RNU4ATAC*,¹² we investigated the hypothesis that immunodeficiency could also be part of the MOPDI phenotype. Variable combinations of severe combined immunodeficiency with sometimes low platelet counts may be observed in RFMN and are possibly linked to U12-type intron retention.¹⁰ Several patients with MOPDI showed decrease amounts of total lymphocytes, CD4+ T-cells, regenerative T-cells and antibodies.^{14,15} In contrast with the patient described in Hagiwara et al., the twin sisters reported here have no severe infections nor autoimmunity. While T-cell counts and functions were normal in both sisters, mild but consistent B-cell anomalies were observed at 12 and 24 months including low B-cells counts, elevated fractions of transitional cells, low naive B-cells, and elevated memory B-cells and plasmablasts. Interestingly, an increase in plasmablasts was also found in RFMN.¹⁰ These observations suggest insufficient B-cells production and excessive activation of naive

B-cells rather than a blockage of B-cell maturation, which, if any, may be partial and transitory. Along this line, this increased activation process would not be completely compensated by increased B-cell lymphocyte production by the bone marrow. In total, B-cell changes observed in the MOPDI twin sisters reported here and combined immunodeficiency observed in the three other MOPDI patients¹³⁻¹⁵ suggest that variable immunodeficiency may be observed in MOPDI. Our observations favor the idea that immunodeficiency can occur even if *RNU4ATAC* mutations are both located outside stem II. An independent work from our team using lymphoblastoid cell lines from the twin patients revealed that the g.108_126del *RNU4ATAC* mutation is unstable.¹⁶ Levels of the mature g.111G>A mutation and minor di- and tri-snRNPs were decreased compared to control cells, suggesting the occurrence of a splicing defect in U12-genes vital for immune system development (Table 2). The pathophysiology linking *RNU4ATAC* mutations to immune dysfunction in *RNU4ATAC*-associated disorders is still under investigation. Finally, we strongly recommend to perform early and thorough immune investigations in *RNU4ATAC*-opathies including MOPDI to design adapted therapeutic strategies.

AUTHOR CONTRIBUTIONS

Conceptualization and supervision: PE. Resources and validation: PE, LP, MG, SV, SC, LWG. Visualization: LWG. Writing: LWG, PE, MG, CM, SV, AP. All authors reviewed and approved the manuscript.

ACKNOWLEDGMENTS

The authors are sincerely grateful to the patients' family for their consent and contribution to this work.

CONFLICT OF INTEREST STATEMENT

None.

DATA AVAILABILITY STATEMENT

The data that support the findings of this study are available from the corresponding author upon reasonable request.

ETHICS STATEMENT

This study was accepted by the local ethics committee. Patients' parents consented for the publication of data and photographs.

ORCID

Sylvie Mazoyer  <https://orcid.org/0000-0002-2135-0160>

REFERENCES

- Majewski F, Spranger J. A new type of primordial dwarfism. *Monatsschr Kinderheilkd (1902)*. 1976;124:499-503.
- Meinecke P, Passarge E. Microcephalic osteodysplastic primordial dwarfism type I/III in sibs. *J Med Genet*. 1991;28:795-800. doi:10.1136/jmg.28.11.795
- Putoux A, Alqahtani A, Pinson L, et al. Refining the phenotypical and mutational spectrum of Taybi-Linder syndrome. *Clin Genet*. 2016;90:550-555. doi:10.1111/cge.12781
- Edery P, Marcaillou C, Sahbatou M, et al. Association of TALS developmental disorder with defect in minor splicing component U4atac snRNA. *Science*. 2011;332:240-243. doi:10.1126/science.1202205
- He H, Liyanarachchi S, Akagi K, et al. Mutations in U4atac snRNA, a component of the minor spliceosome, in the developmental disorder MOPD I. *Science*. 2011;332:238-240. doi:10.1126/science.1200587
- Padgett RA. New connections between splicing and human disease. *Trends Genet*. 2012;28:147-154. doi:10.1016/j.tig.2012.01.001
- Cologne A, Benoit-Pilven C, Besson A, et al. New insights into minor splicing—a transcriptomic analysis of cells derived from TALS patients. *RNA*. 2019;25:1130-1149. doi:10.1261/rna.071423.119
- Benoit-Pilven C, Besson A, Putoux A, et al. Clinical interpretation of variants identified in RNU4ATAC, a non-coding spliceosomal gene. *PLoS One*. 2020;15:e0235655. doi:10.1371/journal.pone.0235655
- Farach LS, Little ME, Duker AL, et al. The expanding phenotype of RNU4ATAC pathogenic variants to Lowry Wood syndrome. *Am J Med Genet A*. 2018;176:465-469. doi:10.1002/ajmg.a.38581
- Heremans J, Garcia-Perez JE, Turro E, et al. Abnormal differentiation of B cells and megakaryocytes in patients with Roifman syndrome. *J Allergy Clin Immunol*. 2018;142:630-646. doi:10.1016/j.jaci.2017.11.061
- Merico D, Roifman M, Braunschweig U, et al. Compound heterozygous mutations in the noncoding RNU4ATAC cause Roifman syndrome by disrupting minor intron splicing. *Nat Commun*. 2015;6:8718. doi:10.1038/ncomms9718
- Roifman CM. Antibody deficiency, growth retardation, spondyloepiphyseal dysplasia and retinal dystrophy: a novel syndrome. *Clin Genet*. 1999;55:103-109. doi:10.1034/j.1399-0004.1999.550206.x
- Khatri D, Putoux A, Cologne A, et al. Deficiency of the minor spliceosome component U4atac snRNA secondarily results in ciliary defects in human and zebrafish. *Proc Natl Acad Sci U S A*. 2023;120:e2102569120. doi:10.1073/pnas.2102569120
- Hagiwara H, Matsumoto H, Uematsu K, et al. Immunodeficiency in a patient with microcephalic osteodysplastic primordial dwarfism type I as compared to Roifman syndrome. *Brain Dev*. 2021;43:337-342. doi:10.1016/j.braindev.2020.09.007
- Sirohi N, Duker AL, Bober MB, DeFelice ML. Immune deficiency in microcephalic osteodysplastic primordial dwarfism type I/III. *J Clin Immunol*. 2023;43:895-897. doi:10.1007/s10875-023-01447-1
- Almentina Ramos Shidi F, Cologne A, Delous M, et al. Mutations in the non-coding RNU4ATAC gene affect the homeostasis and function of the integrator complex. *Nucleic Acids Res*. 2023;51:712-727. doi:10.1093/nar/gkac1182
- Sigaudy S, Toutain A, Moncla A, et al. Microcephalic osteodysplastic primordial dwarfism Taybi-Linder type: report of four cases and review of the literature. *Am J Med Genet*. 1998;80:16-24.
- Shukla GC, Cole AJ, Dietrich RC, Padgett RA. Domains of human U4atac snRNA required for U12-dependent splicing in vivo. *Nucleic Acids Res*. 2002;30:4650-4657. doi:10.1093/nar/gkf609

SUPPORTING INFORMATION

Additional supporting information can be found online in the Supporting Information section at the end of this article.

How to cite this article: Gauthier LW, Gossez M, Malcus C, et al. B-cell immune deficiency in twin sisters expands the phenotype of MOPDI. *Clinical Genetics*. 2024;106(4):476-482. doi:10.1111/cge.14571