



**HAL**  
open science

## Histopathological and Anti-hemorrhoid Effect of the Leaf Extract of *Ocimum gratissimum* in Croton Oil-induced Hemorrhoid

Moneme, E. C, Nwaka, A. C, Oladejo, A.A, Anyanwu, R. O, Onuegbu, M. E, Ajakpofu, F. O

► **To cite this version:**

Moneme, E. C, Nwaka, A. C, Oladejo, A.A, Anyanwu, R. O, Onuegbu, M. E, et al.. Histopathological and Anti-hemorrhoid Effect of the Leaf Extract of *Ocimum gratissimum* in Croton Oil-induced Hemorrhoid. *Journal of Complementary and Alternative Medical Research*, 2024, 25 (12), pp.1 - 10. 10.9734/jocamr/2024/v25i12592 . hal-04795293

**HAL Id: hal-04795293**

**<https://hal.science/hal-04795293v1>**

Submitted on 21 Nov 2024

**HAL** is a multi-disciplinary open access archive for the deposit and dissemination of scientific research documents, whether they are published or not. The documents may come from teaching and research institutions in France or abroad, or from public or private research centers.

L'archive ouverte pluridisciplinaire **HAL**, est destinée au dépôt et à la diffusion de documents scientifiques de niveau recherche, publiés ou non, émanant des établissements d'enseignement et de recherche français ou étrangers, des laboratoires publics ou privés.



# Histopathological and Anti-hemorrhoid Effect of the Leaf Extract of *Ocimum gratissimum* in Croton Oil-induced Hemorrhoid

**Moneme, E. C. <sup>a\*</sup>, Nwaka, A. C. <sup>a</sup>, Oladejo, A.A. <sup>b</sup>,  
Anyanwu, R. O. <sup>b</sup>, Onuegbu, M. E <sup>b</sup> and Ajakpofo, F. O. <sup>b</sup>**

<sup>a</sup> Department of Biochemistry, Chukwuemeka Odumegwu Ojukwu University, Uli, Nigeria.

<sup>b</sup> Department of Applied Biochemistry, Nnamdi Azikiwe University, Awka, Nigeria.

## **Authors' contributions**

*This work was carried out in collaboration among all authors. All authors read and approved the final manuscript.*

## **Article Information**

DOI: <https://doi.org/10.9734/jocamr/2024/v25i12592>

## **Open Peer Review History:**

This journal follows the Advanced Open Peer Review policy. Identity of the Reviewers, Editor(s) and additional Reviewers, peer review comments, different versions of the manuscript, comments of the editors, etc are available here: <https://www.sdiarticle5.com/review-history/126657>

**Original Research Article**

**Received: 03/09/2024**

**Accepted: 07/11/2024**

**Published: 20/11/2024**

## **ABSTRACT**

The use of medicinal plants in the treatment of various diseases dates back into centuries. Hemorrhoids are swollen veins in the lower rectum or anus, ranging from being acute to a complicated state; and affecting several millions of people worldwide. This study evaluates the histopathological and anti-hemorrhoid effect of the leaf extract of *Ocimum gratissimum* in croton oil-induced hemorrhoid in wistar rats. Hemorrhoids was induced to the experimental animals using croton oil, following standard methods. Thirty five (35) wistar rats were randomly grouped into five

\*Corresponding author: E-mail: [emekamoneme5@gmail.com](mailto:emekamoneme5@gmail.com);

**Cite as:** E. C., Moneme, Nwaka, A. C., Oladejo, A.A., Anyanwu, R. O., Onuegbu, M. E, and Ajakpofo, F. O. 2024. "Histopathological and Anti-Hemorrhoid Effect of the Leaf Extract of *Ocimum Gratissimum* in Croton Oil-Induced Hemorrhoid". *Journal of Complementary and Alternative Medical Research* 25 (12):1-10. <https://doi.org/10.9734/jocamr/2024/v25i12592>.

classes (A, B, C, D and E) of seven rats each. Groups A, B and C served as normal control (un-induced, untreated), negative control (induced, untreated) and standard control (induced, treated with standard drug; Daflon) respectively while groups D and E served as treatment groups and were administered 100 and 400 mg/kg dose of ethanol leaf extract of *Ocimum gratissimum* respectively. All the rats (except the group A) animals were induced with croton oil and were thereafter treated for fourteen days (two weeks). The body weight of the animals were monitored throughout the experimental period and percentage rectal water content, anorectal coefficient as well as histopathological assay were carried out at the end of the fourteen days, using standard methods. Results showed a significant decrease ( $p>0.05$ ) in body weight of the untreated group while there was a marked increase in the body weight of the animals in the extract treated groups from day 1 to the 14<sup>th</sup> day. The result of the percentage rectal water content as well as anorectal coefficient of the untreated group showed a significant increase ( $p<0.05$ ) (76%) when compared to the extract treated groups (67%), while the histopathological studies showed a reversal of the inflammatory and necrotic conditions of the induced anorectal portion for the extract treated animals. From the result of this study, it could be concluded that the leaf extract of *Ocimum gratissimum* could help to mitigate anorectal disorders and contribute significantly to improved health.

**Keywords:** *Ocimum gratissimum*; hemorrhoid; inflammation; health.

## 1. INTRODUCTION

Hemorrhoid is one of the most common inflammatory disease which can be characterized by alteration in vasculature of the anal canal including blood vessels, supporting tissues, muscles and elastic fibers. According to the report of National Centre for Health Statistics, the prevalence of hemorrhoid is 3.82% in United States (Faujdar S et al, 2019) and 0.36% in India that frequently appears in the age of 45 to 65 years (Sowndhararajan K et al, 2015). Free radical generation is the primary reason for initiation of many physiological and pathological disorders like hemorrhoids. Involvement of free radicals in the precipitation of hemorrhoids is well documented in the literature (Ojo O et al, 2013, Scaldaferrri F et al, 2018, Jorge BC et al, 2022). It is well known fact that excess concentration of free radicals is a consequence of improper balance between reactive oxygen species and their metabolites. Antioxidants neutralize free radicals and thus play major role in the eradication of these free radicals and hence are involved in the management of diseases (Onwubuya EI and Oladejo AA, 2022), including hemorrhoids. Unavoidable and serious adverse effects associated with commercial or synthetic antioxidants are becoming a major concern for the researchers to develop natural antioxidants. Herbal extracts rich in phytoantioxidants like polyphenols, flavonoids, tannins and other related compounds are known to possess positive health effects and eventually reduces the incidence of diseases (Kalu OA et al, 2024). Therefore much attention has been focused on

the use of natural antioxidants that can provide more significant health benefits with minimal toxicities (Oladejo AA et al, 2024).

*Ocimum gratissimum* (*O. gratissimum*) is a herbaceous plant that belongs to the Lamiaceae family and is sometimes referred to as smell leaf, African basil, camphor basil, basil leaf, or ram tulsi (Kalita M et al, 2023). This particular species of tropical plant is popularly known as "scent leaf," a term that Nigerians find particularly endearing. It is known as Nchanwu in Igbo, Daidoya in Hausa, and Efirin in Yoruba in native Nigeria (Zaku SG et al, 2015, Imosemi IO, 2020, Moneme EC et al.). It is a small to average-sized plant with leaves that is comparable to cloves-like flavor and aroma, making it a significant herb in various cuisines (Puneet S and Monika S, 2022). In West Africa, the plant is commonly grown for both culinary and medicinal reasons (Kalita M et al, 2023), usually in gardens around community huts. *O. gratissimum* is used as a culinary ingredient in salads, soups, pastas, vinegars, and jellies in many parts of the world. Nutritionally, the plants have been documented to be rich in microelements sufficient for improved health and vitality (Moneme EC et al.).

Additionally, the plant has been documented to contain a number of phytochemicals such as flavonoids and polyphenols (Ironi EA et al, 2016, Melo RS et al, 2019) which has been reported to be responsible for its many pharmacological activities such as hypoglycaemic activities (Shittu ST et al 2019), anti-inflammatory activities (Ajayi AM et al,

2017), anti-anaemic, hepatoprotective (Akara EU et al, 2021), anti-hypertensive (Shaw M et al, 2017), antibacterial (Melo RS et al, 2019), antifungal (Mohr FB et al, 2017) as well as exhibits many other pharmacological activities. Although there have been several reports on its other pharmacological activities, its histopathological effects, especially in hemorrhoids disease remain to be explored. Hence, this study was designed to evaluate the histopathological effect of the leaf extract of *Ocimum gratissimum* in Croton oil-Induced Hemorrhoid.

## 2. MATERIALS AND METHODS

### 2.1 Sample Collection and Preparation of Extract

Fresh leaves of *Ocimum gratissimum* were purchased from the daily market, Mgbakwu in Awka North Local Government Area of Anambra State, Nigeria and were authenticated by a Taxonomist, Mr Iroka Finan of the Department of Botany, Nnamdi Azikiwe University, Awka, and a voucher specimen was deposited with Herbarium no NAUH 35B. The leaves were then detached from the stalk, rinsed with distilled water and were oven-dried at 40 °C and weighed (300 g). The weighed powdered sample (300 g) was then used for the extraction with a solvent combination of ethanol and water (7:3) (2500 ml) for 48 hr via maceration in an unheated medium. The mixture was decanted and filtered using sterile Whatman paper No. 1. The filtrate was there after evaporated to dryness with the aid of a rotary evaporator set at 50 °C to obtain crude ethanol extract which was carefully preserved for further analysis.

### 2.2 Animal Studies

#### 2.2.1 Procurement of study animals

Wistar albino rats (35) weighing approximately 150 g were purchased from Chris Farm Ltd Mgbakwu. The rats were kept in standard cages with saw dust as bedding, and at standard room temperature as well as standard housing conditions of 12:12 light: dark cycles and fed with standard rat pellets and water *ad libitum*. The animals were allowed to acclimatize for seven days.

#### 2.2.2 Dose preparation and treatment

The hydro-ethanolic leaf extract of *Ocimum gratissimum* was prepared with distilled water in two doses (100 and 400) mg / kg, Daflon (1 g/kg)

was used as a reference drug and distilled water was used as a vehicle for the untreated group. The animals were administered the extract and drug orally for fourteen consecutive days with water *per os* and feed *ad libitum* (Liu H et al, 2012).

### 2.2.3 Experimental design

The animals were randomly grouped into five, with seven animals in each group, and the treatment was as follows: Groups A served as normal control and was administered distilled water, group B served as negative control and was induced with hemorrhoid without any treatment, group C served as the standard control and was induced and treated with standard drug (Daflon), groups D and E served as the treatment groups and was administered 100 and 400 mg/kg ethanol extract of *O. gratissimum*.

### 2.2.4 Induction of hemorrhoid

By administering a croton oil formulation, hemorrhoids were caused in all subjects except group A (Normal Control). A cotton swab (4mm in diameter) was placed into the anus and left there for 10seconds after being soaked in Croton oil preparation (0.16 ml). Within 7-8 hours of the introduction of croton oil, a linear progression of oedema was seen. Body weight was checked weekly while treatment was given daily for 14 days (Liu H et al, 2012).

### 2.2.5 Monitoring and weight evaluations

The rats were physically monitored and body weights were measured weekly. Data was collected throughout the duration of the experiment and recorded.

### 2.2.6 Treatment and anorectal evaluation

After 24 hours of induction, two rats were taken from group A and used for pilot studies; while two rats each were taken from groups B to D and used for microscopy, histology and wet weight determination respectively as baseline studies. Treatment was then given to all the groups daily for 14 days. The standard drug used for group C was Daflon at the dose of 1g (3x per day) for 4 days, then 1g (2x per day) subsequently while 100 mg/kg of extract was used to treat group D and 400 mg/kg of extract was used for group E. The control group A was given distilled water only. On day 14, all animals were euthanized under anesthesia. The anorectal portions were

subsequently cut and evaluated (Liu H et al, 2012).

### 2.2.7 Determination of wet weight and anorectal coefficient

Twenty millimeter of the anorectal portion of the first set was cut and the wet weight recorded before drying. After drying, the dry weight was also recorded. The values were used to calculate the % rectal water content by the method of Liu et al. (2012).

The % rectal water content was calculated using the formula,

$$\% \text{ rectal water content} = \frac{\text{Wet weight} - \text{Dry weight}}{\text{Wet weight}} \times \frac{100}{1}$$

The Anorectal Co-efficient (ARC) was calculated using the formular,

$$\frac{\text{Water Content (ml)}}{\text{Body weight (g)}}$$

### 2.3 Histologic and Microscopic Analysis

Twenty millimeter of the anorectal portion of the second set of rats was cut and fixed in 10% formal saline and used for microscopic and

histological evaluation by the method of Carleton (1967) and Ajibade et al., (2019) respectively.

Histological observation was performed for inflammation, congestion, hemorrhage, vasodilation and necrosis.

Microscopy was done, and the section's permanent micrographs and morphological observations were recorded.

### 2.4 Data Analysis

The values obtained and the significance between the treated and control group was analyzed by one-way ANOVA using the SPSS version 17 and P < 0.05 was considered to be statistically significant.

## 3. RESULTS

The result showing the effect of *O. gratissimum* leaf extract in Croton oil-Induced Hemorrhoid on body weight of Wistar rats is presented in Fig. 1. Result showed an increase in the weight of extract treated groups (D and E) after 14 days while there was a significant decrease in the weight of the untreated animals (group B) after 14 days. From the bar chart, a total of about 1.9% weight loss was calculated for the group B animals after the period of the experiment while 18% weight gain was observed in

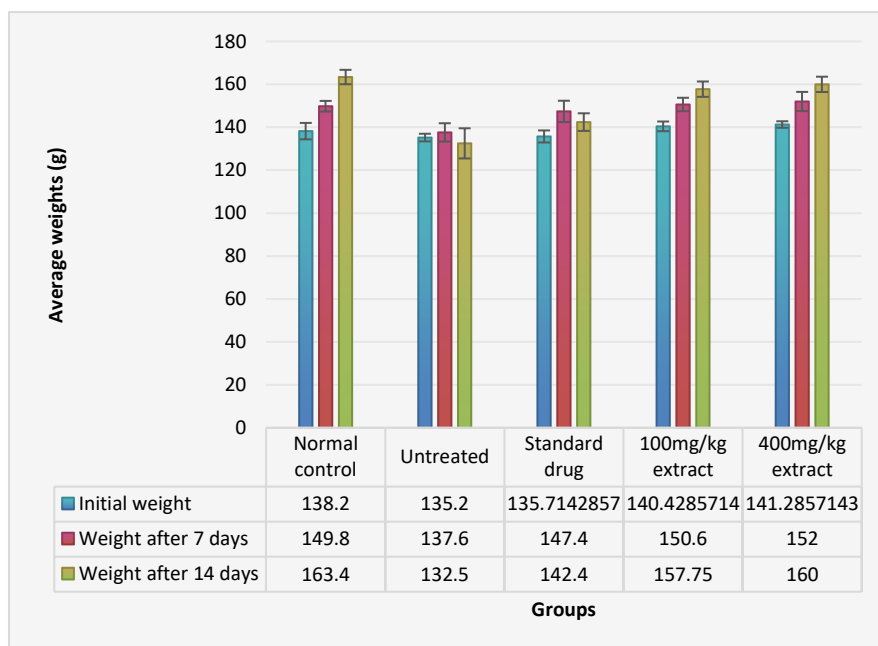


Fig. 1. Effect of Oral Administration of the leaf extract of *Ocimum gratissimum* in Croton oil-Induced Hemorrhoid on body weight of Wistar Rat

the normal control (group A). However, extract treated groups (D and E) had 12.3% and 13.2% weight increase respectively.

The result showing the effect of *O. gratissimum* leaf extract in Croton oil-Induced Hemorrhoid of percentagerectal water content in Wistar rat is presented in Fig. 2.

Result showed a significant increase in the percentagerectal water content of group B ( $76.00 \pm 1.00$ ) (untreated) animals compared to the extract treated groups D and E ( $67.00 \pm 2.34$ ) while the standard control group (group C) has percentagerectal water content of ( $67.75 \pm 1.14$ ).

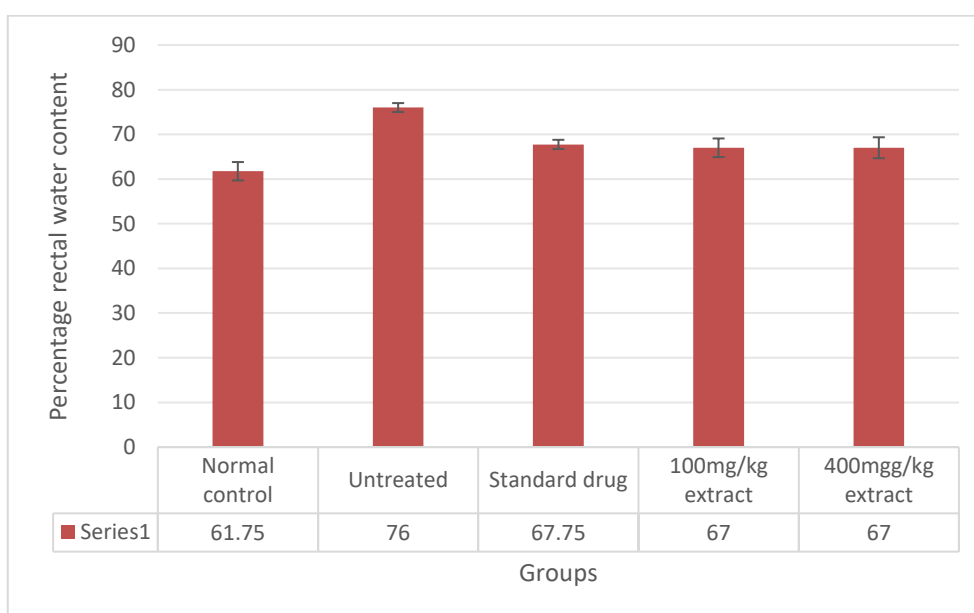
The result showing the effect of *O. gratissimum* leaf extract in Croton oil-Induced Hemorrhoid on anorectal coefficient in Wistar rat is presented in Fig. 3. Result showed a significant increase in the anorectal coefficient of group B (0.0056) (untreated) animals compared to the extract treated groups D and E (0.00415) and (0.00416) respectively while the normal control group (group A) has anorectal coefficient of 0.003825.

#### 4. DISCUSSION

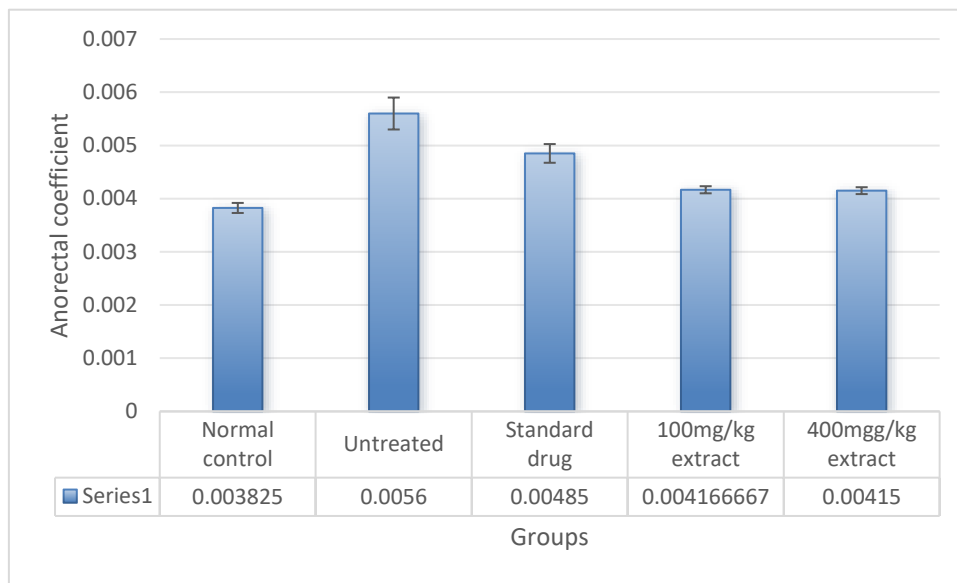
From time immemorial, medicinal plants have contributed significantly to the prevention and treatment of diseases including hemorrhoids. Plants are known to contain bioactive

compounds which help them to perform these functions (Onwubuya El et al, 2023). Assessing the impacts of plants' administration on hemorrhoid disorder remains crucial in evaluating their therapeutic index against inflammatory diseases including hemorrhoid. Thus, the possible ameliorative effects of leaf extract of *Ocimum gratissimum* on hemorrhoid were carried out.

Overall, the results of this finding showed that extract of *Ocimum gratissimum* could help to ameliorate inflammatory disorders especially hemorrhoids. Fig. 1 showed the effect of *O. gratissimum* leaf extract in croton oil-induced hemorrhoid on body weight of wistar rats. From the result of the study, there was significant increase in the body weight of the experimental animals in the extract treated groups from day 1 to day 14 of the experiment while a decline in body weight was observed for the untreated control (group B). This is consistent with the findings of Anyanwu and Ogbadu, (2024). It is worthy of note that hemorrhoids are a very common anorectal condition that has been defined as the symptomatic enlargement and distal displacement of the normal anal cushions and characterized with abnormal dilatation and distortion of the vascular channel, together with destructive changes in the supporting connective tissue within the anal cushion (Lohsiriwat V, 2017) and consequently leading to loss of water in a biological system.



**Fig. 2. Effect of oral administration of the leaf extract of *Ocimum gratissimum* in croton oil-induced hemorrhoid on percentage rectal water content of wistar rat**



**Fig. 3. Effect of Oral Administration of the leaf extract of *Ocimum gratissimum* in Croton oil-Induced Hemorrhoid on anorectal coefficient in Wistar rat**

Furthermore, the result of this study is also in agreement with previous finding which indicated that inflammation demands the convergence of more cells at the site of activity by way of secreting inflammatory cytokines and chemokines which can cause the animals to lose weight due to high energy expended in the process (Huang CM and Lee TT, 2018). Earlier reports have indicated that phytochemicals help to reduce cytokine gene expression of IL-1 $\beta$ , IL-6 and TNF- $\alpha$  which are pro-inflammatory cytokines and increase IL-10 which is anti-inflammatory cytokine in LPS-activated cells (Lee M et al, 2018). The anti-inflammatory response of the extract could be vital in averting the weight loss among the treated animals (Group D and E) and possibly enhanced its anti-hemorrhoid capacity. The response of the extract is supported by Sorhue et al. (2021) who reported that *Ocimum gratissimum* increased IL-10 expression while simultaneously decreasing IL-1 $\beta$  expression in experimental animals.

As depicted in Figs. 2 and 3, there was significant increase in the percentage rectal water content and anorectal coefficient of untreated group (group B) compared to the extract treated groups respectively. Percentage rectal water content refers to the amount of water present in the stool within the rectum, expressed as a percentage of the total stool weight. Since hemorrhoids occur when veins in the rectum or anus become swollen, percentage rectal water

content therefore plays a significant role in hemorrhoid development and prevention. Induction of hemorrhoid through the administration of croton oil in the experimental animals caused a significant increase in the rectal water content of the animals above the reference range of 60-70%. However, following the administration of the plant extract over the treatment period, the percentage rectal water content was able to be brought to normal (67%). This is an important observation as this could serve as a potential anti-hemorrhoid agent for clinical practice. This result is consistent with the reports of Anusmitha et al., (2022).

Similarly, anorectal coefficient of the untreated group was observed to be significantly high compared to the extract-treated groups. Anorectal coefficient is said to be the ratio of the anal canal length to the rectal length, typically measured during anorectal manometry and it helps to diagnose and assess anorectal disorders, including hemorrhoids. Since a high coefficient (>0.8) has been implicated in the pathogenesis of hemorrhoids, the ability of the plant extract to significantly reduce this coefficient in the treatment group is suggestive of its potency to mitigate anorectal disorders. Huiyi, (2013) made similar assertion.

The morphological Observations and the histopathology assessments (Fig. 4) displayed reversal of the inflammatory and necrotic conditions of the induced anorectal portion for



the Group E animals that were treated with 400 mg/kg dose of extract since the photomicrograph showed that the cytoarchitecture of their induced anorectal tissue was restored and normalised. This is a possible indication of the hemorrhoid

healing effect of the extract and is supported by Lohsiriwat (2012), Faujdar et al. (2019) and Margetis (2019) who identified inflammatory and necrotic conditions of the anorectal tissue as characteristic pathologic presentations

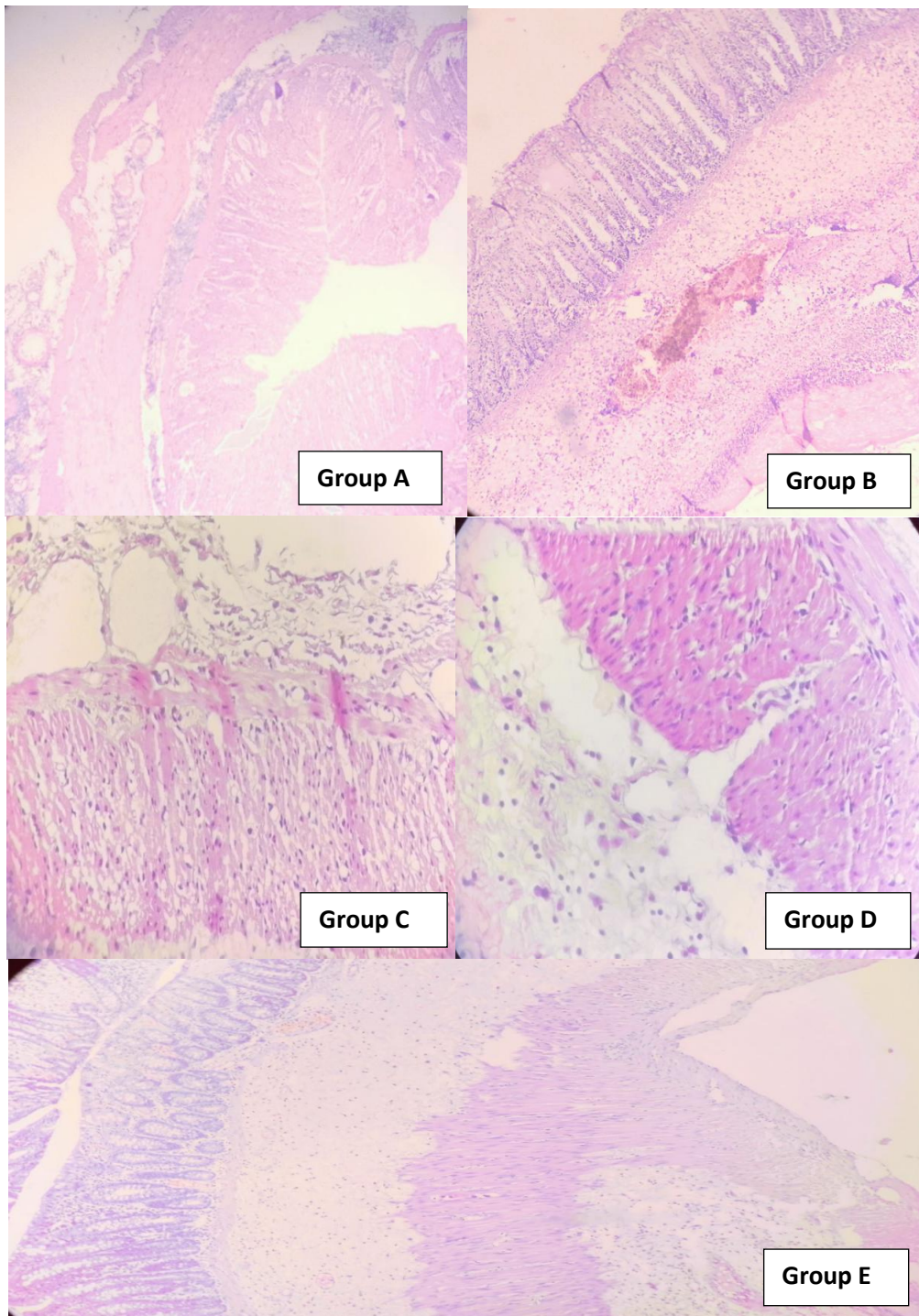


Fig. 4. Effect of oral administration of the leaf extract of *Ocimum gratissimum* in croton oil-induced hemorrhoid on microscopy and histological analysis in Wistar rat



of hemorrhoid. Also, Faujdar et al. (2019) noted that the degree of restoration or normalisation of the anorectal cytoarchitecture after treatment is indicative of the degree of hemorrhoid healing.

## 5. CONCLUSION

From the observations in this study, it can be concluded that the ethanol leaf extract of *Ocimum gratissimum* showed significant medicinal properties via the reparation of anorectal tissue and therefore could help to mitigate anorectal disorders especially hemorrhoids and serve as potential agent for inflammatory disorders.

## DISCLAIMER (ARTIFICIAL INTELLIGENCE)

Author(s) hereby declare that NO generative AI technologies such as Large Language Models (ChatGPT, COPILOT, etc.) and text-to-image generators have been used during the writing or editing of this manuscript.

## ETHICAL APPROVAL

Animal Ethic committee approval has been collected and preserved by the author(s).

## CONSENT

It is not applicable.

## COMPETING INTERESTS

Authors have declared that no competing interests exist.

## REFERENCES

- Ajayi, A. M., Umukoro, S., Ben-Azu, B., Adzu, B., & Ademowo, O. G. (2017). Toxicity and protective effect of phenolic-enriched ethylacetate fraction of *Ocimum gratissimum* (Linn.) leaf against acute inflammation and oxidative stress in rats. *Drug Development Research*, 78, 135-145. <https://doi.org/10.1002/ddr.21374>
- Ajibade, A. J., Esho, J. O., Kehinde, B. D., & Adeleye, O. O. (2019). Histological and biochemical effects of mercury chloride on the kidney of adult Wistar rats. *EAS Journal of Pharmacy and Pharmacology*, 1(1), 21-27. <https://doi.org/10.9734/easjpp/2019/v1i116865>
- Akara, E. U., Okezie, E., Ude, V. C., Uche-Ikonne, C., Eke, G., & Ugbogu, A. E. (2021). *Ocimum gratissimum* leaf extract ameliorates phenylhydrazine-induced anaemia and toxicity in Wistar rats. *Drug Metabolism Perspectives in Therapeutics*, 10(3), 342-354. <https://doi.org/10.16910/jdmpt.10.3.342>
- Anusmitha, K. M., Aruna, M., Job, T. T., Narayanankutty, A., Benil, P. B., Rajagopal, R., Alfarhan, A., & Barcelo, D. (2022). Phytochemical analysis, antioxidant, anti-inflammatory, anti-genotoxic, and anticancer activities of different *Ocimum* plant extracts prepared by ultrasound-assisted method. *Physiological and Molecular Plant Pathology*, 117, 101746. <https://doi.org/10.1016/j.pmpp.2022.101746>
- Anyanwu, G. O., & Ogbadu, D. E. (2024). Anti-obesity effect of *Ocimum gratissimum* leaf powder supplementation on high fat diet-induced obesity in male Wistar rats. *Tropical Journal of Natural Product Research*, 8(6), 7397-7402. <https://doi.org/10.26452/tjnpr.v8i6.7397>
- Carleton's Histological Techniques (4th ed.). (1967). Oxford University Press.
- Faujdar, S., Sati, B., Sharma, S., Pathak, A. K., & Paliwal, S. K. (2019). Phytochemical evaluation and anti-hemorrhoidal activity of bark of *Acacia ferruginea*. *Journal of Traditional and Complementary Medicine*, 9(2), 85-89. <https://doi.org/10.1016/j.jtcme.2018.05.004>
- Huang, C. M., & Lee, T. T. (2018). Immunomodulatory effects of phytochemicals in chickens and pigs: A review. *Asian-Australasian Journal of Animal Sciences*, 31, 617-627. <https://doi.org/10.5713/ajas.17.0556>
- Huiyi, J. (2013). Theoperamide treats neonatal hypoxic-ischemic encephalopathy by postsynaptic H1 receptors. *Neural Regeneration Research*, 8, 1814-1822. <https://doi.org/10.4103/1673-5374.124792>
- Imosemi, I. O. (2020). A review of the medicinal values, pharmacological actions, morphological effects, and toxicity of *Ocimum gratissimum* Linn. *European Journal of Pharmaceutical and Medical Research*, 7(7), 29-40. <https://www.ejpmr.com/>
- Irondi, E. A., Agboola, S. O., Oboh, G., & Boligon, A. A. (2016). Inhibitory effect of leaves extracts of *Ocimum basilicum* and *Ocimum gratissimum* on two key enzymes involved in obesity and hypertension *in vitro*. *Journal of Intercultural*

- Ethnopharmacology*, 5, 396-402. <https://doi.org/10.5455/jjce.20160517042649>
- Jorge, B. C., Júnior, A. J., Stein, J., Reis, A. C., Moreira, S., Manoel, B., et al. (2022). Safety assessment of the ethanolic extract from *Piper vicosanum* Yunck leaves in male rats. *Phytomedicine*, 2. <https://doi.org/10.1016/j.phymed.2022.154083>
- Kalita, M., Devi, N., & Narzary, D. (2023). *Ocimum gratissimum* L. ssp. *gratissimum* var. *macrophyllum* Briq. (Lamiaceae: Nepetoideae: Ocimeae) a new record from northeastern India. *Journal of Threatened Taxa*, 15(10), 24086-24091. <https://doi.org/10.11609/jott.2023.15.10.24086>
- Kalu, O. A., Onwubuya, E. I., Oladejo, A. A., Okeke, C. B., & Ezenwelu, C. O. (2024). Investigating the cardio-protective activity of *Volvariella volvacea* in isoproterenol-induced myocardial infarction using an animal model: An in vivo approach. *Journal of Complementary and Alternative Medicine Research*, 25(7), 73-83. <https://doi.org/10.9734/jcamr/2024/v25i741736>
- Lee, M., Lin, W., Wang, S., Lin, L., Yu, B., & Lee, T. (2018). Evaluation of potential antioxidant and anti-inflammatory effects of *Antrodia cinnamomea* powder and the underlying molecular mechanisms via Nrf2 and NF- $\kappa$ B dominated pathways in broiler chickens. *Poultry Science*, 97, 2419-2434. <https://doi.org/10.3382/ps/pey030>
- Liu, H., Yang, M., & Qiu, G. P. (2012). Aquaporin 9 in rat brain after severe traumatic brain injury. *Arquivos de Neuropsiquiatria*, 20(3), 214-220. <https://doi.org/10.1590/S1678-422X2012000300008>
- Lohsiriwat, V. (2012). Hemorrhoids: From basic pathophysiology to clinical management. *World Journal of Gastroenterology*, 18(17), 2009-2017. <https://doi.org/10.3748/wjg.v18.i17.2009>
- Lohsiriwat, V. (2017). Hemorrhoids: From basic pathophysiology to clinical management. *World Journal of Gastroenterology*, 18(17), 20-27. <https://doi.org/10.3748/wjg.v18.i17.3209>
- Margetis, N. (2019). Pathophysiology of internal hemorrhoids. *Annals of Gastroenterology*, 32(3), 264-272. <https://doi.org/10.20524/aog.2019.0337>
- Melo, R. S., Azevedo, A. M. A., Pereira, A. M. G., Rocha, R. R., Cavalcante, R. M. B., Matos, M. N. C., et al. (2019). Chemical composition and antimicrobial effectiveness of *Ocimum gratissimum* L. essential oil against multidrug-resistant isolates of *Staphylococcus aureus* and *Escherichia coli*. *Molecules*, 24(21), 3864. <https://doi.org/10.3390/molecules24213864>
- Mohr, F. B., Lermen, C., Gazim, Z. C., Gonçalves, J. E., & Alberton, O. (2017). Antifungal activity, yield, and composition of *Ocimum gratissimum* essential oil. *Genetics and Molecular Research*, 11(6), 23-31. <https://doi.org/10.4238/gmr16088812>
- Moneme, E. C., Nwaka, A. C., Ajakpofo, F. O., & Anyanwu, R. O. and Onuegbu, M. E., (2024). Evaluation of nutritional composition of *Ocimum gratissimum* leaf extract. *International Journal of Biochemistry Research & Review*, 33(6), 415-419. <https://doi.org/10.9734/ijbrr/2022/v33i641738>
- Ojo, O., Oloyede, O., Olarewaju, O., Ojo, A., Ajiboye, B., & Onikanni, S. (2013). In-vitro antioxidant and free radical scavenging activities of *Ocimum gratissimum*. *World Journal of Pharmaceutical Research*, 2(6), 1899-1912. <https://www.wjpr.net/>
- Oladejo, A. A., Onwubuya, E. I., Kalu, O. A., Okeke, C. B., Okeke, C. M., & Ikemefuna, P. N. (2024). Investigating the cardio-protective activity of *Agaricus bisporus* in Wistar rats induced with myocardial infarction. *Cardiology and Angiology: International Journal*, 13(3), 57-66. <https://doi.org/10.9734/caij/2024/v13i341748>
- Onwubuya, E. I., & Oladejo, A. A. (2022). Possible effects of free radical scavengers on dissolution of inflammatory granuloma: An experience with Wistar rats. *Current Research in Complementary and Alternative Medicine*, 6, 149. <https://doi.org/10.1016/j.crcam.2022.149>
- Onwubuya, E. I., Oladejo, A. A., Kalu, O. A., & Ndubueze, I. K. (2023). Possible ameliorative and preventive effect of leaf extract of *Andrographis paniculata* on atherosclerosis: An experience with isoproterenol-induced Wistar rats. *Journal of Complementary and Alternative Medicine Research*, 23(1), 1-8. <https://doi.org/10.9734/jcamr/2023/v23i142835>

- Puneet, S., & Monika, S. (2022). Exploration of antifungal potential of extracts of leaves of *Ocimum gratissimum* against *Microsporum gypseum*. *Research Journal of Pharmacy and Technology*, 4(2), 234-250. <https://www.rjpt.com/>
- Scaldaferri, F., Ingravalle, F., Zinicola, T., Holleran, G., & Gasbarrini, A. (2018). Medical therapy of hemorrhoidal disease. *Hemorrhoids*, 2(3), 319-356. <https://doi.org/10.1016/j.hem.2018.04.001>
- Shaw, M., Wu, J., & Wang, M. (2017). Antihypertensive effects of *Ocimum gratissimum* extract: Angiotensin-converting enzyme inhibitor in vitro and in vivo investigation. *Journal of Functional Foods*, 35, 68-73. <https://doi.org/10.1016/j.jff.2017.05.013>
- Shittu, S. T., Shittu, S. A., Olatunji, A. A., & Oyeyemi, W. A. (2019). *Ocimum gratissimum* leaf extract may precipitate infertility in male diabetic Wistar rats. *JBRA Assisted Reproduction*, 23, 34-44. <https://doi.org/10.5935/1678-2954.20190010>
- Sorhue, U. G., Onainor, E. R., Moemeka, A. M., & Peterson, I. E. (2021). Dietary inclusion of scent leaf meal (*Ocimum gratissimum*) affects immune gene expression in chicken spleen at 28 and 56 days. *Animal Review*, 8(1), 10-19. <https://doi.org/10.20448/jar.2021.8.1.10-19>
- Sowndhararajan, K., Hong, S., Jhoo, J. W., Kim, S., & Chin, N. L. (2015). Effect of acetone extract from stem bark of *Acacia* species (*A. dealbata*, *A. ferruginea*, and *A. leucophloea*) on antioxidant enzyme status in hydrogen peroxide induced HepG2 cells. *Saudi Journal of Biological Sciences*, 22(6), 685-691. <https://doi.org/10.1016/j.sjbs.2015.03.008>
- Zaku, S. G., Emmanuel, S., Tukur, A. A., & Kabir, A. (2015). *Moringa oleifera*: An underutilized tree in Nigeria with amazing versatility: A review. *African Journal of Food Science*, 9(9), 456-461. <https://doi.org/10.5897/ajfs2015.1373>

**Disclaimer/Publisher's Note:** The statements, opinions and data contained in all publications are solely those of the individual author(s) and contributor(s) and not of the publisher and/or the editor(s). This publisher and/or the editor(s) disclaim responsibility for any injury to people or property resulting from any ideas, methods, instructions or products referred to in the content.

© Copyright (2024): Author(s). The licensee is the journal publisher. This is an Open Access article distributed under the terms of the Creative Commons Attribution License (<http://creativecommons.org/licenses/by/4.0>), which permits unrestricted use, distribution, and reproduction in any medium, provided the original work is properly cited.

Peer-review history:

The peer review history for this paper can be accessed here:  
<https://www.sdiarticle5.com/review-history/126657>