



**HAL**  
open science

## Combined Flow-Fluorescence in situ hybridization to HHV-8 and EBV reveals the viral heterogeneity of primary effusion lymphoma

Romain Stammler, Lauriane Vacher, Benjamin Fournier, Pierre Lemaire, Clémentine Chauvel, Marc-antoine Silvestrini, Silène Knapp, Grégoire Martin de Frémont, Véronique Meignin, Maud Salmona, et al.

### ► To cite this version:

Romain Stammler, Lauriane Vacher, Benjamin Fournier, Pierre Lemaire, Clémentine Chauvel, et al.. Combined Flow-Fluorescence in situ hybridization to HHV-8 and EBV reveals the viral heterogeneity of primary effusion lymphoma. *Journal of Medical Virology*, 2024, 96 (8), 10.1002/jmv.29836 . hal-04790746

HAL Id: hal-04790746

<https://hal.science/hal-04790746v1>

Submitted on 19 Nov 2024





**HAL** is a multi-disciplinary open access archive for the deposit and dissemination of scientific research documents, whether they are published or not. The documents may come from teaching and research institutions in France or abroad, or from public or private research centers.

L'archive ouverte pluridisciplinaire **HAL**, est destinée au dépôt et à la diffusion de documents scientifiques de niveau recherche, publiés ou non, émanant des établissements d'enseignement et de recherche français ou étrangers, des laboratoires publics ou privés.



Distributed under a Creative Commons Attribution - NonCommercial 4.0 International License

# Combined Flow-Fluorescence in situ hybridization to HHV-8 and EBV reveals the viral heterogeneity of primary effusion lymphoma

Romain Stammler<sup>1</sup> | Lauriane Vacher<sup>2</sup> | Benjamin Fournier<sup>3</sup> | Pierre Lemaire<sup>4</sup> | Clémentine Chauvel<sup>4</sup> | Marc-Antoine Silvestrini<sup>1,3</sup> | Silène Knapp<sup>1</sup> | Grégoire Martin de Frémont<sup>1</sup> | Véronique Meignin<sup>5,6</sup> | Maud Salmona<sup>7</sup>  | Jérôme Legoff<sup>7</sup>  | Anthony Vanjak<sup>1</sup>  | Bertrand Dunogué<sup>8</sup> | Fanny Urbain<sup>9</sup> | Olivier Lambotte<sup>9</sup> | Nicolas Noël<sup>9</sup> | Laurence Gérard<sup>2,5</sup> | Eric Oksenhendler<sup>2,5</sup> | Lionel Galicier<sup>2,5</sup> | Sylvain Latour<sup>3</sup> | David Boutboul<sup>1,3,5,10</sup> 

<sup>1</sup>Inserm U976 HIPI, Institut Universitaire d'Hématologie, Université Paris Cité, Paris, France

<sup>2</sup>Department of Clinical Immunology, Hôpital Saint Louis, AP-HP, Université Paris Cité, Paris, France

<sup>3</sup>Laboratory of Lymphocyte Activation and Susceptibility to EBV infection, INSERM UMR 1163, Imagine Institute, Université Paris Cité, Paris, France

<sup>4</sup>Laboratory of Haematology, Hôpital Saint Louis, AP-HP, Université Paris Cité, Paris, France

<sup>5</sup>National Reference Center for Castleman disease, Hôpital Saint Louis, AP-HP, Université Paris Cité, Paris, France

<sup>6</sup>Pathology Department, Hôpital Saint Louis, AP-HP, Université Paris Cité, Paris, France

<sup>7</sup>Laboratory of Virology, Hôpital Saint Louis, AP-HP, Université Paris Cité, Paris, France

<sup>8</sup>Department of Internal Medicine, Hôpital Cochin, AP-HP, Université Paris Cité, Paris, France

<sup>9</sup>Department of Internal Medicine, Hôpital Bicêtre, AP-HP, Le Kremlin-Bicêtre, Université Paris Saclay, Le Kremlin-Bicêtre, France

<sup>10</sup>Department of Hematology, Hôpital Cochin, AP-HP, Université Paris Cité, Paris, France

## Correspondence

David Boutboul, CNR Maladies de Castleman, Université Paris Cité, 1 Ave Claude Vellefaux, 75010 Paris, France.

Email: [david.boutboul@aphp.fr](mailto:david.boutboul@aphp.fr)

## Abstract

Primary effusion lymphoma (PEL) is a rare B-cell non-Hodgkin lymphoma associated with Kaposi Sarcoma-associated herpesvirus (KSHV/HHV8) infection. Lymphoma cells are coinfecting with Epstein-Barr virus (EBV) in 60–80% of cases. Tools allowing a reliable PEL diagnosis are lacking. This study reports PEL diagnosis in 4 patients using a Flow-Fluorescence in situ hybridization (FlowFISH) technique that allowed detection of differentially expressed EBV and HHV8 transcripts within the same sample, revealing viral heterogeneity of the disease. Moreover, infected cells exhibited variable expressions of CD19, CD38, CD40, and CD138. Therefore, FlowFISH is a promising tool to diagnose and characterize complex viral lymphoproliferations.

## KEYWORDS

EBV, Flow-Fluorescence in situ hybridization, HHV8, KSHV, primary effusion lymphoma

This is an open access article under the terms of the [Creative Commons Attribution-NonCommercial-NoDerivs](https://creativecommons.org/licenses/by-nc-nd/4.0/) License, which permits use and distribution in any medium, provided the original work is properly cited, the use is non-commercial and no modifications or adaptations are made.

© 2024 The Author(s). *Journal of Medical Virology* published by Wiley Periodicals LLC.

Primary effusion lymphoma (PEL) is a rare B-cell non-Hodgkin lymphoma which usually affects immunocompromised individuals. Initial descriptions reported involvement of the pleural, peritoneal and/or pericardial cavities but extracavitary PEL cases were also described in the last two decades.<sup>1-4</sup> PEL belongs to the spectrum of Kaposi Sarcoma Associated Herpesvirus/Human herpes virus 8 (KSHV/HHV8) lymphoproliferative disorders. Diagnosis relies on the evidence of KSHV/HHV8 infected large B cells displaying loss of immunoglobulin chains, with a highly variable phenotype, marked by an inconstant expression of plasma-cell markers and a frequent aberrant positivity for T-cell lineage antigens, rendering the diagnosis of PEL challenging. Malignant PEL cells are coinfecting with Epstein-Barr Virus (EBV) in 66–80% of cases.<sup>5-8</sup> A high KSHV viral load within effusions may suggest a diagnosis of PEL. However, this approach lacks specificity, as other KSHV/HHV8-related disorders may be associated with an increased replication of KSHV/HHV-8 in effusions.<sup>9</sup> Moreover, in cases of KSHV/HHV8 + EBV + PEL, direct demonstration of viral co-infection is often difficult using conventional techniques. This is nevertheless necessary to exclude other associated EBV+ lymphoproliferative disorders that frequently co-occur in immunocompromised patients and require specific treatment.<sup>10</sup> The Flow-Fluorescence in situ hybridization (FlowFISH) technique, combining flow cytometry and fluorescence in situ hybridization (FISH), was previously validated to detect and characterize EBV-infected cells during chronic active EBV infection<sup>11</sup> and KSHV/HHV8-infected viroblasts (KIV) during active KSHV/HHV8+ multicentric Castleman disease.<sup>12</sup> We hypothesized that it could represent a novel and rapid tool for the diagnosis of PEL in effusions. Here we report four cases of PEL supporting the role of FlowFISH in the diagnosis of these complex viral-induced lymphoproliferations. Moreover, FlowFISH allowed the detection of multiple cell populations differentially expressing EBV and HHV8 transcripts within a same patient, underlining the viral heterogeneity of the disease. This work was approved by our local ethics committee (CLEA-2020-113) and was in accordance with the ethical standards of the Declaration of Helsinki. All patients gave informed consent to participate in the study.

Clinical and biological characteristics of the four patients are summarized in Table 1. The first patient was a 68-year-old HIV-positive male patient admitted for the exploration of rapid onset of cognitive impairment and cerebellar dysfunction. B symptoms were absent and extra-neurological clinical examination was unremarkable. HIV viral load was undetectable upon admission. Peripheral blood lymphocyte immunophenotyping showed only HIV-related CD4 T-cell lymphopenia and no abnormal B- or T-cell populations were isolated. Whole-body Positron Emission Tomography-Computed Tomography (PET-CT) scan did not find any pathological hypermetabolic activity. A T2/FLAIR gadolinium-enhanced hypersignal of the superior part of the cerebellar vermis was noted on cerebral magnetic resonance imaging (MRI). Spinal tap showed normal opening pressure (12 cm H<sub>2</sub>O), meningitis (230 leukocytes/mm<sup>3</sup>, differential: lymphocytes = 19%, other cells = 79%), an increased cerebrospinal fluid (CSF) protein level (302 mg/dL) and a decreased glucose level

(0.8 mmol/L, synchronous blood glucose level = 7 mmol/L). Cerebrospinal fluid herpesvirus screening was positive for EBV (4.88 log/mL, synchronous whole blood PCR = 4.15 log/mL) and KSHV/HHV8 (6.27 log/mL, synchronous whole blood PCR = 4.55 log/mL). Cerebrospinal fluid cytology revealed very large basophilic lymphoid cells with irregular nuclei. Cerebrospinal fluid lymphocyte phenotyping failed to identify any abnormal population. We performed a FlowFISH analysis on 3.10<sup>5</sup> CSF cells demonstrating the presence of an abnormal CD38+ CD138+ CD19- CD40+ population (representing 22% of the total number of cells) expressing both latency-associated nuclear antigen (LANA) and Epstein Barr encoding region (EBER) viral transcripts (Figure 1, refer to Supplemental Material for technical details). Interestingly, a small population of cells that had the same phenotype as the LANA+ EBER+ population expressed only LANA (Supporting Information S1: Figures 1 and 2).

The second patient was a 70-year-old HIV-negative male patient admitted for acute dyspnea associated with weight loss. He had a medical history of chronic lymphocytic leukemia diagnosed 3 years earlier, with a watch-and-wait strategy. CT-scan showed bilateral pleural effusion associated with pericardial effusion and diffuse lymphadenopathy. A thoracocentesis was performed revealing pleiomorphic lymphoid cells with Sternberg-like, anaplastic-like morphology. Pleural effusion lymphocyte phenotyping demonstrated the presence of a large CD20-CD3-population expressing CD30 and CD138 antigens. Pleural effusion herpesvirus screening was positive for EBV (7.01 log/mL, synchronous whole blood PCR = 4.44 log/mL) and KSHV/HHV8 (9.12 log/mL, synchronous whole blood PCR = 5.47 log/mL). FlowFISH was performed on 5.10<sup>6</sup> pleural cells demonstrating the presence of an abnormal CD38+ CD138- CD19- CD40- population (representing 1% of the total number of cells) expressing both LANA and EBER viral transcripts (Figure 1). Again, a small LANA+ population was detected bearing the same phenotype as the LANA + EBER+ population (Supporting Information S1: Figures 1 and 2).

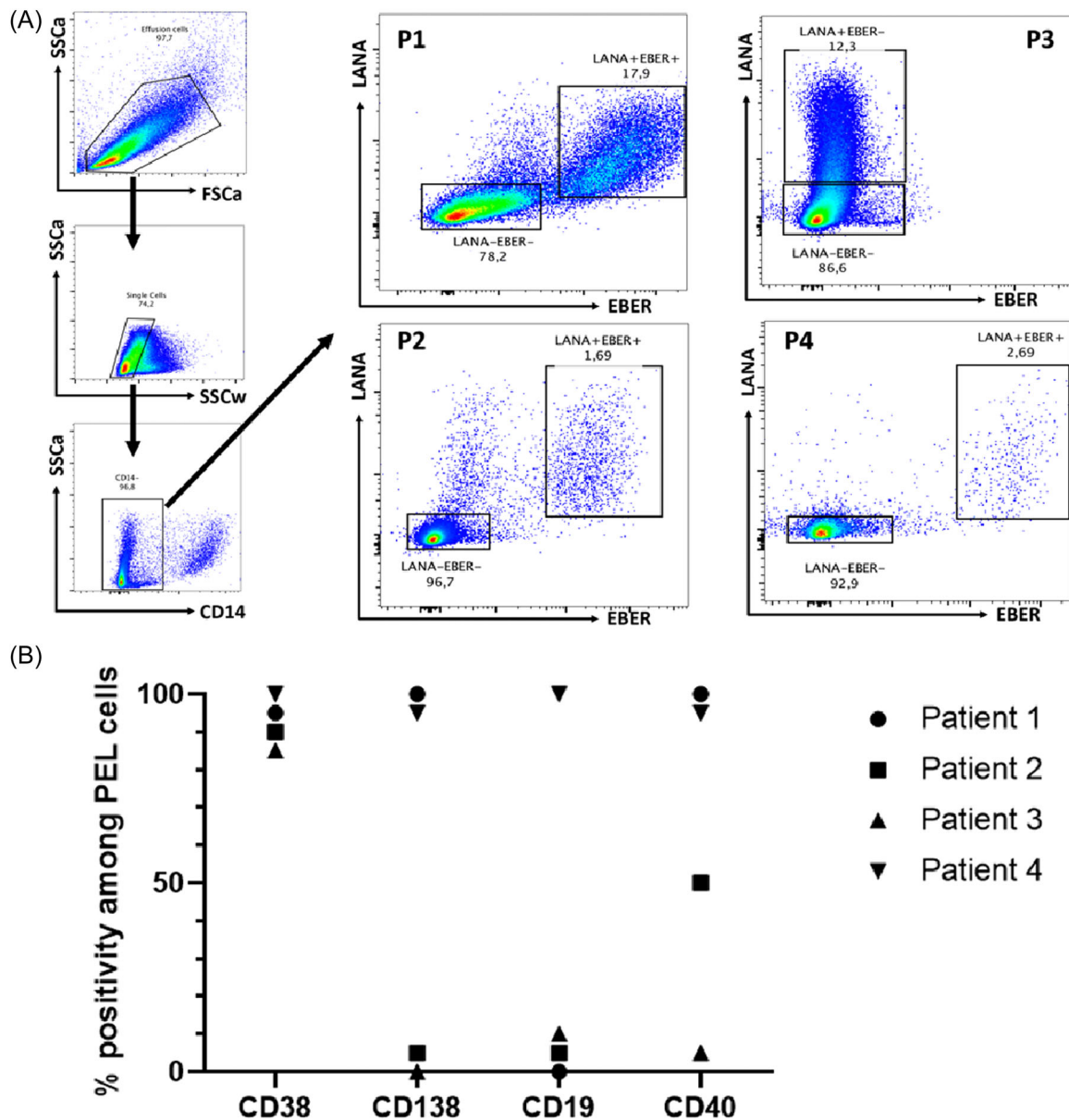
The third patient was a 84-year-old HIV-negative male patient who presented with an increased abdominal girth and weight gain occurring 6 months after having received rituximab for the treatment of a first flare of HHV8+ multicentric Castleman disease. Peripheral blood lymphocyte immunophenotyping was unremarkable. A CT-scan was performed showing abundant ascites. A paracentesis was performed revealing exudative effusion containing large lymphoid cells with irregular nuclei and several nucleoli. Lymphocyte phenotyping showed the presence of a large CD138-CD20-CD30-CD3+ population evocative of T-cell lymphoma. Effusion was positive for HHV8 (8.01 log/mL, synchronous whole blood PCR = 3.75 log/mL) and negative for EBV. FlowFISH was performed on 5.10<sup>6</sup> cells demonstrating the presence of an abnormal CD38+ CD138- CD19- CD40- population (representing 9% of the total number of cells) expressing only the LANA viral transcript (Figure 1).

The fourth patient was a 25-year-old HIV-positive male patient presenting with dyspnea, diffuse lymphadenopathy and splenomegaly. Plasma HIV viral load was low (29 copies/mL). A CT-scan showed bilateral pleural effusion. A PET-CT was also performed revealing

TABLE 1 Clinical and biological features of the four patients with PEL.

Sex	Age at diagnosis (years)	HIV status	HIV load (copies/mL)	CD4 count ( $\times 10^6/L$ )	HIV viral load (copies/mL)	Localization of PEL	Whole blood			EBV viral load within effusion (log)	Cytological exam	Routine immune phenotyping	PEL phenotype	PEL karyotype	Outcome
							HHV8 viral load (log)	HHV8 viral load within blood (log)	Whole blood EBV viral load (log)						
P1	M	68	+	329	0	CNS	4.55	6.27	4.15	4.88	Very large basophilic lymphoid cells with irregular nucleus	Negative	CD38 + CD138 + CD19- CD40+	NA	Complete response at 12 months
P2	M	70	-	NA	0	Pericardial and pleural	9.12	5.47	4.42	7.01	Pleiomorphic lymphoid cells with Sternberg-like, anaplastic-like morphology	CD138 + CD30 + CD20- CD3-CD5-CD10- -	CD38 + CD138- CD19- CD40low	NA	Ongoing first line treatment
P3	M	84	-	631	0	Peritoneal	3.75	8.1	0	0	Large lymphoid cells with irregular nuclei and several nucleoli	CD138-CD20- CD30-CD3+	CD38 + CD138- CD19- CD40-	Complex, hyperdiploidy	Deceased 7 months after diagnosis (progressive disease)
P4	M	25	+	335	29	Pericardial and pleural	5.19	8.1	4.34	6.43	Negative	Negative	CD38 + CD138 + CD19 + CD40+	Complex	Alive in relapse 4 years after diagnosis

Abbreviations: CNS, central nervous system; EBV, Epstein Barr Virus; HHV8, Human Herpes Virus 8; HIV, human immunodeficiency virus; int, intermediary; M, male; NA, not available; PEL, primary effusion lymphoma.



**FIGURE 1** Viral and host phenotypes of 4 cases of primary effusion lymphomas using FlowFISH. (A) Flow-Fluorescence in situ hybridization (FlowFISH) using latency associated nuclear antigen (LANA) and Epstein Barr encoding region (EBER) probes. After selection of single cells, gating was performed on the CD14-negative population of patient 1 (P1), patient 2 (P2), patient 3 (P3) and patient 4 (P4). Data are representative of two independent experiments. (B) Column scatter plot of CD38, CD138, CD19 and CD40 expression among LANA+ EBER+ population in patients 1 (circle), 2 (square) and 4 (down arrowhead), and in LANA+ EBER- population in patient 3 (up arrowhead).

metabolic hyperactivity of the lymph nodes without pleural activity. A thoracentesis was performed revealing large basophil cells with irregular nuclei. Routine pleural immune phenotyping revealed an inflammatory infiltrate composed of normal CD4+ and CD8+ lymphocytes. Pleural effusion herpesvirus screening was positive for EBV (6.43 log/mL, synchronous whole blood PCR = 4.34 log/mL) and KSHV/HHV8 (8.1 log/mL, synchronous whole blood PCR = 5.19 log/mL). We performed a FlowFISH analysis on  $8.10^5$  pleural cells demonstrating the presence of an abnormal CD38+ CD138+ CD19+ CD40+ population (representing 2% of the total number of cells) expressing both LANA and EBER transcripts (Figure 1). A LANA

mono-infected population was also detected but represented a minority among all lymphoid cells and was not further characterized due to the low number of events on flow cytometry analysis.

There is no gold standard for the diagnosis of cavity PEL. PEL remains a challenging situation for clinicians and pathologists, especially when dealing with small effusion samples such as CSF. Moreover, the percentage of abnormal cells within an effusion is often small compared to the abundant reactive lymphoid infiltrate. Here we report four cases of PEL with variable localizations and heterogeneous clinical presentations. Cytology, lymphocyte phenotyping and assessment of KSHV/HHV8 viral load were first-line

useful diagnostic techniques but not only lacked sensitivity and specificity, but also failed to show direct infection of the malignant cells. A recent study by Lurain et al. reported 26 patients with cavitory or extracavitary systemic PEL, among whom 5 (19%) had evidence of neurological involvement, underlining meningeal tropism of PEL.<sup>3</sup> In this work, KSHV/HHV8 viral load in CSF was strongly associated with asymptomatic CSF involvement during systemic PEL but lacked specificity, as one of four patients (25%) with KSHV/HHV8+ multicentric Castleman disease who underwent CSF sampling also had increased intrathecal KSHV/HHV8 replication without evidence of PEL. Performed on a small number of cells, FlowFISH allows the direct detection of the infected lymphomatous population, even within an abundant reactive infiltrate. Multiparametric flow cytometry is a helpful support to thoroughly characterize the phenotype of PEL and will help identify novel therapeutic targets in a near future. Finally, FlowFISH allowed the detection of multiple malignant populations differentially expressing EBV and KSHV/HHV8 transcripts within a same patient, underlining the viral heterogeneity of the disease. We thus carefully reviewed the phenotype of the monoinfected KSHV+/EBV- population in all patients and none had the same phenotype as KSHV-infected viroblasts (KIVs, 12) or Lambda-restricted cells (LRPs, 9). The evaluation of light chain expression using intracellular flow cytometry was negative in the KSHV+/EBV- population (Supporting Information S1: Figures 1 and 2). The KSHV+/EBV- population was in fact strictly comparable to the KSHV+/EBV+ population. Since the coinfecting population was largely predominant in the effusions, these data suggest that while KSHV/HHV8 infection seems to drive the extracellular phenotype of PEL, EBV superinfection seems crucial in promoting the survival and proliferation of malignant cells. These data, obtained on a limited number of patients, need further evaluation to define the exact position of FlowFish in the diagnostic workup of PEL.

In conclusion, FlowFISH appears to be a promising tool for the accurate and rapid diagnosis of PEL and other complex virus-induced lymphoproliferations.

## 2 | STUDY APPROVAL

This work was approved by our local ethics committee (CLEA-2020-113) and was in accordance with the ethical standards of the Declaration of Helsinki. All patients gave informed consent to study participation.

### AUTHOR CONTRIBUTIONS

Romain Stammler and David Boutboul wrote the manuscript. Lauriane Vacher, Véronique Meignin, Laurence Gérard, Eric Oksenhendler, Lionel Galicier, Fanny Urbain, Nicolas Noël, Olivier Lambotte, and David Boutboul contributed to the patient recruitment and management. Pierre Lemaire and Clémentine Chauvel performed cytologic examination and routine immune phenotyping. Marc-Antoine Silvestrini and Jérôme Legoff performed evaluation of EBV

and HHV-8 viral loads. Bertrand Dunogué performed English editing of the manuscript. Romain Stammler, Benjamin Fournier, Silène Knapp, Grégoire Martin de Frémont, Anthony Vanjak, and David Boutboul set up the FlowFISH technique. Romain Stammler, Benjamin Fournier, Marc-Antoine Silvestrini, Silène Knapp, and David Boutboul performed experiments and interpreted data. David Boutboul supervised the project. All the authors critically reviewed the manuscript.

### CONFLICT OF INTEREST STATEMENT

The authors declare no conflict of interest.

### DATA AVAILABILITY STATEMENT

Data and detailed protocols are available upon request to the corresponding author ([david.boutboul@aphp.fr](mailto:david.boutboul@aphp.fr)).

### ORCID

Maud Salmon  <http://orcid.org/0000-0001-7985-6132>

Jérôme Legoff  <http://orcid.org/0000-0001-7111-1865>

Anthony Vanjak  <http://orcid.org/0000-0002-9288-3386>

David Boutboul  <http://orcid.org/0000-0002-5006-8279>

### REFERENCES

- Simonelli C, Spina M, Cinelli R, et al. Clinical features and outcome of primary effusion lymphoma in HIV-infected patients: a single-institution study. *J Clin Oncol*. 2003;21(21):3948-3954.
- Guillet S, Gérard L, Meignin V, et al. Classic and extracavitary primary effusion lymphoma in 51HIV-infected patients from a single institution. *Am J Hematol*. 2016;91(2):233-237.
- Lurain K, Ramaswami R, Marshall V, et al. Kaposi sarcoma herpesvirus viral load as a biomarker for leptomeningeal involvement by primary effusion lymphoma. *Haematologica*. 2022;108(7):1940-1944.
- Kabiawu-Ajise OE, Harris J, Ismaili N, Amorosi E, Ibrahim S. Primary effusion lymphoma with central nervous system involvement in an HIV-negative homosexual male. *Acta Haematol*. 2012;128(2):77-82.
- Horenstein MG, Nador RG, Chadburn A, et al. Epstein-Barr virus latent gene expression in primary effusion lymphomas containing Kaposi's sarcoma-associated Herpesvirus/Human Herpesvirus-8. 1997.
- Nador R, Cesarman E, Chadburn A, et al. Primary effusion lymphoma: a distinct clinicopathologic entity associated with the Kaposi's sarcoma-associated herpes virus. *Blood*. 1996;88(2):645-656.
- Calvani J, Gérard L, Fadlallah J, et al. A comprehensive clinicopathologic and molecular study of 19 primary effusion lymphomas in HIV-infected patients. *Am J Surg Pathol*. 2022;46(3):353-362.
- Lurain K, Polizzotto MN, Aleman K, et al. Viral, immunologic, and clinical features of primary effusion lymphoma. *Blood*. 2019;133(16):1753-1761.
- Zhou T, Yuan CM, Lurain K, et al. A novel approach for characterization of KSHV-associated multicentric Castleman disease from effusions. *Br J Haematol*. 2023;200(4):462-475.
- Marcelin AG, Motol J, Guihot A, et al. Relationship between the quantity of kaposi sarcoma-associated herpesvirus (KSHV) in peripheral blood and effusion fluid samples and KSHV-associated disease. *J Infect Dis*. 2007;196(8):1163-1166.
- Fournier B, Boutboul D, Bruneau J, et al. Rapid identification and characterization of infected cells in blood during chronic active Epstein-Barr virus infection. *J Exp Med*. 2020;217(11):e20192262.

12. Martin De Frémont G, Vanjak A, Sbihi Z, et al. Characteristics of circulating KSHV-infected viroblasts during active KSHV+ multicentric Castleman disease. *Blood Adv.* 2023;7(9):1682-1691.

### SUPPORTING INFORMATION

Additional supporting information can be found online in the Supporting Information section at the end of this article.

**How to cite this article:** Stammeler R, Vacher L, Fournier B, et al. Combined Flow-Fluorescence in situ hybridization to HHV-8 and EBV reveals the viral heterogeneity of primary effusion lymphoma. *J Med Virol.* 2024;96:e29836.

[doi:10.1002/jmv.29836](https://doi.org/10.1002/jmv.29836)