



HAL
open science

The management of delayed cerebral ischemia after aneurysmal subarachnoid hemorrhage

B. Balança, B. Bouchier, T. Ritzenthaler

► **To cite this version:**

B. Balança, B. Bouchier, T. Ritzenthaler. The management of delayed cerebral ischemia after aneurysmal subarachnoid hemorrhage. *Revue Neurologique*, 2022, 178 (1-2), pp.64-73. 10.1016/j.neurol.2021.11.006 . hal-04789933

HAL Id: hal-04789933

<https://hal.science/hal-04789933v1>

Submitted on 29 Nov 2024

HAL is a multi-disciplinary open access archive for the deposit and dissemination of scientific research documents, whether they are published or not. The documents may come from teaching and research institutions in France or abroad, or from public or private research centers.

L'archive ouverte pluridisciplinaire **HAL**, est destinée au dépôt et à la diffusion de documents scientifiques de niveau recherche, publiés ou non, émanant des établissements d'enseignement et de recherche français ou étrangers, des laboratoires publics ou privés.



Distributed under a Creative Commons Attribution - NonCommercial 4.0 International License

The management of delayed cerebral ischemia after aneurysmal subarachnoid hemorrhage.

Baptiste Balança^{1,2}, Baptiste Bouchier¹, Thomas Ritzenthaler^{1,3}

Affiliations:

1 Hospices civils de Lyon, hôpital neurologique, service d'anesthésie réanimation, 59, boulevard Pinel, 69500 Bron, France

2 Université de Lyon, Centre de recherche en neurosciences de Lyon, équipe TIGER, U1028, UMR5292, 69500 Bron, France

3 Université de Lyon CREATIS, CNRS UMR5220, INSERMU1044, INSA-Lyon, Université Lyon 1, Hospices Civils de Lyon, Bron Cedex, France

Corresponding author: Baptiste Balança

e-mail : baptiste.balanca@chu-lyon.fr

Postal adress: Service d'anesthésie réanimation neurologique, Hôpital Pierre Wertheimer ; 59 Bd Pinel, 69677 Bron cedex, France

Declarations of interest: none.

Funding sources: This research did not receive any specific grant from funding agencies in the public, commercial, or not-for-profit sectors.

Acknowledgement: not applicable

Abstract:

Aneurysmal subarachnoid hemorrhage (SAH) is a rare event affecting relatively young patients therefore leading to a high social impact. The management of SAH follows a biphasic course with early brain injuries in the first 72 hours followed by a phase at risk of secondary deterioration due to delayed cerebral ischemia (DCI) in 20 to 30% patients. Cerebral infarction from DCI is the most preventable cause of mortality and morbidity after SAH. DCI prevention, early detection and treatment is therefore advocated. Formerly limited to the occurrence of vasospasm, DCI is now associated with multiple pathophysiological processes involving for instance the macrocirculation, the microcirculation, neurovascular units, and inflammation. Therefore, the therapeutic targets and management strategies are also evolving and are not only focused on proximal vasospasm. In this review, we describe the current knowledge of DCI pathophysiology. We then discuss the diagnosis strategies that may guide physicians at the bedside with a multimodal approach in the unconscious patient. We will present the prevention strategies that have proven efficient as well as future targets and present the therapeutic approach that is currently being developed when a DCI occurs.

Keywords: Subarachnoid hemorrhage, Delayed cerebral ischemia, Vasospasm

Abbreviations:

aNIHSS: abbreviated national institute of health stroke scale

BOX: Bilirubin oxidation products

CBF: cerebral blood flow

CT: computed tomography

DAMPs: Damaging associated molecular patterns

DCI: delayed cerebral ischemia

EBI: early brain injuries

EEG: electroencephalography

mGCS: modified Glasgow coma scale

NO: nitric oxide

PbtO₂: partial brain tissue oxygen pressure

SAH: subarachnoid hemorrhage

SD: spreading depolarization

TCD: transcranial doppler

TCCS: Transcranial Color-Coded real-time Sonography

Introduction:

Aneurysmal subarachnoid hemorrhage (SAH) due to the rupture of an intracranial aneurysm is a rare event affecting relatively young patients therefore leading to a high social impact [1]. SAH 28-day

mortality is reported to range from 26% to 40% in Europe [2] and half of those who survive sustain irreversible brain damage [3]. The management of SAH follows a biphasic course with an early phase due to bleeding consequences, such as cerebral edema, intracerebral hemorrhage, mechanical stress, raised intracranial pressure or systemic complications as well as re-bleeding or aneurysm treatment complications. These first brain insults have been grouped together and termed early brain injuries (EBI) and are important determinants of poor outcome [4–6]. The second phase between day 3 and day 21 is at risk of secondary deterioration due to delayed cerebral ischemia (DCI) in 20 to 30% of patients, peaking in the second week after bleeding [7]. Cerebral infarction from DCI is the most preventable cause of mortality and morbidity after SAH [8]. Therefore, DCI prevention, early detection and treatment before irreversible damage occurrence is a key element in the management of patients following SAH [9].

Despite improvement in patient care and DCI prevention [3,10], SAH is fraught with significant morbidity. For decades cerebral vasospasm was thought to be the main process underlying DCI, however the current knowledge of its pathophysiology evidenced multiple processes, and elements that lead to new cerebral infarction are partially understood. This new approach also implies management strategies that are not centered solely on the diagnosis and treatment of proximal vasospasm and remains a matter of debate [8,9,11].

In this review, we will describe the current knowledge of DCI pathophysiology. We will then discuss the diagnosis strategies that may guide physicians at the bedside with a multimodal approach in the unconscious patient with an unreliable clinical examination. We will present the prevention strategies that have proven efficient as well as future targets and present the therapeutic approach that is currently being developed when a DCI occurs.

Delayed cerebral ischemia pathophysiology (Fig. 1):

Formerly limited to the occurrence of vasospasm, DCI is now associated with multiple pathophysiological processes involving for instance the macrocirculation, the microcirculation, neurovascular units, and inflammation. Cerebral vasospasm is defined as a focal or diffuse arterial narrowing seen on vascular imaging involving large intradural (i.e. pial) arteries located on the surface of the brain [12]. Cerebral vasospasm can be observed from several days following the initial bleeding and its occurrence peaks one week later [7,13]. At the early phase, the release of calcium triggers by the subarachnoid clot leads to sustained smooth muscle contraction. Later mechanisms are calcium independent and involve chemical and ultrastructural changes of the vascular wall layer [13]. The oxidation of oxyhemoglobin released from blood clot produces methemoglobin and superoxide anion radicals which trigger oxidative stress, inflammation and imbalance the vascular tone toward vasoconstriction. There will be an over-production of vasoconstriction factors such as endothelin-1 and a depletion of vasodilatory factors such as neuropeptide and nitric oxide (NO). NO is scavenged by oxyhemoglobin and there is a downregulator of endothelial NO synthase [14]. Endless inflammatory mechanisms activated after SAH may contribute to vascular remodeling, leading to narrowing of the arterial wall [13]. Angiographic vasospasm is very common, as it affects up to two-thirds of patients after SAH, but only one-third experience neurological decline [15] and proximal arterial spasm may be compensated by distal autoregulatory vasodilatation.

After SAH, neurovascular coupling is disrupted and may even be inverted due to the lack of vasodilation agents as discussed above. Instead of vasodilatation in response to neuronal activation, a transient or sustained vasoconstriction can be observed that may result in ischemic damage [16].

The presence of a clot in the subarachnoid space may also trigger cortical spreading depolarizations (SD) that will propagate in the gray matter at rate of a few mm/min on the cortical surface associated with a depression of the background neuronal activity [17]. They result in a near complete breakdown of cell membrane potentials and required a huge amount of energy to recover [18]. They are mainly observed between day 5 and day 7 after bleeding; when NO is low, such as after an SAH,

SD can induce an inverse vascular coupling also called spreading ischemia that can contribute to DCI [19] and may induce band-like cortical lesions that can develop independently of a cerebral vasospasm [20].

The initial bleeding triggers a strong inflammatory response, which correlates with both EBI and DCI. As blood enters the subarachnoid space, it releases molecules that promote an inflammatory response. Heme and other red blood cell degradation products (bilirubin oxidation products, BOX) can act as damage-associated molecular pattern (DAMPs) recognize by innate immune cells with pattern recognition receptors expressed mainly by microglial cells and infiltrating monocytes [16,21]; as the blood brain barrier breakdown during EBI allows peripheral immune cells (neutrophils, monocytes/macrophages, lymphocytes) to penetrate into the brain [15]. The activation of microglia and the intrathecal infiltration of neutrophils may help to clear these red blood cell degradation products that entered the subarachnoid space, but they can also cause neuronal apoptosis [22]. Pattern recognition receptors expression, such as the toll like receptor 4 or the receptor for advanced glycation end products which both bind heme and BOX, are related to vasospasm [22]. Moreover, the subsequent cytokine release (e.g. interleukin 6 and 1 β , tumor necrosis factor, matrix metalloproteinase 9) lead to sterile inflammation and eventually to neuronal death, and have been associated with vasospasm and DCI [15].

The transient global cerebral ischemia that is the consequence of EBI causes a no-reflow phenomenon causing platelet aggregation in micro vessels thereby forming microthrombi [7]. The early constriction of the microvasculature with reduced flow also facilitates the formation of platelet aggregates. Moreover, ischemic endothelial injury resulting from the limited cerebral blood flow (CBF) exposes collagen, von Willebrand factor, and thrombin perpetuating platelet activation [15]. Activated platelets may participate in vascular constriction and wall remodeling through the release of thromboxane A₂ or prostaglandin [23–25].

If cerebral autoregulation mechanisms are overwhelmed, a drop in perfusion pressure or increased metabolic needs result in insufficient blood and nutrient supply leading to cerebral ischemia [26]. This microvascular dysfunction may also be affected by the consequences of EBI that is responsible for transient global ischemia leading to neuronal death (cytotoxic edema) and endothelial damage with breakdown of the blood brain barrier (vasogenic edema) thereby affecting cerebral autoregulation [27]. The obstruction of cerebrospinal fluid flow, resulting in hydrocephalus and increased brain water content, and/or intraparenchymal hemorrhage contribute also to the rise in intracranial pressure thereby reducing CBF [16].

How to diagnose delayed cerebral ischemia

DCI has multiple origins but is defined as the occurrence of a new focal neurological deficit or decrease of the level of consciousness lasting more than one hour, in the absence of another cause of neuro-worsening [12]. Frequent neurological assessment to detect a new deficit is therefore critical and can be monitored with the modified Glasgow Coma Scale (mGCS, i.e. using the worse instead of the best motor score) or the abbreviated National Institute of Health Stroke Scale which includes the elements that are the most related to neurological outcome (aNIHSS, i.e. rating seven items including the level of consciousness, left and right arm motor movement, left and right leg motor movement, speech fluency, and speech clarity) [28,29]. A two-point mGCS decrease or aNIHSS increase, and/or a new focal neurological deficit in patients with a reliable clinical examination must evoke a DCI in the absence of another diagnosis [30]. In the unconscious patient (because of EBI or due to ongoing sedation), the detection of DCI is more challenging before irreversible ischemic lesions are present. Daily wake-up trials in brain-injured sedated patients should be performed with extreme caution as it can raise intracranial pressure and reduce brain oxygenation [31]. Multimodal neuromonitoring is thus advocated looking for proximal vasospasm, cerebral energetic mismatch, or abnormal neurological activities (Fig. 2).

Transcranial Doppler ultrasonography (TCD) is a non-invasive tool widely available at the bedside with a rapid learning curve [32]. TCD can detect large vessel narrowing with elevated velocities as long as the cerebral perfusion pressure is maintained. In addition, transcranial color-coded real-time sonography (TCCS) helps visualize the vessel of interest and select sites with high velocities [33]. A mean velocity in the middle cerebral artery $> 120\text{cm/s}$ has 67% sensitivity and 99% specificity to diagnose vasospasm [34]. However, the diagnostic accuracy for anterior and posterior cerebral arteries is poorer with many false negative tests (40-80%) [34]. Blood flow velocities are also influenced by hemoglobin level, blood pressure and arterial CO_2 . The Lindegaard index (i.e. the ratio between mean velocities in the middle cerebral artery and the extracranial portion of the internal carotid) can distinguish between vasospasm and hyperemia, an index > 3 being in favor of a vasospasm [35]. Although TCD monitoring is recommended after SAH, it is not specific for DCI as it detects proximal vasospasm regardless of its consequences on downstream CBF and subsequent neurological deficit [36,37]. When the neurological examination is not reliable, DCI is tracked with indirect markers of cerebral energetic mismatch such as low partial brain tissue oxygen pressure (PbtO_2) or low extracellular glucose. Several thresholds have been described to diagnose an energetic mismatch. For instance, a $\text{PbtO}_2 < 20\text{mmHg}$ should raise an alert while a value below 10mmHg is considered critical [38]. A cerebral glucose concentration $< 0.7\text{mmol/l}$ and/or a lactate/pyruvate ratio > 40 is also considered critical [39]. However, trend analyses may be even more relevant than single threshold values to guide intervention at the bedside [9]. Those markers are monitored with intracranial probes in the white matter (PbtO_2 and/or cerebral microdialysis) and are therefore very dependent on the location of the probe in relation to the ischemic region. Even if the probe placement should match the territory most at risk of DCI it is not always accessible and delayed infarcts may be missed and detected on follow-up brain imaging [40].

Unlike regional intracranial monitoring, electroencephalography (EEG) is a non-invasive technique providing functional information from most superficial cortical area, with ischemia related changes occurring before the CBF decrease reaches irreversible ischemic values [41,42]. Several studies

investigated EEG changes associated with DCI and evidenced that a prolonged decrease in the alpha/theta ratio (i.e. focal or global slowing of brain activity) and/or the appearance of lateralized periodic discharges are associated with DCI and may precede clinical deterioration [43,44]. However, EEG cannot detect other DCI mechanisms such as SD that requires cortical electrodes to evidence the slow potential changes that spread across the cortex [Dreier.2017yvl]. SD monitoring may in the near future be implemented in a multimodal monitoring approach as they are both a mechanism of DCI pathophysiology and a biomarker of new cortical injury even if the electrodes are distant from the injured area [19,45,46].

The most studied blood biomarker of new brain injury is the S100B protein, a calcium binding protein mainly expressed in astrocytes. The serum concentration of S100B at hospital admission is a good biomarker of the severity of EBI and decreases before the period at risk of DCI [47,48]. Later on the level of S100B within the first 5 to 7 days after bleeding is a good marker of long-term outcome as it may include both early and late brain injuries [48–51]. However, the diagnostic accuracy of S100B changes during the hospital stay to predict DCI or new cerebral infarction has yet to be evaluated.

When DCI occurs or is suspected, cerebral and vascular imaging with perfusion data will look for a proximal vasospasm and guide therapeutic intervention that will be discussed in a following section (Fig. 2). The gold standard is digital subtraction angiography which can accurately diagnose proximal vasospasm as a narrowing of cerebral arteries [52,53]. However, it is an invasive technique not always accessible and which does not provide information about the consequences of the vasospasm on CBF. Conversely, computed tomography (CT) perfusion and angiography are noninvasive tools that can both identify vascular narrowing and CBF changes. It provides perfusion maps of CBF, cerebral blood volume, mean transit time and time to peak. The changes of CBF reach positive and negative predictive values above 90% to diagnose vasospasm confirmed with an angiography [53]. The development of cerebral magnetic resonance imaging (MRI) makes it a safe and accessible technique to detect brain lesions, and is a valuable alternative to perfusion CT. Furthermore, in addition to

vascular and perfusion weighted images, it can also diagnose cortical ischemia that are not related to proximal vasospasm [54].

Prevention strategies

Several vasodilatory agents have been tried to prevent the occurrence of vasospasm and/or DCI and improve patient outcome. The only treatment that is efficient to improve the long-term outcome and that is therefore recommended, is the calcium channel inhibitor nimodipine [3,55]. Daily oral nimodipine for 21 days improves long-term outcome; when the oral route is not available, the intravenous formulation may be used but its beneficial effect is more controversial probably because of underpowered trials [56]. Surprisingly nimodipine does not significantly reduce proximal vasospasm [57] but may act among other things by improving micro-vascularization. For instance, it experimentally partially restores neurovascular coupling during spreading depolarization [58]. Other nimodipine formulations are under investigation to increase its concentration in the cerebrospinal fluid with micro- or nanoparticles [59,60]. The NEWTON2 trial tested a single intraventricular administration of EG-1962 which delivers nimodipine microparticles in the subarachnoid space. It was prematurely halted because the primary endpoint (i.e. 6-month Glasgow outcome scale) was unlikely to be achieved but there was a significant reduction of vasospasm and a lower incidence of hypotension [60]. Conversely, the co-administration of magnesium with oral nimodipine, which is also a noncompetitive inhibitor of voltage gated calcium channel and the NMDA receptor, was not efficient [61].

In Japan, where nimodipine is not available, cilostazol, a phosphodiesterase 3 inhibitor, has been tried as a vasodilator agent following SAH. The authors evidenced that cilostazol reduced vasospasm, DCI, cerebral ischemia and improved long-term outcome [62]. It also has a similar effect on spreading depolarization induced changes [63]. The effect of cilostazol in centers using daily nimodipine needs to be evaluated. The effect of milrinone administration, another phosphodiesterase 3 inhibitor, with

nimodipine to prevent DCI is also currently under investigation in the OPTIMIL clinical trial (NCT04282629).

The endothelin-1 receptor A inhibitor, clazosentan, has been tried in several clinical trials (CONSCIOUS trials 1,2 and 3), however the results of the phase 3 randomized controlled trial were not conclusive. Only high doses of clazosentan were able to reduce DCI with frequent adverse events such as pulmonary edema and hypotension, without any effect on long-term outcome [30,64,65]. Subgroup analyses suggested that clazosentan may be more effective on the morbidity related to DCI in patients with limited EBI [64]. The effect of clazosentan in patients with limited EBI and a high risk of DCI defined as the presence of a thick and diffuse clot in the subarachnoid space, is under investigation in the REACT trial (NCT03585270).

Statins inhibit 3-hydroxy-3-methylglutaryl coenzyme A reductase and block the formation of mevalonate, an important precursor for both cholesterol and other nonsterol products. This might underpin some of the known neuroprotective properties of statins such as the upregulation of endothelial nitric oxide synthetase, the inhibition of platelet activation and the reduction of neuro-inflammation [66]. A recent meta-analysis of small sample size randomized controlled trials suggest that statin treatment reduces the occurrence of vasospasm and DCI [67]. Unfortunately, there was no effect on long-term prognosis, even in the large STAHL trial [67,68]. The Rho-kinase pathway is also implicated in many mechanisms which play a role in DCI progression such as vasoconstriction, endothelial injury, platelet activation, inflammation, and oxidative stress. The Rho-kinase inhibitor fasudil was tested against nimodipine in an unblinded trial and seemed to be more efficient than nimodipine to reduce symptomatic vasospasm and to improve the outcome [69]. However, all patients had a surgical clipping unlike in other countries where coiling is usually preferred, and both treatments were administered intravenously although this formulation of nimodipine may not be as efficient as the oral one [56].

The clearance of blood clots from the cerebrospinal fluid compartment is also critical in the development of DCI. A high cisternal clot clearance seems associated with a low probability of DCI [70]. Therefore, another approach to reduce the amount of blood and its degradation derivatives consists of clot removal from the subarachnoid space using cisternal or ventricular catheters with fibrinolytic agents. Results of small studies are promising with a reduced risk of symptomatic vasospasms or DCI [71,72], and randomized studies such as the EARLYDRAIN trial (NCT01258257) [73] or the FIVHeMA trial (NCT03187405) [74] are currently investigating the impact of this strategy on clinical outcome and DCI.

Therapeutic approach when delayed cerebral ischemia occurs

There is no randomized trial to support a clear strategy when DCI occurs. The current evolution of DCI management developed in many centers is based on tiered approach with frequent re-evaluations of clinical and/or multimodal monitoring data to escalate or de-escalate therapeutic interventions [9,55] (Fig. 2). The previous approach consisted of the so-called triple H therapy (hypertension, hypervolemia, hemodilution), with a risk of heart failure or cerebral edema [75–77]. Nowadays, the first tier when DCI occurs is a stepwise increase in arterial blood pressure also called induced, permissive or controlled hypertension [3,55]. The increase of systemic blood pressure with norepinephrine and correction of potent hypovolemia improves the perfusion deficit associated with DCI [78], and may improve clinical deterioration [46,75,79–82]. The randomized HIMALAIA study that intended to evaluate the effect of permissive hypertension on long-term outcome, was terminated due to low recruitment and did not evidence any difference in terms of outcome [46]. Goal-directed therapy with the use of fluid responsiveness indices is useful to avoid fluid overload, correct hypovolemia, and prevent DCI [83,84]. In unconscious patients with intracranial monitoring, the optimization of CBF relies on arterial and intracranial pressure changes and PbtO₂ levels {Schmidt, Rass.2019r9g}.

If DCI is due to a symptomatic vasospasm (i.e. vasospasm with downstream perfusion deficit identified on a perfusion CT or MRI) and refractory to permissive hypertension, an endovascular intervention should be considered [3,55]. Endovascular treatment efficacy has been studied only in observational or retrospective trials. Intra-arterial calcium channel antagonists (nimodipine, nicardipine or verapamil) or milrinone can be used to reverse the vasospasm but their effect might be short lasting [85,86]. To overcome this, transluminal balloon angioplasty can also be performed with a low rate of vasospasm recurrence and rare complication such as vascular rupture or occlusion [87]. New technical developments may reduce the risk of such procedure using a dual lumen balloon [88] or a solitary stent retriever [89]. Intravenous administration milrinone could also be used as a rescue therapy when the symptomatic vasospasm is not accessible to an endovascular procedure or combined with an endovascular treatment, with promising results to reverse angiographic vasospasm [86,90]. The MIVAR randomized, double blinded, placebo-controlled trial is currently investigating the effect of intravenous milrinone administration on long-term outcome when symptomatic vasospasm occurs (NCT04362527).

When proximal vasospasm is not the primary mechanism of DCI, other therapeutic interventions should be considered. For instance, if repeated SDs occur despite optimal cerebral perfusion and oxygenation, some authors suggest using ketamine in addition to ongoing sedation. If SDs are still observed, a stepwise ketamine increase could be performed with a close monitoring of side effects such as hepatotoxicity [91–93]. However, the effect of such strategy remains to be evaluated [11]. A more liberal hemoglobin threshold for red blood cell transfusion in order to increase cerebral oxygen delivery is also suggested and currently under investigation in the TRAIN trial (NCT02968654).

Conclusion:

Our understanding of the pathophysiology of new cerebral injuries after an SAH has evolved from the initial discovery of arterial vasospasm to a more complex phenomenon that encompasses

microcirculatory changes (i.e. proximal and distal arterial narrowing), microcirculation disturbance (i.e. impaired autoregulation, inverse vascular coupling and spreading ischemia), platelet activation and aggregation and neuro-inflammation. Therefore, the therapeutic targets and management strategies are also evolving and are not only focused on proximal vasospasm. Future strategies for DCI management may depend on the predominant mechanism in place and need to be evaluated in randomized clinical trials.

References:

- [1] Rooij NK de, Linn FHH, Plas JA van der, Algra A, Rinkel GJE. Incidence of subarachnoid haemorrhage: a systematic review with emphasis on region, age, gender and time trends. *J Neurology Neurosurg Psychiatry* 2007;78:1365. <https://doi.org/10.1136/jnnp.2007.117655>.
- [2] Ingall T, Asplund K, Mähönen M, Bonita R. A Multinational Comparison of Subarachnoid Hemorrhage Epidemiology in the WHO MONICA Stroke Study. *Stroke* 2000;31:1054–61. <https://doi.org/10.1161/01.str.31.5.1054>.
- [3] Connolly SE, Rabinstein AA, Carhuapoma RJ, Derdeyn CP, Dion J, Higashida RT, et al. Guidelines for the Management of Aneurysmal Subarachnoid Hemorrhage A Guideline for Healthcare Professionals From the American Heart Association/American Stroke Association. *Stroke* 2012;43:1711–37. <https://doi.org/10.1161/str.0b013e3182587839>.
- [4] Claassen J, Vu A, Kreiter KT, Kowalski RG, Du EY, Ostapkovich N, et al. Effect of acute physiologic derangements on outcome after subarachnoid hemorrhage. *Critical Care Medicine* 2004;32:832–8. <https://doi.org/10.1097/01.ccm.0000114830.48833.8a>.

- [5] Kreiter KT, Copeland D, Bernardini GL, Bates JE, Peery S, Claassen J, et al. Predictors of cognitive dysfunction after subarachnoid hemorrhage. *Stroke* 2002;33:200–8. <https://doi.org/10.1161/hs0102.101080>.
- [6] Broderick J, Brott T, Duldner J, Tomsick T, Leach A. Initial and recurrent bleeding are the major causes of death following subarachnoid hemorrhage. *Stroke* 1994;25:1342–7. <https://doi.org/10.1161/01.str.25.7.1342>.
- [7] Macdonald RL. Delayed neurological deterioration after subarachnoid haemorrhage. *Nat Rev Neurol* 2014;10:44–58. <https://doi.org/10.1038/nrneurol.2013.246>.
- [8] Francoeur CL, Mayer SA. Management of delayed cerebral ischemia after subarachnoid hemorrhage. *Critical Care* 2016;20:277. <https://doi.org/10.1186/s13054-016-1447-6>.
- [9] Rass V, Helbok R. How to diagnose delayed cerebral ischaemia and symptomatic vasospasm and prevent cerebral infarction in patients with subarachnoid haemorrhage. *Curr Opin Crit Care* 2021;27:103–14. <https://doi.org/10.1097/mcc.0000000000000798>.
- [10] Pickard J, Murray G, Illingworth R, Shaw M. Effect of oral nimodipine on cerebral infarction and outcome after subarachnoid haemorrhage: British aneurysm nimodipine trial. 1989;298. <https://doi.org/10.1136/bmj.298.6674.636>.
- [11] Helbok R, Hartings JA, Schiefecker A, Balança B, Jewel S, Foreman B, et al. What Should a Clinician Do When Spreading Depolarizations are Observed in a Patient? *Neurocrit Care* 2020;32:306–10. <https://doi.org/10.1007/s12028-019-00777-6>.
- [12] Vergouwen MDI, Vermeulen M, Gijn J van, Rinkel GJE, Wijdicks EF, Muizelaar JP, et al. Definition of Delayed Cerebral Ischemia After Aneurysmal Subarachnoid Hemorrhage as an Outcome Event in Clinical Trials and Observational Studies. *Stroke* 2010;41:2391–5. <https://doi.org/10.1161/strokeaha.110.589275>.

- [13] Findlay JM, Nisar J, Darsaut T. Cerebral Vasospasm: A Review. *Can J Neurological Sci J Can Des Sci Neurologiques* 2016;43:15–32. <https://doi.org/10.1017/cjn.2015.288>.
- [14] Flynn L, Andrews P. Advances in the understanding of delayed cerebral ischaemia after aneurysmal subarachnoid haemorrhage. *F1000research* 2015;4:F1000 Faculty Rev-1200. <https://doi.org/10.12688/f1000research.6635.1>.
- [15] Foreman B. The Pathophysiology of Delayed Cerebral Ischemia. *J Clin Neurophysiol* 2016;33:174–82. <https://doi.org/10.1097/wnp.0000000000000273>.
- [16] Geraghty JR, Testai FD. Delayed Cerebral Ischemia after Subarachnoid Hemorrhage: Beyond Vasospasm and Towards a Multifactorial Pathophysiology. *Curr Atheroscler Rep* 2017;19:50. <https://doi.org/10.1007/s11883-017-0690-x>.
- [17] Hartings JA, York J, Carroll CP, Hinzman JM, Mahoney E, Krueger B, et al. Subarachnoid blood acutely induces spreading depolarizations and early cortical infarction. *Brain* 2017;140:2673–90. <https://doi.org/10.1093/brain/awx214>.
- [18] Balança B, Meiller A, Bezin L, Dreier JP, Marinesco S, Lieutaud T. Altered hypermetabolic response to cortical spreading depolarizations after traumatic brain injury in rats. *J Cereb Blood Flow Metabolism* 2016;37:1670–86. <https://doi.org/10.1177/0271678x16657571>.
- [19] Dreier JP, Woitzik J, Fabricius M, Bhatia R, Major S, Drenckhahn C, et al. Delayed ischaemic neurological deficits after subarachnoid haemorrhage are associated with clusters of spreading depolarizations. *Brain* 2006;129:3224–37. <https://doi.org/10.1093/brain/awl297>.
- [20] Weidauer S, Lanfermann H, Raabe A, Zanella F, Seifert V, Beck J. Impairment of Cerebral Perfusion and Infarct Patterns Attributable to Vasospasm After Aneurysmal Subarachnoid Hemorrhage. *Stroke* 2007;38:1831–6. <https://doi.org/10.1161/strokeaha.106.477976>.

- [21] Balança B, Desmurs L, Grelier J, Perret-Liaudet A, Lukaszewicz A-C. DAMPs and RAGE Pathophysiology at the Acute Phase of Brain Injury: An Overview. *Int J Mol Sci* 2021;22:2439. <https://doi.org/10.3390/ijms22052439>.
- [22] Zhang Z, Fang Y, Lenahan C, Chen S. The role of immune inflammation in aneurysmal subarachnoid hemorrhage. *Exp Neurol* 2021;336:113535. <https://doi.org/10.1016/j.expneurol.2020.113535>.
- [23] Sachinidis A, Flesch M, Ko Y, Schrör K, Böhm M, Düsing R, et al. Thromboxane A2 and vascular smooth muscle cell proliferation. *Hypertension (Dallas, Tex : 1979)* 1995;26:771–80. <https://doi.org/10.1161/01.hyp.26.5.771>.
- [24] Ohkuma H, Ogane K, Fujita S, Manabe H, Suzuki S. Impairment of anti-platelet-aggregating activity of endothelial cells after experimental subarachnoid hemorrhage. *Stroke* 2018;24:1541–5. <https://doi.org/10.1161/01.str.24.10.1541>.
- [25] Lagier D, Tonon D, Garrigue P, Guillet B, Giacomino L, Martin J-C, et al. Thromboxane–prostaglandin receptor antagonist, terutroban, prevents neurovascular events after subarachnoid haemorrhage: a nanoSPECT study in rats. *Critical Care* 2019;23:42. <https://doi.org/10.1186/s13054-019-2338-4>.
- [26] Budohoski KP, Guilfoyle M, Helmy A, Huuskonen T, Czosnyka M, Kirollos R, et al. The pathophysiology and treatment of delayed cerebral ischaemia following subarachnoid haemorrhage. *J Neurology Neurosurg Psychiatry* 2014;85:1343. <https://doi.org/10.1136/jnnp-2014-307711>.
- [27] Rass V, Helbok R. Early Brain Injury After Poor-Grade Subarachnoid Hemorrhage. *Curr Neurol Neurosci* 2019;19:78. <https://doi.org/10.1007/s11910-019-0990-3>.
- [28] Raza SA, Frankel MR, Rangaraju S. Abbreviation of the Follow-Up NIH Stroke Scale Using Factor Analysis. *Cerebrovasc Dis Extra* 2017;7:120–9. <https://doi.org/10.1159/000479933>.

[29] Bae I-S, Chun H-J, Choi K-S, Yi H-J. Modified Glasgow coma scale for predicting outcome after subarachnoid hemorrhage surgery. *Medicine* 2021;100:e25815. <https://doi.org/10.1097/md.00000000000025815>.

[30] Macdonald RL, Higashida RT, Keller E, Mayer SA, Molyneux A, Raabe A, et al. Clazosentan, an endothelin receptor antagonist, in patients with aneurysmal subarachnoid haemorrhage undergoing surgical clipping: a randomised, double-blind, placebo-controlled phase 3 trial (CONSCIOUS-2). *Lancet Neurology* 2011;10:618–25. [https://doi.org/10.1016/s1474-4422\(11\)70108-9](https://doi.org/10.1016/s1474-4422(11)70108-9).

[31] Helbok R, Kurtz P, Schmidt MJ, Stuart MR, Fernandez L, Connolly SE, et al. Effects of the neurological wake-up test on clinical examination, intracranial pressure, brain metabolism and brain tissue oxygenation in severely brain-injured patients. *Crit Care* 2012;16:R226–R226. <https://doi.org/10.1186/cc11880>.

[32] Klinzing S, Steiger P, Schüpbach RA, Bèchir M, Brandi G. Competence for transcranial color-coded Duplex sonography is rapidly acquired. *Minerva Anestesiol* 2014;81:298–304.

[33] Robba C, Goffi A, Geeraerts T, Cardim D, Via G, Czosnyka M, et al. Brain ultrasonography: methodology, basic and advanced principles and clinical applications. A narrative review. *Intensive Care Medicine* 2019;1–15. <https://doi.org/10.1007/s00134-019-05610-4>.

[34] Lysakowski C, Walder B, Costanza MC, Tramèr MR. Transcranial Doppler Versus Angiography in Patients With Vasospasm due to a Ruptured Cerebral Aneurysm. *Stroke* 2001;32:2292–8. <https://doi.org/10.1161/hs1001.097108>.

[35] Lindegaard K-F, Nornes H, Bakke SJ, Sorteberg W, Nakstad P. Cerebral vasospasm diagnosis by means of angiography and blood velocity measurements. *Acta Neurochir* 1989;100:12–24. <https://doi.org/10.1007/bf01405268>.

[36] Kunze E, Pham M, Raslan F, Stetter C, Lee J-Y, Solymosi L, et al. Value of Perfusion CT, Transcranial Doppler Sonography, and Neurological Examination to Detect Delayed Vasospasm after

Aneurysmal Subarachnoid Hemorrhage. *Radiology Res Pract* 2012;2012:231206.
<https://doi.org/10.1155/2012/231206>.

[37] Kumar G, Shahripour RB, Harrigan MR. Vasospasm on transcranial Doppler is predictive of delayed cerebral ischemia in aneurysmal subarachnoid hemorrhage: a systematic review and meta-analysis. *J Neurosurg* 2016;124:1257–64. <https://doi.org/10.3171/2015.4.jns15428>.

[38] Chen HI, Stiefel MF, Oddo M, Milby AH, Maloney-Wilensky E, Frangos S, et al. Detection of Cerebral Compromise With Multimodality Monitoring in Patients With Subarachnoid Hemorrhage. *Neurosurgery* 2011;69:53–63. <https://doi.org/10.1227/neu.0b013e3182191451>.

[39] Torné R, Culebras D, Sanchez-Etayo G, García-García S, Muñoz G, Llull L, et al. Double hemispheric Microdialysis study in poor-grade SAH patients. *Sci Rep-Uk* 2020;10:7466. <https://doi.org/10.1038/s41598-020-64543-x>.

[40] Tholance Y, Barcelos GK, Perret-Liaudet A, Omar E, Carrillon R, Grousseau S, et al. Placing intracerebral probes to optimise detection of delayed cerebral ischemia and allow for the prediction of patient outcome in aneurysmal subarachnoid haemorrhage. *Journal of Cerebral Blood Flow & Metabolism* 2017;37. <https://doi.org/10.1177/0271678x16675880>.

[41] Symon L, Branston N, Strong A, Hope T. The concepts of thresholds of ischaemia in relation to brain structure and function. *Journal of Clinical Pathology Supplement (Royal College of Pathologists)* 1977;11:149–54. <https://doi.org/10.1136/jcp.s3-11.1.149>.

[42] Sundt TJ, Sharbrough F, Piepgras D. Correlation of cerebral blood flow and electroencephalographic changes during carotid endarterectomy: with results of surgery and hemodynamics of cerebral ischemia. 1982;56.

[43] Guo Y, Fang S, Wang J, Wang C, Zhao J, Gai Y. Continuous EEG detection of DCI and seizures following aSAH: a systematic review. *Brit J Neurosurg* 2019;34:1–6. <https://doi.org/10.1080/02688697.2019.1630547>.

- [44] Balança B, Dailier F, Boulogne S, Ritzenthaler T, Gobert F, Rheims S, et al. Diagnostic accuracy of quantitative EEG to detect delayed cerebral ischemia after subarachnoid hemorrhage: A preliminary study. *Clin Neurophysiol* 2018;129:1926–36. <https://doi.org/10.1016/j.clinph.2018.06.013>.
- [45] Engquist H, Lewén A, Hillered L, Ronne-Engström E, Nilsson P, Enblad P, et al. CBF changes and cerebral energy metabolism during hypervolemia, hemodilution, and hypertension therapy in patients with poor-grade subarachnoid hemorrhage. *J Neurosurg* 2021;134:555–64. <https://doi.org/10.3171/2019.11.jns192759>.
- [46] Gathier CS, Bergh WM van den, Jagt M van der, Verweij BH, Dankbaar JW, Müller MC, et al. Induced Hypertension for Delayed Cerebral Ischemia After Aneurysmal Subarachnoid Hemorrhage. *Stroke* 2018;49:76–83. <https://doi.org/10.1161/strokeaha.117.017956>.
- [47] Balança B, Ritzenthaler T, Gobert F, Richet C, Bodonian C, Carrillon R, et al. Significance and Diagnostic Accuracy of Early S100B Serum Concentration after Aneurysmal Subarachnoid Hemorrhage. *J Clin Medicine* 2020;9:1746. <https://doi.org/10.3390/jcm9061746>.
- [48] Quintard H, Leduc S, Ferrari P, Petit I, Ichai C. Early and persistent high level of PS 100β is associated with increased poor neurological outcome in patients with SAH: is there a PS 100β threshold for SAH prognosis? *Critical Care* 2016;20:33. <https://doi.org/10.1186/s13054-016-1200-1>.
- [49] Kellermann I, Kleindienst A, Hore N, Buchfelder M, Brandner S. Early CSF and Serum S100B Concentrations for Outcome Prediction in Traumatic Brain Injury and Subarachnoid Hemorrhage. *Clinical Neurology and Neurosurgery* 2016;145:79–83. <https://doi.org/10.1016/j.clineuro.2016.04.005>.
- [50] Weiss N, Sanchez-Peña P, Roche S, Beaudeau JL, Colonne C, Coriat P, et al. Prognosis value of plasma S100B protein levels after subarachnoid aneurysmal hemorrhage. *Anesthesiology* 2006;104:658–66. <https://doi.org/10.1097/00000542-200604000-00008>.

- [51] Sanchez-Peña P, Pereira A-R, Sourour N-A, Biondi A, Lejean L, Colonne C, et al. S100B as an additional prognostic marker in subarachnoid aneurysmal hemorrhage. *Critical Care Medicine* 2008;36:2267–73. <https://doi.org/10.1097/CCM.0b013e3181809750>.
- [52] Wintermark M, Ko NU, Smith WS, Liu S, Higashida RT, Dillon WP. Vasospasm after subarachnoid hemorrhage: utility of perfusion CT and CT angiography on diagnosis and management. *Ajnr Am J Neuroradiol* 2006;27:26–34.
- [53] SUN H, ZHANG H, MA J, LIU Y, YOU C. Evaluating the Diagnostic Accuracy of Ct Perfusion in Patients with Cerebral Vasospasm After Aneurysm Rupture: A Meta-Analysis. *Turk Neurosurg* 2014;24:757–62. <https://doi.org/10.5137/1019-5149.jtn.9914-13.1>.
- [54] Nelson SE, Sair HI, Stevens RD. Magnetic Resonance Imaging in Aneurysmal Subarachnoid Hemorrhage: Current Evidence and Future Directions. *Neurocrit Care* 2018;29:241–52. <https://doi.org/10.1007/s12028-018-0534-8>.
- [55] Steiner T, Juvela S, Unterberg A, Jung C, Forsting M, Rinkel G, et al. European Stroke Organization Guidelines for the Management of Intracranial Aneurysms and Subarachnoid Haemorrhage. *Cerebrovascular Diseases* 2013;35:93–112. <https://doi.org/10.1159/000346087>.
- [56] Mees SD, Rinkel GJ, Feigin VL, Algra A, Bergh WM van den, Vermeulen M, et al. Calcium antagonists for aneurysmal subarachnoid haemorrhage. *Cochrane Db Syst Rev* 2007:CD000277. <https://doi.org/10.1002/14651858.cd000277.pub3>.
- [57] Feigin VL, Rinkel GJE, Algra A, Vermeulen M, Gijn J van. Calcium antagonists in patients with aneurysmal subarachnoid hemorrhage. *Neurology* 1998;50:876–83. <https://doi.org/10.1212/wnl.50.4.876>.
- [58] Menyhárt Á, Farkas AE, Varga DP, Frank R, Tóth R, Bálint AR, et al. Large-conductance Ca²⁺-activated potassium channels are potentially involved in the inverse neurovascular response to spreading depolarization. *Neurobiol Dis* 2018;119:41–52. <https://doi.org/10.1016/j.nbd.2018.07.026>.

- [59] Tóth OM, Menyhárt Á, Varga VÉ, Hantosi D, Ivánkovits-Kiss O, Varga DP, et al. Chitosan nanoparticles release nimodipine in response to tissue acidosis to attenuate spreading depolarization evoked during forebrain ischemia. *Neuropharmacology* 2019;107850. <https://doi.org/10.1016/j.neuropharm.2019.107850>.
- [60] Carlson AP, Hänggi D, Wong GK, Etminan N, Mayer SA, Aldrich F, et al. Single-Dose Intraventricular Nimodipine Microparticles Versus Oral Nimodipine for Aneurysmal Subarachnoid Hemorrhage. *Stroke* 2020;51:1142–9. <https://doi.org/10.1161/strokeaha.119.027396>.
- [61] Mees SMD, Algra A, Vandertop WP, Kooten F van, Kuijsten HA, Boiten J, et al. Magnesium for aneurysmal subarachnoid haemorrhage (MASH-2): a randomised placebo-controlled trial. *Lancet* 2012;380:44–9. [https://doi.org/10.1016/s0140-6736\(12\)60724-7](https://doi.org/10.1016/s0140-6736(12)60724-7).
- [62] Shan T, Zhang T, Qian W, Ma L, Li H, You C, et al. Effectiveness and feasibility of cilostazol in patients with aneurysmal subarachnoid hemorrhage: a systematic review and meta-analysis. *J Neurol* 2020;267:1577–84. <https://doi.org/10.1007/s00415-019-09198-z>.
- [63] Sugimoto K, Nomura S, Shirao S, Inoue T, Ishihara H, Kawano R, et al. Cilostazol decreases duration of spreading depolarization and spreading ischemia after aneurysmal subarachnoid hemorrhage. *Ann Neurol* 2018;84:873–85. <https://doi.org/10.1002/ana.25361>.
- [64] Macdonald RL, Higashida RT, Keller E, Mayer SA, Molyneux A, Raabe A, et al. Randomized Trial of Clazosentan in Patients With Aneurysmal Subarachnoid Hemorrhage Undergoing Endovascular Coiling. *Stroke* 2012;43:1463–9. <https://doi.org/10.1161/strokeaha.111.648980>.
- [65] Macdonald R, Kassell NF, Mayer S, Ruefenacht D, Schmiedek P, Weidauer S, et al. Clazosentan to overcome neurological ischemia and infarction occurring after subarachnoid hemorrhage (CONSCIOUS-1): randomized, double-blind, placebo-controlled phase 2 dose-finding trial. *Stroke* 2008;39:3015–21. <https://doi.org/10.1161/strokeaha.108.519942>.

[66] Vaughan CJ, Delanty N. Neuroprotective Properties of Statins in Cerebral Ischemia and Stroke. *Stroke* 1999;30:1969–73. <https://doi.org/10.1161/01.str.30.9.1969>.

[67] Shen J, Shen J, Zhu K, Zhou H, Tian H, Yu G. Efficacy of Statins in Cerebral Vasospasm, Mortality, and Delayed Cerebral Ischemia in Patients with Aneurysmal Subarachnoid Hemorrhage: A Systematic Review and Meta-Analysis of Randomized Controlled Trials. *World Neurosurg* 2019;131:e65–73. <https://doi.org/10.1016/j.wneu.2019.07.016>.

[68] Kirkpatrick PJ, Turner CL, Smith C, Hutchinson PJ, Murray GD, Collaborators S for the. Simvastatin in aneurysmal subarachnoid haemorrhage (STASH): a multicentre randomised phase 3 trial. *The Lancet Neurology* 2014;13:666–75. [https://doi.org/10.1016/s1474-4422\(14\)70084-5](https://doi.org/10.1016/s1474-4422(14)70084-5).

[69] ZHAO J, ZHOU D, GUO J, REN Z, ZHOU L, WANG S, et al. Efficacy and Safety of Fasudil in Patients With Subarachnoid Hemorrhage: Final Results of a Randomized Trial of Fasudil Versus Nimodipine. *Neurologia Medico-Chirurgica* 2011;51:679–83. <https://doi.org/10.2176/nmc.51.679>.

[70] Ritzenthaler T, Gobert F, Bouchier B, Dailier F. Amount of blood during the subacute phase and clot clearance rate as prognostic factors for delayed cerebral ischemia after aneurysmal subarachnoid hemorrhage. *J Clin Neurosci* 2021;87:74–9. <https://doi.org/10.1016/j.jocn.2021.02.007>.

[71] Sasaki T, Kodama N, Kawakami M, Sato M, Asari J, Sakurai Y, et al. Urokinase Cisternal Irrigation Therapy for Prevention of Symptomatic Vasospasm After Aneurysmal Subarachnoid Hemorrhage. *Stroke* 2000;31:1256–62. <https://doi.org/10.1161/01.str.31.6.1256>.

[72] KINOCHI H, OGASAWARA K, SHIMIZU H, MIZOI K, YOSHIMOTO T. Prevention of Symptomatic Vasospasm After Aneurysmal Subarachnoid Hemorrhage by Intraoperative Cisternal Fibrinolysis Using Tissue-Type Plasminogen Activator Combined With Continuous Cisternal Drainage. *Neurol Med-Chir* 2004;44:569–77. <https://doi.org/10.2176/nmc.44.569>.

- [73] Bardutzky J, Witsch J, Jüttler E, Schwab S, Vajkoczy P, Wolf S. EARLYDRAIN- outcome after early lumbar CSF-drainage in aneurysmal subarachnoid hemorrhage: study protocol for a randomized controlled trial. *Trials* 2011;12:203–203. <https://doi.org/10.1186/1745-6215-12-203>.
- [74] Gaberel T, Gakuba C, Fournel F, Blanc EL, Gaillard C, Paul LPS, et al. FIVHeMA: Intraventricular fibrinolysis versus external ventricular drainage alone in aneurysmal subarachnoid hemorrhage: A randomized controlled trial. *Neurochirurgie* 2019;65:14–9. <https://doi.org/10.1016/j.neuchi.2018.11.004>.
- [75] Kosnik EJ, Hunt WE. Postoperative hypertension in the management of patients with intracranial arterial aneurysms. *J Neurosurg* 1976;45:148–54. <https://doi.org/10.3171/jns.1976.45.2.0148>.
- [76] Sepideh A-H, Schwartz RB, Sathi S, Stieg PE. Hypertensive Encephalopathy as a Complication of Hyperdynamic Therapy for Vasospasm: Report of Two Cases. *Neurosurgery* 1999;44:1113–6. <https://doi.org/10.1097/00006123-199905000-00097>.
- [77] Wartenberg KE, Parra A. CT and CT-Perfusion Findings of Reversible Leukoencephalopathy During Triple-H Therapy for Symptomatic Subarachnoid Hemorrhage-Related Vasospasm. *J Neuroimaging* 2006;16:170–5. <https://doi.org/10.1111/j.1552-6569.2006.00031.x>.
- [78] Murphy A, Manoel A de, Macdonald LR, Baker A, Lee T-Y, Marotta T, et al. Changes in Cerebral Perfusion with Induced Hypertension in Aneurysmal Subarachnoid Hemorrhage: A Pilot and Feasibility Study. *Neurocritical Care* 2017. <https://doi.org/10.1007/s12028-017-0379-6>.
- [79] TOUHO H, KARASAWA J, OHNISHI H, SHISHIDO H, YAMADA K, SHIBAMOTO K. Evaluation of Therapeutically Induced Hypertension in Patients with Delayed Cerebral Vasospasm by Xenon-enhanced Computed Tomography. *Neurol Med-Chir* 1992;32:671–8. <https://doi.org/10.2176/nmc.32.671>.

[80] Otsubo H, Takemae T, Inoue T, Kobayashi Sh, Sugita K. Normovolaemic induced hypertension therapy for cerebral vasospasm after subarachnoid haemorrhage. *Acta Neurochir* 1990;103:18–26. <https://doi.org/10.1007/bf01420187>.

[81] Muizelaar JP, Becker DP. Induced hypertension for the treatment of cerebral ischemia after subarachnoid hemorrhage. Direct effect on cerebral blood flow. *Surg Neurol* 1986;25:317–25. [https://doi.org/10.1016/0090-3019\(86\)90205-3](https://doi.org/10.1016/0090-3019(86)90205-3).

[82] Kassell NF, Peerless SJ, Durward QJ, Beck DW, Drake CG, Adams HP. Treatment of Ischemic Deficits from Vasospasm with Intravascular Volume Expansion and Induced Arterial Hypertension. *Neurosurgery* 1982;11:337–43. <https://doi.org/10.1227/00006123-198209000-00001>.

[83] Tagami T, Kuwamoto K, Watanabe A, Unemoto K, Yokobori S, Matsumoto G, et al. Optimal Range of Global End-Diastolic Volume for Fluid Management After Aneurysmal Subarachnoid Hemorrhage. *Crit Care Med* 2014;42:1348–56. <https://doi.org/10.1097/ccm.000000000000163>.

[84] Anetsberger A, Gempt J, Blobner M, Ringel F, Bogdanski R, Heim M, et al. Impact of Goal-Directed Therapy on Delayed Ischemia After Aneurysmal Subarachnoid Hemorrhage: Randomized Controlled Trial. *Stroke* 2020;51:2287–96. <https://doi.org/10.1161/strokeaha.120.029279>.

[85] Jabbarli R, Pierscianek D, Rölz R, Oppong MD, Kaier K, Shah M, et al. Endovascular treatment of cerebral vasospasm after subarachnoid hemorrhage: More is more. *Neurology* 2019;93:e458–66. <https://doi.org/10.1212/wnl.0000000000007862>.

[86] Crespy T, Heintzelmann M, Chiron C, Vinclair M, Tahon F, Francony G, et al. Which Protocol for Milrinone to Treat Cerebral Vasospasm Associated With Subarachnoid Hemorrhage? *Journal of Neurosurgical Anesthesiology* 2018. <https://doi.org/10.1097/ana.0000000000000527>.

[87] Schacht H, Kuchler J, Boppel T, Leppert J, Ditz C, Schramm P, et al. Transluminal balloon angioplasty for cerebral vasospasm after spontaneous subarachnoid hemorrhage: A single-center experience. *Clin Neurol Neurosur* 2020;188:105590. <https://doi.org/10.1016/j.clineuro.2019.105590>.

- [88] Tsogkas I, Malinova V, Schregel K, Mielke D, Behme D, Rohde V, et al. Angioplasty with the sceptor C dual lumen balloon catheter and postprocedural result evaluation in patients with subarachnoid hemorrhage related vasospasms. *Bmc Neurol* 2020;20:260. <https://doi.org/10.1186/s12883-020-01792-3>.
- [89] Su YS, Ali MS, Pukenas BA, Favilla CG, Zanaty M, Hasan DM, et al. Novel Treatment of Cerebral Vasospasm Using Solitaire Stent Retriever-Assisted Angioplasty: Case Series. *World Neurosurg* 2020;135:e657–63. <https://doi.org/10.1016/j.wneu.2019.12.097>.
- [90] Fraticelli A, Cholley BP, Losser M-R, Maurice J-P, Payen D. Milrinone for the Treatment of Cerebral Vasospasm After Aneurysmal Subarachnoid Hemorrhage. *Stroke* 2008;39:893–8. <https://doi.org/10.1161/strokeaha.107.492447>.
- [91] Carlson AP, Abbas M, Alunday RL, Qeadan F, Shuttleworth WC. Spreading depolarization in acute brain injury inhibited by ketamine: a prospective, randomized, multiple crossover trial. *J Neurosurg* 2019;130:1513–9. <https://doi.org/10.3171/2017.12.jns171665>.
- [92] Hertle DN, Dreier JP, Woitzik J, Hartings JA, Bullock R, Okonkwo DO, et al. Effect of analgesics and sedatives on the occurrence of spreading depolarizations accompanying acute brain injury. *Brain* 2012;135:2390–8. <https://doi.org/10.1093/brain/aws152>.
- [93] Sanchez-Porrás R, Santos E, Scho II M, Kunzmann K, Stock C, Silos H, et al. Ketamine modulation of the haemodynamic response to spreading depolarization in the gyrencephalic swine brain. *Journal of Cerebral Blood Flow & Metabolism* 2016. <https://doi.org/10.1177/0271678x16646586>.

Figures:

Figure 1. Pathophysiology of delayed cerebral ischemia.

SAH: subarachnoid hemorrhage, IVH: intraventricular hemorrhage, ICH: intracerebral hemorrhage, IC: intracranial pressure, CBF: cerebral blood flow, BBB: blood brain barrier, NO: nitric oxyd, ET-1: endothelin-1

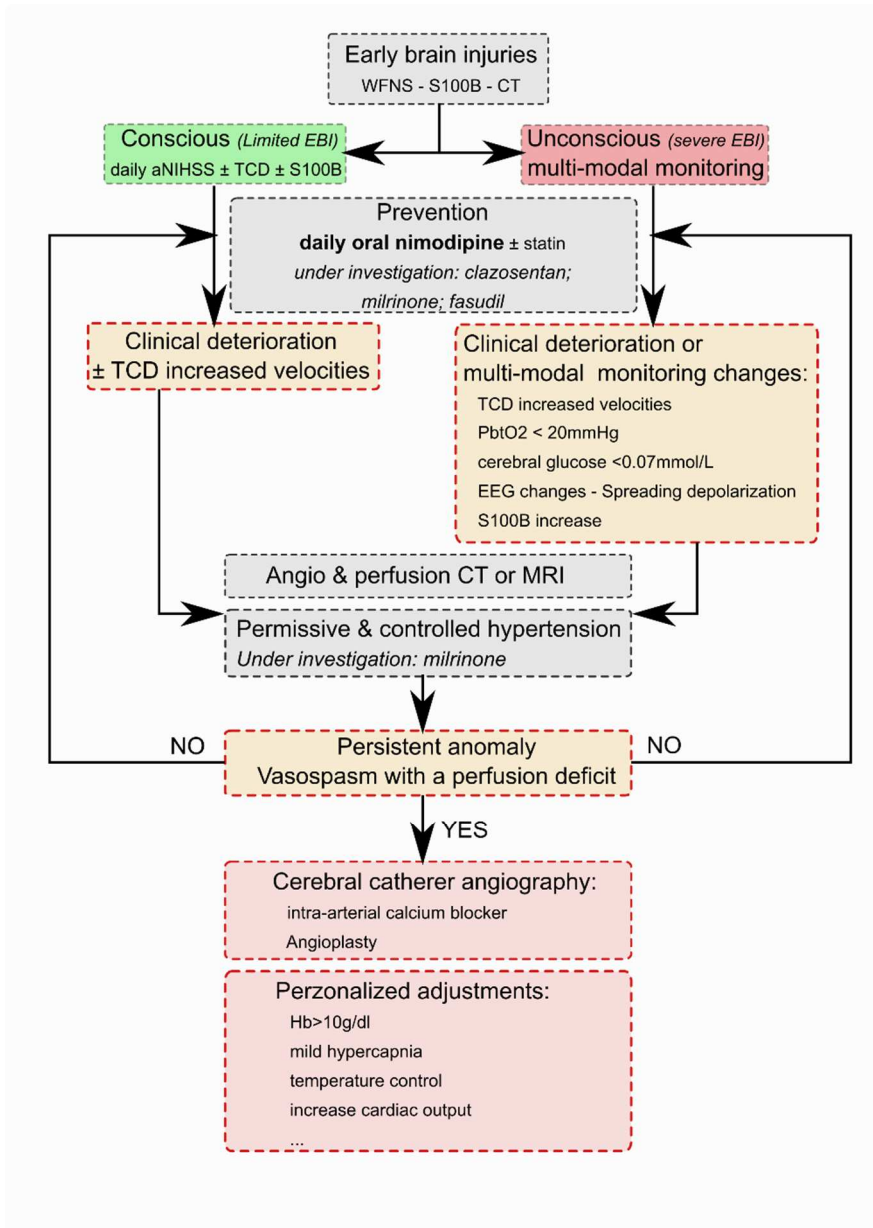


Figure 2. Delayed cerebral ischemia management algorithm after subarachnoid hemorrhage.

CT: computed tomography; MRI: magnetic resonance imaging; TCD: transcranial doppler; WFNS: world federation of neurosurgeon scale.