



HAL
open science

Intraoperative cerebral blood flow monitoring in neurosurgery: A review of contemporary technologies and emerging perspectives

N. Tahhan, B. Balanca, J. Fierstra, T. Waelchli, T. Picart, C. Dumot, O. Eker, S. Marinesco, I. Radovanovic, F. Cotton, et al.

► To cite this version:

N. Tahhan, B. Balanca, J. Fierstra, T. Waelchli, T. Picart, et al.. Intraoperative cerebral blood flow monitoring in neurosurgery: A review of contemporary technologies and emerging perspectives. *Neurochirurgie*, 2022, 68 (4), pp.414-425. 10.1016/j.neuchi.2021.10.005 . hal-04789910

HAL Id: hal-04789910

<https://hal.science/hal-04789910v1>

Submitted on 29 Nov 2024

HAL is a multi-disciplinary open access archive for the deposit and dissemination of scientific research documents, whether they are published or not. The documents may come from teaching and research institutions in France or abroad, or from public or private research centers.

L'archive ouverte pluridisciplinaire **HAL**, est destinée au dépôt et à la diffusion de documents scientifiques de niveau recherche, publiés ou non, émanant des établissements d'enseignement et de recherche français ou étrangers, des laboratoires publics ou privés.



Distributed under a Creative Commons Attribution - NonCommercial 4.0 International License

INTRAOPERATIVE CEREBRAL BLOOD FLOW MONITORING IN NEUROSURGERY: A REVIEW OF CONTEMPORARY TECHNOLOGIES AND EMERGING PERSPECTIVES

Nadim TAHHAN¹, Baptiste BALANCA^{2,3}, Jorn FIERSTRA⁴, Thomas WAELCHLI⁵,
Thiebaud PICART¹, Chloe DUMOT¹, Omer EKER⁶, Stephane MARINESCO³, Ivan
RADOVANOVIC⁵, François COTTON^{7,8}, Moncef BERHOUMA^{1,5,8}

1 - Department of Neurosurgical Oncology and Vascular Neurosurgery – Pierre Wertheimer
Neurological and Neurosurgical Hospital – Hospices Civils de Lyon – France

2 - Department of Neuro-Anesthesia and Neuro-Critical Care – Pierre Wertheimer Neurological and
Neurosurgical Hospital – Hospices Civils de Lyon – France

3 - Lyon Neuroscience Research Center, TIGER team and AniRA-Beliv technological platform,
Inserm U2018, CNRS UMR 5292, Lyon 1 University - France

4 – Department of Neurosurgery, Clinical Neuroscience Center, University Hospital Zurich,
University of Zurich, Switzerland

5 - Division of Neurosurgery, Toronto Western Hospital, University of Toronto, Canada

6 – Department of Interventional Neuroradiology - Pierre Wertheimer Neurological and Neurosurgical
Hospital – Hospices Civils de Lyon – France

7 – Department of Imaging – Centre Hospitalier Lyon Sud – Hospices Civils de Lyon – France

8 - Creatis Lab - CNRS UMR 5220 – INSERM U1206 – Lyon 1 University – INSA Lyon – France

Corresponding Author: **Moncef BERHOUMA MD, PhD**

Department of Neurosurgical Oncology and Vascular Neurosurgery

Pierre Wertheimer Neurological and Neurosurgical Hospital

University of Lyon – Hospices Civils de Lyon

59 Boulevard Pinel 69003 Lyon – France

Email: berhouma.moncef@gmail.com

moncef.berhouma@chu-lyon.fr

Telephone: (0033) 04.72.35.69.8&

RUNNING TITLE: Intraoperative cerebral blood flow monitoring

ABSTRACT

Intraoperative monitoring of cerebral blood flow (CBF) has become an invaluable adjunct to vascular and oncological neurosurgery, reducing the risk of postoperative morbidity and mortality. Several technologies have been developed during the last two decades, including laser-based techniques, videomicroscopy, intraoperative MRI, indocyanine green angiography, and thermography. Although these technologies have been thoroughly studied and clinically applied outside the operative room, current practice lacks an optimal technology that perfectly fits the workflow within the neurosurgical operative room. The different available technologies have specific strengths but suffer several drawbacks, mainly including limited spatial and/or temporal resolution. An optimal CBF monitoring technology should meet particular criteria for intraoperative use: excellent spatial and temporal resolution, integration in the operative workflow, real-time quantitative monitoring, ease of use, and non-contact technique. We here review the main contemporary technologies for intraoperative CBF monitoring and their current and potential future applications in neurosurgery.

KEYWORDS: Cerebral blood flow, Intraoperative imaging, Laser speckle contrast imaging, Microcirculation, Sidestream dark field imaging

ABBREVIATIONS:

CBF : Cerebral blood flow

CPP : Cerebral perfusion pressure

CSF : Cerebrospinal fluid

LDF : Laser doppler flowmetry

LDI : Laser doppler imaging

LSCI : Laser speckle cell imaging
MESI : Multi-exposure speckle imaging
CCD : Charge-coupled device
CSD : Cortical spreading depolarization
AVM : arteriovenous malformation
NIRS : Near-infrared spectroscopy
BOLD : blood oxygenation-level dependent
SDF : Sidestream dark field
CLE : Confocal laser endomicroscopy
DSA : Digital subtraction angiography
ICG-VA : Indocyanine green video angiography
MDU : Microvascular doppler ultrasound
FUS : Functional ultrasound
CEU : Contrast-enhanced ultrasound

DECLARATIONS

The manuscript has been read and approved by all the authors, that the requirements for authorship as stated earlier in this document have been met, and that each author believes that the manuscript represents honest work.

Authorship: All authors have critically revised the manuscript and approved its final content.

Manuscript draft, analysis and interpretation of the data: NT, MB, TP, JF, TW. Acquisition of the data: NT, MB, SM, BB, CD. Conception and design of the study: MB, OE, IR, FC.

Interpretation of the data: MB, IR, FC.

ETHICAL STATEMENT:

- Funding: None
- Conflict of interest: The authors declared no potential conflicts of interest with respect to the research, authorship, and/or publication of this article.
- Ethical approval: Not needed
- Informed consent: Not needed

INTRODUCTION

In neurosurgery, monitoring cerebral blood flow (CBF) is a key factor for optimal intra- and peri-operative patient management. Through cerebral perfusion, CBF ensures adequate brain functioning through the delivery of oxygen and energy substrates but also the drainage of metabolic waste products. The regulation of cerebral perfusion is directly correlated to the adjustment of the intracranial volume which includes the cerebrovascular arteriovenous network and the cerebrospinal fluid (CSF) volume. Both cerebrovascular resistance and cerebral perfusion pressure (CPP = mean arterial pressure – intracranial pressure) condition the CBF (Poiseuille's law).

CBF corresponds to the volume of blood that flows per unit mass (or volume) per unit time in the brain. In adults, CBF ranges from 20 to 80 ml/(100 g min) with an average of 50 ml/(100 g min).[1,2]

According to the following equation:

$$\text{Blood flow} = \frac{\Delta P}{R} = \frac{\Delta P \pi r^4}{8 \mu L}$$

(ΔP : Pressure gradient, R : vascular resistance, r : vessel radius, L : vessel length, μ : blood viscosity)

CBF may be primarily affected by variations of vessel radius (i.e. vasodilatation, vasoconstriction), CPP, and blood viscosity (reflection of hematocrit). CBF perpetually adapts to brain metabolism variations (neurovascular coupling) while its homeostasis is rigorously maintained through potent cerebral autoregulation mechanisms.

During a neurosurgical procedure, CBF monitoring is critical to avoid both hypo- and hyper-perfusion complications either secondary to systemic events (arterial pressure

instability, post-hemorrhagic anemia, hyper- or hypocapnia...) or due to local surgical constraints (vessel clipping, brain retraction...). Moreover cerebral arteries may suffer transient vasospasm during their surgical manipulation and/or dissection particularly during aneurysmal subarachnoid hemorrhage, leading to intraoperative CBF variations.[3] CBF monitoring is also a potentially very useful adjunct for brain mapping during tumor resection. Although a myriad of invasive and non-invasive CBF monitoring technologies are available for the pre- and post-operative periods[1,2,4,5], it is rarely available intra-operatively mostly because of the absence of an optimal technology that perfectly suits the environment within an operating room. In the current clinical practice, very few techniques have the capacity to provide real-time CBF monitoring without interfering with the surgical workflow.

Here, we provide a narrative literature review of the predominantly available CBF monitoring techniques that are suitable for the intra-operative environment and we describe the benefits and disadvantages of each technique (Table 1), focusing on the characteristics that appear to be fundamental for the “ideal” CBF monitoring technology in operative neurosurgery: Excellent spatial and temporal resolution, integration in the surgical workflow, quantitative real-time monitoring, ease of use, and non-contact technique.

METHODS

A bibliographic search from March 1982 to March 2020 via Medline and Scopus databases with the keywords “cerebral blood flow”, “intraoperative” and “neurosurgery” was performed (Figure 1). We included both animal and human studies describing CBF monitoring outside and inside the neurosurgical operative room environment. All types of study design were included. The abstracts of identified publications were reviewed, and only relevant articles were considered. There were no language restrictions. To compare the different CBF monitoring technologies, we used a qualitative ordinal scale for each characteristic: Depth of imaging, spatial and temporal resolutions, surgical integration in the workflow, and the possibility to provide quantitative measurements.

LASER DOPPLER-BASED TECHNOLOGIES

Laser Doppler flowmetry (LDF) was developed in the 1970's, mainly for dermatological purposes.[6,7] This optically based technology relies on a coherent laser light and measures the flow of fluids carrying light-scattering particles and erythrocytes within an illuminated brain tissue volume of approximately 1 mm³. [8] The blood flow (reflection of erythrocytes' velocity and density) is indirectly estimated through the frequency shift (resulting from the Doppler effect) transmitted to incident monochromatic photons by the mobile erythrocytes within the vessels (Figure 2). LDF provides relative measurements of blood flow and requires calibration before usage. Different LDF probes have been developed including mainly cortical surface contact probes to intraparenchymal ones (mainly used in intensive care monitoring such as an ICP monitoring probe[9]) allowing either single shot measurements or continuous monitoring during specific neurosurgical procedures.

Rosenblum et al. first introduced LDF in the neurosurgical field in 1987 providing measurements of cortical peri-nidal CBF variations before and after resection of a brain arteriovenous malformation (AVM), depicting at the microcirculatory level the concept of normal perfusion pressure breakthrough.[10] LDF has also been useful in the continuous intraoperative monitoring of CBF during revascularization bypass surgery in moyamoya disease, with the ability to predict post-operative cerebral hyperperfusion syndrome.[11] More recently, Kubo et al. used LDF intraoperatively associated with middle cerebral artery pressure measurement, as a possible substitute of balloon test occlusion, during parent artery surgical occlusion for symptomatic cavernous carotid aneurysms in order to identify the critical variations of CBF and henceforth patients who require a concomitant high-flow bypass.[12] Surface cortical probes provide real-time information on local CBF variations, and thus can help the detection of ischemic events and cortical spreading depolarization (CSD).[13] Other than for vascular neurosurgery, LDF has been shown to be useful in functional and oncological neurosurgery.[14] With its capability in differentiating white matter from grey matter based on specific patterns of microvascular blood flow, LDF with intraparenchymal probes can help improving the safety and accuracy of deep brain stimulation procedures.[15] Haj-Hosseini et al. associated 5-ALA fluorescence and LDF in a unique specific stereotactic probe to optimize the capacity of tracking intra-cerebral vessels on the trajectory of the probe and better detect tumoral tissue.[16]

Overall, during neurosurgical procedures, LDF offers the possibility of excellent real-time blood flow measurements and hence a good temporal resolution as compared to other intraoperative CBF monitoring technologies but suffers a poor spatial resolution due to a single point analysis. The latter raises the problem of representativity of the whole CBF

compared to the local measurements provided by LDF and emphasizes the importance for choosing relevant surgical sites to obtain an exploitable measurement. This lack of representativity becomes particularly evident in the interpretation of CBF data monitored by an intraparenchymal LDF probe in ICU patients.[9] In this choice of surgical site for LDF registration, the neurosurgeon should avoid any cortical zone that includes relatively large vessels to ensure the reliability of measurements in the analyzed brain volume. Another drawback of LDF is the high sensitivity of the probe to micromovements (brain pulsatility, cortical fluids, surgical maneuvers) leading to motion artifacts resulting in imprecise measurements.

In order to overcome these drawbacks, laser doppler imaging (LDI) has been developed. This technology is based on LDF, but a movable mirror directs the laser incident beam on different measurement points to allow scanning of a larger cortical surface. The depth of scanning is 2 to 3 times higher than LDF reaching up to 1.5 mm. Apart of being able to provide a larger surface analysis, LDI is a non-contact technology avoiding the risk of pressure artifacts. It offers a good spatial resolution with a good reproducibility, but its temporal resolution is very low compared to LDF as it does not provide real-time analysis and requires a relatively long time for both surface scanning and data processing. This drawback has limited its usefulness during neurosurgical procedures. Raabe et al. integrated LDI technology into an operative microscope enabling to analyze CBF during awake surgery with a protocol for eloquent cortex stimulation, thereby providing a real-time intraoperative functional brain monitoring[17]. Technologies with faster data acquisition and processing are being investigated and may result in a LDI technology with both improved spatial and temporal resolution, in the near future.

More recently, LDF was combined to spectrophotometry (backscattering spectroscopy) in a single multiparameter probe (“oxygen-to-see or O2C”) to provide the capillary venous oxygenation and the relative hemoglobin content as a metabolic monitoring in addition to microcirculation data.[18] Sommer et al evaluated the feasibility of this system in the intra-operative setting and showed its sensibility to surgical brain tissue retraction and modifications of the head position.[19]

LASER SPECKLE CELL IMAGING

Developed initially in 1981 for imaging of retinal blood flow[20], laser speckle cell imaging (LSCI) - initially known as LASCA for laser speckle contrast analysis - relies on a light effect called laser speckle, secondary to the illumination of a biological tissue by a coherent laser beam. This effect results from the irregular backscattering of the light by the heterogeneous structure of the illuminated tissue. The resulting random speckle pattern detected by a charge-coupled device (CCD) camera (Figure 3) varies with the movement of erythrocytes, becoming more blurred in presence of a high erythrocyte flow and thus reducing the contrast. Blood flow is then deduced by the quantification of the spatial blurring of the speckle pattern over the exposure time of the CCD camera (Figure 4). Basically, the spatial blurring is quantified using the speckle contrast K :

$$K(T) = \frac{\sigma S(T)}{\langle I \rangle}$$

(T corresponds to the exposure time of the camera, σS the standard deviation and I the mean intensity of pixel values). [21]

Even if the K value correlates to the level of motion of erythrocytes, this technique is not able to quantify the absolute blood flow.[22] In contrast to LDF and LDI, LSCI allows faster real-time measurements of blood flow on large surfaces resulting in excellent temporal and spatial resolution, but remains limited in penetration of the brain cortex achieving a maximal depth of approximately 300 μm . Despite LSCI being a non-contact technology, it is very sensitive to movement artifacts - particularly cardiac and respiratory related motions - as well as brain shift during neurosurgical procedures. Richards et al. developed a system allowing a retrospective motion correction based on ECG filtering and physiological noise reduction, resulting in a better intraoperative accuracy of LSCI and the possibility to detect minimal CBF variations.[23] Dunn et al. noted that one important limitation of LSCI results from the use of a single camera exposure time and the sensitivity of the technique to several confounding factors (illumination discrepancies and the presence of light scattered from static tissue), leading to the development of an extension of LSCI named multi-exposure speckle imaging (MESI) to improve the quantitative accuracy for measuring CBF.[24–26] Using a more robust mathematical model, Dunn et al. showed that MESI is adapted to chronic monitoring of the blood flow and has a good correlation with in vivo blood flow values, opening new perspectives for the intra- and inter-patients' CBF comparative studies. Other

parameters can be measured with optical imaging concomitantly with LSCI or MESI, including hemoglobin oxygenation and oxygen tension to better explore and understand neurovascular coupling in ischemic diseases and functional brain mapping.[27–31]

LSCI is currently gaining increased popularity in both research and clinical applications due to its aforementioned excellent spatial and temporal resolutions. Hecht et al. evaluated LSCI in 3 patients undergoing direct cerebral revascularization surgery and confirmed the ability of LSCI to provide quasi-real time relative CBF monitoring with a clear capacity to depict any minimal blood flow variations during surgery.[32] Furthermore, Parthasarathy et al. integrated the LSCI device to the neurosurgical operating microscope to ease the surgical workflow. A filter calibrated with the electrocardiogram was also used to decrease the pulsations-related artifacts.[33] Ideguchi et al. used LSCI to better identify feeding arteries during the resection of brain tumors and AVMs, and thus reduce the risk of post-operative ischemic complications.[34] Specifically, by using temporary arterial occlusion under LSCI monitoring, the authors were able to distinguish feeding arteries from en passage arteries and combined arteries (i.e. en passage arteries providing feeding branches to the lesion). Hecht et al explored the potential of LSCI for the prediction of infarction by monitoring 22 patients undergoing decompressive craniectomy for middle cerebral artery infarction.[35] By standardizing LSCI analysis parameters, the authors determined LSCI specific perfusion thresholds that not only allow the recognition of infarcted brain but mainly predict further infarctions. Klijn et al. evaluated the feasibility of LSCI in identifying eloquent brain cortex during awake glioma surgery.[36] They confirmed that LSCI was accurately able to detect any cortical CBF increase secondary to induced motor activity, overcoming the limitations of traditional electric stimulations mapping, i.e. the time consumption and risk of false positive responses as well as seizure activity. Woitzik et al. used LSCI intraoperatively to identify and follow the spatiotemporal progression of CSD in malignant stroke as CSDs exhibit characteristic cortical CBF patterns.[37]

LSCI and MESI are easily accessible technologies with an excellent spatiotemporal resolution providing a quantitative monitoring of CBF. The combination of LSCI and other videomicroscopic imaging can provide a morphological assessment of the microcirculation (vessel density, proportion of perfused vessels, etc....) in addition to the quantitative monitoring of CBF.[38] In the upcoming years, its integration in the surgical microscope will certainly ease its regular use in vascular but also oncological neurosurgery, providing a close to quantitative real-time CBF monitoring.

SIDESTREAM DARK FIELD IMAGING

Sidestream dark field (SDF) imaging is a videomicroscopy technique allowing a direct visualization of the cortical microcirculation. Originally, Slaaf et al. developed in 1987 an incident illuminator for intravital imaging of microcirculation.[39] In 1999 Groner et al. improved the concept by developing orthogonal polarization spectral (OPS) imaging, the precursor of sidestream dark field (SDF) technique.[40] This videomicroscopic technique relies on a stroboscopic light emitting diode ring-based modality and allows a direct visualization of the cortical microcirculation (Figure 5). The hand-held device includes a light guide, a magnifying lens and a CCD video camera (Figure 6a). The illumination is ensured by a 530 to 548 nm wavelength green light specifically absorbed by hemoglobin, leading to a dark appearance of erythrocytes. SDF provides imaging of the microcirculation at a depth of approximately 530 μm and with a final on-screen magnification reaching 320 to 325 times that of the original and a field size of 1280 μm x 960 μm . This technology allows measuring key microcirculatory parameters (Figure 6b), such as vessel density, vessel diameter, flow index, proportion of perfused vessels and microvasospasms.[41] The recent development of advanced analysis software permits real-time intraoperative analysis of these microcirculatory parameters by optimizing the temporal resolution. The spatial resolution, however, remains limited. As all contact technologies, SDF suffers the possibility of motion and pressure artifacts. In neurosurgery, these artifacts may be reduced by the use of a self-retaining holding arm for the probe during registration. When image acquisition is optimal, the intra-observer and inter-observer variabilities remain very limited.

The development of compact portable handheld OPS and SDF devices have offered the possibility of intraoperative use in neurosurgery to monitor the microcirculation, including microvascular blood flow. In two subsequent studies, Uhl et al. monitored microcirculation during brain aneurysm surgery revealing microvascular vasospasms and decreased vascular density in patients with subarachnoid hemorrhage.[42,43] Pennings et al. used OPS imaging to reveal arteriolar contractility in response to hypercapnia in a surgical series of aneurysmal subarachnoid hemorrhage.[44] Furthermore, with OPS technology, the same group investigated the perfusion variations of the peri-nidal area during brain AVM surgery and the microvascular response to local papaverine administration during brain aneurysm surgery.[45,46] More recently, Perez-Barcena et al. confirmed the feasibility of intraoperative SDF imaging to monitor microcirculatory parameters in traumatic brain injury and malignant

stroke.[47,48] Our group has recently evaluated the feasibility of SDF imaging of peritumoral microcirculation in intracranial meningiomas to better explore the pathogenesis of peritumoral edema.[49] The intra-operative use of SDF imaging as a continuous real-time monitoring technology in neurosurgery remains very limited due to the poor spatial resolution (single points analysis), susceptibility to motion and pressure artifacts, and difficulties to measure high blood flow velocities.

INDOCYANINE GREEN VIDEO ANGIOGRAPHY

Indocyanine green video angiography (ICG-VA) is an intraoperative technique using a near-infrared range fluorescent tricarboyanine water-soluble dye, initially developed to evaluate the cardiac output, hepatic function and ophthalmic angiography, and has been introduced in neurosurgery during the last two decades (Figures 7a and 7b).[50] ICG shows a spectral absorption at 800-805 nm and an emission peak at 835 nm, with a half-life ranging between 150 to 180 seconds. Injected intravenously at a dose of 0.2 to 0.5 mg/kg, ICG binds to alpha-1 lipoprotein and remains intravascular to be finally excreted by the liver. Repeated intravenous injections are possible at different stages of surgery to allow comparative assessments of blood flow, respecting an interval of 20-25 minutes between two injections to maintain an optimal contrast enhancement and limiting the cumulative total dose inferior to 5 mg/kg. The visualization technology is actually integrated in most operative neurosurgical microscopes without significant interruption of the workflow, providing a flow graph evaluating the time to peak (interval from the raise of the wave to the peak of signal intensity) and thus semi-quantitative evaluation of CBF. Flow maps of CBF may be obtained using the ratio between fluorescence intensity and rise time.[51] Different authors have suggested correlations between the time-intensity curve obtained with a specific software for ICG-VA and the quantitative CBF obtained by an ultrasound flowmeter, allowing in fine a quasi-quantitative blood flow assessment by ICG-VA.[52] Real-time intraoperative blood flow analysis using ICG-VA may be useful in the evaluation of flow dynamics in and around brain AVMs, aneurysm surgery to check the absence of parent vessel post-clipping stenosis and the absence of aneurysmal residue (Figures 7a and 7b), and in hemangioblastomas surgery.[51–56] ICG-VA is very useful during revascularization surgery as, in addition to intraoperative evaluation of graft patency and a quantitative analysis of the relative flow through the bypass, it provides the possibility to identify an optimal recipient artery for the bypass (“flash

fluorescence technique”)[54], and even help predict the postoperative neurological outcome.[57,58] Although ICG-VA has become a relatively low-cost widely used technique in operative rooms with a good safety profile, it still suffers some specific drawbacks compared to other intraoperative CBF imaging techniques: (i) It doesn’t allow a continuous monitoring of blood flow and requires repetitive intravenous dye injections with a minimum of 20-25 minutes between two injections; (ii) Very rare adverse reactions to the intravenous dye are possible (nausea, vomiting, pruritus, bronchospasm, allergy, myocardial infarction, epilepsy); (iii) exploration of subcortical vasculature is limited.

DIGITAL SUBTRACTION ANGIOGRAPHY

Intraoperative digital subtraction angiography (DSA) is routinely used in neurosurgery since a few decades, particularly for complex aneurysm surgery, revascularization procedures, brain AVM resections, and dural arteriovenous fistula surgery.[59] DSA provides mainly morphological information on brain vasculature and basic dynamic alterations (flow slow-down, vasospasm...). Recently, color-coded quantitative digital subtraction angiography has been generated from conventional DSA sequence and may provide in the next future temporal information of contrasted cerebral blood flow as well as quantitative blood flow mapping. Intraoperative DSA requires a specific operating room installation and exposes the patient and the staff personnel to radiations. DSA owns its own complications: arterial dissection, thromboembolic event, allergy to contrast product, and groin hematoma. Intraoperative DSA has been largely replaced by ICG-VA due to its simplicity of use and integration in the operative microscope.

THERMAL IMAGING

Both CBF and to a lesser extent metabolic activity, result in variations of the cortical temperature.[60–62] Imaging of these temperature variations (thermography) have been developed for brain tumor identification[60,63], cortical mapping[61] and CBF monitoring during cerebrovascular surgery.[64,65] The combination of thermography and an intravenous cold saline bolus injection as a contrast agent has greatly improved the possibility of real-time intraoperative CBF imaging, not only on the cortical surface but also in the deeper surgical

cavities.[64] Hwang et al. used thermal imaging to depict the vascular steal phenomenon usually observed in the peri-nidal region of a brain AVM.[65] Muller et al. compared the thermal imaging to ICG-VA during aneurysm surgery and highlighted the possibility of imaging perfusion within the parenchyma deeper than the cortical surface.[64] Suzuki et al. developed a multimodal device associating thermography and LSCI to help understand the part of metabolic activity and microvascular blood flow in the variations of cortical temperature with promising possibilities for the study of neurovascular and metabolic coupling.[66] Even though thermography lacks the possibility of direct quantitative absolute measurements of CBF and morphological imaging of microcirculation, its contactlessness, real-time and non-invasive characteristics, open interesting perspectives for its development in the intraoperative imaging armamentarium in neurosurgery.

NEAR-INFRARED SPECTROSCOPY

Near-infrared spectroscopy (NIRS) is an optical technology used to measure the variations of hemoglobin concentration (oxyhemoglobin (HbO_2), deoxyhemoglobin (dHb) and total hemoglobin concentration ($\text{HbT}=\text{HbO}_2+\text{dHb}$)) via absorption spectroscopy, usually utilized as a non-invasive technique through the scalp, thus providing a reflection of CBF.[67] The cerebral oxygen saturation (ScO_2) results from the ratio HbO_2/HbT . Both ScO_2 and the concentration difference HbD (HbO_2-dHb) are correlated to CBF. NIRS may be used alone in intensive care or associated to other optical techniques such as diffuse correlation spectroscopy to monitor CBF.[68] Recently, NIRS has been adapted to be used in the operative room with an emitting light intensity 75% lower than the scalp NIRS. Fukuda et al. used intraoperative NIRS to demonstrate hemodynamic variations in cortico-cortical activity between the primary and supplementary motor cortex during epilepsy surgery.[69] By using the same intraoperative technique and direct cortical stimulations, Sato et al. were able to highlight the cortico-cortical hemodynamic variations in the language networks with a specific pattern of increase in oxyhemoglobin concomitant with a decrease in deoxyhemoglobin reflecting neurovascular coupling.[70] In their experience, the authors have been limited in their study by a reduced spatial resolution (quasi-single point analysis) in contrast with an excellent temporal resolution, with a depth sensitivity up to 30 mm from the cortical surface. Intraoperative NIRS represents an interesting seizure-free brain mapping technique[71] and a portable technology for the exploration of neurovascular coupling, but

still does not provide direct blood flow measurements with sufficient spatial and temporal resolutions as required in cerebrovascular neurosurgery.

INTRAOPERATIVE MRI

Intraoperative MRI is regularly used in oncological neurosurgery to assess the quality of tumor resection and update neuronavigation data following brain shift.[72] Intraoperative MRI usually relies on anatomical sequences as well as on functional sequences and diffusion tensor imaging for the detection of eloquent cortical and subcortical areas.[73] Recently, Stadlbauer et al. evaluated a quantitative blood oxygenation-level dependent (BOLD) MR sequence intraoperatively to monitor oxygen metabolism and CBF before and after brain tumor resection depicting the beneficial effect of mass effect withdrawal on peri-tumoral blood flow.[74] Moreover, Fierstra et al. demonstrated the feasibility of BOLD fMRI to intraoperatively assess cerebrovascular reactivity (CVR) using 3 cycles of apnea-induced hypercapnia on a 3-tesla MRI (Figure 8).[75] According to the authors, intraoperative BOLD-CVR may not only help monitoring regional and global cerebral hemodynamics during neurosurgical revascularizations surgeries[76], but also assist for detecting residual glioma with a specific CVR pattern[77]. Nevertheless, intraoperative MRI requires an elaborate environment and suffers specific potential drawbacks, such as prolonged anesthetic and time of the entire procedure, specific requirements for the operating instrumentation and staff, as well as a poor temporal resolution impeding any real-time continuous monitoring of CBF, relative measurement of CBF, and the sensibility to surgical field artifacts (air, blood and hemostatic products).

CONFOCAL LASER ENDOMICROSCOPY

Confocal laser endomicroscopy (CLE) is a high resolution and high contrast optical imaging technique based on tissue illumination by a low-power laser and detection of the fluorescence reflected from the brain tissue through a pinhole. With a depth of exploration reaching 200 μm , CLE is used intraoperatively in neurosurgery to provide in-vivo histological diagnosis and may help in the near future to better visualize tumor borders and thus optimize the surgical resection of brain tumors.[78] Besides, CLE has the capacity to visualize the superficial microvascular network intraoperatively[79] and the movement of erythrocytes as

well as flow abnormalities (thrombosis, cell rolling...) but its role for the intraoperative blood flow monitoring remains very scarce because of low spatiotemporal resolution. As an alternative to CLE, the two-photon microscopy is a fluorescence imaging technique using near-infrared excitation light and allowing a deeper brain tissue penetration (up to 1mm). However its intraoperative applicability in humans still remains restricted due to its limited temporal and spatial resolution for usage in neurosurgery.[80]

ULTRASOUND-BASED TECHNOLOGIES

Microvascular doppler ultrasound (MDU) is a simple and straightforward tool regularly used in vascular neurosurgery.[55,81] In addition to ICG-VA, MDU provides essential information on vessel patency and quality of aneurysmal sac exclusion. Nevertheless, MDU requires a direct application on the vessel to be analyzed and thus have very poor spatial resolution. It also suffers poor sensitivity to detect arterial stenosis except if morphological ultrasound is used simultaneously to appreciate vessel diameter. In contrast, flow quantification probes offer the possibility to quantify blood flow in a specific vessel, and thus represents an invaluable tool particularly during revascularization surgeries to assess the bypass and help identify vessel donor and recipient.

Several ultrasound techniques have been described for an intraoperative use in neurosurgery, predominantly as an adjunct for brain tumor resection. Contrast enhanced ultrasound (CEU) utilizes an intravenous contrast agent containing microbubbles (air or inert gas).[82] With the imaging of tumoral microvasculature, CEU offers a better visualization of brain gliomas than standard B-mode ultrasound and may optimize the surgical resection, but does not provide any possibility of CBF monitoring. More recently, a new modality based on high-frame-rate ultrasound named functional ultrasound (FUS) has been introduced to the operative room.[83] FUS allows the detection of very small variations in blood dynamics that correlate with metabolic activation of brain tissue through neurovascular coupling, and thus help optimizing the brain mapping during awake surgery for tumor removal.[84] This data should be interpreted taking into account systemic variables such as hematocrit or CO₂ levels as well as mean arterial pressure. Even if CEU and FUS provide a valuable help for brain tumor delineation and brain mapping based on microvasculature imaging, these techniques do not provide a quantitative CBF monitoring. Both modalities offer deep

penetration analysis, a large field of view and real-time imaging, but remain contact techniques with the risk of motion and pressure artifacts.

PERSPECTIVES AND CONCLUSION

Outside the operative room, CBF monitoring is widely used with a multitude of technological modalities. In contrast, for intraoperative monitoring of CBF, there is no optimal technology that is entirely suitable. Ideally, such a technology should rely on specific requirements for applications in operative neurosurgery:

- Non-contact: Any contact with the brain tissue may lead to motion- and pressure artifacts and thus results in inaccurate CBF measurements. This is particularly significant with LDF, SDF imaging and NIRS. Nevertheless, all available technologies including non-contact devices face the issue of brain pulsations that can lead to a certain amount of motions artifacts.
- Excellent temporal resolution: permitting a real-time continuous monitoring of CBF (data acquisition and analysis) and allowing the neurosurgeon to have an immediate feed-back for any incident as well as enabling to enforce local (clip readjustment, retractor release...) and/or systemic (optimization of blood pressure, CO₂ pressure, depth of anesthesia...) correction measures without delay.
- Excellent spatial resolution: allowing CBF imaging of large brain tissue areas to have a more regional assessment instead of a very limited focal or even single-point imaging.
- Quantitative CBF measurements: The majority of available technologies for intraoperative CBF monitoring does not provide absolute measurements of CBF but relative values and estimations, with the exception of the Doppler flowmeter which is limited to the study of only one artery at a time. This inability to provide absolute measurements makes it difficult to perform intra- and mostly inter-patient comparisons, and to define quantitative thresholds for the intra-operative decision process.
- Depth analysis: Except intraoperative MRI, DSA and NIRS, common CBF imaging technologies provide only very superficial cortical analysis (less than 1.5 mm), impeding the assessment of deep white matter and perforating microvascular blood

flow. This limitation can lead to false interpretations where cortical flow is maintained while invisible deep circulation is impaired, for example when a feeding artery is temporarily clipped during an AVM surgery.

- Integration in the surgical workflow: an optimal CBF monitoring system should not significantly impact the duration of surgery and should ideally be fully integrated into the surgical microscope to avoid substantial interruptions of the workflow. Integration in the microscope makes sterile draping easier, thus minimizing the risk of infection. Simplicity of use and data comprehension are also paramount. Intraoperative MRI and DSA, despite the essential information they can provide, are quite expensive and cumbersome in that regard.

Considering all these characteristics, LSCI and MESI appear to have the best current technological profile for the intraoperative use in neurosurgery, including excellent temporal and spatial resolution, and particularly integration to the surgical microscope (Figure 9). Applications of intra-operative CBF monitoring in neurosurgery should dramatically increase in the near future because of the technical refinements that are being developed and the expanding integration in the surgical workflow. These applications will certainly exceed the field of vascular neurosurgery, which is actually manifest, to encompass neuro-oncological surgery (brain mapping, tumor identification) and functional surgery (deep brain stimulation), particularly when used in association with electrophysiological monitoring to concomitantly monitor deep brain vasculature and reduce operative morbidity. Finally, the development of hybrid solutions associating blood flow and metabolic monitoring are of great interest in brain surgery and shall help in the understanding of neurometabolic coupling mechanisms.[19,66,68]

REFERENCES

- [1] Lal C, Leahy MJ. An Updated Review of Methods and Advancements in Microvascular Blood Flow Imaging. *Microcirculation* 2016;23:345–63. <https://doi.org/10.1111/micc.12284>.
- [2] Fantini S, Sassaroli A, Tgavalekos KT, Kornbluth J. Cerebral blood flow and autoregulation: current measurement techniques and prospects for noninvasive optical methods. *Neurophotonics* 2016;3:031411. <https://doi.org/10.1117/1.NPh.3.3.031411>.
- [3] Findlay JM, Macdonald RL, Weir BK, Grace MG. Surgical manipulation of primate cerebral arteries in established vasospasm. *J Neurosurg* 1991;75:425–32. <https://doi.org/10.3171/jns.1991.75.3.0425>.
- [4] Daly SM, Leahy MJ. 'Go with the flow': a review of methods and advancements in blood flow imaging. *J Biophotonics* 2013;6:217–55. <https://doi.org/10.1002/jbio.201200071>.
- [5] Devor A, Sakadžić S, Srinivasan VJ, Yaseen MA, Nizar K, Saisan PA, et al. Frontiers in Optical Imaging of Cerebral Blood Flow and Metabolism. *J Cereb Blood Flow Metab* 2012;32:1259–76. <https://doi.org/10.1038/jcbfm.2011.195>.
- [6] Riva C, Ross B, Benedek GB. Laser Doppler measurements of blood flow in capillary tubes and retinal arteries. *Invest Ophthalmol* 1972;11:936–44.
- [7] Stern MD, Lappe DL, Bowen PD, Chimosky JE, Holloway GA, Keiser HR, et al. Continuous measurement of tissue blood flow by laser-Doppler spectroscopy. *Am J Physiol* 1977;232:H441–448. <https://doi.org/10.1152/ajpheart.1977.232.4.H441>.
- [8] Arbit E, DiResta GR. Application of laser Doppler flowmetry in neurosurgery. *Neurosurg Clin N Am* 1996;7:741–8.
- [9] Kirkpatrick PJ, Smielewski P, Czosnyka M, Pickard JD. Continuous monitoring of cortical perfusion by laser Doppler flowmetry in ventilated patients with head injury. *J Neurol Neurosurg Psychiatry* 1994;57:1382–8. <https://doi.org/10.1136/jnnp.57.11.1382>.
- [10] Rosenblum BR, Bonner RF, Oldfield EH. Intraoperative measurement of cortical blood flow adjacent to cerebral AVM using laser Doppler velocimetry. *J Neurosurg* 1987;66:396–9. <https://doi.org/10.3171/jns.1987.66.3.0396>.
- [11] Kawamata T, Kawashima A, Yamaguchi K, Hori T, Okada Y. Usefulness of intraoperative laser Doppler flowmetry and thermography to predict a risk of postoperative hyperperfusion after superficial temporal artery–middle cerebral artery bypass for moyamoya disease. *Neurosurg Rev* 2011;34:355–62. <https://doi.org/10.1007/s10143-011-0331-8>.
- [12] Kubo Y, Koji T, Kondo R, Yoshida K, Ogasawara K. Intraoperative monitoring of cerebral cortical blood flow and middle cerebral artery pressure as a substitute for preoperative balloon test occlusion in patients with internal carotid artery aneurysms. *Acta Neurochir (Wien)* 2018;160:1129–37. <https://doi.org/10.1007/s00701-018-3469-0>.
- [13] Winkler MKL, Chassidim Y, Lublinsky S, Revankar GS, Major S, Kang E-J, et al. Impaired neurovascular coupling to ictal epileptic activity and spreading depolarization in a patient with subarachnoid hemorrhage: Possible link to blood–brain barrier dysfunction. *Epilepsia* 2012;53:22–30. <https://doi.org/10.1111/j.1528-1167.2012.03699.x>.
- [14] Rejmstad P, Åkesson G, Åneman O, Wårdell K. A laser Doppler system for monitoring cerebral microcirculation: implementation and evaluation during neurosurgery. *Med Biol Eng Comput* 2016;54:123–31. <https://doi.org/10.1007/s11517-015-1332-5>.
- [15] Wårdell K, Zsigmond P, Richter J, Hemm S. Relationship Between Laser Doppler Signals and Anatomy During Deep Brain Stimulation Electrode Implantation Toward the

- Ventral Intermediate Nucleus and Subthalamic Nucleus. *Oper Neurosurg (Hagerstown)* 2013;72:ons127–40. <https://doi.org/10.1227/NEU.0b013e31827e5821>.
- [16] Haj-Hosseini N, Richter JCO, Milos P, Hallbeck M, Wårdell K. 5-ALA fluorescence and laser Doppler flowmetry for guidance in a stereotactic brain tumor biopsy. *Biomed Opt Express* 2018;9:2284–96. <https://doi.org/10.1364/BOE.9.002284>.
- [17] Raabe A, Van De Ville D, Leutenegger M, Szelényi A, Hattingen E, Gerlach R, et al. Laser Doppler imaging for intraoperative human brain mapping. *Neuroimage* 2009;44:1284–9. <https://doi.org/10.1016/j.neuroimage.2008.10.049>.
- [18] Klein KU, Stadie A, Fukui K, Schramm P, Werner C, Oertel J, et al. Measurement of cortical microcirculation during intracranial aneurysm surgery by combined laser-Doppler flowmetry and photospectrometry. *Neurosurgery* 2011;69:391–8. <https://doi.org/10.1227/NEU.0b013e3182178bc9>.
- [19] Sommer B, Kreuzer M, Bischoff B, Wolf D, Schmitt H, Eyupoglu IY, et al. Combined Laser-Doppler Flowmetry and Spectrophotometry: Feasibility Study of a Novel Device for Monitoring Local Cortical Microcirculation during Aneurysm Surgery. *J Neurol Surg A Cent Eur Neurosurg* 2017;78:1–11. <https://doi.org/10.1055/s-0036-1584510>.
- [20] Briers JD, Fercher AF. Retinal blood-flow visualization by means of laser speckle photography. *Invest Ophthalmol Vis Sci* 1982;22:255–9.
- [21] Dunn AK. Laser speckle contrast imaging of cerebral blood flow. *Ann Biomed Eng* 2012;40:367–77. <https://doi.org/10.1007/s10439-011-0469-0>.
- [22] Kazmi SMS, Richards LM, Schrandt CJ, Davis MA, Dunn AK. Expanding applications, accuracy, and interpretation of laser speckle contrast imaging of cerebral blood flow. *J Cereb Blood Flow Metab* 2015;35:1076–84. <https://doi.org/10.1038/jcbfm.2015.84>.
- [23] Richards LM, Towle EL, Fox DJ, Dunn AK. Intraoperative laser speckle contrast imaging with retrospective motion correction for quantitative assessment of cerebral blood flow. *NPh* 2014;1:015006. <https://doi.org/10.1117/1.NPh.1.1.015006>.
- [24] Parthasarathy AB, Tom WJ, Gopal A, Zhang X, Dunn AK. Robust flow measurement with multi-exposure speckle imaging. *Opt Express* 2008;16:1975–89. <https://doi.org/10.1364/oe.16.001975>.
- [25] Kazmi SMS, Parthasarathy AB, Song NE, Jones TA, Dunn AK. Chronic imaging of cortical blood flow using Multi-Exposure Speckle Imaging. *J Cereb Blood Flow Metab* 2013;33:798–808. <https://doi.org/10.1038/jcbfm.2013.57>.
- [26] Richards LM, Kazmi SS, Olin KE, Waldron JS, Fox DJ, Dunn AK. Intraoperative multi-exposure speckle imaging of cerebral blood flow. *J Cereb Blood Flow Metab* 2017;37:3097–109. <https://doi.org/10.1177/0271678X16686987>.
- [27] Ponticorvo A, Dunn AK. Simultaneous imaging of oxygen tension and blood flow in animals using a digital micromirror device. *Opt Express* 2010;18:8160–70. <https://doi.org/10.1364/OE.18.008160>.
- [28] Jones PB, Shin HK, Boas DA, Hyman BT, Moskowitz MA, Ayata C, et al. Simultaneous multispectral reflectance imaging and laser speckle flowmetry of cerebral blood flow and oxygen metabolism in focal cerebral ischemia. *J Biomed Opt* 2008;13:044007. <https://doi.org/10.1117/1.2950312>.
- [29] Shin HK, Dunn AK, Jones PB, Boas DA, Lo EH, Moskowitz MA, et al. Normobaric hyperoxia improves cerebral blood flow and oxygenation, and inhibits peri-infarct

- depolarizations in experimental focal ischaemia. *Brain* 2007;130:1631–42. <https://doi.org/10.1093/brain/awm071>.
- [30] Dunn AK, Devor A, Dale AM, Boas DA. Spatial extent of oxygen metabolism and hemodynamic changes during functional activation of the rat somatosensory cortex. *Neuroimage* 2005;27:279–90. <https://doi.org/10.1016/j.neuroimage.2005.04.024>.
- [31] Dunn AK, Devor A, Bolay H, Andermann ML, Moskowitz MA, Dale AM, et al. Simultaneous imaging of total cerebral hemoglobin concentration, oxygenation, and blood flow during functional activation. *Opt Lett* 2003;28:28–30. <https://doi.org/10.1364/ol.28.000028>.
- [32] Hecht N, Woitzik J, Dreier JP, Vajkoczy P. Intraoperative monitoring of cerebral blood flow by laser speckle contrast analysis. *Neurosurgical Focus* 2009;27:E11. <https://doi.org/10.3171/2009.8.FOCUS09148>.
- [33] Parthasarathy AB, Weber EL, Richards LM, Fox DJ, Dunn AK. Laser speckle contrast imaging of cerebral blood flow in humans during neurosurgery: a pilot clinical study. *J Biomed Opt* 2010;15:066030. <https://doi.org/10.1117/1.3526368>.
- [34] Ideguchi M, Kajiwara K, Yoshikawa K, Goto H, Sugimoto K, Inoue T, et al. Avoidance of ischemic complications after resection of a brain lesion based on intraoperative real-time recognition of the vasculature using laser speckle flow imaging. *J Neurosurg* 2017;126:274–80. <https://doi.org/10.3171/2016.1.JNS152067>.
- [35] Hecht N, Müller M-M, Sandow N, Pinczolits A, Vajkoczy P, Woitzik J. Infarct prediction by intraoperative laser speckle imaging in patients with malignant hemispheric stroke. *J Cereb Blood Flow Metab* 2016;36:1022–32. <https://doi.org/10.1177/0271678X15612487>.
- [36] Klijn E, Hulscher HC, Balvers RK, Holland WPJ, Bakker J, Vincent AJPE, et al. Laser speckle imaging identification of increases in cortical microcirculatory blood flow induced by motor activity during awake craniotomy. *J Neurosurg* 2013;118:280–6. <https://doi.org/10.3171/2012.10.JNS1219>.
- [37] Woitzik J, Hecht N, Pinczolits A, Sandow N, Major S, Winkler MKL, et al. Propagation of cortical spreading depolarization in the human cortex after malignant stroke. *Neurology* 2013;80:1095–102. <https://doi.org/10.1212/WNL.0b013e3182886932>.
- [38] Nadort A, Kalkman K, van Leeuwen TG, Faber DJ. Quantitative blood flow velocity imaging using laser speckle flowmetry. *Scientific Reports* 2016;6:1–10. <https://doi.org/10.1038/srep25258>.
- [39] Slaaf DW, Tangelder GJ, Reneman RS, Jäger K, Bollinger A. A versatile incident illuminator for intravital microscopy. *Int J Microcirc Clin Exp* 1987;6:391–7.
- [40] Groner W, Winkelmann JW, Harris AG, Ince C, Bouma GJ, Messmer K, et al. Orthogonal polarization spectral imaging: A new method for study of the microcirculation. *Nat Med* 1999;5:1209–12. <https://doi.org/10.1038/13529>.
- [41] De Backer D, Hollenberg S, Boerma C, Goedhart P, Büchele G, Ospina-Tascon G, et al. How to evaluate the microcirculation: report of a round table conference. *Crit Care* 2007;11:R101. <https://doi.org/10.1186/cc6118>.
- [42] Uhl E, Lehmeberg J, Steiger H-J, Messmer K. Intraoperative Observation of Human Cerebral Microcirculation. *Orthogonal Polarization Spectral Imaging* 2000;24:72–81. <https://doi.org/10.1159/000061947>.

- [43] Uhl E, Lehmborg J, Steiger H-J, Messmer K. Intraoperative detection of early microvasospasm in patients with subarachnoid hemorrhage by using orthogonal polarization spectral imaging. *Neurosurgery* 2003;52:1307–15; discussion 1315-1317. <https://doi.org/10.1227/01.neu.0000065154.04824.9e>.
- [44] Pennings FA, Bouma GJ, Ince C. Direct Observation of the Human Cerebral Microcirculation During Aneurysm Surgery Reveals Increased Arteriolar Contractility. *Stroke* 2004;35:1284–8. <https://doi.org/10.1161/01.STR.0000126039.91400.cb>.
- [45] Pennings FA, Ince C, Bouma GJ. Continuous real-time visualization of the human cerebral microcirculation during arteriovenous malformation surgery using orthogonal polarization spectral imaging. *Neurosurgery* 2006;59:167–71; discussion 167-171. <https://doi.org/10.1227/01.NEU.0000219242.92669.3B>.
- [46] Pennings FA, Albrecht KW, Muizelaar JP, Schuurman PR, Bouma GJ. Abnormal responses of the human cerebral microcirculation to papaverin during aneurysm surgery. *Stroke* 2009;40:317–20. <https://doi.org/10.1161/STROKEAHA.108.522375>.
- [47] Pérez-Bárcena J, Goedhart P, Ibáñez J, Brell M, García R, Llinás P, et al. Direct observation of human microcirculation during decompressive craniectomy after stroke. *Crit Care Med* 2011;39:1126–9. <https://doi.org/10.1097/CCM.0b013e31820ead5e>.
- [48] Pérez-Bárcena J, Romay E, Llompарт-Pou JA, Ibáñez J, Brell M, Llinás P, et al. Direct observation during surgery shows preservation of cerebral microcirculation in patients with traumatic brain injury. *J Neurol Sci* 2015;353:38–43. <https://doi.org/10.1016/j.jns.2015.03.044>.
- [49] Berhouma M, Picart T, Dumot C, Pelissou-Guyotat I, Meyronet D, Ducray F, et al. Alterations of cerebral microcirculation in peri-tumoral edema: Feasibility of in vivo sidestream dark field imaging in intracranial meningiomas. *Neuro Oncol Adv* n.d. <https://doi.org/10.1093/noajnl/vdaa108>.
- [50] Raabe A, Beck J, Gerlach R, Zimmermann M, Seifert V. Near-infrared indocyanine green video angiography: a new method for intraoperative assessment of vascular flow. *Neurosurgery* 2003;52:132–9; discussion 139. <https://doi.org/10.1097/00006123-200301000-00017>.
- [51] Woitzik J, Peña-Tapia PG, Schneider UC, Vajkoczy P, Thomé C. Cortical perfusion measurement by indocyanine-green videoangiography in patients undergoing hemispherectomy for malignant stroke. *Stroke* 2006;37:1549–51. <https://doi.org/10.1161/01.STR.0000221671.94521.51>.
- [52] Saito M, Saga T, Hayashi H, Noro S, Wada H, Kamada K. Quantitative Blood Flow Assessment by Multiparameter Analysis of Indocyanine Green Video Angiography. *World Neurosurg* 2018;116:e187–93. <https://doi.org/10.1016/j.wneu.2018.04.148>.
- [53] Kato N, Prinz V, Dengler J, Vajkoczy P. Blood Flow Assessment of Arteriovenous Malformations Using Intraoperative Indocyanine Green Videoangiography. *Stroke Res Treat* 2019;2019. <https://doi.org/10.1155/2019/7292304>.
- [54] Cavallo C, Gandhi S, Zhao X, Belykh E, Valli D, Nakaji P, et al. Applications of Microscope-Integrated Indocyanine Green Videoangiography in Cerebral Revascularization Procedures. *Front Surg* 2019;6. <https://doi.org/10.3389/fsurg.2019.00059>.
- [55] Starke RM, Dumont AS. Intraoperative imaging and assessment of cerebral blood flow in cerebrovascular surgery: hybrid operating rooms, intraoperative angiography and

- magnetic resonance imaging, Doppler ultrasound, cerebral blood flow probes, endoscopic assistance, indocyanine green videography, and laser speckle contrast imaging. *World Neurosurg* 2014;82:e693-696. <https://doi.org/10.1016/j.wneu.2013.10.045>.
- [56] Raabe A, Nakaji P, Beck J, Kim LJ, Hsu FPK, Kamerman JD, et al. Prospective evaluation of surgical microscope—integrated intraoperative near-infrared indocyanine green videoangiography during aneurysm surgery. *Journal of Neurosurgery* 2005;103:982–9. <https://doi.org/10.3171/jns.2005.103.6.0982>.
- [57] Uchino H, Kazumata K, Ito M, Nakayama N, Kuroda S, Houkin K. Intraoperative assessment of cortical perfusion by indocyanine green videoangiography in surgical revascularization for moyamoya disease. *Acta Neurochir* 2014;156:1753–60. <https://doi.org/10.1007/s00701-014-2161-2>.
- [58] Horie N, Fukuda Y, Izumo T, Hayashi K, Suyama K, Nagata I. Indocyanine green videoangiography for assessment of postoperative hyperperfusion in moyamoya disease. *Acta Neurochir* 2014;156:919–26. <https://doi.org/10.1007/s00701-014-2054-4>.
- [59] Fredrickson VL, Russin JJ, Strickland BA, Bakhsheshian J, Amar AP. Intraoperative Imaging for Vascular Lesions. *Neurosurg Clin N Am* 2017;28:603–13. <https://doi.org/10.1016/j.nec.2017.05.011>.
- [60] Gorbach AM, Heiss JD, Kopylev L, Oldfield EH. Intraoperative infrared imaging of brain tumors. *J Neurosurg* 2004;101:960–9. <https://doi.org/10.3171/jns.2004.101.6.0960>.
- [61] Hoffmann N, Radev Y, Koch E, Petersohn U, Steiner G, Kirsch M. Intraoperative mapping of the sensory cortex by time-resolved thermal imaging. *Biomed Tech (Berl)* 2018;63:567–72. <https://doi.org/10.1515/bmt-2017-0229>.
- [62] Shevelev IA, Tscicalov EN, Gorbach AM, Budko KP, Sharaev GA. Thermoimaging of the brain. *J Neurosci Methods* 1993;46:49–57. [https://doi.org/10.1016/0165-0270\(93\)90140-m](https://doi.org/10.1016/0165-0270(93)90140-m).
- [63] Kateb B, Yamamoto V, Yu C, Grundfest W, Gruen JP. Infrared thermal imaging: A review of the literature and case report. *NeuroImage* 2009;47:T154–62. <https://doi.org/10.1016/j.neuroimage.2009.03.043>.
- [64] Müller J, Schreiter V, Böhl E, Steiner G, Koch E, Schackert G, et al. Application of thermography for cerebral perfusion imaging during aneurysm surgery. *Current Directions in Biomedical Engineering* 2018;4:29–32. <https://doi.org/10.1515/cdbme-2018-0008>.
- [65] Hwang PYK, Lewis PM, Maller JJ. Use of intracranial and ocular thermography before and after arteriovenous malformation excision. *J Biomed Opt* 2014;19:110503. <https://doi.org/10.1117/1.JBO.19.11.110503>.
- [66] Suzuki T, Oishi N, Fukuyama H. Simultaneous infrared thermal imaging and laser speckle imaging of brain temperature and cerebral blood flow in rats. *J Biomed Opt* 2018;24:1–11. <https://doi.org/10.1117/1.JBO.24.3.031014>.
- [67] Pham T, Tgavalekos K, Sassaroli A, Blaney G, Fantini S. Quantitative measurements of cerebral blood flow with near-infrared spectroscopy. *Biomed Opt Express* 2019;10:2117–34. <https://doi.org/10.1364/BOE.10.002117>.
- [68] Baker WB, Balu R, He L, Kavuri VC, Busch DR, Amendolia O, et al. Continuous non-invasive optical monitoring of cerebral blood flow and oxidative metabolism after acute brain injury. *J Cereb Blood Flow Metab* 2019;39:1469–85. <https://doi.org/10.1177/0271678X19846657>.

- [69] Fukuda M, Takao T, Hiraishi T, Aoki H, Ogura R, Sato Y, et al. Cortico-cortical activity between the primary and supplementary motor cortex: An intraoperative near-infrared spectroscopy study. *Surg Neurol Int* 2015;6:44. <https://doi.org/10.4103/2152-7806.153872>.
- [70] Sato K, Fukuda M, Sato Y, Hiraishi T, Takao T, Fujii Y. Cortico-cortical evoked hemodynamic responses in human language systems using intraoperative near-infrared spectroscopy during direct cortical stimulation. *Neuroscience Letters* 2016;630:136–40. <https://doi.org/10.1016/j.neulet.2016.07.037>.
- [71] Qiu T, Hameed NUF, Peng Y, Wang S, Wu J, Zhou L. Functional near-infrared spectroscopy for intraoperative brain mapping. *NPh* 2019;6:045010. <https://doi.org/10.1117/1.NPh.6.4.045010>.
- [72] Ulmer S. Intraoperative perfusion magnetic resonance imaging: Cutting-edge improvement in neurosurgical procedures. *World J Radiol* 2014;6:538–43. <https://doi.org/10.4329/wjr.v6.i8.538>.
- [73] Roder C, Charyasz-Leks E, Breitkopf M, Decker K, Ernemann U, Klose U, et al. Resting-state functional MRI in an intraoperative MRI setting: proof of feasibility and correlation to clinical outcome of patients. *J Neurosurg* 2016;125:401–9. <https://doi.org/10.3171/2015.7.JNS15617>.
- [74] Stadlbauer A, Merkel A, Zimmermann M, Sommer B, Buchfelder M, Meyer-Bäse A, et al. Intraoperative Magnetic Resonance Imaging of Cerebral Oxygen Metabolism During Resection of Brain Lesions. *World Neurosurg* 2017;100:388–94. <https://doi.org/10.1016/j.wneu.2017.01.060>.
- [75] Fierstra J, Burkhardt J-K, van Niftrik CHB, Piccirelli M, Pangalu A, Kocian R, et al. Blood oxygen-level dependent functional assessment of cerebrovascular reactivity: Feasibility for intraoperative 3 Tesla MRI. *Magn Reson Med* 2017;77:806–13. <https://doi.org/10.1002/mrm.26135>.
- [76] Muscas G, Bas van Niftrik CH, Fierstra J, Piccirelli M, Sebök M, Burkhardt J-K, et al. Feasibility and safety of intraoperative BOLD functional MRI cerebrovascular reactivity to evaluate extracranial-to-intracranial bypass efficacy. *Neurosurg Focus* 2019;46:E7. <https://doi.org/10.3171/2018.11.FOCUS18502>.
- [77] Hsu Y-Y, Chang C-N, Jung S-M, Lim K-E, Huang J-C, Fang S-Y, et al. Blood oxygenation level-dependent MRI of cerebral gliomas during breath holding. *J Magn Reson Imaging* 2004;19:160–7. <https://doi.org/10.1002/jmri.10447>.
- [78] Belykh E, Miller EJ, Carotenuto A, Patel AA, Cavallo C, Martirosyan NL, et al. Progress in Confocal Laser Endomicroscopy for Neurosurgery and Technical Nuances for Brain Tumor Imaging With Fluorescein. *Front Oncol* 2019;9. <https://doi.org/10.3389/fonc.2019.00554>.
- [79] Belykh E, Cavallo C, Zhao X, Lawton MT, Nakaji P, Preul MC. 312 Intraoperative Imaging of Cerebral Vasculature and Blood Flow Using Confocal Laser Endomicroscopy: New Perspectives in Precise Real-Time Brain Fluorescence Microimaging. *Neurosurgery* 2018;65:126–7. <https://doi.org/10.1093/neuros/nyy303.312>.
- [80] Shih AY, Driscoll JD, Drew PJ, Nishimura N, Schaffer CB, Kleinfeld D. Two-photon microscopy as a tool to study blood flow and neurovascular coupling in the rodent brain. *J Cereb Blood Flow Metab* 2012;32:1277–309. <https://doi.org/10.1038/jcbfm.2011.196>.
- [81] Gruber A, Dorfer C, Standhardt H, Bavinzski G, Knosp E. Prospective comparison of

intraoperative vascular monitoring technologies during cerebral aneurysm surgery. *Neurosurgery* 2011;68:657–73; discussion 673. <https://doi.org/10.1227/NEU.0b013e31820777ee>.

[82] Prada F, Perin A, Martegani A, Aiani L, Solbiati L, Lamperti M, et al. Intraoperative contrast-enhanced ultrasound for brain tumor surgery. *Neurosurgery* 2014;74:542–52; discussion 552. <https://doi.org/10.1227/NEU.0000000000000301>.

[83] Soloukey S, Vincent AJPE, Satoer DD, Mastik F, Smits M, Dirven CMF, et al. Functional Ultrasound (fUS) During Awake Brain Surgery: The Clinical Potential of Intra-Operative Functional and Vascular Brain Mapping. *Front Neurosci* 2020;13. <https://doi.org/10.3389/fnins.2019.01384>.

[84] Deffieux T, Demene C, Pernot M, Tanter M. Functional ultrasound neuroimaging: a review of the preclinical and clinical state of the art. *Curr Opin Neurobiol* 2018;50:128–35. <https://doi.org/10.1016/j.conb.2018.02.001>.

TABLES

Table 1: Characteristics of main contemporary technologies for the intraoperative cerebral blood flow imaging in neurosurgery.

FIGURES

Figure 1: Flow chart of literature search strategy

Figure 2: Laser Doppler Flowmetry. An incident photons source produces a laser light beam that infiltrates approximately 1 mm³ of brain cortex. Mobile (erythrocytes, leucocytes, etc....) and immobile (neurons, glial cells, etc....) structures scatter the incident photons resulting in a Doppler shift and an electrical signal reflecting both velocity and density of erythrocytes.

Figure 3: Laser speckle cell imaging. A coherent laser beam illuminates the most superficial heterogeneous layer of the brain cortex up to 300 µm resulting in an irregular backscattering of the light. A CCD camera, possibly integrated in the operative microscope, detects the ensuing random speckle pattern which is variable with erythrocytes' movements.

Figure 4: Example of intraoperative laser speckle cell imaging during brain glioma removal with a surgical microscope integrated LSCI device (Omegazone OZ-3, Omegawave Inc.). The difference in CBF can be measured between 2 ROIs (ROI1 corresponds to normal brain tissue, ROI2 corresponds to tumoral brain tissue). (Courtesy of Dr Jun Muto, Fujita Health University)

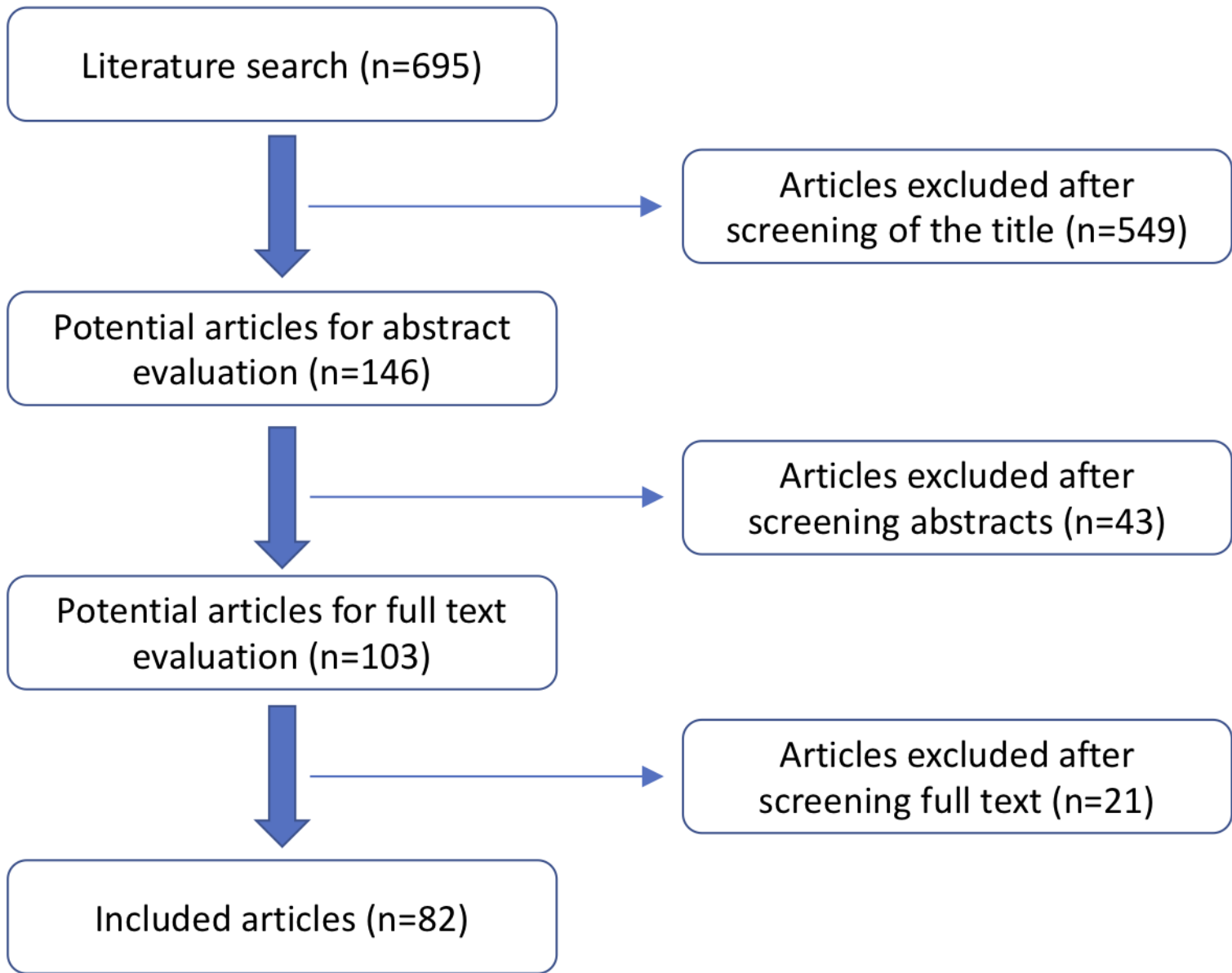
Figure 5: Sidestream dark field imaging. A stroboscopic green light (530 to 548 nm) illuminates the cortical surface up to 500 μm . This specific wavelength light is exclusively absorbed by erythrocytes and results in the display of the black vascular network in a gray background.

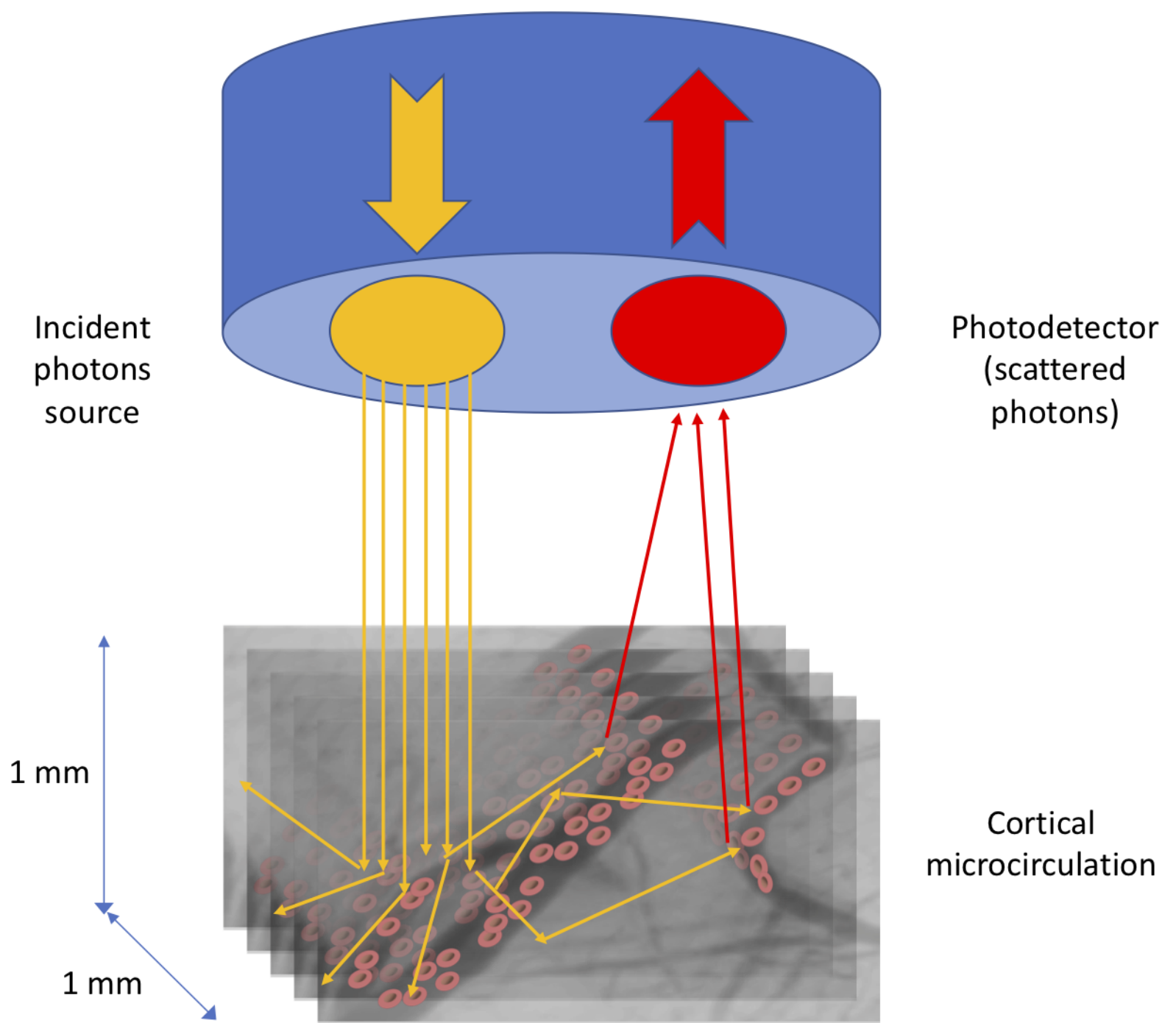
Figures 6: Sidestream dark field imaging. The development of a hand-held device and a real-time image analysis ease its use intra-operatively (Figure 6a) (Courtesy of MicroscanTM, Microvision Medical, Amsterdam, The Netherlands). Example of cortical SDF imaging showing the flow of erythrocytes (Figure 6b).

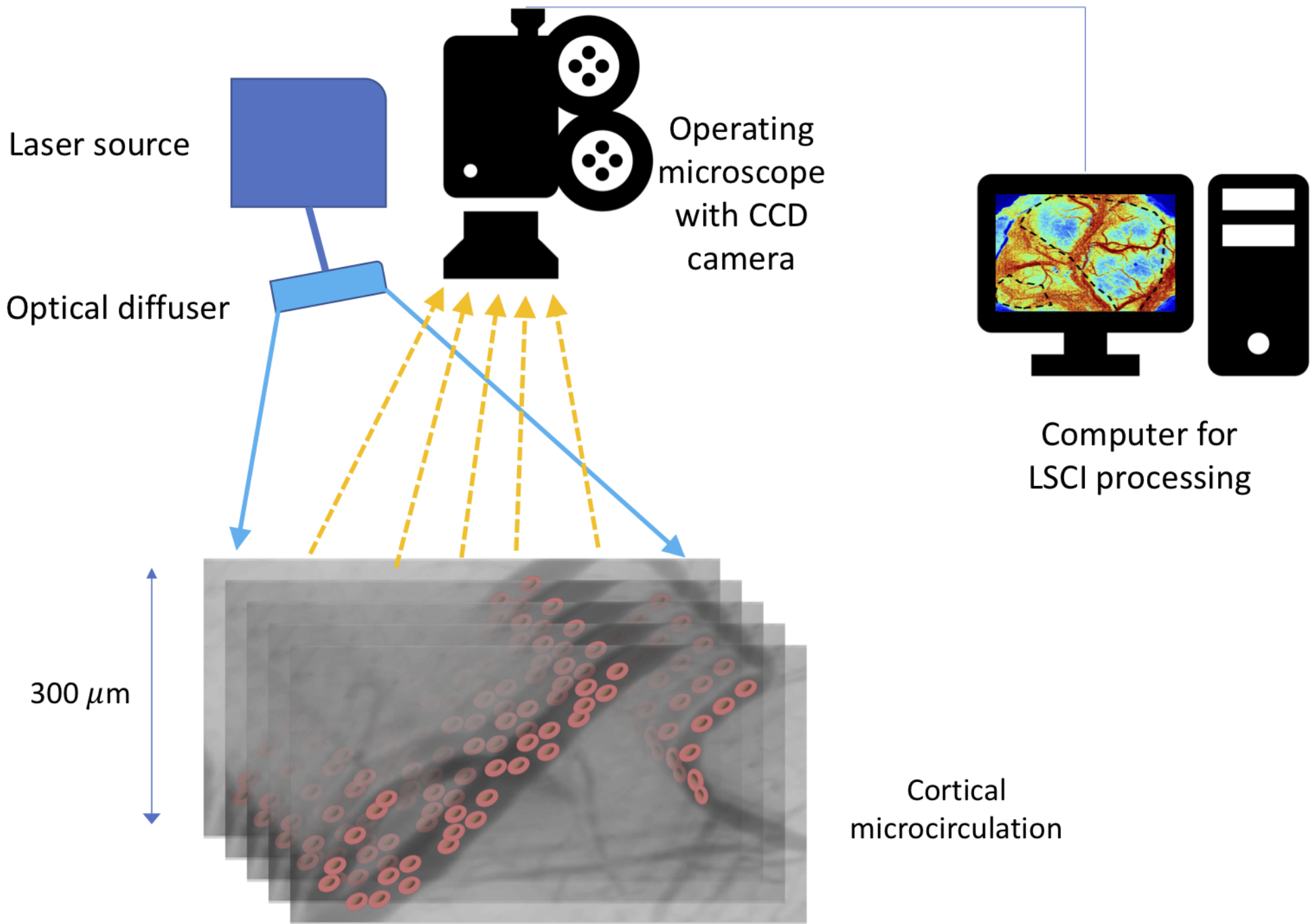
Figure 7: Indocyanine green video angiography (ICG-VA). Right middle cerebral artery aneurysm previously coiled presenting with a significant recurrence at his neck and treated surgically by clipping (Figure 7a). Intraoperative ICG-VA confirms the absence of aneurysmal sac residue and the qualitative preservation of the flow in the parent vessel and its branches (Figure 7b).

Figure 8: Example of an intraoperative BOLD-CVR study of a patient with a left-sided carotid occlusion that underwent EC-IC bypass revascularization. The BOLD-CVR image is depicted in an axial orientation with color-coding of the CVR values (ranging from red - normal/positive CVR- towards blue -impaired/negative CVR-). One can appreciate that already on this intraoperative study immediately after bypass anastomosis, CVR improvement in the left hemisphere as well as the contralateral hemisphere can be seen (yellow and red areas). BOLD-CVR is calculated as $\% \text{BOLD signal change} / \text{mmHg change in CO}_2$.

Figure 9: Comparative overview of cerebral blood flow monitoring technologies focusing on depth of analysis, spatial and temporal resolutions, integration to the surgical workflow and possibility of quantitative measurements.







GAIN

B/W

Color

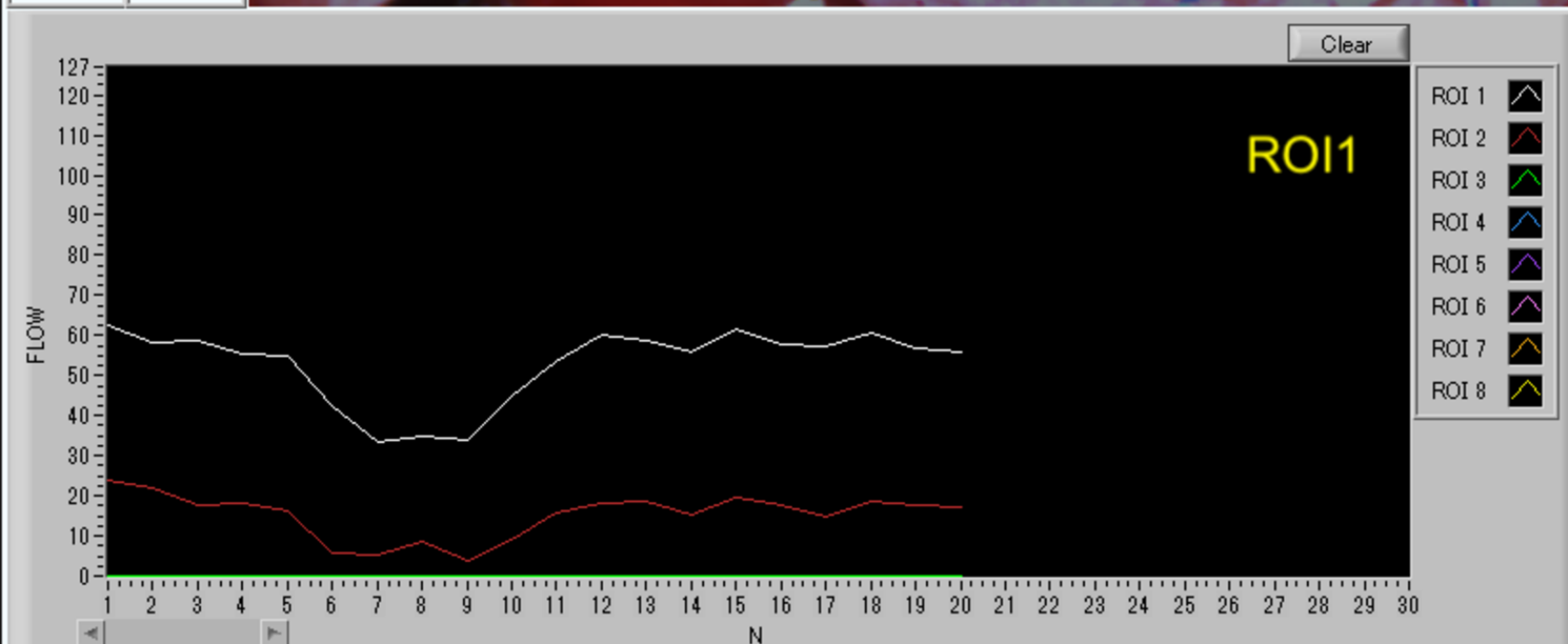
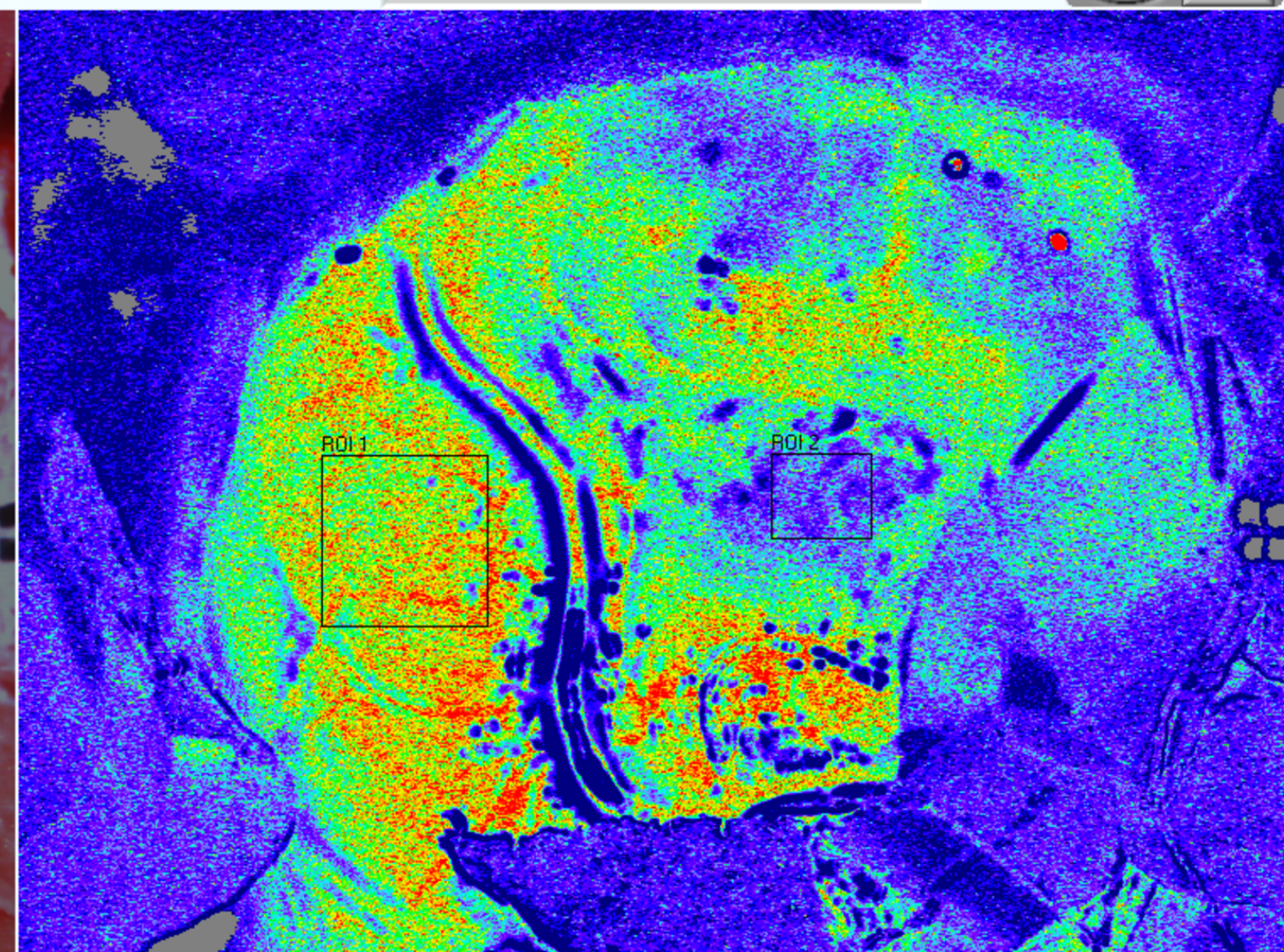
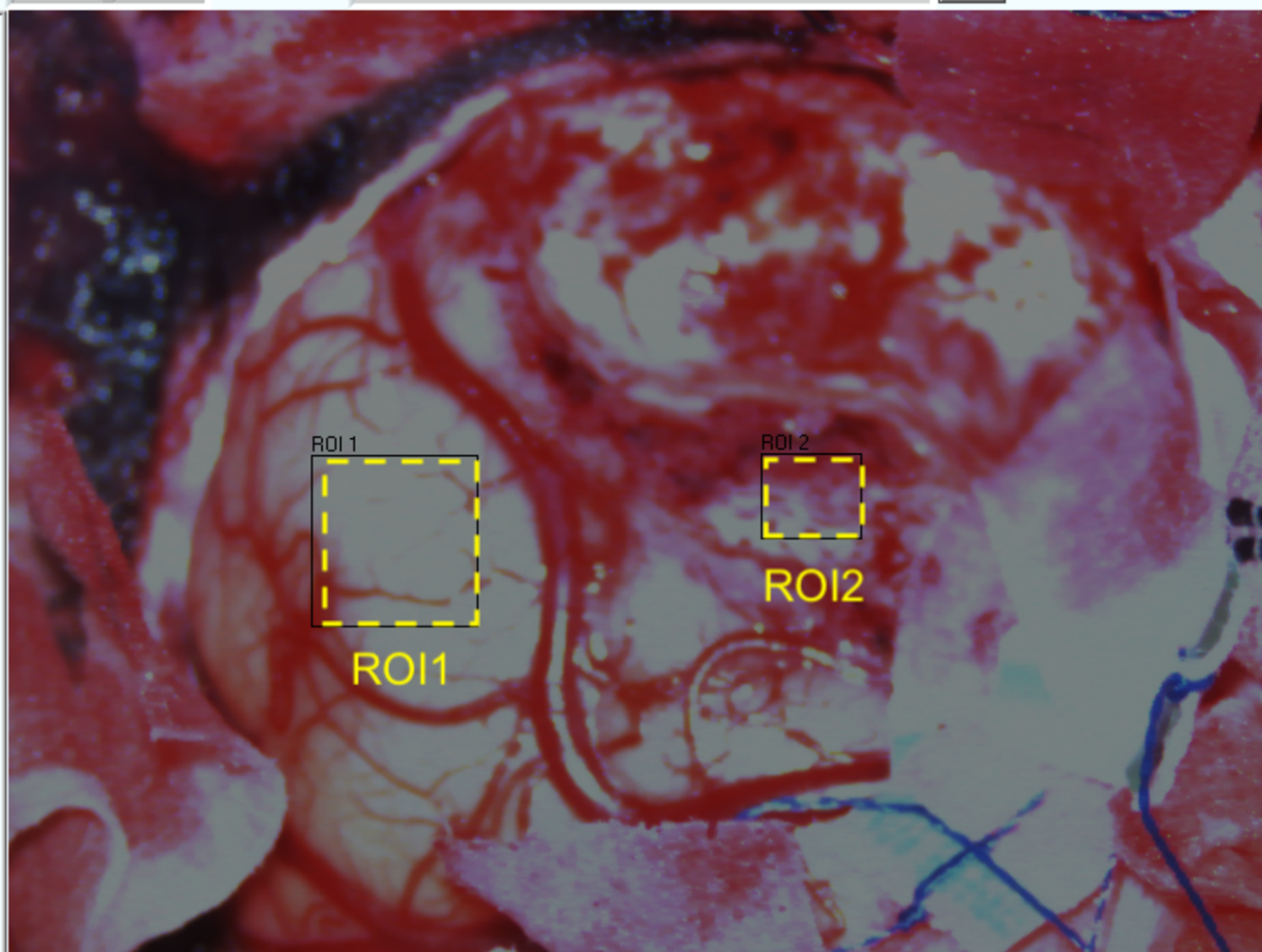
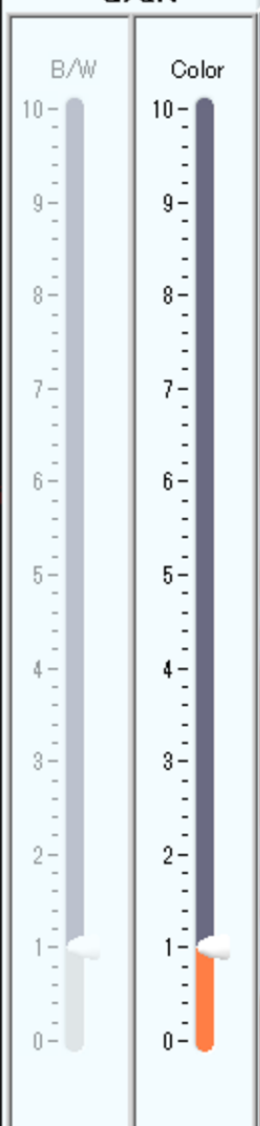
Real Image : Image HR Color R1T*14026No00001.tif

Blood Flow Image : Image HR BF R1T*14026No00001.tif

Display

Marker

95



Clear

ROI No: ROI 2

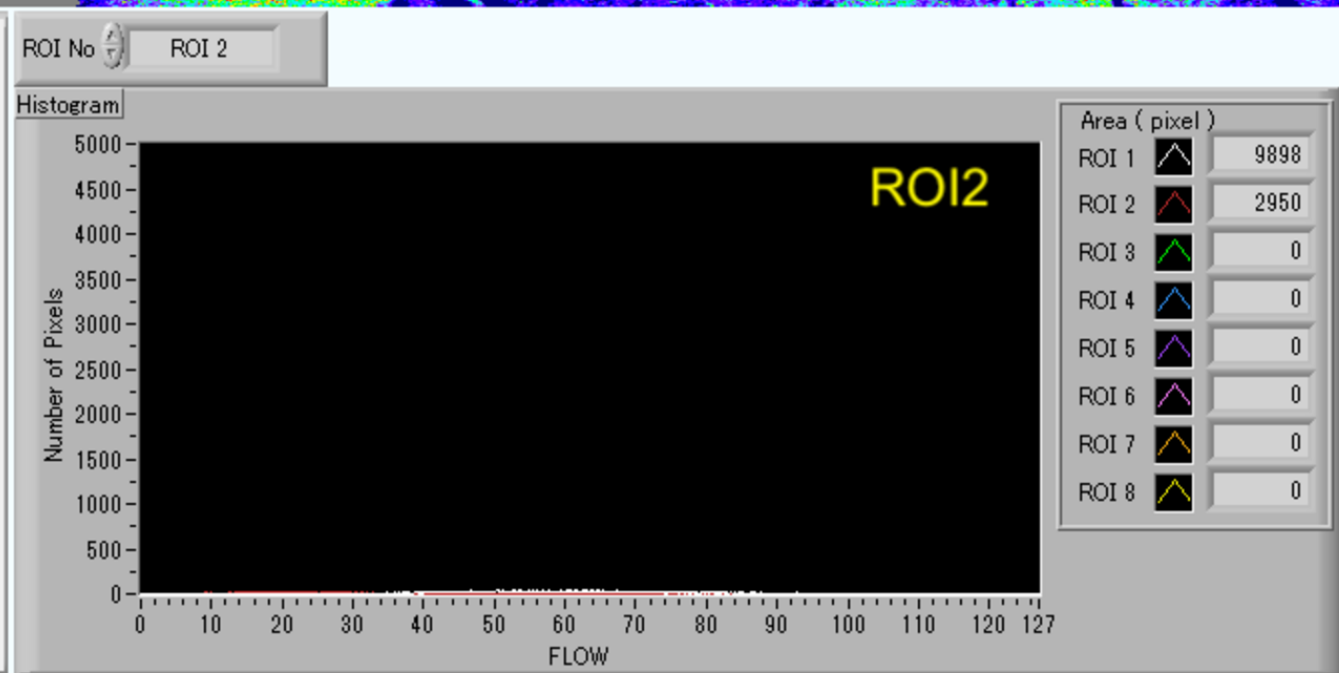
102
16-bit image

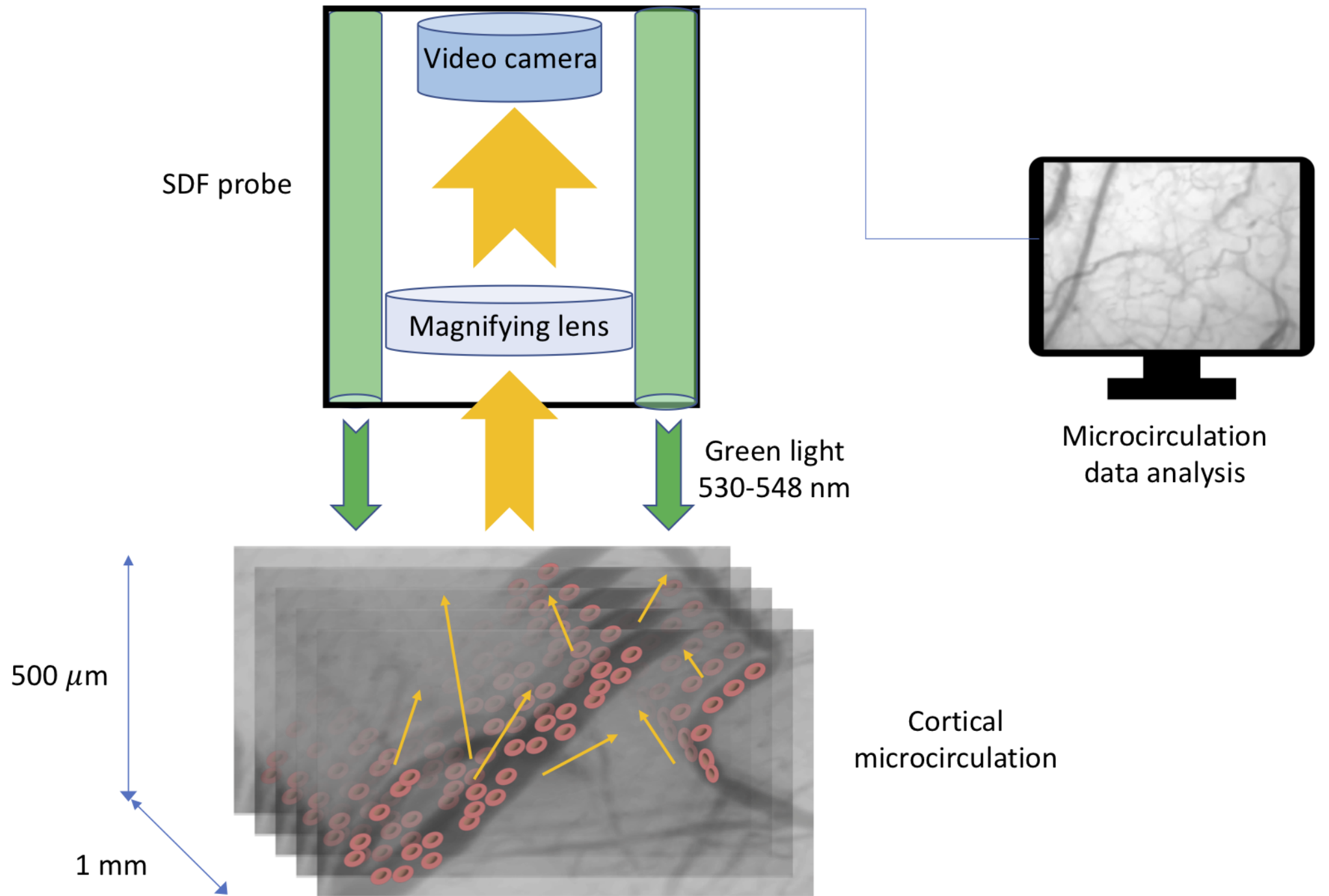
X: 547
Y: 273

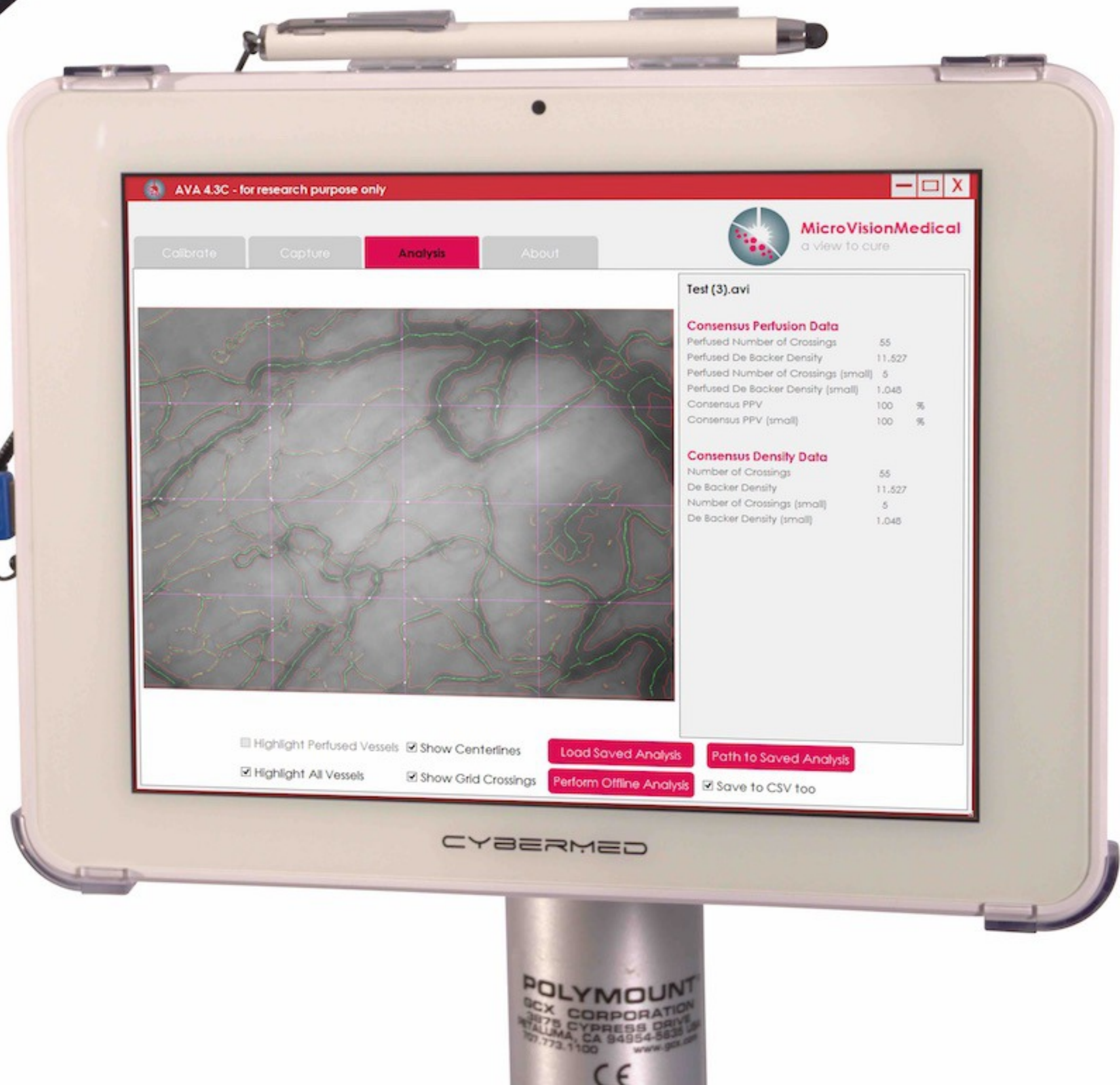X: 0
Y: 0

X: 0
Y: 0

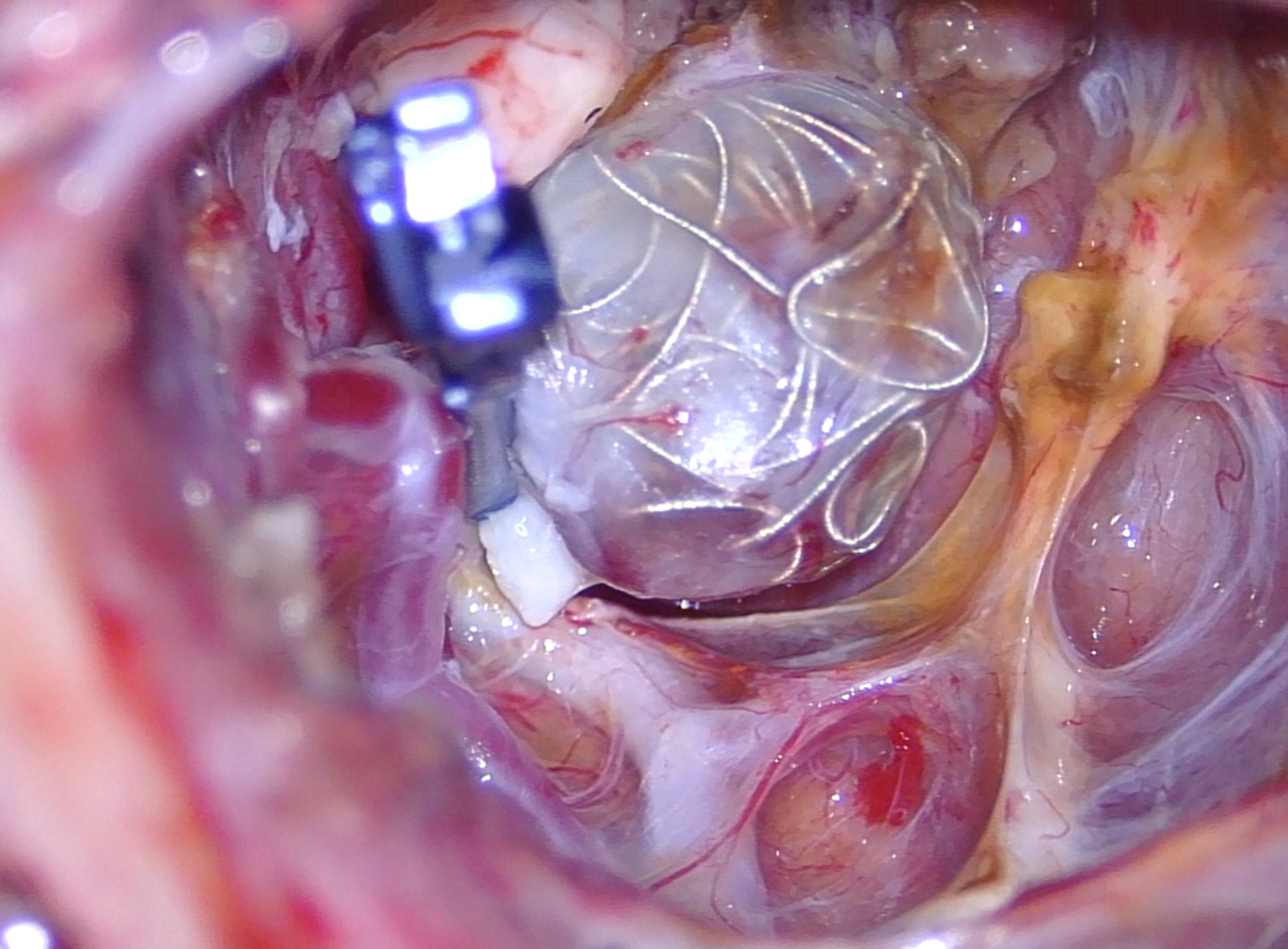
Length: 0
Angle: 0

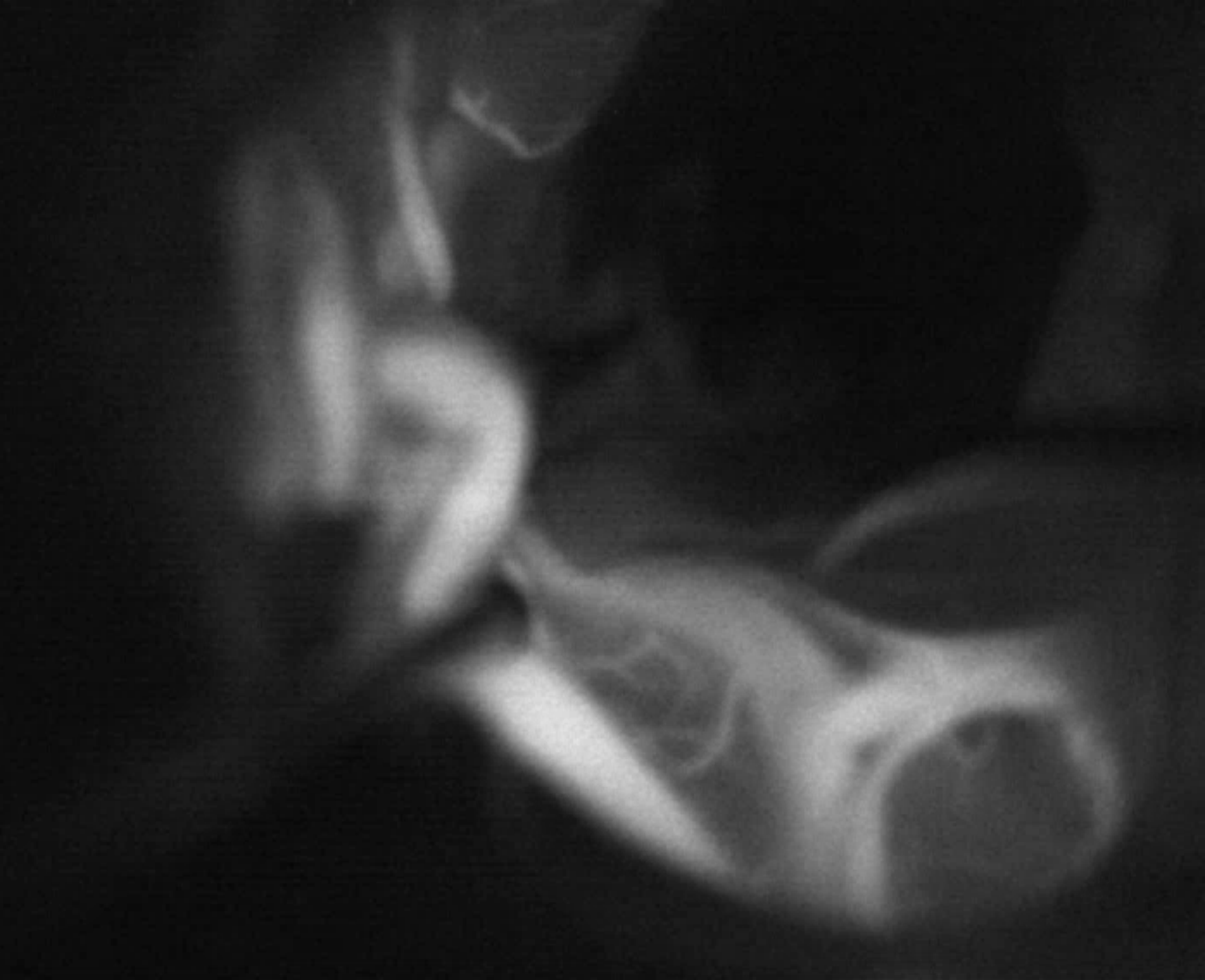



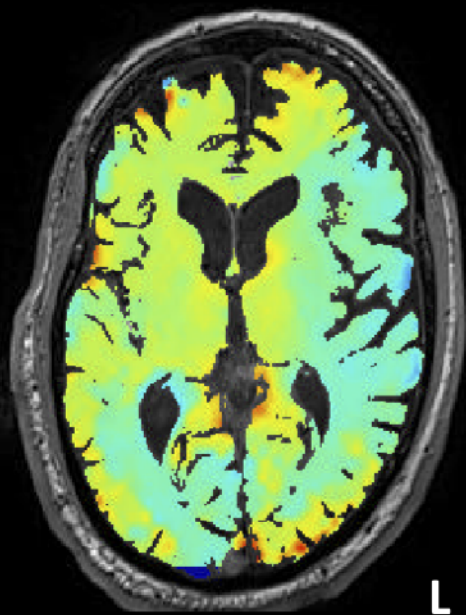




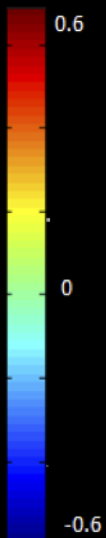
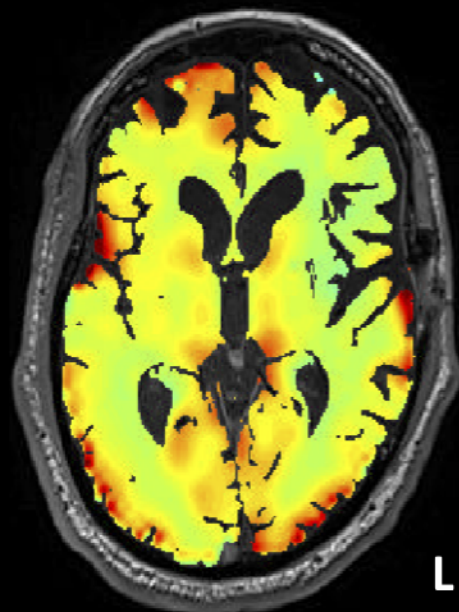




Preoperative



Intraoperative (after EC-IC bypass)

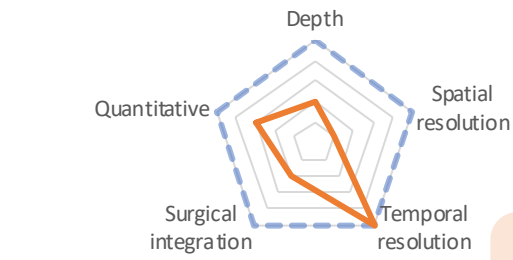




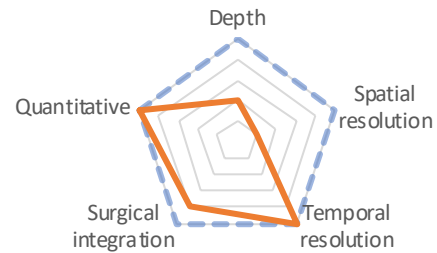
Research

Vascular surgery

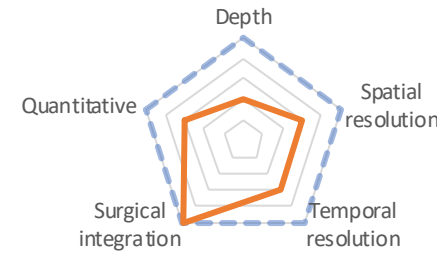
Tumor surgery



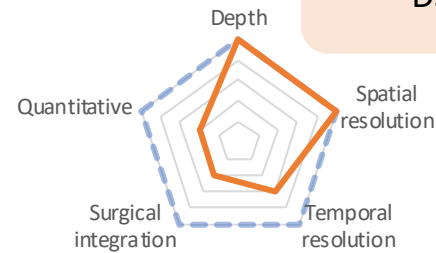
Laser Doppler flowmetry



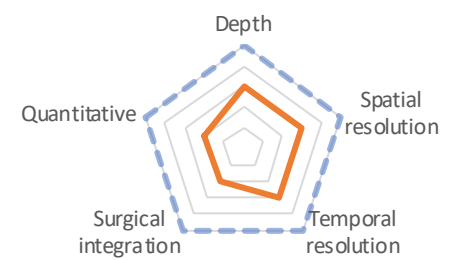
Microvascular doppler ultrasound



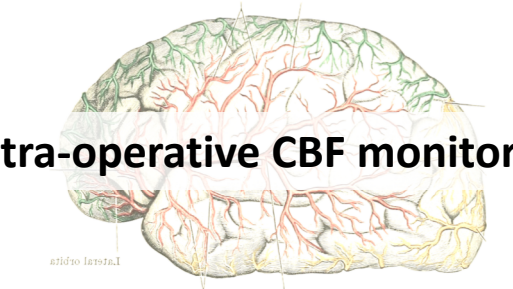
Indocyanine green video angiography



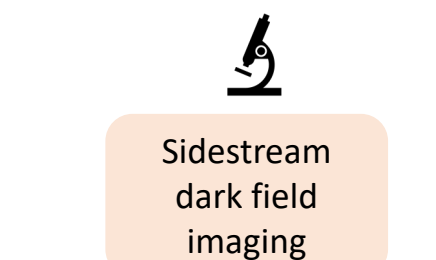Intra-operative DSA



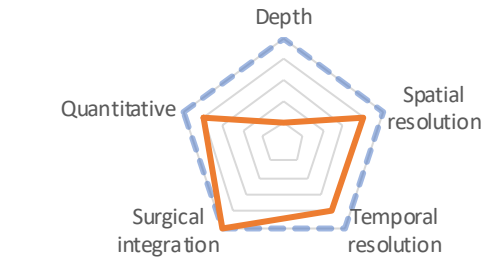
Thermal imaging



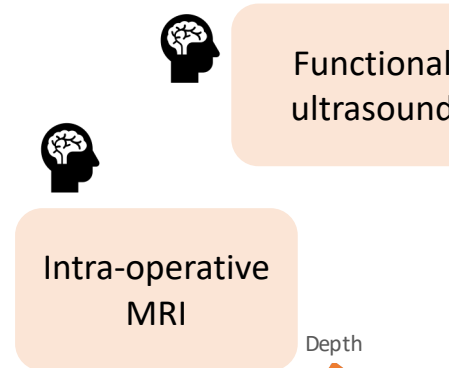
Intra-operative CBF monitoring



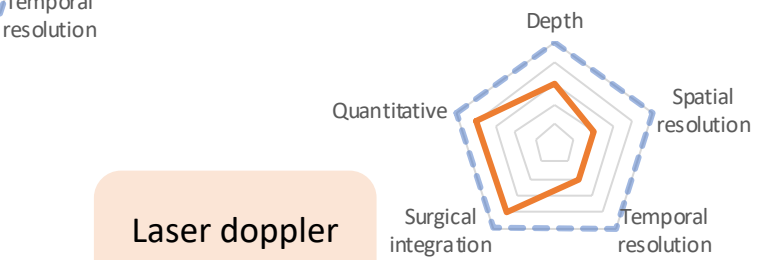
Sidestream dark field imaging



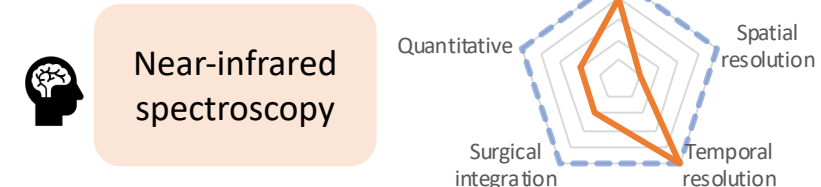
Laser speckle contrast imaging



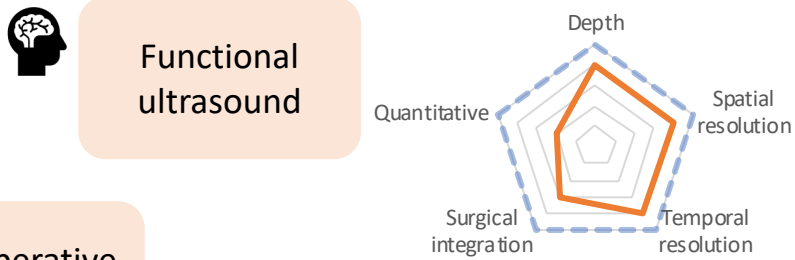
Intra-operative MRI



Laser Doppler imaging



Near-infrared spectroscopy



Functional ultrasound

| | Laser Doppler technologies | | LSCI | SDF | ICG-VA | Thermal imaging | NIRS |
|--|----------------------------|--|--|--|-------------------------------------|---|---|
| | LDF | LDI | | | | | |
| Depth analysis | 500 μ m | 1-1.5 mm | 530 μ m | 300 μ m | \leq 1mm | \leq 1mm | 30 mm |
| Contact with the brain | Yes | No | Yes | No | No | No | Yes |
| Spatial resolution | - | + | - | ++ | + | + | - |
| Temporal resolution | ++ | - | + | ++ | + | + | ++ |
| Possibility of continuous intraoperative monitoring | Yes | No | No | No | No | No | No |
| Integration in the surgical microscope | - | + | - | ++ | - | ++ | - |
| Type of analysis | Relative CBF measurements | Color coded map with relative CBF measurements | No CBF measurement Microcirculation parameters: vessel density, flow pattern, | Color coded map with relative CBF measurements | Indirect estimation of relative CBF | Morphological analysis of the vasculature Color coded map with relative CBF measurements | Indirect estimation of relative CBF (measurement of Hb concentration) |

| | | | | | | | |
|---|--|--|--|---|---|--|---------------|
| | | | perfused vessels, vessel diameter | | | | |
| Applications in neurosurgery | Peri-nidal monitoring in brain AVMs Detection of CSD Optimization of deep brain electrodes placement and brain biopsies | Brain mapping | Peri-nidal monitoring during AVM surgery Monitoring during decompressive craniectomy for stroke and brain injury Monitoring during aneurysm surgery | Monitoring of CBF during revascularization surgery Identification of feeding arteries during tumor or AVM surgery Brain mapping Detection of CSD | Brain tumor identification Brain mapping Vascular neurosurgery | Vascular neurosurgery (Aneurysm clipping, patency of bypass and identification of optimal recipient artery, AVM resection) Hemangioblastoma surgery | Brain mapping |
| Technical variants | Possibility of intra- parenchymal probe | Combination with spectrophotometry ("oxygen-to-see" probe) to provide concomitant metabolic monitoring | Recently developed incident dark field imaging may provide a better image resolution | Multi-exposure speckle imaging (MESI) for better quantitative accuracy | Possibility to use an intravenous bolus of cold saline as a contrast agent | | |

Table 1. Characteristics of main contemporary technologies for the intraoperative cerebral blood flow imaging in neurosurgery.

LDF: Laser Doppler flowmeter, LDI: Laser Doppler imaging, CSD: Cortical spreading depolarization, LSCI: Laser speckle-contrast imaging, SDF: Sidestream dark field, ICG-VA: Indocyanine green video angiography, NIRS: Near-infrared spectroscopy, AVM: arteriovenous malformation

Poor : -

Good : +

Excellent : ++