



HAL
open science

Coexisting Diastematomyelia, Tethered Spinal Cord, Syringomyelia and Filum Terminale Lipoma in a Child with Preceding Meningomyelocele and Hydrocephalus

Parul Gupta

► **To cite this version:**

Parul Gupta. Coexisting Diastematomyelia, Tethered Spinal Cord, Syringomyelia and Filum Terminale Lipoma in a Child with Preceding Meningomyelocele and Hydrocephalus. *International Journal of Neurology and Neurosurgery*, 2024, 16 (1-2), pp.23-27. <10.21088/ijnn.0975.0223.161224.3>. <hal-04788550>

HAL Id: hal-04788550

<https://hal.science/hal-04788550v1>

Submitted on 18 Nov 2024

HAL is a multi-disciplinary open access archive for the deposit and dissemination of scientific research documents, whether they are published or not. The documents may come from teaching and research institutions in France or abroad, or from public or private research centers.

L'archive ouverte pluridisciplinaire **HAL**, est destinée au dépôt et à la diffusion de documents scientifiques de niveau recherche, publiés ou non, émanant des établissements d'enseignement et de recherche français ou étrangers, des laboratoires publics ou privés.



HAL Authorization

Coexisting Diastematomyelia, Tethered Spinal Cord, Syringomyelia and Filum Terminale Lipoma in a Child with Preceding Meningomyelocele and Hydrocephalus

Parul Gupta

How to cite this article:

Parul Gupta. Coexisting Diastematomyelia, Tethered Spinal Cord, Syringomyelia and Filum Terminale Lipoma in a Child with Preceding Meningomyelocele and Hydrocephalus. International Journal of Neurology and Neurosurgery. 2024;16(1-2):23-27.

Abstract

Background: This case report shows co-occurrence of diastematomyelia, tethered spinal cord, syringomyelia and filum terminale lipoma in a follow up case of meningomyelocele repair and hydrocephalus, which are rarely known to co-exist in a great frequency.

Methods: We present a 5-year-old girl who, four years after meningomyelocele repair, developed bilateral lower limb weakness. Her filum terminale lipoma was sectioned, and the spinal cord was untethered.

Results: She recovered well from surgery and experienced no neurological impairment.

Conclusion: Thus, this case report aims to show the presence of primary and secondary neurulation defects in the same individual and the approach to its management.

Keywords: Diastematomyelia; Filum terminale lipoma; Meningomyelocele; Spinal dysraphism; Syringomyelia; Tethered cord syndrome.

INTRODUCTION

Spinal dysraphism is a congenital condition that impacts the spinal cord, nerve roots, &

bony structure. The most prevalent abnormality of spinal dysraphism, meningomyelocele (MMC), has garnered attention from pediatric neurosurgeons and is documented in the literature.¹²

Amongst Occult Spinal Dysraphisms (OSD) types, there are significant differences in the natural history, neurological deterioration mechanisms, and surgical complexity. Without a mass, OSD can include split cord malformations, caudal regression, dermal sinuses, bony spina bifida, spinal segmental dysgenesis, tight filum terminale, filar and intradural lipomas, and persistent terminal ventricle.³ It can also include a complete dorsal enteric fistula or a neurenteric cyst.

Primary neurulation defects include disjunction, or the division of the neural from cutaneous ectoderm, and myelomeningocele, or the failure of neural tube closure.²

Author Affiliation: MCh Resident, Department of Neurosurgery, Christian Medical College & Hospital, Ludhiana 141008, Punjab, India.

Corresponding Author: Parul Gupta, MCh Resident, Department of Neurosurgery, Christian Medical College & Hospital, Ludhiana 141008, Punjab, India.

E-mail: docparul1411@gmail.com

Received on: 21.08.2024

Accepted on: 05.10.2024



During secondary neurulation, the conus medullaris, filum terminale, and cauda equina of the terminal spinal cord form. The most prevalent and mildest secondary neurulation anomaly is the thickened or fatty filum terminale, whereas the caudal lumbosacral lipoma is a more complicated condition.²

Nevertheless, there are very few reports of MMC and diastematomyelia, also known as split cord malformation (SCM), together in one person in the literature currently in publication. The current body of literature does not describe the clinical profile, course of treatment, or outcome of such cases. Having both SCM and MMC is most likely a sign of a defect during the development during 3rd and 4th week of embryogenesis.^{12,13}

When the MMC is repaired, scar tissue forms around the damaged nerves, which can lead to Tethered Cord Syndrome (TCS), a progressive neurological degeneration that affects only the lower spinal cord due to traction and is often linked to OSD.

In this instance, we discuss a child aged five who had hydrocephalus due to a meningocele of the lumbar region at birth and underwent MMC closure surgery for VP shunting and MMC closure. Later, when she developed bilateral lower limb weakness that worsened over time, a radiological examination of the entire neuroaxis revealed additional OSD and the tethered cord syndrome diagnosis (TCS).

Although they make up only 3.8–5% of all spinal abnormalities that are congenital, diastematomyelia can cause up to 25% of cases of OSD.¹ Based on radiography, only 10–30% cases of repaired MMC have a tethered cord, which would develop signs or symptoms⁴, as was in our case. Tethering can result from a thickened terminal filum or from dorsal tethering bands between the hemi cords and dura.¹⁰

In this case report, we describe the rare co-occurrence of the SCM and MMC in the same individual and its clinical presentation and treatment approach. The TCS in this case may be attributed to the additional finding of filum terminale lipoma. Consequently, the peculiarity of having defects in both primary and secondary neurulation simultaneously have been discussed.

CASE DESCRIPTION

Clinical Presentation

A 5-year-old female presented with chief complaints of gradually increasing weakness of

bilateral lower limbs since birth and deformity in bilateral lower limbs. She was born at 8 months of gestational age, with a cystic lesion at the lumbar region and was diagnosed as a case of Myelomeningocele with Hydrocephalus. Myelomeningocele repair in the region of L2-L4 and right sided ventriculoperitoneal shunting was done at 2 months of age (outside our centre). There were no bowel or bladder complaints or any complaints of headache/seizure/vomiting. There was no reliable history of antenatal intake of iron/folic Acid by the mother.

Diagnostic assessment

The child was moderately built, conscious and oriented to time, place and person. The developmental milestones were normal for age. On physical examination she had a midline horizontal scar of previous surgery over the dorso-lumbar spine. There was no evidence of any scoliotic deformity or any other cutaneous stigmata over the spine. Examination of lower extremities was suggestive of bilateral equinovarus deformity. Neurologic exam revealed she had Power 5/5 in bilateral upper limbs, hips and knees, but had Power 3+/5 in Ankle dorsiflexion and plantar flexion. Sensation was intact in all dermatomes. Ankle jerk was exaggerated bilaterally.

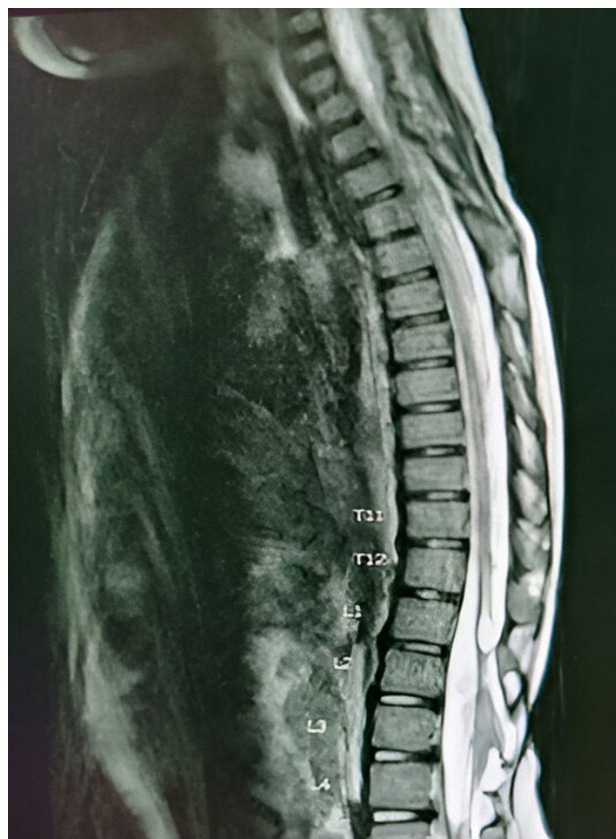

Fig. 1: MRI whole spine sagittal view

Radiological Assessment

A spinal MRI detected a conus that is positioned lower than normal and intramedullary T2 hyperintensity (hydrosyringomyelia) rostrally to the surface of the tethered cord. According to (Fig. 1), the conus tip was at L5 level. Axial section also revealed type II Split cord malformation in the dorso-lumbar region. In the region of the tethered cord (L3-L4), posterior bulging of thecal sac and adherence of neural tissue with posterior dura was noted on T2 weighted images. CT lumbar spine showed bony defects at the posterior element of the spine (from L1-L5).

The results of her blood work and post-voidal ultrasonography were normal and did not show any significant findings.

Therapeutic intervention

Patient was operated in prone position, under general anaesthesia. The surgical steps for sectioning of filum terminale lipoma were as

follows-A midline skin incision was made using aseptic precautions, matching the position of the conus at the junction with the filum terminal, or L4-5 level. Then the spinous processes and laminae were separated from the paraspinal muscles. A laminectomy was performed on L4, L5, and the dura was visible. An L4-L5 midline durotomy was performed. Filum terminale was identified under an operating microscope, extending from the most caudal coccygeal nerve root caudally. It was possible to distinguish the filum terminale lipoma from the nearby nerves (Fig. 2). The filum terminale lipoma was carefully resected. (Fig. 3). Asking the anesthetist to perform a Valsalva maneuver verified that the L4-L5 dura was closed water-tightly after inspection of the nerve roots. For approaching to the tethered segment, L2-L3-L4 laminectomy was done and then at the dorsal L2-3-4 dura, tethered cord was visualised. Detethering of nerve roots and dura mater was done meticulously. Dural closure was done, followed by the muscle, fascia, and skin.

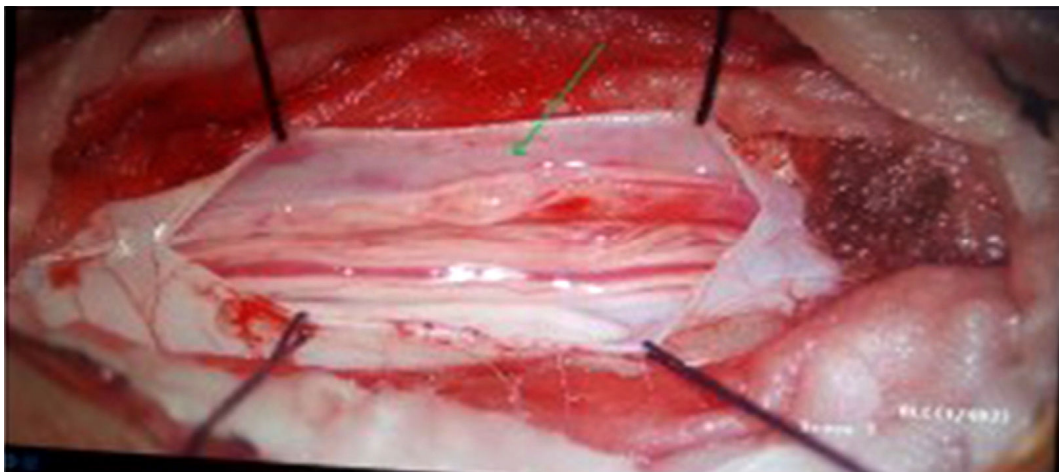


Fig. 2: filum terminale lipoma (green arrow, intra-op)

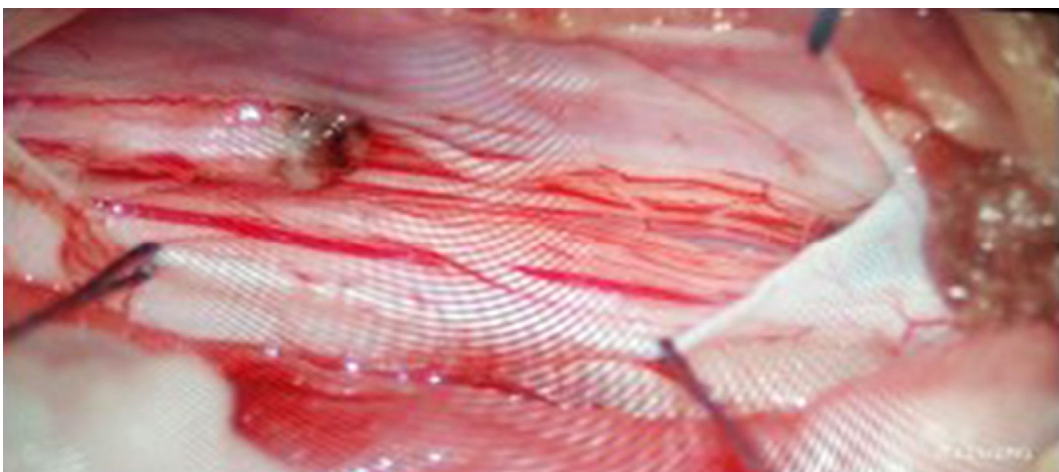

Fig. 3: Filum terminale stump post lipoma resection

Outcome and follow-up

Post operatively, the patient was managed with antibiotics and analgesics. Recovery was uneventful. Patient was discharged on postoperative day 4. In the immediate postoperative period, power in the lower limbs was similar to the preoperative status (3+/5) in bilateral lower limbs. No bladder/bowel abnormality was noted post operatively. At postoperative follow up at 1 month, Power of bilateral lower limbs was noted to be 4+/5. Patient is now ambulant at home with minimal support and following up with Orthopaedics is following up with the patient for bilateral equinovarus deformity correction. Financial considerations prevented the ordering of a postoperative MRI.

DISCUSSION

The traditional MMC repair method involves removing the zona epitheliosa in order to separate the placode, then closing it with a pial suture to encourage tunelization. Next, the normal skin is closed and the dura is exposed on the side. It is then stitched to cover the tunelized placode. Because the placode is attached to the structures around it, the conus medullaris of MMC patients is usually below the normal level at birth, at L1 or L2. This attachment can cause the spinal cord to stretch during childhood growth, and in 30 percent of patients on average, symptoms arise.¹¹

Syringomyelia may be associated with tethered cords, though these are less common in cases of occult spinal dysraphism than in cases of open neural tube defects.⁷ The filum terminale lipoma was taken out without the syrinx being emptied so that the spinal cord could be freed. Getting rid of the tethered segment has been shown to help syringomyelia.⁷

Numerous anomalies have a correlation with SCM. MMC, lipomas, teratomas, and neuroenteric cysts are common associations.⁸ We and others have reported that the dorsolumbar and lumbar areas are the common sites of SCM.¹⁰ Coexisting anomalies, or the relationship between MMC and SCM, are known to occur; various researchers have reported that this association occurs between 5 and 36% of the time.^{9,6} The presence of anomalies suggests a shared embryogenesis, as reported by Pang *et al.*⁹

However, it is crucial to diagnose fatty filum and/or filum terminale lipoma as a cause of tethering in a pt with already diagnosed SCM, in order to provide the right care, as they are entirely

distinct clinical entities and are assumed to result from distinct pathophysiologies.⁵

Untethering the cord from a tight filum terminale, occult spinal dysraphism, and split cord malformation resulted in improved neurologic, urologic, and deformity outcomes.¹⁴ Based on the other reports, the patient did not experience any neurological or urodynamic issues following the surgery.

CONCLUSION

Symptomatic retethering is a known complication in children with meningocele repair. Early detection and release of the tethered cord can stabilise or reverse neurological dysfunction. The above case report shows a relatively rare combination of primary neurulation defects (meningocele, diastematomyelia), its complication (tethered cord syndrome) and secondary neurulation defects (Filar lipoma). Since SCM is common in MMC, it is a good idea to subject patients to complete craniospinal imaging in a single setting. This demonstrates the necessity of monitoring patients who were born with neurulation defects constantly. More investigation is needed into the coexistence of primary and secondary neurulation defects as well as the evaluation of any related spinal abnormalities.

Consent

The guardian of the patient gave written consent for this case report to be published.

Declaration of Competing Interest

None

REFERENCES

1. Andar UB, Harkness WF, Hayward RD. Split Cord Malformations of the Lumbar Region: A Model for the Neurosurgical Management of All Types of 'Occult' Spinal Dysraphism?. *Pediatric neurosurgery*. 1997 Mar 7;26(1):17-24.
2. Dias MS. Normal and abnormal development of the spine. *Neurosurgery Clinics of North America*. 2007 Jul 1;18(3):415-29.
3. Hendrick BE, Hoffman HJ, Humphreys RP. The tethered spinal cord. *Neurosurgery*. 1983 Jan 1;30:457-63.
4. Hudgins RJ, Gilreath CL. Tethered spinal cord following repair of myelomeningocele. *Neurosurgical focus*. 2004 Feb 1;16(2):1-4.

5. Izci Y, Pusat S, Onguru O. Fatty filum with different histological features. Case report. *Neurocirugía*. 2011 Jan 1;22(5):457-60.
6. Jindal A, Mahapatra AK, Kamal R. Spinal dysraphism. *The Indian Journal of Pediatrics*. 1999 Sep;66:697-705.
7. Lee JY, Kim KH, Wang KC. Syringomyelia in the tethered spinal cords. *Journal of Korean Neurosurgical Society*. 2020 Apr 27;63(3):338-41.
8. Litvack ZN, Selden NR. Split spinal cord. *Youmans neurological surgery*. Vol 2. Philadelphia: Elsevier; 2011. 2219-2226.
9. Pang D, Dias MS, Ahab-Barmada M. Split cord malformation: Part I: A unified theory of embryogenesis for double spinal cord malformations. *Neurosurgery*. 1992 Sep 1;31(3):451-80.
10. Pang D. Split cord malformation: Part II: Clinical syndrome. *Neurosurgery*. 1992 Sep 1;31(3):481-500.
11. Perry VL, Albright AL, Adelson PD. Operative nuances of myelomeningocele closure. *Neurosurgery*. 2002 Sep 1;51(3):719-24.
12. Reigel DH. Spina bifida. *Pediatric neurosurgery*. 1994;51-76.
13. Rokos J. Pathogenesis of diastematomyelia and spina bifida. *The Journal of Pathology*. 1975 Nov 1;117(3):155-61.
14. Tuite GF, Thompson DN, Austin PF, Bauer SB. Evaluation and management of tethered cord syndrome in occult spinal dysraphism: recommendations from the international children's continence society. *Neurourology and urodynamics*. 2018 Mar;37(3):890-903.

