



HAL
open science

Description and Durability of the Various Indirect Restoration Techniques in Molar-Incisor Hypomineralisation: A Systematic Review

Alice Broutin, Julien Delrieu, Cassandre Blanc, Rémi Esclassan, Karim Nasr, Mathieu Marty, Thibault Canceill, Emmanuelle Noirrit-Esclassan

► To cite this version:

Alice Broutin, Julien Delrieu, Cassandre Blanc, Rémi Esclassan, Karim Nasr, et al.. Description and Durability of the Various Indirect Restoration Techniques in Molar-Incisor Hypomineralisation: A Systematic Review. *European Journal of Prosthodontics and Restorative Dentistry*, 2024, 32 (1), 10.1922/EJPRD_2557Broutin11 . hal-04786738

HAL Id: hal-04786738

<https://hal.science/hal-04786738v1>

Submitted on 16 Nov 2024

HAL is a multi-disciplinary open access archive for the deposit and dissemination of scientific research documents, whether they are published or not. The documents may come from teaching and research institutions in France or abroad, or from public or private research centers.

L'archive ouverte pluridisciplinaire **HAL**, est destinée au dépôt et à la diffusion de documents scientifiques de niveau recherche, publiés ou non, émanant des établissements d'enseignement et de recherche français ou étrangers, des laboratoires publics ou privés.

Description and Durability of the Various Indirect Restoration Techniques in Molar-Incisor Hypomineralisation: A Systematic Review

Keywords

Restorative Dentistry
CAD-CAM
Dental Bonding
Molar-Incisor Hypomineralisation
Inlay-Onlay

Authors

Alice Broutin * †
(DDS, MS)

Julien Delrieu *
(DDS, MS, senior lecturer)

Cassandra Blanc *
(DDS)

Remi Esclassan * †
(DDS, PHD, Professor)

Karim Nasr *
(DDS, MS, senior lecturer)

Mathieu Marty * §
(DDS, PHD, senior lecturer)

Thibault Canceill * ^
(DDS, PHD, senior lecturer)

Emmanuelle Noirrit * †
(DDS, PHD, senior lecturer)

Address for Correspondence

Emmanuelle Noirrit * †

Email: noirrit.e@odonto-tlse.eu

* CHU Toulouse, Odontology Unit, Toulouse, France

† Centre for Anthropobiology & Genomics of Toulouse (CAGT) CNRS UMR 5288, Université Paul Sabatier, Toulouse, France

§ LIRDEF (Laboratoire Interdisciplinaire de Recherche en Didactique Education et Formation, Université Paul Valéry Montpellier 3, France

^ InCOMM (Intestine ClinicOmics Microbiota & Metabolism) UMR1297 Inserm/Université Toulouse III, French Institute of Metabolic and Cardiovascular Diseases (i2MC), Toulouse, France

† UMR n°7268 ADES EFS CNRS, Marseille, France

Received: 05.04.2023

Accepted: 17.09.2023

doi: 10.1922/EJPRD_2557Broutin11

ABSTRACT

Molar-incisor hypomineralisation (MIH) is a qualitative defect of the enamel structure. Indirect restorations may represent the most suitable therapeutic solutions for patients presenting MIH with tooth restorative procedures. This systematic review aims to determine the feasibility of indirect restorations. MATERIALS AND METHODS: A systematic review has been performed and is reported following the PRISMA guidelines. It was performed on three databases (PubMed, Science Direct, and Google Scholar). Ten articles were included. RESULTS: Only two articles reported the use of CAD/CAM technologies, whereas the other eight preferred conventional registration and handmade stratification for ceramics. All indirect bonded restorations made of composite resins or ceramics had significant success rates. A temporary material was placed in most of the articles. There was no clear consensus for tissue conditioning before bonding. Depending on the authors and the articles, the follow-up period extended from 2 months to 6 years. CONCLUSIONS: The survival rate and the non-invasive procedures of indirect restorations are two main arguments that can help dental practitioners in daily practice. Development of CAD/CAM technologies adds new perspectives in the registration, the design and production. However, more clinical trials are needed to confirm the conclusions.

INTRODUCTION

Molar-incisor hypomineralisation (MIH) is a qualitative defect of the enamel structure that was described for the first time in 2001 by Weerheijm et al.¹ after a significant increase in cases observed since the 1970s.^{1,2} Today, this may involve 13 to 14% of children worldwide.³ The particularity of MIH is that the disease presents a multifactorial origin, involving local, systemic, and epigenetic risk factors.⁴⁻⁶ Among these risk factors that have been studied in order to determine if they can be involved in the development of MIH, some are pre-natal factors which may interfere with tooth formation during the last pregnancy trimester.⁷ Stress,⁸ disease, medication,⁴ tobacco consumption,⁸ or endocrine disruptor exposure of the mother during her pregnancy^{9,10} have, for example, already been incriminated. Vitamin D deficiency during the pre- and post-birth period

could also play a role, but no significant link for this has been demonstrated to date.¹¹ Difficulties during childbirth or premature induction of birth could also be involved.⁷ Finally, exposure to several factors during the first four years of the child's life (childhood diseases with recurrent fever, chicken pox, hypocalcemia, exposure to environmental toxins) could also favour the development of MIH as it corresponds to the period of amelogenesis.¹² The genetic factor suggested by several authors in view of the occurrence of MIH among siblings would concern one or more mutations in genes involved in amelogenesis,⁵ but their identification is still controversial.

MIH is characterised by the involvement of at least one of the permanent first molars and often central incisors.¹³ Definitely, MIH generates qualitative defects of enamel¹⁴ and is easy to observe in children's teeth with clearly limited opacities on dental surfaces, porous and softer enamel,¹⁵ and possible exposition of the underlying dentin.^{16,17} The most common symptomatology is thus tooth hypersensitivity.¹⁸ The lesions are highly variable in terms of appearance and severity, as they can range from simple opacities to major hypomineralised enamel fractures.¹⁹ Most often, the occurrence of lesions on incisors indicates a severe character of the pathology.²⁰

The criteria that enable a diagnosis of molar-incisor hypomineralisation were clearly defined by the European Academy for Pediatric Dentistry in 2003.¹³ They bring together the type of involved teeth, good delimitation of the lesions, possible enamel fractures, the presence of atypical restorations, tooth hypersensitivity, and a history of early tooth extractions. Differential diagnosis must be performed with other defects of dental tissue such as amelogenesis imperfecta,²¹ in which all the temporary and permanent denture is involved, or fluorosis with more diffuse opacities.²² In young children, the occurrence of hypomineralisation in temporary second molars and/or canines is called Hypomineralised Second Primary Molars and would be a predictive sign of MIH in future permanent teeth.²³

According to Schwendicke *et al.*, approximately a quarter of the patients presenting an MIH need tooth restorative procedures to recover the shape, function, and aesthetics of the affected teeth.³ Nevertheless, taking care of these patients represents a therapeutic challenge for dentists for several reasons. As the physical and chemical properties of the enamel are altered, the adhesion of restorative materials to hypomineralised lesions is less efficient.¹⁵ It also appears that the patients involved are often young children,²⁴ with partially erupted teeth which are difficult to isolate with a rubber dam. Moreover, they are not classically the easier patients to treat in terms of cooperation and are even less so if the presence of MIH lesions is associated with hypersensitivity of the affected teeth and difficulty in anaesthetising.¹⁸ Faced with these problems, dental practitioners may be tempted to put provisional restorations on their patients' teeth, with poor survival rates over time, in the hope of better cooperation when the child

is an adolescent for the design of permanent restorations.²⁵ However, Linner *et al.* have shown that tooth restorations are more frequent when they are implemented as second-intention treatment.²⁵ This highlights the interest in performing permanent restorations as early as possible, but with the systematic question of the direct or indirect way to restore the teeth. Damage to the cusps associated with MIH compromises the survival of restorations using the direct chairside method, such as composite resins.²⁵ Indirect restorations, designed in the dental lab or by CAD/CAM equipment inside the dental office, would thus be the most suitable therapeutic solutions. They would constitute perennial, tissue preservative, and aesthetic restorations. The use of digital methods can improve the relationship between the practitioner and both the patient and his accompanying person through a presentation of treatment planning, a reduction of appointment duration, and better cooperation of young patients.²⁵⁻²⁷

The objective of this work is to determine the different techniques of indirect restorations in patients with MIH lesions and their durability through a review of the international literature.

MATERIALS AND METHODS

A systematic review was performed in 2023 and is reported here following the PRISMA guidelines.^{28,29}

ELIGIBILITY CRITERIA

We included randomized control trials, cross-sectional studies, case control studies, cohort studies and case series dealing with indirect bonded restoration on at least one permanent molar or incisor affected by MIH without any age limitation. Only clinical studies were included. Total as well as partial restorations were eligible. Articles published in other languages than English, French, or Spanish were excluded.

INFORMATION SOURCES

The systematic review was performed on three databases (PubMed, Science Direct and Google Scholar), according to the recommendations to bring together the maximum of data.³⁰ An additional research was also performed on Cochrane CENTRAL but retrieved no different results than those obtained on PubMed. We have therefore chosen not to mention them in this article

SEARCH

The requests on the three databases were launched on 24 February 2023. The procedure was different between PubMed and the two others, with an advanced search in several steps on PubMed (Supplementary Data 1) and a one-step request on Science Direct and Google Scholar: ((CAD-CAM) OR (indirect) OR (computer)) AND ((MIH) OR (hypomineralization) OR (hypomineralisation)).

STUDY SELECTION

A first screening of the available articles, based on the titles and abstracts, was performed by two trained investigators (CB and TC). Publications that did not meet the inclusion criteria were discarded. A second round of selection was then undertaken, with full studies of the publications.

DATA COLLECTION PROCESS

Once the selection of the publications was completed, a database was created on Microsoft Excel 2016® software and implemented as the articles were read. The same two investigators who had determined the eligibility of the articles for inclusion in the study performed the data collection process.

DATA ITEMS

The following data were collected in the articles: date and country of publication, authors' names, type of study/publication, number of cases presented, age and sex of the patients, follow-up duration and frequency, restored teeth, type and materials for restoration, protocols for tissue preparation and material preparation, results and conclusion expressed by the authors.

RISK OF BIAS IN INDIVIDUAL STUDIES AND ACROSS STUDIES

The risk of bias was planned to be high as the design of our review was prepared to include case reports and case series. We thus performed a bias assessment by using checklists from Joanna Briggs Institute (JBI).

SYNTHESIS OF RESULTS

In view of the important part of case reports included in the results, no statistical analysis could be performed. A complete table has been built to compile the main data obtained.

RESULTS

STUDY SELECTION

At the end of the selection process, 10 articles were included in this systematic review: 6 from PubMed, 2 from Science Direct and 2 from Google Scholar (*Figure 1*).

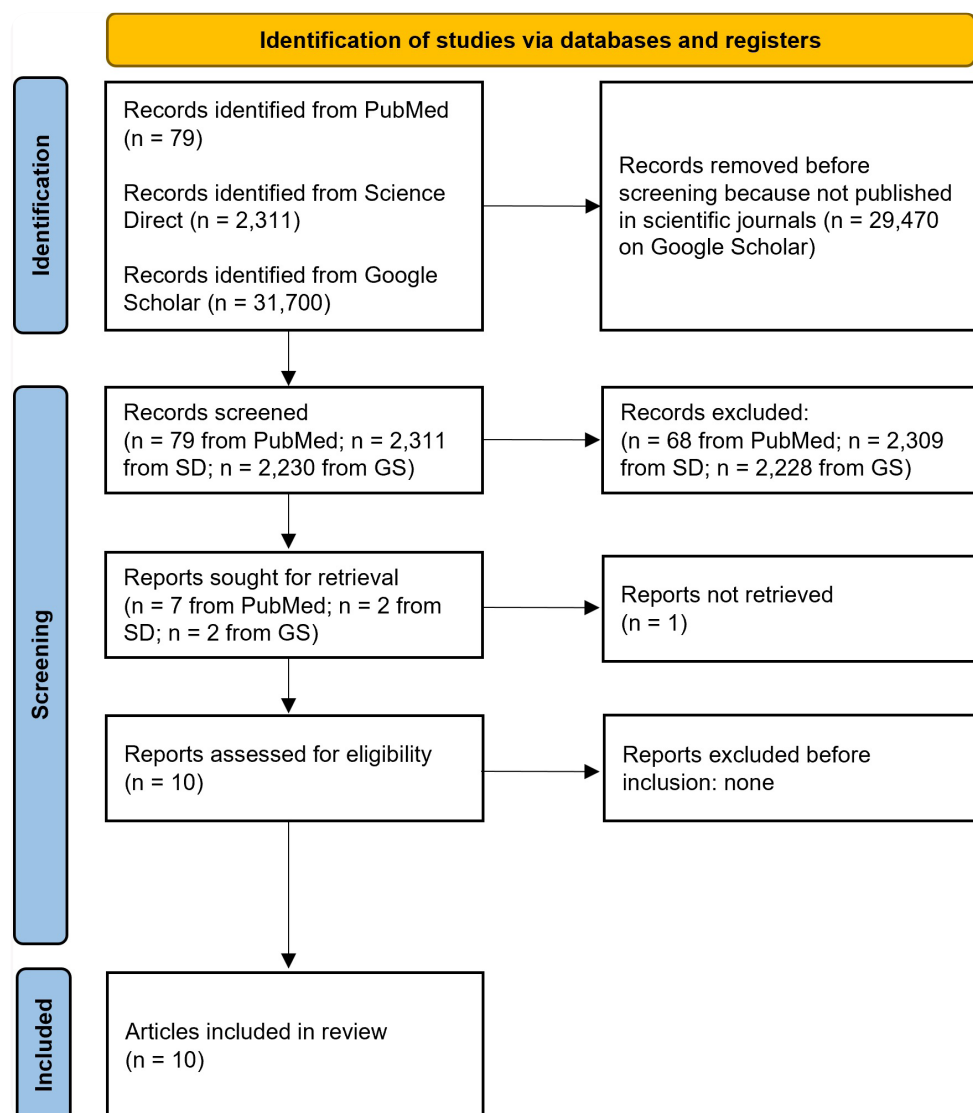


Figure 1: PRISMA flow-chart of the study.

STUDY CHARACTERISTICS

The included publications were all published between 2000 and 2022, 6 of them (60%) in 2020 and 2022. Four articles (40%) were published by German authors, 2 by Indian, 1 by Brazilian, 1 by Colombian, 1 in Saudi Arabia and 1 in Israel (Figure 2). Six publications are considered as case reports (60%), 3 are retrospective studies and the last is a prospective randomised trial with parallel groups.

RESULTS

A total of 221 subjects were described in the publications. Among them, 103 (46.61%) are girls or women and 106 (47.96%) are boys or men (for 12 patients, the sex is not indicated) and they are mainly children and young adults between 6 and 18 years old. Only one article was specifically dedicated to the treatment of a patient aged 22, in order to introduce the possibility to use Digital Smile Design (DSD) software for anterior teeth rehabilitation.³¹ In all the other cases, the restorations concerned posterior teeth. Criteria used in the choice of restorations were mainly linked to the patients' age and compliance, the severity of the lesion and a confrontation between the cost of restoration and family preferences.

In 117 posterior cases, partial restorations were designed and in 126 cases, full coverage crowns were preferred. Only two pellicular veneers were described. Among the restorations, 76 were made of cobalt-chromium alloys, 29 of gold, 45 of composite resin and 34 of ceramics. Only two articles reported the use of CAD/CAM technologies, whereas the other eight preferred conventional registration and handmade stratification for ceramics.

All indirect bonded restorations (n=79) made of composite resins (n=45; 56.96%) or ceramics (n=34; 43.04%) had significant success rates, particularly in terms of retention, appearance of

dental sensitivity, preservation of pulp vitality, and absence of secondary caries. These criteria, together with marginal integrity and colour stability, were the main outcomes evaluated by the authors to judge the success of the restorations performed.

Concerning the protocols applied on the patients, in nine publications the authors described local anaesthesia to prepare the teeth and eliminate hypomineralised enamel areas. A temporary material was placed in all but three articles. The tissue conditioning before bonding was very different between the publications, with no clear consensus on the necessity of performing air-polishing, chemical disinfection with sodium hypochlorite, or even immediate dentin sealing. In 5 of the articles (50%), a rubber dam was placed before the assembly of restorations of dental tissue. Depending on the authors and the articles, the follow-up period extended from 2 months to 6 years, with regular appointments at the dental office every 6 months. Radiological controls were not described at each appointment. One study reported only a phone follow-up.

All results are presented in Table 1 and bias assessment is available for all the included publications in Table 2.

DISCUSSION

The results of this systematic review show how partial and complete indirect restorations of hypomineralised molars constitute reliable, aesthetic, and functional therapeutics, regardless of the biomaterial used for their conception. This opens up the field of therapeutics for the rehabilitation of these teeth through the use of technological tools such as CAD/CAM techniques^{25,26} and Digital Smile Design software.³¹ Patient care is thus modernised, young patients' compliance increased, and therapeutics finely adjusted to patient needs.^{25,26,31}

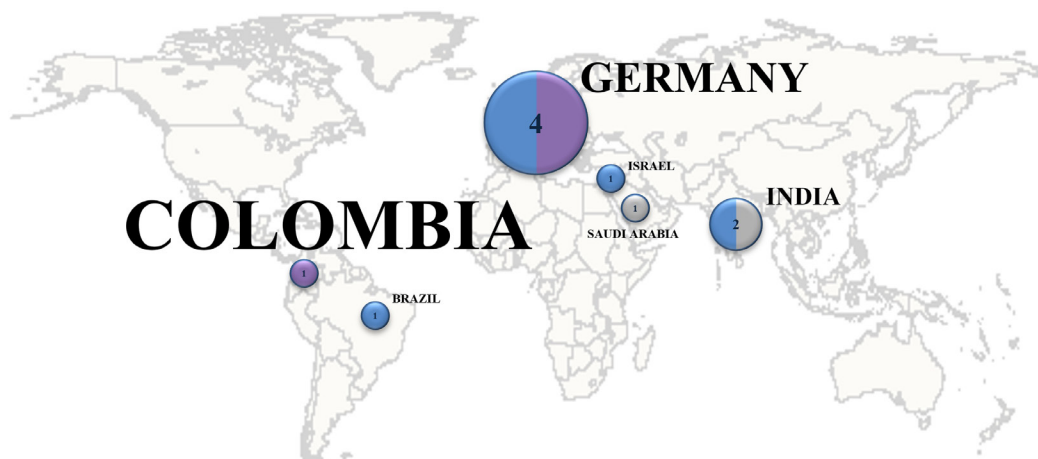


Figure 2: Schematic representation of the geographical places where studies included in this review were performed worldwide. The size of the circles associated with each country and the number inscribed inside indicates the number of articles published in that country. The proportion of blue, purple, and grey filling the circles illustrates the ratio of publications that are case reports (blue), retrospective studies (purple) or randomised controlled trials (grey). The size of the font for each state is proportional to the number of subjects who were included or described in the studies as suffering from MIH lesions.

Table 1. Summary of data extracted from the articles included in the systematic review.

Authors	Alfarraj et al. ³²	De Farias et al. ³³	Davidovich et al. ²⁶	Linner et al. ²⁵	Hahn et al. ²⁷	Barreto et al. ³¹	Dhareula et al. ³⁴	Darheula et al. ³⁵	Feierabend et al. ³⁶	Koch et al. ³⁷
GENERAL DATA										
Country	Saudi Arabia	Colombia	Israel	Germany	Germany	Brazil	India	India	Germany	Germany
Year	2022	2022	2020	2020	2020	2020	2019	2018	2012	2000
Type of study	Case Report	Retrospective	Case Report	Retrospective	Case Report	Case Report	Randomized Clinical Trial	Case Series	Case Report	Retrospective
Topic	Molar management of a patient with MIH	Stainless-steel crown vs. composite resin on first permanent molars	Moderate to severe MIH lesions treated with the help of CAD/CAM	Glass ionomer cement vs. composite resin vs. CAD/CAM restorations	Oral treatment of a patient with MIH	Digital Smile Design and veneers on a patient with MIH	Metallic onlay vs. composite resin on severe MIH	Molar management on patients with severe MIH	Secure and reproducible protocol for all types of MIH	Gold crown vs. composite resins vs. ceramics in cases of severe MIH
Number of cases	1	115	1	52	1	1	25	10	3 with MIH	12
Sex	♀	60 ♂/ 55 ♀	♀	26 ♂/ 26 ♀	♂	♀	21 ♂/ 9 ♀	6 ♂/ 4 ♀	2 ♂/ 6 ♀	-
Age (years)	8	8.4 [7-10]	8	11.2 ± 2.9	11	22	8 to 13	8 to 14	6 to 15	6 to 8
Follow-up duration	2 years	24 months	-	Mean 42.9 months	6 years	-	36 months	30 to 36 months	2 to 48 months	2 to 5 years
Follow-up frequency	6 months, then 2 years	1, 6, 12 and 24 months	1 week, 3 months and then regularly	-	2 weeks and then every 3 months	-	9, 18 and 36 months	Every 6 months	2 weeks, every 6 months, or every 3 months if more than 1 restoration	Every 6 months
Follow-up modalities	Clinical examination + radiographs	Clinical examination	-	Clinical examination + photographs	Clinical examination with orthodontist	-	Clinical examination + radiographs	Clinical examination + radiographs	Phone call	Clinical examination ± radiographs
Teeth treated	8 primary and 2 permanent teeth	115 first permanent molars	1 tooth (#36)	204 restorations (184 molars, 20 incisors). 127 first treatment and 77 re-treatment	15 teeth	6 teeth	42 permanent teeth	10 permanent teeth	34 permanent teeth	41 permanent teeth
Materials for indirect restorations	Stainless-steel crowns	Stainless-steel crowns	LDSRC	LDSRC, ZirconoRC	Micro-charged composite resin reinforced with glass fibers	Composite resin, LDSRC	Cobalt-Chromium, micro-charged composite resin	Micro-charged composite resin	Micro-charged composite resin reinforced with glass fibers	Gold, composite resin, leucite-reinforced ceramics
TISSUE PREPARATION FOR INDIRECT RESTORATIONS										
Etching	-	-	-	-	Orthophosphoric acid	Orthophosphoric acid	Orthophosphoric acid	Orthophosphoric acid	Orthophosphoric acid	Orthophosphoric acid
Adhesive and/or primer	-	-	-	Syntac Classic (Ivoclar Vivadent)	Syntac II Primer, Heliobond (Ivoclar Vivadent)	Adper Single Bond Plus (3M)	Multilink Primer (Ivoclar Vivadent)	Excite F (Ivoclar Vivadent)	Adper Single Bond Plus (3M)	-

Table 1 continued overleaf

Table 1. Summary of data extracted from the articles included in the systematic review.

Bonding material	-	-	Bonding composite resin (Variolink, Ivoclar Vivadent)	Bonding composite resin	-	Luting cement (RelyX Unicem 2, 3M ESPE)	Bonding composite resin (Multilink Automix, Ivoclar Vivadent)	Bonding composite resin (Variolink Veneer, Ivoclar Vivadent)	Luting cement (RelyX Unicem 2, 3M ESPE)	-
Temporary material	-	-	1 week provisional composite resin (Telio, Ivoclar Vivadent)	-	Provisional composite resin (ProTemp, 3M ESPE) and eugenol-free cement	-	1 week provisional composite resin	Mock-up (from the wax-up made in dental lab)	7 to 10 days – provisional inlay and eugenol-free cement	Yes, in case of MIH
Fabrication process	-	-	CAD/CAM	-	Physical registration (polyether) and stratification in dental lab	Physical registration and stratification in dental lab	Physical registration (silicone) and stratification in dental lab	Physical registration (silicone) and stratification in dental lab	Physical registration (silicone) and stratification in dental lab	Physical registration (silicone) and stratification in dental lab
Rubber dam for preparation	-	No, isolation with cotton rolls	Yes	Yes	Yes	Yes	-	-	Yes	Yes, in case of MIH
Precisions on tissue prep	-	Elimination of hypomineralised structures	-	Elimination of affected enamel	-	Metal: 1.5mm reduction for supporting cusps and 1mm for guiding cusps. Composite resin: 2mm reduction for supporting cusps and 1.5mm for guiding cusps	Elimination of weaknesses, margins on healthy enamel, slight depression in the middle of the cavity to improve stability	-	1.5mm reduction for supporting cusps and 1mm for guiding cusps	-
Tissue conditioning before temporization	-	-	Immediate dentin sealing	-	-	Calcium hydroxide ± glass ionomer cement, composite resin	Immediate dentin sealing	-	-	Air-polishing and glycine powder
Hypoplasia zones elimination	-	Unsupported structures	Entirely	Entirely if preparation	-	Entirely	Entirely for enamel	-	-	Entirely for enamel
Margins on healthy enamel	-	-	Yes	Yes	-	Yes	Yes	Yes	Yes	Yes
Pre-treatment applied	-	Professional prophylaxis	-	-	-	5.2% sodium hypochlorite	Air-polishing with glycerin powder	-	-	-
MATERIAL PREPARATION										
Surface treatment	-	-	-	-	Silane (Monobond-S, Ivoclar Vivadent)	Sandblasting with 100µm alumine, 10% fluorhydric acid, silane (3M ESPE)	Sandblasting, silane (Monobond Plus, Ivoclar Vivadent)	Sandblasting with 100µm alumin, silane (Prosil, FGM)	Sablage alumine 100µm, Acide fluo. 10%, Silane (3M ESPE)	Sablage alumine 100µm, Silane (Monobond-S, Ivoclar Vivadent)

Table 1 continued overleaf

Table 1. Summary of data extracted from the articles included in the systematic review.

Rubber dam for bonding	-	-	Yes	-	Yes	Yes	No	-	-	If possible
Assembly of both teeth and restorations	Glass ionomer cement	Glass ionomer cement	Bonding	Bonding for CAD/CAM restorations	For gold: zinc phosphate cement / For composite resin and ceramics: bonding	Auto-adhesive bonding	Bonding	Bonding	Auto-adhesive bonding	Bonding
RESULTS AND CONCLUSION										
Advantages of indirect technique	-	Higher survival rate and direct effect on pain reduction	Speed, precision, cooperation, communication	-	-	Conservative	Communication, observance, prefer composite resin for erupting teeth	DSD for personalized treatment, communication, thin restorations, biomimetism, resistance	Speed of partial restorations, observance, occlusal integration, hygiene	-
Results	Perennial restorations	Stainless-steel crowns present a higher survival rate than composite resins	Perennial restorations. Cost and cooperation to evaluate.	36 months survival rate: 100% for ceramics	Marginal adaptation is excellent for 39 crowns. Good stability after 5 years.	36 months retention rate: 95%.	Hypersensitivities continue for 2 weeks. Restoration survival validated at 6 years.	-	30-36 months survival rate: 100%	2-48 months survival rate: 100%
Conclusion	Validation of endodontic treatment on permanent molars with MIH	Validation of the use of stainless-steel crowns	CAD/CAM validated	CAD/CAM validated. Failure of minimally invasive restorations	Laboratory crown validated	Composite resin onlays validated.	Indirect composite resin restorations validated	Esthetic simulation validated	Composite resin onlays validated	-

LDSRC means Lithium DiSilicate-Reinforced Ceramics, ZirconRC means Zircon-Reinforced Ceramic

Table 2. Bias assessment by checklists from Joanna Briggs Institute’s (JBI) Critical Appraisal Tools. The colors are related to the bias assessment (green means low risk of bias).

Articles	Type of study	Bias assessment (%)	Bias assessment color
Alfarraj et al. ³²	Case Report	100	green
De Farias et al. ³³	Retrospective cohort study	90	green
Davidovich et al. ²⁶	Case Report	75	green
Linner et al. ²⁵	Retrospective cohort study	91	green
Hahn et al. ²⁷	Case Report	100	green
Barreto et al. ³¹	Case Report	63.5	orange
Dhareula et al. ³⁴	Randomized CT	90	green
Darheula et al. ³⁵	Case Series	85	green
Feierabend et al. ³⁶	Case Series	65	orange
Koch et al. ³⁷	Retrospective cohort study	85	green

The management of people suffering from MIH lesions involves several issues. Beyond aesthetic considerations,³⁸ porous enamel¹⁵ is more likely to break¹⁷ and to favour caries development.³⁹ Its physical and mechanical properties are reduced, as are its hardness and its elastic modulus.¹⁵ It contains less minerals and a higher percentage of protein in its structure.¹⁵ A chronic inflammation of pulp tissues, linked to easy deterioration of the enamel,⁴⁰ leads to tooth hypersensitivity,¹⁸ difficulties in maintaining correct oral hygiene⁴¹ and obtaining sufficient anaesthesia during dental care.⁴¹ In 2016, an international work group edited the MIH-Treatment Need Index (MIH-TNI) to guide dental practitioners during diagnosis and management of patients suffering from MIH.⁴² Tooth damage was classified on a 0 to 4 scale according to whether enamel was conserved or destroyed and whether or not the patient presented dental sensitivity. Each score was associated with treatment recommendations: prophylaxis, direct restoration, indirect restoration, or tooth extraction.⁴²

The current trend in dentistry being respect for the therapeutic gradient, from the least invasive therapies to the less conservative,⁴³ the range of treatments currently used for the management of MIH lesions also ranges from simple bond-

ing of sealant in a preventive approach to complete coverage of the tooth, or even its extraction if no restorative procedure can be applied.²⁷ Linner *et al.* have demonstrated that restorations made without tissue preparation have significantly higher failure rates, whatever the biomaterial chosen between composite resin or glass ionomer cement, compared to conventional restorations with removal of hypomineralised enamel areas.²⁵ One of the possible explanations for this phenomenon is the reduced efficiency of orthophosphoric acid etching on hypomineralised enamel for no-prep restorations. Interestingly, restorations designed with placement of preparation margins on healthy enamel had very high success rates, with 36-month cumulative survival probabilities of 100% for ceramic restorations and 76.2% for composite resin restorations, compared to 7% and 29.9% for non-invasive glass-ionomer cement and composite resins respectively.²⁵ There is no consensus today that all or part of hypomineralised tissue should be removed. Some studies support the removal of all altered enamel and dentin,²⁶ but others, in order to be more conservative and preserve pulp vitality, affirm that it is possible to conserve small areas of hypomineralised dentin at the bottom of a cavity with no influence on the success rate of restoration.^{27,36} Some authors perform immediate dentin sealing (IDS) to ensure the disappearance of dental sensitivity and allow better predictability of the success of final restorations.^{26,27}

Finally, what stands out in the literature is the great heterogeneity in the management of teeth affected by MIH. Many protocols are described to deal with symptoms and the need for sustainable restoration. Dhareula *et al.* have, for example, described the use of calcium hydroxide before composite resin restoration,³⁴ whereas Feierabend *et al.* have only performed an air-polishing procedure on dental surfaces.³⁶ Application of 5.2% sodium hypochlorite would also reduce the protein content of the affected enamel and thus improve restoration adherence.³⁴ However, the lack of standardised studies does not allow comparison of the several protocols proposed in the literature. The conclusion concerning pre-treatment of surfaces that can be drawn from the publications is that the success rate of final restoration and the reduction of symptoms are always positive. The longest results are presented after a follow-up of 6 years.²⁷

Regarding the bonding protocol, most studies recommend the use of a rubber dam.^{26,34,37} Interestingly, the success of restorations designed and bonded with basic isolation remains very high, at 6 years.²⁷ The criteria for judging this survival rate varied between the publications but retention, marginal adaptation, integrity of restoration, and pulpal vitality were the most common. Sometimes a change in the shade of composite resins^{35,37} has been noted, but this phenomenon is found in all patients in dental practice and is not limited to MIH patients. It was also noted that treatment failure was higher for teeth that were treated again after the failure of a previous restoration. This highlights the importance of performing permanent fillings with preparation and removal of hypomin-

eralised enamel areas as soon as the patient's compliance allows this. It thus implies reserving temporary restorative procedures (no-prep restorations or preformed pedodontic crowns (PPCs)) only in patients whose cooperation and/or clinical situation does not allow definitive restoration.^{25,26}

The limits of the management of MIH lesions are first of all the cooperation of the patient, which may represent a real challenge,²⁴ and their dental history, which can be chaotic.⁴⁴ In these cases, a no-prep composite resin or a no-prep GIC restoration can be a temporary alternative to protect residual tissue as much as possible, and then consideration of a more durable filling as soon as cooperation is better.²⁵

All the studies agree that partial bonded restorations (inlays, onlays, overlays...) represent excellent therapeutic solutions that can be performed on moderate to severe MIH lesions.^{26,27,34–36} These are even more conservative than full coverage crowns.^{27,35} The limit is the need to conserve supra-gingival limits during tooth preparation, as they require a bonding procedure, which is very constraining regarding the presence of oral fluids. In the literature, there seem to be no differences between the several materials that can be used to design tooth restoration. Indeed, there are no significantly different values between the clinical success rates of metallic and resin inlays³⁴ and only a slightly superior survival rate for resin inlays.³⁴ One of the criteria that must be considered is the easier bonding of orthodontic brackets on restorations made of composite resins if the patient is to receive such treatment.²⁷ The use of ceramics, whatever the lesions present on the tooth, continues to represent the gold standard in terms of mechanical resistance, available shades, surface properties, and brilliancy.⁴⁵ Lithium disilicate-reinforced glass ceramics, in particular, are the most commonly used for their excellent aesthetic properties and their flexural strength that can reach 400MPa.⁴⁶

CONCLUSION

This literature review highlights the reliability of indirect restorations in the management of MIH lesions whether they are bonded or cemented to teeth. Their survival rate and the non-invasive procedures required by their design are two main arguments that can help dental practitioners in daily practice when they must deal with young patients. The development of CAD/CAM technologies adds new perspectives in the registration, design, and production of these indirect restorations. However, extensive clinical trials are needed to confirm the conclusions drawn from the cases reported in this review.

REFERENCES

- Weerheijm, K.L., Jälevik, B. and Alaluusua, S. Molar-Incisor Hypomineralisation. *Caries Res.* 2001; **35**:390–391.
- Lygidakis, N.A. Treatment modalities in children with teeth affected by molar-incisor enamel hypomineralisation (MIH): A systematic review. *Eur Arch Paediatr Dent.* 2010; **11**:65–74.
- Schwendicke, F., Elhennawy, K., Reda, S., Bekes, K., Manton, D.J. and Krois, J. Global burden of molar incisor hypomineralization. *J Dent.* 2018; **68**:10–18.
- Alaluusua, S. Aetiology of Molar-Incisor Hypomineralisation: A systematic review. *Eur Arch Paediatr Dent Off J Eur Acad Paediatr Dent.* 2010; **11**:53–58.
- Jeremias, F., Pierri, R.A.G., Souza, J.F., Fragelli, C.M.B., Restrepo, M., Finoti, L.S., et al. Family-Based Genetic Association for Molar-Incisor Hypomineralization. *Caries Res.* 2016; **50**:310–318.
- Kühnisch, J., Thiering, E., Heitmüller, D., Tiesler, C.M.T., Grallert, H., Heinrich-Weltzien, R., et al. Genome-wide association study (GWAS) for molar-incisor hypomineralization (MIH). *Clin Oral Investig.* 2014; **18**:677–682.
- Lygidakis, N.A., Dimou, G. and Marinou, D. Molar-incisor-hypomineralisation (MIH). A retrospective clinical study in Greek children. II. Possible medical aetiological factors. *Eur Arch Paediatr Dent Off J Eur Acad Paediatr Dent.* 2008; **9**:207–217.
- Thomas Marquillier, C.L., Caroline Delfosse, T.T. and Celine Catteau. L'Hypominéralisation Molaires-Incisives en 3 questions. *Clinic (Paris).* 2021; **42**:825–828.
- Estelle Mathonat. *MIH et Bisphénol A : Revue systématique de la littérature [Thèse d'exercice].* [Toulouse]: Université Toulouse III Paul Sabatier; 2021.
- Jedeon, K., De la Dure-Molla, M., Brookes, S.J., Loiodice, S., Marciano, C., Kirkham, J., et al. Enamel defects reflect perinatal exposure to bisphenol A. *Am J Pathol.* 2013; **183**:108–118.
- Van Der Tas, J.T., Elfrink, M.E.C., Heijboer, A.C., Rivadeneira, F., Jaddoe, V.W.V., Tiemeier, H., et al. Foetal, neonatal and child vitamin D status and enamel hypomineralization. *Community Dent Oral Epidemiol.* 2018; **46**:343–351.
- Allazzam, S.M., Alaki, S.M. and El Meligy, O.A.S. Molar Incisor Hypomineralization, Prevalence, and Etiology. *Int J Dent.* 2014; **2014**:1–8.
- Weerheijm, K.L., Duggal, M., Mejåre, I., Papagiannoulis, L., Koch, G., Martens, L.C., et al. Judgement criteria for molar incisor hypomineralisation (MIH) in epidemiologic studies: a summary of the European meeting on MIH held in Athens, 2003. *Eur J Paediatr Dent.* 2003; **4**:110–113.
- Koch, G., Hallonsten, A.L., Ludvigsson, N., Hansson, B.O., Holst, A. and Ullbro, C. Epidemiologic study of idiopathic enamel hypomineralization in permanent teeth of Swedish children. *Community Dent Oral Epidemiol.* 1987; **15**:279–285.
- Elhennawy, K., Manton, D.J., Crombie, F., Zaslansky, P., Radlanski, R.J., Jost-Brinkmann, P.G., et al. Structural, mechanical and chemical evaluation of molar-incisor hypomineralization-affected enamel: A systematic review. *Arch Oral Biol.* 2017; **83**:272–281.
- Costa-Silva, C.M., Ambrosano, G.M.B., Jeremias, F., De Souza, J.F. and Mialhe, F.L. Increase in severity of molar-incisor hypomineralization and its relationship with the colour of enamel opacity: a prospective cohort study: Increase in severity of molar-incisor hypomineralization: a prospective cohort study. *Int J Paediatr Dent.* 2011; **21**:333–341.
- Fagrell, T.G., Dietz, W., Jälevik, B. and Norén, J.G. Chemical, mechanical and morphological properties of hypomineralized enamel of permanent first molars. *Acta Odontol Scand.* 2010; **68**:215–222.
- Raposo, F., de Carvalho Rodrigues, A.C., Lia, É.N. and Leal, S.C. Prevalence of Hypersensitivity in Teeth Affected by Molar-Incisor Hypomineralization (MIH). *Caries Res.* 2019; **53**:424–430.
- Kilpatrick, N. New developments in understanding development defects of enamel: optimizing clinical outcomes. *J Orthod.* 2009; **36**:277–282.

20. Silva, M.J., Kilpatrick, N., Crombie, F., Ghanim, A. and Manton, D. What's new in molar incisor hypomineralization? *Dent Update*. 2017; **44**:100–106.
21. Mast, P., Rodrigueztapia, M.T., Daeniker, L. and Krejci, I. Understanding MIH: definition, epidemiology, differential diagnosis and new treatment guidelines. *Eur J Paediatr Dent*. 2013; **14**:204–208.
22. Ghanim, A., Elfrink, M., Weerheijm, K., Mariño, R. and Manton, D. A practical method for use in epidemiological studies on enamel hypomineralisation. *Eur Arch Paediatr Dent*. 2015; **16**:235–246.
23. Garot, E., Denis, A., Delbos, Y., Manton, D., Silva, M. and Rouas, P. Are hypomineralised lesions on second primary molars (HSPM) a predictive sign of molar incisor hypomineralisation (MIH)? A systematic review and a meta-analysis. *J Dent*. 2018; **72**:8–13.
24. William, V., Messer, L.B., and Burrow, M.F. Molar incisor hypomineralization: review and recommendations for clinical management. *Pediatr Dent*. 2006; **28**:224–232.
25. Linner, T., Khazaei, Y., Bücher, K., Pfisterer, J., Hickel, R. and Kühnisch, J. Comparison of four different treatment strategies in teeth with molar-incisor hypomineralization-related enamel breakdown—A retrospective cohort study. *Int J Paediatr Dent*. 2020; **30**:597–606.
26. Davidovich, E., Dagon, S., Tamari, I., Etinger, M. and Mijiritsky, E. An Innovative Treatment Approach Using Digital Workflow and CAD-CAM Part 2: The Restoration of Molar Incisor Hypomineralization in Children. *Int J Environ Res Public Health*. 2020; **17**:1499.
27. Hahn, B., Krastl, G., Halbleib, K. and Soliman, S. Management of a Patient with Hypomineralized Teeth from the Mixed to Permanent Dentition Stage - A Case Report with 6-year Follow-up. *J Adhes Dent*. 2020; **22**:455–463.
28. Moher, D., Liberati, A., Tetzlaff, J., Altman, D. and The PRISMA Group. Preferred Reporting Items for Systematic Reviews and Meta-Analyses: *The PRISMA Statement*. 21 Juillet 2009. 2009;**6**(7).
29. Page, M.J., McKenzie, J.E., Bossuyt, P.M., Boutron, I., Hoffmann, T.C., Mulrow, C.D., et al. The PRISMA 2020 statement: an updated guideline for reporting systematic reviews. *BMJ*. 2021; **71**.
30. Gasparyan, A.Y., Ayvazyan, L., Blackmore, H. and Kitas, G.D. Writing a narrative biomedical review: considerations for authors, peer reviewers, and editors. *Rheumatol Int*. 2011; **31**:1409–1417.
31. Barreto, S.C., Soares, V.V.B., Neves, A. de A., Nascimento, D.F.L., Maia, L.C. and Pereira, G.D. da S. Molar Incisor Hypomineralization: the use of Digital Smile Design (DSD) in the Esthetic and Functional Recovery of Teeth. *J Health Sci*. 2020; **22**:135–141.
32. Alfarraj, J.H. and Alsaeed, A.A. Clinical Management of Molar Incisor Hypomineralization Affected Molars in a Pediatric Patient Including Endodontic Treatment, Case Report and Review of the Literature. *Clin Cosmet Investig Dent*. 2022; **14**:183–189.
33. de Farias, A.L., Rojas-Gualdrón, D.F., Mejía, J.D., Bussaneli, D.G., Santos-Pinto, L. and Restrepo, M. Survival of stainless-steel crowns and composite resin restorations in molars affected by molar-incisor hypomineralization (MIH). *Int J Paediatr Dent*. 2022; **32**:240–250.
34. Dhareula, A., Goyal, A., Gauba, K., Bhatia, S.K., Kapur, A. and Bhandari, S. A clinical and radiographic investigation comparing the efficacy of cast metal and indirect resin onlays in rehabilitation of permanent first molars affected with severe molar incisor hypomineralisation (MIH): a 36-month randomised controlled clinical trial. *Eur Arch Paediatr Dent*. 2019; **20**:489–500.
35. Dhareula, A., Goyal, A., Gauba, K. and Bhatia, S.K. Esthetic rehabilitation of first permanent molars affected with severe form of Molar Incisor Hypomineralization using indirect composite onlays-A case series. *Pediatr Dent J*. 2018; **28**:62–67.
36. Feierabend, S., Halbleib, K., Klaiber, B. and Hellwig, E. Laboratory-made composite resin restorations in children and adolescents with hypoplasia or hypomineralization of teeth. *Quintessence Int Berl Ger* 1985. 2012; **43**:305–311.
37. Koch, M.J. The Clinical Performance of Laboratory-Fabricated Crowns: Placed on First Permanent Molars with Developmental Defects. *J Am Dent Assoc*. 2000; **131**:1285–1290.
38. Lygidakis, N.A., Wong, F., Jälevik, B., Vierrou, A.M., Alaluusua, S. and Espelid, I. Best Clinical Practice Guidance for clinicians dealing with children presenting with Molar-Incisor-Hypomineralisation (MIH): An EAPD Policy Document. *Eur Arch Paediatr Dent Off J Eur Acad Paediatr Dent*. 2010; **11**:75–81.
39. Americano, G.C.A., Jacobsen, P.E., Soviero, V.M. and Haubek, D. A systematic review on the association between molar incisor hypomineralization and dental caries. *Int J Paediatr Dent*. 2017; **27**:11–21.
40. Rodd, H.D., Boissonade, F.M. and Day, P.F. Pulpal status of hypomineralized permanent molars. *Pediatr Dent*. 2007; **29**:514–520.
41. Weber, K.R., Wierichs, R.J., Meyer-Lueckel, H. and Flury, S. Restoration of teeth affected by molar-incisor hypomineralisation: a systematic review. *Swiss Dent J*. 2021; **131**:988–997.
42. Steffen, R., Krämer, N. and Bekes, K. The Würzburg MIH concept: the MIH treatment need index (MIH TNI): A new index to assess and plan treatment in patients with molar incisor hypomineralisation (MIH). *Eur Arch Paediatr Dent*. 2017; **18**:355–361.
43. Tirtlet, G., Crescenzo, H., Crescenzo, D. and Bazos, P. Ceramic adhesive restorations and biomimetic dentistry: tissue preservation and adhesion. *Int J Esthet Dent*. 2014; **9**:354–369.
44. Jälevik, B. and Klingberg, G. Treatment outcomes and dental anxiety in 18-year-olds with MIH, comparisons with healthy controls - a longitudinal study. *Int J Paediatr Dent*. 2012; **22**:85–91.
45. Pjetursson, B.E., Valente, N.A., Stranding, M., Zwahlen, M., Liu, S. and Sailer, I. A systematic review of the survival and complication rates of zirconia-ceramic and metal-ceramic single crowns. *Clin Oral Implants Res*. 2018; **29**:199–214.
46. Aziz, A. and El-Mowafy, O. Six-year clinical performance of lithium disilicate glass-ceramic CAD-CAM versus metal-ceramic crowns. *J Adv Prosthodont*. 2023;**15**:44–54.

