



HAL
open science

First bioarchaeological evidence of the familial practice of embalming of infant and adult relatives in Early Modern France

Caroline Partiot, Maryelle Bessou, Sacha Kacki, Maxime Penet, Géraldine Sachau-Carcel, Dominique Castex

► To cite this version:

Caroline Partiot, Maryelle Bessou, Sacha Kacki, Maxime Penet, Géraldine Sachau-Carcel, et al.. First bioarchaeological evidence of the familial practice of embalming of infant and adult relatives in Early Modern France. *Scientific Reports*, 2024, 14 (1), pp.27075. 10.1038/s41598-024-78258-w . hal-04784100

HAL Id: hal-04784100

<https://hal.science/hal-04784100v1>

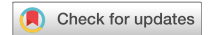Submitted on 6 Jan 2025

HAL is a multi-disciplinary open access archive for the deposit and dissemination of scientific research documents, whether they are published or not. The documents may come from teaching and research institutions in France or abroad, or from public or private research centers.

L'archive ouverte pluridisciplinaire **HAL**, est destinée au dépôt et à la diffusion de documents scientifiques de niveau recherche, publiés ou non, émanant des établissements d'enseignement et de recherche français ou étrangers, des laboratoires publics ou privés.



Distributed under a Creative Commons Attribution 4.0 International License



OPEN First bioarchaeological evidence of the familial practice of embalming of infant and adult relatives in Early Modern France

Caroline Partiot^{1✉}, Maryelle Bessou², Sacha Kacki^{2,3}, Maxime Penet²,
Géraldine Sachau-Carcel⁴ & Dominique Castex²

While medieval and modern embalming practices in Western Europe are attested to historically and bioarcheologically, especially for famous historical figures, there are few recorded occurrences of this type of corpse preparation for a large number of archaeological individuals from the same lineage. Moreover, evidence of such practices mainly concerns adult individuals, whereas traces of child embalming are extremely rare. In 2017, the discovery of a crypt in the chapel of the Château des Milandes (Castelnaud-la-Chapelle, Dordogne, France) revealed a collective burial of the scattered remains of seven adults and five children of the aristocratic Caumont family, who died in the 16th and 17th centuries and whose skeletons all show marks of embalming practices. In 2021, another excavation in the chapel uncovered the individual grave of an elderly woman whose body was also embalmed. This skeletal sample provides a unique opportunity to examine the *modus operandi* of medieval embalming through the cutmarks left on the cranium and appendicular skeleton and to compare mortuary protocols for adults and children. Our macroscopic and microscopic investigations revealed a thorough and highly standardized technical treatment that was similar for both adult and very young immature individuals and displays a skillset that was passed down over two centuries.

While embalming practices are usually associated with Egyptian or South American funerary rituals, body preparation in medieval Western Europe has been documented since the 9th century and was practiced in royal, noble, and bourgeois families in the late Middle Ages and Early Modern period^{1–3}, e.g.⁴. Unlike Egyptian mummification, medieval/early modern embalming was not about preserving the body for the long term, but rather about slowing decomposition for long enough to display the corpse of a member of a privileged social group before and during their funeral. This treatment had even greater importance when the person had died far from home.

The theoretical *modus operandi* is known from the most important surgical treatises such as the works of Ambroise Paré (1509–1590) or Jacques Guillemeau (1544–1613) (for a review, see^{5,6}). According to these medical sources, for purposes of necropsy or embalming, all internal organs, including the brain, were removed before the corpse was washed and filled with balsam and aromatic substances^{5,6}. On a practical level, the protocol is also partially documented by bioarchaeological sources relating to the mummified soft tissues and odoriferous substances used to “stuff” the empty spaces and perfume the corpse e.g.^{5–8}, or to the cutmarks associated with craniotomy and sterno-thoracotomy^{3,5,6,9,10}.

However, cases of medieval/modern embalming are rare in the archaeological record, and many practical aspects of the operator’s manipulation of the corpse have remained unclear, including the body parts affected by the preparation (head, abdomen and thorax only, or possibly the upper and lower limbs as well), the tools used, and the possible differences in treatment based on criteria such as sex or age at death. Moreover, occurrences of multiple cases of embalming in the same corpus e.g.^{3,9} or family¹¹ have rarely been reported. Cases of embalmed children are also extremely rare in the chrono-geographical context of medieval/modern Western Europe, being limited to one five-year-old child and a newborn from the Medici family in Italy⁶, and two children from the Jacobin convent in Rennes, whose presence was recorded but who have not been studied osteologically³, the youngest of whom died at around 5 years of age.

¹Bioarchaeology Lab, Archaeological Sciences, Austrian Archaeological Institute at the Austrian Academy of Sciences, Vienna 1010, Austria. ²UMR 5199 PACEA, CNRS, Université de Bordeaux, Pessac 33615, France. ³Department of Archaeology, Durham University, Durham DH1 3LE, United Kingdom. ⁴UMR 7268 ADES, CNRS, EFS, Aix-Marseille Université, Marseille 13284, France. ✉email: caroline.partiot@oeaw.ac.at

The recent discovery, in the chapel of the Château des Milandes in Dordogne (south-western France), of the skeletal remains of members of a noble family showing numerous traces of embalming on both cranial and postcranial elements, therefore provides the first archaeological evidence of embalming of children and adults from the same lineage in the Early Modern period in France. It has offered an opportunity to examine in detail the practicalities of corpse preparation based on the marks left on the cranial and postcranial skeleton, and to investigate the variability of mortuary protocols based on age at death for privileged social groups.

The Château des Milandes was built in the second half of the 15th century on the left bank of the river Dordogne in south-western France (Fig. 1a), by François de Caumont, lord of Caumont (Lot-et-Garonne) and Castelnaud (Dordogne). Situated on the western edge of the municipality of Castelnaud-la-Chapelle, it is better known today as the residence of Josephine Baker between 1947 and 1968.

In accordance with the will of François de Caumont, a chapel was built in the early 16th century to the south of the castle (Fig. 1b). Its recent restoration led to an archaeological investigation in 2017 and the discovery of a vaulted burial crypt measuring about 9 m² (Fig. 1c, d, e).

In October 2019, complete excavation of this vaulted burial crypt revealed a large number of fragmented human remains associated with a large quantity of other materials including wood, nails, lead fragments and small objects. The archaeological context was very complex, as all these remains were commingled across the entire surface of the vault without any apparent organisation. A total of 2207 vestiges were recorded and identified, including 1885 human bone elements (Fig. 2).

Spatial analysis of the remains, based on photogrammetric models of the bone assemblage and the re-association of bones through post-excitation anthropological study, revealed that the burials had been considerably disturbed over time by one or more human interventions (probably including lead extraction

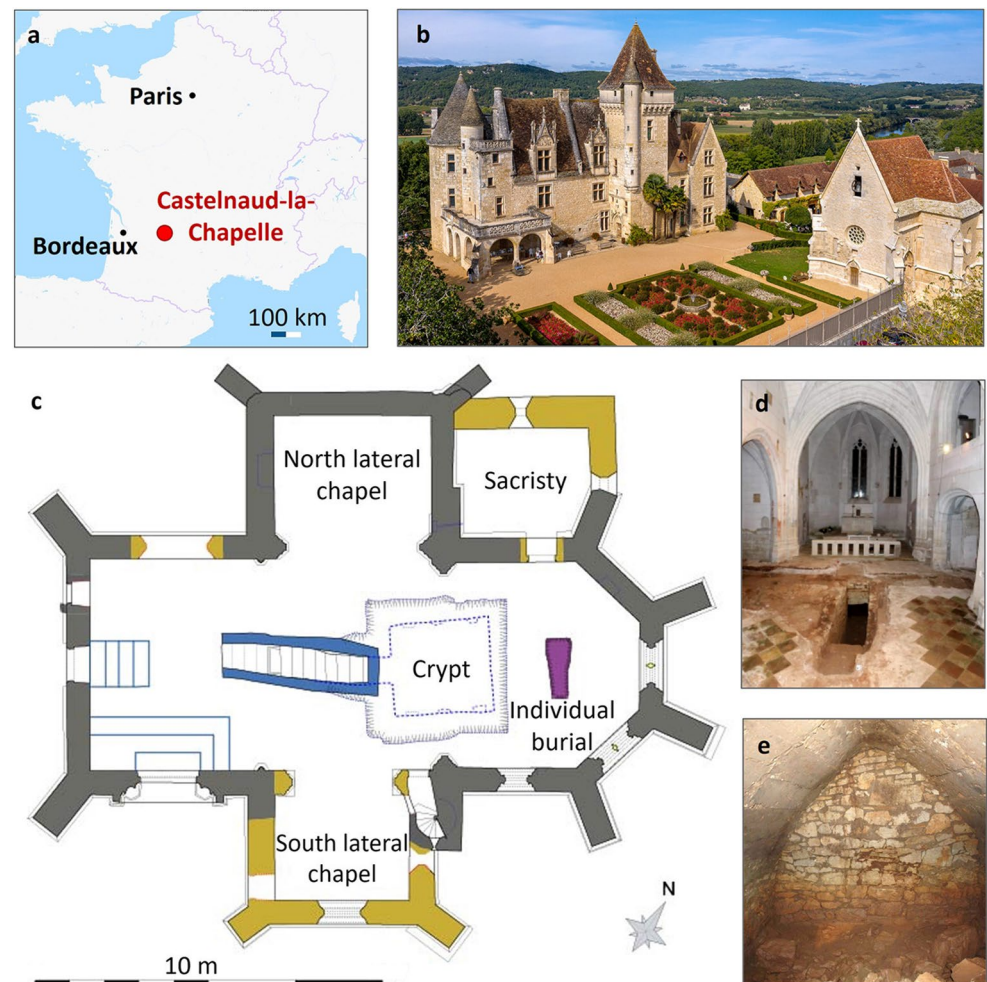


Figure 1. (a) Location of the Château des Milandes in Castelnaud-la-Chapelle, Dordogne, France. Map: <https://www.openstreetmap.org/relation/2377311#map=5/45.416/3.691>; (b) Aerial view of the Château des Milandes (left) and the chapel (right), © D. Castex; (c) Map of the chapel, modified after the map of F. Mandon (Atemporelle Archaeological service). In grey: elevations dating from the second half of the 15th century; in yellow: elevations dating from the beginning of the 16th century; in blue: crypt dating from the 2nd half of the 16th century; in purple: individual burial ML2021; (d) Entrance to the crypt in the chapel, © F. Mandon; (e) interior of the crypt, details © F. Mandon.




Figure 2. Photogrammetric recording of the surface. (a) Example during one phase of excavation; (b) Photogrammetric recording of the same vestiges with a visualization of the localization of each object by M.P. © G. Sachau-Carcel.

during the French Revolution). A reconstruction of the funerary practices was proposed as follows: the deceased were initially placed in wooden and lead containers laid on floors along the sides of the vault, with the head to the west and the feet to the east. The initial in situ observations (identification of cranial fragments with saw marks and postcranial bones with cutmarks) and the presence of a possible cardioph (container for a mummified heart) indicated embalming practices in the collection. The presence of members of the Caumont family, strongly surmised on the basis of archival sources, was confirmed by the presence of two small gold bracelet clasps bearing the family motto.

Another excavation, conducted in 2021 in the chevet of the chapel, revealed an isolated primary burial in a coffin containing an almost completely preserved individual, referred to as ML2021 (Fig. 1.c and Fig. 3) and radiocarbon dated to between 1448 and 1620 cal. AD. The skeletal remains also exhibit the marks of embalming, providing an exceptional opportunity to complete the study of embalming procedures based on a sub-complete skeleton.

Results

Minimum number of individuals (MNI) and biological identity

The anthropological study revealed that at least 12 individuals (7 adults and 5 immature individuals) were buried in the crypt over almost two centuries. The craniofacial remains, reassembled according to a specific protocol (see [Material and Methods](#) section and Information Material n°1) were arbitrarily labelled A to G for the adults ($n=7$) and H to J for the immature individuals ($n=3$). Two more immature individuals were identified through biological examination of the postcranial remains. With the addition of the individual ML2021 (cranium K), the corpus of Les Milandes therefore includes a MNI of 8 adults and 5 immature individuals (Fig. 4).

In this crypt sample, sex diagnosis based on two right and one left coxal bones was possible for three adult individuals, two males and one female. Two frontal bones belonging to other adult individuals show signs of *hyperostosis frontalis interna*, a pathology that almost exclusively affects elderly female individuals¹², thus leading us to assume the presence of two additional female individuals. Age at death could be assessed for two adults from the crypt, one of whom was over 30 years old, and the other over 60 years old. From the commingled remains, two anatomical sets could be reconstituted, one consisting of five significantly robust bones (two femora, two tibiae and a left fibula), and the other consisting of particularly gracile remains (humerus, radius, ulna, right coxal bone and femur). Palaeopathological examination revealed that one of the adult female individuals from the crypt probably suffered from osteoporosis.

The immature individuals were assigned to age groups based on their dental development and on the size and maturation of their postcranial bones. One (IM5) belongs to the 6–12 months age group (statural age at death estimated to 9 postpartum months; central age: 19.1 lunar months, confidence interval: [18.4–19.9]); two others (IM3 and IM4) to the 1–4 year-old group; another (M2) to the 5–9 year-old group; the last one (M1) to the broader 5–14 year-old group (Fig. 4). The individual who died between 6 and 12 months exhibited extensive pathological bone formation on their ectocranial surfaces, as well as subperiosteal new bone formation on long bones (right and left humerus, right and left femora, right and left tibiae, left fibula). These features, possibly associated with an infection¹³, are indicative of a compromised health status.

The individual found in the primary burial in the chapel's chevet was identified as a woman over 50 years of age who suffered from several age-related pathologies. Her skeleton is well represented and preserved, with the notable exception of the missing sternum.

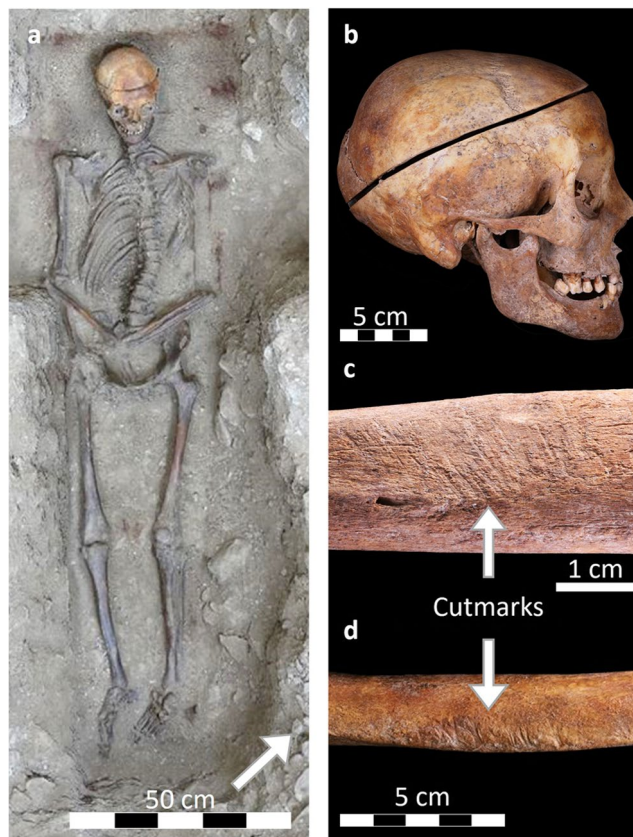


Figure 3. Individual burial ML2021 found in the chevet of the chapel in 2021. (a) In situ photo © H. Gaillard; (b) Marks of embalming on the cranium; (c) Marks on the right humerus (antero-medial view), (d) Marks on the left tibia (anterior view) © C. Partiot and M. Bessou.

Comparison with archival findings and possible identification from administrative records

According to the list of the deceased in the Caumont lineage between the 16th and the end of the 17th century reconstituted from available administrative records, a minimum of 9 adults and 1 immature individual could have been buried in the crypt¹⁴. They include François II de Caumont, who was murdered in 1564, Geoffroy de Caumont, who was poisoned in 1574, his wife Marguerite de Lustrac, who died in 1597, their son Jean de Caumont, who died in 1579 at the age of nine, and Jacques Nompars de Caumont, who died in 1652. Comparison with bioarchaeological data shows that the only tangible difference relates to the number of children: only one child appears on the burial list, whereas we have identified a minimum of five. Based on archival sources emphasizing the fact that Jacques Nompars de Caumont was very tall, we hypothesized that the robust bones from the crypt might belong to him. The individual grave in the chapel could be that of Claude de Cardaillac, who was the wife of François de Caumont, founder of Les Milandes and who died in 1514 before the construction of the crypt was completed, or of Jeanne de Beynac, who was the wife of Charles 1^{er} de Caumont and whose date of death is unknown, or of Jeanne Peyrusse des Cars, wife to Charles II de Caumont, who was born in 1480 and died after 1535, or of Marguerite de Lustrac, wife to Geoffroy de Caumont, who died in 1597 (Fig. 4).

Macroscopic analysis of the cranial remains from the crypt

Except for one poorly preserved cranium (D), all the crania from the crypt show cutmarks and sawing marks on the bone. Macroscopic analysis of the surface modifications described for each of the nine crania according to the specific terminology (see Supplementary Information n°2 online) enabled us to determine the procedure for post-mortem cranial treatment. Sagittal and coronal striations on the adult calvaria show that the operator first cut the scalp along the sagittal and coronal axes into four flaps to expose the cranial vault (Fig. 5a, example of the cranium F, area 1; see Supplementary Information n°3 online). The cranium was then cut open circularly to gain access to the brain, with an oblique primary cut (Fig. 5b, example of the cranium F) from anterior to posterior through the frontal region and superior nuchal line most commonly observed. Based on the relative timing of the cuts, we identified the most common sequence of operator practice: first a saw cut into the frontal bone, then a second cut towards the parietal/temporal region (Fig. 5b, example of the cranium F, area 2), before the body was turned around to saw off the occipital bone and remove the upper part of the cranium.

However, two adult individuals also show rather atypical cranium openings (see Supplementary Information n°3 online): cranium E shows that the operator started sawing from the parietal region in a postero-anterior direction, whereas cranium F shows a classic circular cut (Fig. 5b) as well as an unusual secondary cut along the

Les Milandes: distribution of the individuals and possible identification

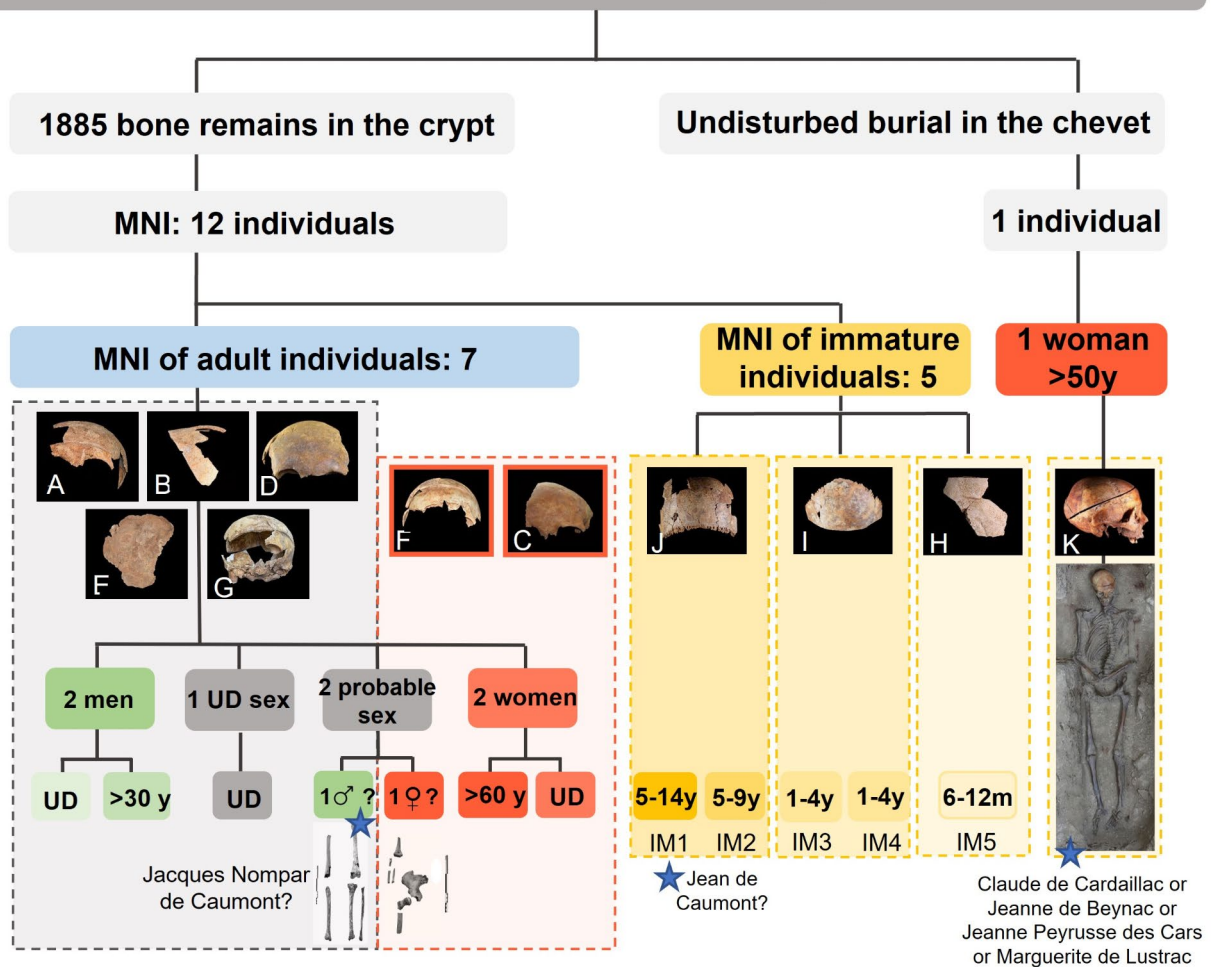


Figure 4. Distribution of the individuals found in the chapel of the Château des Milandes based on the biological study, and possible individual identification. MNI: Minimum Number of Individuals; UD: UnDetermined; y: years of age; IM: Immature, Blue stars: possible identification from administrative records. © C. Partiot, D. Castex and M. Penet.

sagittal axis (Fig. 5c, area 3). This first sagittal cut was made into the frontal bone with a curved blade (Fig. 5c area 4), but was followed by an unusual gesture, as the operator used manual pressure to remove a piece of the vault corresponding to the left and median parts of the frontal bone and the antero-lateral part of the left parietal (Fig. 5c), as shown by the marks on the antero-medial edge of the fragment. However, the operator systematically avoided damage to the brain by stopping the saw cut on reaching the internal table, as shown by the flat marks indicating a stop (Fig. 5c, area 4).

Some variations in the cutting protocol also reflect either special care or practical difficulties (see Supplementary Information n°3 online): crania F and G show multiple incisions associated with sawing that started from a primer incision on the outer table, suggesting that the operator favoured numerous small, short-range sawing movements that were resumed each time from the outer table, rather than a few large movements. This choice might be associated with special care taken to preserve the integrity of the brain. The cranium G, in particular, shows numerous sawing attempts and saw skips, which may indicate that the operator had some difficulty in penetrating the vault.

The procedures applied to the immature crania are broadly similar to that of adults, but with some special features. Cranium H belongs to an infant whose age at the time of death was estimated at 6 months to 1 year (Fig. 6a to d). Although the calvarium is not well represented, analysis of the fragments indicates that the head was also cut circularly, with an oblique antero-posterior cut passing through the inferior part of the parietal bone (Fig. 6a and b) and the supero-medial part of the occipital bone (Fig. 6c), and probably through the frontal eminences. The different fragments of the vault show numerous fine cutmarks, attesting to the precautions taken to avoid breaking the skull.

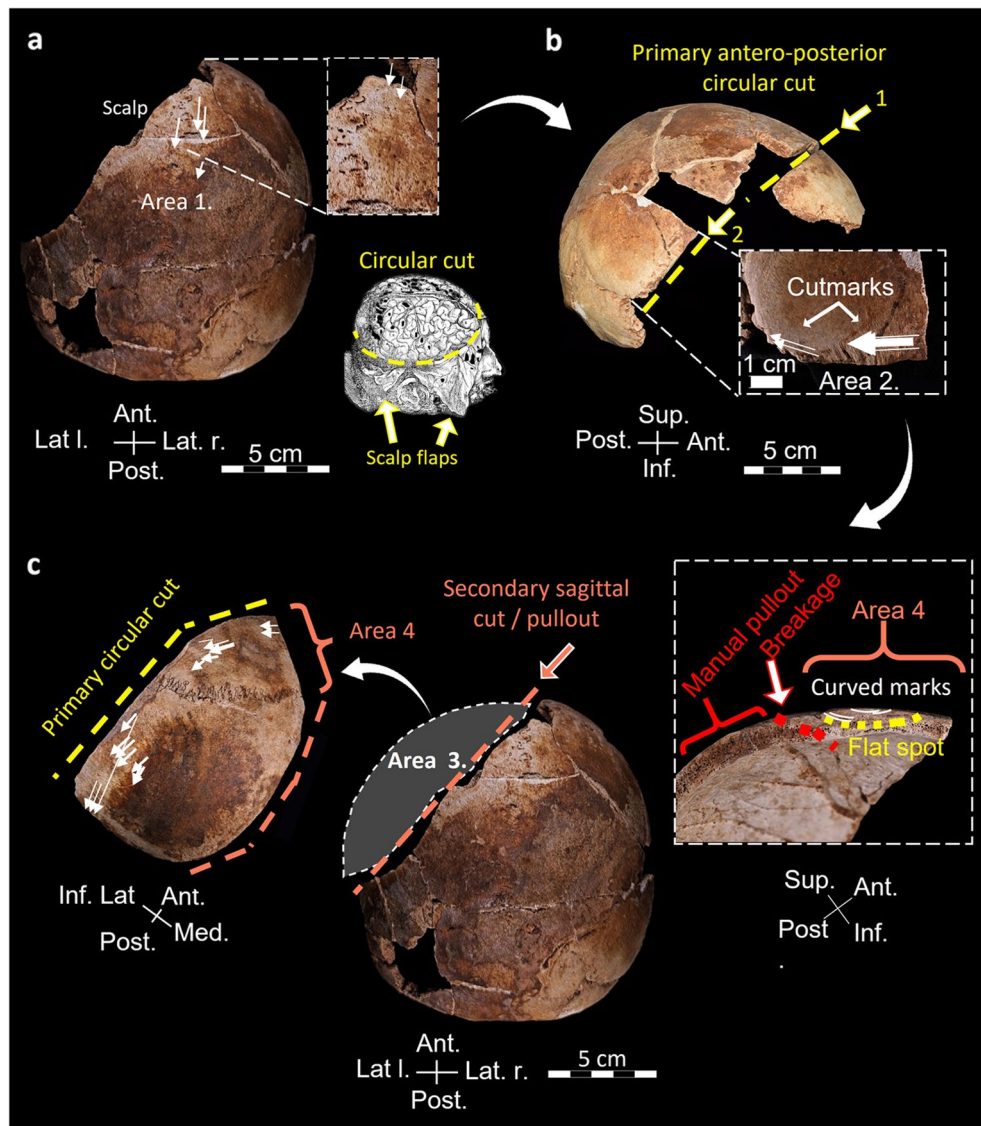


Figure 5. Cranium F, details of the sequence of events for craniotomy. (a) Step 1, cutting of the scalp with close-up showing the thin scalpel marks, superior view, and modified example illustration after Vésale (1543). (b) Step 2, Primary circular cut (yellow dotted line) made with a saw and starting in the frontal region with close-up showing the striated cutmarks, lateral right view. (c) Step 3, unusual step of secondary sagittal cut (orange dotted line) with manual pull-out of the left antero-lateral part of the cranium (area 3) and details of the medial edge of the detached fragment and the cutmarks left by the curved blade (area 4) © C. Partiot.

Cranium I belongs to an immature individual who died between 1 and 4 years of age (Fig. 6e to h). Sagittal scalp cuts are evident near the bregma region (Fig. 6e), and the cranium was circularly cut, with saw marks indicating frequent changes of direction during sawing, with manipulation of the head (Fig. 6e, f and g). On a fragment from the frontal spine area, unusual perpendicular cutting grooves might indicate that a tool was used to sever the inner table, perhaps by levering, without damaging the brain (Fig. 6h).

The third immature cranium (J), (Fig. 6i to k), assigned to the 5–9 or to the 5–14 year-old group, has longitudinal scalp striations unusually located on both the left and right parietal bone (Fig. 6i), and in the right supra-orbital area (Fig. 6j). Scalping may therefore have been done in longitudinal strips instead of four flaps with intersecting sections. The cutting plan is pseudo-transverse and runs very inferiorly along the left and right temporal bones (Fig. 6k).

The detailed results of each cranial macroscopic analysis can be found in Supplementary Information n°3 online.

Macroscopic analysis of the postcranial remains from the crypt

Regarding the distribution pattern of cutmarks on the scattered postcranial remains (Fig. 7), almost 7.5% of them, from all age groups combined, exhibit embalming marks ($N=48/659$). Of the latter, 35% ($N=17$) are located on the upper limbs, 31% ($N=15$) on the lower limbs, 19% ($N=9$) on the spine and ribs, 5 on the

shoulder girdle and 2 on the pelvic girdle. Postcranial cutmarks were identified on 24 immature bone remains, on 23 adult-sized remains and on one bone whose age group could not be identified with certainty. The detailed observations on postcranial remains can be found in Supplementary Information n⁴ online.

In the adults, the marks are predominantly found on the long bones (Fig. 7). The muscles were transected in the joint area and/or in the mid-diaphysis area, with some of them showing repeated cuts (see Supplementary Information n⁵ online). The cutmarks are mostly located on the anterior, anteromedial and superior (for the clavicles) sides of the skeleton, whereas in the immature individuals, they are much more commonly located posteriorly. In the immature individuals, cutmarks are also found on the anterior and posterior surfaces of two ilia (from the immature individual IM5 who died between 6 months and 1 year of age, and from the immature individual IM1 who died between 5 and 14 years of age), indicating evisceration and defleshing of the posterior muscles. A cluster is observed on the anterior face of a rib fragment belonging to the immature individual IM2 (5–9 years). No cut rib has been identified. Overall, very few cutmarks were observed on the ribs from the crypt sample (only 4 occurrences), and a majority of these elements are fragmented and poorly preserved (39 complete ribs for 244 fragments). With the exception of a fragment of manubrium, no complete or fragmented sternum has been found among the crypt's scattered adult and immature remains. One adult phalanx of the hand, as well as one metatarsal and one metacarpal attributed to the immature individual IM2, show that the process affected the upper and lower limbs even at the most distal level (Fig. 7i and j).

The single individual buried in the chevet

Osteological analysis shows that the preparation of the body of the female individual in the undisturbed grave was similar to that of the subjects found in the crypt, with a peripheral circular cut of the cranium (Fig. 3), removal of the brain and thorough defleshing of the upper and lower limbs (Fig. 8ab) and the thoracic cage (Fig. 8d). In the upper and lower limbs, the cutmarks are symmetrical between the left and right sides. A particularly interesting finding is a transverse cutmark in the anterior region of the 3rd cervical vertebra, which might be related to the severing of the trachea (Fig. 8c). As in the crypt, no sternum, either complete or fragmented, has been found among the remains. The detailed observations on the remains of individual ML2021 can be found in Supplementary Information n⁶ online.

Microscopic analyses


The 3D and profile confocal analyses of selected cutmarks of the adult cranium F and immature cranium I allowed us to distinguish between different types of marks (Table 1): the incisions made to remove the scalp from the vault are extremely thin (30 µm wide on average), superficial (40 µm deep) and symmetrical, with a very flat bottom, confirming that they were made with a very thin and sharp scalpel-like blade that initially penetrated the thickness of the scalp tissue (Fig. 9). The incisions corresponding to the striated cutmarks and the attempt to initiate sawing near the cutting plane are ten times wider (about 1,000 µm) and deeper (about 600 µm) than the incisions in the scalp, with a U-shaped, more or less asymmetrical profile and with a more irregular bottom and concave slopes. These features reflect the fact that the cut was made with a different tool and with some force applied directly to the bone. The cutmarks left by the sawing process itself, which appear very asymmetrical with a very irregular profile, are of medium width (500 µm), but shallow (50 µm), with rather convex slopes. The grooves left by the curved saw blade, identified only on cranium F, are quite wide (800 µm) and shallow (120 µm), with a very characteristic profile: a pseudo-vertical slope on one side and a very gentle and convex slope on the other. Sawing was therefore done with moderate force and precaution.

The cutmarks on the immature cranium I are morphologically more irregular than those on the cranium of the adult F, with the saw cuts on the immature individual being ten times shallower and two to three times narrower than on the adult cranium (Table 1). The results of the microscopic analyses on the skulls of the individuals F and I can be found in Supplementary Information n⁷ online.

Discussion

The first known occurrence of embalming practices in the chrono-cultural context of Medieval Western Europe dates back to the death of Charles II the Bald in 877¹⁵. This post-mortem treatment was first reserved for the King, then to the elite of the kingdom. It aimed to slow down the decomposition processes and reduce odors for the time needed to transport and/or display the body. From the 13th century onwards, the process was sometimes accompanied by the dispersion and burial of the viscera in different places, thereby showing favour to different religious establishments^{15,16}. According to the medical literature and bioanthropological sources, the preparation involved successive phases including opening of the cavities and removal of the viscera, preparation of the viscera, internal treatment of the cavities, external application of liniment and wrapping of the deceased. Among the viscera, the brain and the heart appear to have been especially valued as representing part of the identity of the deceased. The composition of the products used to preserve them has been documented based on archaeobotanical and chemical analyses performed on mummified remains^{2,5,8}. Whereas the procedures associated with the treatment of these soft tissues are relatively well understood, historical sources deliver little information on the practical *modus operandi*. How the heart was extracted is still uncertain: it may have been done by laparotomy (opening the abdomen leaving no trace on the bones), by thoracotomy (opening of the thorax at the level of the ribs) or by sternotomy (opening of the sternum). Since surgical encyclopedias barely mention these acts of evisceration and the areas affected outside the head and chest, bioarchaeological studies are the only source that can provide an insight into the practical aspects of these post-mortem treatments. Therefore, the study of the Les Milandes collection makes a significant in-depth contribution to our knowledge of the *modus operandi* and to the documentation of the tools used during the embalming process.

Although the Milandes collection is older, the techniques and tools used seem to be remarkably similar to those illustrated by Dionis (1708) and identified by Signoli and colleagues¹⁷ on an 18th century autopsy case



from Marseille. The first step consists of scalping the skull using the scalpel A or B (Fig. 10a) mentioned in the work of Dionis¹⁸, according to which the operator “will make a longitudinal incision from the root of the nose to the nape of the neck and another transverse incision from one ear to the other cutting the scalp and the pericranium (...), making a cross on the top of the head: he will then lift these four parts which he will separate from the skull,

◀ **Figure 6.** Embalming marks on crania H (a to d), an immature individual who died between 6 months and 1 year of age, I (e to h), an immature individual who died between 1 and 4 years of age, and J (i to k), an immature individual who died between 5 and 14 years of age. (a) Possible inferior part of left parietal, external view; (b) inferior part of left parietal, external view; (c) Supero-median part of the occipital, external view; (d) Possible fragment of parietal, external view; (e) Cut-out part of the frontal bone, anterior view; (f) Cut-out part of the frontal bone, inferior edge; (g) Left supra-orbital part of the frontal bone, anterior view and superior view of the sawn edge; (h) Fragment of the frontal spine, superior or inferior view and left temporal, mastoid process, superior view of the sawn edge; (i) Parietal bones, supero-anterior view; (j) Right supra-orbital region, anterior view; (k) Fragments of right and left temporal bone, internal and external views. © C. Partiot.



Figure 7. A selection of embalming marks on adult and immature postcranial bones. (a) Left tibia in anteromedial view; (b) Right femur, anterior view; (c) Distal third of left humerus, posterior view; (d) Distal half of left humerus, anterior view; (e) Distal half of left ulna, medial view; (f) Sub-complete right clavicle, superior view; (g) Fragment of left ilium, anterior view and (h) Fragment of right ilium, posterior view; (i) Sub-complete left radius, anterior view; (j) Sub-complete phalanx of the hand from IM2, palmar view; (k) Sub-complete metacarpal from IM2, dorsal view; l. Vertebral half of left rib from IM2, superior view. © C. Partiot.

which will fall down leaving the skull uncovered” (Fig. 10b). In the case of immature individual J, the scalp appears to have been removed by not one, but several longitudinal incisions made from the supraorbital region.

The sectioning into the cranium then appears to be partially standardized, with a circular oblique cut starting in the frontal region in 7 of the 9 sawn crania (except cranium F and cranium E), as in numerous documented cases from the West European record, e.g. cases from the medieval cemetery of La Madeleine in Orléans, France¹⁰, from the church of Saint-Hubert in Haccourt, Belgium¹⁹ and from the chapel of Saint Laurent in the Cathedral of Strasbourg, France¹⁵. In cranium E, the cut begins on the parietal bone, a lateral approach beginning in the asterion area²⁰, also noted in the Sens collection from the end of the 15th century. Cranium F, in addition to the classic circular oblique cut, exhibits an atypical antero-posterior cut in the sagittal plane, probably made

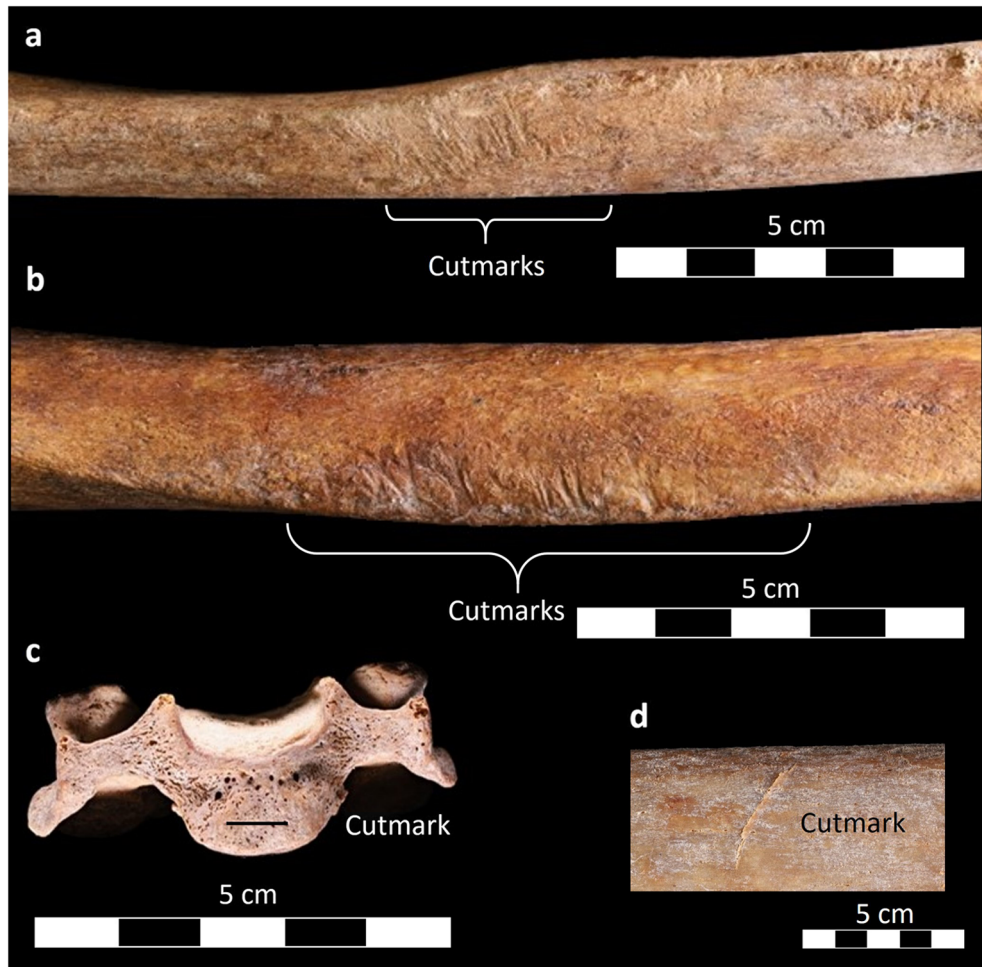

Figure 8. A selection of embalming marks on the individual ML2021 from the individual grave. (a) Right humerus, anterior view; (b) Left tibia, anterior view; (c) Third cervical vertebra, anterior view; (d) Rib fragment, external view. © C. Partiot.

	Area	Type	Edges/slopes	Profile	Symmetry of the edges	Bottom	Max depth	Min depth	Max width	Min width (bottom)
Cranium F	1	Scalping striations	Pseudo-vertical	U	Symmetry	Flat	40	30	30	15
	2	Incision attempts, striated cutmarks	Pseudo-vertical / concave	U	Dissymmetry	Irregular	600	200	1,200	1,000
	9	Striated cutmarks	Concave	U	Symmetry / dissymmetry	Flat / irregular	600	400	1,000	400
	13	Sawing	Vertical / convex	V	Symmetry dissymmetry /	Very irregular	75	50	500	20
	20	Curved sawing	Convex	L	Dissymmetry	Irregular	120	80	800	100
	26	Sawing	Convex / concave	V	Symmetry dissymmetry /	Flat / irregular	100	50	400	100
Cranium I	1	Scalp	no	no	No	No	no	no	no	no
	2	Striated cutmarks	Vertical /convex	V / L	Dissymmetry	Irregular	50	40	400	20
	3	Sawing	Convex	V	Dissymmetry	Irregular	40	20	300	20

Table 1. Synthesis of the morphological and morphometric characteristics of the cutting marks analysed microscopically, no: not observable; D: depth; W: Width; cranium F: adult individual; cranium I: immature individual. For the precise location of the areas analysed on the two crania, see supplementary information n°7 online.

with a curved blade, such as tool D shown in Fig. 10, before manual removal of a large cranium fragment. In Fig. 10, the tool is identified by Dionis (1708), the author, as an *élévatoire*, or trepanning lever, although its shape differs somewhat from the usual pattern for these tools, which were classically used to lever off the calvarium in the final stage of its removal, rather than to cut into the cranial vault (Fig. 10a, tool D). Only one occurrence

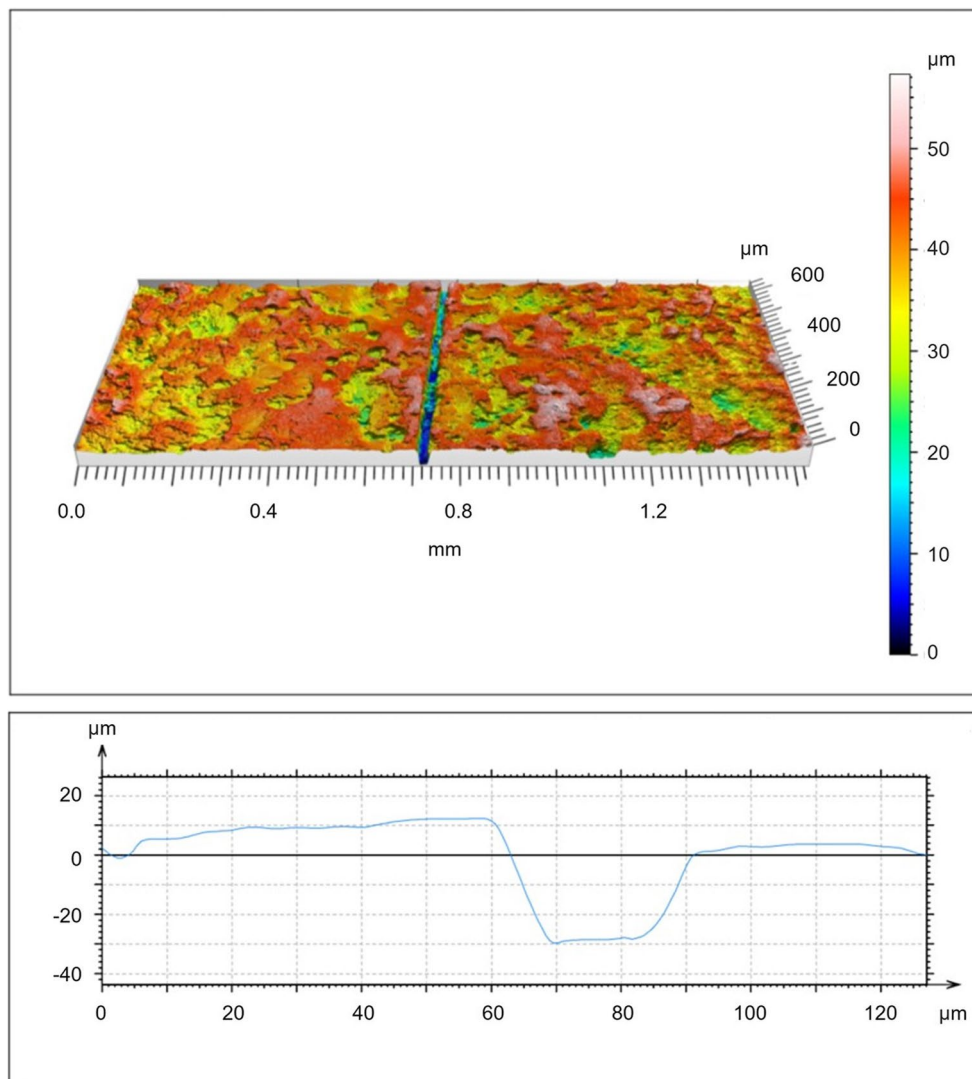


Figure 9. Example of a confocal analysis of scalp cutmark on the adult cranium F. Upper: 3D view of a section of the surface; lower: cross-sectional view of the scalp cutmark. © C. Partiot.

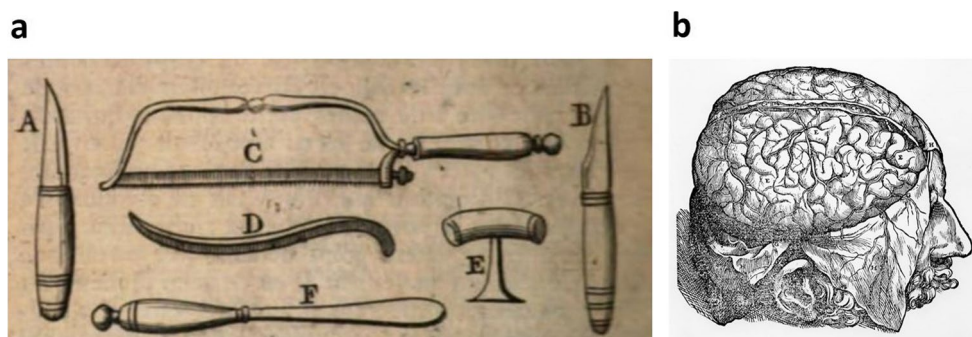

Figure 10. The opening of the cranium. (a) Instruments used for “the opening of a corpse” modified after Dionis (1708, p. 598). A and B: scalpels; C: saw; D: “*élévatoire*”, trepanning lever; E: trephine; F: spatula. (b) Illustration of scalping, modified after Vésale (1543).

of such a procedure involving sagittal sawing and manual bone fracturing has been reported previously, in the medieval sample from the church of Notre-Dame de Cléry-Saint-André²¹. Therefore, and paradoxically, the great care taken to preserve the integrity of the brain, which is illustrated by the frequent manipulations of the head aiming to avoid damage to the underlying soft tissues, did not prevent the operator from employing a very straightforward procedure in this case. Cutting of the vault is, however, not systematically observed in embalming cases from the bioarchaeological record. Cases of thoracic openings without removal of the brain are documented, for example, in the collection from the Jacobin convent of Rennes (France, 16th century⁹).

Regarding the method of evisceration and removal of the heart, three procedures are documented historically: (1) laparotomy, (2) sternotomy and (3) thoracotomy. Laparotomy, i.e. opening of the abdomen to perform visceral exeresis, generally does not leave any trace on bones. Sternotomy involves cutting the sternum along its median plane, so that the two parts of the thorax can be moved apart to reach the heart. The two parts of the sternum would then remain attached to the ribs by the cartilage, enabling the body to be returned to its full volume after the operation. This technique is attested only in rare cases, such as the sawn-off sternums in the tomb of Louis XI in Cléry-Saint-André, in the Ganagobie priory of Saint-Martin des Champs (Paris) and in the funeral chapel of Marguerite of Scotland in the church of Saint-Laon in Thouars²². Thoracotomy, on the other hand, aims to expose the rib cage, separating the sternum from the ribs by severing the connecting cartilage and removing the sternum to gain easy access to the thoracic cavity. In this case, there is no need to section the ribs, and the sternum is removed during the operation. In the Château des Milandes, there are very few cutmarks on the ribs and no sawn rib or complete or fragmented sternum were found, which could support the hypothesis of a thoracotomy. The fact that the few cutmarks observed on the ribs are found on their external surface could indicate that they are associated with the prior removal of soft tissue, and their small number would reflect the care taken in the procedure. This practice would also be consistent with the textual documentation for this chronological period: post-medieval medical and surgical encyclopedias focusing on embalming practices all describe thoracotomy as the most appropriate method for retrieving the heart (Georges, 2006).

A crucial finding of our study is that the embalming process involved an extremely thorough defleshing procedure including the upper and lower limbs down to the tips of the fingers and toes. The operator detached muscle and adipose tissue from the appendicular skeleton by making incisions perpendicular or oblique to the axis of the diaphysis of the long bones and in specific anatomical regions (specifically the mid-diaphysis of the femora, tibiae, humeri, radii and ulnae, as well as the superior surface of the clavicle). While the method for restoring the volume of the thorax is known and documented, the techniques used to restore the volume lost through the removal of the limb muscles are still unclear, since the procedure may have been concealed by covering clothing worn during the presentation of the body. Another finding of particular interest is the transverse section in the anterior region of the third cervical vertebra, probably corresponding to the cut of the trachea, previously reported only at the cervico-thoracic junction in the mummy of Louis Bruslon du Plessis from the Jacobin convent in Rennes⁹.

Since the embalming of children is extremely rare in this chronocultural context, the Les Milandes collection seems to be exceptional, with at least five immature individuals who died before 14 years of age, including three who died between 6 months and 4 years of age. Therefore, one of the main outcomes of the analysis consists of the precise documentation of a protocol for very young children that seems similar to that for adults from the same lineage, and equally careful. The section of the cranial vaults of the individuals who died between the 1 and 4 years of age, an extremely delicate step given the thinness of the bone tables, was performed with special care to preserve the brain as well, as evidenced microscopically by the shallower grooves on cranium I belonging to a child in this age group. In the few archaeological cases of embalming of young children reported in the literature, removal of the brain does not appear to have been systematic, as also observed in adult individuals⁹. In the Medici family group, for example, the perinate underwent craniotomy, but the five-year-old child apparently did not⁶.

In the collection from the Château des Milandes, the cutmarks on the postcranial skeletons of the immature individuals are located in the same anatomical regions as in the adults (mid-diaphysis of the long bones, upper surface of the clavicle). The presence of cutmarks on the anterior surface of the ilium of one infant is indicative of complete evisceration and defleshing of the internal cavities. The fact that the incisions appear somewhat more pronounced in immature individuals is probably due to their thinner soft tissues.

The high number of embalmed individuals and the recurrence of this post-mortem treatment indicate the existence of a tradition of displaying the dead, which is not explicitly mentioned in the textual sources, but which is particularly well established within the family. It aims to ensure a long-lasting mortuary ceremony, probably to give the public time to be informed and to come and pay their respects. The fact that the only comparable occurrence of this practice in Western Europe is in the Medici family, a very high lineage that reigned over the Grand Duchy of Tuscany, reflects the particularly high social status of the Caumont family over many generations, with a strong influence at the regional level and probably beyond. Its application to family members regardless of the age at death and sex also reflects the acquisition of this status by birth and emphasizes the great importance of the event of a death in the lineage.

The recurrence and homogeneity of the gestures observed suggest a certain standardization of the protocol and the employment of skilled operators, either local or from outside the region during the time the chapel was in use, probably for one to two centuries. They seem to be custodians of a *savoir-faire* or know-how, which suggests the existence of systems for transmitting (in writing but maybe also orally?) the details of the *modus operandi*.

Materials and methods

Osteology and assessment of the minimum number of individuals (MNI)

Excavations were conducted using the techniques recommended by Duday²³ and combined with photogrammetric recording²⁴. The first phase involved cleaning the scattered cranial and postcranial bone remains and reassembling them in the laboratory. Sex diagnosis was then performed for adult-sized coxal bones using morphoscopic traits²⁵ and a morphometric method²⁶. Age at death of the adults was estimated based on the metamorphosis of the sacropelvic surface of two *coxal bones*²⁷. The age at death of the immature individuals was assessed primarily from tooth mineralisation using the method of Moorrees and colleagues^{28,29} and from bone growth and maturation^{30–32}. For the infant who died before one year of age, age at death was also estimated in lunar months based on the length of a left humerus and *via* an estimation of stature, using the logarithmic formula from the method of Fazekas and Kósa³³, revised by Sellier and published in Schmitt and Georges³⁴. This method was chosen because the logarithmic formulae provide confidence intervals and can be applied to different long bones of individuals from the foetal stage to four years of age³⁵.

Re-association of cranial fragments

Given the importance of cranial remains for analyses of embalming practices, a specific protocol was established for re-associating the crania and the scattered fragments, following the system of Thibeault and Villotte³⁶. The likelihood of associations between 58 cranial fragments and the reconstructed cranium was assessed two-by-two based on five criteria (see Supplementary information n°1 online), (A) observation of direct reassembly; (B) thickness of the vault; (C) colour of the fragment (D) presence of taphonomic alterations or specific biological characteristics (vascular network, Pacchionion granulations, etc.); (E) morphology of the sutures, and six levels: a) non-observable (comparison impossible due to taphonomic damage); association impossible (overlapping anatomical regions or obvious incompatibilities in age at death); c) association unlikely (strong discrepancies between the fragment and the cranium based on the criteria); d) possible association (the bones do not overlap and the age-at-death assessments are compatible); e) probable association (the characteristics of the fragment are highly compatible with the cranium); f) actual association (direct reassembly).

Macroscopic and microscopic analysis

The cranial and postcranial bones ($N=1885$) were systematically examined macroscopically and with a stereomicroscope for the marks of post-mortem treatment (i.e., cutmarks left by cutting instruments and surfaces and organic material possibly associated with the operation). Each consistent unit of cutmarks (isolated incision or group of nearly identical striae in the same region) was photographed at high magnification using Helicon focus stacking software, and described in a database according to the terminology (see Supplementary information n°2 online) and to 12 criteria based on reference publications in bioarchaeology, archaeozoology and taphonomy^{37–45}:

- location (bone, area, location in relation to the reference plane).
- number (1, 2, 3 or bundle).
- trajectory (straight, slightly bent or curved, sinuous, angular).
- orientation in relation to the reference plane (parallel, oblique, perpendicular).
- length (about 0.5, 1, 2 or more than 3 cm).
- width estimated with the naked eye (thin, medium or wide).
- depth estimated with the naked eye (superficial, medium, deep).
- distance between the striae estimated with the naked eye (in mm, “null” if the striae are next to each other, “abs” if there is only a single cutmark).
- overlap between cutmarks.
- “shoulder effect”.
- internal microstriations.
- “barb effect”.

Based on these descriptions, the relative chronology of the cutmark units was examined to determine the sequence of gestures.

Microscopic analysis

Microscopic analysis of nine selected cutmark units (6 on the adult cranium F and 3 on the immature cranium I) was performed using a SensoFAR confocal microscope and SensoMAP Standard 7 software. Cranium F was selected because it is the only cranium in the collection where the marks of a curved blade tool were identified. Cranium I was selected because of the number of preserved cutmarks, and because its good skeletal representation allowed an accurate analysis of the different stages of the process.

Different types of cutmarks were selected for both crania (scalp marks, saw bounces, saw attempts, saw cuts), of which two consecutive non-destructive casts were made with COLTENE PRÉSIDENT regular silicone. Every second cast was analysed with the confocal microscope in autofocus mode at x20 magnification, creating a 3D view of the surface topography, and then a profile curve, with the surface mirrored in Z and levelled to correct the underlying general shape (levelled least squares method) and with extrapolation of the missing points (filled-in non-measured points, see Supplementary Information n°7 online).

The criteria observed were:

- the nature of the edges (vertical or oblique).
- symmetry or asymmetry of the edges.

- the general profile of the incision (U-shaped or V-shaped).
- the nature of the bottom (flat or irregular).
- an order of magnitude of the minimum and maximum depth of the striae.
- an order of magnitude of the width of their bottoms.

Discrimination between taphonomic alterations and anthropic marks

The differentiation between taphonomic alterations that may mimic cutting marks, on the one hand, and genuine human-made marks, on the other hand, was based on criteria highlighted in the reference taphonomic and archaeozoological publications used for the macroscopic description^{37–45}, as well as on the experience of the observers, who are familiar with various osteological collections from different contexts. Several factors were therefore taken into account to identify and exclude taphonomic alterations of potentially different origin (sediments, roots, animals, etc.).

Excluded were marks located in areas with poorly preserved cortex, shallow striae with a particularly irregular or blunt trajectory, marks with rounded bottom and blunt outer edges, or bundles with multiple randomly oriented striae.

In some cases (e.g. the long bones of the individual ML2021, Fig. 8a and b), the symmetry of marks between the left and right sides of the same individual has been a factor in ruling out a taphonomic origin. In others, (e.g. putative scalp marks on immature crania), the hypothesis of taphonomic marks was ruled out based on the microscopic features of the striae³⁸ (for cranium J) or the similarity in morphology and trajectory with microscopically attested cutmarks. If the human-made nature of the marks was still ambiguous after macroscopic observation and binocular magnification, they were excluded from the analyses as a precaution.

Data availability

The scattered remains from the crypt are available for study on request at the CNRS UMR 5199 PACEA laboratory (Université de Bordeaux, Bâtiment B8, Allée Geoffroy Saint Hilaire, 33615 Pessac, France). The remains of the elderly lady ML2021 have been reburied on the site. The dataset with the macroscopic description of each consistent unit of cutmarks is available in French from the corresponding author on reasonable request.

Received: 18 March 2024; Accepted: 29 October 2024

Published online: 14 November 2024

References

1. Corbineau, R. & Georges-Zimmermann, P. Le parfum de la mort. Plantes et aromates pour la préparation des corps (Moyen Âge et période Moderne). In *Micrologus. Parfums et Odeurs au Moyen Âge – Science, Usage, Symboles*. (eds. Agostino Paravicini Bagliani, A.) 161–180 (SISMEL, Edizioni del Galluzzo, 2015).
2. Corbineau, R. et al. Plants and aromatics for embalming in Late Middle Ages and modern period: a synthesis of written sources and archaeobotanical data (France, Italy). *Veget. Hist. Archaeobot.* **27**, 151–164 (2018).
3. Colleter, R. L'embaumement et les funérailles multiples au couvent des Jacobins. In *Louise de Quengo, une Bretonne du XVII^e siècle: Archéologie, Anthropologie, Histoire* (eds. Colleter, R., Pichot, D. & Crubézy, É) 225–239 (Presses universitaires de Rennes, Rennes, 2021).
4. Biotti-Mache, F. Thanatopraxis through History. *Etudes sur la mort* **143**, 13–59 (2013).
5. Giuffra, V. et al. Embalming methods and plants in Renaissance Italy: two artificial mummies from Siena (central Italy). *J. Archaeol. Sci.* **38**, 1949–1956 (2011a).
6. Giuffra, V. et al. The children of the Medici, grand dukes of Florence: embalming in renaissance Italy (XVI–XVII century). *Atti della Società Toscana di Scienze Naturali Residente in Pisa Memorie serie B*, 81–88 (2011b).
7. Charlier, P. et al. The embalmed heart of Richard the Lionheart (1199 A.D.): a biological and anthropological analysis. *Sci. Rep.* **3**, 1296 (2013).
8. Charlier, P. et al. The embalming of John of Lancaster, first Duke of Bedford (1435 AD): A forensic analysis. *Med. Sci. Law.* **56**, 107–115 (2016).
9. Colleter, R. et al. Procedures and frequencies of embalming and heart extractions in Modern Period in Brittany. Contribution to the evolution of ritual funerary in Europe. *PLoS One.* **11**, e0167988 (2016).
10. Kacki, S., Georges, P. & Blanchard, P. Un cas de sciage crânien avorté chez un sujet du cimetière médiéval de la Madeleine à Orléans (Loiret). *Rev. Archéol. Loiret.* **33**, 45–52 (2009).
11. Fornaciari, G. et al. Autopsy and embalming of the Medici, Grand Dukes of Florence (16th–18th centuries). In *Proceedings of the VI World Congress on Mummy Studies, Lanzarote: Academia Canaria de la Historia*. 325–331 (2008).
12. Hershkovitz, I. et al. Hyperostosis frontalis interna: an anthropological perspective. *Am. J. Phys. Anthropol.* **109**(3), 303–325 (1999).
13. Lewis, M. *Paleopathology of children: Identification of pathological conditions in the human skeletal remains of non-adults*. (Academic Press, Cambridge, 2017).
14. Bêcheau, A., Castex, D. & Bessou, M. Vivre et mourir aux Milandes au temps des Caumont. In *Mourir au château - Actes des Rencontres d'Archéologie et d'Histoire en Périgord, Scripta Mediaevalia*. (dir. Cocula, A.-M., & Combet, M.) 11–29 (Editions Ausonius, Bordeaux, 2022).
15. Georges, P. *La pourriture escamotée: cachez ce cadavre que je ne saurais voir! Quelques destins post mortem de la protohistoire à nos jours à la lumière de l'archéologie(thanato)logie: étudier les os, appréhender le corps*. Doctoral thesis, Université Toulouse 2 - Jean Jaurès. (2020).
16. Park, K. The life of the corpse: division and dissection in late Medieval Europe. *J. Hist. Med. Allied. Sci.* **50**, 111–132 (1995).
17. Signoli, M., Léonetti, G., Champsaur, P., Brunet, C. & Dutour, O. Mise en évidence d'une autopsie crânienne réalisée pendant la Grande Peste de Marseille (1720–1722). *C. R. Acad. Sci. III* **320**, 575–580 (1997).
18. Dionis, P. *Cours d'opérations de chirurgie démontrés au jardin royal*. (ed. Les frères T'Serstevens, Paris, 1708).
19. Masy, P. Quatre cas d'ouverture volontaire de la boîte crânienne dans des sépultures médiévales tardives ou post-médiévales. *Bull. Chérch. Wallonie* **35**, 79–101 (1995).
20. Valentin, F. & d'Errico, F. Skeletal evidence of operations on cadavers from Sens (Yonne, France) at the end of the XVth century. *Am. J. Phys. Anthropol.* **98**, 375–390 (1995).
21. Kacki, S., Crâne du caveau, F. In *Les Sépultures Prestigieuses de l'Eglise Notre-Dame de Cléry-saint-André (Loiret): Etude Pluridisciplinaire du Caveau de Louis XI* (dir. George-Zimmermann, P.) 1–386 (Editions L'Harmattan, Paris, 2015).

22. Georges, P. L'embaulement et le prélèvement du cœur au Moyen-Âge: le sciage du sternum. In *Collection Pathographie* (dir. Charlier, P.) 54–72 (De Boccard, Paris, 2006).
23. Dудay, H. & Cipriani, A. M. *The Archaeology of The Dead: Lectures in Archaeoanthatology*. (Oxbow Books, 2009).
24. Sachau-Carcel, G., Castex, D. & Vergnieux, R. Sites à stratification complexe et modélisation tridimensionnelle : vers une nouvelle approche des sépultures multiples. *Archeosci.* 89–104 (2013).
25. Bruzek, J. A method for visual determination of sex, using the human hip bone. *Am. J. Phys. Anthropol.* **117**, 157–168 (2002).
26. Bruzek, J., Santos, F., Dutailly, B., Murail, P. & Cunha, E. Validation and reliability of the sex estimation of the human os coxae using freely available DSP2 software for bioarchaeology and forensic anthropology. *Am. J. Phys. Anthropol.* **164**, 440–449 (2017).
27. Schmitt, A. Une nouvelle méthode pour estimer l'âge au décès des adultes à partir de la surface sacro-pelvienne iliaque. *BMSAP* **17**, 89–101 (2005).
28. Moorrees, C. F. A., Fanning, E. A. & Hunt, E. E. Formation and resorption of three deciduous teeth in children. *Am. J. Phys. Anthropol.* **1**, 205–213 (1963).
29. Moorrees, C. F. A., Fanning, E. A. & Hunt, E. E. Age variation of formation stages for ten permanent teeth. *J. Dent. Res.* **42**, 1490–1502 (1963).
30. Maresh, M. M. Measurements from roentgenograms, heart size, long bone lengths, bone, muscles and fat widths, skeletal maturation. in *Human Growth and Development*. (dir. McCammon, R.W.) 155–200 (Charles C. Thomas publisher, Springfield, 1970).
31. Schaefer, M., Scheuer, L. & Black, S. M. *Juvenile osteology: a laboratory and field manual*. (Elsevier/Academic Press, Cambridge, 2009).
32. Scheuer, L. & Black, S. M. *Developmental juvenile osteology* (Academic Press, San Diego, 2000).
33. Fazekas, I. G. & Kósa, F. *Forensic foetal osteology*. (1978).
34. Schmitt, A. & Georges, P. Quelle démarche suivre pour estimer l'âge au décès à partir du squelette? in *Manuel Pratique de Paleopathologie Humaine* (dir. Charlier, P.) 269–280 (De Boccard, Paris, 2008).
35. Sellier, P., Tillier, A.-M. & Bruzek, J. À la recherche d'une référence pour l'estimation de l'âge des foetus, nouveau-nés et nourrissons. *Anthropol. Préhis.* **108**, 75–87 (1997).
36. Thibeault, A. & Villotte, S. Disentangling Cro-Magnon: A multiproxy approach to reassociate lower limb skeletal remains and to determine the biological profiles of the adult individuals. *J. Archaeol. Sci. Rep.* **21**, 76–86 (2018).
37. Marginedas, F. et al. Making skull cups: Butchering traces on cannibalised human skulls from five European archaeological sites. *J. Archaeol. Sci.* **114**, 105076 (2020).
38. Domínguez-Rodrigo, M., de Juana, S., Galán, A. B. & Rodríguez, M. A new protocol to differentiate trampling marks from butchery cut marks. *J. Archaeol. Sci.* **36**, 2643–2654 (2009).
39. Maté-González, M. Á. et al. Assessment of statistical agreement of three techniques for the study of cut marks: 3D digital microscope, laser scanning confocal microscopy and micro-photogrammetry. *J. Microsc.* **267**, 356–370 (2017).
40. Maté-González, M. Á., Yravedra, J., González-Aguilera, D., Palomeque-González, J. F. & Domínguez-Rodrigo, M. Micro-photogrammetric characterization of cut marks on bones. *J. Archaeol. Sci.* **62**, 128–142 (2015).
41. Domínguez-Rodrigo, M. et al. Use and abuse of cut mark analyses: The Rorschach effect. *J. Archaeol. Sci.* **86**, 14–23 (2017).
42. Bromage, T. G. & Boyde, A. Microscopic criteria for the determination of directionality of cutmarks on bone. *Am. J. Phys. Anthropol.* **65**, 359–366 (1984).
43. Santana, J., Rodríguez-Santos, F. J., Camalich-Massieu, M. D., Martín-Socas, D. & Fregel, R. Aggressive or funerary cannibalism? Skull-cup and human bone manipulation in Cueva de El Toro (Early Neolithic, southern Iberia). *Am. J. Phys. Anthropol.* **169**, 31–54 (2019).
44. Costamagno, S., Soulier, M.-C., Val, A. & Chong, S. The reference collection of cutmarks. *Paleth. Archéol. Sci. Hum.* **10**, 186–280 (2019).
45. Souron, A. et al. A new geometric morphometrics-based shape and size analysis discriminating anthropogenic and non-anthropogenic bone surface modifications of an experimental data set. In *Proceedings of the IMEKO TC-4 International Conference on Metrology for Archaeology and Cultural Heritage, Florence, Italy*. (ed. International Measurement Confederation IMEKO) 560–565 (2019).

Acknowledgements

This study received financial support from the French government in the framework of the University of Bordeaux's IdEx “Investments for the Future” program / GPR “Human Past”, from grant funding to the Nouvelle-Aquitaine Regional Archeology Service and from the Austrian Archaeological Institute at the Austrian Academy of Sciences via the Bioarchaeology Lab - Archaeological Sciences coordinated by Andreas G. Heiss and Alfred Galik. We particularly thank Hervé Gaillard and Patrice Buraud from the Nouvelle-Aquitaine Regional Archeology Service for taking part in the excavation and the post-excavation studies, Anne Bécheau for the historical investigations, Antoine Souron and Eric Pubert for their support with the confocal microscope, and Christopher J. Knüsel for his advice. We particularly thank Ilona Bossanyi for her assistance in editing the article prior to submission. We would like to offer our warmest thanks to Angélique de Labarre, owner of the Château des Milandes, for granting the necessary permissions and for her unfailing support.

Author contributions

CP designed the study of embalming stigmata and the protocol, analysed the remains with scientific advice from D.C., M.B., G.S-C and S.K., and drafted the manuscript. D.C. coordinated the project with the research funding and scientific advice and led the excavation in which M.B., M.P. and G.S-C took part. M.B., M.P. and G.S-C carried out the first archaeo-anthropological studies and interpretations in situ and in the laboratory, with G.S-C taking charge of the 3D processes. All the authors reviewed and edited the manuscript.

Declarations

Ethics statement

The research was conducted in accordance with all French ethical and legal guidelines for the excavation, handling, and analysis of archaeological human remains. The remains were handled with care to minimize disturbance and preserve their integrity for future research, with some remains being partially reburied in situ.

Competing interests

The authors declare no competing interests.

Additional information

Supplementary Information The online version contains supplementary material available at <https://doi.org/10.1038/s41598-024-78258-w>.

Correspondence and requests for materials should be addressed to C.P.

Reprints and permissions information is available at www.nature.com/reprints.

Publisher's note Springer Nature remains neutral with regard to jurisdictional claims in published maps and institutional affiliations.

Open Access This article is licensed under a Creative Commons Attribution-NonCommercial-NoDerivatives 4.0 International License, which permits any non-commercial use, sharing, distribution and reproduction in any medium or format, as long as you give appropriate credit to the original author(s) and the source, provide a link to the Creative Commons licence, and indicate if you modified the licensed material. You do not have permission under this licence to share adapted material derived from this article or parts of it. The images or other third party material in this article are included in the article's Creative Commons licence, unless indicated otherwise in a credit line to the material. If material is not included in the article's Creative Commons licence and your intended use is not permitted by statutory regulation or exceeds the permitted use, you will need to obtain permission directly from the copyright holder. To view a copy of this licence, visit <http://creativecommons.org/licenses/by-nc-nd/4.0/>.

© The Author(s) 2024