



HAL
open science

Ultrasonographic evaluations of stomach and colostrum intake in newborn piglets

Boulot S, Hervé G

► **To cite this version:**

Boulot S, Hervé G. Ultrasonographic evaluations of stomach and colostrum intake in newborn piglets. IPVS-ESPHM 2024, Jun 2024, Leipzig (DE), France. 2024. hal-04779234

HAL Id: hal-04779234

<https://hal.science/hal-04779234v1>

Submitted on 13 Nov 2024

HAL is a multi-disciplinary open access archive for the deposit and dissemination of scientific research documents, whether they are published or not. The documents may come from teaching and research institutions in France or abroad, or from public or private research centers.

L'archive ouverte pluridisciplinaire **HAL**, est destinée au dépôt et à la diffusion de documents scientifiques de niveau recherche, publiés ou non, émanant des établissements d'enseignement et de recherche français ou étrangers, des laboratoires publics ou privés.



Ultrasonographic evaluations of stomach and colostrum intake in newborn piglets



Sylviane Boulot, **Gwendoline Hervé**
IFIP-Institut du porc, 9 Boulevard du Trieux, 35740 Pacé, France
sylviane.boulot@ifip.asso.fr

In large litters, poor colostrum intake and hypothermia are major causes of pre-weaning mortality, with high rates of empty stomachs (40 to 70%) in necropsied piglets. Early detection of colostrum deprivation would support better care and survival. However, subjective evaluations on liveborn are imprecise.

The aim of this study is to evaluate the suitability of ultrasonographic stomach examination for future non-invasive real time detection of poor colostrum intake.

Conclusion

These preliminary results on piglets suggest that ultrasonographic pictures may vary according to milk intake, stage of digestion and cause of death. Despite suckling and swallowing may increase stomach air content and detrimental artefacts, this tool proved to be accurate for detection of empty stomachs in human beings. More data are required to evaluate accuracy on live animals.

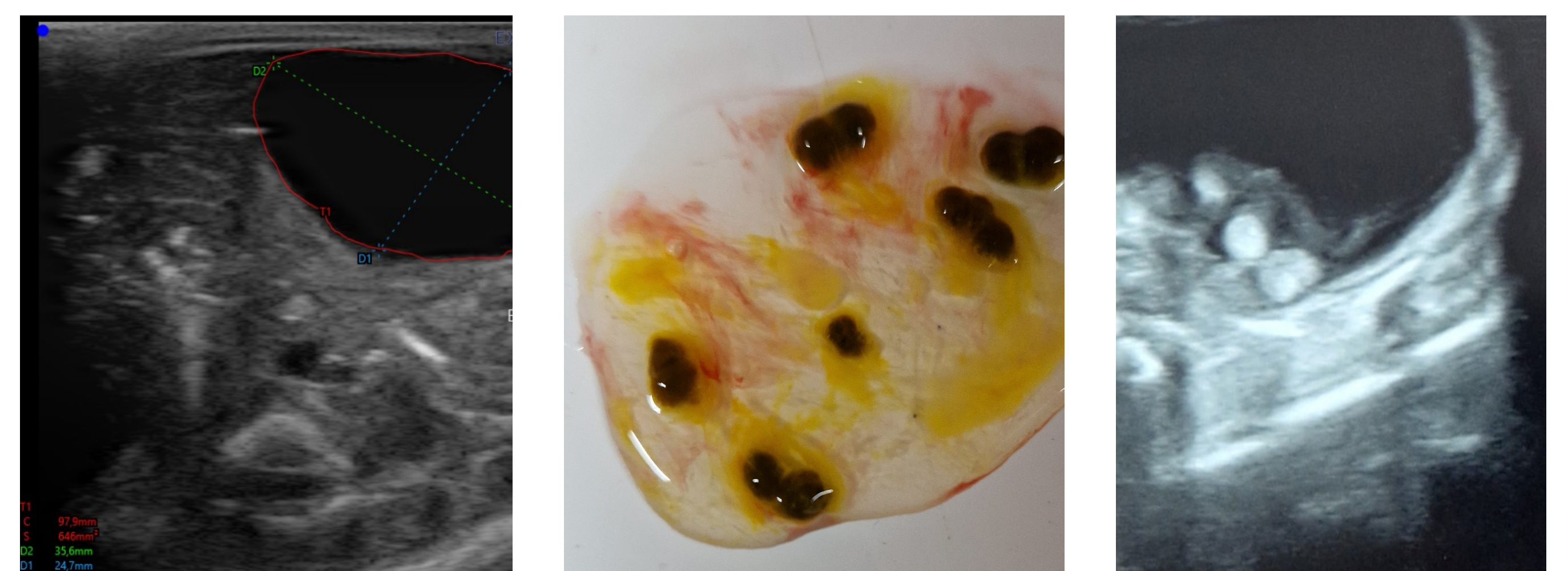Material and methods

Study took place in IFIP experimental farm

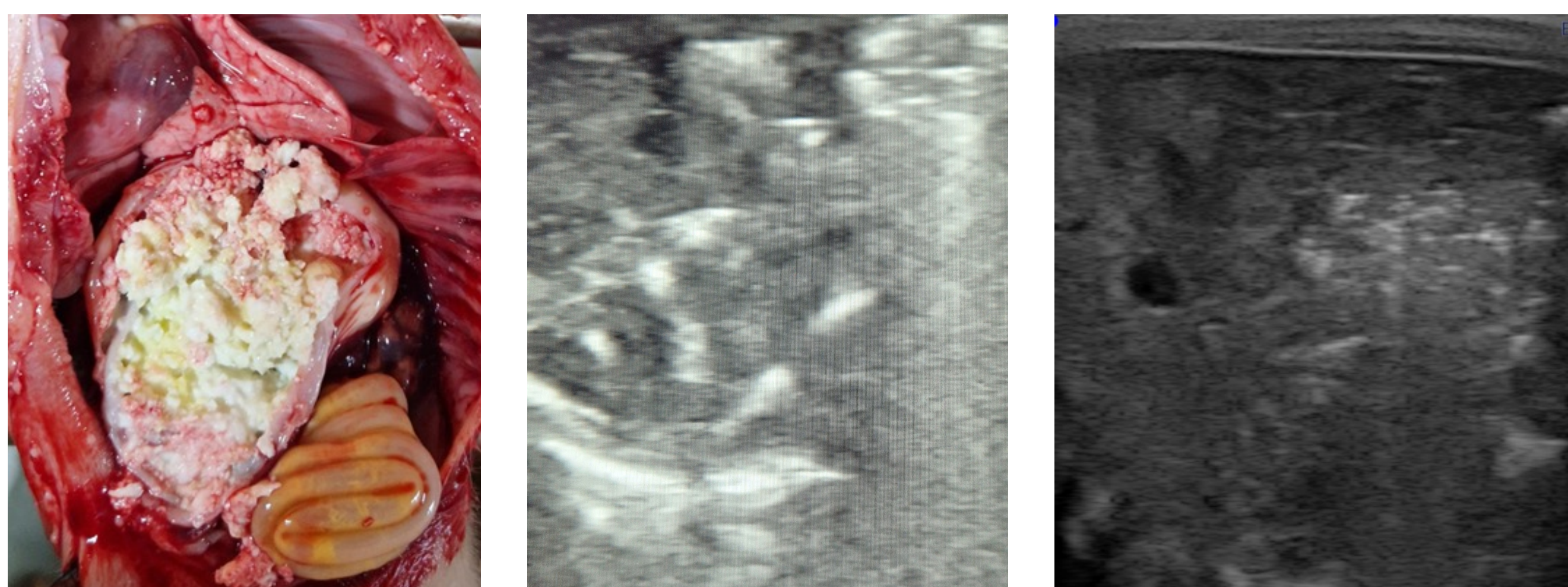
- Piglets born in large litters (17.7 ± 4.7 total born), found dead at birth (N = 20) or within 2 days (N = 20)
- Ultrasonographic examinations of lungs and abdomen were performed in supine and lateral decubitus positions (5 - 7.5 MHz linear probe, Exapad®)
- Morphological analysis: birth weight, Intra Uterine Growth Retardation score (IUGR), hoof-tip status, wounds, signs of crushing
- Necropsies for confirmation of status (stillborn/liveborn) and analysis of stomach content
- Reference pictures were collected after echo guided injections of milk (fresh, clotted) and air, in empty stomachs of stillborn piglets

Results

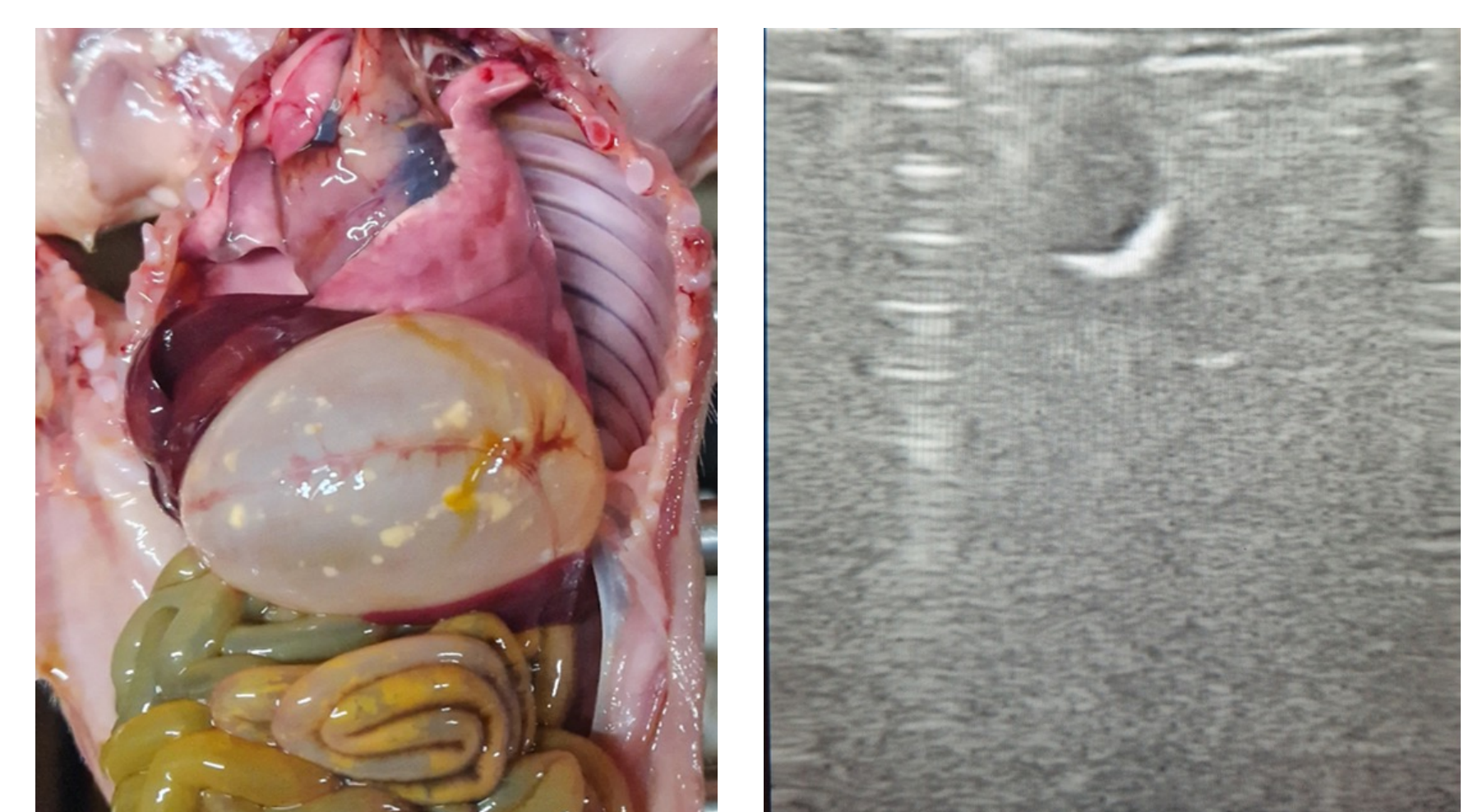
- Large size of the liver limits visualization: supine position provides the best pictures
- In stillborn piglets, stomach is easily located. It is full of amniotic fluid and hypoechogenic pictures are dark and round, without artefacts
- Replacement of amniotic fluid by milk shows echogenic round picture of stomach content, with clotting and air associated with perturbations or artefacts
- In many liveborn piglets found dead, stomach is full of gas, with none or small colostrum particles. In these cases, abdomen and stomach contents are masked by aeration shadowing artefacts



In stillborn piglets, stomach is full of hypoechogenic amniotic fluid. Meconium beads may provide small round hyper-echogenic signals.



Clotted milk causes white hyper-echogenic signals showing « frosted glass » or « starry-night » aspects in case of minor air content probably related to suckling.



In piglets found dead after birth, acoustic shadowing and artefacts frequently mask the stomach, mainly due to abnormal large gas content.