



HAL
open science

Long-term and transient body representation plasticity after left brachial plexus avulsion

Sébastien Mateo, Flimmy Agon, Yves Rossetti, Karen T Reilly, Gilles Rode

► **To cite this version:**

Sébastien Mateo, Flimmy Agon, Yves Rossetti, Karen T Reilly, Gilles Rode. Long-term and transient body representation plasticity after left brachial plexus avulsion. *Cortex*, 2024, 174, pp.215-218. 10.1016/j.cortex.2024.03.005 . hal-04773065

HAL Id: hal-04773065

<https://hal.science/hal-04773065v1>

Submitted on 8 Nov 2024

HAL is a multi-disciplinary open access archive for the deposit and dissemination of scientific research documents, whether they are published or not. The documents may come from teaching and research institutions in France or abroad, or from public or private research centers.

L'archive ouverte pluridisciplinaire **HAL**, est destinée au dépôt et à la diffusion de documents scientifiques de niveau recherche, publiés ou non, émanant des établissements d'enseignement et de recherche français ou étrangers, des laboratoires publics ou privés.



Clinical Postcard

Long-term and transient body representation plasticity after left brachial plexus avulsion

Sébastien Mateo ^{a,b,*}, Flimmy Agon ^a, Yves Rossetti ^{a,b},
Karen T. Reilly ^{a,1} and Gilles Rode ^{a,b,1}

^a Université de Lyon, Université Lyon 1, INSERM U1028, CNRS UMR5292, Lyon Neuroscience Research Center, Trajectoires Team, Lyon, France

^b Hospices Civils de Lyon, Hôpital Henry Gabrielle, Plate-forme Mouvement et Handicap, Lyon, France

ARTICLE INFO

Article history:

Received 19 February 2024

Reviewed 21 February 2024

Revised 7 March 2024

Accepted 18 March 2024

Action editor Sergio Della Sala

Published online 21 March 2024

Supernumerary phantom limb (SPL) is a phenomenon in which people perceive an extra limb in addition to their own arms and legs. Despite being experienced by patients with stroke (Cipriani et al., 2011), or with brachial plexus avulsion (BPA – Lhermitte, 1960), this body representation disorder has rarely been investigated systematically, with most studies focusing instead on pain and the efficacy of pain treatments. Here we describe long-term (>10 years) changes in the SPL of an individual with left BPA as well as transient changes following two sessions of mirror therapy 11 years after his accident. We propose several hypotheses to explain long-term and transient changes in body representation after BPA.

1. Long term changes in SPL

In 2002, MD was 55 years old when he experienced a complete left-sided BPA due to a road traffic accident. MRI confirmed the

absence of any brain or spinal cord lesions but revealed a left plexus brachial injury from C5 to T1, including complete avulsion of C6 and C7 roots. The extent of the nerve injury precluded neurosurgery. Clinical examination revealed i) complete paralysis of all left upper limb muscles (0/5 on the Manual muscle test MRC score); ii) absence of all left upper limb osteotendinous reflexes; iii) absence of somatosensory sensations in dermatomes C5 to T1, presence of decreased sensation in C4 and the pectoral part of T2; and iv) no cognitive or psychiatric disorder. At this time MD described having a **permanent** SPL that was the same size as his left forearm and hand but was attached to his paralyzed arm at the elbow (laterally deviated by 60° to the forearm axis – see Fig. 1). The phantom hand was permanently closed into a fist and was cramped and painful. Ten years later, in 2012, clinical examination revealed no change in the paralysis of the left upper limb muscles and osteotendinous areflexia, but partial recovery of sensation in C5 and the arm part of T2, as well as changes in the size, position, permanence, and sensations of

* Corresponding author. Hôpital Henry Gabrielle, F-69230 Saint Genis Laval, France.

E-mail address: sebastien.mateo@chu-lyon.fr (S. Mateo).

¹ Authors contributed equally to this work.

<https://doi.org/10.1016/j.cortex.2024.03.005>

0010-9452/© 2024 Published by Elsevier Ltd.

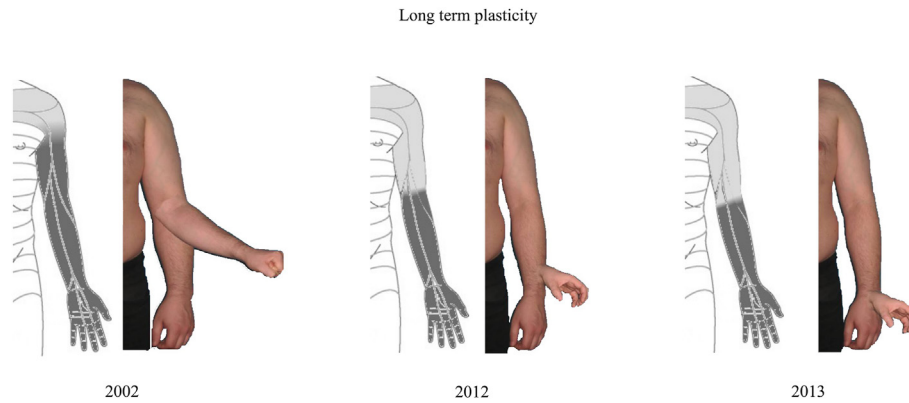


Fig. 1 – Changes from 2002 to 2013 in the extent of somatosensory deficit and in the size and position of the supernumerary phantom limb in a patient with left chronic plexus brachial avulsion. The size and position of the phantom were assessed using a somatosensory-to-visual matching task. MD was presented with static color images of his left paralyzed upper limb. He was asked to indicate i) the size of his phantom limb ii) its position and orientation. MD was seated in front of a table and observed an A4 color image (21 cm × 29.7 cm) displaying the head, the trunk, and both upper limbs. Assessments were performed at three different times (2002, 2012 and 2013) during routine medical consultations related to his longitudinal medical care. The medical examination included an in-depth assessment of left upper limb somatosensory sensation (light touch and deep touch). Dark grey refers to no sensations whereas light grey to decreased sensations. Note the progressive recovery from absent to decreased sensations (light touch) in the C5 and arm part of T2 in 2012 and until just below the elbow in 2013 along with changes in the reported length and position of the SPL.

the SPL. The forearm had disappeared, and the phantom now consisted of only the wrist, hand, and fingers. As in 2002, it was the same size as his left hand, but rather than being attached at the elbow it was now attached more distally, near the lower end of the forearm. Furthermore, it was only present when he focused on it (**non-permanent**) and the painful cramping sensation described during the first clinical examination had been replaced by spontaneous, short-lasting, painful electrical discharge sensations. Another notable change was the fact that MD could now make voluntary movements with the SPL like wrist and finger flexion/extension and hand orienting using pronation/supination. In 2013, clinical examination revealed further improvement, albeit slight, with incomplete recovery of somatosensory sensations until just below the elbow. The SPL remained **non-permanent**, was the same size and shape as his left hand and was attached at the dorsal part of the wrist joint - even more distally than in 2012. He was still able to make voluntarily movements that included opposition between the thumb and index and middle fingers (see Fig. 1).

Phantom sensations experienced by stroke patients might be due to subtotal somatosensory deafferentation and defective motor efference (Antoniello et al., 2010). If the SPL experienced by MD for more than 10 years after his BPA is caused by similar mechanisms, then changes in its perceptual properties (size and position) could be explained by alterations in somatosensory input following somatosensory recovery. Similarly, the appearance of kinesthetic properties (voluntary movements) between the first and second clinical examinations might be related to alterations in motor planning (Staub et al., 2006).

An fMRI investigation of a patient with a right subcortical stroke who reported a SPL with both perceptual and kinesthetic properties that she could ‘feel, see, and intentionally

move’ (Khateb et al., 2009, p. 699) revealed activity within somesthetic parietal areas when she scratched her left cheek with her phantom limb. The posterior parietal cortex (PPC) plays a major role in multisensory plasticity and appears to contribute to cross-modal plasticity after somatosensory deafferentation (Gilissen & Arckens, 2021). Since motor imagery is impaired when it is lesioned, the PPC also appears to be involved in generating mental movement representations (Sirigu et al., 1996). Processing motor intention within the posterior parietal cortex (PPC) seems to be intricately linked with sensory prediction, while intention within the supplementary motor area (SMA) is more strongly associated with motor commands (Desmurget et al., 2009). The somesthetic and kinesthetic dimensions of the SPL might therefore rely on PPC activity (Anderson & Lenz, 2011). As such, recovery-related reorganizational changes involving the PPC, the premotor cortex, the SMA and the thalamus could explain the changes we observed in both the somesthetic and kinesthetic dimensions of MD’s SPL, similar to cortical changes observed in cases of SPL reported after spinal cord injury (Moore et al., 2000).

2. Transient changes in SPL in response to mirror therapy

During a three-day hospital admission in 2013, MD participated in two sessions of therapist-supervised mirror therapy (separated by one day). The aim of these sessions was to enable him to self-administer mirror therapy at home to improve his body representation. In each session we investigated transient changes in the somesthetic and kinesthetic properties of his SPL. He could only see the mirror image of his

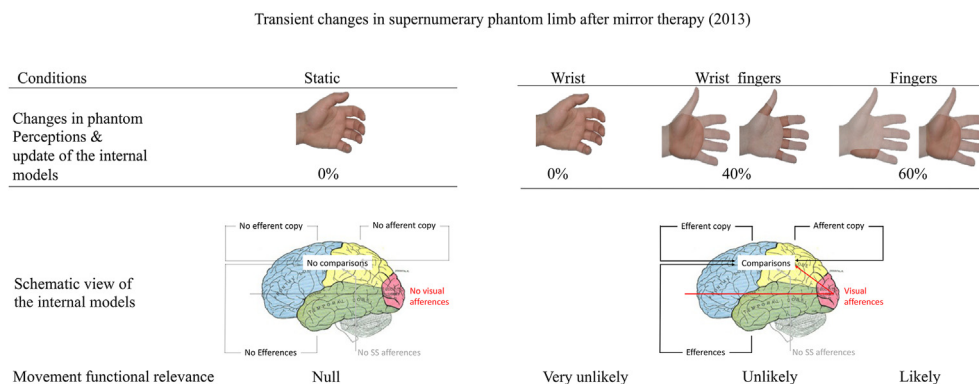


Fig. 2 – Upper panel: Changes in the perceptual properties of the phantom limb after a mirror session. Percentages represent the reduction in size of the SPL relative to the intact hand. Note that the SPL was reduced only when MD observed movements involving the fingers. Lower panel: a possible explanation of these changes based on internal models. SPL changes might rely on internal model updates which in turn rely on movements with functional/ecological relevance (i.e., those involving the fingers).

functioning right hand (paralyzed left hand was positioned behind the mirror and right hand hidden from direct view). Four different conditions were delivered in a random order during the mirror sessions: 1) observation of a static hand; cyclic (.1 Hz) flexion/extension movements of the 2) wrist, 3) fingers, 4) combination of both wrist and fingers. A semi-structured interview was used to document changes in SPL manifestations, including a specific question about any change in its size (expressed as a percentage relative to the paralyzed hand's surface area). MD never reported any change in the SPL when he observed the static hand, nor when he observed cyclic flexion/extension movements of his right wrist in the mirror. In contrast, he reported that parts of the phantom disappeared when he observed flexion/extension movements of the fingers alone or in combination with the wrist (see Fig. 2).

It has been known for many years that mirror therapy with amputees can both produce phantom limb sensations and alleviate phantom pain (Ramachandran & Rogers-Ramachandran, 1996). To our knowledge, however, this is the first report showing that mirror therapy can produce an immediate, transient effect of reducing the somesthetic perception of a SPL. Interestingly, changes in the SPL observed on day 1 and day 2 of the mirror therapy were different, although they were always triggered by finger alone or a combination of finger and wrist movements, and never by wrist movements alone or by observation of a static hand.

Internal action model theories suggest that movements are associated with multiple efferent copies and that comparison between efferent copies as well as between afferences and efferences results in correction of subsequent actions and ongoing perception adjustments (Wolpert et al., 1995). The partial elimination of MD's SPL could be due to incomplete updating of internal models, the long-term changes due to sensorimotor recovery and the variability in transient changes after mirror therapy due to noise in the motor control system (Leib et al., 2023). Based on these ideas, mirror therapy given at a different time in the recovery process would likely produce different effects, and the transient changes in the SPL

observed after each session might become more similar following more intensive mirror therapy training.

Future studies should further investigate long-term and transient changes in SPL at various times after BPA using neuroimaging combined with narrative and neuropsychological methods. This will help gain a better understanding of the complex relationship between SPL, motor planning, brain plasticity and body representation disorders.

CRediT authorship contribution statement

Sébastien Mateo: Writing – review & editing, Writing – original draft, Visualization, Validation, Software, Resources, Methodology, Investigation, Formal analysis, Data curation, Conceptualization. **Flimmy Agon:** Writing – review & editing, Writing – original draft, Visualization, Methodology, Investigation, Formal analysis, Data curation, Conceptualization. **Yves Rossetti:** Writing – review & editing, Writing – original draft, Visualization, Validation, Investigation, Data curation. **Karen T. Reilly:** Writing – review & editing, Writing – original draft, Visualization, Validation, Supervision, Project administration, Methodology, Investigation, Formal analysis. **Gilles Rode:** Writing – review & editing, Writing – original draft, Visualization, Validation, Supervision, Resources, Project administration, Methodology, Investigation, Formal analysis, Conceptualization.

Acknowledgments

We have no funding for this work.

REFERENCES

Anderson, W. S., & Lenz, F. A. (2011). Review of motor and phantom-related imagery. *NeuroReport*, 22(17), 939–942. <https://doi.org/10.1097/WNR.0b013e32834ca58d>

- Antonietto, D., Kluger, B. M., Sahlein, D. H., & Heilman, K. M. (2010). Phantom limb after stroke: An underreported phenomenon. *Cortex; a Journal Devoted To the Study of the Nervous System and Behavior*, 46(9), 1114–1122. <https://doi.org/10.1016/j.cortex.2009.10.003>
- Cipriani, G., Picchi, L., Vedovello, M., Nuti, A., & Fiorino, M. D. (2011). The phantom and the supernumerary phantom limb: Historical review and new case. *Neuroscience Bulletin*, 27(6), 359–365. <https://doi.org/10.1007/s12264-011-1737-6>
- Desmurget, M., Reilly, K. T., Richard, N., Szathmari, A., Mottolese, C., & Sirigu, A. (2009). Movement intention after parietal cortex stimulation in humans. *Science*, 324(5928), 811–813. <https://doi.org/10.1126/science.1169896>
- Gilissen, S. R., & Arckens, L. (2021). Posterior parietal cortex contributions to cross-modal brain plasticity upon sensory loss. *Current Opinion in Neurobiology*, 67, 16–25. <https://doi.org/10.1016/j.conb.2020.07.001>
- Khateb, A., Simon, S. R., Dieguez, S., Lazeyras, F., Momjian-Mayor, I., Blanke, O., Landis, T., Pegna, A. J., & Annoni, J.-M. (2009). Seeing the phantom: A functional magnetic resonance imaging study of a supernumerary phantom limb. *Annals of Neurology*, 65(6), 698–705. <https://doi.org/10.1002/ana.21647>
- Leib, R., Howard, I. S., Millard, M., & Franklin, D. W. (2023). Behavioral motor performance. In Y. S. Prakash (Ed.), *Comprehensive physiology* (1st ed., pp. 5179–5224). Wiley. <https://doi.org/10.1002/cphy.c220032>
- Lhermitte, F. (1960). *Les perturbations somatognosiques en pathologie nerveuse: Rapport de neurologie présenté au Congrès de Psychiatrie et de Neurologie de Langue Française, LVIIIe session—Lille—27 Juin—2 Juillet 1960*. Masson.
- Moore, C. I., Stern, C. E., Dunbar, C., Kostyk, S. K., Gehi, A., & Corkin, S. (2000). Referred phantom sensations and cortical reorganization after spinal cord injury in humans. *Proceedings of the National Academy of Sciences*, 97(26), 14703–14708. <https://doi.org/10.1073/pnas.250348997>
- Ramachandran, V. S., & Rogers-Ramachandran, D. (1996). Synaesthesia in phantom limbs induced with mirrors. *Proceedings. Biological Sciences*, 263(1369), 377–386. <https://doi.org/10.1098/rspb.1996.0058>
- Sirigu, A., Duhamel, J. R., Cohen, L., Pillon, B., Dubois, B., & Agid, Y. (1996). The mental representation of hand movements after parietal cortex damage. *Science*, 273(5281), 1564–1568.
- Staub, F., Bogousslavsky, J., Maeder, P., Maeder-Ingvar, M., Fornari, E., Ghika, J., Vingerhoets, F., & Assal, G. (2006). Intentional motor phantom limb syndrome. *Neurology*, 67(12), 2140–2146. <https://doi.org/10.1212/01.wnl.0000249135.78905.75>
- Wolpert, D. M., Ghahramani, Z., & Jordan, M. I. (1995). An internal model for sensorimotor integration. *Science*, 269(5232), 1880–1882. <https://doi.org/10.1126/science.7569931>