



HAL
open science

A probable case of hypophosphatasia in St Bride's Lower Churchyard (1770-1849, London, UK)

Pierre-Hadrien Decaup, Ana Ribeiro, Christine Couture, Sacha Kacki, Tania Kausmally, Elsa Garot

► **To cite this version:**

Pierre-Hadrien Decaup, Ana Ribeiro, Christine Couture, Sacha Kacki, Tania Kausmally, et al.. A probable case of hypophosphatasia in St Bride's Lower Churchyard (1770-1849, London, UK). *International Journal of Paleopathology*, 2024, 46, pp.24-36. <10.1016/j.ijpp.2024.06.003>. <hal-04769183>

HAL Id: hal-04769183

<https://hal.science/hal-04769183v1>

Submitted on 6 Nov 2024

HAL is a multi-disciplinary open access archive for the deposit and dissemination of scientific research documents, whether they are published or not. The documents may come from teaching and research institutions in France or abroad, or from public or private research centers.

L'archive ouverte pluridisciplinaire **HAL**, est destinée au dépôt et à la diffusion de documents scientifiques de niveau recherche, publiés ou non, émanant des établissements d'enseignement et de recherche français ou étrangers, des laboratoires publics ou privés.



Copyright - All rights reserved

A probable case of hypophosphatasia in St Bride's Lower Churchyard (1770-1849, London, UK)

Pierre-Pierre-Hadrien Decaup^{a,b,c}, Ana Ribeiro^{a,d}, Christine Couture^b, Sacha Kacki^b, Tania Kausmally^e, Elsa Garot^{a,b,c}

a. Univ. de Bordeaux, UFR des Sciences odontologiques, Bordeaux, France

b. Univ. de Bordeaux, PACEA UMR 5199, CNRS, MCC, Pessac, France

c. Centre de Compétence des Maladies Rares Orales et Dentaires, CCMR O-Rares, C.H.U. de Bordeaux, France

d. Pôle de médecine et chirurgie bucco-dentaires, C.H.U de Bordeaux, France

e. Ossafreelance, USA

Abstract

Objectives: The objective of this study was to analyse an individual whose remains are characterised by early deciduous tooth loss and multi-focal lesions on the post-cranial skeleton.

Materials: Skeletal remains of an immature individual buried between 1770 and 1849 in London.

Methods: The remains were examined by visual macroscopic inspection, supplemented by radiographic examination of the mandible and maxillae. A differential diagnosis with possible conditions, frequent in this archaeological context, was conducted. A comprehensive examination of dental lesions was performed to investigate the aetiologies of deciduous tooth loss.

Results: The individual exhibited a mosaic of skeletal and dental pathological changes, including premature loss of deciduous dentition, premature eruption of permanent teeth generalised bone loss in both the mandible and maxilla; osteomyelitis of the left radius; osteolytic lesion on the body of the second lumbar vertebra, and marked expansions of the rib shafts due to sub-periosteal new bone formation.

Conclusion: A differential diagnosis considered indicates that the pathological changes of the individual were most likely associated with a comorbidity involving hypophosphatasia and tuberculosis.

Significance: We present in this study several oral signs that could alert paleopathologists and bioarcheologists to systematically consider the potential of a condition that is rarely encountered in archaeological contexts.

Limitations: Due to poor preservation, this study was confined to the analysis of a partial maxilla and mandible, a left radius shaft and the axial skeleton (rib heads and vertebrae) of the individual.

Suggestions for further research: Further radiographic, histological and genetic analyses would confirm the diagnosis.

Keywords: Tuberculosis, Metabolic disorders, Early tooth loss, Periodontitis, Periosteal new bone formation

1. Introduction

The paleopathological context of the British industrial era is characterised by a clear association between socio-economic status and health inequalities (Lewis, 2002, Newman et al., 2019, Yaussy, 2019). During this period, the overall health of the population declined. Nevertheless, the same health conditions as in the pre-industrial era were prevalent, mainly rickets and osteomalacia, scurvy and tuberculosis (Buckberry and Crane-Kramer, 2022). Detection of rarer diseases involving bone metabolism in this well-established pathological context can become more challenging because of possible overlapping signs. Analysis of dental status, such as the chronology of developmental stages and dynamics of eruption and the aetiologies of tooth loss when present, is a valuable aid in establishing differential diagnoses in this context. Notably, in the presence of early deciduous tooth loss, a systemic aetiological cause should be considered (Spodzieja and Olczak-Kowalczyk, 2022). The aim of this study was to investigate the potential occurrence of a rare genetic condition in a child from the British industrial period whose remains are characterised by early deciduous tooth loss and multi-focal lesions on the post-cranial skeleton, and thus to expand our knowledge of pathological conditions present in 18th-19th-century London.

2. Materials

We present and analyse the remains of individual FAO90 [1296] from St Bride's Lower Churchyard (75–82 Farringdon Street, London, United-Kingdom, Museum of London Centre for Human Bioarcheology, originally assessed by Kausmally, 2008). The St Bride's Lower Churchyard assemblage was part of St Bride's parish in southwest London, where St Bride's Fleet Street cemetery is located (Milne, 1997). Indeed, St Bride's Lower cemetery was used to solve the overcrowding of St Bride's Fleet Street burial ground during the industrial era (Milne, 1997). The main period of occupation of the lower churchyard was between 1770 and 1849 (Kausmally, 2008, Miles and Conheaney, 2005, Milne, 1997). Excavations in the lower churchyard conducted by the Museum of London Archaeological Services in 1991–1992 found 606 individuals, mostly recovered in wooden coffins and distributed in two areas: 497 individuals in the open yard and 47 individuals in a brick vault (Milne, 1997). This assemblage comprised a low socio-economic population, including the poorest parishioners of St Bride, as well as the deceased from Bridewell Workhouse and Fleet Prison (Kausmally, 2008, Scheuer, 1998).

Individual FAO90 [1296] consisted of an incomplete immature skeleton buried between 1770 and 1849 according to the historical and archaeological context (Kausmally, 2008, Milne, 1997). Skeletal completeness was poor, with only a partial left radius, partially preserved ribs and vertebrae, the right hemi-mandible, part of the left hemi-mandible, and the left and right maxillae recovered (Fig. 1). Taphonomic changes included post-mortem damage on the proximal and distal ends of the radius, posterior left maxilla and mandible left of the midline (between the lateral incisor and canine) and several post-mortem fractures of the vertebral processes and bodies.

[FIGURE 1]

3. Methods

The left radius, ribs and vertebrae were examined macroscopically, and a new radiographic exploration of the mandible and maxillae was conducted using four X-ray acquisitions (70–80 kV, 60 s) in the sagittal and horizontal planes. Estimation of age at death was based on root development and dental eruption (AlQahtani et al., 2010, Bengston, 1935, Moorrees et al., 1963) and vertebral ossification chronology, based on the standards of Scheuer and Black (2000), were used.

Post-mortem tooth loss was indicated by a sharp-edged socket with no indications of healing, and ante-mortem tooth loss was indicated by full or partial healing of the empty socket (Cucina and Tiesler, 2003, Hillson, 1996, Powers, 2012). The loss of a permanent tooth was considered 'early' as was the loss of deciduous teeth two years before the average age of exfoliation (AlQahtani et al., 2010, Hartsfield, 1994, Moorrees et al., 1963). Tooth loss associated with periodontal conditions was assessed by observing concomitant mandibular or maxillary bone loss and possible variations in the texture and architecture of the interdental septum (Clarke et al., 1986, Costa, 1982, Kerr, 1980, Ogden, 2007). Alveolar bone loss was measured with a periodontal probe in six equidistant areas around each fully erupted tooth to estimate the distance from the cemento-enamel junction to the alveolar bone level (Lavigne and Molto, 1995, Muller and Perizonius, 1980) and compared with age-matched standards (Al Jamal et al., 2011, Benn, 1990). In edentulous areas, bone loss was estimated with the Cawood and Howell (1988) classification based on shape changes after tooth loss. For deciduous teeth, a distinction was made between teeth exfoliated with resorbed roots (physiological or 'early' if two years earlier than the average age) and teeth exfoliated with intact roots (whether early or not), which was always considered pathological and a possible sign of disease (Feeney et al., 2018, Spodzieja and Olczak-Kowalczyk, 2022). Possible tooth agenesis was considered based on the absence of an open gap and empty tooth sockets (Hillson, 1996, Lacy, 2021). Tooth loss due to extensive dental caries was evaluated by observing root debris, decayed dental crowns or bone loss associated with older endodontic infections (Buikstra and Ubelaker, 1994, Hillson, 1996, Powers, 2012). Tooth loss due to traumatic injuries was evaluated on the basis of tooth position, with the incisors being the most affected teeth, and through the macroscopical observation of amelo-dentinal fractures, bone fractures and dental displacements in adjacent teeth (Petti et al., 2018). Amelo-dentinal fracture from traumatic injuries were differentiated from enamel chipping, which would have appeared as crescent-shaped enamel removal from the outer rim of a posterior crown (Scott and Turner, 1988, Scott and Winn, 2011, Towle et al., 2021).

The morphology of the pulp chambers of multi-rooted teeth was assessed radiographically and categorised into three groups: normal, constricted and chair-shaped (D'Ortenzio et al., 2018). A tooth's root-crown ratio was measured when possible, based on the method of Hölttä et al. (2004). The mean ratios from the same study were used to determine the root length group: short, normal or long (Hölttä et al., 2004).

The few preserved postcranial bones were examined macroscopically for lesions, following standard palaeopathological observation protocols (Buikstra and Ubelaker, 1994). Suspected lesions were further investigated by examining close-up views from high-resolution photographs, notably for

assessing signs of bone remodelling. Bone changes were described in accordance with the recommendations of the Nomenclature in Palaeopathology (Manchester et al. 2016).

4. Results

4.1. Age at death

Age at death was estimated to be between 5.5 and 8.5 years (AlQahtani et al., 2010, Bengston, 1935, Moorrees et al., 1963). Notably, the permanent incisor root lengths did not exceed the crown lengths. The stage of development of the vertebral elements supports this estimate and even suggests that the age at death of individual FAO90 was closest to the lowest limit of this age range. Despite the damage to most of the vertebrae, it is obvious that the anterior arch of the atlas was unfused, and that one cervical vertebra had no or incomplete neuro-central fusion (Supplementary Information Figure S1), whereas the fusion of this element is expected to occur between 5 and 6 years of age and between 3 and 4 years of age, respectively (Scheuer & Black 2000, p. 218). In the other preserved vertebrae, neuro-central fusion is either partial or complete (Supplementary Information Figures S1, S2 and S3). Overall, the findings potentially suggest an age of death of between 5 and 6 years old.

4.2. Pathological description of the cranio-facial elements

Individual FAO90 [1296] was characterised by partial edentulism involving all deciduous teeth in the right hemi-mandible (Fig. 2, Fig. 3) and from the right deciduous second molar to the left first deciduous molar in the maxillae (Fig. 2, Fig. 4). The loss of deciduous incisors supported the chronology of tooth development because the physiological loss age range of the deciduous central incisor is 6.5–7.5 years and 6.5–8.5 years for the deciduous lateral incisor (AlQahtani et al., 2010, Moorrees et al., 1963). Residual sockets for the right mandibular and left and right maxillary deciduous canine root tips were visible superior to the permanent canine germs (Fig. 3, Fig. 4). Healing signs were detected in these residual sockets. Observation of the small empty sockets confirmed that these teeth had experienced ante-mortem exfoliation with intact roots. The loss of deciduous canines was not in line with the estimated age of the individual since loss of deciduous canines is not expected before 9.5–11.5 years (AlQahtani et al., 2020; Moorrees, 1963). No traces of sockets were visible for the deciduous molars.

[FIGURES 2-4]

All permanent teeth expected in the estimated age range were observed in individual FAO90 [1296], except for the right and left mandibular central incisors, right lateral incisor and second premolar (Table 1). The right and left permanent mandibular central incisors and the right lateral incisor were lost post-mortem. The right mandibular second premolar germ was missing, and no crypt or sockets could be seen on the radiograph (Fig. 2). The left maxillary second premolar germ was also

missing, but clear taphonomic destruction in this part of the maxilla (Fig. 4) did not permit confirmation of the agenesis of this tooth (Fig. 2, Fig. 4).

[TABLE 1]

Individual FAO90 [1296] showed no evidence of active extensive dental caries (Fig. 5). No evidence of dental trauma was observed in the maxilla or mandible. Horizontal alveolar bone loss (Cawood and Howell, 1988) was observed in both the mandible and maxilla's edentulous area. The mandibular right first permanent molar exhibited unevenly distributed bone loss, with the average measurement around the tooth being 6 mm from the cemento-enamel junction. As a standard, the expected mean cemento-enamel junction and alveolar bone level distance is between 1 and 2 mm in age-matched living populations (Al Jamal et al., 2011, Benn, 1990). The maxillary right first permanent molar presented similar bone characteristics with a measured average bone loss of 5 mm from the cemento-enamel junction.

[FIGURE 5]

Linear enamel hypoplasia was observed on the maxillary central incisors and punctiform enamel hypoplasia on the molars and incisors of individual FAO90 [1296].

The pulp chambers of the mandibular and maxillary right first permanent molars were classified as 'normal', showing no signs of bilateral ('constricted') or unilateral ('chair-shaped') constriction (D'Ortenzio et al., 2018). Moreover, the maxillary right first permanent molar displayed large root canals associated with a larger than higher pulp chamber in the lateral view, which are unusual features for the maxillary first permanent molars (Thomas et al., 1993). The root-crown ratio of the right mandibular first permanent molar (Fig. 6) was 1.6 using the method described by Hölttä et al., (2004). The average root-crown ratio for the corresponding teeth in the study of Hölttä et al. (2004) was 2.11 ± 0.17 in Caucasian males and 2.07 ± 0.18 in females. Consequently, the roots of the mandibular right first permanent molar of FAO90 [1296] were considered 'short'. Because it was challenging to remove the maxillary right first permanent molar from its socket, no root-crown ratio was obtained for this tooth.

[FIGURE 6]

4.3. Pathological description of the post-cranial elements

According to the initial analysis conducted by the Museum of London Centre for Human Bioarchaeology on FAO90 [1296], the pathological bone changes included an osteomyelitis-like lesion on the left radius (thickening of the shaft with no obvious cloacae) and marked expansions on the rib heads with active fine porous lesions on the visceral surface (Kausmally, 2008). A new assessment revealed pathological changes were also evident in the vertebrae. A well-defined, flattened circular

surface, approximately half a centimetre in diameter, was identified on the superior aspect of the spinous process of a thoracic vertebra (Fig. 7). Slight signs of bone remodelling, such as an irregular bone surface and small spicules, were observed on the neural arches of other thoracic vertebrae (Fig. 7). In the body of the second lumbar vertebra, the exposed trabeculae were coarse and thickened and had a smooth appearance indicative of bone remodelling (Fig. 7). The ribs had a porous and rough texture on the visceral surfaces (Fig. 8), indicative of active sub-periosteal new bone formation. Shallow osteolytic lesions were detected on the visceral surfaces of the lower ribs (Fig. 9). The radius was slightly curved, markedly expanded in the middle third of the diaphysis, and covered with large areas of superficial bone proliferation on its medial and lateral aspects (Fig. 10). The cortical bone was fenestrated with two large openings that revealed the underlying cancellous bone, which had a remodelled appearance. Although partly due to post-mortem breakage of the cortical bone, in other parts, these openings showed edges that were well rounded and in continuity with the cancellous bone, indicating bone remodelling following osteolysis (Fig. 10). These signs indicated an osteomyelitic lesion, where the oval perforation observed at the centre of the lesion might represent the cloaca in communication with the medullary canal (Fig. 10).

[FIGURE 7-10]

5. Differential diagnosis

Individual FA090 [1296] exhibited a mosaic of skeletal and dental pathological changes, including the following relevant signs: early loss of deciduous canines with intact roots; early loss of deciduous molars most probably with intact roots; a pattern of 'early' eruption of permanent teeth in comparison with crown and root development; generalised horizontal alveolar bone loss in both the mandible and maxilla; localised bone loss at the mandibular right first permanent molar; a wider than higher pulp chamber the maxillary right first permanent molar; enlarged root canals of the first permanent molars; short dental roots; osteomyelitis of the left radius; osteolytic lesion at the body of the second lumbar vertebra; and marked expansions of the rib shafts due to sub-periosteal new bone formation. Similar dental and/or post-cranial changes were observed in various pathological conditions, which were considered in the differential diagnosis (Table 2, Table 3).

[TABLES 2-3]

Among the conditions that may cause early loss of deciduous teeth, the most common are hypophosphatasia (Brandt, 2013, Feeney et al., 2018, Nunes, 1993, Szabo et al., 2019, Whyte, 2017), dentine dysplasia type 1 (Chen et al., 2019), Papillon-Lefèvre syndrome (Canger et al., 2008, de Freitas et al., 2007, Giannetti et al., 2020) and Chediak-Higashi syndrome (de Arruda et al., 2023, Rezende et al., 2013, Ziaei et al., 2021). The root morphology of individual FA090 [1296] did not correspond to the characteristics of tooth roots observed in dentine dysplasia type 1, which are described as either absent or very thin and sharp (Chen et al., 2019). Moreover, the pulp chamber morphology in dentine

dysplasia type 1 cases is predominantly reported to be reduced, contrary to that observed in individual FAO90 [1296], who exhibited a larger and well-developed pulp chamber. In Papillon–Lefèvre syndrome and Chediak–Higashi syndrome, early deciduous tooth loss is due to aggressive bacterial periodontitis, leading to multi-focal vertical alveolar bone loss (Canger et al., 2008, de Arruda et al., 2023, de Freitas et al., 2007, Giannetti et al., 2020, Rezende et al., 2013). Thus, the generalised horizontal alveolar bone loss of individual FAO90 [1296] did not match the alveolar bone signs of these conditions. In addition, Papillon–Lefèvre syndrome and Chediak–Higashi syndrome include an increased prevalence of carious lesions, which was not the case in individual FAO90 [1296]. The association of early loss of deciduous teeth, generalised horizontal bone loss, enlarged pulp chamber morphology and shortened roots are exclusively described in hypophosphatasia (Table 2), which thus appears to be the most probable diagnosis for the dental changes observed in FAO90 [1296].

It is noteworthy, however, that most of the post-cranial bone changes exhibited by the individual under study are not expected to be produced by hypophosphatasia. Bone oedema mimicking chronic non-bacterial osteomyelitis may occasionally occur in long bones, as a result of extra-cellular accumulation of calcium pyrophosphate or phosphate crystals in the periarticular area or soft tissues, due to the reduced activity of alkaline phosphatase associated with the condition (Girschick et al., 2007, Whyte et al., 2009, Simon et al., 2018). However, this is a rare occurrence. Moreover, osteolytic lesions in vertebrae and sub-periosteal new bone formation on ribs is not observed in hypophosphatasia. It is therefore very likely that these various post-cranial signs are actually related to some other pathological condition.

Other common diseases, noted in archaeological contexts, were considered in the second step of the differential diagnosis (Table 3). Based on relevant literature on the skeletal signs of nutritional rickets (Brickley and Mays, 2019, Brickley and Morgan, 2023, D’Ortenzio et al., 2018, Kacki et al., 2011, Mays et al., 2006), tuberculosis (Dangvard Pedersen et al., 2019, Holloway et al., 2011), brucellosis (Bendrey et al., 2020), non-systemic periodontitis (Miller et al., 2018, Papapanou et al., 2018, Suzuki, 1988), scurvy (Brickley and Morgan, 2023, Brothwell, 1981, Maat, 2004, Snoddy et al., 2018) and hypophosphatasia (Brandt, 2013, Feeney et al., 2018, Nunes, 1993, Whyte, 2017), it appears that none of these conditions alone may explain the entirety of the lesions reported. The association of the two conditions (comorbidity) in individual FAO90 [1296] may therefore be considered as an alternative hypothesis.

Based on the data reported in Table 3, the diagnosis of environmental rickets associated with non-systemic periodontitis, although potentially matching well with archaeological and historical contexts, can be ruled out. Indeed, individual FAO90 [1296] did not show typical macroscopic dental features associated with rickets (‘constricted’ or ‘chair-shaped’ pulp chambers) or aggressive vertical bone loss associated with pre-pubertal periodontitis. Similarly, although several dental signs are consistent with scurvy, this diagnosis is rejected because major signs of this disease were not found, including sub-periosteal new bone formation and cortical porosities related to bleeding of vasculature associated with masticatory muscles (Brickley and Morgan, 2023, Maat, 2004, Ortner, 2003, Snoddy et al., 2018). However, several bone changes, such as periosteal new bone formation on the visceral aspect of the ribs and osteolytic lesions in the body of the second lumbar vertebra are highly indicative of a systemic

infectious process. Tuberculosis, in particular, is a likely diagnosis because this disease frequently results in osteolytic destruction of the lower thoracic or lumbar vertebrae, as well as periosteal new bone formation and osteolytic foci on the visceral surface of the ribs (Lewis, 2011, Ortner, 2003, Roberts and Buikstra, 2003, Santos and Roberts, 2006). Because tuberculosis alone could not explain the individual's craniofacial signs (particularly the early deciduous teeth loss) and non-systemic periodontitis has been ruled out, a possible diagnosis is the combination of hypophosphatasia and bone tuberculosis. This comorbidity appears even more likely considering that hypophosphatasia can predispose a person to pulmonary infections (Feeney et al., 2018, Whyte, 2017).

6. Discussion

We have analyzed individual FAO90 [1296]'s early deciduous tooth loss and bone changes and argue that the most plausible diagnosis was a comorbidity with a non-severe form of hypophosphatasia and an infectious disease, potentially tuberculosis. Hypophosphatasia is a rare genetic condition characterised by metabolic disorders stemming from insufficient activity of the tissue-non-specific isoenzyme of alkaline phosphatase, leading to the extracellular buildup of its substrates (Feeney et al., 2018). It is caused by a mutation in the ALPL gene, which encodes tissue-non-specific alkaline phosphatase in bone osteoblasts and liver, kidney and skin fibroblasts. The major signs include impaired or defective mineralisation of bones and early exfoliation of deciduous teeth (Feeney et al., 2018, Okawa et al., 2019). The clinical presentation of the disease varies and may encompass skeletal, dental, neurological and renal manifestations, pain, muscle weakness, growth defects, ambulatory difficulties or frequent bone fractures (Feeney et al., 2018, Okawa et al., 2019). In the childhood and in the less severe forms of the conditions (the severe forms lead to death in the first years of life), the most prevalent sign is early deciduous tooth loss, whereas in adulthood, bone metabolism is more affected (Szabo et al., 2019). Other dental signs, such as enamel and dentine defects, alveolar bone loss and perturbations of the developmental chronology, are less common in childhood but could explain the second premolar agenesis of FAO90 [1296] (Szabo et al., 2019). The premature loss of deciduous teeth is putatively related to cementum defects rather than to the perturbation of bone mineralisation (van den Bos et al., 2005). The dysregulated hydrolysis of inorganic pyrophosphates (PPi, a potent inhibitor of hydroxyapatite) caused by tissue-non-specific alkaline phosphatase deficiency leads to the accumulation of PPi in the extracellular matrix, which explains bone, dentine and cementum defects in hypophosphatasia (Komaru et al., 2019). Nevertheless, this process is tissue-dependent, and cementum development is more sensitive than dentine development to the accumulation of PPi (Bloch-Zupan and Vaysse, 2017, van den Bos et al., 2005). In deciduous tooth loss associated with hypophosphatasia, both the acellular and cellular layers of the cementum are absent or severely impacted. Consequently, the periodontal ligament and the dentine are separated by a space filled with non-fibrillar material rather than being connected by collagen fibrils (van den Bos et al., 2005).

Hypophosphatasia has been classified into six subtypes. Depending on the time of diagnosis and clinical assessment, the condition is described as perinatal severe hypophosphatasia, perinatal benign

hypophosphatasia (in utero and at birth), infantile hypophosphatasia (<6 months), childhood hypophosphatasia (6 months–18 years) or adult hypophosphatasia (>18 years). Beyond tooth eruption, a clinical description confined to dental symptoms constitutes the sixth sub-type, odontohypophosphatasia (Mornet et al., 2021, Okawa et al., 2019). Because odontohypophosphatasia is frequently succeeded by more systemic forms after or during childhood, some authors propose that childhood hypophosphatasia is a progressive condition leading to dental signs in childhood and evolving to systemic signs in adulthood (Mori et al., 2016). Perinatal and infantile forms are associated with significant mortality (Whyte, 2017). Patients with severe forms of hypophosphatasia generally die before the eruption of deciduous dentition (Okawa et al., 2019, Whyte, 2017). For FAO90 [1296], a possible hypophosphatasia diagnosis would include the childhood form. The estimated prevalence from genetic data of mild forms of the condition is 1/2430 in the European population (Mornet et al., 2021).

St Bride's Lower Churchyard sub-adults were characterised by a high mortality rate, likely due to environmental conditions (malnutrition and socio-economic status) leading to metabolic disorders such as rickets and scurvy in 40 % of the population (Kausmally, 2008). The left mandibular second premolar agenesis of FAO90 [1296] could be related to physiological disturbances associated with poor socio-economic conditions (Dinis et al., 2023). The prevalence of moderate and severe periodontitis in the adult population of the burial area was estimated to be approximately 20 % (Al-Mutairi et al., 2022). However, individual FAO90 [1296] did not display typical signs of rickets, scurvy, or non-systemic periodontitis (Table 3).

Early deciduous tooth loss is the key to understanding the pathological context of individual FAO90 [1296]. No deciduous root debris was detected. Caries in deciduous dentition is the most reliable predictors of future caries in young permanent dentition (Demers et al., 1990, Li and Wang, 2002, Powell, 1998, Skeie et al., 2006, Tagliaferro et al., 2006). Thus, the absence of extensive carious lesions in the pits and grooves of the remaining erupted permanent teeth of FAO90 [1296] was not consistent with an early deciduous tooth loss due to dental caries. This sign, when common oral aetiologies have been excluded (cariou disease, periodontitis, traumatism and oligodontia), is often associated with rarer conditions than those classically encountered in past populations (Spodzieja and Olczak-Kowalczyk, 2022). Notably, early deciduous tooth loss is rarely reported in environmental rickets (D'Ortenzio et al., 2018). Moreover, the discrepancies between the development of permanent tooth germs and their stages of eruption were also interpreted as a sign associated with a possible rarer condition. However, this last sign is not often reported in patients with hypophosphatasia (Whyte, 2017). Another explanation could be the consequence of early deciduous teeth exfoliation involving the entire deciduous dentition. In fact, early exfoliation of deciduous teeth can accelerate the development and eruption of permanent dentition (Kjær, 2014, Loevy, 1989), which could explain these discrepancies and 'high' permanent teeth germ locations. Another concern was the age estimation of individual FAO90 [1296] in the context of developmental and eruption disturbances. As the eruption position (AlQahtani et al., 2010, Bengston, 1935) could have been influenced by horizontal general bone loss, developmental status (AlQahtani et al., 2010, Moorrees et al., 1963) has been selected to refine the estimation. Dental eruption is an intermittent process that is sensitive to local

factors such as crowding or deciduous tooth loss (Loevy, 1989, Yan et al., 2013). Dental development, conversely, is an ongoing process that is less sensitive to local factors and is therefore considered more reliable for estimating chronological age (Kuremoto et al., 2022, Panchbhai, 2011, Yan et al., 2013). Moreover, the late stages of root formation are generally considered less reliable than the early stages (Liversidge et al., 2010). The developmental stages (Table 1) of the incisors, canines, first and second premolars and second molars were therefore prioritised over that of the first permanent molar in the age estimation. Finally, because the chosen age estimation methods (AlQahtani et al., 2010, Moorrees et al., 1963) produce a mean absolute deviation range of 0.38–0.44 years, which tends to underestimate the chronological age in the 5.5–7.5 years range (AlQahtani et al., 2014), we chose a wide range for refining the age at death (5.5–8.5 years).

The identification of multiple early tooth loss in an immature individual, without obvious signs of carious disease or traumatic loss, should prompt palaeopathologists to systematically investigate a potential association with a systemic condition. Indeed, except for scurvy, this sign, particularly when involving severe edentulism, is rarely or never reported in association with metabolic or infectious disorders such as environmental rickets, tuberculosis or brucellosis but frequent in ‘genetic disorder’ conditions (Spodzieja and Olczak-Kowalczyk, 2022). In this case study, we used differential diagnosis based on possible conditions associated with early deciduous tooth loss to orient the diagnosis. The differential diagnosis based on archaeological contexts suggested the presence of the comorbidity of hypophosphatasia associated with tuberculosis. This finding is not surprising, as hypophosphatasia could predispose patients to pulmonary infections (Feeney et al., 2018, Whyte, 2017). This is possibly the first diagnosis of hypophosphatasia in a past population (Brandt, 2013), if confirmed by further studies. Future analysis of individual FAO90 [1296] should include radiographic imaging of the left radial shaft to identify ‘radiolucent tongues’ reaching from the metaphysis into the shaft, micro-CT imaging to evaluate bone density, and a histological analysis of the cementum, which would appear afibrillar, sometimes absent or with impaired calcification features in case of hypophosphatasia (Brandt, 2013, Whyte, 2017). Sequencing of the ALPL gene of the individual could definitely confirm this diagnosis (Brandt, 2013, Whyte, 2017).

7. Conclusion

In this study we offer a possible case of comorbidity of hypophosphatasia and tuberculosis, a condition never reported in the context of the British industrial era, and one that is informed by careful differential diagnosis and attention to archaeological and socio-economic contexts. Key signs to potentially identify hypophosphatasia in archaeological contexts were compiled, notably severe early deciduous tooth loss, which may be used to alert palaeopathologists and bioarcheologists of the condition. Early deciduous tooth loss requires a thorough examination of possible associated conditions. Subsequent radiographic, histologic and genetic analyses could help confirm the diagnosis of individual FAO90 [1296].

CRedit authorship contribution statement

Ana Ribeiro: Writing – review & editing, Writing – original draft, Methodology, Formal analysis, Data curation, Conceptualization. Pierre-Hadrien Decaup: Writing – original draft, Methodology, Formal analysis, Conceptualization. Christine Couture: Writing – original draft. Tania Kausmally: Writing – original draft. Sacha Kacki: Writing – original draft. Elsa Garot: Writing – original draft.

Acknowledgments

The authors thanks Jelena Bekvalac and the Museum of London Centre for Human Bioarchaeology for granting access to the remains of the individual FAO90 [1296] and David Manton for his attentive proofreading. The research was supported by the EVODIBIO team (PACEA, UMR 5199, University of Bordeaux). The study received financial support from the French government in the framework of the University of Bordeaux's IdEx "Investments for the Future" program/GPR Human Past.

References

- Al Jamal, G., Al-Batayneh, O.B., Hamamy, D., 2011. The alveolar bone height of the primary and first permanent molars in healthy 6- to 9-year-old Jordanian children. *Int J Paediatr Dent* 21, 151–159. <https://doi.org/10.1111/j.1365-263X.2010.01073.x>
- Al-Mutairi, R., Liversidge, H., Gillam, D.G., 2022. Prevalence of Moderate to Severe Periodontitis in an 18–19th Century Sample—St. Bride’s Lower Churchyard (London, UK). *Dent J (Basel)* 10, 56. <https://doi.org/10.3390/dj10040056>
- AlQahtani, S.J., Hector, M.P., Liversidge, H.M., 2014. Accuracy of dental age estimation charts: Schour and Massler, Ubelaker and the London Atlas. *Am J Phys Anthropol* 154, 70–78. <https://doi.org/10.1002/ajpa.22473>
- AlQahtani, S.J., Hector, M.P., Liversidge, H.M., 2010. Brief communication: The London atlas of human tooth development and eruption. *Am J Phys Anthropol* 142, 481–490. <https://doi.org/10.1002/ajpa.21258>
- Bendrey, R., Cassidy, J.P., Fournié, G., Merrett, D.C., Oakes, R.H.A., Taylor, G.M., 2020. Approaching ancient disease from a One Health perspective: Interdisciplinary review for the investigation of zoonotic brucellosis. *Int J Osteoarchaeol* 30, 99–108. <https://doi.org/10.1002/oa.2837>
- Bengston, R., 1935. A study of the time of eruption and root development of the permanent teeth between six and thirteen years. *Northwest Univ Bull* 35, 3–9.
- Benn, D.K., 1990. A review of the reliability of radiographic measurements in estimating alveolar bone changes. *J Clin Periodontol* 17, 14–21. <https://doi.org/10.1111/j.1600-051x.1990.tb01041.x>
- Bloch-Zupan, A., Vaysse, F., 2017. Hypophosphatasia: oral cavity and dental disorders. *Arch Pediatr, Hypophosphatasia* 24, 5S80-5S84. [https://doi.org/10.1016/S0929-693X\(18\)30020-4](https://doi.org/10.1016/S0929-693X(18)30020-4)
- Brandt, G., 2013. Did Tutankhamun suffer from hypophosphatasia? A hypothetical approach. *Anthropol Anz* 70, 249–260. <https://doi.org/10.1127/0003-5548/2013/0322>

- Brickley, M.B., Mays, S., 2019. Chapter 15 - Metabolic Disease, in: Buikstra, J.E. (Ed.), Ortner's Identification of Pathological Conditions in Human Skeletal Remains (Third Edition). Academic Press, San Diego, pp. 531–566. <https://doi.org/10.1016/B978-0-12-809738-0.00015-6>
- Brickley, M.B., Morgan, B., 2023. Assessing diagnostic certainty for scurvy and rickets in human skeletal remains. *Am J Biol Anthropol* 181, 637–645. <https://doi.org/10.1002/ajpa.24799>
- Brothwell, D.R., 1981. *Digging Up Bones: The Excavation, Treatment, and Study of Human Skeletal Remains*. Cornell University Press.
- Buckberry, J., Crane-Kramer, G., 2022. The dark satanic mills: Evaluating patterns of health in England during the industrial revolution. *Int J Paleopathol* 39, 93–108. <https://doi.org/10.1016/j.ijpp.2022.10.002>
- Buikstra, J.E., Ubelaker, D.H., 1994. Standards for Data Collection from Human Skeletal Remains. *Ark Archeol Sur Res*. <https://doi.org/10.1002/ajhb.1310070519>.
- Canger, E.M., Celenk, P., Devrim, I., Yenisey, M., Gunhan, O., 2008. Intraoral findings of Papillon-LeFevre syndrome. *J Dent Child* 75, 99–103.
- Cawood, J.I, Howell, R.A., 1988, A classification of the edentulous jaws. *Int J Oral Maxillofac Surg* 17(4), 232–236, [https://doi.org/10.106/s0901-5027\(88\)80047-x](https://doi.org/10.106/s0901-5027(88)80047-x)
- Chen, D., Li, X., Lu, F., Wang, Y., Xiong, F., Li, Q., 2019. Dentin dysplasia type I—A dental disease with genetic heterogeneity. *Oral Dis* 25, 439–446. <https://doi.org/10.1111/odi.12861>
- Clarke, N.G., Carey, S.E., Srikandi, W., Hirsch, R.S., Leppard, P.I., 1986. Periodontal disease in ancient populations. *Am J Phys Anthropol* 71, 173–183. <https://doi.org/10.1002/ajpa.1330710205>
- Costa, R.L., 1982. Periodontal disease in the prehistoric Ipiutak and Tigara skeletal remains from Point Hope, Alaska. *Am J Phys Anthropol* 59, 97–110. <https://doi.org/10.1002/ajpa.1330590109>
- Cucina, A., Tiesler, V., 2003. Dental caries and antemortem tooth loss in the Northern Peten area, Mexico: A biocultural perspective on social status differences among the Classic Maya. *Am J Phys Anthropol* 122, 1–10. <https://doi.org/10.1002/ajpa.10267>
- Dangvard Pedersen, D., Milner, G.R., Kolmos, H.J., Boldsen, J.L., 2019. The association between skeletal lesions and tuberculosis diagnosis using a probabilistic approach. *Int J Paleopathol* 27, 88–100. <https://doi.org/10.1016/j.ijpp.2019.01.001>
- de Arruda, J.A.A., Sousa-Neto, S.S., Abreu, L.G., Schuch, L.F., Souza, V.G., Alves, T.V.L., Martins-Andrade, B., Shetty, S.S., Monteiro, J.L.G.C., Mendonça, E.F., Mesquita, R.A., Callou, G., 2023. Oral manifestations of Chediak-Higashi syndrome: A systematic review. *Dis Mon* 69, 101356. <https://doi.org/10.1016/j.disamonth.2022.101356>
- de Freitas, A.C., Assed, S., da Silva, L.A.B., Silva, R.A.B., 2007. Aggressive periodontitis associated with Papillon-Lefèvre syndrome: report of a 14-year follow-up. *Spec Care Dentist* 27, 95–100. <https://doi.org/10.1111/j.1754-4505.2007.tb01747.x>
- Demers, M., Brodeur, J.M., Simard, P.L., Mouton, C., Veilleux, G., Fréchette, S., 1990. Caries predictors suitable for mass-screenings in children: a literature review. *Community Dent Health* 7, 11–21.

- Dinis, A.R., Teixeira, A., Pérez-Mongioli, D., Caldas, I.M., 2023. Fluctuating asymmetry in third molar agenesis as an aid to estimate socioeconomic status. *Forensic Sci Med Pathol*.
<https://doi.org/10.1007/s12024-023-00706-2>
- D’Ortenzio, L., Ribot, I., Kahlon, B., Bertrand, B., Bocaage, E., Raguin, E., Schattmann, A., Brickley, M., 2018. The rachitic tooth: The use of radiographs as a screening technique. *Int J Paleopathol*, Vitamin D deficiency in bioarchaeology and beyond: The study of rickets and osteomalacia in the past 23, 32–42. <https://doi.org/10.1016/j.ijpp.2017.10.001>
- Feeney, C., Stanford, N., Lee, S., Barry, S., 2018. Hypophosphatasia and the importance of the general dental practitioner - a case series and discussion of upcoming treatments. *Br Dent J* 224, 937–943. <https://doi.org/10.1038/sj.bdj.2018.441>
- Giannetti, L., Apponi, R., Dello Diago, A.M., Jafferany, M., Goldust, M., Sadoughifar, R., 2020. Papillon-Lefèvre syndrome: Oral aspects and treatment. *Dermatol Ther* 33, e13336. <https://doi.org/10.1111/dth.13336>
- Girschick, H.J., Mornet, E., Beer, M., Warmuth-Metz, M., Schneider, P., 2007. Chronic multifocal non-bacterial osteomyelitis in hypophosphatasia mimicking malignancy. *BMC Pediatrics* 7, 3. <https://doi.org/10.1186/1471-2431-7-3>
- Hartsfield, J.K.J., 1994. Premature exfoliation of teeth in childhood and adolescence. *Adv Pediatr* 41, 453–470.
- Hillson, S., 1996. *Dental anthropology*, 2 edn, Cambridge. ed.
- Holloway, K.L., Henneberg, R.J., de Barros Lopes, M., Henneberg, M., 2011. Evolution of human tuberculosis: A systematic review and meta-analysis of paleopathological evidence. *HOMO* 62, 402–458. <https://doi.org/10.1016/j.jchb.2011.10.001>
- Hölttä, P., Nyström, M., Evälahti, M., Alaluusua, S., 2004. Root-crown ratios of permanent teeth in a healthy Finnish population assessed from panoramic radiographs. *Eur J Orthod* 26, 491–497. <https://doi.org/10.1093/ejo/26.5.491>
- Kacki, S., Villotte, S., Knüsel, C.J., 2011. Baastrup’s sign (kissing spines): A neglected condition in paleopathology. *Int J Paleopathol* 1, 104–110. <https://doi.org/10.1016/j.ijpp.2011.09.001>
- Kausmally, T., 2008. St. Bride’s Lower Churchyard cemetery, osteological database. Centre for Human Bioarchaeology, Museum of London.
- Kerr, W.J., 1980. The effect of the premature loss of deciduous canines and molars on the eruption of their successors. *Eur J Orthod* 2, 123–128. <https://doi.org/10.1093/ejo/2.2.123>
- Kjær, I., 2014. Mechanism of Human Tooth Eruption: Review Article Including a New Theory for Future Studies on the Eruption Process. *Scientifica* 2014, 341905. <https://doi.org/10.1155/2014/341905>
- Komaru, K., Ishida-Okumura, Y., Numa-Kinjoh, N., Hasegawa, T., Oda, K., 2019. Molecular and cellular basis of hypophosphatasia. *J Oral Biosci* 61, 141–148. <https://doi.org/10.1016/j.job.2019.07.003>
- Kuremoto, K., Okawa, R., Matayoshi, S., Kokomoto, K., Nakano, K., 2022. Estimation of dental age based on the developmental stages of permanent teeth in Japanese children and adolescents. *Sci Rep* 12, 3345. <https://doi.org/10.1038/s41598-022-07304-2>

- Lacy, S.A., 2021. Evidence of dental agenesis in late pleistocene Homo. *Int J Paleopathology* 32, 103–110. <https://doi.org/10.1016/j.ijpp.2021.01.001>
- Lavigne, S.E., Molto, J.E., 1995. System of measurement of the severity of periodontal disease in past populations. *Int J Osteoarchaeol* 5, 265–273. <https://doi.org/10.1002/oa.1390050305>
- Lewis, M.E., 2011. Tuberculosis in the non-adults from Romano-British Poundbury Camp, Dorset, England. *Int J Paleopathol* 1, 12–23. <https://doi.org/10.1016/j.ijpp.2011.02.002>
- Lewis, M.E., 2002. Impact of industrialization: comparative study of child health in four sites from medieval and postmedieval England (A.D. 850-1859). *Am J Phys Anthropol* 119, 211–223. <https://doi.org/10.1002/ajpa.10126>
- Li, Y., Wang, W., 2002. Predicting Caries in Permanent Teeth from Caries in Primary Teeth: An Eight-year Cohort Study. *J Dent Res* 81, 561–566. <https://doi.org/10.1177/154405910208100812>
- Liversidge, H.M., Smith, B.H., Maber, M., 2010. Bias and accuracy of age estimation using developing teeth in 946 children. *Am J Phys Anthropol* 143, 545–554. <https://doi.org/10.1002/ajpa.21349>
- Loevy, H.T., 1989. The effect of primary tooth extraction on the eruption of succedaneous premolars. *J Am Dent Assoc* 118, 715–718. <https://doi.org/10.14219/jada.archive.1989.0162>
- Maat, G.J.R., 2004. Scurvy in adults and youngsters: the Dutch experience. A review of the history and pathology of a disregarded disease. *Int J Osteoarchaeol* 14, 77–81. <https://doi.org/10.1002/oa.708>
- Manchester, K., Ogden, A., and Storm, R., 2016. Nomenclature in Palaeopathology, *Palaeopathology Newsletter* 175.
- Mays, S., Brickley, M., Ives, R., 2006. Skeletal manifestations of rickets in infants and young children in a historic population from England. *Am J Phys Anthropol* 129, 362–374. <https://doi.org/10.1002/ajpa.20292>
- Miles, A., Conheaney, J., 2005. A Post-medieval population from London: excavations in the St Bride's Lower Churchyard 75–82 Farringdon Street, City of London, EC4. *MoLAS Studies Series*. London: MoLAS.
- Miller, K., Treloar, T., Guelmann, M., Rody, W.J.J., Shaddox, L.M., 2018. Clinical Characteristics of Localized Aggressive Periodontitis in Primary Dentition. *J Clin Pediatr Dent* 42, 95–102. <https://doi.org/10.17796/1053-4628-42.2.3>
- Milne, G., 1997. St. Bride's Church, London: archaeological research 1952–60 and 1992–5. London: English Heritage.
- Moorrees, C.F., Fanning, E.A., Hunt, E.E., 1963. Age variation of formation stages for ten permanent teeth. *J Dent Res* 42, 1490–1502. <https://doi.org/10.1177/00220345630420062701>
- Mori, M., DeArme, S.L., Weber, T.J., Kishnani, P.S., 2016. Case series: Odontohypophosphatasia or missed diagnosis of childhood/adult-onset hypophosphatasia? – Call for a long-term follow-up of premature loss of primary teeth. *Bone Rep* 5, 228–232. <https://doi.org/10.1016/j.bonr.2016.08.004>
- Mornet, E., Taillandier, A., Domingues, C., Dufour, A., Benaloun, E., Lavaud, N., Wallon, F., Rousseau, N., Charle, C., Guberto, M., Muti, C., Simon-Bouy, B., 2021. Hypophosphatasia: a genetic-based

- nosology and new insights in genotype-phenotype correlation. *Eur J Hum Genet* 29, 289–299. <https://doi.org/10.1038/s41431-020-00732-6>
- Muller, D., Perizonius, W., 1980. The scoring of defects of the alveolar process in human crania. *J Hum Evol* 9, 113–116.
- Newman, S.L., Gowland, R.L., Caffell, A.C., 2019. North and south: A comprehensive analysis of non-adult growth and health in the industrial revolution (AD 18th-19th C), England. *Am J Phys Anthropol* 169, 104–121. <https://doi.org/10.1002/ajpa.23817>
- Nunes, M.E., 1993. Hypophosphatasia., in: Adam, M.P., Everman, D.B., Mirzaa, G.M., Pagon, R.A., Wallace, S.E., Bean, L.J., Gripp, K.W., Amemiya, A. (Eds.), *GeneReviews*(®). University of Washington, Seattle, Seattle (WA).
- Ogden, A., 2007. Advances in Human Paleopathology, in: *Advances in Human Paleopathology*. pp. 283–307. <https://doi.org/10.1002/9780470724187.ch13>
- Okawa, R., Kokomoto, K., Kitaoka, T., Kubota, T., Watanabe, A., Taketani, T., Michigami, T., Ozono, K., Nakano, K., 2019. Japanese nationwide survey of hypophosphatasia reveals prominent differences in genetic and dental findings between odonto and non-odonto types. *PLoS One* 14, e0222931. <https://doi.org/10.1371/journal.pone.0222931>
- Ortner, D.J., 2003. Identification of pathological conditions in human skeletal remains, (second ed.). ed. Academic Press, New York.
- Panchbhai, A., 2011. Dental radiographic indicators, a key to age estimation. *Dentomaxillofac Radiol* 40, 199–212. <https://doi.org/10.1259/dmfr/19478385>
- Papapanou, P.N., Sanz, M., Buduneli, N., Dietrich, T., Feres, M., Fine, D.H., Flemmig, T.F., Garcia, R., Giannobile, W.V., Graziani, F., Greenwell, H., Herrera, D., Kao, R.T., Kerschull, M., Kinane, D.F., Kirkwood, K.L., Kocher, T., Kornman, K.S., Kumar, P.S., Loos, B.G., Machtei, E., Meng, H., Mombelli, A., Needleman, I., Offenbacher, S., Seymour, G.J., Teles, R., Tonetti, M.S., 2018. Periodontitis: Consensus report of workgroup 2 of the 2017 World Workshop on the Classification of Periodontal and Peri-Implant Diseases and Conditions. *J Clin Periodontol* 45, S162–S170. <https://doi.org/10.1111/jcpe.12946>
- Petti, S., Glendor, U., Andersson, L., 2018. World traumatic dental injury prevalence and incidence, a meta-analysis-One billion living people have had traumatic dental injuries. *Dent traumatol* 34. <https://doi.org/10.1111/edt.12389>
- Powell, L.V., 1998. Caries prediction: a review of the literature. *Community Dent Oral Epidemiol* 26, 361–371. <https://doi.org/10.1111/j.1600-0528.1998.tb01974.x>
- Powers, N., 2012. Human osteology method statement. London: Museum of London Archaeological Services. London: Museum of London Archaeological Services.
- Rezende, K.M., Canela, A.H.C., Ortega, A.O.L., Tintel, C., Bönecker, M., 2013. Chediak-Higashi syndrome and premature exfoliation of primary teeth. *Braz Dent J* 24, 667–670. <https://doi.org/10.1590/0103-6440201302258>
- Roberts, C.A., Buikstra, J.E., 2003. The bioarchaeology of tuberculosis: a global view on a re-emerging disease, University Press of Florida.

- Santos, A.L., Roberts, C.A., 2006. Anatomy of a serial killer: Differential diagnosis of tuberculosis based on rib lesions of adult individuals from the Coimbra identified skeletal collection, Portugal. *Am J Phys Anthropol* 130, 38–49. <https://doi.org/10.1002/ajpa.20160>
- Scheuer, L., 1998. Age at death and cause of death of the people buried in St Bride's Church, Fleet Street, London. In: Cox M, editor. *Grave concerns: death and burial in England 1700 to 1850*. York: Council for British Archaeology p 100-111.
- Scott, G.R., Turner C.G.II., 1988. Dental anthropology, *Annu Rev Anthropol* 17, 99 – 126. <https://doi.org/10.1146/annurev.an.17.100188.000531>
- Scott, G.R., Winn, J.R., 2011. Dental chipping: contrasting patterns of microtrauma in inuit and European populations, *Int J Osteoarchaeol* 21(6), 723 – 731. <https://doi.org/10.1002/oa/1184>
- Simon, S., Resch, H., Klaushofer, K., Roschger, P., Zwerina, J., & Kocijan, R., 2018. Hypophosphatasia: from diagnosis to treatment. *Cur Rheum Rep*, 20, 1-7.
- Skeie, M.S., Raadal, M., Strand, G.V., Espelid, I., 2006. The relationship between caries in the primary dentition at 5 years of age and permanent dentition at 10 years of age – a longitudinal study. *Int J Paediatr Dent* 16, 152–160. <https://doi.org/10.1111/j.1365-263X.2006.00720.x>
- Snoddy, A.M.E., Buckley, H.R., Elliott, G.E., Standen, V.G., Arriaza, B.T., Halcrow, S.E., 2018. Macroscopic features of scurvy in human skeletal remains: A literature synthesis and diagnostic guide. *Am J Phys Anthropol* 167, 876–895. <https://doi.org/10.1002/ajpa.23699>
- Spodzieja, K., Olczak-Kowalczyk, D., 2022. Premature Loss of Deciduous Teeth as a Symptom of Systemic Disease: A Narrative Literature Review. *Int J Environ Res Public Health* 19, 3386. <https://doi.org/10.3390/ijerph19063386>
- Suzuki, J.B., 1988. Diagnosis and classification of the periodontal diseases. *Dent Clin North Am* 32, 195–216.
- Szabo, S.M., Tomazos, I.C., Petryk, A., Powell, L.C., Donato, B.M.K., Zarate, Y.A., Tiulpakov, A., Martos-Moreno, G.Á., 2019. Frequency and age at occurrence of clinical manifestations of disease in patients with hypophosphatasia: a systematic literature review. *Orph J Rar Dis* 14, 85. <https://doi.org/10.1186/s13023-019-1062-0>
- Tagliaferro, E.P. da S., Pereira, A.C., Meneghim, M. de C., Ambrosano, G.M.B., 2006. Assessment of dental caries predictors in a seven-year longitudinal study. *J Public Health Dent* 66, 169–173. <https://doi.org/10.1111/j.1752-7325.2006.tb02575.x>
- Thomas, R.P., Moule, A.J., Bryant, R., 1993. Root canal morphology of maxillary permanent first molar teeth at various ages. *Int Endod J* 26, 257–267. <https://doi.org/10.1111/j.1365-2591.1993.tb00570.x>
- Towle, I., Loch, C., Irish, J.D., Veneziano, A., Ito, T., 2021. Chipping and wear patterns in extant primate and fossil hominin molars: 'Functional' cusps are associated with extensive wear but low levels of fracture. *J Hum Evol* 151, 102923. <https://doi.org/10.1016/j.hevool.2020.102.923>
- van den Bos, T., Handoko, G., Niehof, A., Ryan, L.M., Coburn, S.P., Whyte, M.P., Beertsen, W., 2005. Cementum and Dentin Hypophosphatasia. *J Dent Res* 84, 1021–1025. <https://doi.org/10.1177/154405910508401110>

- Whyte, M.P., 2017. Hypophosphatasia: An overview For 2017. *Bone* 102, 15–25.
<https://doi.org/10.1016/j.bone.2017.02.011>
- Whyte, M.P., Wenkert, D., McAlister, W.H., Mughal, M.Z., Freemont, A.J., Whitehouse, R., Baidam, E.M., Coburn, S.P., Ryan, L.M., Mumm, S., 2009. Chronic recurrent multifocal osteomyelitis mimicked in childhood hypophosphatasia. *J Bone Miner Res* 24, 1493–1505.
<https://doi.org/10.1359/jbmr.090308>
- Yan, J., Lou, X., Xie, L., Yu, D., Shen, G., Wang, Y., 2013. Assessment of Dental Age of Children Aged 3.5 to 16.9 Years Using Demirjian’s Method: A Meta-Analysis Based on 26 Studies. *PLoS One* 8, e84672. <https://doi.org/10.1371/journal.pone.0084672>
- Yaussy, S.L., 2019. The intersections of industrialization: Variation in skeletal indicators of frailty by age, sex, and socioeconomic status in 18th- and 19th-century England. *Am J Phys Anthropol* 170, 116–130. <https://doi.org/10.1002/ajpa.23881>
- Ziaei, H., Tonkaboni, A., Shamshiri, A., Rezaei, N., 2021. “Oral Manifestations of Patients with Inherited Defect in Phagocyte Number or Function” a systematic review. *Clin Immunol* 229, 108796. <https://doi.org/10.1016/j.clim.2021.108796>

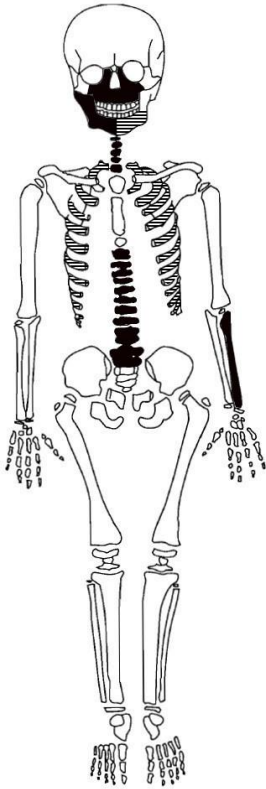


Fig. 1. Skeletal inventory of individual FA090 [1296]. The black shading indicates that bones are present, the white shading indicates that bones are absent, and the striped shading indicates that bones are present but partially preserved.

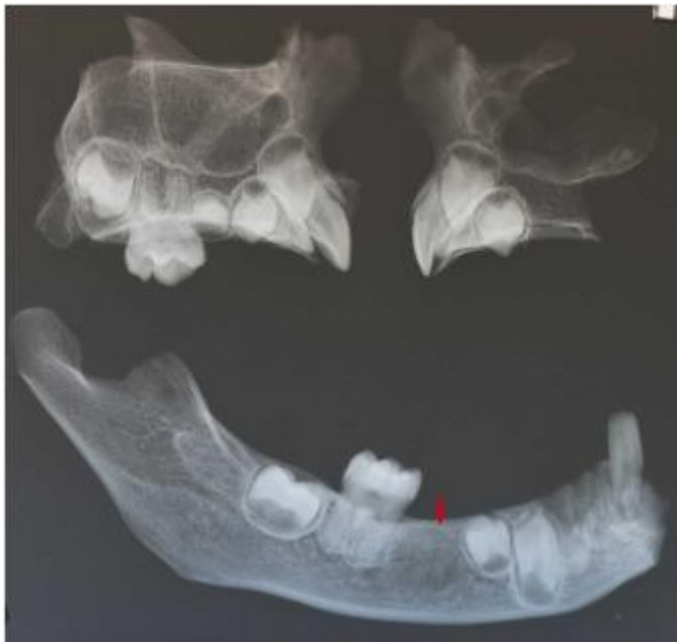

Fig. 2. Panoramic radiograph of the maxilla and mandible of individual FA090 [1296]. The red arrow indicates the radiotransparent area substituting for the germ of the mandibular right second permanent premolar.

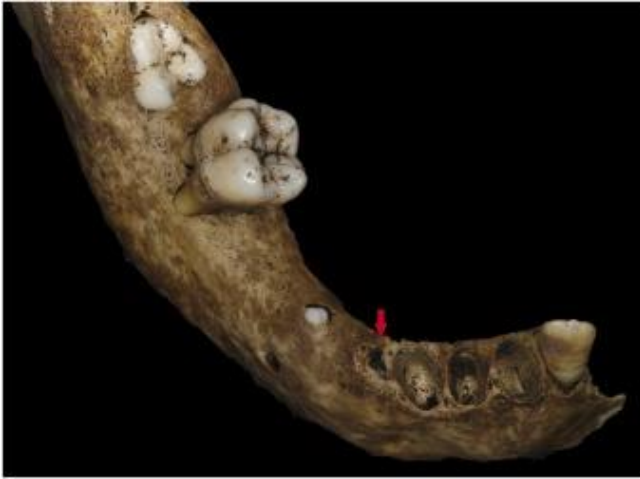

Fig. 3. Right hemi-mandible of individual FAO90 [1296] in occlusal view. The red arrow indicates the healing socket of the mandibular right deciduous canine.

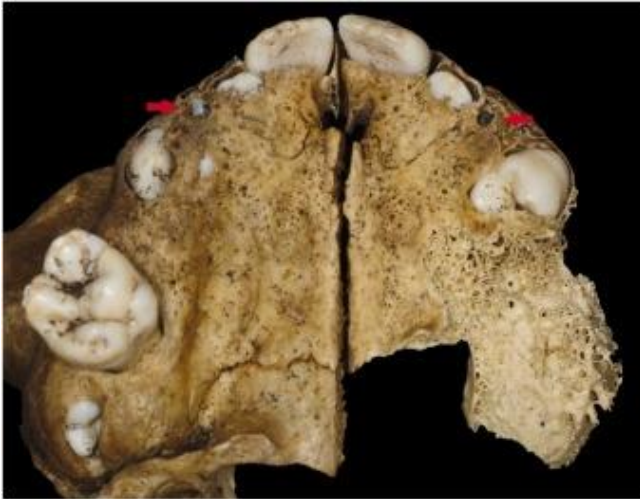

Fig. 4. Maxilla of individual FAO90 [1296] in occlusal view. The red arrows indicate the healing socket of the maxillary right and left deciduous canines.

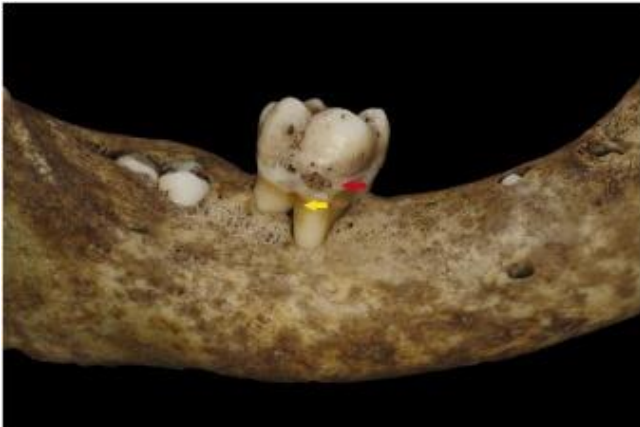


Fig. 5. Right hemi-mandible of individual FAO90 [1296] in lateral view. The red arrow indicates the slight carious lesion at the cemento-enamel junction of the right first permanent molar. The yellow arrow indicates the exposition of the furcation of the right first permanent molar.

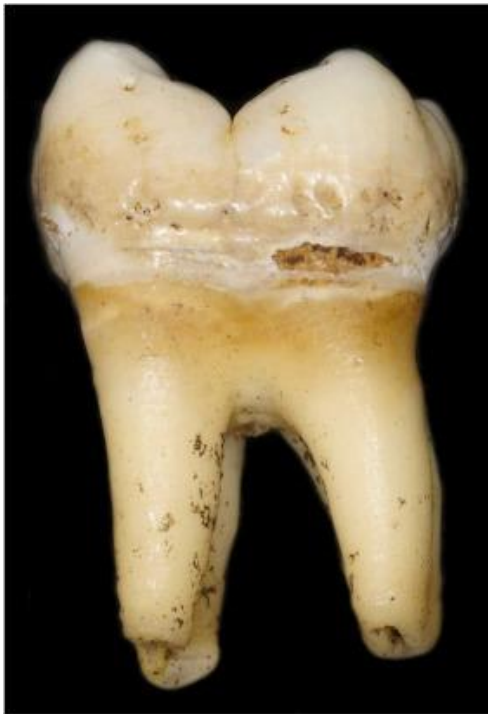

Fig. 6. Mandibular right first permanent molar of individual FAO90 [1296].

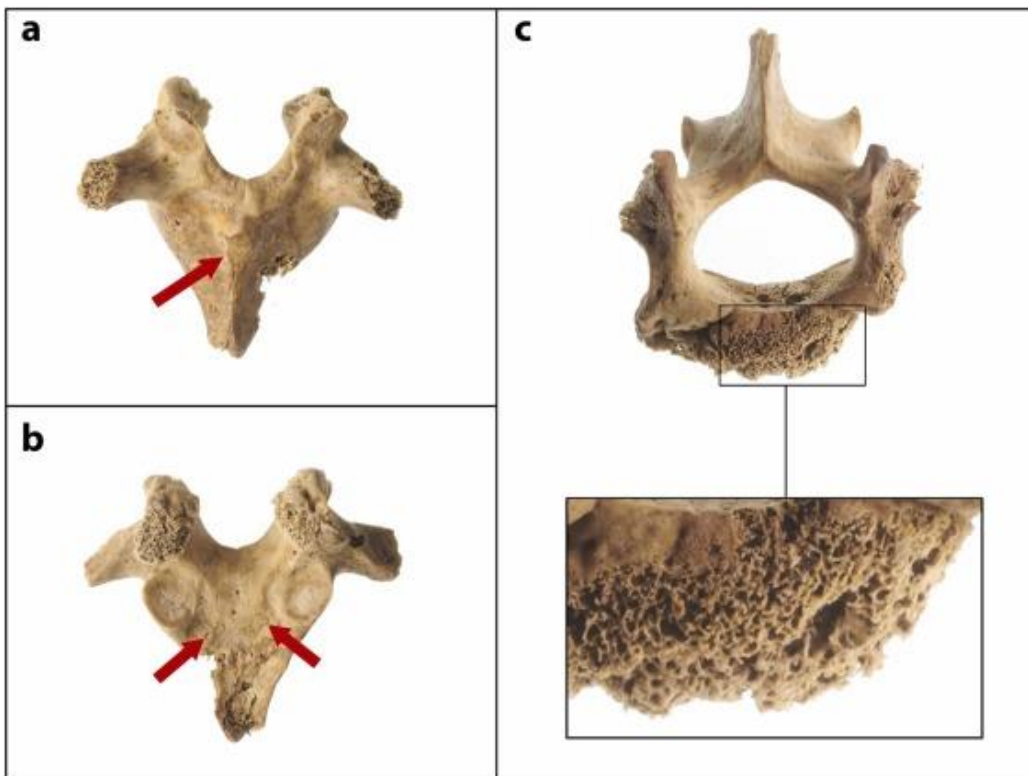


Fig. 7. Vertebral changes of individual FAO90 [1296]. a) Baastrup's sign at the base of the spinous process of a thoracic vertebra; b) bone production on the anterior surface of the neural arch of a thoracic vertebra; c) general and close-up view of the second lumbar vertebra, showing remodelled trabeculae indicative of bone remodelling secondary to an osteolytic process.



Fig. 8. Ribs changes of individual FA090 [1296]. a) General view of the ribs of the individual; b) Enlargement of the rib heads and porosity on the visceral surfaces; c) Marked porosity due to superficial bone proliferation; d) Rough texture and osteolytic foci on the visceral surface.



Fig. 9. Shallow osteolytic lesion surrounded by bone remodelling in the visceral surface of a rib.

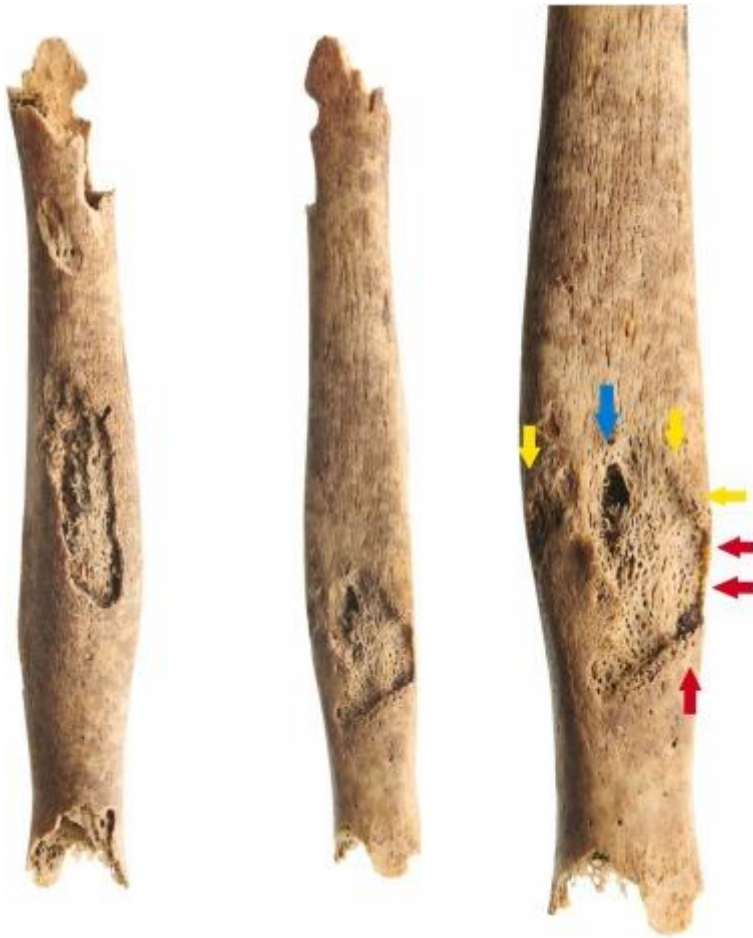

Fig. 10. Radius shaft of individual FAO90 [1296]. From left to right: swelling aspect of the radius shaft, opening in the cortical bone revealing densified cancellous bone, possible osteomyelitic lesion of the radius: The red arrows indicate the post-mortem fracture edges, the yellow arrows indicate the area of bone remodelling, the blue arrow indicates the cloaca.

Table 1. Eruption position and developmental stage of the teeth of individual FAO90 [1296].

		Eruption	Position definition**	Age (y)	Development	Stage definition**	Age Individual FAO90 [1296] (y)
RIGHT	I^{1*}	Position 3	Incisal surface midway between the alveolar bone and the occlusal plane	6.5 – 7.5	R _¼ stage	Root length less than crown length	5.5 – 7.5
	I^{2*}	Position 3	Incisal surface midway between the alveolar bone and the occlusal plane	7.5 – 9.5	R _¼ stage	Root length less than crown length	6.5 – 8.5
	C*	Position 2	Occlusal surface breaks through the crest of the alveolar bone	> 11.5	R _i stage	Initial root formation with divergent edges	5.5 – 8.5****
	P^{3*}	Position 2	Occlusal surface breaks through the crest of the alveolar bone	> 10.5	R _i stage	Initial root formation with divergent edges	6.5 – 8.5
	P^{4*}	Position 1 (inverted)	Occlusal surface is covered entirely by bone	< 11.5	Cr _¼ stage	Crown three quarters completed	4.5 – 7.5
	M¹	Position 4	Occlusal surface in the occlusal plane	> 6.5	R _c stage	Root length completed with open apexes and parallel ends	7.5 – 10.5
	M^{2*}	Position 2	Occlusal surface breaks through the crest of the alveolar bone	> 10.5	Cr _c stage	Crown completed with defined pulp roof	6.5 – 8.5
	M³	–	–	–	–	–	–
MAXILLA	I^{1*}	Position 3	Incisal surface midway between the alveolar bone and the occlusal plane	6.5 – 7.5	R _¼ stage	Root length less than crown length	5.5 – 7.5
	I^{2*}	Position 3	Incisal surface midway between the alveolar bone and the occlusal plane	7.5 – 9.5	R _¼ stage	Root length less than crown length	6.5 – 8.5
	C*	Position 2	Occlusal surface breaks through the crest of the alveolar bone	> 11.5	R _i stage	Initial root formation with divergent edges	5.5 – 8.5
	P^{3*}	Position 2	Occlusal surface breaks through the crest of the alveolar bone	> 10.5	Cr _c stage	Crown completed with defined pulp roof	5.5 – 7.5
	P⁴	–	–	–	–	–	–
	M¹	–	–	–	–	–	–
	M²	–	–	–	–	–	–
	M³	–	–	–	–	–	–
LEFT	I^{1*}	Position 3	Incisal surface midway between the alveolar bone and the occlusal plane	6.5 – 7.5	R _¼ stage	Root length less than crown length	5.5 – 7.5
	I^{2*}	Position 3	Incisal surface midway between the alveolar bone and the occlusal plane	7.5 – 9.5	R _¼ stage	Root length less than crown length	6.5 – 8.5
	C*	Position 2	Occlusal surface breaks through the crest of the alveolar bone	> 11.5	R _i stage	Initial root formation with divergent edges	5.5 – 8.5
	P^{3*}	Position 2	Occlusal surface breaks through the crest of the alveolar bone	> 10.5	Cr _c stage	Crown completed with defined pulp roof	5.5 – 7.5
	P⁴	–	–	–	–	–	–
	M¹	–	–	–	–	–	–
	M²	–	–	–	–	–	–
	M³	–	–	–	–	–	–

MANDIBLE	RIGHT	I ¹	Position 4	Occlusal surface in the occlusal plane	> 7.5	–	–	–
		I ²	Position 4	Occlusal surface in the occlusal plane	> 7.5	–	–	–
		C*	Position 1	Occlusal surface is covered entirely by bone	< 9.5	R _½ stage	Root length less than crown length	6.5 – 9.5
		P^{3*}	Position 2	Occlusal surface breaks through the crest of the alveolar bone	> 10.5	R _i stage	Initial root formation with divergent edges	6.5 – 8.5
		P ⁴	–	–	–	–	–	–
		M ¹	Position 4	Occlusal surface in the occlusal plane	> 6.5	R _c stage	Root length completed with open apexes and parallel ends	7.5 – 10.5
		M^{2*}	Position 2	Occlusal surface breaks through the crest of the alveolar bone	> 10.5	C _r stage	Crown completed with defined pulp roof	8.5 – 9.5
	M ³	–	–	–	–	–	–	
	LEFT	I ¹	Position 4	Occlusal surface in the occlusal plane	> 7.5	–	–	–
		I ^{2*}	Position 4	Occlusal surface in the occlusal plane	> 7.5	R _½ stage	Root length equals crown length	5.5 – 8.5
		C	–	–	–	–	–	–
		P ³	–	–	–	–	–	–
		P ⁴	–	–	–	–	–	–
		M ¹	–	–	–	–	–	–
M ²		–	–	–	–	–	–	
M ³	–	–	–	–	–	–		

*Teeth identified as providing a robust estimation of age at death.

**Eruptional position and developmental stages were assessed with the standards of AlQahtani et al., 2010; Bengston, 1935 and Moorrees et al., 1963.

***The physiological age ranges were based on AlQahtani et al., 2010.

****Age ranges highlighted in bold indicate discrepancies between physiological eruptional position expected age and the physiological developmental tooth stage expected age when exceeding 2 years of variation in the individual FAO90 [1296].

Table 2. Differential diagnosis for individual FA090 [1296] based on early deciduous tooth loss.

	Hypophosphatasia	Dentin Dysplasia Type I	Papillon–Lefèvre Syndrome	Chediak-Higashi Syndrome
Nosology – Aetiology	A genetic condition involving metabolic disorders due to the deficient activity of the tissue non-specific isoenzyme of alkaline phosphatase	A genetic condition due to mutations in the DSPP gene (4q21.3) coding for dentin sialophosphoprotein, involved in dentinogenesis	A genetic condition due to mutations in the CTS gene, encoding the proteolytic enzyme cathepsin C	A genetic condition due to mutations in the <i>LYST</i> lysosomal trafficking regulator gene
Early deciduous teeth loss mechanism	Teeth loss with non-resorbed roots due to cementum defects	Teeth loss due to roots malformation or absence	Aggressive periodontitis due to chemotaxis deficit	Aggressive periodontitis due to neutrophils and monocytes dysfunctions
Enamel	Possible hypoplasia ✓	No changes ✗	No changes ✗	Possible hypoplasia ✓
Dentin	Possible thin dentin wall ?	Absence of root dentin ✗	No changes ?	No changes ?
Pulp	Enlarged pulp chambers ✓	Obliterated pulp chambers ✗	No changes ✗	No changes ✗
Crown	Bulbous crowns ✓	No changes ✗	Possible microdontia ✗	No changes ✗
Roots	Short roots ✓	Absent or shortened ✗	Possibly shorts ✓	No changes ✗
Periodontal defects	Generalized horizontal bone lysis ✓	Possible bone lysis ✓	Vertical and multifocal lysis ✗	Vertical and multifocal lysis ✗
Carious lesions	Possible at the cemento-enamel junction ✓	No changes ✓	Increased incidence ✗	Increased incidence ✗
Agnesia – Eruption defects	Eruption defects ✓	Possible hypodontia ?	No changes ✗	No changes ✗

- ✓ Consistent with individual FA090 [1296].
- ? Not available or is not fully consistent with individual FA090 [1296].
- ✗ Not found in individual FA090 [1296].

Table 3. Differential diagnosis for individual FA090 [1296] in an archaeological context.

	Nutritional rickets	Scurvy	Tuberculosis	Brucellosis	Hypophosphatasia	Non-systemic aggressive pre-pubertal periodontitis
Nosology – Aetiology	A metabolic disease due to Vitamin D deficiency	A metabolic disease due to vitamin C deficiency	A mycobacterial disease due to the infection by <i>Mycobacterium tuberculosis</i>	The most common bacterial zoonosis due to the infection by <i>Brucella</i> genus pathogen	A genetic condition involving metabolic disorders due to the deficient activity of the tissue non-specific isoenzyme of alkaline phosphatase	An oral chronic multifactorial inflammatory disease associated with dysbiotic plaque biofilms and characterized by progressive destruction of the tooth-supporting apparatus at an early age of onset
Dental changes						
Early tooth loss	Absent ❌	Early tooth loss of the teeth possible ✅	Periodontal attachment involvement rarely reported ❌	Absent ❌	Early tooth loss of the deciduous teeth with intact roots ✅	Mostly the first and second deciduous molars, canines and incisors are rarely concerned ❌
Pulp chamber	“Constricted” or “chair-shaped” ❌	No changes ❌	No changes ❌	No changes ❌	Enlarged pulp chambers and root canals ✅	No changes ❌
Roots	Short roots ✅	No changes ❌	No changes ❌	No changes ❌	Short roots ✅	Mostly external and possible internal root resorptions in first and

						second deciduous molars [?]
Crowns	No changes [⊗]	No changes [⊗]	No changes [⊗]	No changes [⊗]	Bulbous crown [✓]	No changes [⊗]
Enamel – Dentin	Thin enamel [?] Enamel hypoplasia [✓]	Dentin defects [?]	Enamel hypoplasia [✓]	Enamel hypoplasia [✓]	Thin dentin wall [?] Enamel hypoplasia [✓]	No changes [⊗]
Carious lesions	Increased incidence [⊗]	Increased incidence [⊗]	No changes [⊗]	No changes [⊗]	Possible at the cemento-enamel junction [✓]	Possible at the cemento-enamel junction [✓]
Agnesia – Eruption defects	Possible agnesia and eruption defects [?]	No changes [⊗]	No changes [⊗]	No changes [⊗]	Eruption defects [✓]	No changes [⊗]
Black stains at the root tips	Absent [✓]	Present [⊗]	Absent [✓]	Absent [✓]	Absent [✓]	Absent [✓]
Cranio-facial changes						Localized bone lysis – vertical “U” bone defects around first permanent molars [⊗]
Alveolar bone lysis	Absent [⊗]	Generalized lysis [✓]	Rarely reported [⊗]	Absent [⊗]	Generalized lysis [✓]	
Cranial vault porosities (“Porotic hyperostosis”)	Possibly present [?]	Present [?]	Possibly present [?]	Possibly present [?]	Possibly present [?]	Absent [?]
Orbital roof porosities (“Cribra orbitalia”)	Possibly present [?]	Present [?]	Possibly present [?]	Possibly present [?]	Possibly present [?]	Absent [?]

**Cortical porosities
and / or
subperiosteal new
bone in lateral
aspect of the
zygomatic**

Possibly present ✓ Present ✗ Absent ✓ Absent ✓ Possibly present ✓ Absent ✓

**Cortical porosities
and / or
subperiosteal new
bone in anterior
aspect of the
maxilla**

Possibly present ✓ Present ✗ Absent ✓ Absent ✓ Possibly present ✓ Absent ✓

**Cortical porosities
and / or
subperiosteal new
bone in posterior
aspect of the
maxilla**

Possibly present ✓ Present ✗ Absent ✓ Absent ✓ Possibly present ✓ Absent ✓

**Cortical porosities
and / or
subperiosteal new
bone in palatal
aspect of the
maxilla**

Possibly present ✓ Present ✓ Absent ✗ Absent ✗ Possibly present ✓ Absent ✗

Bilateral subperiosteal new bone in mylohyoid line of the mandible


Possibly present  Present  Absent  Absent  Possibly present  Absent 

Biomechanical deformity







Deformation of the mandibular ramus  Absent  Absent  Absent  Rarely reported in the cranio-facial bones  Absent 

Ribs changes

Biomechanical deformity

Bending Absent  Absent  Absent  Bending  Absent 







Thin diameter

Possible  Absent  Absent  Absent  Present  Absent 

Costo-chondral rib flaring

Present  Present  Absent  Absent  Present  Absent 

Costo-chondral rib porosities

Present (consequence of the impaired or defective bone mineralization)  Subperiosteal new bone on the antero-lateral shaft  Present (possible consequence of a superficial bone proliferation on the visceral surfaces)  Present (possible consequence of a subperiosteal bone proliferation on the anterior surfaces)  Present (consequence of the impaired or defective bone mineralization)  Absent 

Bean-shaped lytic lesions on the visceral surfaces

Absent  Absent  Present  Absent  Absent  Absent 

Low nodules and rough texture along the costal

Rough texture as a possible consequence of the impaired or Absent  Present  Rough texture as a possible consequence of the Rough texture as a possible consequence of Absent 

grooves on the visceral surfaces	defective bone mineralization ✓			woven bone deposition ✓	the impaired or defective bone mineralization ✓
---	---------------------------------	--	--	-------------------------	---

Combination of areas with reduced and increased bone density	Possible (consequence of impaired or defective bone mineralization) ✓	Absent ✗	Possible (consequence of a superficial bone proliferation on the visceral surfaces) ✓	Possible (consequence of a subperiosteal new bone proliferation on the anterior surfaces)	Present (consequence of impaired or defective bone mineralization) ✓	Absent ✗
---	---	----------	---	---	--	----------

Long bone changes (upper limb)	Biomechanical deformity	Bending ?	Absent ?	Absent ?	Absent ?	Bending ?	Absent ?
---------------------------------------	--------------------------------	-----------	----------	----------	----------	-----------	----------

Cortical porosities	Present, especially metaphyseal (consequence of the impaired or defective bone mineralization) ✓	Diffuse subperiosteal new bone areas ?	Absent ✗	Absent ✗	Present (consequence of the impaired or defective bone mineralization) ✓	Absent ✗
----------------------------	--	--	----------	----------	--	----------

Bone thickening and or enlargement	General thickening when sufficient vitamin D becomes available to mineralize accumulated osteoid ✗	Metaphyseal enlargement ✗	Absent ✗	Absent ✗	Flared metaphysis and possible combination of areas with reduced and increased bone density ✗	Absent ✗
---	--	---------------------------	----------	----------	---	----------

Non-bacterial multifocal	Absent ✗	Absent ✗	Absent ✗	Absent ✗	Present ✓	Absent ✗
---------------------------------	----------	----------	----------	----------	-----------	----------

osteomyelitis bone lesions

Clustered pits or large cavities in the radial tuberosity of the proximal radius

Possible ✓

Absent ✓

Present ✗

Absent ✓

Possible ✓

Absent ✓

Uni or bilateral ossified hematomas

Absent ✗

Present ✓

Absent ✗

Absent ✗

Absent ✗

Absent ✗

Porosis / roughening on bone underlying growth plates

Present ?

Absent ✗

Absent ?

Absent ?

Present ?

Absent ?

Vertebral changes (thoracic and lumbar vertebral bodies)

Clustered pits or deep cavities on the cranial and caudal surfaces

Absent ✓

Absent ✓

Present ✗

Possible in less severe form than in tuberculosis ✗

Absent ✓

Absent ✓

Large pits with a roughly circular shape and rounded edges on the ventral part

Absent ?

Absent ?

Present ?

Possible in less severe form than in tuberculosis ?

Absent ?

Absent ?

Woven bone deposition on the ventral part	Absent [?]	Absent [?]	Present [?]	Possible in less severe form than in tuberculosis [?]	Absent [?]	Absent [?]
Resorption of the anterior superior margin (sclerosis, Pedro Pon's sign) +/- anterior bone spurs	Absent [×]	Absent [×]	Possible [✓]	Present [×]	Absent [×]	Absent [×]
Formation of a new joint between two vertebrae's processes (Baastrup's sign)	Possible [✓]	Absent [×]	Possible [✓]	Absent [×]	Absent [×]	Absent [×]

- ✓ Consistent with individual FAO90 [1296].
- ⊛ Not available or is not fully consistent with individual FAO90 [1296].
- ⊗ Not found in individual FAO90 [1296].