



**HAL**  
open science

## Experimental study of pelvic perioperative brachytherapy with iodine 125 seeds (I-125) in an animal model

Thomas Brun, Gwenael Ferron, Thomas Filleron, Jacques Bonnet, Alejandra Martinez, Anne Ducassou, Fabien Corbiere, Martine Delannes

### ► To cite this version:

Thomas Brun, Gwenael Ferron, Thomas Filleron, Jacques Bonnet, Alejandra Martinez, et al.. Experimental study of pelvic perioperative brachytherapy with iodine 125 seeds (I-125) in an animal model. *Journal of Contemporary Brachytherapy*, 2018, 10 (5), pp.463-469. 10.5114/jcb.2018.79470 . hal-04766411

**HAL Id: hal-04766411**

**<https://hal.science/hal-04766411v1>**

Submitted on 4 Nov 2024

**HAL** is a multi-disciplinary open access archive for the deposit and dissemination of scientific research documents, whether they are published or not. The documents may come from teaching and research institutions in France or abroad, or from public or private research centers.

L'archive ouverte pluridisciplinaire **HAL**, est destinée au dépôt et à la diffusion de documents scientifiques de niveau recherche, publiés ou non, émanant des établissements d'enseignement et de recherche français ou étrangers, des laboratoires publics ou privés.

# Experimental study of pelvic perioperative brachytherapy with iodine 125 seeds (I-125) in an animal model

Thomas Brun, MSc<sup>1</sup>, Gwenael Ferron, MD, PhD<sup>2</sup>, Thomas Filleron, PhD<sup>3</sup>, Jacques Bonnet, PhD<sup>1</sup>, Alejandra Martinez, MD<sup>2</sup>, Anne Ducassou, MD<sup>4</sup>, Fabien Corbiere, DMV, PhD<sup>5</sup>, Martine Delannes, MD<sup>4</sup>

<sup>1</sup>Department of Engineering and Medical Physics, Institut Claudius Regaud, Institut Universitaire du Cancer de Toulouse – Oncopôle,

<sup>2</sup>Department of Surgery, Inserm CRCT I9 (OncoSARC), Institut Claudius Regaud, Institut Universitaire du Cancer de Toulouse – Oncopôle,

<sup>3</sup>Institut Claudius Regaud, Institut Universitaire du Cancer de Toulouse – Oncopôle, Clinical Trials Office, <sup>4</sup>Department of Radiotherapy, Institut Claudius Regaud, Institut Universitaire du Cancer de Toulouse – Oncopôle, <sup>5</sup>Institut National Polytechnique de Toulouse/Ecole Nationale Vétérinaire de Toulouse UMR, Toulouse, France

## Abstract

**Purpose:** The aim of this study is to investigate the feasibility of perioperative I-125 low-dose-rate brachytherapy mesh implantation in pelvic locations in an animal model, before applying it clinically.

**Material and methods:** The animal model was the Romanov adult ewe. Non-radioactive dummy I-125 seeds were implanted by laparotomy in the pelvic area. Forty-five dummy seeds were placed on a 10 cm<sup>2</sup> polyglactin mesh to obtain a dose of 160 Gy at 5 mm from the center of each seed. Three CT scans were performed at day 15, day 70, and day 180 after surgery to check the positioning of the mesh for eventual seed migration according to bony landmarks and to perform a 3D theoretical dosimetric study. The experimental study design was based on Simon's minimax plan with a preliminary analysis of 10 ewes to validate the protocol and a second series of 7 ewes.

**Results:** After the first step, 9 of 10 ewes were investigated. For 8 of 9 animals, the 160 Gy isodose line volume was within 10%, showing feasibility of the procedure and allowing 7 more to be added. At the end of the study, 16 of 17 animals were examined. No seeds loss was observed. The volume difference of the 160 Gy isodose line was within 10% in 13 of 16 ewes between the three CT scans. Twelve out of 16 had a coordinate deviation less than or equal to 10 mm on the three axes between the first and the third scans.

**Conclusions:** These results show the technical feasibility of the pelvic mesh implantation in ewes. A phase I study for patients with locally advanced or recurrent pelvic tumors amenable to surgery, in combination with surgical resection should be possible.

J Contemp Brachytherapy 2018; 10, 5: 463–469

DOI: <https://doi.org/10.5114/jcb.2018.79470>

**Key words:** I-125 seeds, animal model, brachytherapy, pelvic location.

## Purpose

Locally advanced or recurrent pelvic soft tissue or gynecological tumors can be challenging for radical surgery, especially when abutting the pelvic sidewall. For patients with no previous radiotherapy, pre- or post-operative external beam radiation therapy (EBRT) is usually applied to reduce the risk of local recurrence, but the risk of microscopic involved margins after resection remains high. For patients who recur after previous radiotherapy, the dose is often limited by the risk of exceeding the normal tissue tolerance.

Intra-operative external beam radiotherapy (IORT) or brachytherapy (BT) can allow dose escalation that can

be used in such situations, delivering a perfectly targeted and localized boost dose in the perioperative period, where microscopic residues are expected, and potentially improving outcome [1,2,3,4]. Permanent low-dose-rate implants with iodine 125 (I-125) seeds, which are mostly used for prostate interstitial BT [5], could have numerous advantages compared to other techniques of perioperative dose delivery in the treatment of deep-seated pelvic tumors [6,7].

We conducted an experimental animal study to test the technical feasibility of this perioperative I-125 brachytherapy mesh implantation in a pelvic location, before applying it clinically.

**Address for correspondence:** Thomas Brun, MSc, Department of Engineering and Medical Physics, Institut Claudius Regaud, Institut Universitaire du Cancer de Toulouse – Oncopôle, 1 Avenue Irène Joliot-Curie 31059 Toulouse Cedex 9, France, phone: +33 531 155 467, fax: +33 531 155 928,   
 ✉ e-mail: [brun.thomas@iuct-oncopole.fr](mailto:brun.thomas@iuct-oncopole.fr)

Received: 07.08.2018

Accepted: 02.10.2018

Published: 30.10.2018

## Material and methods

### Animal selection

Animal selection was based on anatomical constraints similar to humans and species with low weight gain. Therefore, we used the following criteria: large adult animals, mobile and constant weight to allow unbiased evaluation during 6-month study. Thus, Romanov ewes supplied by INRA, the French national agricultural research body, aged 3 to 6 years and weighing between 50 and 60 kg were chosen for the study.

### Study design and experimental workflow

This experimental study was approved by the ethical committee for animal experimentation in the Midi-Pyrenees region, France. All the partners agreed not to euthanize the animals at the end of the study. They returned to the INRA farm to lead a normal life, in particular for reproductive purposes.

We first implanted non-radioactive dummy seeds similar to the radioactive iodine 125 seeds used in humans, with a bio-compatible flexible sterile absorbable mesh. No ewe became pregnant during the study in order to avoid the displacement of small loops by a pregnant

uterus. For the same reason, all meshes were implanted on the right side of the animal, so that the rumen, which may sometimes occupy the entire left abdomen, did not vary in volume. Meshes were therefore positioned by laparotomy in the pelvic area under general left lateral decubitus anesthesia and with minimal manipulation to avoid seed movement (Figure 1). Anesthesia was performed by a veterinary surgeon and surgery by an oncologist surgeon with an animal experimentation license.

The surgical approach was by a right transversal incision and implantation was performed after dissecting the right pelvic peritoneum. The meshes were attached to the underlying muscle wall by atraumatic clips. The intervention time ranged from 40 to 60 minutes per animal, including anesthesia, mowing, shaving, skin preparation, mesh implantation, and abdominal closure in three planes.

For this study, 45 dummy seeds (BARD Medical, Covington, USA) were placed evenly on a 10 cm<sup>2</sup> polyglactin (Vicryl®) mesh (Figure 2). The seeds were positioned so as to obtain a dose of 160 Gy at 5 mm from the center of each seed. Therefore, the seeds were shifted, and the center-to-center distance of the seeds was 10 mm for each line; the diagonal distance between each seed was 1.4 cm ( $=\sqrt{2}$ ). The seeds were glued on the mesh with a sterile

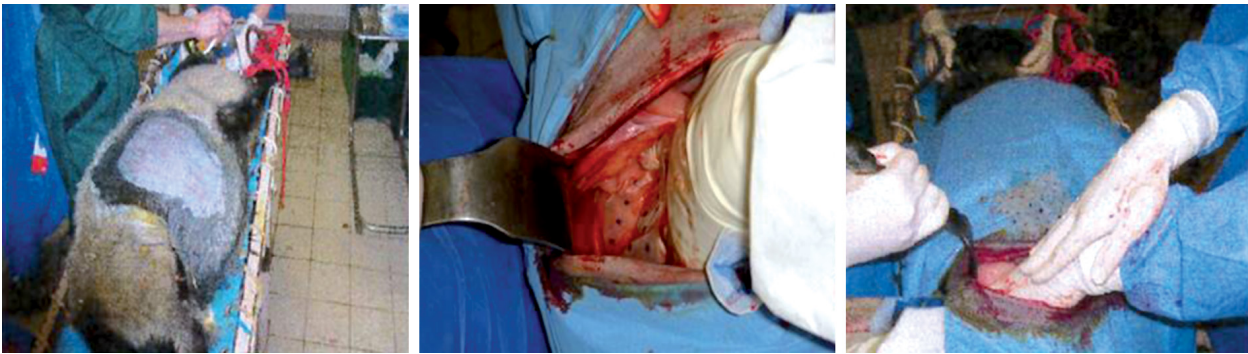


Fig. 1. Laparotomy in pelvic area of an ewe with insertion of a polyglactin mesh

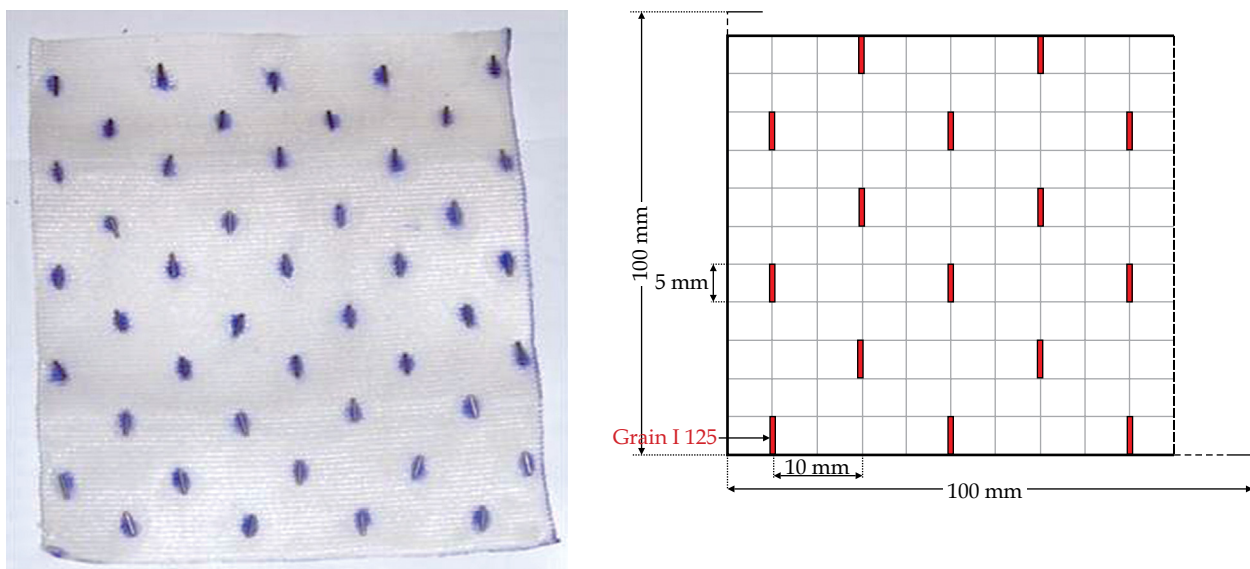


Fig. 2. 45 non-radioactive seeds distributed on a 10 cm × 10 cm polyglactin mesh

durable cyano-acrylate adhesive solution. This polyglactin mesh can be easily cut to match irregular anatomical areas.

The dummy seeds used in this study were the same as those used in human surgery. They were hermetically sealed in a titanium capsule, medical grade ASTM F67, and the ends were laser-welded. The thickness of the titanium capsule was 0.08 mm and that of the welds was 0.13 mm. Titanium is the only material that encounters the tissues and is perfectly biocompatible. Normally, the radioactive seeds contain iodine 125, which is adsorbed on an aluminum wire with a nickel copper-plated gold core. The gold contained in the wire serves as a radio-opaque X-ray marker, thereby allowing visualization after implantation. The copper layer serves as a physical substrate for the adsorption of iodine 125. The device had the following dimensions: D 0.8 mm × L 4.5 mm (Figure 3).

Finally, after the recovery period, the animals were transferred to the INRA farm and then transported to undergo dosimetric CT scans. Three CT scans were performed on a dedicated veterinary CT scanner at day 15, day 70, and day 180 after implantation. These three CT scans are called CT1, CT2, and CT3, respectively. CT

scans were completed under general anesthesia (identical protocol) to limit their stress and avoid movement.

**Dosimetric analysis**

Seed position and geometric verification during surgery and follow-up in living animals were major issues in this study. For example, if the seeds are spaced irregularly, this may cause significant dose modifications that, in turn, may lead to under-detection or over-dosing, with the foreseeable consequences of inefficient treatment and the risks of complications. A preliminary analysis with an Advantage Workstation (GE, version 4.4, USA) was carried out in order to check the positioning of the plates and any seed migration. Then, the mesh coordinates were determined between the centroid of the plate and the bone anatomical landmarks to have the same mark on the two CT scans at D+15 (CT1) and D+180 (CT3) (Figure 4). The tolerance of a shift was set at 10 mm in all directions (X, Y, Z).

Finally, a dosimetric analysis was performed on VariSeed™ (Treatment Planning System, v8.0.2, Varian Medical Systems, Inc., Palo Alto, CA, USA) between CT1, CT2, and CT3. Seeds were detected automatically on each CT scan.

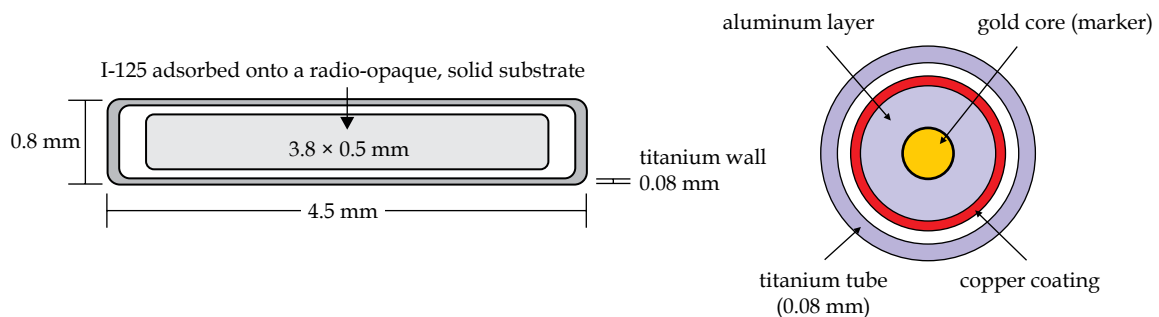


Fig. 3. Technical description of I-125 seed

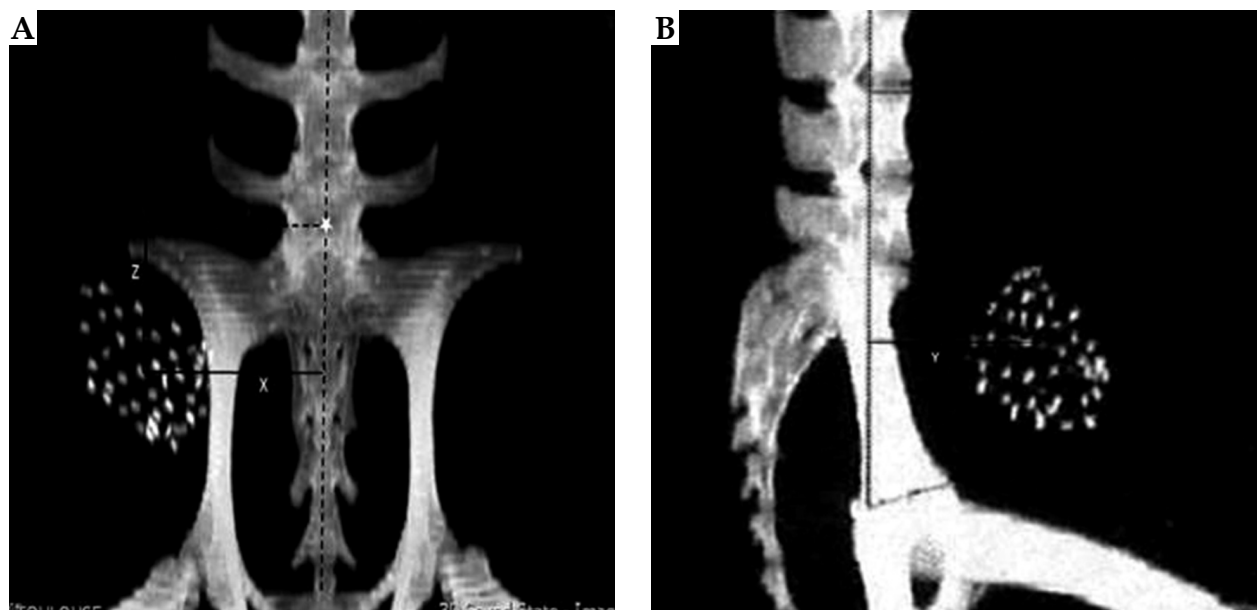


Fig. 4. Example of analysis between the center of gravity (X,Y,Z) of pelvic mesh and fixed bone references on reconstructed orthogonal images for the same CT scan

Seed activity was fixed arbitrarily at 1 U ( $= 1 \text{ uGy.m}^2/\text{h}$ ) or 0.787 mCi, to have a 160 Gy dose line around the mesh volume and 5 mm from the center of each seed (Figure 5).

### Statistical analysis

The primary endpoint was the feasibility rate. Feasibility of success was defined as a difference in the 160 Gy isodose line volume lower than  $\pm 10\%$ . Using a Simon minimax design with  $\alpha = 10$ ,  $1-\beta = 90$ ,  $p_0 = 0.70$  (maximum percentage of non-feasibility) and  $p_1 = 0.95$  (minimum percentage of feasibility), 17 ewes were included in the experimental arm. An interim analysis was performed after the inclusion of 10 ewes. If the procedure had a feasibility of success in 7 (or fewer) out of 10 animals, the procedure could be considered insufficiently feasible. At the end of the second stage, if at least 13 ewes showed a feasibility of success, it could be considered sufficiently feasible for further investigation. Continuous data were presented using median and range. Comparisons between continuous paired data were performed using the Wilcoxon paired test.

## Results

In the first phase, one out of 10 animals did not undergo the third scan and was excluded from the study. In total, 16 ewes were analyzed, 9 in the first phase and 7 in the second.

### Number of seeds and dose distribution

No seed migration was observed between the three scans; the 45 seeds remaining detectable in the 16 ewes.

For 8 of 9 animals, the 160 Gy isodose line volume was within 10%, thereby testifying the feasibility of success and allowing 7 more ewes to be added to the study. The difference in volume of the 160 Gy isodose line between the three scans and for each ewe is shown in Table 1 and Figure 6. All 16 ewes were exploitable, and 13 had a volume difference  $\leq 10\%$ . The absolute median volume difference values were 5.64% (range: 0.24-21.03) between CT1 and CT3, 3.07% (range: 0.26-16.77) between CT1 and CT2, and 3.86% (range: 0.50-13.73) between CT2 and CT3. Table 2 shows the median volume in cc of the 160 Gy isodose for the three scans and the 16 ewes.

### Mesh coordinates

Table 3 and Figure 7 shows the center of gravity coordinates of the meshes between CT1 and CT3. Twelve out of 16 animals had a coordinate deviation  $\leq 10$  mm in the three axes, 1 had one axis  $> 10$  mm, and 3 had 2 axes  $> 10$  mm. The absolute median offsets were 6.3 mm (range: 0.2-13.4) in X, 5.3 mm (range: 0.0-16.8) in Y, and 5.8 mm (range: 0.3-21.7) in Z.

## Discussion

Intra-operative external beam radiotherapy and perioperative BT allows dose escalation, while avoiding excessive doses on surrounding normal sensitive tissues [1,2,3,4]. Dose escalation with external beam radiotherapy may be difficult to establish because the high-risk residual volume cannot always be precisely defined on imaging, and/or organs at risk (OARs) cannot be correctly protected from high doses, even with intensity modulat-

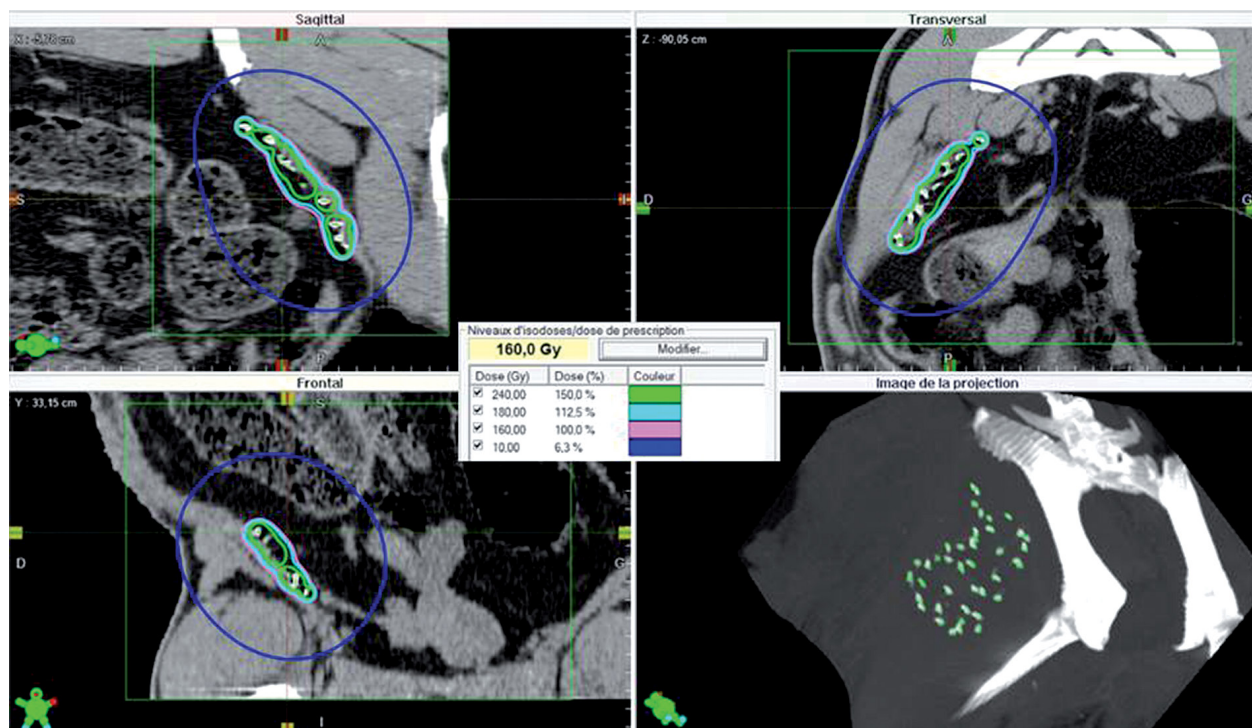


Fig. 5. Dose distribution on pelvic mesh with Variseed. 10 Gy, 160 Gy, 180 Gy, and 240 Gy isodose lines are shown in dark blue, pink, light blue, and light green, respectively

**Table 1.** Volume deviation for the first 9 ewes (left) and all 16 ewes (right) between three CT scans. “Yes” represents the number of ewes that are within 10% tolerances

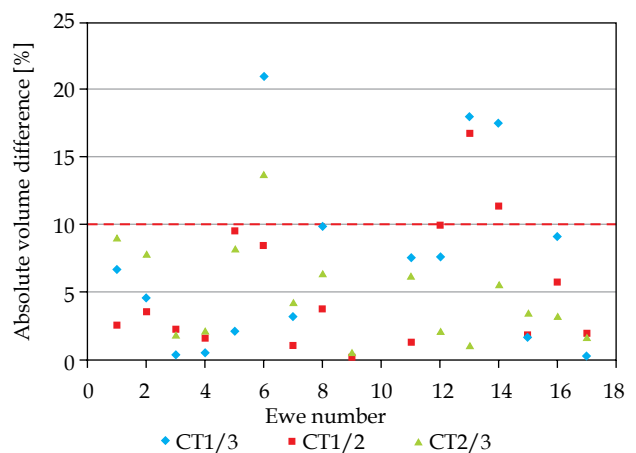
| N (%)                                  |           | N (%)                                   |            |
|--|-----------|---|------------|
| Volume deviation CT1/CT2 ≤ 10% (n = 9) |           | Volume deviation CT1/CT2 ≤ 10% (n = 16) |            |
| No                                     | 0 (0%)    | No                                      | 2 (12.5%)  |
| Yes                                    | 9 (100%)  | Yes                                     | 14 (87.5%) |
| Volume deviation CT1/CT3 ≤ 10% (n = 9) |           | Volume deviation CT1/CT3 ≤ 10% (n = 16) |            |
| No                                     | 1 (11.1%) | No                                      | 3 (18.8%)  |
| Yes                                    | 8 (88.9%) | Yes                                     | 13 (81.3%) |
| Volume deviation CT2/CT3 ≤ 10% (n = 9) |           | Volume deviation CT2/CT3 ≤ 10% (n = 16) |            |
| No                                     | 1 (11.1%) | No                                      | 1 (6.3%)   |
| Yes                                    | 8 (88.9%) | Yes                                     | 15 (93.8%) |

CT – computed tomography

ed radiation therapy. This is even more challenging in the event of recurrence after previous radiotherapy [2,3,4]. Perioperative radiation therapy with an external beam or BT can overcome these limitations, allowing the dose to be targeted to a limited volume of tissue on the high-risk region defined by a surgeon and radiation oncologist at the time of surgery. However, IORT may be difficult to apply because the facilities are lacking or because the existing applicators are not suited for treating irregular or curved surfaces.

In this setting, BT is a useful option. Temporary iridium 192 implants have been widely used in the extremities or in retro-peritoneal sarcomas [8,9,10,11,12]. The technique is much more complex for pelvic locations than for tumors of the extremities owing to the complex anatomy with curved surfaces and adjacent critical structures. This limitation can be overcome by using HDR intra-operative BT, the dose being delivered perioperatively. Thus, any critical structures may be moved away from the treatment area or protected by shielding [13]. However, there are numerous drawbacks. First, the delivery of a single high-dose can increase the risk of side effects compared to fractionated treatment, especially if any neurologic structures are within the target volume. Second, the operative time can increase significantly, if large volumes are concerned. Third, this type of brachytherapy must be performed in a dedicated shielded room.

I-125 permanent implants can overcome the limitations or drawbacks of the other BT techniques, and be of particular value in the treatment of pelvic locally advanced or recurrent tumors, especially if the recurrence occurs in a previously irradiated region. The advantage of applying this type of BT is the low energy of the I-125;



**Fig. 6.** Absolute 160 Gy volume difference for all 16 ewes between CT scans at 15 (CT1), 70 (CT2), and 180 (CT3) days after the surgery. Red line is the 10% protocol tolerance

the surrounding normal tissues can be protected more efficiently than with an Ir-192 source, and the much lower dose rate limits the occurrence of side effects. From a technical point of view, the smallness of the seeds, which can be embedded in a flexible mesh, allows any type of irregular or curved anatomical surface to be treated such as the pelvic or sacral wall, with no limitation of the irradiated volume. Moreover, the treatment can begin as soon as the operation has begun, with no need to move the patient to a dedicated unit for radioprotection or to remove catheters. Clinical experience with this type of brachytherapy is scarce and has mostly concerned thoracic tumors and abdominopelvic locations [14,15,16,17,18,19,20].

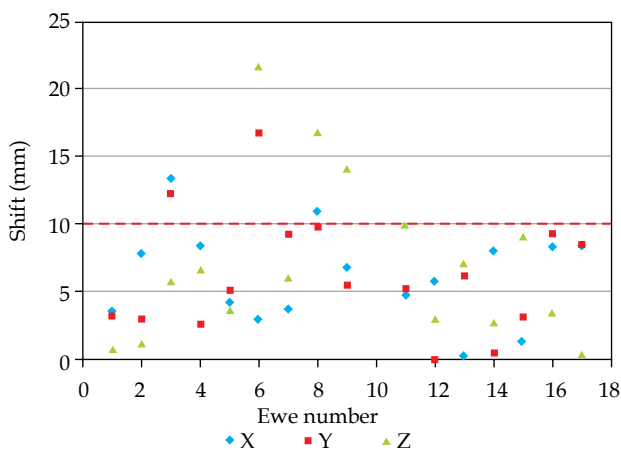
**Table 2.** Median volume (cc) of 160 Gy isodose for three CT scans on all 16 ewes

|                              | CT1<br>N = 16    | CT2<br>N = 16    | CT3<br>N = 16    | CT1 vs. CT2 | CT1 vs. CT3 | CT2 vs. CT3 |
|------------------------------|------------------|------------------|------------------|-------------|-------------|-------------|
| Volume receiving 160 Gy (cc) |                  |                  |                  | p = 0.1208  | p = 0.7959  | p = 0.4080  |
| Median (range)               | 51.3 (39.6-54.1) | 50.7 (41.9-54.3) | 50.6 (40.6-54.0) |             |             |             |

**Table 3.** Statistical analysis of pelvic mesh coordinates for the first 9 ewes (left) and all 16 ewes (right) between CT scans at 15 and 180 days after the surgery. “Yes” and “No” corresponds to the number of ewes that are in the constraints of 10 mm in the three axes, or not. 1, 2, and 3 corresponds to the number of axes that are within the tolerances of 10 mm

|                                  | N (%)     |
|----------------------------------|-----------|
| Axis deviation X ≤ 10 mm (n = 9) |           |
| No                               | 2 (22.2%) |
| Yes                              | 7 (77.8%) |
| Axis deviation Y ≤ 10 mm (n = 9) |           |
| No                               | 2 (22.2%) |
| Yes                              | 7 (77.8%) |
| Axis deviation Z ≤ 10 mm (n = 9) |           |
| No                               | 3 (33.3%) |
| Yes                              | 6 (66.7%) |
| Total deviation ≤ 10 mm (n = 9)  |           |
| 1                                | 3 (33.3%) |
| 2                                | 1 (11.1%) |
| 3                                | 5 (55.6%) |

|                                   | N (%)      |
|-----------------------------------|------------|
| Axis deviation X ≤ 10 mm (n = 16) |            |
| No                                | 2 (12.5%)  |
| Yes                               | 7 (87.5%)  |
| Axis deviation Y ≤ 10 mm (n = 16) |            |
| No                                | 2 (12.5%)  |
| Yes                               | 7 (87.5%)  |
| Axis deviation Z ≤ 10 mm (n = 16) |            |
| No                                | 3 (18.8%)  |
| Yes                               | 6 (81.3%)  |
| Total deviation ≤ 10 mm (n = 16)  |            |
| 1                                 | 3 (18.8%)  |
| 2                                 | 1 (6.3%)   |
| 3                                 | 12 (75.0%) |



**Fig. 7.** Absolute difference in coordinates for all 16 ewes between CT scans at 15 (CT1) and 180 (CT3) days after the surgery. Red line is the 10 mm protocol tolerance

Since dose delivery with permanent implants lasts 6 months, we needed to verify whether the geometry of the implant could be maintained throughout with no loss of seeds, and that the dose delivered in an experimental study was the same as the prescribed dose, before applying it clinically. We decided to use non-radioactive seeds placed on a 10 cm<sup>2</sup> mesh to deliver a theoretical 160 Gy dose at 5 mm, if radioactive I-125 were used. The mesh was then inserted on a pelvic wall of 10 adult ewes by a laparotomy performed under general anesthesia. Three CT scans were performed at day 15, day 70, and day 180 after implantation, corresponding to the post-operative evaluation, to the evaluation at the theoretical half-life

of the seeds and finally to the time necessary to deliver 90% of the dose. Of the 10 animals implanted in the first phase of the study, 9 were examined until the last scan. No seed loss was observed in any of the 9 animals. In 8 of 9 animals, the tissue volume receiving 160 Gy was within ±10%, thereby allowing 7 more animals to be included. In the 16 animals investigated at the end of the study, no loss of seeds was observed. There was no movement of the center of gravity of the mesh according to the bony landmarks exceeding 10 mm between the first and the third CT scan for 12 ewes out of 16, the maximum median value being 6.3 mm in the X axis. Moreover, 13 of the 16 animals received the treatment according to the dosimetric constraints, with ≤ 10% differences in the 160 Gy isodose line volume. Thus, the complete resorption of the polyglactin mesh in 8 weeks showed that tissue reworking is sufficient for our study and minimize the seeds migration. Furthermore, TG-43 applies perfectly in homogeneous conditions as our study. This formalism has been adopted by the entire scientific community; however, this method is not based on a model and is closely related to the superposition principle, which limits are known [21,22].

This study has several limitations. First, the abdominal volume of the animals varied owing to the size of their rumen, so it was not possible to obtain dose volume histograms of digestive or other intra-pelvic OAR. Second, it is difficult to position animals for a CT scan even when they are sedated. However, the results show that the technique can be reproduced in mobile animals. The seeds remained in position during the 6 months, with no seed loss and very little migration of the mesh, so the planned dose could be delivered in more than 80% of the

cases. The three animals that did not reach the constraints received 79%, 118%, and 118% of the planned 160 Gy volume, in which the pelvic OAR will need to be moved away from the mesh by epiploplasty or using expanders [23,24,25,26]. Furthermore, appropriate measures will be required to limit radiation exposure to the staff. For radioprotection reasons, a robot will be used to position the mesh in the pelvis, and we are now designing a procedure to allow the seeds to be placed automatically on the mesh. Once this issue is solved, a phase I study will commence for locally advanced or recurrent pelvic tumors in previously irradiated patients using intra-operative permanent I-125 implants as an adjunct to surgery.

## Conclusions

This experimental study shows that I-125 seed implantation in pelvic locations is feasible and allows adequate dose delivery during the 6 months needed to deliver the dose with permanent implants. A phase I study can now begin in patients with locally advanced or recurrent pelvic tumors amenable to surgery in combination with surgical resection.

## Disclosure

Authors report no conflict of interest.

## References

- Krengli M, Pisani C, Deantonio L et al. Intraoperative radiotherapy in gynaecological and genito-urinary malignancies: focus on endometrial, cervical, renal, bladder, and prostate cancers. *Radiat Oncol* 2017; 12: 18.
- Llewelyn M, Taylor A. Re-irradiation of cervical and endometrial cancer. *Curr Opin Oncol* 2017; 29: 343-350.
- Backes FJ, Billingsley CC, Martin DD et al. Does intra-operative radiation at the time of pelvic exenteration improve survival for patients with recurrent, previously irradiated cervical, vaginal, or vulvar cancer? *Gynecol Oncol* 2014; 135: 95-99.
- Calvo F, Sole C, Lozano M et al. Gynecologic Oncology Intraoperative electron beam radiotherapy and extended surgical resection for gynecological pelvic recurrent malignancies with and without external beam radiation therapy: Long-term outcomes. *Gynecol Oncol* 2013; 130: 537-544.
- Nath R, Bice WS, Butler WM et al. AAPM Recommendations on Dose Prescription and Reporting Methods for Permanent Interstitial Brachytherapy for Prostate Cancer: Report of AAPM Task Group No 137, 2009.
- Nath R, Anderson LL, Luxton G et al. Dosimetry of interstitial brachytherapy sources: Recommendations of the AAPM Radiation Therapy Committee Task Group No 43. *Med Phys* 1995; 22: 209-234.
- Nath R, Dewerd LA, Dezarn WA et al. Guidelines by the AAPM and GEC-ESTRO on the use of innovative brachytherapy devices and applications: Report of Task Group No 167. *Med Phys* 2016; 43: 3178-3205.
- Pisters BPWT, Harrison LB, Woodruff JM et al. Tissue sarcomas of the extremity and superficial trunk. *J Clin Oncol* 1994; 12: 1150-1155.
- Lla C, Delannes M, Minsat M et al. Low-dose intraoperative brachytherapy in soft tissue sarcomas involving neurovascular structure. *Radiother Oncol* 2006; 78: 10-16.
- Muhic A, Hovgaard D, Mørk M et al. Local control and survival in patients with soft tissue sarcomas treated with limb sparing surgery in combination with interstitial brachytherapy and external radiation. *Radiother Oncol* 2008; 88: 382-387.
- San Miguel I, San Julian M, Cambeiro M et al. Determinants of toxicity, patterns of failure, and outcome among adult patients with soft tissue sarcomas of the extremity and superficial trunk treated with greater than conventional doses of perioperative high-dose-rate brachytherapy and external beam. *Int J Radiat Oncol Biol Phys* 2011; 81: 529-539.
- Holloway CL, Delaney TF, Alektiar KM et al. American Brachytherapy Society (ABS) consensus statement for sarcoma brachytherapy. *Brachytherapy* 2013; 12: 179-190.
- Lloyd S, Alektiar KM, Nag S et al. Intraoperative high-dose-rate brachytherapy: An American Brachytherapy Society consensus report. *Brachytherapy* 2017; 16: 446-465.
- D'Amato T, Galloway M, Szydowski G et al. Intraoperative brachytherapy following thoracoscopic wedge resection of stage I lung cancer. *Chest* 1998; 114: 1112-1115.
- Voynov G, Heron DE, Lin CJ et al. Intraoperative 125 I Vicryl mesh sublobar resection for high-risk stage I non-small cell lung cancer. *Brachytherapy* 2005; 4: 278-285.
- Chen A, Galloway M, Landreneau R et al. Intraoperative I125 brachytherapy for high-risk stage I non-small cell lung carcinoma. *Int J Radiat Oncol Biol Phys* 1999; 44: 1057-1063.
- Fernando HC, Santos RS, Benfield JR et al. Lobar and sublobar resection with and without brachytherapy for small stage IA non-small cell lung cancer. *J Thorac Cardiovasc Surg* 2005; 129: 261-267.
- Santos R, Colonias A, Parda D et al. Comparison between sublobar resection and 125 Iodine brachytherapy after sublobar resection in high-risk patients with stage I non-small-cell lung cancer. *Surgery* 2003; 134: 691-697.
- Mutyala S, Stewart A, Khan AJ et al. Permanent iodine-125 interstitial planar seed brachytherapy for close or positive margins for thoracic malignancies. *Int J Radiat Oncol Biol Phys* 2010; 76: 1114-1120.
- Fairweather M, Wang J, Devlin PM et al. Safety and efficacy of radiation dose delivered via iodine-125 brachytherapy mesh implantation for deep cavity sarcomas. *Ann Surg Oncol* 2014; 22: 1455-1463.
- Ferré M, Mailleux H, Pierrat N, Dejean C. Brachytherapy dose calculation. *Cancer Radiother* 2013; 17: 89-92.
- Beaulieu L, Tedgren A, Carrier JF et al. Report of the Task Group 186 on model-based dose calculation methods in brachytherapy beyond the TG-43 formalism: Current status and recommendations for clinical implementation. *Med Phys* 2012; 39: 6208-6236.
- Leblanc E, Narducci F, Bresson L et al. A new laparoscopic method of bowel radio-protection before pelvic chemoradiation of locally advanced cervix cancers. *Surg Endosc* 2014; 28: 2713-2718.
- Choi HJ, Lee HS. Effect of omental pedicle hammock in protection against radiation-induced enteropathy in patients with rectal cancer. *Dis Colon Rectum* 1995; 38: 276-280.
- Lechner P, Cesnik H. Abdominopelvic omentopexy: preparatory procedure for radiotherapy in rectal cancer. *Dis Colon Rectum* 1992; 35: 1157-1160.
- Uehara S, Oue T, Adachi K et al. Tissue expander placement to prevent the adverse intestinal effects of radiotherapy in malignant pelvic tumors. *J Pediatr Hematol Oncol* 2016; 38: 78-81.