



**HAL**  
open science

## Reappraising *Cladophialophora bantiana* phaeohyphomycosis in France: retrospective nation-based study

Olivier Lortholary, Dea Garcia-Hermoso, Aude Sturny-Leclère, Karine Sitbon, Céline Nourrisson, Valérie Letscher-Bru, Nicole Desbois-Nogard, Ferouze Bani-Sadr, Frédéric Bastides, Boris Bienvenu, et al.

### ► To cite this version:

Olivier Lortholary, Dea Garcia-Hermoso, Aude Sturny-Leclère, Karine Sitbon, Céline Nourrisson, et al.. Reappraising *Cladophialophora bantiana* phaeohyphomycosis in France: retrospective nation-based study. *The Lancet Microbe*, 2024, 5 (11), pp.100907. 10.1016/S2666-5247(24)00139-3 . hal-04765687

HAL Id: hal-04765687

<https://hal.science/hal-04765687v1>

Submitted on 4 Nov 2024

**HAL** is a multi-disciplinary open access archive for the deposit and dissemination of scientific research documents, whether they are published or not. The documents may come from teaching and research institutions in France or abroad, or from public or private research centers.

L'archive ouverte pluridisciplinaire **HAL**, est destinée au dépôt et à la diffusion de documents scientifiques de niveau recherche, publiés ou non, émanant des établissements d'enseignement et de recherche français ou étrangers, des laboratoires publics ou privés.



Distributed under a Creative Commons Attribution - NonCommercial - NoDerivatives 4.0 International License

# Reappraising *Cladophialophora bantiana* phaeohyphomycosis in France: retrospective nation-based study



Olivier Lortholary\*, Dea Garcia-Hermoso\*, Aude Sturny-Leclère†, Karine Sitbon†, Céline Nourrisson, Valérie Letscher-Bru, Nicole Desbois-Nogard, Ferouze Bani-Sadr, Frédéric Bastides, Boris Bienvenu, Camille Cordier, Anne Coste, François Danion, Tristan Dégot, David Delarbre, Arnaud Fekkar, Christophe Garcia, Cyril Garrouste, Maud Gits-Muselli, Emilie Guemas, Antoine Huguenin, Frédéric Janvier, Nassim Kamar, Cyril Kervinio, Solène Le Gal, Olivier Lesens, Marie Machouart, Florence Persat, Sandrine Picot, Anahita Rouze, Stéphane Ranque, Yvon Ruch, Matthieu Saada, Sarah Stabler, Alexandre Alanio, Fanny Lanternier, Guillaume Desoubeaux

## Summary

**Background** *Cladophialophora bantiana* is one of the most virulent phaeohyphomycetes, typically causes non-angiogenic single (or sometimes multiple) cystic brain lesions, and has resulted in a mortality rate of up to 70%. Most *C bantiana* cases are described either in a series of isolated reports or in very small cohorts. The aim of this retrospective nation-based study was to share the data on *C bantiana* phaeohyphomycosis cases reported in France and French overseas territories over the past two decades to improve understanding of this disease.

**Methods** Patients with *C bantiana* infection were processed through the active surveillance programme of invasive fungal infections launched by the National Reference Center for Mycoses and Antifungals, Institut Pasteur (Paris, France), and the French Surveillance Network of Invasive Fungal Infections, which involved 29 hospitals from mainland France and overseas French territories. Only proven and probable cases of infection, according to the revised and updated consensus definitions from the European Organization for Research and Treatment of Cancer and Mycoses Study Group, were included in the study. Patients were diagnosed or confirmed, or both, using a polyphasic approach at the Institut Pasteur between 2002 and 2022. Patients were separated into two groups: those with CNS involvement and those with no CNS involvement. The primary outcome was the survival rate.

**Findings** A total of 23 patients with a *C bantiana* invasive infection were included during the study period (Jan 1, 2002, to Dec 31, 2022). The median age was 56 years in the CNS involvement group and 65 years in the non-CNS involvement group. Until 2021, the annual number of cases varied between zero and two, with six cases observed in 2022, the warmest year recorded in France since 1900. CNS involvement was observed in 15 (65%) patients, including three disseminated cases; skin and soft tissue involvement in seven (30%) patients and an isolated lung infection in one case. Diabetes was observed in five patients, and any immunodepression factor was observed in 14 (61%) of 23 patients. When considering only patients with CNS involvement, 9-month survival appeared higher in patients who underwent exeresis or large drainage (three [75%] of four patients vs three [27%] of 11 patients;  $p=0.24$ ) and significantly higher in those treated for 2 or more weeks with triple antifungal therapy (liposomal amphotericin B plus posaconazole and flucytosine; seven [78%] of nine patients vs one [17%] of six patients;  $p=0.040$ ). Two patients were treated with excision surgery alone (one patient with success, and the other patient lost to follow-up).

**Interpretation** This study shows that the clinical presentations and underlying medical conditions of *C bantiana* infections are more diverse than previously described. It also emphasises a significant difference in mortality rate between those with and without CNS involvement. The prognosis improved when surgery was performed and triple antifungal therapy was administered. Such rare and devastating invasive fungal infections should be managed by a multidisciplinary team.

**Funding** Santé Publique France.

**Copyright** © 2024 Published by Elsevier Ltd. This is an open access article under the CC BY-NC-ND license (<http://creativecommons.org/licenses/by-nc-nd/4.0/>).

## Introduction

Melanin-pigmented fungi, referred to as phaeohyphomycetes or dematiaceous moulds, cause diseases called phaeohyphomycosis. The absence of specific histopathological findings—neither sclerotic Medlar cells nor grains, but only yeast-like cells, pseudo-hyphae-like structures,

hyphae, or any combination of these features—distinguishes phaeohyphomycosis from chromoblastomycosis and mycetoma. These so-called black fungi can colonise harsh oligotrophic environments because of their melanised cell wall, which provides them with extreme phenotypic plasticity for adaptation. Most of them are ascomycetous

Lancet Microbe 2024

Published Online

[https://doi.org/10.1016/S2666-5247\(24\)00139-3](https://doi.org/10.1016/S2666-5247(24)00139-3)

\*Contributed equally

†Contributed equally

Institut Pasteur, Paris Cité University, National Reference Center for Invasive Mycoses and Antifungals, Translational Mycology Research Group, Mycology Department, Paris, France (Prof O Lortholary MD, D Garcia-Hermoso PhD, A Sturny-Leclère PhD, K Sitbon MD, Prof A Alanio MD, Prof F Lanternier MD); Paris Cité University, Necker-Enfants Malades University Hospital, Necker-Pasteur Center for Infectious Diseases and Tropical Medicine, Assistance Publique-Hôpitaux de Paris, Institut Hospitalo Universitaire Imagine, Paris, France (Prof O Lortholary, Prof F Lanternier); Service Parasitologie-Mycologie Centre de Biologie, Hôpital Gabriel Montpied, Clermont-Ferrand, France (C Nourrisson PharmD); Université de Strasbourg, UR 3073 Pathogens-Host-Arthropods-Vectors Interactions, Instituts de Bactériologie et de Parasitologie de la Faculté de Médecine, Strasbourg, France (V Letscher-Bru PharmD); Centre Hospitalier Régional Universitaire de Strasbourg, Plateau Technique de Microbiologie, Laboratoire de Parasitologie et Mycologie Médicale, Strasbourg, France (V Letscher-Bru); Laboratoire de Parasitologie-Mycologie, Centre Hospitalier Universitaire de la Martinique, Fort-de-France, France (N Desbois-Nogard MD); Department of Infectious Diseases, University Hospital of Reims, Reims, France (Prof F Bani-Sadr MD);

Centre Hospitalo-Universitaire Régional de Tours, Department of Infectious Diseases, Bretonneau University Hospital of Tours, Tours, France (F Bastides MD); Department of Internal Medicine, Hôpital Saint Joseph, Marseille, France (Prof B Bienvenu MD); Laboratoire de Parasitologie-Mycologie, Centre Hospitalier Universitaire de Lille, Lille, France (C Cordier PharmD); Service de Maladies Infectieuses et Tropicales, Hôpital de la Cavale Blanche, Centre Hospitalier Universitaire de Brest, Brest, France (A Coste MD); Laboratoire de Traitement de l'Information Médicale, Université de Bretagne Occidentale, Brest, France (A Coste); Hôpitaux Universitaires de Strasbourg, Service de Maladies Infectieuses et Tropicales, Strasbourg, France (F Danion MD); Université de Strasbourg, Laboratoire d'Immuno-Rhumatologie Moléculaire, Institut National de la Santé et de la Recherche Médicale S 1109, Strasbourg, France (F Danion); Respiratory Medicine and Lung Transplantation, Strasbourg University Hospital, Strasbourg, France (T Dégot MD); Service de Médecine Interne, Hôpital d'Instruction des Armées Sainte-Anne, Toulon, France (D Delarbre MD); Assistance Publique-Hôpitaux de Paris, Groupe Hospitalier La Pitié-Salpêtrière, Parasitologie Mycologie, Paris, France (A Fekkar PharmD); Sorbonne Université, Inserm, Centre National de la Recherche Scientifique, Centre d'Immunologie et des Maladies Infectieuses Cimi-Paris, Paris, France (A Fekkar); Laboratoire Commun de Biologie du Groupement Hospitalier de Territoire Béarn & Soule Centre Hospitalier de Pau, Pau, France (C Garcie PharmD); Department of Nephrology, Hôpital Gabriel-Montpied, Clermont-Ferrand, France (C Garrouste MD); Service de Microbiologie, Centre National de Référence Associé Escherichia Coli, Hôpital Robert-Debré, Assistance Publique-Hôpitaux de Paris, Paris, France (M Gits-Muselli MD); Université

## Research in context

### Evidence before this study

Melanin-pigmented fungi, referred to as phaeohyphomycetes or dematiaceous moulds, cause diseases called phaeohyphomycosis, which differs from eumycetoma by the absence of black or yellow grains and from chromoblastomycosis by the absence of other specific histopathological findings such as sclerotic Medlar cells. These so-called black fungi can colonise harsh oligotrophic environments because of their melanised cell wall, which provides them with extreme phenotypic plasticity for adaptation.

*Cladophialophora bantiana*, a member of the Chaetothyriales order, is among the most virulent phaeohyphomycetes. It typically causes a brain infection, as do other species from the *Rhinoctadiella* and *Exophiala* genera. There is no precise information about this species' ecological niche. The first case of *C bantiana* infection was described by Banti more than a century ago.

We searched PubMed for studies published between Jan 1, 2002, and Feb 6, 2024, using the terms "phaeohyphomycosis" AND "*Cladophialophora bantiana*" AND "brain" AND "diagnostic" AND "antifungal" without language restriction, and filtering for reviews and case reports. All articles retrieved were retrospective analyses of small series or individual case reports, mostly from India, dealing with brain infections occurring in young adults, most of whom were immunocompetent male patients. In these patients, non-angiogenic unique (or sometimes multiple) cystic brain lesions might occur and have resulted in a mortality rate of up to 70%. The largest series reported ten cases over 27 years. Extracerebral human infections due to *C bantiana* are extremely rare. Altogether, the data available so far do not allow for a clear picture of the epidemiological and clinical presentation, or of the most appropriate therapeutic strategy and outcome, of human *C bantiana* infections. To better assess the knowledge of this fungus and associated diseases, we decided to broaden the recruitment source of patients and corresponding fungal isolates to the country level, with national coordination from the French National Reference Center for Mycoses and Antifungals at the Institut Pasteur in Paris, France.

organisms belonging to the *Chaetothyriomycetidae* and *Dothideomycetidae* lineages. More than 150 species and 70 genera have been reported in the literature.<sup>1</sup>

*Cladophialophora bantiana*, a member of the Chaetothyriales order, is among the most virulent phaeohyphomycetes. It typically causes a brain infection, as do other species from the *Rhinoctadiella* and *Exophiala* genera. There is no precise information about this species' ecological niche. The first case of *C bantiana* infection was described by Banti<sup>2</sup> in 1911, and the first culture-proven brain infection was reported by Binford<sup>3</sup> in 1952. Since then, only a few cases have been reported, mostly from India and particularly in hosts presumed to be immunocompetent. In these patients, non-angiogenic single (or sometimes multiple) cystic brain

### Added value of this study

Based on the analysis of 23 patients with various clinical presentations and medical histories, we found that until 2021, the annual number of cases varied between zero and two, compared with six cases in 2022, which was the warmest year recorded in France since 1900. CNS involvement was observed in 15 (65%) patients (including three disseminated cases), and skin, soft tissue, and osteo-articular infections in seven (30%) patients, and an isolated lung infection in one case. Any immunodepression factor was observed in 14 patients and diabetes in five patients; when considering only patients with CNS involvement, 9-month survival was higher in patients who underwent surgery (three [75%] of four patients vs three [27%] of 11 patients;  $p=0.24$ ) and in those treated for 2 or more weeks with liposomal amphotericin B plus posaconazole and flucytosine (seven [78%] of nine patients vs one [17%] of six patients;  $p=0.040$ ). When focusing on the eight patients with non-CNS involvement, three had major surgical procedures and six survived. One patient was successfully treated with excision surgery alone.

### Implications of all the available evidence

Here, we present the largest cohort of patients with *C bantiana* infection at the country level, providing epidemiological data for temperate western regions of the world in comparison with subtropical and humid areas. The fact that less than half of patients diagnosed with *C bantiana* phaeohyphomycosis did not travel outside of France showed the autochthonous origin of these cases. In addition, skin clinical presentations supported the idea that *C bantiana* resides in French soil environments. We were able to compile a valuable and well characterised strain collection from this investigation. In combination with previous evidence, our results highlight a notable association between mean outdoor temperature and the number of infections due to *C bantiana*; clinical presentations and underlying medical conditions were more diverse than previously reported; and, finally, it was found that surgery combined with triple antifungal therapy improved the prognosis for patients with CNS involvement. This therapeutic strategy is proposed, despite the paucity of in-vivo and in-vitro experimental data.

lesions might occur and have resulted in a mortality rate of up to 70%.<sup>4</sup>

Most of the *C bantiana* cases referenced in the literature are described either in a series of isolated reports or in very small cohorts, depicted in a low number of patients. The largest series reported ten cases over a 27-year period.<sup>5</sup> In addition, several narrative reviews in this field were published, with several identical messages regarding risk factors, clinical presentation, and outcome repeated in subsequent papers without reporting additional original cases. Altogether, the available data do not provide a clear picture of the epidemiological and clinical presentation, or of the most appropriate therapeutic strategy and outcome of human *C bantiana* infection. The aim of this retrospective

nation-based study was to share the data on *C bantiana* phaeohyphomycosis cases reported in France over the past two decades to improve understanding of this disease.

## Methods

### Census of *Cladophialophora bantiana* infection cases

Patients with *C bantiana* infection were prospectively processed through the active surveillance programme of invasive fungal infections launched by the National Reference Center for Mycoses and Antifungals (NRCMA), Institut Pasteur (Paris, France) in 2002, and the French Surveillance Network of Invasive Fungal Infections, initiated in 2012. This programme involved the participation of 29 hospitals from mainland France and overseas French territories and continued until December, 2022. Only proven and probable cases of infection, according to the revised and updated consensus definitions from the European Organization for Research and Treatment of Cancer and Mycoses Study Group,<sup>6</sup> were included in the study.

A questionnaire was specifically designed to retrospectively collect data on demographics; birth location; history of travel abroad; any underlying immunodepression; clinical data; results of CT scans or MRIs of the brain; microbiological data, including  $\beta$ -d-glucan in serum and cerebrospinal fluid when available; what therapies a patient had taken; and survival. The questionnaires were distributed to each of the participant centres and completed by the clinicians and mycologists in charge of each patient.

This study involves human participants. The surveillance of the NRCMA, for which written informed consent of the patient was not necessary, was approved by the Institut Pasteur Institutional Review Board 1 (2009–34/IRB) and the Commission Nationale de l'Informatique et des Libertés according to French regulations. Physicians provided information to patients regarding data collection and ensured that if a patient did not want to be included, they would be excluded.

### Characterisation of the *Cladophialophora bantiana* isolates

Isolates were collected in their respective centres and stored in appropriate conditions. They were systematically sent to the NRCMA for identification or species confirmation in a biosafety level 3 (highly virulent fungus) containment laboratory. A polyphasic approach was carried out, with isolates first checked for purity before being subcultured on potato dextrose agar medium for at least 7 days at 30°C and 7 days at 40°C. Wet mounts were prepared from positive cultures that were 4–7 days old for microscopic examination. Genomic DNA was extracted for sequencing, as previously described,<sup>7</sup> and the barcode for the ITS1–5-8S–ITS2 region and ribosomal DNA large subunit D1–D2 (28S) sequences were used for identification.<sup>8</sup> Consensus sequences were obtained using the Sequencher version 5.4.6 sequence analysis software and pairwise aligned against curated fungal reference databases available online from the Institut Pasteur FungiBank and MycoBank database. Sequences from all isolates were deposited in GenBank under accessions

numbers: PP664419 to PP664437 (ITS) and PP664462 to PP664480 (28S). In-vitro susceptibility testing was done in accordance with the European Committee on Antimicrobial Susceptibility Testing procedure.<sup>9</sup> Six antifungal agents were used to establish the minimal inhibitory concentrations (MICs): amphotericin B, itraconazole, voriconazole, posaconazole, caspofungin, and micafungin (obtained from ALSACHIM, Illkirch, France).

### Meteorological records

Climate data were recorded by measuring the mean annual outside temperature in France from 2002 to 2022 using data from the French Meteorology Center. The results were then compared with the incidence of *C bantiana* infection. The primary outcome was survival at 9 months after diagnosis.

### Statistical analysis

All patients with *C bantiana* infection from the surveillance programmes were included. For the analysis, patients were separated into two subgroups: those with CNS involvement, with or without dissemination and with or without immunodeficiency, and those with no apparent radiological lesions in the CNS, with localised lesions after a major trauma (car accidents, etc) and with or without immunodeficiency. Patients were separated into these subgroups because CNS involvement is a marker of the initial severity of a *C bantiana* infection and indicates therapeutic difficulty. Analyses were performed on isolates from single episodes of *C bantiana*, with each isolate corresponding to a single patient. Quantitative variables (eg, age and duration of therapy) were expressed as the mean (SD), whereas qualitative variables (eg, male to female sex ratio and the presence of pre-existing risk factors) were presented in frequency (percentages) and SD. 95% CIs were also calculated for all quantitative variables. Fisher's exact, Wilcoxon, and Mann–Whitney tests were used for independent samples. The  $\alpha$  risk was set at 0.05. Statistical analyses were done in XLStat2023 Addinsoft, version 1.1.

### Role of the funding source

The funder of the study had no role in study design, data collection, data analysis, data interpretation, or writing of the report.

### Results

A total of 23 patients with a *C bantiana* invasive infection were included during the study period (Jan 1, 2002, to Dec 31, 2022; tables 1, 2), including one child aged 6 years (patient number 9). There were no cases in 2002–03, and then subsequently between zero and two cases each year until 2021. In 2022, six cases were observed (patient numbers 18–23). According to the French Meteorology Center, 2022 was the hottest year recorded since 1900 (appendix p 1). Among 23 patients, four declared at least one instance of travel outside of France and three travelled in one of the French overseas territories. Any immunodepression was observed in 14 (61%) of 23 patients.

Paris Cité, Infection Antimicrobials Modelling Evolution, Institut National de la Santé et de la Recherche Médicale, Paris, France (M Gits-Muselli); Parasitology-Mycology Department of Toulouse University Hospital, Toulouse, France (E Guemas PharmD); Centre National de la Recherche Scientifique, Unité Mixte de Recherche 5051, Institut National de la Santé et de la Recherche Médicale, Unité Mixte de Recherche 1291, Université Paul Sabatier, Toulouse, France (E Guemas); Université de Reims Champagne Ardenne, Epidémiologie et Circulation de Parasites dans les Environnements - UR 7510 Equipe d'Accueil 510, Reims, France (A Huguenin MD); Laboratoire de Parasitologie-Mycologie, Pôle de Biologie Pathologie, Centre Hospitalier Universitaire de Reims, Rue du Général Koenig, Reims, France (A Huguenin); Service de Microbiologie et Hygiène Hospitalière, Hôpital d'Instruction des Armées Sainte-Anne, Toulon et Ecole du Val-de-Grâce, Paris, France (F Janvier MD); Transplantation, Toulouse University Hospital, Institut National de la Santé et de la Recherche Médicale, Unité Mixte de Recherche 1291, Toulouse Institute for Infectious and Inflammatory Diseases (Infinity), Université Paul Sabatier, Toulouse, France (Prof N Kamar MD); Service de Gériatrie, Centre Hospitalier François Mitterrand, Pau, France (C Kervinio MD); Centre Hospitalier Régional Universitaire Hôpital de la Cavale Blanche, Brest, France (S Le Gal MD); Université d'Angers, Infections Respiratoires Fongiques, Brest, France (S Le Gal); Service de Médecine Interne, Hôpital Gabriel-Montpied, Clermont-Ferrand, France (Prof O Lesens MD); Laboratoire Stress Immunité Pathogènes, EA7300, Faculté de Médecine, Vandœuvre-les-Nancy, France (Prof M Machouart PharmD); Service de Parasitologie-Mycologie, Centre Hospitalier Régional Universitaire de Nancy, Hôpitaux de Brabois, Nancy, France (Prof M Machouart);

UR3738 Centre pour l'Innovation en Cancérologie de Lyon, Team Inflammation and Immunity of the Respiratory Epithelium, Claude Bernard University-Lyon 1, Pierre Bénite, France (F Persat PhD); Department of Medical Mycology and Parasitology, Institute of Infectious Agents, Croix-Rousse Hospital, Hospices Civils de Lyon, Lyon, France (F Persat); Bacteriologie, Centre Hospitalier Universitaire Sud Réunion, Saint-Pierre, France (S Picot PharmD); Centre National de la Recherche Scientifique, Institut National de la Santé et de la Recherche Médicale, Centre Hospitalier Universitaire Lille, Unité Mixte de Recherche 8576 - U1285 - Unité de Glycobiologie Structurale et Fonctionnelle, Lille, France (A Rouze MD); Service de Médecine Intensive - Réanimation, Université de Lille, Lille, France (A Rouze); Institut Hospitalo-Universitaire, Méditerranée Infection, Marseille, France (Prof S Ranque MD); Hôpitaux Universitaires de Strasbourg, Department of Tropical and Infectious Diseases, Nouvel Hôpital Civil, Strasbourg, France (Y Ruch MD); Centre Hospitalier de Perpignan, Infectious Diseases Unit, Perpignan, France (M Saada MD); University Lille, Centre National de la Recherche Scientifique Institut National de la Santé et de la Recherche Médicale Lille, Lille, France (S Stabler MD); Institut Pasteur de Lille, U1019 - Unité Mixte de Recherche 9017 - Center for Infection and Immunity of Lille, Lille, France (S Stabler); Laboratoire de Parasitologie-Mycologie, AP-HP, Hôpital Saint-Louis, Paris, France (Prof A Alanio); Centre Hospitalo-Universitaire Régional de Tours, Department of Parasitology-Mycology-Tropical Medicine, Tours, France (Prof G Desoubeaux MD)

Correspondence to: Prof Olivier Lortholary, Institut Pasteur, Paris Cité University, National Reference Center for Invasive Mycoses and Antifungals, Translational Mycology Research Group, Mycology Department, Paris 75015, France [olivier.lortholary@pasteur.fr](mailto:olivier.lortholary@pasteur.fr)

	Date of diagnosis	Sex, age (years)	Continent of birth	Travel outside France	Underlying diseases or pre-existing risk factors and treatment	Time between onset of symptoms and DO (days)	Anatomical sites of infection (additional details)	Co-infections
1	2004	F, 66	Africa	Réunion	Autoimmune hepatitis plus corticosteroids and immunosuppressive regimen	142	Skin (abscess of the left forearm)	Oesophageal candidiasis
2	2005	F, 74	Europe	NA	Chronic lymphoid leukaemia plus fludarabine	37	Brain (left temporal cystic lesion)	None
3	2006	M, 57	Europe	NA	COPD plus corticosteroids and lung cancer	NA	Brain (hydrocephalus)	None
4	2009	M, 48	NA	Viet Nam	Local injection of corticosteroids for a non-specific inflammatory nodule	879	Skin (single subcutaneous nodule)	None
5	2009	M, 76	Europe	None	Mycosis fungoides and diabetes	82	Brain (right thalamic cystic mass with perilesional oedema)	None
6	2010	M, 75	Europe	None	Previous tuberculosis and prostate adenocarcinoma	27	Brain (left parieto-occipital mass with perilesional oedema)	None
7	2011	M, 44	Africa	NA	Traffic accident responsible for skin abscess	2	Skin (abscess of the left leg)	<i>Aspergillus fumigatus</i> and <i>Pleurostomophora</i> sp in the wound
8	2013	F, 38	Europe	None	Cystic fibrosis with lung transplantation and diabetes	90	Brain (left cerebellar nodule and myelitis)	Influenza infection and pulmonary mucormycosis
9	2014	M, 6	South America	Guyana	Cranial trauma	22	Brain (multiple abscesses with perilesional oedema and ventriculitis)	<i>Candida haemulonii</i> and <i>Kodamaea ohmer</i> in the sinus
10	2014	F, 80	NA	NA	Bronchial dilatation	6	Lung	None
11	2016	M, 35	Europe	Togo	Traffic accident responsible for skin abscess	390	Skin (tumefaction of the elbow)	None
12	2016	M, 63	Europe	None	Lung transplantation plus corticosteroids and immunosuppressive regimen, diabetes, and renal failure	34	Brain (multiple frontal, left temporal, and occipital abscesses)	None
13	2017	M, 58	Europe	None	Chronic parotiditis	24	Brain (three necrotic masses: frontal, cerebellar, and left lenticulo-insular with perilesional oedema)	Prostatitis with <i>Pseudomonas aeruginosa</i> , bacteraemia, and dental abscess in the left maxillary sinus
14	2019	M, 47	Europe	Kosovo	Kidney transplantation plus corticosteroids and immunosuppressive regimen	15	Brain (left parieto-occipital mass with perilesional oedema)	None
15	2019	F, 69	Europe	None	None	27	Skin (tumefaction of the right foot)	<i>Mycobacterium fortuitum</i> in the wound
16	2020	M, 36	Europe	None	Chronic granulomatous disease	110	Disseminated (brain: one in occipital and two in temporal lobes, plus one in the cerebellum, lungs, and lymph nodes)	None
17	2020	M, 56	Africa	Congo (Brazzaville)	Kidney transplantation plus corticosteroids, immunosuppressive regimen, and diabetes	36	Disseminated (brain and skin)	COVID-19
18	2022	F, 38	Africa	NA	Tuberous sclerosis with multi-organ involvement, kidney transplantation plus corticosteroids and immunosuppressive regimen, and diabetes	20	Brain (left frontal abscess with perilesional oedema) and lungs (nodule in the right superior lobe)	Tuberculosis and pneumocystis pneumonia

(Table 1 continues on next page)



Date of diagnosis	Sex, age (years)	Continent of birth	Travel outside France	Underlying diseases or pre-existing risk factors and treatment	Time between onset of symptoms and DO (days)	Anatomical sites of infection (additional details)	Co-infections	
(Continued from previous page)								
19	2022	F, 76	NA	None	Idiopathic CD4 <sup>+</sup> lymphocytopenia	30	Brain (left frontal mass)	None
20	2022	M, 80	Europe	None	Stage 3 COPD	32	Brain (left frontal abscess)	None
21	2022	M, 83	Central America	French West Indies	Squamous cell carcinoma of the oropharynx	NA	Skin (tumefaction of the dorsal surface of the left hand)	None
22	2022	M, 39	Europe	None	Inherited immune deficiency	106	Brain	None
23	2022	M, 63	Europe	Corsica	Ankle trauma	29	Skin and bone (necrosis of soft tissues and lower part of the left tibia)	None

DO was the day of diagnosis completion. No cases were observed in 2002 and 2003. COPD=chronic obstructive pulmonary disease. F=female. M=male. NA=not available.

**Table 1: Description of 23 individual cases *Cladophialophora bantiana* infection diagnosed in France between 2002 and 2022, with confirmation by the National Reference Center of Mycosis and Antifungals**

As briefly mentioned earlier, the global cohort included two substantially different subgroups: one group with CNS involvement (n=15), including localisation to the brain alone for 12 patients and with dissemination to other organs for three patients (ie, with at least one non-CNS organ involved: skin in patient number 16, lungs and lymph nodes in patient number 17, and lungs for patient number 18); and another group without CNS infection (n=8) that mostly concerned skin and soft tissues involvement (in seven of eight patients). One patient in the no CNS involvement group had an isolated pulmonary disease, and was also the only patient to present with a probable infection (patient number 10). Where the patients resided was mapped against the city where *C bantiana* strain was first isolated (appendix p 1). There was not a significantly higher number of cases in the warmest regions, but 14 patients were diagnosed in the southern part of France or in overseas French territories, whereas four other patients (diagnosed in the northern part of France) could potentially have contracted the disease from abroad.

In the subgroup of 15 patients with a CNS infection (tables 1–3), the median age was 56 years, 11 (73%) of 15 patients were male, and four (27%) patients were female. Briefly, 15 patients presented with at least one pre-existing associated immunodeficiency: six (40%) patients who underwent immunosuppressive therapy, four (27%) patients who had an inherited immune deficiency or from some form of cancer, including leukaemia, and five (33%) who had diabetes or were solid organ transplant recipients, or both. One (7%) patient had head trauma.

From the results of a CT scan or MRI of the brain, 11 (73%) of 15 patients had a single lesion, whereas four (27%) had multiple lesions with no location predominance or influence from any associated disease. In addition to the brain, the spinal cord, cerebellum, and ventricles were all affected in patient number 16. Figure 1 depicts two MRI

images of a single brain abscess in patient number 13. The median time from symptom onset to diagnosis completion was 33 days. The prognosis did not differ significantly based on cerebral imaging findings or the duration of the diagnosis procedure (p>0.05).

Eight patients were included in the no CNS involvement group (tables 1–3), seven of which presented with at least one pre-existing associated immunodeficiency; seven cases involved skin infection (plus local involvement of the tibia bone for patient number 23) and one only lung involvement (patient number 10). The median age was 65 years, five (63%) of eight patients were male, and three (38%) patients were female. Trauma (eg, accident, fall, drug, or medicine injection) was present in four patients (50%), with six (75%) of these cases occurring outside of mainland France. The time between the trauma and the infection diagnosis varied from 2 weeks to 110 days, with no significant effect on the prognosis (p>0.05).

Histopathological investigations were performed in 11 patients (48%), ten with CNS involvement and one with no CNS involvement: pigmented hyphae were seen in eight patients with CNS involvement (figure 2A) and one patient with no CNS involvement (patient number 4); in a majority of these 11 patients, pigmented hyphae were seen in a granulomatous inflammatory reaction. Macroscopic examination of the biopsies showed yellow brown infected tissues, necrotic tissue deterioration, and pus production. Direct microscopic mycological observation was completed for 19 patients (83%) and was compatible with the diagnosis of phaeohiphomyces by revealing the presence of black hyphae for 14 specimens (61%), including ten of 13 with CNS involvement (figure 2B) and four of six with no CNS involvement. Mycological culture was positive in all cases which was the primary criterion for inclusion. All strains were morphologically compatible with *C bantiana*, growing at 42°C as velvety to hairy olivaceous green colonies with long

or  
Prof Guillaume Desoubeaux,  
Centre Hospitalo-Universitaire  
Régional de Tours, Department  
of Parasitology-Mycology-  
Tropical Medicine, Tours 37044,  
France  
[guillaume.desoubeaux@univ-tours.fr](mailto:guillaume.desoubeaux@univ-tours.fr)

For the Institut Pasteur  
FungiBank, see: [https://  
fungi.bank.pasteur.fr/](https://fungi.bank.pasteur.fr/)

For the MycoBank database,  
see: <http://www.mycobank.org/>

For the French Meteorology  
Center, see: <https://meteofrance.com/>

See Online for appendix

	Diagnostic approaches			Therapy						Mortality status $\leq 9$ months* (date)
	Histopathology of available tissue	Conventional mycology		$\beta$ -d-glucan measurement (pg/mL)	Date of surgeries		Antifungal drugs			
		Direct examination	Fungal culture		Punction or drain	Exeresis	First line	Second line	Subsequent lines	
1	NA	Negative	Positive	NA	None	None	None	None	None	Deceased (D10)
2	NA	Positive	Positive	NA	None	None	Liposomal amphotericin plus voriconazole plus flucytosine (D1–4)	Liposomal amphotericin plus voriconazole (D5–13)	None	Deceased (D13)
3	NA	NA	Positive	NA	None	None	Liposomal amphotericin plus flucytosine (D1–15)	None	None	Deceased (D15)
4	Positive	Positive	Positive	NA	None	D0	None	None	None	Alive (D5048)
5	Negative	Negative	Positive	NA	D13	None	Voriconazole (D5–51)	None	None	Deceased (D51)
6	Positive	Negative	Positive	NA	D14	None	Liposomal amphotericin plus posaconazole plus flucytosine (D9–527)	Posaconazole plus flucytosine (D528–3257)	None	Alive (D3256)
7	NA	Negative	Positive	NA	None	None	Posaconazole plus flucytosine (D1–185)	None	None	Alive (D4138)
8	Positive	Positive	Positive	NA	None	None	Liposomal amphotericin plus posaconazole plus flucytosine (D1 onwards)	None	None	Alive (D569)
9	NA	Positive	Positive	Serum 149 pg/mL; cerebrospinal fluid >500 pg/mL	D3	D1	Liposomal amphotericin (D1–8)	Liposomal amphotericin plus voriconazole (D8–10)	Liposomal amphotericin plus voriconazole plus flucytosine (D10–36), and then liposomal amphotericin plus posaconazole plus flucytosine (D37–58)	Alive (D431)
10	NA	NA	Positive	NA	None	None	Posaconazole	None	None	Alive (D1003)
11	NA	Positive	Positive	NA	D5	None	Itraconazole (D9–24)	None	None	NA
12	Positive	Positive	Positive	Serum >80 pg/mL	None	None	Voriconazole (D0–D1)	Voriconazole plus caspofungin (D0–9)	Voriconazole plus caspofungin plus flucytosine (D9–180), and then voriconazole plus flucytosine (D181–228)	Alive (D227)
13	Positive	Positive	Positive	Serum >80 pg/mL	None	None	Liposomal amphotericin (D1–3)	Liposomal amphotericin plus posaconazole (D3–9)	Liposomal amphotericin plus posaconazole plus flucytosine (D10–50), posaconazole plus flucytosine (D51–1230), and then posaconazole (D1230 onwards)	Alive (D1608)
14	NA	Positive	Positive	NA	D0	None	None	None	None	Deceased (D1)
15	NA	Positive	Positive	NA	D6	None	Posaconazole plus caspofungin (D3–7)	Posaconazole (D8–95)	None	Alive (D95)
16	Positive	Positive	Positive	Serum <80 pg/mL	D1 and D0	D13 (brain), D49 and D125 (nodes)	Posaconazole plus caspofungin plus flucytosine (D1–31)	Liposomal amphotericin plus posaconazole plus flucytosine (D32–171)	Liposomal amphotericin plus posaconazole (D172–475)	Alive (D1280)
17	Positive	Positive	Positive	Serum >80 pg/mL	D0 and D13 (skin)	None	Liposomal amphotericin (D19–21)	Voriconazole (D21–41)	Liposomal amphotericin plus posaconazole plus flucytosine (D42–63)	Deceased (D63)
18	NA	Positive	Positive	NA	D0 and D112	None	Liposomal amphotericin plus posaconazole plus flucytosine (D1 onwards)	None	None	Alive (D180)
19	Positive	NA	Positive	NA	None	None	Liposomal amphotericin (D0–8)	Liposomal amphotericin plus posaconazole plus flucytosine (D09–13)	Posaconazole plus flucytosine (D14–16)	Deceased (D16)
20	Negative	Negative	Positive	NA	None	None	Isavuconazole (D31 onwards)	None	None	Alive (D360)
21	NA	Positive	Positive	NA	None	D0	None	None	None	Alive (D270)
22	Positive	Positive	Positive	NA	None	None	Liposomal amphotericin plus posaconazole plus flucytosine (D1–107)	None	None	Deceased (D107)
23	NA	NA	Positive	NA	D0	None	Liposomal amphotericin (D7 onwards)	None	None	Alive (D134)

D0 was the day of diagnosis completion, and D1 onwards were all subsequent days. No cases were observed in 2002 and 2003. NA=not available. \*For deceased patients, the date is the day of death; for alive patients, the date is the day at which mortality was last recorded.

**Table 2: Investigation, treatment, and outcome of 23 individual cases *Cladophialophora bantiana* infection diagnosed in France between 2002 and 2022, with confirmation by the National Reference Center of Mycosis and Antifungals**

	CNS involvement (n=15)		No CNS involvement (n=8)	
	Number of patients	Percentage of patients (95% CI)	Number of patients	Percentage of patients (95% CI)
Median age, years	56 (6–80)	50.8 (95% CI 37.4–64.1)	65 (35–83)	61.0 (95% CI 46.6–75.4)
<b>Continent of birth</b>				
Europe	11	73.3% (95% CI 53.8–96.2)	3	37.5% (95% CI 4.0–71.0)
Africa	2	13.3% (95% CI 0.0–28.7)	2	25.0% (95% CI 0.0–55.0)
North and South America	1	8.7% (95% CI 0.0–18.1)	1	12.5% (95% CI 0.0–35.4)
Travel outside France	4	20% (95% CI 0.5–49.5)	4	50.0% (95% CI 15.4–84.6)
Underlying diseases or pre-existing risk factors*	15	100.0% (95% CI 100–100)	7	87.5% (95% CI 64.6–100)
Immunosuppressive drugs or systemic corticosteroids	6	40.0% (95% CI 13.8–61.2)	2	25.0% (95% CI 0.0–55.0)
Diabetes	5	33.3% (95% CI 9.5–57.2)	0	0
Solid organ transplantation	5	33.3% (95% CI 9.5–57.2)	0	0
Leukaemia or other types of cancers	4	26.6% (95% CI 4.3–49.0)	1	6.6% (95% CI 0.0–35.4)
Inherited immune deficiency	4	26.6% (95% CI 4.3–49.0)	0	0
Trauma or tissue effraction	0	0	4	50.0% (95% CI 15.4–84.6)
Concomitant co-infections*	4	26.6% (95% CI 4.3–49.0)	3	37.5% (95% CI 4.0–71.0)
With bacteria	3	20.0% (95% CI 0.5–49.5)	1	6.6% (95% CI 0.0–35.4)
With other fungi	4	26.6% (95% CI 4.3–49.0)	3	37.5% (95% CI 4.0–71.0)
With viruses	2	13.3%	0	0
Median number of days between onset of symptoms and date of diagnosis completion	33 (15–110)	48.0 (95% CI 28.3–67.7)	29 (2–879)	206.1 (95% CI 0.0–508.4)
Completion of laboratory diagnostics*	15	100.0% (95% CI 100–100)	8	100.0% (95% CI 100–100)
Histological observation of any clinically relevant tissue sample available	10	67.7% (95% CI 42.8–90.5)	1	12.5% (95% CI 0.0–35.4)
Positive for black hyphae and granuloma	8	53.6% (95% CI 31.0–75.8)	1	12.5% (95% CI 0.0–35.4)
Direct examination of any tissue or fluid clinically relevant available	13	93.3% (95% CI 69.5–100)	6	87.5% (95% CI 45.0–100)
Positive for black septate hyphae	10	67.7% (95% CI 42.8–90.5)	4	50.0% (95% CI 15.4–84.6)
Fungal culture	15	100.0% (95% CI 100–100)	8	100.0% (95% CI 100–100)
Positive for <i>C. bantiana</i>	15	100.0% (95% CI 100–100)	8	100.0% (95% CI 100–100)
$\beta$ -d-glucan measurement	5	33.3% (95% CI 9.5–57.2)	0	0
Above the positive $\beta$ -d-glucan threshold ( $\geq 80$ pg/mL)	4	26.6% (95% CI 4.3–49.0)	0	0

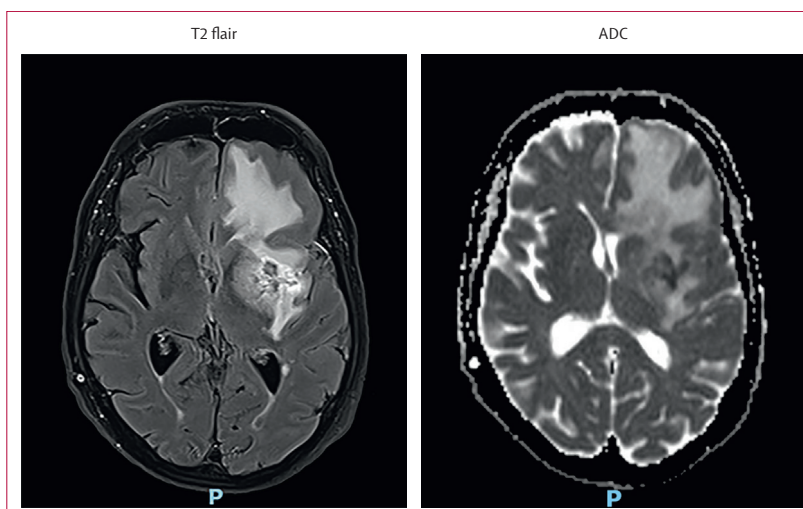
\*Several are possible in a single patient.

**Table 3:** Description of 23 cases of *Cladophialophora bantiana* infection including their diagnostic strategy, according to CNS involvement or not

chains of ellipsoidal to fusiform conidia (figure 2C, D). DNA sequencing (GenBank accession numbers; appendix p 2) revealed that all isolates univocally belonged to the species *C. bantiana*. Percentage identity with reference strain CBS 173.52 ranged from 99.6 to 100.0% (more than 457 base pairs in length) for internal transcribed spacer from 99.0 to 100.0% (more than 557 base pairs in length) for large subunits.

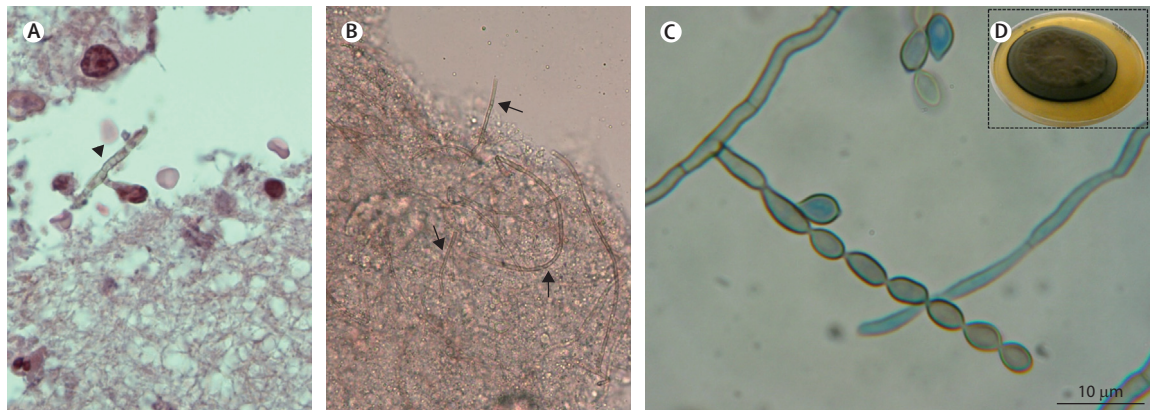
$\beta$ -d-glucan was tested for in the serum of five patients with a CNS infection (patients number 9, 12, 13, 16, and 17), and was more than 80 pg/mL (the threshold) in four patients. Of note,  $\beta$ -d-glucan was more than 500 pg/mL in the cerebrospinal fluid for patient number 9.

Nine strains were tested to establish the MICs; all other strains did not sporulate sufficiently for this purpose. The most active antifungal agents were posaconazole (MIC range 0.02–0.03 mg/L), itraconazole (0.03–0.06 mg/L), and voriconazole (0.13–0.25 mg/L). Isavuconazole (0.25–1.00 mg/L) and amphotericin B (0.50–2.00 mg/L) showed moderate activity, whereas echinocandins, such as caspofungin and micafungin, had high MIC values (more than 4 mg/L).



**Figure 1:** Medical imaging of a brain abscess caused by *Cladophialophora bantiana*  
MRI for patient number 13, according to T2 flair sequence and ADC diffusion, highlighting important oedema around the nodular neoteric lesion in the left frontotemporal lobe. ADC=apparent diffusion coefficient.





**Figure 2: Diagnostic findings for *Cladophialophora bantiana* infection**

(A) Histopathological observation showing pigmented and septate hyphae (black dart) within the brain parenchyma for patient number 13 (haematoxylin eosin safran staining, magnification  $\times 400$ ). (B) Mycological direct observation showing pigmented hyphae (black arrows) with septa and right-angle branching for patient number 13 (fresh mounting, magnification  $\times 400$ ). (C) Conidiogenous cell and catenate melanised conidia. Scale bars indicate  $10\ \mu\text{m}$ . (D) Suede-like colony on Sabouraud dextrose agar after 20 days at  $30^\circ\text{C}$ .

Surgery was possible in seven (47%) of 15 patients with CNS involvement, including two who benefited from a radical excision of the main lesions (at the time of diagnosis for patient number 9, whereas smaller lesions in patient number 16's cerebellum and temporal lobe were not accessible), and two patients benefited from large abscess drainage (appendix p 3). Except for one patient who died soon after diagnosis (patient number 14), all patients with CNS involvement received systemic antifungal therapy for 2 or more weeks. A combination of two or more antifungal drugs were given to 12 (80%) patients, with 11 (73%) patients benefiting from triple association and six (40%) patients in first-line therapy after diagnosis. The most commonly used combination was liposomal amphotericin B plus posaconazole and flucytosine at a high dose ( $\geq 5\ \text{mg/kg}$  per day; nine [82%] of 11 patients). This triple therapy was initiated on average 15 days (1–42) after diagnosis and for a mean duration of 171 days (5–569). In contrast, only three (38%) of eight patients in the no CNS involvement subgroup received a combination therapy (appendix p 3). The majority of patients (five [63%] of eight patients) instead had access to debridement surgery, alone or sometimes in association with medicines.

Except for those who died rapidly (two [9%] of 23 died within 10 days after diagnosis), all patients with no CNS involvement had a follow-up of more than 3 months. Eight (35%) of 23 patients died at a median of 54 days after their diagnosis. Mortality was higher in cases with CNS involvement compared with those without (mortality rate, 66.7% vs 12.5%;  $p=0.030$ ). The prognosis improved in the CNS subgroup when a triple antifungal combination was given for 2 or more weeks (survival rate, 77.7% vs 16.7%;  $p=0.040$ ; table 4), but there was no significant difference with first-line, second-line, or third-line therapy ( $p>0.05$ ). Regardless of the clinical context, surgical intervention (radical exeresis or large drainage) was associated with better outcomes (88.9% vs 35.7%;  $p=0.030$ ).

## Discussion

This nationwide study of *C bantiana* infection provides several important new insights. First, in terms of epidemiology and trends, we reported 23 cases over a 20-year period of investigation, the largest cohort ever studied at a country level. We provided epidemiological data that were discordant with data usually seen in temperate western regions of the world, which are different from subtropical and humid areas as reported in the literature.<sup>1</sup> The fact that 70% of patients diagnosed with *C bantiana* phaeohiphomycosis had not travelled outside of mainland France showed the autochthonous origin of these cases. In addition, the high representation of skin clinical presentation supported the idea that *C bantiana* resides in French soil environments. Of note, although other *Cladophialophora* species are typically found in the soil,<sup>10</sup> most previous studies have not shown an environmental reservoir for *C bantiana*, with a few exceptions. In the published literature, a majority of *C bantiana* cases are in men (>70%), the mean age was 35 years, nearly 60% of patients had no comorbidities, and a third had been treated with steroids for other underlying diseases.

Furthermore, few cases have been described in kidney, liver, and heart recipients previously. Infection occurs at a median time of 7–22 months after solid organ transplantation<sup>11</sup> or allogeneic bone marrow engraftment.<sup>12</sup> In patients who had undergone allogeneic bone marrow engraftment, dissemination with concomitant cerebral and pulmonary lesions have been observed in previous studies. Infections in children are rare and, when they occur, justify screening for a primary inherited immune deficiency. For example, in other fungal diseases, a genetic predisposition has been suggested for *CARD9* mutation<sup>13</sup> or chronic granulomatous disease. Few animal cases have been reported, but none among them were sufficiently documented to suggest any direct transmission to humans.<sup>14</sup> Only 15 cases had data on the occupations and activities of deceased patients, and the two most frequent were farmers and florists or gardeners.<sup>15</sup>

	Number of patients	Percentage of patients who underwent therapeutic intervention (95% CI)	Outcome at 9 months	Success ratio	Percentage of patients who survived (95% CI)	p value*
<b>Cases of <i>Cladophialophora bantiana</i> infection involving the CNS, with or without dissemination (n=15)</b>						
Exeresis or large drainage: complete	4	26.7% (95% CI 4.3–49.0)	Survival	3:4	75.0% (95% CI 32.6–100.0)	..
Exeresis or large drainage: absence or partial	11	73.3% (95% CI 53.8–96.2)	Survival	3:11	27.3% (95% CI 10.0–53.6)	0.24
Triple antifungal therapy: duration ≥2 weeks	9†	60.0% (95% CI 29.2–76.7)	Survival	7:9	77.7% (95% CI 50.6–100.0)	..
Triple antifungal therapy: absence or duration <2 weeks	6	40.0% (95% CI 13.8–61.2)	Survival	1:6	16.7% (95% CI 0.0–46.5)	0.04
<b>Cases of <i>C bantiana</i> infection limited to skin and soft tissues or lungs only, without dissemination and excluding involvement of the CNS (n=8)</b>						
Exeresis or large drainage: complete	5	62.5% (95% CI 29.0–96.0)	Survival‡	5:5‡	100.0% (95% CI 100.0–100.0)	..
Exeresis or large drainage: absence or partial	3	37.5% (95% CI 4.0–71.0)	Survival‡	2:3	66.6% (95% CI 13.3–100.0)	0.37
Triple antifungal therapy: duration ≥2 weeks	0	0.0% (95% CI 0.0–0.0)	Survival‡	Not available	Not available	..
Triple antifungal therapy: absence or duration <2 weeks	8	100.0% (95% CI 100–100)	Survival‡	7:8‡	87.5% (95% CI 64.6–100.0)	NA

NA=not applicable. \*Fisher's exact test for independent samples. †Including eight of nine patients receiving liposomal amphotericin B plus posaconazole plus flucytosine in combination, and four among these eight patients were in first-line therapy. ‡One patient was lost to follow-up and was considered alive.

**Table 4: Type of therapeutic interventions and outcome, by CNS involvement**

Our study had some limitations. First, in our study, no clear factors related to work and environmental exposure could be found. In comparison with other *Cladophialophora* species, the thermotolerance (ie, growth at 40°C or even at 42°C) of *C bantiana* was higher. Therefore, the increased annual incidence of infectious episodes in 2022 (up to 6 times more in 2022 vs what was recorded in all other years between 2002 and 2021), the warmest year in France since 1900, might be linked to this exceptional hot weather event. Furthermore, other emergent pathogenic fungi could also be the consequence of global warming.<sup>16</sup>

Second, in our study, the clinical presentation of *C bantiana* infection was different from previous reports. In contrast to 97.5% of previously reported cases,<sup>13</sup> cases with CNS involvement represented only 65% of patients in our study. Among 101 cases of culture-proven CNS phaeohyphomycosis referenced in the English language literature from 1966 to 2002, 48 (47.5%) were due to *C bantiana*, meaning it was the agent that most frequently caused CNS brain abscesses among all cases of CNS phaeohyphomycosis recorded.<sup>1</sup> Two large studies conducted in Chandigarh<sup>4</sup> and Bangalore<sup>17</sup> in India indicated that *C bantiana* caused 15.2% and 44% of infections with CNS involvement, respectively. Finally, in a prospective 5-year trial, *C bantiana* caused 1.3% of all-cause intracranial abscesses in India.<sup>18</sup> CNS involvement usually affects patients who are immunocompetent (in approximately three-quarters of all cases),<sup>15</sup> which contrasts with our data (all CNS cases had underlying diseases or were pre-exposed to any type of immunosuppression). It has been found that brain infection concerns a single lesion in 67% of cases, located in the white matter and most often located in the frontal lobes,<sup>19</sup> and is rarely occipital.<sup>2</sup> MRI examination finds ring-enhancing lesions on the T1 sequence, and a hypointensity of the ring on T2. Involvement of meninges in association with the brain (in 14.2% of cases) or alone (in 2.5% of cases) is rare. Myelitis has also been reported.<sup>20</sup> In patients who are immunosuppressed, there might be multiple lesions. In this study, we reported seven cases of skin, soft tissue, and bone infection after an identified trauma in four cases. In the literature,

only a few cases of isolated skin or subcutaneous, or both, *C bantiana* infections were observed, more commonly after a severe trauma (n>5), steroid injections in a skin scar, or in immunosuppressed individuals.<sup>21</sup> The time between trauma and the infection diagnosis varied substantially from 2 weeks to 110 days in our study and was observed up to 15 years in the literature.<sup>17</sup> In addition, septic arthritis, vertebral osteomyelitis, and tibia subacute osteomyelitis have been reported, especially during dissemination in immunodeficient patients.<sup>22</sup> Of note, an infection occurring in the site of renal allograft has also been reported.

Third, looking at the diagnosis of *C bantiana* infection, it is noteworthy that CNS clinical symptoms are non-specific, so that its confirmation might be delayed until autopsy.<sup>4</sup> Biopsies typically show a granulomatous reaction with vasculitis and brown septate hyphae inside. *C bantiana* grows slowly on routine culture media mostly in 2 weeks, resulting in moderate conidiogenesis. Usually, blood and cerebrospinal fluid cultures are sterile.<sup>23</sup> The microbiology laboratory should receive a black mould alert, and biosafety level 3 precautions should be applied.<sup>15,24</sup>

Fourth, our study corroborated the severity of CNS infection due to *C bantiana*, but also provided important data on therapeutic options. A better outcome was observed in patients who had surgical resection and in those with CNS involvement treated with a triple combination antifungal therapy containing posaconazole, liposomal amphotericin B, and flucytosine. The treatment of CNS infection due to *C bantiana* is supposed to include a radical surgical debridement, a double or triple combination of antifungals, and, when possible, immune recovery. Excision of the brain lesion has been shown to be associated with increased survival, but is not always feasible.<sup>14</sup> Regarding the antifungal therapy, the four drugs shown in vitro to be the most active against *C bantiana* are amphotericin B, flucytosine, posaconazole, and voriconazole. Amphotericin B is fungicidal, showing excellent diffusion into the brain, especially in its liposomal form. The relevance for using flucytosine relies on its correct penetration in the CNS, its in vitro synergy with amphotericin B<sup>24</sup> and its efficacy in

experimental models and in patients. Unfortunately, in reality, this compound is on short supply.

Although it is only fungistatic and has limited penetration in the brain,<sup>25</sup> posaconazole has the lowest MIC values.<sup>26</sup> Variable efficacy has been shown with voriconazole.<sup>27</sup> In one study summarising the literature data, a triple therapy combining amphotericin B, flucytosine, and an azole drug (itraconazole) improved the survival in a subgroup of transplant recipients.<sup>1</sup> Experimentally, long-term therapy with posaconazole, micafungin, and flucytosine appeared to be one of the best combinations.<sup>28</sup> The in situ administration of amphotericin B might be valuable if a large resection cannot be completed.<sup>29</sup> The recently published international guidelines on rare mould infections recommend either itraconazole or voriconazole monotherapy for localised lesions, whereas disseminated infections should be treated by a combination containing voriconazole or posaconazole in addition to one echinocandin or even voriconazole and terbinafine.<sup>30</sup> The duration of therapy is not standardised: in cases of cerebral abscesses when surgery is not possible and in cases of disseminated infection in immunocompromised patients,<sup>30</sup> it is recommended to systematically administer at least two antifungal drugs for a long-term therapy ( $\geq 3$  months) until the normalisation of MRI and potential side-effects are manageable.<sup>31</sup> Revankar and colleagues<sup>1</sup> proposed that patients who are free of symptoms for at least 1 year could be considered for the withdrawal of antifungal therapy. In contrast, other authors suggest that *C bantiana* cannot be totally eradicated, thereby requiring definitive maintenance therapy. Of note, general therapeutic guidelines for the treatment of systemic phaeo-ophomycosis are now available;<sup>26</sup> they suggest obtaining in vitro MICs of each isolate. Moreover, adjunctive cytokine and colony-stimulating factor-based immunotherapy might reinforce the strategy, but none of the patients in our study received this therapy.<sup>31–34</sup>

Despite the informative new data generated in the present study, there are also some limitations, such as the long-term period of the study, resulting in different evaluation tools being used over time, as well as this study's retrospective nature, and the low number of patients which could make it difficult to produce definitive conclusions.

In conclusion, we suggest that climate changes had an effect on the epidemiology of *C bantiana* infection, and that the clinical features of this infection should be reappraised compared with the literature, because our study had a high representation of non-CNS disease. Despite innovative therapeutic strategies, the persistent severity of CNS infection due to *C bantiana* suggests that it should be diagnosed as soon as possible even in non-tropical areas such as mainland France. Finally, it was found that surgery combined with triple antifungal therapy improved the prognosis of this infection, although confirmatory data are warranted.

In high-income countries, there should now be clinical awareness on the emergence of phaeo-ophomycosis due to *C bantiana*, with the occurrence of severe cerebral lesions

and foci after major telluric trauma. Although our new data on antifungal therapy data are of interest, they do not replace international guidelines.

#### Contributors

OL and GD conceived the study concept. KS made the census of the cases. OL, KS, and GD created the clinical report form. OL, KS, and GD contacted all the scientific partners for obtaining the medical records. KS and GD completed the summary table with all the medical records. DG-H confirmed the strain identification. DG-H and AS-L established the in vitro testing for identifying the minimum inhibitory concentration. OL, KS, DG-H, and GD analysed the data. OL, DG-H, and GD interpreted the data. OL wrote the first version of the manuscript. GD edited the first version of the manuscript and completed the manuscript. KS and DG-H read and modified the updated version of the manuscript. All authors revised the manuscript and approved the final version for publication. OL, FL, and GD supervised the whole process. OL, DG-H, and GD had access to and verified the data.

#### Declaration of interests

We declare no competing interests.

#### Data sharing

The anonymised data file can be shared upon request to the corresponding author (olivier.lortholary@pasteur.fr), via a link allowing the file to be downloaded through an institutional secure server.

#### Acknowledgments

The study was supported by Santé Publique France, which provided salaries.

#### References

- Revankar SG, Sutton DA. Melanized fungi in human disease. *Clin Microbiol Rev* 2010; **23**: 884–928.
- Banti G. Sopra un caso di oidiomicosi cerebrale. *Lo Sperimentale* 1911; **65**: 341.
- Binford CH, Thompson RK, Gorham ME. Mycotic brain abscess due to *Cladospirium trichoides*, a new species; report of a case. *Am J Clin Pathol* 1952; **22**: 535–42.
- Chakrabarti A, Kaur H, Rudramurthy SM, et al. Brain abscess due to *Cladophialophora bantiana*: a review of 124 cases. *Med Mycol* 2016; **54**: 111–19.
- Garg N, Devi IB, Vajramani GV, et al. Central nervous system cladosporiosis: an account of ten culture-proven cases. *Neurol India* 2007; **55**: 282–88.
- Donnelly JP, Chen SC, Kauffman CA, et al. Revision and update of the consensus definitions of invasive fungal disease from the European Organization for Research and Treatment of Cancer and the Mycoses Study Group Education and Research Consortium. *Clin Infect Dis* 2020; **71**: 1367–76.
- Garcia-Hermoso D, Hamane S, Fekkar A, et al. Invasive infections with *Nannizziopsis obscura* species complex in 9 patients from west Africa, France, 2004–2020(1). *Emerg Infect Dis* 2020; **26**: 2022–30.
- Garcia-Hermoso D, Hoinard D, Gantier JC, Grenouillet F, Dromer F, Dannaoui E. Molecular and phenotypic evaluation of *Lichtheimia corymbifera* (formerly *Absidia corymbifera*) complex isolates associated with human mucormycosis: rehabilitation of *L. ramosa*. *J Clin Microbiol* 2009; **47**: 3862–70.
- European Committee on Antimicrobial Susceptibility Testing. EUCAST definitive document E.DEF 9.4. March, 2022. [https://www.eucast.org/fileadmin/src/media/PDFs/EUCAST\\_files/AFST/Files/EUCAST\\_EDef\\_9.4\\_method\\_for\\_susceptibility\\_testing\\_of\\_moulds.pdf](https://www.eucast.org/fileadmin/src/media/PDFs/EUCAST_files/AFST/Files/EUCAST_EDef_9.4_method_for_susceptibility_testing_of_moulds.pdf) (accessed Aug 7, 2024).
- Vicente VA, Attili-Angelis D, Pie MR, et al. Environmental isolation of black yeast-like fungi involved in human infection. *Stud Mycol* 2008; **61**: 137–44.
- Levin TP, Baty DE, Fekete T, Truant AL, Suh B. *Cladophialophora bantiana* brain abscess in a solid-organ transplant recipient: case report and review of the literature. *J Clin Microbiol* 2004; **42**: 4374–78.
- Emmens RK, Richardson D, Thomas W, et al. Necrotizing cerebritis in an allogeneic bone marrow transplant recipient due to *Cladophialophora bantiana*. *J Clin Microbiol* 1996; **34**: 1330–32.

- 13 Seyedmousavi S, Netea MG, Mouton JW, Melchers WJ, Verweij PE, de Hoog GS. Black yeasts and their filamentous relatives: principles of pathogenesis and host defense. *Clin Microbiol Rev* 2014; **27**: 527–42.
- 14 Rantala M, Attia S, Koukila-Kähkölä P, de Hoog S, Anttila M, Katila T. *Cladophialophora bantiana* as an emerging pathogen in animals: case report of equine endometritis and review of the literature. *J Clin Microbiol* 2015; **53**: 3047–53.
- 15 Kantarcioglu AS, Guarro J, De Hoog S, Apaydin H, Kiraz N. An updated comprehensive systematic review of *Cladophialophora bantiana* and analysis of epidemiology, clinical characteristics, and outcome of cerebral cases. *Med Mycol* 2017; **55**: 579–604.
- 16 Casadevall A. Global warming could drive the emergence of new fungal pathogens. *Nat Microbiol* 2023; **8**: 2217–19.
- 17 P K, Raj P, Jabeen S, et al. Clinicomycological overview of brain abscess in a tertiary care center: a 38 year retrospective: fungal brain abscess. *J Mycol* 2021; **31**: 101156.
- 18 Menon S, Bharadwaj R, Chowdhary A, Kaundinya DV, Palande DA. Current epidemiology of intracranial abscesses: a prospective 5 year study. *J Med Microbiol* 2008; **57**: 1259–68.
- 19 Dixon DM, Walsh TJ, Merz WG, McGinnis MR. Infections due to *Xylohypha bantiana* (*Cladosporium trichoides*). *Rev Infect Dis* 1989; **11**: 515–25.
- 20 Shields GS, Castillo M. Myelitis caused by *Cladophialophora bantiana*. *AJR Am J Roentgenol* 2002; **179**: 278–79.
- 21 Hussey SM, Gander R, Southern P, Hoang MP. Subcutaneous phaeohyphomycosis caused by *Cladophialophora bantiana*. *Arch Pathol Lab Med* 2005; **129**: 794–97.
- 22 Lim A, Speers D, Inderjeeth C. *Cladophialophora* (*Xylohypha*) *bantiana*—an unusual cause of septic arthritis. *Rheumatology (Oxford)* 2013; **52**: 958–59.
- 23 Chatzopoulos K, Eschbacher KL, Gurrum PR, et al. An 82-year-old man with a right frontal lobe rim-enhancing lesion. *Brain Pathol* 2022; **32**: e13021.
- 24 Deng S, Pan W, Liao W, et al. Combination of Amphotericin b and flucytosine against neurotropic species of melanized fungi causing primary cerebral phaeohyphomycosis. *Antimicrob Agents Chemother* 2016; **60**: 2346–51.
- 25 Barde F, Billaud E, Goldwirt L, et al. Low central nervous system posaconazole concentrations during cerebral phaeohyphomycosis. *Antimicrob Agents Chemother* 2019; **63**: e01184-19.
- 26 Al-Abdely HM, Najvar LK, Bocanegra R, Graybill JR. Antifungal therapy of experimental cerebral phaeohyphomycosis due to *Cladophialophora bantiana*. *Antimicrob Agents Chemother* 2005; **49**: 1701–07.
- 27 Schweizer LA, Bärlocher L, Graber A, Boggian K. Brain abscess caused by *Cladophialophora bantiana*: total remission after full resection and short-course voriconazole treatment. *Med Mycol Case Rep* 2018; **23**: 43–45.
- 28 Mariné M, Pastor FJ, Guarro J. Combined antifungal therapy in a murine model of disseminated infection by *Cladophialophora bantiana*. *Med Mycol* 2009; **47**: 45–49.
- 29 Aljuboori Z, Hruska R, Yaseen A, Arnold F, Wojda B, Nauta H. Fungal brain abscess caused by “Black Mold” (*Cladophialophora bantiana*) - a case report of successful treatment with an emphasis on how fungal brain abscess may be different from bacterial brain abscess. *Surg Neurol Int* 2017; **8**: 46.
- 30 Hoenigl M, Salmanton-García J, Walsh TJ, et al. Global guideline for the diagnosis and management of rare mould infections: an initiative of the European Confederation of Medical Mycology in cooperation with the International Society for Human and Animal Mycology and the American Society for Microbiology. *Lancet Infect Dis* 2021; **21**: e246–57.
- 31 Mody P, Wada P, Bloch KC, et al. Gram stain to the rescue: a case report of cerebral phaeohyphomycosis by *Cladophialophora bantiana* in an immunocompetent 24-year-old. *BMC Infect Dis* 2022; **22**: 13.
- 32 Casadevall A, Pirofski LA. Adjunctive immune therapy for fungal infections. *Clin Infect Dis* 2001; **33**: 1048–56.
- 33 Mazo Fávero Gimenes V, Da Glória de Souza M, Ferreira KS, et al. Cytokines and lymphocyte proliferation in patients with different clinical forms of chromoblastomycosis. *Microbes Infect* 2005; **7**: 708–13.
- 34 Teixeira de Sousa MG, Ghosn EE, Almeida SR. Absence of CD4+ T cells impairs host defence of mice infected with *Fonsecaea pedrosoi*. *Scand J Immunol* 2006; **64**: 595–600.