



**HAL**  
open science

# Genomic Diversity of HPV6 and HPV11 in Recurrent Respiratory Papillomatosis: Association with Malignant Transformation in the Lungs and Clinical Outcomes

Massilva Rahmoun, Audrey Aussel, Sarah Bouzidi, Vincent Pederagnana, Victor Malassigné, Julien Puech, David Veyer, Hélène Péré, Charles Lépine, Fabian Blanc, et al.

## ► To cite this version:

Massilva Rahmoun, Audrey Aussel, Sarah Bouzidi, Vincent Pederagnana, Victor Malassigné, et al.. Genomic Diversity of HPV6 and HPV11 in Recurrent Respiratory Papillomatosis: Association with Malignant Transformation in the Lungs and Clinical Outcomes. *Tumour Virus Research*, 2024, 18, pp.200294. 10.1016/j.tvr.2024.200294 . hal-04762020

**HAL Id: hal-04762020**

**<https://hal.science/hal-04762020v1>**

Submitted on 31 Oct 2024

**HAL** is a multi-disciplinary open access archive for the deposit and dissemination of scientific research documents, whether they are published or not. The documents may come from teaching and research institutions in France or abroad, or from public or private research centers.

L'archive ouverte pluridisciplinaire **HAL**, est destinée au dépôt et à la diffusion de documents scientifiques de niveau recherche, publiés ou non, émanant des établissements d'enseignement et de recherche français ou étrangers, des laboratoires publics ou privés.



## Genomic diversity of HPV6 and HPV11 in recurrent respiratory papillomatosis: Association with malignant transformation in the lungs and clinical outcomes

Massilva Rahmoun<sup>a,1</sup>, Audrey Aussel<sup>b,1</sup>, Sarah Bouzidi<sup>a</sup>, Vincent Pedergrana<sup>a</sup>, Victor Malassigné<sup>c</sup>, Julien Puech<sup>d</sup>, David Veyer<sup>c,d</sup>, Hélène Péré<sup>c,d</sup>, Charles Lepine<sup>e,f</sup>, Fabian Blanc<sup>g</sup>, Nathalie Boulle<sup>h</sup>, Valérie Costes-Martineau<sup>b</sup>, Ignacio G. Bravo<sup>a,\*</sup>

<sup>a</sup> Laboratory MIVEGEC (Univ Montpellier, CNRS, IRD), French National Center for Scientific Research (CNRS), Montpellier, France

<sup>b</sup> Service D'anatomie et Cytologie pathologiques, CHU de Montpellier, Montpellier, France

<sup>c</sup> Unité de Génomique Fonctionnelle des Tumeurs Solides, Centre de Recherche des Cordeliers, INSERM, Université Paris, Paris, France

<sup>d</sup> Laboratoire de Virologie, Service de Microbiologie, hôpital européen Georges Pompidou, Assistance Publique-Hôpitaux de Paris, Paris, France

<sup>e</sup> Nantes University, CHU de Nantes, Pathology Department, Nantes, France

<sup>f</sup> INSERM, CNRS, Immunology and New Concepts in ImmunoTherapy, INCIT, UMR 1302/EMR6001, Nantes, France

<sup>g</sup> Department of Head and Neck Surgery, CHU de Montpellier, Montpellier, France

<sup>h</sup> Pathogenesis and Control of Chronic and Emerging Infections, Department of Pathology and Oncobiology, Laboratory of Solid Tumors, CHU Montpellier, University of Montpellier, INSERM, EFS, Montpellier, France

### ARTICLE INFO

#### Keywords:

Human papillomavirus  
Recurrent respiratory papillomatosis  
Squamous cell carcinoma  
HPV6  
HPV11  
Variant  
Lineage  
NLRP1  
Viral diversity  
Within-patient diversity  
Malignant transformation

### ABSTRACT

Recurrent respiratory papillomatosis (RRP) is a rare, proliferative disease caused by human papillomavirus 6 (HPV6) and HPV11. RRP can occasionally spread and undergo malignant transformation.

We analysed samples across time for five RRP patients with malignant transformation and four with highly recurrent, non-malignant RRP by applying high-throughput sequencing.

Patients with malignant transformation were infected by HPV11 A1/A2, while most non-malignant cases were associated with HPV6. Transient multiple infections with HPV6 and HPV11 were found in two patients, and resolved later to single infections. Viral genome loads were homogeneous across groups (median = 78 viral genomes per human genome). Within-patient, we did not observe differences between the viral sequences in the papillomatous lesions and in the malignant tissue. Genetic analysis of the *NLRP1* gene revealed no known mutations linked to idiopathic RRP, though some novel variants merit to be explored in larger cohorts.

HPV11 infections appear associated with RRP malignant transformation in young patients. Multiple infections can occur in RRP, but within-patient viral diversity is minimal for a given genotype. Our results confirm the importance of viral genotype in disease prognosis and are consistent with growing evidence of HPV11 infections to be differentially associated with RRP malignant transformation in young patients.

### 1. Introduction

Recurrent respiratory papillomatosis (RRP) is a rare, proliferative, chronic and benign infectious disease affecting the upper airways. The disease presents a bimodal age distribution: a juvenile onset form with an incidence of 4.3/100,000 in children and an adult onset form with an incidence between 1.8 and 2.3/100,000 in adults [1]. Clinically, RRP is characterized by recurrent exophytic papillomas in the upper airways,

most frequently in the larynx, on the vocal cords. Symptoms include hoarseness, chronic cough, dyspnea, recurrent upper airway infections, pneumonia, dysphagia, stridor and even respiratory failure [2].

The course of RRP is unpredictable, ranging from spontaneous remission to frequent recurrence, and death in rare cases. Complications, such as airway obstruction, infections or spread throughout the respiratory tract, contribute to the disease virulence [2]. Lung dissemination is a rare complication, occurring in 3.3 % of RRP cases, although

\* Corresponding author.

E-mail address: [ignacio.bravo@cnrs.fr](mailto:ignacio.bravo@cnrs.fr) (I.G. Bravo).

<sup>1</sup> Equal author contributors.

higher incidence rates of up to 7 % have been reported [3]. Among these, 16 % may show a malignant progression, specifically towards pulmonary squamous cell carcinoma (SCC) [4]. Many hypotheses have been proposed to account for the development of lung lesions in juvenile RRP, including continuous papilloma proliferation, widespread viral infection, multicentric papilloma genesis, and aerial fragment dispersion during tracheotomy or endoscopic resection [5,6]. While smoking and irradiation have been considered risk factors for malignant transformation, their roles have not been ultimately proven [7,8].

The etiology of RRP is infectious: the closely related Human Papillomaviruses 6 (HPV6) and HPV11 are the major causative agents, with additional rare contribution of other genotypes, chiefly HPV16, HPV18, HPV31, HPV33 or HPV39 [9]. The infection route for the juvenile form of RRP is usually from mother to child during birth [10,11]. For the adult form no specific infection route has been identified, and an increased risk is associated to a high number of sexual partners [12,13]. Viral etiology of RRP offers a possibility of primary prevention via vaccination, and indeed the incidence of the juvenile form of RRP has been drastically diminished in the USA after the introduction of the anti-HPV prophylactic vaccine that targets among others HPV6 and HPV11 [14].

The standard treatment for RRP involves surgical excision by suspension microlaryngoscopy under general anesthesia, primarily to ensure airway patency and maintain acceptable vocal quality. Advancement of surgical techniques and adjuvant therapies, such as Cidofovir or Bevacizumab, results in extended time intervals between surgeries [15,16]. Tracheostomy can be indicated in some severe cases and is most frequently used when surgery is not feasible [17]. In addition, administration with therapeutic purposes of the prophylactic vaccine targeting HPV6 and HPV11 has proven effective both as a preventive treatment to reduce the incidence of the disease [16], and as an adjuvant treatment to space out surgical procedures [18].

Papillomavirus taxonomy is based on genetic distances, with lineages called “variants”, identified by nucleotide identity levels above 98 % [19,20]. Extant genetic diversity has been described for HPV6 [21] and for HPV11 [22], leading to the description of variants A and B1 to B5 for HPV6 [23], and variants A1 to A4 and B for HPV11 [24]. Insertions and duplications in the regulatory sequences of HPV6 and HPV11, as well as polymorphisms in the *e6*, *e1*, *e2*, or *L1* Open Reading Frames (ORFs) have been reported, some of them linked to differential clinical presentation [25–27] or potential for malignant progression [28–31]. In the case of RRP, the differential pathogenicity of viral variants has not been thoroughly documented [32,33], as clinical features are rarely reported in conjunction with sequence data, and *vice versa*.

A syndromic form of RRP has been recently reported in children, associated with gain-of-function polymorphisms in the *NLRP1* (nucleotide-binding oligomerisation domain-like receptor containing a PYRIN domain 1) locus [34] resulting in an exaggerated activation of the *NLRP1* inflammasome in respiratory epithelial keratinocytes [35]. Other functional deficiencies related to *NLRP1* polymorphisms have also been identified in benign to cancerous hyperproliferative skin lesions [36–38].

The malignant transformation of RRP towards invasive carcinoma is rare and intriguing, especially given the low potential for malignisation of HPV6 and HPV11 infections in other anatomical regions [39,40]. In this study, we sought to sequence, characterize and compare the viral genomes recovered from nine severe RRP cases, including five with malignant lung proliferation, and to screen for polymorphisms in the human *NLRP1* locus. Identifying a differential association between viral lineages, *NLRP1* polymorphisms and disease progression may eventually lead to improved prognostic biomarkers and better management of individual RRP cases.

## 2. Materials and methods

### 2.1. Patient selection

For this retrospective cohort study, we searched the database of the Montpellier (France) hospital registry data (DIAMIC software) between 2000 and 2020, for patients' entries associated with the following terms: “HPV”, “papilloma” or “papillomatosis”, in the larynx, trachea, bronchus or lung, recorded. This search retrieved 217 files, corresponding to 147 patients. After reviewing each clinical file, we excluded patients who had no diagnosis of RRP, had only a single sample, had a non-severe form, or whose disease had remitted. Disease severity estimation is not consensual in the literature and uses composite scores incorporating disease localization criteria, such as the Derkay-Wiatrack score [41], as well as surgery-related criteria, such as the number of endoscopies under general anesthesia per year [42]. To overcome this limitation, we employed severity criteria based on the existence of distal spread or malignant transformation, the number of laryngeal procedures per year (more than four), the requirement for tracheostomy, or the occurrence of death. Eight patients met the inclusion criteria of severe, unresolved RRP and multiple excisions between 2000 and 2020. Four of these patients were diagnosed with a malignant transformation (hereafter named T1 to T4), while the other four patients presented an aggressive form of RRP without malignisation (named R1 to R4). None of these patients was diagnosed with any form of immunodeficiency during the follow-up. A ninth patient meeting these criteria was additionally referred to us by the Assistance Publique – Hôpitaux de Paris and included in the series (named T5). Eight patients presented a juvenile onset of the RRP (average age at diagnostic, 22 months) while patient T2 presented adult onset of the RRP (age at diagnostic, 50 years) It is of note that patient T2 had been diagnosed as infected with HIV at the age of 24 (Table 1).

### 2.2. Clinical samples

From the nine selected patients, we could retrieve 76 routine histopathological formalin-fixed paraffin embedded (FFPE) blocks containing papilloma or malignant tissue and archived with their haematoxylin and eosin (H&E) stained slides. After morphological review by two pathologists, 28 representative blocks were selected based on the quality and the number of pathological cells. For samples of small size, 10 to 15 sections of 8 µm thickness were cut from the FFPE block, and control H&E slides were prepared before and after the sections using the sandwich method [43]. For larger samples, a 1 mm diameter core-biopsy was taken. Staining was performed automatically using a Dako CoverStainer.

### 2.3. DNA isolation and clinical HPV genotyping

DNA was extracted from FFPE tissue sections and biopsies using the Maxwell® RSC DNA FFPE kit (Promega, France). The DNA was quantified using Qubit-HS assay kit, and diluted to a final concentration of 5–10 ng/µL. HPV genotyping was done in duplicate using 10 µL of DNA and the INNO-LiPA HPV Genotyping Extra II assay (Fujirebio, Les Ulis, France). This test, based on reverse hybridization after a polymerase chain reaction (PCR) step, allows type-specific detection of 32 viral genotypes within the *Alphapapillomavirus* genus, including oncogenic HPVs (HPV16, 18, 31, 33, 35, 39, 45, 51, 52, 56, 58, 59), possibly oncogenic (HPV68), probably oncogenic HPVs (HPV26, 53, 66, 67, 70, 73, 82), and non-oncogenic/unclassified HPVs (HPV6, 11, 40, 42, 43, 44, 54, 61, 62, 81, 83, 89) [44].

For the time points missing HPV genotyping, we performed specific PCRs targeting HPV6 and HPV11, at the Upstream Regulatory Region (URR) or at the *e2-L2* intergenic region, as described [32]. PCR reaction conditions as well as primer sequences used for amplification are listed in Supplementary material.

**Table 1**

Demographic and clinical characteristics of patients with severe recurrent respiratory papillomatosis.

Patient	Gender <sup>a</sup>	Clinical HPV genotype	Year of birth	Age at diagnostic <sup>b</sup>	Age at distal dissemination	Age at SCC onset	Outcome <sup>c</sup>	Tracheotomy	Maximum number of endoscopies in one year
T1	F	HPV11	1987	4 mo	15 y	31 y	C	no	6
T2 <sup>d</sup>	M	HPV11	1963	50 y	54 y	54 y	C	no	3
T3	F	HPV11	1994	14 mo	16 y	19 y	D	no	10
T4	F	HPV11	1992	2 y	12 y	15 y	D	yes	3
T5	F	HPV11	NA	17 mo	NA	18 y	D	yes	8
R1	M	HPV11	2004	NA	NC	NC	D	yes	6.6
R2	F	HPV6	2011	5 y	NC	NC	L	yes	7
R3	M	HPV6	2018	10 mo	NC	NC	C	no	6.5
R4	M	HPV6	2013	4 y	NC	NC	L	no	4.7

NA, not available.

NC, not concerned.

SCC, squamous cell carcinoma.

<sup>a</sup> F, female; M, male.<sup>b</sup> Mo, month; y, year.<sup>c</sup> Outcome at end of study: C, continuing to be treated; D, died; L, lost to follow-up.<sup>d</sup> HIV positive at age 24.

#### 2.4. Viral whole genome HTS and capture-targeted HTS; reconstruction and annotation

Total DNA from all samples (n = 28) was extracted using the Quick-DNA FFPE Miniprep kit (Zymo Research) and quantified using a Qubit dsDNA HS Assay Kit (Thermo Fisher Scientific). Whole genome high-throughput sequencing (HTS) was performed using 2 × 150 nt paired-end sequencing on an Illumina NovaSeq 6000 machine using NovaSeq reagent kits, at the MGX facility (Montpellier, France). For samples not yielding results in the whole DNA HTS (n = 9, corresponding to three patients), total DNA was additionally submitted to a capture-HPV method followed by HTS using over 22,000 probes, with an average length of 75 nucleotides, covering all HPV genotypes identified by the International Papillomavirus Reference Center, as described [45], using the KAPA Hypercapture and HyperExplore MAX reagents. Libraries were built using KAPA EvoPlus and dual-indexing reagents and sequenced on an Illumina MiSeq system (150 bp paired-end reads). For quality and normalization purposes, the targeted HTS contains additional probes to capture also the human genes kallikrein-related peptidase 3 (*KLK3*, 12,850 bp, chromosome19), glyceraldehyde-3-phosphate dehydrogenase (*GAPDH*, 10,880 bp, chromosome 12), and member 7 A of the RAS oncogene family (*RAB7A*, 9800 bp, chromosome 3).

Raw reads were clipped and quality-trimmed using *Trimmomatic v0.38* [46] with the options *ILLUMINACLIP:/usr/local/Trimmomatic-0.38/adapters/TruSeq3-PE.fa:2:30:10:2:keepBothReads LEADING:3 TRAILING:3 SLIDINGWINDOW:4:15 MINLEN:40*. Except for viral capture reads, a filter-out step was performed by aligning viable reads against the Bowtie2 index of human genome GRCh38 no alternate contigs analysis with *Bowtie2 v2.3.4.1* [47], specifying that unmatched reads should be retained.

Non-human reads were aligned against an in-house database of GenBank entries composed of 763 human and animal papillomavirus (PV) complete genomes, referenced in PaVE (pave.niaid.nih.gov), using *breseq v0.38.1* [48]. HPV6 and HPV11 alignments with a complete coverage were recovered with *SAMtools view v1.10*. Viral reads from these alignments were collected using *SAMtools fastq v1.10* and read coverage distribution as well as a variant calling were performed against the HPV6 FR751328 or the HPV11 M14119 GenBank reference genomes with *breseq v0.38.1*. Polymorphic sites showing a frequency above 0.5, including indels, were subsequently incorporated into the reference used with *gtools APPLY from breseq v0.38.1* to obtain a consensus viral genome sequence. All retrieved whole HPV genome sequences were deposited in the GenBank database under the accession numbers PP715864-PP715886, as well as biosamples SAMN41013900-SAMN41013925, within the bioproject PRJNA1102161 (Table S1).

#### 2.5. Taxonomic placement of HPV6 and HPV11 recovered genomes

Full-length annotated HPV6 and HPV11 genomes were recovered from the GenBank, rotated to start at the ATG start codon of the *e6* ORF, using *Blastn v2.12.0+* [49] and GenBank entries X00203 and M14119 as reference genomes to locate *e6* ORFs for HPV6 and HPV11 respectively, then aligned using *MAFFT v7.505* [50]. Phylogenetic inference was performed on this full-genome alignment using *RAxML-ng v1.10* [51] under the GTR + G + I evolutionary model. Variant lineages were defined and named according to the literature for HPV6 [23] and for HPV11 [24]. Novel consensus genome sequences were aligned and placed on the previously computed phylogeny using the evolutionary placement algorithm in *RAxML v8.2.12* [52]. We created a correspondence table between nodes names, and variant and subvariant lineages for each of the reference trees, and calculated for every novel consensus genome the cumulative maximum likelihood of belonging to each lineage.

For HPV11-positive samples not successful for HTS (n = 3, corresponding to three patients), variant identification was done by Sanger sequencing of both strands of *e2-l2* PCR products at Genoscreen (Lille, France), and processed for phylogenetic placement. Primer sequences used for sequencing were the same as for amplification (see Supplementary material). Because we were only able to amplify and Sanger sequence the *e2-l2* PCR product described in Ref. [32], we could assign with confidence between variants HPV11\_A and HPV11\_B, but we could not discern between HPV11\_A1 and HPV11\_A2, as the targeted amplicon is identical for the two subvariants. Notwithstanding, we could generate full genotyping from either whole genome HTS or capture HTS for all patients for at least one time point.

We calculated viral genome loads by normalizing viral reads per viral genome length over human reads per human genome length (3.1 Gbp for the full-length human genome, in whole genome HTS) or human genes length (33,530 bp for the human genes in the capture HTS) (Table S1). We estimated viral genome loads as a joint function of the HPV genotype (HPV6 or HPV11) and of the patient type (T or R), controlling for each individual patient as a random factor, by means of a standard least squares restricted Maximum Likelihood method, using *JMP v14.3.0*.

#### 2.6. Identification of intra-patient polymorphisms in HPV genomes

For patients with several samples (n = 6), viral reads were re-aligned and a variant calling was performed against the newly created consensus corresponding to the earliest sample using *breseq v0.38.1*. Polymorphic positions were compared across samples for each patient using *gtools COMPARE* from *breseq v0.38.1*. Values for within-host nucleotide diversity were estimated following [53].

## 2.7. Detection of polymorphisms in the human gene *NLRP1*

Human alignments from the filter-out step were sorted and indexed with *SAMtools sort* and *SAMtools index v1.10* [54] in order to explore polymorphisms in the human gene *NLRP1*, a potential candidate gene for RRP susceptibility [55]. Alignments of the human reads against the *NLRP1* locus were recovered from positions 5,501,396–5,584,509 on chromosome 17 (reference CM000679) with *SAMtools view v1.10*, and merged and indexed by patient using *SAMtools merge* and *SAMtools index v1.10*. Variant calling was performed using *FreeBayes v1.0.2* [56] against the index chromosome 17, made with *SAMtools faidx v1.10*, using *BCFtools query v1.10.2*, and results transposed into a table format. Polymorphisms previously identified in the *NLRP1* gene in the OMIM database (<https://www.omim.org/allelicVariants/606636>) potentially related to RRP, and specifically the G > T mutation reported in an idiopathic form of RRP [34] were targeted and confirmed by

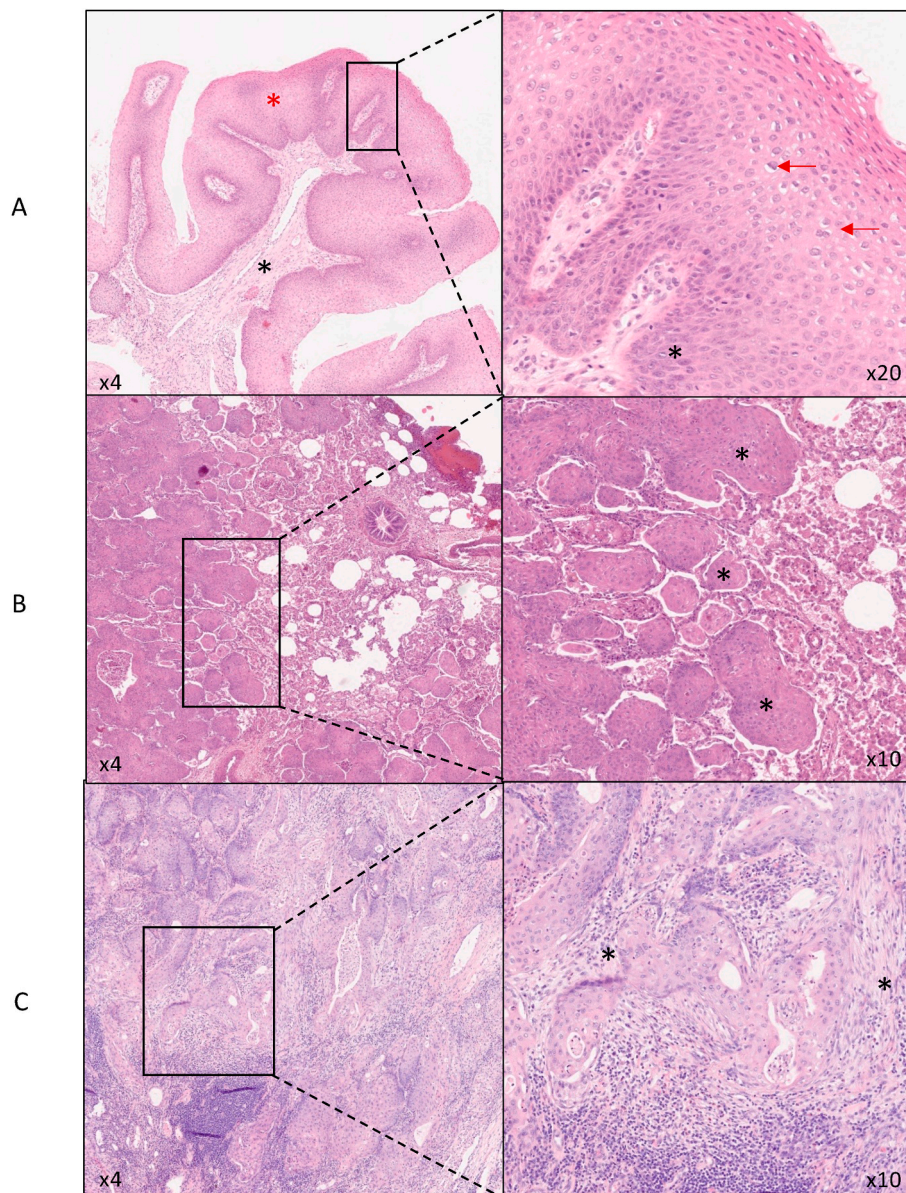
exon-specific Sanger sequencing (Genoscreen). The targeted positions and the associated human variation data are provided in Table S2. PCR reaction conditions as well as primer sequences used for amplification and sequencing are listed in Supplementary material. Comparison of the chromatogram with the reference sequence was performed using U-gene [57].

A flowchart overview of all bioinformatic analyses is provided in Fig. S1.

## 3. Results

### 3.1. Clinical characteristics of the patients

Our study involved nine patients with a highly aggressive presentation of RRP: five patients presenting a malignant transformation after a juvenile onset of the RRP (named T1, T3, T4, T5); one patient presenting



**Fig. 1.** Histology of RRP from laryngeal papilloma to squamous cell carcinoma in patient T1 (A) Laryngeal papilloma of T1 in 2008 (sample T1\_B). Left: conjunctivo-vascular axis (\*) lined by hyperplastic squamous epithelium (\*). Right: Higher magnification of the squamous epithelium: koilocytes (β) and basal cell hyperplasia with mitosis (\*). (B) Lung papilloma of T1 in 2011 (sample T1\_C). Left and higher magnification at right: Squamous papillomatous proliferation (\*) extension inside alveolar spaces. (C) Lung squamous cell carcinoma of T1 in 2018 (sample T1\_D). Left and higher magnification at right: lung parenchyma destruction by squamous cell carcinoma, presence of fibrous stroma (\*).

a malignant transformation after an adult onset of the RRP (named T2); and four patients with juvenile onset of the RRP, but without signs of malignant transformation during follow-up (named R1 to R4). Five of the patients were females and four were males. For juvenile RRP patients presenting transformation, the median age at RRP diagnosis was 15.5 months (range 4–24 months), and the median age at diagnosis of distal carcinogenic transformation was 18.5 years (range 15–31 years). For juvenile RRP patients without transformation, median age at diagnosis was 48 months (range 10–60 months). Of note, the patient with adult onset of the RRP patient had become HIV-positive at the age of 24, this is 26 years before being diagnosed of RRP and 4 years before being diagnosed with distal transformation. HPV DNA was found in all patients, either at the time of diagnosis or during hospital follow-up, with HPV11 in patients T1-T5 and R1, and HPV6 in patients R2-R4. Table 1 summarises the patients characteristics.

### 3.2. Histological analysis

Routine histopathological FFPE blocks containing papilloma or lung squamous cell carcinoma tissue were collected for all participants. Fig. 1 illustrates the progression from benign laryngeal papilloma to malignant lung squamous cell carcinoma in patient T1. Initially, a 2008 sample (T1\_B) showed a typical laryngeal papilloma made of a fibro-vascular

connective axis and lined by hyperplastic squamous epithelium (Fig. 1A). Parabasal keratinocytes located in the lower part of the epithelium proliferated, as evidenced by the thickening of the basal layers and the presence of mitoses. Some superficial cells, known as koilocytes, showed morphological changes indicative of papillomavirus infection, characterized by a peri-nuclear halo, binucleations and irregular, enlarged nuclei. Dyskeratotic cells may be present, but no high-grade dysplasia nor infiltration were observed. Three years later, a sample (T1\_C) presented the colonization of pulmonary alveoli by pulmonary benign papilloma (Fig. 1B): alveolar spaces were colonized by a squamous, benign proliferation. Conjunctive-vascular axis and koilocytes were not always visible, unlike in the laryngeal localization. Finally, seven years later (sample T1\_D), a malignant transformation was detected in the lung (Fig. 1C). This transformation displayed an infiltrative architecture, a fibrous stroma reaction and polygonal cells with abundant eosinophil cytoplasm, as well as foci of keratinization, necrosis and nuclear atypia.

### 3.3. Viral DNA detection, genotyping and variant distribution

We analysed 28 samples (2–5 samples per patient) from various anatomical sites, including the larynx (n = 15), lung (n = 6), bronchus (n = 2) and trachea (n = 1) (Table 2). The sampling time range was 1–11

**Table 2**  
Characteristics of processed samples and HPV variant distribution

Within a given patient, samples are named in chronological order, with the letter A representing the initial sample  
Clinical HPV genotype determined using the Innolipa ExtraII HPV Test.

Patient	Sample name	Sampling year (patient's age)	Clinical diagnosis (anatomical location)	Clinical HPV genotype	HPV genotype (specific PCR)	HPV variant	Viral genome load (viral genome copies per cell genome copies)
T1	T1-A	2007 (20)	P (larynx)	HPV11	–	HPV11_A2H <sup>a</sup>	292
T1	T1-B	2008	P (larynx)		–		
T1	T1-C	2011	P (lung)				
T1	T1-D	2018	P (bronchus)		HPV11	HPV11_A2 <sup>c</sup>	7
T1	T1-E	2018	SCC (lung)		HPV11	HPV11_A2 <sup>c</sup>	15
T2	T2-A	2014 (51)	P (larynx)	HPV11	HPV11	HPV11_A <sup>b</sup>	
T2	T2-B	2016	P (larynx)		HPV11	HPV11_A2 <sup>c</sup>	51
T2	T2-C	2018	SCC (lung)		HPV11	HPV11_A2 <sup>c</sup>	16
T3	T3-A	2011 (17)	P (larynx)	HPV11	HPV11	HPV11_Ab <sup>b</sup>	
T3	T3-B	2014	P (lung)		–		
T3	T3-C	2014	SCC (lung)		–		
T3	T3-D	2014	SCC (lung)		–	HPV11_A1 <sup>a</sup>	11
T3	T3-E	2015	P (larynx)		–	HPV11_A1 <sup>a</sup>	336
T4	T4-A	2005 (13)	P (trachea)	HPV11	–	HPV11_A2 <sup>c</sup>	37
T4	T4-B	2007	SCC (bronchus)		–		
T5	T5-A	2012 (NA)	P (NA)	HPV11	HPV6	HPV6_A <sup>c</sup> and HPV11_A1 <sup>a</sup> /HPV6_A <sup>a</sup>	53 and 45/62
T5	T5-B	2012	SCC (NA)		HPV11	HPV11_A1 <sup>c</sup>	48
T5	T5-C	2012	SCC (NA)		–	HPV11_A1 <sup>a</sup>	27
R1	R1-A	2008 (4)	P (larynx)	HPV11	–		
R1	R1-B	2009	P (larynx)		–	HPV11_A1 <sup>a</sup>	30
R1	R1-C	2010	P (larynx)		–	HPV11_A1 <sup>a</sup>	25
R1	R1-D	2010	P (NA)		HPV11	HPV11_A <sup>b</sup>	
R2	R2-A	2018 (7)	P (larynx)	HPV6	HPV6	HPV6_B5 <sup>c</sup>	271
R2	R2-B	2019	P (larynx)		HPV6	HPV6_B5 <sup>c</sup>	98
R3	R3-A	2020 (2)	P (larynx)	HPV6	HPV6	HPV6_A <sup>c</sup>	33
R3	R3-B	2021	P (larynx)		HPV6	HPV6_A <sup>c</sup>	20
R4	R4-A	2018 (5)	P (larynx)	HPV6	HPV11	HPV11_A1 <sup>c</sup> and HPV6_A <sup>c</sup>	30 and 152
R4	R4-B	2018	P (larynx)		HPV6	HPV6_A <sup>c</sup> HPV6_A <sup>a</sup>	41/89

HTS, High Throughput Sequencing.

NA, not available.

P, papilloma.

SCC, squamous cell carcinoma.

<sup>a</sup> After viral capture followed by HTS.

<sup>b</sup> After Sanger sequencing of a fragment within the e2-I2 genomic region, no precision for identifying subvariant lineages.

<sup>c</sup> After whole genome HTS.

years for the juvenile RRP patients ( $n = 8$ ), and 4 years for the adult patient. Initial HPV clinical genotyping identified HPV11 in all T1-T5 patients as well as in patient R1, and HPV6 in R2-R4 patients (Table 2). We combined an agnostic, whole-genome HTS and a capture-targeted HTS approach to generate full-length viral genomes from 19 samples, and further identified the viral genotype using Sanger sequencing in three additional samples. Whole-genome HTS yielded a median of 22,754 viral reads per sample, corresponding to a median of 0.040 % of all reads generated per sample, while capture-targeted HTS yielded a median of 542,815 viral reads per sample, corresponding to a median of 95.97 % of all reads generated per sample (Table S1). Viral HTS sequencing allowed for full-length reconstruction of viral genomes with high sequence depth (median average coverage 418 for whole-genome HTS and 6248 for capture HTS; Table S1). Our HTS results confirmed the initial clinical genotyping (Table 2). For HPV6 at the variant level, HPV6\_A was detected in samples from one patient displaying transformation and in two patients with highly recurrent RRP, while HPV6\_B5 was detected in one patient with highly recurrent RRP. For HPV11 at the variant level, HPV11\_A2 was identified in samples from three out of five patients with transformation, while HPV11\_A1 was detected in two patients displaying transformation and in two patients with highly recurrent RRP.

Strikingly, HTS revealed the presence of two HPV multiple infections in two patients: i) in patient T5, HPV6\_A and HPV11\_A1 were detected in an early non-transformed papilloma sample (T5\_A), while only HPV11\_A1 was detected in later specimens from transformed tissue (T5\_B and T5\_C); ii) in patient R4, HPV6\_A and HPV11\_A1 were detected in an early papilloma sample (R4\_A), while only HPV6\_A was detected in a laryngeal papilloma a few months later (R4\_B) (Table 2).

We estimated viral genome loads for each HPV present, after normalizing by the human genome levels in the corresponding sample. The results displayed large variation, both within patient and between patient (Table 2 and Table S1). Of note, disease progression in patient T1 was accompanied by a 26-times reduction in viral genome load over ten years follow-up, while in patient T3 one sample taken from a laryngeal papilloma displayed viral genome levels 30-times higher than one sample taken the same year from the squamous cell carcinoma in the lung (Table 2 and Table S1). Overall, variations in viral genome loads were not explained by the combination of clinical presentation and viral genotype ( $R^2 = 0.00$ ;  $p = 0.9979$ ), so that viral loads were not different between patients showing transformation or simple recurrency (respectively estimated values 76.1 and 79.3;  $p = 0.9492$ ), nor between HPV6-positive and HPV11-positive samples (respectively estimated values 76.5 and 78.8;  $p = 0.9643$ ), after correcting for each individual as a random factor.

### 3.4. Analysis of intra-patient viral diversity

We explored the within-patient viral genotypic diversity, taking advantage of the high coverage values for all newly assembled genomes. For each patient we chose the sample with the highest overall coverage to be used as a reference to construct a consensus viral genome. We then mapped all reads recovered from each sample against this consensus genome to identify polymorphisms present with a frequency above 5 %, and reported the genomic location and the possible coding effects of each polymorphism. Results are displayed in Table S3. For patients T2, T4, T5 and R2 we did not observe within-patient viral polymorphisms above our threshold in any sample. For samples from patients T1, T3, R1, R3 and R4, nucleotide diversity remained very low (median value  $2.27 \times 10^{-5}$ , range  $0-6.98 \times 10^{-4}$ ). We found ten samples from these five patients displaying a total of 84 polymorphic sites, with a median frequency of the alternative, minor allele at 6.4 % (95 % CI: 5.1%–29.9 %). We identified a possible selection event in the HPV6\_A genome, with eight polymorphic positions in the *URR* around 30 % frequency of the minor allele in sample R4\_A that became fixed in sample R4\_B. Additionally, we detected a possible selection event in position 5580 of the

HPV11\_A1, genome in patient T3, with the appearance of a C > T mutation absent in sample T3\_D and displaying around 80 % frequency in T3\_E, corresponding to a synonymous change within *L2*.

### 3.5. Analysis of genetic diversity in the human *NLRP1* gene

We explored the polymorphisms in the *NLRP1* locus, a potential candidate gene for RRP susceptibility, targeting the positions reported in the OMIM database as being possibly related to clinical epithelial proliferative phenotypes (<https://www.omim.org/allelicVariants/606636>). We mapped the HTS reads in the selected positions and verified the findings using Sanger sequencing. Results are listed in Table S2. In position Chr.17:5,558,432 a G > T mutation had been reported in this position for an idiopathic, non-infectious form of RRP [34], but all nine patients studied here present the ancestral G allele. Similarly, all nine patients present the ancestral allele in positions Chr.17:5,583,728; 5,583,761 and 5,583,798, for which mutations had been reported to be possibly related to a corneal intraepithelial dyskeratosis-palmoplantar hyperkeratosis-laryngeal dyskeratosis syndrome. We extended our examination to two candidate genomic loci in the *NLRP1* gene: Chr.17:5,583,612–5584,019 (in *NLRP1* exon 1) and Chr.17:5,558,296–5558,493 (in *NLRP1* exon 4), using HTS and/or Sanger sequencing. Two patients (T5 and R4) were heterozygous G|C for position Chr.17:5,558,351. No clinical phenotype has been associated to this polymorphism. The reported reference allele for this position is G, and the overall prevalence in humans of the C variant allele is around 5.4 %. Additionally, two patients (T1 and T4) were homozygous G and one patient (T5) was heterozygous C|G for position Chr.17:5,583,844. The reported reference allele for this position is C and the overall prevalence in humans of the G variant allele is around 14.6 %. This mutation is reported to be possibly associated to three clinical presentations: i) corneal intraepithelial dyskeratosis-palmoplantar hyperkeratosis-laryngeal dyskeratosis syndrome; ii) autoinflammation with arthritis and dyskeratosis; and iii) the congenital, juvenile, idiopathic, non-infectious form of RRP referred above.

## 4. Discussion

Recurrent respiratory papillomatosis is a rare proliferative disease of viral etiology, with HPV6 and HPV11 accounting for over 90 % of cases [58]. In this study we aimed to characterize the viral genomic diversity in RRP lesions, comparing cases that had undergone malignant transformation with highly recurrent cases that have not undergone transformation, to explore a putative link between viral genomic diversity and phenotypic, clinical presentation of the infection. We checked for the presence in our samples of Illumina reads compatible with all PVs in the PAVE repertoire (<http://pave.niaid.nih.gov>), and we did not detect reads from any PV other than HPV6 and HPV11. All patients who developed malignancy were infected by HPV11, in contrast with patients without malignant transformation who were HPV6 positive, except one who displayed non-malignant tracheal lesions and succumbed to the disease. Our results are thus compatible with an association between HPV11 and malignant transformation in RRP patients. The four patients with a juvenile form of RRP that eventually resulted in malignant progression had been diagnosed for RRP between 4 and 24 months of age. Our results are in good agreement with most studies showing that a younger age at onset of RRP is an important independent predictor of disease severity [59] and with the growing consensus that HPV11 is associated with a more aggressive pathology and with a bad prognosis [40,60–62]. Even within HPV11-positive cases, the disease presents a large individual variation in progression timing for patients with juvenile onset RRP: while for patients T3 and T4 diagnosis of squamous cell carcinoma occurred only three years after distal dissemination, in patient T1 malignisation was diagnosed 15 years upon distal dissemination. In the case of T2, with an adult onset RRP, dissemination and malignisation were detected within the same year. However, while

aiming at being representative of the full lesion, it is conceivable that at the time the biopsy for dissemination was taken, lung and tracheal malignant involvement were already in place elsewhere, but that no malignant tissue was sampled.

Several attempts have been made to explain the aetiopathogenesis of the malignant progression in RRP in the absence of obvious carcinogenic factors, such as smoking and irradiation, as was indeed the case of almost all the young patients in the present study. Our result suggest a stronger association between HPV11 infections and potential for RRP malignisation, consistent with the growing evidence in the literature for an increased risk for malignant progression towards invasive carcinoma in juvenile RRP cases [25,28,62–65], as well as in adult RRP forms that progressed towards an invasive carcinoma [66]. Because of these differences in the natural history of the infection, viral genotyping has indeed been proposed as a biomarker for disease severity and progression [62]. Albeit with a lower prevalence in lung involvement than HPV11 [40], HPV6 has been identified in adult RRP cases with extensive anatomical spread [67], in malignant progression of laryngeal papilloma [68,69], as well as in juvenile RRP cases with spontaneous malignant transformation [70–72].

The eight patients in the study with juvenile form of RRP were immunocompetent, while patient T2 was HIV-positive since the age of 24, developed an adult form of RRP at the age of 50, and was diagnosed with a distal RRP malignisation at the age of 54. Individual case reports for HIV-positive patients developing severe RRP have been communicated [73]. However, no differences in the probability of developing a malignant progression of RRP have been described between immunocompetent and immunosuppressed patients [74].

The molecular mechanisms underlying malignant progression in RRP remain elusive. From the point of view of the host, certain descriptions have proposed a p53 defect leading to uncontrolled cell proliferation [70], but a p53 overexpression has also been communicated in HPV11-positive papillomas and carcinomas [75]. A particular, syndromic form of RRP has been described, not associated to viral infection and linked instead to a particular SNP in the *NLRP1* locus [34]. We have analysed this locus in the genomes of all patients in the cohort, and none of them presented the SNP reported to be causative of the syndromic form of RRP. We have analysed additionally polymorphisms in the *NLRP1* locus that had been described to be associated to different conditions, from benign to malignant, all of them related to epithelial proliferations [36–38]. The only potential host genetic finding that may merit further research maps in Chr.17:5,583,844, for which three out of four patients displaying transformation for the juvenile form of RRP presented either homozygous G or heterozygous C|G, compared to the ancestral C variant. This SNP has been associated to different dyskeratotic syndromes. However, given the very small sample size in our cohort and the 14.5 % basal prevalence of the G allele in humans, we cannot conclude of any possible association with increased risk of malignisation for this allele and can only call for further analyses in larger cohorts of juvenile onset of the RRP.

From the point of view of viral carcinogenicity, infections by both HPV6 and HPV11 have been associated to anogenital cancer cases, albeit rarely [76], and large duplications in the upstream regulatory region of both HPV6 and HPV11 have been reported in RRP malignant transformations [28,29,77]. In our study, we did not detect any duplication events nor large indels in the regulatory region or elsewhere in the viral genomes, as the read depth analysis showed no stepwise variation in sequencing coverage. Finally, integration events have been communicated for HPV6 and HPV11 in the host genome over the course of RRP, but again, the individual presentation varies largely depending on the virus involved and in disease progression. Thus, while HPV6 has been found in episomal state in 25 RRP patients [78], it has been detected in episomal state in the papilloma and in integrated form in the carcinoma in the same patient [79] and in both episomal and integrated states in a tonsillar carcinoma [80]. Regarding HPV11, it has been detected in the integrated form in three of seven patients suffering from RRP with

malignant lung involvement [81], but it remained in episomal presentation in one patient after a history of aggressive juvenile RRP with a malignant outcome [82]. In our study population, we did not retrieve viral-human chimeric reads that could be consistent with an integration event in any of the viral genomes analysed by whole genome HTS or by targeted capture HTS. Our results confirm thus the literature reports and suggest that malignisation can be associated to the presence of episomal forms or to the coexistence of integrated and episomal forms of HPV6 or HPV11 genomes.

At the variant level, HPV11\_A1 and HPV11\_A2 predominated in patients with malignant transformation. Our results are consistent with the highest prevalence of these variants within the overall HPV11 diversity [24], as well as with more recently reported data showing that HPV11\_A2 variant was most prevalent (62.5 %) in a cohort of 79 RRP patients [33]. In RRP patients without carcinoma, we observed a predominance of HPV6\_A over HPV6\_B5 although our sample size is too small to draw any conclusion. Our findings diverge from reports describing high prevalence of HPV-6vc (corresponding to HPV6\_B1) in juvenile RRP lesions [83,84]. However, the largest global HPV6 genomic diversity study to date suggests that HPV6 lineages may display variations in prevalence depending on the genetic background of the host and geography, as well as on the clinical presentation of the infection [23].

In cervical infections, high HPV16 viral genome loads are related to an increase in disease progression towards high-grade lesions [85]. We explored viral genome loads in our study population and we did not find any significant differences between lesions caused by HPV6 and HPV11, nor between patients showing or not lung transformation (Table 2). Other studies have also reported no significant differences between HPV6 and HPV11 viral load [86]. Overall, the median estimated viral load in our samples was 78 viral genome copies per human cell genome copies, consistent with the value of 41 HPV6 genome copies per cell reported for RRP-associated papillomas [78]. Notwithstanding, we observe large variations both between patient and within patient, with lowest and highest viral genome loads reaching respectively 7 and 336 viral genome copies per human cell genome copies. Such large variations in observed viral genome load have also been reported in other studies analysing RRP lesions, with ranges reported between 5.4 and 3057 [78], between 0.07 and 126 [87], or between 0.4 and 350 [88] viral genomes per cell. Further, viral genome load in RRP lesions is not a prognostic factor for response to interferon alpha treatments, and the evolution of viral genome load has been reported to be highly heterogeneous among patients after interferon alpha treatment [87]. Samples from two patients in our cohort display lower viral genome load values in biopsies from malignant tissue compared to near-in-time samples from papillomas. This is a potentially interesting finding, which could reflect a differential role of viral infection in papilloma and in cancer lesions. However, given the large within-patient variation, this finding is also compatible with local large variations in viral load between lesions, or between regions of a lesion, and could also reflect a sampling bias, as described above for the difficulty of identifying the onset of malignant transformation. This interpretation has also been proposed by other authors to account for large within-patient differences in viral load across time [86].

Full-length genome sequencing and high read coverage allowed us to examine HPV6 and HPV11 within-patient viral diversity. We observe that in four cases there was no within-patient diversity above our 5 % threshold per position, while in the remaining five cases the average nucleotide diversity (which can be understood as the probability that two viral genome molecules picked at random from the sample studied are not identical) was very low, around  $2.3 \times 10^{-5}$ . We identify only a quasi-fixation event of a synonymous mutation in patient T3. Accordingly, the consensus viral sequences remained stable over time, in line with previous studies [89,90], notably between the papillomatous lesions and the malignant tissue, for a given patient.

Very interestingly, we detect two cases of multiple infection by HPV11\_A1 and HPV6\_A, in one patient with malignant transformation



and one without. The co-infection was in both cases transient, as it was not detected in later samples from both patients. Notwithstanding, the high viral loads for both viral genomes (Table S1) suggest that these simultaneous detections correspond to actual multiple infections. Similar cases of multiple infection with HPV6 and HPV11 have already been documented, and several reports have described co-infections with high-risk HPVs [91–95]. Simultaneous DNA detection of two viral genomes in a sample does not imply that the same host cell is infected by the two genotypes. Indeed, individual PV lesions most likely correspond to clonal expansions from a single-cell infection event [96], and in anogenital lesions it has been demonstrated by laser-capture microdissection that multiple infections correspond to separate foci of separate infection events, that may appear in direct apposition [97].

The main limitations of our study are the small sample size and the retrospective data collection. Yet, the strength of this work resides in the reporting of HPV6 and HPV11 full-genomic sequences over time, for a rare disease with an even rarer complication of progression to malignancy.

## 5. Conclusion

Our findings support the growing consensus that infection by HPV11 is a relevant factor for prognosis in young patients with aggressive RRP. We observed no differences in viral genome load across patients, independently of the clinical course of the disease or of the viral genotype involved, and we estimated an average of 77.7 viral genome copies per human genome copy. Analysis of intra-patient viral diversity identified a very limited number of variable positions and a high stability of the viral genomes. Notably, the viral genomes in the malignant tissue were virtually identical to those found in the papillomatous lesions around the same timing. At the host level, our patients did not harbor any of the *NLRP1* gene mutations reported in the literature to be related to cellular proliferation. We communicate nevertheless one novel synonymous variant shared by three of the four patients with juvenile onset of the RRP and subsequent malignisation, which may be worth to explore in depth in larger cohorts. Future studies will need to combine viral and host genomic analyses and their interactions, as well as exposure and environmental data relationship between HPV and its host. Only such comprehensive analyses will help us go beyond our partial understanding of the factors underlying the differential RRP of progression and malignisation.

## CRedit authorship contribution statement

**Massilva Rahmoun:** Writing – original draft, Visualization, Validation, Methodology, Investigation. **Audrey Aussel:** Writing – original draft, Visualization, Validation, Methodology, Investigation. **Sarah Bouzidi:** Writing – original draft, Visualization, Software, Formal analysis. **Vincent Pedergrana:** Formal analysis. **Victor Malassigné:** Validation, Investigation. **Julien Puech:** Validation, Investigation. **David Veyer:** Validation, Investigation. **Hélène Péré:** Validation, Investigation. **Charles Lepine:** Validation, Investigation. **Fabian Blanc:** Validation, Investigation. **Nathalie Boulle:** Validation, Investigation. **Valérie Costes-Martineau:** Validation, Investigation. **Ignacio G. Bravo:** Writing – original draft, Supervision, Funding acquisition, Formal analysis, Conceptualization.

## Conflicts of interest

The authors declare that there are no conflicts of interest.

## Ethical approval

This observational retrospective study was approved by the Institutional Review Board (IRB – Project number: 202,000,601), the bioethic council and the “Comité de Protection des Personnes (CPP)”.

## Repositories

The HPV6 and HPV11 genomes herein communicated are available as GenBank entries PP715864-PP715886, and the corresponding bio-samples SAMN41013900-SAMN41013925 are deposited within the bioproject PRJNA1102161.

## Data summary

The authors confirm all supporting data, code and protocols have been provided within the article or through supplementary data files.

## Funding information

The funders played no role in the study or in the preparation of the article or in the decision to publish.

## Declaration of competing interest

The authors declare that they have no known competing financial interests or personal relationships that could have appeared to influence the work reported in this paper.

## Acknowledgements

The authors acknowledge the ISO 9001-certified IRD iTrop HPC (member of the South Green Platform) at IRD Montpellier for providing HPC resources that have contributed to the research results reported within this paper. URL: <https://bioinfo.ird.fr/> - <http://www.southgreen.fr>.

## Appendix A. Supplementary data

Supplementary data to this article can be found online at <https://doi.org/10.1016/j.tvr.2024.200294>.

## Data availability

All supporting data, code and protocols have been provided within the article or through supplementary data files.

## References

- [1] A.K. El-Naggar, J.K.C. Chan, T. Takata, J.R. Grandis, P.J. Sliotweg, WHO Classification of Head and Neck Tumours fourth ed., vols. 28–31, International Agency for Research on Cancer, Lyon, France, 2017, pp. 115–116, 93–95.
- [2] C.S. Derkay, B. Wiatrak, Recurrent respiratory papillomatosis: a review, *Laryngoscope* 118 (2008) 1236–1247.
- [3] Yang Q, Li Y, Ma L, Xiao Y, Wang H, et al. Long-term outcomes of juvenile onset recurrent respiratory papillomatosis with pulmonary involvement. *Laryngoscope*; 131. Epub ahead of print July 2021. DOI: 10.1002/lary.29376.
- [4] J.-F. Gélinas, J. Manoukian, A. Côté, Lung involvement in juvenile onset recurrent respiratory papillomatosis: a systematic review of the literature, *Int. J. Pediatr. Otorhinolaryngol.* 72 (2008) 433–452.
- [5] I.L. Soldatski, E.K. Onufrieva, A.M. Steklov, N.V. Schepin, Tracheal, bronchial, and pulmonary papillomatosis in children, *Laryngoscope* 115 (2005) 1848–1854.
- [6] T. Frauenfelder, B. Marincek, S. Wildermuth, Pulmonary spread of recurrent respiratory papillomatosis with malignant transformation: CT-findings and airflow simulation, *Eur. J. Radiol. Extra* 56 (2005) 11–16.
- [7] J.H. Blumin, E.B. Handler, C.B. Simpson, V. Osipov, A.L. Merati, Dysplasia in adults with recurrent respiratory papillomatosis: incidence and risk factors, *Ann. Otol. Rhinol. Laryngol.* 118 (2009) 481–485.
- [8] L.-A. Lee, A.-J. Cheng, T.-J. Fang, C.-G. Huang, C.-T. Liao, et al., High incidence of malignant transformation of laryngeal papilloma in Taiwan, *Laryngoscope* 118 (2008) 50–55.
- [9] I.N. Mammias, G. Sourvinos, E. Vakonaki, P. Giamarelou, C. Michael, et al., Novel human papilloma virus (HPV) genotypes in children with recurrent respiratory papillomatosis, *Eur. J. Pediatr.* 169 (2010) 1017–1021.
- [10] A. Welschmeyer, G.S. Berke, An updated review of the epidemiological factors associated with recurrent respiratory papillomatosis, *Laryngoscope Investig Otolaryngol* 6 (2021) 226–233.

- [11] H.K. Kashima, F. Shah, A. Lyles, R. Glackin, N. Muhammad, et al., A comparison of risk factors in juvenile-onset and adult-onset recurrent respiratory papillomatosis, *Laryngoscope* 102 (1992) 9–13.
- [12] R. Ruiz, S. Achlatis, A. Verma, H. Born, F. Kapadia, et al., Risk factors for adult-onset recurrent respiratory papillomatosis, *Laryngoscope* 124 (2014) 2338–2344.
- [13] M. James, D. Katundu, D. Chussi, P. Shija, Prevalence, clinical presentations, associated risk factors and recurrence of laryngeal papillomatosis among inpatients attended at a Tertiary Hospital in Northern zone Tanzania, *Pan Afr Med J* 30 (2018) 209.
- [14] E. Meites, L. Stone, R. Amiling, V. Singh, E.R. Unger, et al., Significant declines in juvenile-onset recurrent respiratory papillomatosis following human papillomavirus (HPV) vaccine introduction in the United States, *Clin. Infect. Dis.* 73 (2021) 885–890.
- [15] R.C. Hoesli, A.L. Thatcher, N.D. Hogikyan, R.A. Kupfer, Evaluation of safety of intralesional Cidofovir for adjuvant treatment of recurrent respiratory papillomatosis, *JAMA Otolaryngol Head Neck Surg* 146 (2020) 231–236.
- [16] J.J. Benedict, C.S. Derkay, Recurrent respiratory papillomatosis: a 2020 perspective, *Laryngoscope Investig Oto* 6 (2021) 340–345.
- [17] R.Y. Seedat, Juvenile-onset recurrent respiratory papillomatosis diagnosis and management - a developing country review, *Pediatr. Health Med. Therapeut.* 11 (2020) 39–46.
- [18] A. Ponduri, M.C. Azmy, E. Axler, J. Lin, R. Schwartz, et al., The efficacy of human papillomavirus vaccination as an adjuvant therapy in recurrent respiratory papillomatosis, *Laryngoscope* 133 (2023) 2046–2054.
- [19] Bernard H-U. Genome diversity and evolution of papillomaviruses. In: *Origin and Evolution of Viruses*. Elsevier, pp. 417–429.
- [20] K. Van Doorslaer, Revisiting papillomavirus taxonomy: a proposal for updating the current classification in line with evolutionary evidence, *Viruses* 14 (2022) 2308.
- [21] B.J. Kocjan, M. Poljak, M. Cimerman, N. Gale, M. Potočnik, et al., Prevalence of genetic diversity of human papillomavirus genotype 6 (HPV 6), *Virology* 391 (2009) 274–283.
- [22] P.J. Maver, B.J. Kocjan, K. Seme, M. Potočnik, N. Gale, et al., Prevalence of genetic diversity of human papillomavirus genotype 11: a study on 63 clinical isolates and 10 full-length genome sequences, *J. Med. Virol.* 83 (2011) 461–470.
- [23] M.M. Jelen, Z. Chen, B.J. Kocjan, F.J. Burt, P.K.S. Chan, et al., Global genomic diversity of human papillomavirus 6 based on 724 isolates and 190 complete genome sequences, *J. Virol.* 88 (2014) 7307–7316.
- [24] M.M. Jelen, Z. Chen, B.J. Kocjan, L. Hosnjak, F.J. Burt, et al., Global genomic diversity of human papillomavirus 11 based on 433 isolates and 78 complete genome sequences, *J. Virol.* 90 (2016) 5503–5513.
- [25] M. Gabbott, Y.E. Cossart, A. Kan, M. Konopka, R. Chan, et al., Human papillomavirus and host variables as predictors of clinical course in patients with juvenile-onset recurrent respiratory papillomatosis, *J. Clin. Microbiol.* 35 (1997) 3098–3103.
- [26] C.E. Combrinck, R.Y. Seedat, C. Randall, Y. Roodt, F.J. Burt, Novel HPV-6 variants of human papillomavirus causing recurrent respiratory papillomatosis in southern Africa, *Epidemiol. Infect.* 140 (2012) 1095–1101.
- [27] T. Gáll, A. Kis, T.Z. Tatár, G. Kardos, L. Gergely, et al., Genomic differences in the background of different severity in juvenile-onset respiratory papillomatosis associated with human papillomavirus type 11, *Med. Microbiol. Immunol.* 202 (2013) 353–363.
- [28] J.C. Byrne, M.S. Tsao, R.S. Fraser, P.M. Howley, Human papillomavirus-11 DNA in a patient with chronic laryngotracheobronchial papillomatosis and metastatic squamous-cell carcinoma of the lung, *N. Engl. J. Med.* 317 (1987) 873–878.
- [29] T.P. DiLorenzo, A. Tamsen, A.L. Abramson, B.M. Steinberg, Human papillomavirus type 6a DNA in the lung carcinoma of a patient with recurrent laryngeal papillomatosis is characterized by a partial duplication, *J. Gen. Virol.* 73 (1992) 423–428.
- [30] K. Grassmann, S.P. Wilczynski, N. Cook, B. Rapp, T. Ifner, HPV6 variants from malignant tumors with sequence alterations in the regulatory region do not reveal differences in the activities of the oncogene promoters but do contain amino acid exchanges in the E6 and E7 proteins, *Virology* 223 (1996) 185–197.
- [31] H. Yuan, D. Zhou, J. Wang, R. Schlegel, Divergent human papillomavirus associated with recurrent respiratory papillomatosis with lung involvement, *Genome Announc.* 1 (2013) e00474, 13.
- [32] J.M. Godínez, S. Nicolás-Párraga, V.N. Pimenoff, B. Mengual-Chuliá, N. Muñoz, et al., Phylogenetically related, clinically different: human papillomaviruses 6 and 11 variants distribution in genital warts and in laryngeal papillomatosis, *Clin. Microbiol. Infect.* 20 (2014) O406–O413.
- [33] L. Sicheo, S. Ferreira, R.V.M. López, B.P. Mello, V. Costa, et al., Prevalence of human papillomavirus 6 and 11 variants in recurrent respiratory papillomatosis, *J. Med. Virol.* 93 (2021) 3835–3840.
- [34] S.B. Drutman, F. Haerynck, F.L. Zhong, D. Hum, N.J. Hernandez, et al., Homozygous *NLRP1* gain-of-function mutation in siblings with a syndromic form of recurrent respiratory papillomatosis, *Proc. Natl. Acad. Sci. U.S.A.* 116 (2019) 19055–19063.
- [35] P.S. Mitchell, A. Sandstrom, R.E. Vance, The *NLRP1* inflammasome: new mechanistic insights and unresolved mysteries, *Curr. Opin. Immunol.* 60 (2019) 37–45.
- [36] O. Mamaí, L. Boussofara, M. Denguezli, N. Escande-Beillard, W. Kraeim, et al., Multiple self-healing palmo-plantar carcinoma: a familial predisposition to skin cancer with primary palmo-plantar and conjunctival lesions, *J. Invest. Dermatol.* 135 (2015) 304–308.
- [37] F.L. Zhong, O. Mamaí, L. Sborgi, L. Boussofara, R. Hopkins, et al., Germline *NLRP1* mutations cause skin inflammatory and cancer susceptibility syndromes via inflammasome activation, *Cell* 167 (2016) 187–202.e17.
- [38] S. Grandemange, E. Sanchez, P. Louis-Pence, F. Tran Mau-Them, D. Bessis, et al., A new autoinflammatory and autoimmune syndrome associated with *NLRP1* mutations: NAIAD (*NLRP1*-associated autoinflammation with arthritis and dyskeratosis), *Ann. Rheum. Dis.* 76 (2017) 1191–1198.
- [39] N.T. Can, M.S. Tretiakova, J.B. Taxy, Natural history and malignant transformation in recurrent respiratory papillomatosis: human papillomavirus (HPV), dysplasia and an autopsy review, *Fetal Pediatr. Pathol.* 34 (2015) 80–90.
- [40] I. Sechi, N. Muresu, B. Di Lorenzo, L. Saderi, M. Puci, et al., Pulmonary involvement in recurrent respiratory papillomatosis: a systematic review, *Infect. Dis. Rep.* 16 (2024) 200–215.
- [41] C.S. Derkay, D.J. Malis, G. Zalzal, B.J. Wiatrak, H.K. Kashima, et al., A staging system for assessing severity of disease and response to therapy in recurrent respiratory papillomatosis, *Laryngoscope* 108 (1998) 935–937.
- [42] J. Niyibizi, C. Rodier, M. Wassef, H. Trottier, Risk factors for the development and severity of juvenile-onset recurrent respiratory papillomatosis: a systematic review, *Int. J. Pediatr. Otorhinolaryngol.* 78 (2014) 186–197.
- [43] N. Guimera, B. Lloveras, J. Lindeman, L. Alemany, M. van de Sandt, et al., The occasional role of low-risk human papillomaviruses 6, 11, 42, 44, and 70 in anogenital carcinoma defined by laser capture microdissection/PCR methodology: results from a global study, *Am. J. Surg. Pathol.* 37 (2013) 1299–1310.
- [44] Centre international de recherche sur le cancer, in: *A Review of Human Carcinogens*, International agency for research on cancer, Lyon, 2012.
- [45] A. Holmes, S. Lameiras, E. Jeannot, Y. Marie, L. Castera, et al., Mechanistic signatures of HPV insertions in cervical carcinomas, *NPJ Genom Med* 1 (2016) 16004.
- [46] A.M. Bolger, M. Lohse, B. Usadel, Trimmomatic: a flexible trimmer for Illumina sequence data, *Bioinformatics* 30 (2014) 2114–2120.
- [47] B. Langmead, S.L. Salzberg, Fast gapped-read alignment with Bowtie 2, *Nat. Methods* 9 (2012) 357–359.
- [48] D.E. Deatherage, J.E. Barrick, Identification of mutations in laboratory-evolved microbes from next-generation sequencing data using breseq, *Methods Mol. Biol.* 1151 (2014) 165–188.
- [49] C. Camacho, G. Coulouris, V. Avagyan, N. Ma, J. Papadopoulos, et al., BLAST+: architecture and applications, *BMC Bioinf.* 10 (2009) 421.
- [50] K. Katoh, D.M. Standley, MAFFT multiple sequence alignment software version 7: improvements in performance and usability, *Mol. Biol. Evol.* 30 (2013) 772–780.
- [51] A.M. Kozlov, D. Darriba, T. Flouri, B. Morel, A. Stamatakis, RAXML-NG: a fast, scalable and user-friendly tool for maximum likelihood phylogenetic inference, *Bioinformatics* 35 (2019) 4453–4455.
- [52] A. Stamatakis, RAXML version 8: a tool for phylogenetic analysis and post-analysis of large phylogenies, *Bioinformatics* 30 (2014) 1312–1313.
- [53] C.W. Nelson, A.L. Hughes, Within-host nucleotide diversity of virus populations: insights from next-generation sequencing, *Infect. Genet. Evol.* 30 (2015) 1–7.
- [54] P. Danecek, J.K. Bonfield, J. Liddle, J. Marshall, V. Ohan, et al., Twelve years of SAMtools and BCFtools, *GigaScience* 10 (2021) giab008.
- [55] V. Béziat, Human genetic dissection of papillomavirus-driven diseases: new insight into their pathogenesis, *Hum. Genet.* 139 (2020) 919–939.
- [56] Garrison E, Marth G. Haplotype-based Variant Detection from Short-Read Sequencing. Epub ahead of print 20 July 2012. DOI: 10.48550/arXiv.1207.3907.
- [57] K. Okonechnikov, O. Golosova, M. Fursov, the UGENE team, Unipro UGENE: a unified bioinformatics toolkit, *Bioinformatics* 28 (2012) 1166–1167.
- [58] A.J. Donne, L. Hampson, J.J. Homer, I.N. Hampson, The role of HPV type in recurrent respiratory papillomatosis, *Int. J. Pediatr. Otorhinolaryngol.* 74 (2010) 7–14.
- [59] F.J. Buchinsky, W.L. Valentino, N. Ruzskay, E. Powell, C.S. Derkay, et al., Age at diagnosis, but not HPV type, is strongly associated with clinical course in recurrent respiratory papillomatosis, *PLoS One* 14 (2019) e0216697.
- [60] C. Hartley, J. Hamilton, A.R. Birzgalis, W.T. Farrington, Recurrent respiratory papillomatosis – the Manchester experience, 1974–1992, *J. Laryngol. Otol.* 108 (1994) 226–229.
- [61] R.L. Nogueira, D.S. Küpper, C.M. do Bonfim, D.C. Aragon, T.A. Damico, et al., HPV genotype is a prognosticator for recurrence of respiratory papillomatosis in children, *Clin. Otolaryngol.* 46 (2021) 181–188.
- [62] M.C. Bedard, A. de Alarcon, Y.-F. Kou, D. Lee, A. Sestito, et al., HPV strain predicts severity of juvenile-onset recurrent respiratory papillomatosis with implications for disease screening, *Cancers* 13 (2021) 2556.
- [63] J.R. Cook, D.A. Hill, P.A. Humphrey, J.D. Pfeifer, S.K. El-Mofty, Squamous cell carcinoma arising in recurrent respiratory papillomatosis with pulmonary involvement: emerging common pattern of clinical features and human papillomavirus serotype association, *Mod. Pathol.* 13 (2000) 914–918.
- [64] G.L. Mitsumoto, F.D.C. Bernardi, L.L. Villa, B. Mello, G. Pozzan, Juvenile-onset recurrent respiratory papillomatosis with pulmonary involvement and carcinomatous transformation, *Autops Case Rep* 8 (2018) e2018035.
- [65] T. Mamaeva, C.S. Mehlum, J.R. Davidsen, Recurrent respiratory papillomatosis with lower airway involvement in a young woman, *European Clinical Respiratory Journal* 7 (2020) 1740567.
- [66] A.C. Kovacs, D. Vodanovich, E.K. Mogridge, L. Lun, J. Corry, A case of primary tracheal squamous cell carcinoma arising from malignant transformation of recurrent respiratory papillomatosis, with a complete response to concurrent chemoradiotherapy, *SAGE Open Medical Case Reports* 9 (2021), 2050313X2110546.
- [67] P. Mounts, H. Kashima, Association of human papillomavirus subtype and clinical course in respiratory papillomatosis, *Laryngoscope* 94 (1984) 28–33.
- [68] A.P. Zarod, J.D. Rutherford, G. Corbitt, Malignant progression of laryngeal papilloma associated with human papilloma virus type 6 (HPV-6) DNA, *J. Clin. Pathol.* 41 (1988) 280–283.

- [69] H. Kashima, T.C. Wu, P. Mounts, D. Heffner, A. Cachay, et al., Carcinoma ex-papilloma: histologic and virologic studies in whole-organ sections of the larynx, *Laryngoscope* 98 (1988) 619–624.
- [70] T. Kanazawa, N. Fukushima, S. Imayoshi, T. Nagatomo, K. Kawada, et al., Rare case of malignant transformation of recurrent respiratory papillomatosis associated with human papillomavirus type 6 infection and p53 overexpression, *SpringerPlus* 2 (2013) 153.
- [71] Y. Xiao, J. Wang, D. Han, L. Ma, F.A. Lopez, A case of the intrapulmonary spread of recurrent respiratory papillomatosis with malignant transformation, *Am. J. Med. Sci.* 350 (2015) 55–57.
- [72] M. Cardoso Figueiredo, M. Chantre-Justino, R. Latini Ruback, P. Pires De Mello, G. Alves, et al., Clinical and treatment course of lung carcinoma from adult-onset recurrent respiratory papillomatosis with lung involvement: a case report, *Oral Oncol.* 121 (2021) 105398.
- [73] I.C. Gonçalves, C. Silva, J. Gomes, S. Xará, Recurrent respiratory papillomatosis presenting as worsening dyspnea in an HIV-infected patient, *Cureus* 14 (2022) e32908.
- [74] E.L. Erickson, T.E. Freeman, S. Sun, B. Koch, D.Z. Allen, et al., Recurrent respiratory papillomatosis disease course in immunosuppressed populations, *J. Laryngol. Otol.* 138 (2024) 576–580.
- [75] C. Go, M.R. Schwartz, D.T. Donovan, Molecular transformation of recurrent respiratory papillomatosis: viral typing and p53 overexpression, *Ann. Otol. Rhinol. Laryngol.* 112 (2003) 298–302.
- [76] N. Guimera, B. Lloveras, J. Lindeman, L. Alemany, M. van de Sandt, et al., The occasional role of low-risk human papillomaviruses 6, 11, 42, 44, and 70 in anogenital carcinoma defined by laser capture microdissection/PCR methodology: results from a global study, *Am. J. Surg. Pathol.* 37 (2013) 1299–1310.
- [77] H. Kitasato, H. Delius, H. zur Hausen, K. Sorger, F. Rösl, et al., Sequence rearrangements in the upstream regulatory region of human papillomavirus type 6: are these involved in malignant transition? *J. Gen. Virol.* 75 (Pt 5) (1994) 1157–1162.
- [78] O. Forslund, S. Schwartz, K. Olofsson, R. Rydell, Viral load and m RNA expression of HPV type 6 among cases with recurrent respiratory papillomatosis, *Laryngoscope* 126 (2016) 122–127.
- [79] C.U. Huebbers, S.F. Preuss, J. Kolligs, J. Vent, M. Stenner, et al., Integration of HPV6 and downregulation of AKR1C3 expression mark malignant transformation in a patient with juvenile-onset laryngeal papillomatosis, *PLoS One* 8 (2013) e57207.
- [80] T. Kahn, E. Turazza, R. Ojeda, A. Bercovich, A. Stremlau, et al., Integration of human papillomavirus type 6a DNA in a tonsillar carcinoma: chromosomal localization and nucleotide sequence of the genomic target region, *Cancer Res.* 54 (1994) 1305–1312.
- [81] P.M. Reidy, H.H. Dedo, R. Rabah, J.B. Field, R.H. Mathog, et al., Integration of human papillomavirus type 11 in recurrent respiratory papilloma-associated cancer, *Laryngoscope* 114 (2004) 1906–1909.
- [82] H. Yuan, D. Zhou, J. Wang, R. Schlegel, Divergent human papillomavirus associated with recurrent respiratory papillomatosis with lung involvement, *Genome Announc.* 1 (2013) e00474, 13.
- [83] CM do Bonfim, J.S. Sobrinho, R.L. Nogueira, D.S. Kupper, F.C.P. Valera, et al., Differences in transcriptional activity of human papillomavirus type 6 molecular variants in recurrent respiratory papillomatosis, *PLoS One* 10 (2015) e0132325.
- [84] T. Ikegami, H. Hirakawa, N. Tsukahara, A. Murakami, N. Kise, et al., Coordinated expression of HPV-6 genes with predominant E4 and E5 expression in laryngeal papilloma, *Microorganisms* 9 (2021) 520.
- [85] A. Baumann, J. Henriques, Z. Selmani, A. Meurisse, Q. Lepiller, et al., HPV16 load is a potential biomarker to predict risk of high-grade cervical lesions in high-risk HPV-infected women: a large longitudinal French hospital-based cohort study, *Cancers* 13 (2021) 4149.
- [86] S. Yamada, T. Itoh, T. Ikegami, A. Imai, D. Mochizuki, et al., Association between human papillomavirus particle production and the severity of recurrent respiratory papillomatosis, *Sci. Rep.* 13 (2023) 5514.
- [87] M. Szepe, L. Dahlgren, L.-M. Aaltonen, J. Öhd, L. Kanter-Lewenshon, et al., Human papillomavirus, viral load and proliferation rate in recurrent respiratory papillomatosis in response to alpha interferon treatment, *J. Gen. Virol.* 86 (2005) 1695–1702.
- [88] Z. Deng, T. Ikegami, A. Kiyuna, C. Zhang, T. Zhang, et al., Methylation of CpG sites in the upstream regulatory region, physical status and mRNA expression of HPV-6 in adult-onset laryngeal papilloma, *Oncotarget* 8 (2017) 85368–85377.
- [89] H. Ogura, S. Watanabe, K. Fukushima, Y. Baba, Y. Masuda, et al., Persistence of human papillomavirus type 6e in adult multiple laryngeal papilloma and the counterpart false cord of an interferon-treated patient, *Jpn. J. Clin. Oncol.* 23 (1993) 130–133.
- [90] B.J. Kocjan, N. Gale, I. Hočevar Boltežar, K. Seme, K. Fujs Komloš, et al., Identical human papillomavirus (HPV) genomic variants persist in recurrent respiratory papillomatosis for up to 22 years, *J. Infect. Dis.* 207 (2013) 583–587.
- [91] K.Y. Lin, W.H. Westra, H.K. Kashima, P. Mounts, T.C. Wu, Coinfection of HPV-11 and HPV-16 in a case of laryngeal squamous papillomas with severe dysplasia, *Laryngoscope* 107 (1997) 942–947.
- [92] M. Peñaloza-Plascencia, H. Montoya-Fuentes, S.E. Flores-Martínez, F.J. Fierro-Velasco, J.M. Peñaloza-González, et al., Molecular identification of 7 human papillomavirus types in recurrent respiratory papillomatosis, *Arch. Otolaryngol. Head Neck Surg.* 126 (2000) 1119–1123.
- [93] B.J. Wiatrak, D.W. Wiatrak, T.R. Broker, L. Lewis, Recurrent respiratory papillomatosis: a longitudinal study comparing severity associated with human papilloma viral types 6 and 11 and other risk factors in a large pediatric population, *Laryngoscope* 114 (2004) 1–23.
- [94] I.N. Mammias, D.A. Spandidos, G. Sourvinos, Genomic diversity of human papillomaviruses (HPV) and clinical implications: an overview in adulthood and childhood, *Infect. Genet. Evol.* 21 (2014) 220–226.
- [95] A. Ahmed, A. Shukla, N. Hubbell, M.K. Almujaresh, D. LaBuda, et al., Early identification and intervention in malignant transformation of respiratory papillomatosis, *Am J Case Rep* 24 (2023) e937665.
- [96] R.F. Murray, J. Hobbs, B. Payne, Possible clonal origin of common warts (*Verruca vulgaris*), *Nature* 232 (1971) 51–52.
- [97] W. Quint, D. Jenkins, A. Molijn, L. Struijk, M. van de Sandt, et al., One virus, one lesion—individual components of CIN lesions contain a specific HPV type, *J. Pathol.* 227 (2012) 62–71.