



HAL
open science

Successful prevention of BK-polyomavirus nephropathy using extracorporeal photopheresis for immunosuppression minimisation following severe BK polyomavirus replication after kidney transplantation in a double lung transplant recipient, a case report

Florent von Tokarski, François Parquin, Antoine Roux, Victor Hayem, Thibault Kerdiles, Marion Rabant, Pierre Isnard, Alexandre Loupy, Cyril Fourniol, Leila Tricot, et al.

► To cite this version:

Florent von Tokarski, François Parquin, Antoine Roux, Victor Hayem, Thibault Kerdiles, et al.. Successful prevention of BK-polyomavirus nephropathy using extracorporeal photopheresis for immunosuppression minimisation following severe BK polyomavirus replication after kidney transplantation in a double lung transplant recipient, a case report. *BMC Nephrology*, 2024, 25 (1), 10.1186/s12882-024-03788-4 . hal-04758720

HAL Id: hal-04758720

<https://hal.science/hal-04758720v1>

Submitted on 19 Nov 2024

HAL is a multi-disciplinary open access archive for the deposit and dissemination of scientific research documents, whether they are published or not. The documents may come from teaching and research institutions in France or abroad, or from public or private research centers.

L'archive ouverte pluridisciplinaire **HAL**, est destinée au dépôt et à la diffusion de documents scientifiques de niveau recherche, publiés ou non, émanant des établissements d'enseignement et de recherche français ou étrangers, des laboratoires publics ou privés.



Distributed under a Creative Commons Attribution - NonCommercial - NoDerivatives 4.0 International License

CASE REPORT

Open Access



Successful prevention of BK-polyomavirus nephropathy using extracorporeal photopheresis for immunosuppression minimisation following severe BK polyomavirus replication after kidney transplantation in a double lung transplant recipient, a case report

Florent Von Tokarski^{1,2*}, François Parquin³, Antoine Roux^{1,3}, Victor Hayem², Thibault Kerdiles², Marion Rabant⁴, Pierre Isnard⁴, Alexandre Loupy⁵, Cyril Fourniol⁶, Leila Tricot², Clément Picard³, Alexandre Hertig^{1,2} and Julie Oniszczyk²

Abstract

Background BK-polyomavirus (BKpyV) nephropathy (BKVN) is associated with end-stage kidney disease in kidney and non-kidney solid organ transplantation, with no curative treatment.

Case presentation A 45-year-old woman with a past medical history of double lung transplantation subsequently developed end-stage kidney disease, of undetermined origin. One month after receiving a kidney transplant, a diagnosis of early BKVN was suspected, and in retrospect was a reasonable cause for the loss of her native kidneys. Minimisation of immunosuppression, achieved through extracorporeal photopheresis, allowed clearance of BKpyV and so prevented nephropathy. Both lung and kidney grafts had a satisfactory and stable function after one year of follow-up, with no rejection.

Conclusions Extracorporeal photopheresis may have facilitated minimisation of immunosuppression and BKpyV clearance without lung allograft rejection.

Keywords BK-polyomavirus, Kidney transplant, Lung transplant, Extracorporeal photopheresis, Minimization, Case report

*Correspondence:

Florent Von Tokarski
f.von-tokarski@hopital-foch.com

¹Faculty of Medical School, University of Versailles-Saint-Quentin-en-Yvelines, Montigny-Le-Bretonneux, France

²Department of Nephrology, Dialysis, and Transplantation, Foch Hospital, Suresnes, France

³Department of Pneumology, Adult Cystic Fibrosis Center and Lung Transplantation Dept, Foch Hospital, Suresnes, France

⁴Department of Pathology, APHP, Necker Hospital, Université Paris Cité, Paris, France

⁵Paris Transplant Group, National Institute of Health and Medical Research, PARCC U970, Paris, France

⁶Department of Urology, Foch Hospital, Foch Hospital, Suresnes, France



© The Author(s) 2024. **Open Access** This article is licensed under a Creative Commons Attribution-NonCommercial-NoDerivatives 4.0 International License, which permits any non-commercial use, sharing, distribution and reproduction in any medium or format, as long as you give appropriate credit to the original author(s) and the source, provide a link to the Creative Commons licence, and indicate if you modified the licensed material. You do not have permission under this licence to share adapted material derived from this article or parts of it. The images or other third party material in this article are included in the article's Creative Commons licence, unless indicated otherwise in a credit line to the material. If material is not included in the article's Creative Commons licence and your intended use is not permitted by statutory regulation or exceeds the permitted use, you will need to obtain permission directly from the copyright holder. To view a copy of this licence, visit <http://creativecommons.org/licenses/by-nc-nd/4.0/>.

Introduction

BK-polyomavirus (BKpyV) nephropathy (BKVN) is a rare complication of non-kidney solid organ transplantation. Failure to control BKpyV replication in patients exposed to immunosuppressive drugs may result in BKVN. In patients with viral loads peaking above 6 log₁₀ copies/mL, the likelihood of developing extensive BKVN pathology is extremely high (>98%) [1, 2]. BKVN is a well-known complication in kidney transplantation because it compromises graft survival, but it is much less well-established in native kidneys of other organ recipients. Chronic kidney disease (CKD) affecting a significant proportion of patients transplanted with an organ other than a kidney is often attributed to the chronic toxicity of calcineurin inhibitors – a diagnosis by default – while in fact other mechanisms can be involved, one of which is uncontrolled replication of BKpyV [3]. Prospective systematic urine BKpyV viral load screening showed positivity in 16/50 patients undergoing lung transplantation [4]. Dube et al. reported 879 kidney biopsies in lung transplants, 56 (6%) had an increased blood BKpyV viral load and 11 (1.3%) developed BKVN at a median of 46 months after transplant (range, 9–213) with 55% evolving to end-stage kidney disease (ESKD) [5]. Of note, one patient developed acute rejection after immunosuppressive minimisation. Peak BKpyV viral load ≥ 10 000 copies/mL was associated with ESKD (39% vs. 8% $p < 0.001$). We report here the case of a 45-year-old woman presenting with a high BKpyV viral load after kidney transplantation following lung transplantation and successful prevention of BKVN using minimisation of immunosuppression with extracorporeal photopheresis (ECP).

Case presentation

In December 2022, a 45-year-old woman was admitted to our Department of Nephrology to receive a deceased-donor kidney transplant.

The patient had received a double lung transplantation in 2010 for chronic pulmonary hypertension and bronchiectasis secondary to tuberculosis. Induction immunosuppression was achieved using methylprednisolone and anti-thymocyte globulin (10 mg/kg total). The maintenance regimen was cyclosporine A (CsA), mycophenolate mofetil (MMF), and steroids. The postoperative period was marked by an early (postoperative day [POD]7) acute cellular rejection (A1B0) treated with 1500 mg of intravenous methylprednisolone and antibody-mediated rejection at POD10 treated with five plasma exchanges, rituximab, and intravenous immunoglobulins (IVIgs). Tacrolimus replaced CsA at postoperative month (POM)4, and everolimus was added at POM14 on top of tacrolimus, MMF and steroids because of stage I bronchiolitis obliterans syndrome (BOS). Rituximab was re-administered at posttransplant year (POY)8, and IVIgs

were resumed monthly for chronic lung allograft dysfunction (CLAD).

Kidney function was normal prior to lung transplantation (estimated glomerular filtration rate [GFR] was 133 mL/min/1.73 m²) and rapidly deteriorated at POY6 (serum creatinine [SCr] was 240 μmol/L versus 100 μmol/L six months earlier). Proteinuria was 0.5 g per g of creatinine without haematuria and leucocyturia. A renal ultrasound showed a kidney length of 104 mm at right and 74 mm at left, with no signs of obstruction. The renal asymmetry was confirmed by a magnetic resonance angiography which showed no sign of renal artery stenosis. A saline contrast echocardiography showed an aneurysmal inter-atrial septum plus a patent foramen ovale (PFO); in retrospect, PFO was already present at the time of the double lung transplantation surgery. Anticoagulation using Coumadin® was initiated because of doubts about an embolic cause for the left kidney atrophy, and to prevent further episodes (other tests comprising a 24-hour electrocardiogram Holter monitoring, as well as thrombophilia markers, all proved negative). The benefit/risk ratio of a biopsy of the right kidney (functionally unique) was deemed unfavourable. Short of histology, CKD was attributed by default to a nephronic reduction, and to the chronic toxicity of calcineurin inhibitors. Renal replacement therapy was started in 2017 (POY7). Maintenance immunosuppressive therapy comprised tacrolimus, mycophenolic acid, and steroids.

Five years later, the patient received a first kidney transplant procured from a standard criterion deceased donor (non-diabetic 49-year-old male who died from haemorrhagic stroke; body mass index of 45 kg/m²; SCr 100 μmol/L; the graft had two arteries and one vein). The patient had no donor specific antibodies (DSAs) against the donor, and complement-dependent cytotoxicity crossmatch was negative. Cold ischemia time (CIT) was unusually long (33 h). Induction and maintenance immunosuppression were achieved by thymoglobulin (4.5 mg/kg total) and MMF, tacrolimus, and steroids, respectively. Graft function recovery was slow (0% creatinine reduction ratio at POD2, without need for dialysis). Acute graft pyelonephritis occurred on POD7, due to an NDM-1 carbapenemase-producing *Escherichia coli* infection (Cefiderocol, 2 g thrice a day, was administered for 10 days). An endo-ureteral double-J stent was inserted because of ureteral extrinsic compression caused by a haematoma that had developed under unfractionated heparin, prescribed for the PFO.

Real time PCR detected BKpyV DNA replication (EurobioPlex BK virus) in blood (6.9 log₁₀ copies/mL) on POD15, at which point we decided to withdraw MMF. Since the lowest SCr level was 79 μmol/L on POD19 without proteinuria, we decided to cancel the allograft biopsy.

However, SCr concentration increased (145µmol/L) on POD28, proteinuria was 1.5 g per g of creatinine and BKpyV DNA replication increased (8log₁₀ copies/mL, Fig. 1). An allograft biopsy was performed on POD29, which showed neither inflammation nor tubulitis in non-scarred cortical areas. Tubular epithelial cells were free from nuclear anomalies, and Sv40 immunohistochemistry was negative. NanoString analysis (B-HOT panel) of a biopsy sample found no BKpyV-specific transcripts.

Retrospectively, urinary samples taken in 2017 (at enrolment for kidney transplant) showed decoy cells consistent with BKVN. In addition, blood samples taken on the day of transplantation and on POD8 were analysed and showed a BKpyV viral load of 3.85 and 6.19log₁₀ copies/mL, respectively, suggesting that BKpyV viral load was already positive prior to kidney transplantation and

that the patient's native kidney(s) may have presented BKVN in the first place.

Tacrolimus was switched to CsA on POD44 (with a target serum trough concentration of between 150 and 200ng/mL) and, to prevent lung/kidney allograft rejection, ECP was started to accompany this regimen of immunosuppression minimisation (Fig. 1). The ECP protocol is shown in Fig. 2.

On POM4, SCr concentration stabilised around 130µmol/L and technetium-99 m diethylene-triamine-pentaacetate-measured GFR was 32mL/min/1.73m²; urine proteinuria output decreased below 0.3 g per g of creatinine. Blood BKpyV viral load decreased to 3.4log₁₀ copies/mL. DSAs (against both lung and kidney donors) were negative at POM5. A second renal allograft biopsy showed no sign of BKVN (neither tubulitis nor

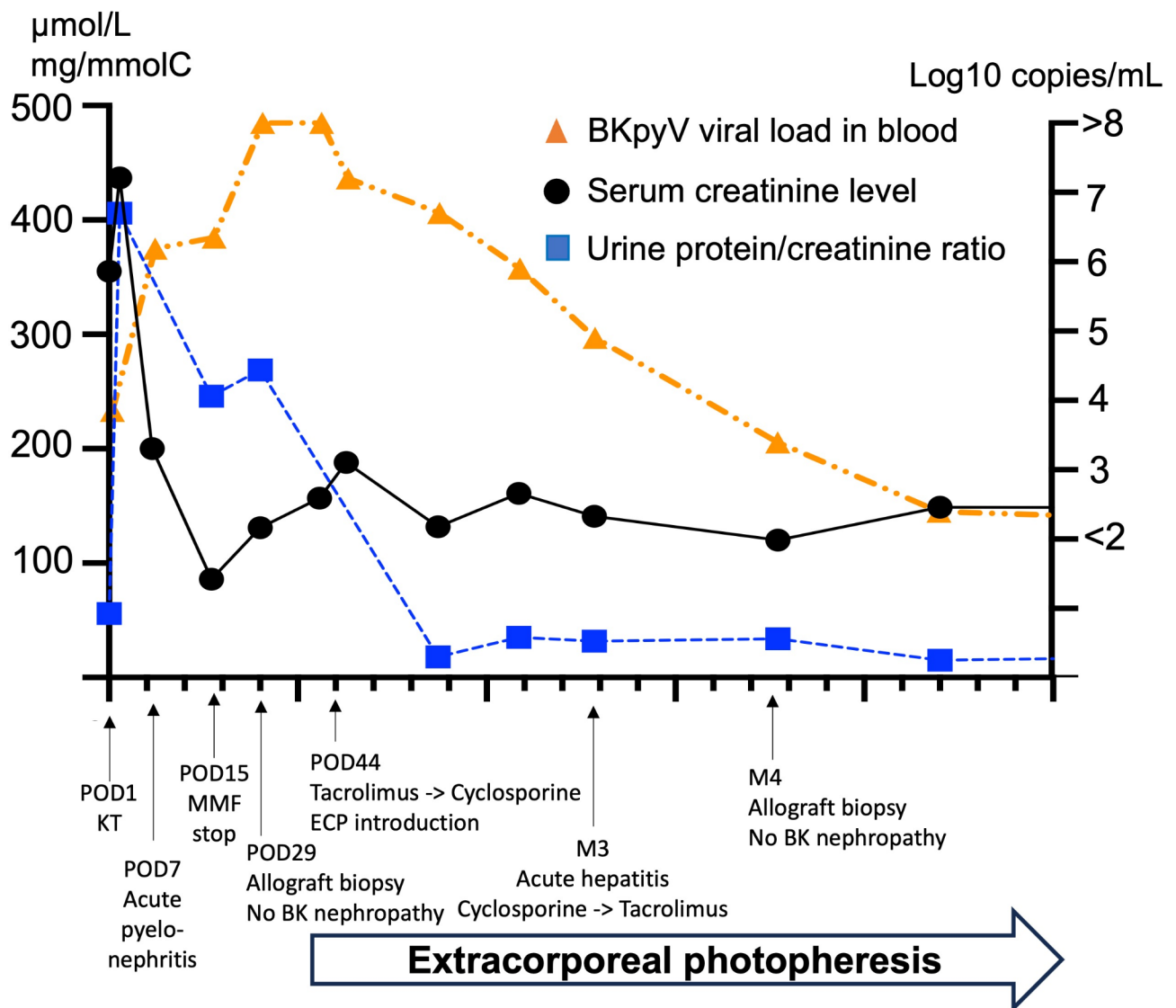


Fig. 1 Management of BK-polyomavirus nephropathy after kidney transplantation in a dual lung transplant recipient. BKpyV: BK polyomavirus; C: creatinine; KT: kidney transplantation; MMF: mycophenolate mofetil; POD: postoperative day

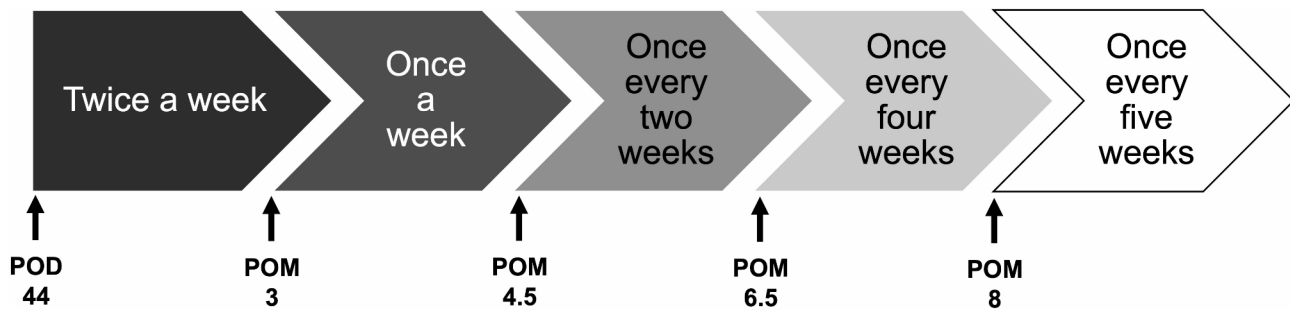


Fig. 2 Extracorporeal photopheresis administration protocol. POD: postoperative day; POM: postoperative month

inflammation, and negative staining for SV40 antigen) or rejection, but with an interstitial fibrosis/tubular atrophy grade 2, with moderate arterial intimal fibrosis. CD3+total T cell count was $870/\text{mm}^3$ at POM1 before ECP and had decreased to $460/\text{mm}^3$ at POM5 (both CD3+CD4+CD8⁻ and CD3+CD4-CD8⁺T cell count decreased). A liver biopsy performed for anicteric cholestasis showed hepatic porto-sinusoidal vascular disease, leading to a switch from CsA to tacrolimus. Blood BKpyV viral load was negative at POM9 and POM11. At that time, SCr concentration was $138\mu\text{mol/L}$ and tacrolimus serum trough level was 5.5ng/mL . Lung transplant function was found to be satisfactory and relatively stable (forced expiratory volume in one second decreased slightly from 860mL to 720mL between preoperative and POM11).

Discussion and conclusions

We present here a successful strategy of BKVN prevention without allograft rejection using ECP to permit MMF minimisation in a kidney recipient previously transplanted with a double lung and experiencing intense BKpyV replication.

Our patient had many risk factors for BKVN including (a) a high cumulative immunosuppressive therapy (two courses of thymoglobulin, rituximab, plasma exchanges, tacrolimus, MMF and steroids), (b) a prolonged CIT before kidney transplantation, (c) a recent endo-ureteral double-J stenting and (d) many HLA mismatches with the kidney donor (A: 2, B: 2, DR: 0, DQ: 2) [6].

Only one study has reported a case of BKVN 30 months after kidney transplantation with prior double lung transplant 8 years earlier [7]. Despite successive cidofovir, leflunomide and ciprofloxacin administration, and MMF cessation, the patient evolved toward ESKD 6 months after, and died 3 months later. However, Dube et al. recently reported 11 cases of BKVN in a native kidney after lung transplantation. Despite light minimisation using a decreased dose of immunosuppression (MMF) or switch (tacrolimus to CsA or mTOR inhibitors), 6 patients evolved towards ESKD. Pulmonary function remained stable and just one patient – the only one in

whom MMF was discontinued – presented with allograft rejection [5]. In our case, ECP allowed safe MMF discontinuation and stabilisation of lung function without sacrificing the newly implanted kidney transplant. Xipell et al. reported a case of BKVN after antibody-mediated rejection where ECP allowed kidney function stabilisation until discontinuation and allograft failure [8]. However, used on top of standard of care immunosuppression in heart transplant recipients, ECP gave no protection against viral infection, suggesting that minimisation is necessary for the immunomodulatory effects of ECP [9].

A BKpyV-specific CD8 T cell response plays a crucial role in controlling viral replication after transplantation [10]. Dekeyser and colleagues showed that, in patients with BKVN, alteration of T cell functionality is indeed limited to BKpyV-specific T cells, and not to the response to other viruses. Furthermore, they showed that class II HLA-DR mismatches play an important role in the control of BKpyV replication, through the help of an allogeneic CD4 T cell [11]. This allogeneic CD4 T cell response may provide some support to BKpyV-specific-memory CD8 T cells, improving their functionality. Signals from CD4 T cells are critical for optimal maintenance and reactivation of memory CD8 T cell responses [12]. ECP seemed an interesting option for countering the loss of a BKpyV-specific T cell response by modulating cytokine profiles or changing trafficking patterns. These modifications have already been described both in ECP for steroid-refractory acute and chronic graft versus host disease and in leukaemic cutaneous T cell lymphoma. Thus, ECP has immunomodulatory properties and promotes T-regulatory lymphocytes [13]. It also has unspecific anti-inflammatory properties, for example by inducing the release of IL-10 [14]. ECP is currently used as a rescue option in patients with BOS or CLAD, ideally at an early stage [15–17]. Whether it affects the BKpyV-specific T cell response is, however, still unknown.

In keeping with current guidelines on BKpyV management, our first step was to reduce immunosuppression by stopping MME, exposing the patient to a vital risk of lung transplant rejection (DSAs, and history of BOS and CLAD) [18]. We thus combined photopheresis to ensure

minimisation of immunosuppression at the earliest possible stage of BKVN (i.e. at a moment of high viral replication, but without any histological or even molecular signal of BKVN). This strategy allowed safe reduction of MMF without lung or kidney transplant rejection, and BKpyV viral load clearance.

Abbreviations

BKpyV	BK polyomavirus
BKVN	BK-polyomavirus nephropathy
BOS	Bronchiolitis obliterans
CIT	Cold ischemia time
CsA	Cyclosporine A
CKD	Chronic kidney disease
CLAD	Chronic lung allograft dysfunction
DSA	Donor specific antibody
ECP	Extracorporeal photopheresis
ESKD	End-stage kidney disease
GFR	Glomerular filtration rate
HLA	Human leukocyte antigen
IVIg	Intravenous immune globulin
MMF	Mycophenolate mofetil
PFO	Patent foramen ovale
POD	Postoperative day
POM	Postoperative month
POY	Postoperative year
SCr	Serum creatinine

Acknowledgements

Mrs Felicity Kay for English editing.

Author contributions

FVT, FP, AR, VH, TK, CF, LT, CP, AH and JO performed multidisciplinary clinical management of the patient. MR, PI and AL performed histology and nanostring analysis. FVT, FP, AH and JO wrote the manuscript. FVT and JO prepared figures 1 and 3. All authors reviewed the manuscript. Informed consent to participate was obtained from all authors.

Data availability

The data supporting this research cannot be made available for ethical and privacy reasons, the data are available from the author (Florent Von Tokarski f.von-tokarski@hopital-foch.com).

Declarations

Ethics approval and consent to participate

No ethics approval was required as this is a case study. Written and verbal consent was obtained from the patient.

Consent for publication

Written informed consent was obtained from the patient for the publication of this case report.

Competing interests

The authors declare no competing interests.

Disclosure

All the authors declared no competing interests. Informed consent to participate was obtained from all authors.

Received: 16 April 2024 / Accepted: 30 September 2024

Published online: 18 October 2024

References

1. Hirsch HH, Knowles W, Dickenmann M, Passweg J, Klimkait T, Mihatsch MJ, et al. Prospective study of polyomavirus type BK replication and nephropathy in renal-transplant recipients. *N Engl J Med*. 2002;347(7):488–96.
2. Pollara CP, Corbellini S, Chiappini S, Sandrini S, De Tomasi D, Bonfanti C, et al. Quantitative viral load measurement for BKV infection in renal transplant recipients as a predictive tool for BKVAN. *New Microbiol*. 2011;34(2):165–71.
3. Albasha W, Vahdani G, Ashoka A, Bracamonte E, Yau AA. Native BK virus nephropathy in lung transplant: a case report and literature review. *Clin Kidney J*. 2022;15(4):808–11.
4. Thomas LD, Vilchez RA, White ZS, Zanwar P, Milstone AP, Butel JS, et al. A prospective longitudinal study of polyomavirus shedding in lung-transplant recipients. *J Infect Dis*. 2007;195(3):442–9.
5. Dube GK, Batal I, Shah L, Robbins H, Arcasoy SM, Husain SA. BK DNAemia and native kidney polyomavirus nephropathy following lung transplantation. *Am J Transpl*. 2023;23(2):284–90.
6. Sawinski D, Goral S. BK virus infection: an update on diagnosis and treatment. *Nephrol Dial Transpl*. 2015;30(2):209–17.
7. Sekulic M, Cray GS, Herrera Hernandez LP. BK Polyomavirus Tubulointerstitial Nephritis with Urothelial Hyperplasia in a kidney transplant. *Am J Kidney Dis*. 2016;68(2):307–11.
8. Xipell M, Molina-Andújar A, Cid J, Piñero GJ, Montagud-Marrahi E, Cofan F, et al. Immunogenic and immunotolerogenic effects of extracorporeal photopheresis in high immunological risk kidney recipients. A single center case series. *J Clin Apher*. 2022;37(3):197–205.
9. Barr ML, Meiser BM, Eisen HJ, Roberts RF, Livi U, Dall'Amico R, et al. Photopheresis for the prevention of rejection in cardiac transplantation. Photopheresis Transplantation Study Group. *N Engl J Med*. 1998;339(24):1744–51.
10. Schaanman JM, Korin Y, Sidwell T, Kandarian F, Harre N, Gjertson D, et al. Increased frequency of BK Virus-Specific Polyfunctional CD8 + T cells predict successful control of BK Viremia after kidney transplantation. *Transplantation*. 2017;101(6):1479–87.
11. Dekeyser M, de Goër de Herve, M. G., Hendel-Chavez, H., Lhotte, R., Scriabine, I., Bargiel, K., Boutin, E., Herr, F., Taupin, J. L., Taoufik, Y., & Durrbach, A. (2024). Allogeneic CD4 T Cells Sustain Effective BK Polyomavirus-Specific CD8 T Cell Response in Kidney Transplant Recipients. *Kidney international reports*, 9(8), 2498–2513. <https://doi.org/10.1016/j.ekir.2024.04.070https://www.researchsquare.com/article/rs-1650939/v1>
12. Kaech SM, Ahmed R, Immunology. CD8 T cells remember with a little help. *Science*. 2003;300(5617):263–5.
13. Cho A, Jantschitsch C, Knobler R. Extracorporeal Photopheresis-An overview. *Front Med (Lausanne)*. 2018;5:236.
14. Knobler R, Arenberger P, Arun A, Assaf C, Bagot M, Berlin G, et al. European dermatology forum - updated guidelines on the use of extracorporeal photopheresis 2020 - part 1. *J Eur Acad Dermatol Venereol*. 2020;34(12):2693–716.
15. Greer M, Dierich M, De Wall C, Suhling H, Rademacher J, Welte T, et al. Phenotyping established chronic lung allograft dysfunction predicts extracorporeal photopheresis response in lung transplant patients. *Am J Transpl*. 2013;13(4):911–8.
16. Hage CA, Klesney-Tait J, Wille K, Arcasoy S, Yung G, Hertz M, et al. Extracorporeal photopheresis to attenuate decline in lung function due to refractory obstructive allograft dysfunction. *Transfus Med*. 2021;31(4):292–302.
17. Greer M, Liu B, Magnusson JM, Fuehner T, Schmidt BMW, Deluca D, et al. Assessing treatment outcomes in CLAD: the Hannover-extracorporeal photopheresis model. *J Heart Lung Transpl*. 2023;42(2):209–17.
18. Hirsch HH, Randhawa PS, AST Infectious Diseases Community of Practice. BK Polyomavirus in solid organ transplantation-guidelines from the American Society of Transplantation Infectious Diseases Community of Practice. *Clin Transpl*. 2019;33(9):e13528.

Publisher's note

Springer Nature remains neutral with regard to jurisdictional claims in published maps and institutional affiliations.