



**HAL**  
open science

# Rare Intrasellar Space Occupying Lesion Presenting as Hypopituitarism: Case Report and Review of the Literature on Intrasellar Arachnoid Cyst

Gupta Parul

► **To cite this version:**

Gupta Parul. Rare Intrasellar Space Occupying Lesion Presenting as Hypopituitarism: Case Report and Review of the Literature on Intrasellar Arachnoid Cyst. *International Journal of Brain Disorders and Treatment*, 2024, 10 (1), <10.23937/2469-5866/1410051>. <hal-04745874>

**HAL Id: hal-04745874**

**<https://hal.science/hal-04745874v1>**

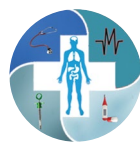Submitted on 21 Oct 2024

HAL is a multi-disciplinary open access archive for the deposit and dissemination of scientific research documents, whether they are published or not. The documents may come from teaching and research institutions in France or abroad, or from public or private research centers.

L'archive ouverte pluridisciplinaire HAL, est destinée au dépôt et à la diffusion de documents scientifiques de niveau recherche, publiés ou non, émanant des établissements d'enseignement et de recherche français ou étrangers, des laboratoires publics ou privés.



HAL Authorization



## CASE REPORT

# Rare Intracellular Space Occupying Lesion Presenting as Hypopituitarism: Case Report and Review of the Literature on Intracellular Arachnoid Cyst

Parul Gupta\* 

Department of Neurosurgery, Christian Medical College, Ludhiana, Punjab, India



\*Corresponding author: Parul Gupta, Department of Neurosurgery, Christian Medical College, Plot no. 17, 284/12, Street 16 A, Pragati Nagar, Risali, Bhilai, Chhattisgarh, 490006, India, Tel: +917587100408

## Abstract

**Background:** Compared to cystic adenomas, craniopharyngiomas, and Rathke's cleft cysts, intracellular arachnoid cysts are rare. The differential of intracellular Arachnoid Cysts should be regarded in patients with radiologically confirmed intracellular cystic lesions.

**Methods and material:** We present a 50-year-old patient with 2 months of diplopia and a cystic sellar mass on radiology. We performed transnasal transsphenoidal surgery. Postoperative recovery was unremarkable.

**Conclusions:** Intracellular Arachnoid Cysts (IAC) are surgically treated like non-secreting adenomas with pituitary malfunction or compression. Although rare, arachnoid cysts must be explored in sellar area differential diagnosis. Rare sellar arachnoid cysts (SACs) are treated only if symptomatic. The Trans-Nasal, Trans-Sphenoidal endoscopic technique is popular.

## Keywords

Arachnoid cyst, Endoscopic, Intracellular arachnoid cyst, Transsphenoidal approach

## Key Message

Preoperative evaluation, treatment modalities, and literature review are shown in this case report.

## Introduction

Arachnoid cysts are primarily congenital lesions. But children rarely develop intracellular arachnoid cysts, and it usually appears in the fourth or fifth decade [1,2]. Headache is their main complaint, however bitemporal hemianopsia and endocrinopathy have been recorded

[2]. Hemorrhagic cysts are often hard to identify from Rathke pouch cysts. A majority of arachnoid cysts are hyperintense on T2-weighted Magnetic Resonance Imaging (MRI) and hypointense on T1. With gadolinium contrast imaging that demonstrates the surrounding vascular construction, the mass effect on nearby structures and anomalies can be best observed. MRI's higher resolution helps detect tiny cysts and cysts near bony structures, notably in the sellar area. MRI distinguishes cerebrospinal fluid (CSF) -like fluid in most arachnoid cysts from proteinaceous fluid in other cystic tumors. Cysts can be distinguished from dermoids, ependymal cysts, tumors, and epidermoids by gadolinium enhancement and T1 and FLAIR imaging sequences. Using proton density-weighted and diffusion-weighted sequences can assist in identifying cysts from epidermoids and malignancies [3].

## Case Report

A 50-year-old man with multiple vomiting episodes and impaired sensorium two months earlier was diagnosed with hyponatremia, treated symptomatically, and released. No comorbidities, headaches, seizures, or vomiting were reported. The patient continued to have generalized weakness and presented to our institute with that being the primary complaint along with diplopia. Clinical examination showed normal visual acuity with Diplopia on lateral gaze (bilaterally). Neurological testing was unremarkable. Ophthalmology and perimetry supported the findings. The endocrinology team recommended routine blood tests and endocrine workup before surgery.



**Citation:** Gupta P (2024) Rare Intracellular Space Occupying Lesion Presenting as Hypopituitarism: Case Report and Review of the Literature on Intracellular Arachnoid Cyst. Int J Brain Disord Treat 10:051. doi.org/10.23937/2469-5866/1410051

**Accepted:** September 16, 2024; **Published:** September 18, 2024

**Copyright:** © 2024 Gupta P. This is an open-access article distributed under the terms of the Creative Commons Attribution License, which permits unrestricted use, distribution, and reproduction in any medium, provided the original author and source are credited.

The following abnormalities were observed:

Severe Hyponatremia -S.Na<sup>+</sup>- 125 mEq/L

Serum cortisol (8 AM)- 3.97 mcg/dL (low)

Serum cortisol (60 min post-ACTH)- 12.74 mcg/dL (low)

ft3- 3.23 mcg/dL (low)

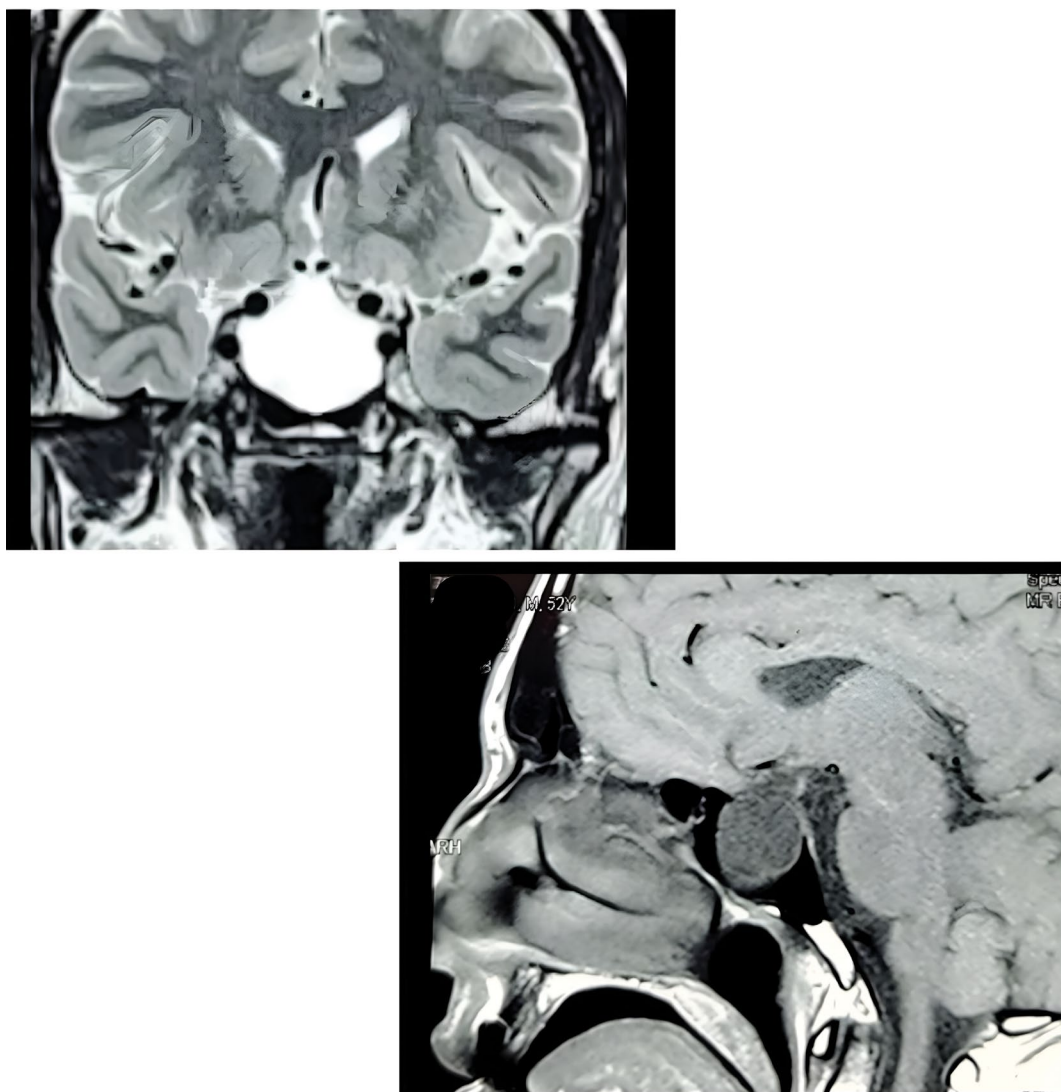
ft4- 5.72 mcg/dL (low).

Gadolinium enhanced Magnetic resonance imaging (MRI) brain indicated enlarged sella along with a cystic lesion. The lesion was - Hypointense in T1 weighted image, hyperintense in T2 weighted image (Figure 1), no diffusion limitation noted on DWI, with additional findings being -suprasellar extension and optic chiasma displacement and compression. There was no evidence of septations or calcification or solid components or any other T1 hyperintense signals. The lesion measured approximately 23.20 mm anteroposteriorly, 34.5 mm craniocaudally, and 28.1 mm transversely and was laterally abutting on the cavernous segments of bilateral internal carotid arteries with a 90-degree abutment. Mass effect was noted in the form of superior

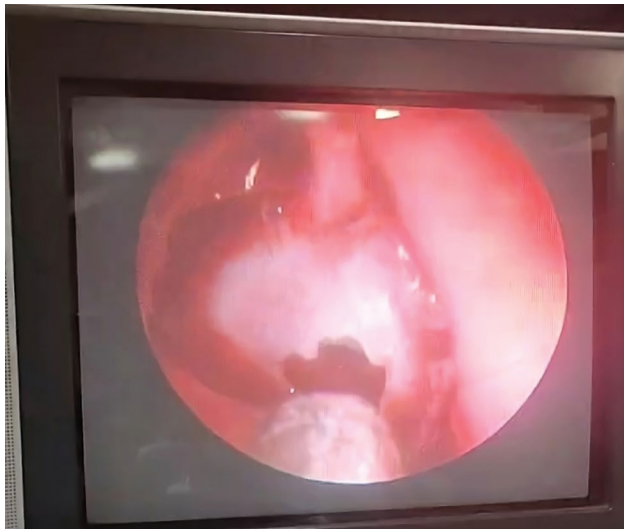
displacement and compression of optic chiasma and postero-superior displacement of the infundibulum. Imaging differentials included-Arachnoid Cyst and Rathke's cleft cyst. Preoperative diagnosis was made as- Sellar mass with Hypopituitarism (hypocortisolemia with hyponatremia with hypothyroidism). Pre-operative endocrinological optimization was done by exogenous T3, and T4 supplementation, injection Hydrocortisone was given for hypocortisolemia correction over a period of 15 days, and hyponatremia correction was done with hypertonic saline infusion. The patient underwent Trans-Nasal, Trans-Sphenoidal Endoscopic drainage of the sellar cyst with the closure of the dural defect with Tensor fascia lata and fat graft.

### Operative technique

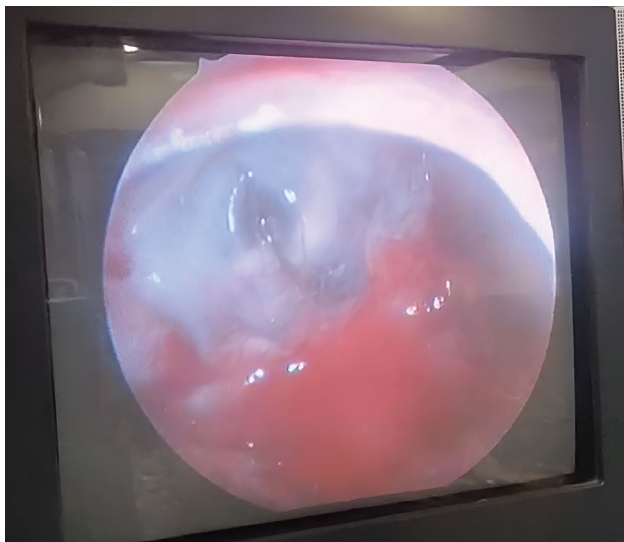
The patient was operated on under General anesthesia in an endoscopy suite under all aseptic precautions in the supine position. Using a zero-degree endoscope, a wide sphenoid ostium was found, through which a smooth bulge from the roof of the sphenoid sinus was seen. Hadad flap was elevated and reserved on the right side of the septum and posterior



**Figure 1:** Magnetic resonance imaging (MRI) brain indicated enlarged sella along with a cystic lesion.

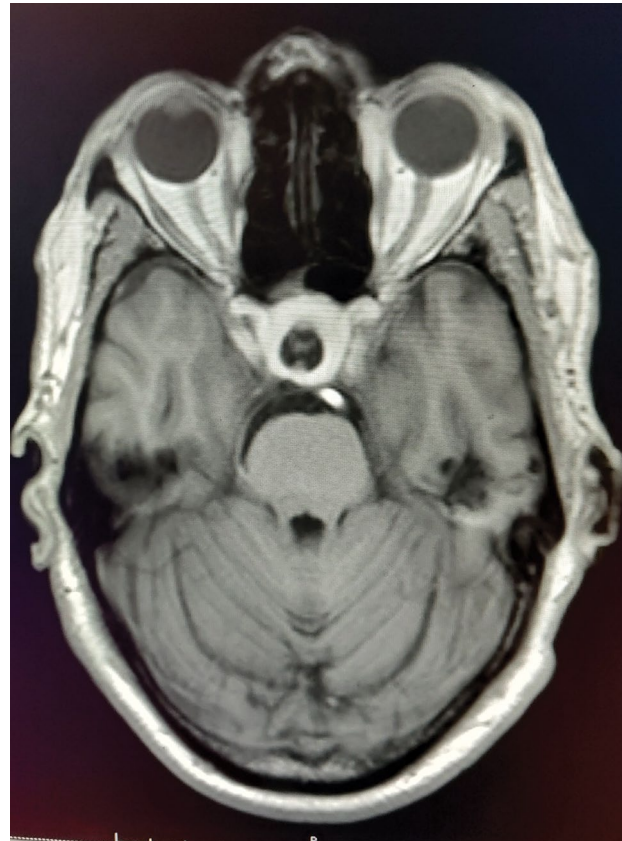


**Figure 2:** Opening the sellar floor revealed the cyst.



**Figure 3:** Cyst cavity was investigated and cleared.

septectomy was done. Opening the sellar floor revealed the cyst (Figure 2). The diaphragma revealed the chiasma and inferior pituitary stalk. A cyst cavity was investigated and cleared (Figure 3). Multiple fat plugs and fascia lata graft were inlaid into the cyst cavity after draining. Tissue glue was applied, Hadad flap was placed over the fascia lata graft, and the tissue glue was reapplied. Postoperative recovery was uneventful. The patient was discharged on day 4 following surgery on oral antibiotics, analgesics, hydrocortisone, and T4 supplementation. After the first follow-up at 3 weeks, repeat endocrinological investigations were done, which were suggestive of no hormonal deficits, and hence, exogenous T3, T4, and steroids were stopped. Disease relapse was absent. Following five months of frequent follow-up, the patient has recovered without neurological or endocrinological complications. Fat-like T1 hyperintensity was detected in postoperative MRI at 5 months (Figure 4).



**Figure 4:** Fat-like T1 hyperintensity was detected in postoperative MRI at 5 months.

## Discussion

Developing meninges end with the arachnoid membrane. Mesoderm surrounds the dura and neural tube early in embryonic development. CSF enters this mesh, separating the subarachnoid and subdural spaces. This septation begins at approximately 15 weeks of gestation. Incomplete separations within the mesh may contribute to the formation of septations within the subarachnoid space. Fluid is then trapped within a compartment isolated from the cisternal CSF circulation. Meyer, et al. hypothesized Intrasellar Arachnoid Cysts between arachnoid layers. Diverticula develop above the diaphragm as well as expand through its aperture or subdiaphragmatic arachnoid layers [4]. An IAC resembles a nonfunctional pituitary adenoma. The age of intrasellar arachnoid cysts is older than other intracranial cysts. Headache and vision problems are their most prevalent complaints. Dura distension causes headaches, whereas optic chiasm compression causes vision problems. Low-frequency endocrine symptoms involve the gonadotropic axis [5-7]. Our patient had diplopia and endocrinological symptoms. According to Elliot, et al. suprasellar arachnoid cysts are pure cystic lesions with no contrast enhancement or calcification and a typical CSF-like signal behavior, with hypointense T1- and hyperintense T2-weighted MRI signals [8]. MRI data supported these aspects in our instance. Rathke's cleft cyst (RCC) and Craniopharyngioma are common

IAC differential diagnoses. RCC and craniopharyngiomas often have rim-like cyst wall enhancement [5,8,9]. Both RCCs and craniopharyngiomas can calcify. A craniopharyngioma cyst has solid, contrast-enhancing components [4,10]. IAC has the same surgical indications as non-secreting adenomas: Pituitary dysfunction, compressions, and severe headaches. The transcranial or more common transsphenoidal approach can diagnose and remove the lesion. The patient underwent transsphenoidal surgery to diagnose and treat optochiasmatic compression without problems or recurrence.

## Conclusion

Intrasellar space occupying lesions predispose to symptoms like diplopia and endocrinological abnormalities. Since the sella turcica lacks leptomeninges and the arachnoid membrane lies below the diaphragma sellae, intrasellar cysts are rare. Along with other common sellar lesions, this rare intrasellar arachnoid cyst should always be kept as a differential when a patient presents with above said symptoms. The goal of surgical treatment is the reduction of the pressure exerted by the cyst on adjacent brain structures. The endoscopic transnasal transsphenoidal approach to sellar/suprasellar ACs is minimally invasive and favored. Nasoseptal flaps lower CSF leak risk without impairing nasal quality of life or requiring additional incisions. Long-term clinical, endocrinological and radiological follow-up is needed to detect late recurrences.

## Sources of Support

None.

## References

1. Starzyk J, Kwiatkowski S, Urbanowicz W, Starzyk B, Harasiewicz M, et al. (2003) Suprasellar arachnoid cyst as a cause of precocious puberty--report of three patients and literature overview. *J Pediatr Endocrinol Metab* 16: 447-455.
2. Baskin DS, Wilson CB (1984) Transsphenoidal treatment of nonneoplastic intrasellar cysts. A report of 38 cases. *J Neurosurg* 60: 8-13.
3. Dutt SN, Mirza S, Chavda SV, Irving RM (2002) Radiologic differentiation of intracranial epidermoids from arachnoid cysts. *Otol Neurotol* 23: 84-92.
4. Meyer FB, Carpenter SM, Laws ER Jr (1987) Intrasellar arachnoid cysts. *Surg Neurol* 28: 105-110.
5. Shim KW, Park EK, Lee YH, Kim SH, Kim DS (2013) Transventricular endoscopic fenestration of intrasellar arachnoid cyst. *Neurosurgery* 72: 520-528.
6. Dubuisson AS, Stevenaert A, Martin DH, Flandroy PP (2007) Intrasellar arachnoid cysts. *Neurosurgery* 61: 505-513.
7. Iqbal J, Kanaan I, Al Homsy M (1999) Non-neoplastic cystic lesions of the sellar region presentation, diagnosis and management of eight cases and review of the literature. *Acta Neurochir (Wien)* 141: 389-397.
8. Elliott RE, Tanweer O, Rubin BA, Koslow M, Mikolaenko I, et al. (2013) Suprasellar hamartoma and arachnoid cyst. *World Neurosurg* 80: e401-e407.
9. Bender B, Honegger JB, Beschoner R, Ernemann U, Horger M (2013) MR imaging findings in colloid cysts of the sellar region: Comparison with colloid cysts of the third ventricle and rathke's cleft cysts. *Acad Radiol* 20: 1457-1465.
10. Shin JL, Asa SL, Woodhouse LJ, Smyth HS, Ezzat S (1999) Cystic lesions of the pituitary: Clinicopathological features distinguishing craniopharyngioma, rathke's cleft cyst, and arachnoid cyst. *J Clin Endocrinol Metab* 84: 3972-3982.