



HAL
open science

Evaluating inflammations in high-resolution x-ray phase contrast images of SKG spondylarthritis mice models

Shifali Singh, Xavier Romand, Ludovic Broche, Bertrand Favier, Athan Baillet, Emmanuel Brun

► To cite this version:

Shifali Singh, Xavier Romand, Ludovic Broche, Bertrand Favier, Athan Baillet, et al.. Evaluating inflammations in high-resolution x-ray phase contrast images of SKG spondylarthritis mice models. *Developments in X-Ray Tomography XIV*, Aug 2022, San Diego, France. pp.47, 10.1117/12.2633894 . hal-04739474

HAL Id: hal-04739474

<https://hal.science/hal-04739474v1>

Submitted on 16 Oct 2024

HAL is a multi-disciplinary open access archive for the deposit and dissemination of scientific research documents, whether they are published or not. The documents may come from teaching and research institutions in France or abroad, or from public or private research centers.

L'archive ouverte pluridisciplinaire **HAL**, est destinée au dépôt et à la diffusion de documents scientifiques de niveau recherche, publiés ou non, émanant des établissements d'enseignement et de recherche français ou étrangers, des laboratoires publics ou privés.

Evaluating inflammations in high-resolution X-ray phase contrast images of SKG spondylarthritis mice models

Singh S.^a, Romand X.^b, Broche L.^c, Favier B.^b, Baillet A.^b, and Brun E.^a

^aUniversity Grenoble Alpes, Inserm, UA7, STROBE Laboratory, Grenoble, France

^bUniversity Grenoble-Alpes, TIMS-CNRS UMR552538700 La Tronche, France

^cESRF-The European Synchrotron 38043 Grenoble, France

ABSTRACT

Spondyloarthritis is an inflammatory rheumatic disease characterized by inflammation of the bone and soft tissues, such as enthesis and synovial membrane, in the spine and peripheral joint. Early diagnosis of this disease plays an important role in deciding the possible treatments but has remained a challenge for decades. Several imaging modalities exist, such as X-ray radiography, Magnetic Resonance Imaging (MRI), and Computed Tomography (CT). However, they are not suitable for the early diagnostics of Spondyloarthritis because of their inability to depict active inflammations. This paper demonstrates the application of a novel X-ray phase contrast imaging (PCI) technique that allows imaging of weakly absorbing tissues with better sensitivities than other conventional imaging modalities.

A PCI imaging procedure involving 6 affected (SKG induced) and 6 control mice ankles was carried out at the European Synchrotron (ESRF). Results from the high-resolution X-ray phase contrast tomography performed on the mice's ankles are presented. It was observed that the improved contrast of the soft tissues could allow us to visualize the inflammations in the form of swelling of the synovial membrane. Deep learning techniques are used to segment and evaluate inflammations. The results obtained in this work highlight the ability of the PCI technique to detect inflammations more efficiently than the other conventionally existing modalities.

Keywords: X-ray, phase contrast imaging (PCI), synchrotron, segmentation, spondylarthritis, inflammation

1. INTRODUCTION

Spondyloarthritis (SpA) is an inflammatory rheumatic disease characterized by inflammation of the bone and soft tissues, such as enthesis and synovial membrane. There are broadly two types of SpA, axial SpA, and peripheral SpA. Axial SpA can affect the spine and involves back pain and morning stiffness in the spine. Peripheral SpA occurs in the peripheral joint that leads to peripheral symptoms like arthritis or enthesitis. Early diagnosis of SpA remains a challenge for decades.¹ Clinical signs of SpA are non-specific and thus require imaging methods for its diagnosis. Conventional X-ray radiography which is widely available is recommended for the first assessment of the disease.² However, due to its low reliability in imaging complex anatomy, this imaging modality is not suitable for its diagnosis. CT scan can provide a precise assessment of the structural changes, but it is not able to depict active inflammations.³ MRI examination of the joint substantially improved its early diagnosis, as the disease can detect active inflammatory changes which occur months to years before structural damages are visible on X-rays. However, there are concerns related to the specificity of the method and related false-positives.

A novel X-ray phase contrast imaging (PCI) technique that allows imaging of weakly absorbing tissues with better sensitivities than other conventional imaging modalities,⁴ can be used to detect inflammations. This article presents the results from the X-ray phase contrast tomography performed on 6 SKG induced and 6 control mice ankles. The experiments were carried out at the European Synchrotron (ESRF). The following sections will present the imaging methodology adopted to image the samples, followed by the segmentation procedure and a series of data analysis procedure that was carried out to compute the inflammations in the joints using deep learning techniques.

Further author information: (Send correspondence to Brun E.)
Brun E.: E-mail: emmanuel.brun@inserm.fr

2. IMAGING METHODOLOGY

2.1 Phase contrast imaging

PCI is based on the principle that when X-rays pass through an object, they not only are attenuated but also are refracted. For light elements such as soft human tissues, its refractive index can be as high as a thousand times compared to its absorption part.⁵ This results in an improved contrast of soft tissues together with the hard tissues and is called Phase Contrast Imaging (PCI) technique.⁶

2.2 Imaging protocol

The imaging procedure involved 6 affected and 6 control post-mortem mice ankles, removed and embedded in agarose. The imaging of the models was carried out at the ID19 beamline of European Synchrotron Radiation Facility (ESRF). In this series of experiments, propagation based PCI technique was implemented to obtain a good contrast between the soft and the hard tissues. This imaging setup involves a highly coherent monochromatic X-ray radiation, impinged on a rotating sample stage and collected on a detector screen placed at a long sample to detector distance of 4 m. This long-distance allows us to measure the interference between the radiation refracted by the sample and the unchanged beam. At the synchrotron, we used the ID19 undulator source to produce a narrow polychromatic beam centered around 26 keV energy range. For a $13.6 \times 13.6 \times 11 \text{ mm}^3$ volume of the scan and a voxel size of $3 \times 3 \times 3 \mu\text{m}^3$, an acquisition of about 30 minutes was carried out on the samples. A Gadox (Gadolinium oxysulfide phosphor) scintillator screen translates the X-ray to visible light using a mirror and is recorded by a camera placed orthogonal to the axis of the radiation. An sCMOS camera (PCO edge) with 2560×2180 pixels was used to capture the images. A so-called Paganin algorithm⁷ was used to extract the phase information from the raw projections. The δ/β value was set to the bone in order to have sufficient contrast but to limit over-shining effects. ‘Nabu’, a tomography processing software is used to reconstruct the projections.⁸

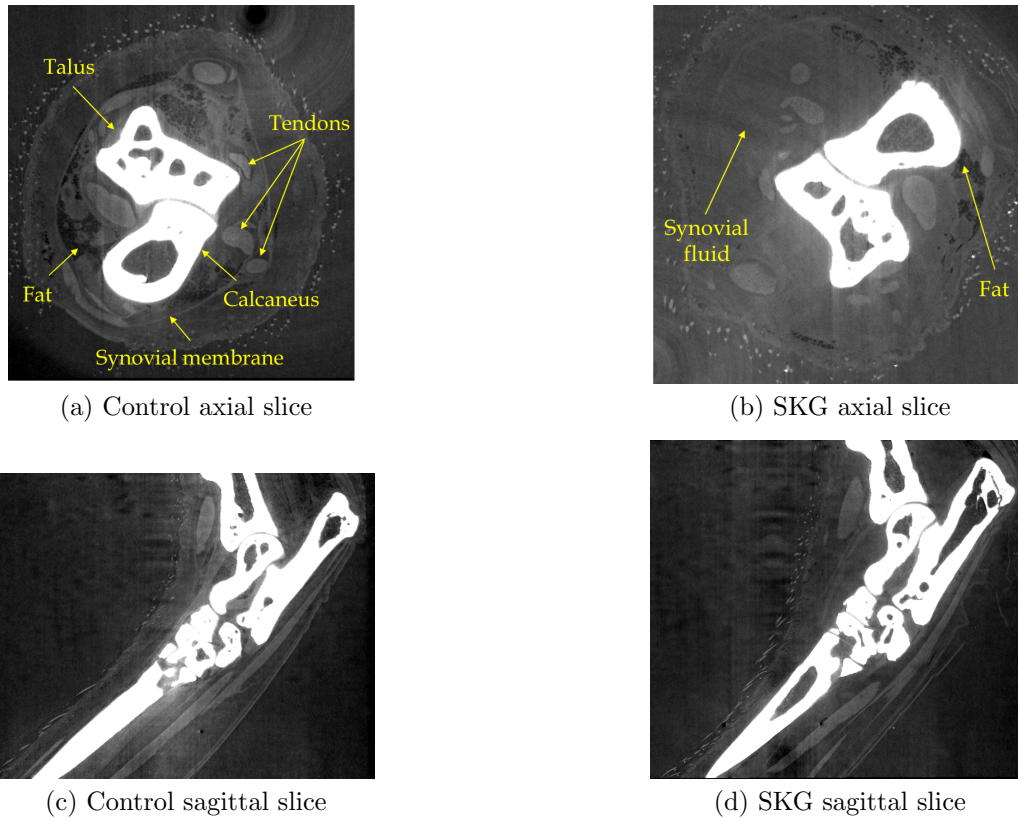


Figure 1. The axial and sagittal slices of control and SKG induced mice ankles

Axial and sagittal phase contrast images of an SKG induced and control mice ankles are shown in Fig. 1. As can be seen in Fig. 1, this imaging technique is able to detect all the different tissues of a joint. Bones, fat, tendons, ligaments, and synovial membrane are clearly distinguishable in the image, which has never been so clearly observed with other imaging modalities, as seen in osteoarticular assessments.⁹ In the acquisitions, it is evident that the SKG mouse model possesses some swelling in its dorso-lateral region in comparison to the control one. Synovial fluid in the infected model appears as uniform areas replacing or displacing the synovial membrane or fat in the control one. Measuring this increase in synovial fluid volume could serve as one of the ways of characterizing the presence of SpA.

3. IMAGE SEGMENTATION AND ANALYSIS

The data analysis of the high resolution phase contrast ankle images poses a challenge as the size of the data of each ankle is about 330 GB. Manual segmentation of this huge volume of data would require a great deal of time and effort. Deep learning technology can be handy in analyzing these enormous amounts of data sets. The inflammation in the ankle was instinctively decided to be measured by segmenting the bone and the soft tissues in the Talus Astragalus dorso-lateral region using deep learning techniques and taking their ratio. We chose to take ratios instead of the difference, to account for changes in animal size. This ratio was believed to be one of the potential indicators of Spondyloarthritis.

To carry out this work, an open-source image processing software called Dragonfly¹⁰ is used for the processing and segmentation of the data. The deep learning module works by training different models such as random forest and U-Net on a slice of the entire volume by categorizing the pixels belonging to different classes; in our case: bones, soft tissue, and background. The generated models can be checked for their prediction on other slices of the image. The model giving better prediction on the second slice can be chosen for further training to improve its learning. These steps can be followed on other slices in order to improve the prediction of the model. Once the model is trained, it is applied to each pixel of the image to get the classified output image. The developed model, in this case, U-net, can also be applied to other volumes of the ankle for their segmentation. Additional post-processing techniques, such as opening, closing, and fill holes were applied as the final step to segment soft tissue and bone volume in the talus astragalus region. One such 3D segmented example of an affected and control mouse ankle in the dorso-lateral region is shown in Fig. 2. The volume of the segmented soft tissue and the bones in the dorso-lateral region for each of the mice ankle samples was then computed to calculate their ratio. Computing this ratio would be an indicator to quantify the inflammation in the infected mice ankles. Higher the ratio, the higher the swelling. The volumes and their ratio are synthesized in Table 1. As can be seen in Table 1, for a majority of cases, the ratio of the volumes of the bone to soft tissues is higher for the SKG samples as compared to the control ones. However, for two of the samples (67 and 68), it was not the case. In sample 68, an abnormality was observed in terms of the bone ossification of the fibula which lead to an increase in the bone volume, thus reducing the ratio.




Figure 2. Segmented soft tissue and bones in the dorso-lateral region of a control (left) and SKG induced mouse ankle (right)

Table 1. Ratio of the soft tissue volume w.r.t. bone volume for the twelve studied cases; six with SKG induced mice ankle samples and six with the control samples

Sample		Volume		Ratio
Sample Type	Sample Number	Bone	Soft Tissue	
Control Sample	S66	14.5 mm ³	3.8 mm ³	3.9
	S67	18.4 mm ³	4.0 mm ³	4.5
	S70	13.3 mm ³	4.6 mm ³	2.9
	S73	13 mm ³	3.9 mm ³	3.3
	S76	15.2 mm ³	4.5 mm ³	3.3
	S77	17 mm ³	4.7 mm ³	3.7
SKG Sample	S64	17.6 mm ³	3.7 mm ³	4.7
	S68	15.4 mm ³	4.5 mm ³	3.5
	S71	22.5 mm ³	4.5 mm ³	5.0
	S74	17.4 mm ³	4 mm ³	4.3
	S80	16 mm ³	4 mm ³	4.2
	S81	23 mm ³	4.0 mm ³	5.6

4. RESULTS AND CONCLUSIONS

This paper presents the results obtained from the PCI imaging carried out at ESRF on 6 affected (SKG induced) and 6 control mice ankles to study Spondyloarthritis. X-ray phase contrast imaging proves to be a good candidate to observe inflammations in ankles of SKG Spondyloarthritis mouse model where inflammatory infiltrates, displaces, or replaces the fat in the dorso-lateral region. A preliminary analysis of the inflammation in the ankles was carried out by segmenting the bone and the soft tissues in the Talus Astragalus dorso-lateral region using a deep learning technique. A trained U-net model is applied to the rest of the models to detect the levels of inflammations in the different levels of SpA. It was found that the ratio of the volume of the soft tissues to bone is higher in the SKG samples in the majority of the cases. Thus, this imaging modality could help diagnose the onset of the disease based on the inflammation detected and also define its severity in patients suffering from SpA.

ACKNOWLEDGMENTS

The authors would like to thank the instrument scientists and technical staffs of ID19 beamline that helped in the successful conduct of the experiment at ESRF. Part of this research has been funded by the project FUI Gigaquant. The author would like to thank La Région Auvergne-Rhône-Alpes and BPI for supporting and funding this project.

REFERENCES

- [1] Redeker, I., Callhoff, J., Hoffmann, F., Haibel, H., Sieper, J., Zink, A., and Poddubnyy, D., “Determinants of diagnostic delay in axial spondyloarthritis: an analysis based on linked claims and patient-reported survey data,” *Rheumatology* **58**(9), 1634–1638 (2019).
- [2] Mandl, P., Navarro-Compán, V., Terslev, L., Aegerter, P., Van Der Heijde, D., D’Agostino, M., Baraliakos, X., Pedersen, S., Jurik, A., Naredo, E., et al., “Eular recommendations for the use of imaging in the diagnosis and management of spondyloarthritis in clinical practice,” *Annals of the rheumatic diseases* **74**(7), 1327–1339 (2015).
- [3] Poddubnyy, D., “Classification vs diagnostic criteria: the challenge of diagnosing axial spondyloarthritis,” *Rheumatology* **59**(Supplement_4), iv6–iv17 (2020).
- [4] Broche, L., Favier, B., Rougé-Labriet, H., Drevet, S., Lardy, B., Brun, E., and Lemasson, B., “Calcified cartilage revealed in whole joint by x-ray phase contrast imaging,” *Osteoarthritis and Cartilage Open* **3**(2), 100168 (2021).

- [5] Bravin, A., Coan, P., and Suortti, P., “X-ray phase-contrast imaging: from pre-clinical applications towards clinics,” *Physics in Medicine & Biology* **58**(1), R1 (2012).
- [6] Davis, T. J., Gao, D., Gureyev, T., Stevenson, A., and Wilkins, S., “Phase-contrast imaging of weakly absorbing materials using hard x-rays,” *Nature* **373**(6515), 595–598 (1995).
- [7] Paganin, D., Mayo, S. C., Gureyev, T. E., Miller, P. R., and Wilkins, S. W., “Simultaneous phase and amplitude extraction from a single defocused image of a homogeneous object,” *Journal of microscopy* **206**(1), 33–40 (2002).
- [8] Nabu 2021.2 [Computer tomography software] European Synchrotron radiation facility, Grenoble, France. The project is hosted on gitlab.esrf.fr/tomotools/nabu.
- [9] Drevet, S., Favier, B., Lardy, B., Gavazzi, G., and Brun, E., “New imaging tools for mouse models of osteoarthritis,” *GeroScience*, 1–12 (2022).
- [10] Dragonfly 2020.2 [Computer software] Object Research Systems (ORS) Inc, Montreal, Canada, 2020 software available at <http://www.theobjects.com/dragonfly>.