



HAL
open science

Assessment of the facial nerve temperature on cadaveric samples during otologic surgery milling

Martin Boillat, Anne-Sophie Bonnet, Cécile Parietti-Winkler

► **To cite this version:**

Martin Boillat, Anne-Sophie Bonnet, Cécile Parietti-Winkler. Assessment of the facial nerve temperature on cadaveric samples during otologic surgery milling. 2024. hal-04738038

HAL Id: hal-04738038

<https://hal.science/hal-04738038v1>

Preprint submitted on 15 Oct 2024

HAL is a multi-disciplinary open access archive for the deposit and dissemination of scientific research documents, whether they are published or not. The documents may come from teaching and research institutions in France or abroad, or from public or private research centers.

L'archive ouverte pluridisciplinaire **HAL**, est destinée au dépôt et à la diffusion de documents scientifiques de niveau recherche, publiés ou non, émanant des établissements d'enseignement et de recherche français ou étrangers, des laboratoires publics ou privés.



Distributed under a Creative Commons Attribution 4.0 International License

Assessment of the facial nerve temperature on cadaveric samples during otologic surgery milling

Martin Boillat

Laboratoire ICube, CNRS UMR 7357, Strasbourg, France

Anne-Sophie Bonnet *

Université de Lorraine, CNRS, Arts et Métiers ParisTech, LEM3, F-57000 Metz, France

Cécile Parietti-Winkler

Département d'Oto-Rhino-Laryngologie et Chirurgie Cervico-Faciale, CHRU Nancy, Nancy, France ; Université de Lorraine, Ecole de Chirurgie Nancy-Lorraine, Faculté de Médecine de Nancy, 54500 Vandœuvre-lès-Nancy, France

*Corresponding author. Email: anne-sophie.bonnet@univ-lorraine.fr

Keywords: Temporal bone;milling;facial nerve;temperature

1. Introduction

Surgical treatment of ear pathologies frequently involves milling of the temporal bone. This allows access to middle and inner ear target anatomical structures without damaging the auditory canal. This milling process generates heat, which is conducted in the bone and can cause potential damage to nearby living tissues. The facial nerve, used as an anatomical landmark during this procedure, is especially at risk due to its location in the vicinity of the surgical path (Peng et al. 2019). Efforts have been made by some authors to study the facial nerve temperature during surgical milling using one thermistor (Abbas and Jones 2001), but they were not able to precisely control the temperature probe's location. In the following are presented assessments of the facial nerve temperature during otologic surgery milling on cadaveric bones. The measurements were done using a novel approach, allowing for simultaneous temperature measurements at precisely controlled locations.

2. Methods

2.1 Cadaveric bones sampling

Three fresh cadaveric temporal bones (two right and one left) were obtained from one male and two female donors aged between 70 and 82 years old, provided by the Laboratory of Anatomy of Nancy University Hospital, France. Soft tissues were removed to expose

the external surface of the petrous pyramid and mastoid bone on all temporal bones. After sampling using a RemB surgical saw (Stryker), the bones were confined in hermetic boxes and underwent a CT scan (0.15 mm spatial resolution, Canon Medical Systems). Immediately after tomography, samples were frozen at -22°C and stored at the School of Surgery of Nancy, France, prior to the experiments.

2.2 Experimental protocol

The cadaveric temporal bones CT scans were manually segmented to obtain 3D representations of all anatomical structures. For each sample, a frame of reference was defined based on external surfaces. 4 target points, separated by about 1 mm, were chosen on the second portion of the facial nerve, close to the standard surgical path. Trajectories were then defined to access those points from the temporal bone medial surface, opposite to surgeon direction of approach during surgery, without intersecting with internal anatomical structures. Canals were then drilled in the bone (thawed at ambient temperature) using a CNC machine, enabling the insertion of 0.8 mm diameter K-type, PFA-insulated thermocouples (Omega Engineering) after prior injection of thermal paste to maximize thermal exchange. Thermocouples were connected to a NI CompactDAC™ using an analog NI-9219 module, allowing for acquisition of the temperature signals at a sample rate of 50 Hz with NI Labview™ 2020 software (National Instruments). Once instrumented, the temporal bones were immediately milled by an expert surgeon under a Zeiss operating microscope, using a Medtronic Indigo High-Speed Otologic Drill motor with a straight handpiece, an IPC console and an IPC System Multi-function Foot pedal. The milling intervention was performed at 22°C using irrigation, following the surgical path corresponding to the first steps of a cochlear implantation. An initial mastoidectomy was performed using 4 mm diameter carbide-tungsten round burr, followed by the skeletonization of the second portion of the facial nerve, with a 4 mm diamond round burr for all cadaveric bones milling. Post processing and analysis of the signals were done using Matlab™ R2020b software (Mathworks). After milling, thermocouples hot junction position was assessed by computed tomography, using an ultra-high resolution Aquilion precision™ CT scanner and GOM Inspect™ software (Carl Zeiss).

3. Results and discussion

For each milled sample, the variation of temperature relative to room temperature was computed to enable comparison (illustrated on Figure 1 below). During mastoidectomy, the temperature rise did not exceed

2.3°C for bone 1, 1.4°C for bone 2 and 3.8°C for bone 3. During skeletonization, we obtained a maximum variation of temperature of respectively 3.0°C, 2.6°C, and 5.8°C for samples 1, 2 and 3.

As short temperature spikes are observed when the tool approaches thermocouples, these measurements can be considered representative of the temperature elevation in the human body due to the reduced heat exchange time with the surroundings. Differences between signals provided by each thermocouple are visible, but they all display coherent behavior relative to each other.

We also observe higher temperature increases for the third cadaveric bone compared to the first two samples, which could be attributed to the biological variability of the cadaveric temporal bones (variation in anatomical structures size and mechanical properties, presence of blood...).

Despite the largest amount of bone being milled during mastoidectomy, the greatest increase in temperature was observed during skeletonization. This is explained by the greater distance between the milling area and the thermocouples' hot junction during mastoidectomy, whereas the surgeon approaches the facial nerve very closely during skeletonization. The differences observed between thermocouple signals depends on their position relative to the tool trajectory.

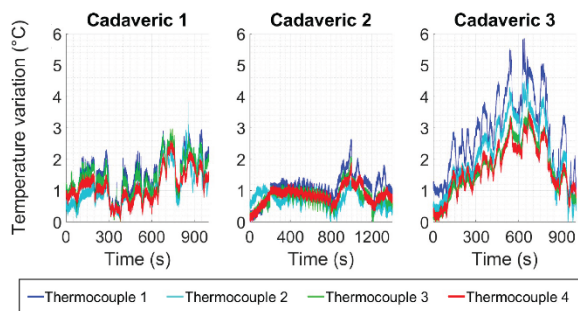


Figure 1. (a) Temperature variation measured during the skeletonization phase and for all cadaveric temporal bones.

The normal distance between the hot junction of each thermocouple and the facial nerve surface was also computed to evaluate the positioning protocol precision (Table 1). All hot junctions were located under 2 mm from the facial nerve, with the closest being at a distance of 0.3 mm, showing good repeatability of the insertion protocol. Furthermore, these distances enable the evaluation of the actual nerve temperature representativity by each thermocouple measurement.

Table 1. Normal distance from each thermocouple hot junction to the facial nerve surface

Sample	Th.1	Th.2	Th.3	Th.4
Bone 1	1.8	1.7	0.7	2.0
Bone 2	0.9	1.6	1.1	1.8
Bone 3	1.3	1.1	0.5	0.3

4. Conclusions

The temperature in the vicinity of the facial nerve has been measured during a standard otologic surgical intervention. The precision of those measurements has been evaluated through quantification of the actual distance of the thermocouples to the facial nerve. In the future, it would be interesting to estimate the thermal dose applied and assess potential damage on the facial nerve. The influence of the cutting parameters and surgeon gesture on the risk of hyperthermia damage of the facial nerve could also be further investigated.

Acknowledgements

We thank the School of Surgery of Nancy for its contribution to the experiments.

Funding

This work was supported by the Région Grand Est and the ID+ Lorraine Foundation.

Conflict of interest statement

All authors declare that they have no conflict of interest.

References

- Peng T, Ramaswamy AT, Kim AH. (2019). Common Otologic Surgical Procedures: Clinical Decision-Making Pearls and the Role of Imaging. *Neuroimaging Clin N Am* [Internet]. 29(1):183–196. <https://doi.org/10.1016/j.nic.2018.09.008>
- Abbas GM, Jones RO. (2001). Measurements of drill-induced temperature change in the facial nerve during mastoid surgery: A cadaveric model using diamond burs. *Annals of Otolaryngology, Rhinology and Laryngology*. 110(9):867–870.

Received date:07/04/2024

Accepted date: 28/06/2024

Published date: XX/XX/2024

Volume: 1

Publication year: 2024